

October 2012

## Retinal Image Analysis: A Review

S. R. Nirmala

*Department of Electronics and Electrical Engineering Indian Institute of Technology Guwahati,*  
nirmala@iitg.ernet.in

Malaya Kumar Nath Mr

*I.I.T. Guwahati, INDIA,* malaya@iitg.ernet.in

Samarendra Dandapat

*Department of Electronics and Electrical Engineering Indian Institute of Technology Guwahati,*  
samaren@iitg.ernet.in

Follow this and additional works at: <https://www.interscience.in/ijcct>

---

### Recommended Citation

Nirmala, S. R.; Nath, Malaya Kumar Mr; and Dandapat, Samarendra (2012) "Retinal Image Analysis: A Review," *International Journal of Computer and Communication Technology*. Vol. 3 : Iss. 4 , Article 9.

DOI: 10.47893/IJCCT.2012.1154

Available at: <https://www.interscience.in/ijcct/vol3/iss4/9>

This Article is brought to you for free and open access by the Interscience Journals at Interscience Research Network. It has been accepted for inclusion in International Journal of Computer and Communication Technology by an authorized editor of Interscience Research Network. For more information, please contact [sritampatnaik@gmail.com](mailto:sritampatnaik@gmail.com).

# Retinal Image Analysis: A Review

S. R. Nirmala, Malaya Kumar Nath and Samarendra Dandapat

Department of Electronics and Electrical Engineering

Indian Institute of Technology Guwahati

E-mail: [nirmala@iitg.ernet.in](mailto:nirmala@iitg.ernet.in), [malaya@iitg.ernet.in](mailto:malaya@iitg.ernet.in) and [samaren@iitg.ernet.in](mailto:samaren@iitg.ernet.in)

**Abstract**—Images of the eye ground or retina not only provide an insight to important parts of the visual system but also reflect the general state of health of the entire human body. Automated retina image analysis is becoming an important screening tool for early detection of certain risks and diseases like diabetic retinopathy, hypertensive retinopathy, age related macular degeneration, glaucoma etc. This can in turn be used to reduce human errors or to provide services to remote areas. In this review paper, we discuss some of the current techniques used to automatically detect the important clinical features of retinal image, such as the blood vessels, optic disc and macula. The quantitative analysis and measurements of these features can be used to better understand the relationship between various diseases and the retinal features.

**Index Terms**—Diabetic retinopathy, fundus image, image processing

## I. Introduction

The human eye (Fig. 1), which gives the sensation of vision including color differentiation and perception of depth due to the presence of rods and cones in the retina (sensory tunic) [1]. Neural layer present in the retina plays a direct role in vision and visual processing. The most important parts of the retina are optic disc (OD), macula, fovea and blood vessels. OD is the brightest region having elliptical shape which appears bright orange pink with a pale center [2]. OD is called blind-spot as it lacks photoreceptors. The blood vessels are emanating out from the OD. Lateral to the blind spot of the eye a hazy dark region having oval shape with a diameter of nearly 0.4 mm is present. It is called macula lutea (yellow spot). The center of the macula is called fovea (having size of a pin head), which contains only the cones and helps in acuity vision. Macula contains mostly the cones and its density declines gradually from the edge of macula to retinal periphery. The neural retina is nourished by the blood circulation in the central artery and central vein, which leave the eye through the center of the OD. These vessels give rise to a rich vascular network, which clearly visible non-invasively by the help of an ophthalmoscope.

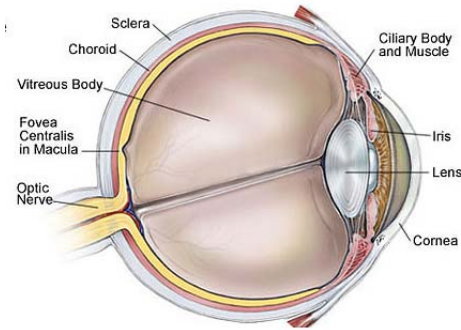


Fig. 1: Sagittal section of the human eye [3]

Due to modern living styles of human being different parts of the retina are affected and cause vision impairments. The different pathological conditions (diseases) of retina are: diabetic retinopathy (DR), macular degeneration and glaucoma. One of the serious complication in modern era is the DR occurs due to progression of diabetes. It causes damage to the different parts of the retina and leads to vision loss. DR is a progressive disease which approaches from non-proliferative diabetic retinopathy (NPDR) to the proliferative diabetic retinopathy (PDR). Microaneurysms, the small red dots in the color fundus photographs are the first clinical sign for the presence of DR [4]. During the PDR [3] stage the tiny blood vessels are blocked. So, new vessels grow to provide nutrients to the retina. These vessels are fragile and causes bleeding into the vitreous, which results cloud vision. The new vessels lead to retinal detachment and vision loss.

Age related macular degeneration (AMD) [5] occurs in the older group peoples, which affects the macula and the central vision. This occurs due to the non functionality of the bruch's membrane, which passes the waste products and the nutrients to the retina from the choroid. Fluid leaks out from the damaged vessels and deposited at the center of macula, which results blurring, obscuring or distorting vision [6]. These liquid deposits are called exudates.

According to Eduard Jaeger (1854) glaucoma [7] is a specific optic nerve disease occurs due to the progressive break down of nerve fibres and causes an elevated pressure in the optic nerve head (ONH). ONH contains the optic nerve fibres, which carries the sight image information to the brain. When a significant number of nerve fiber damaged by high fluid pressure blind spot develops in the field of vision and causes permanent vision loss. It is the second leading cause of vision loss in worldwide and its progression is expected to increase in the coming years [8]. One of the glaucomatous changes observed in the color fundus images is the appearance of optic disc (OD) i.e., enlargement of the depression called cup and thinning of the neuro-retinal rim (Fig 2).

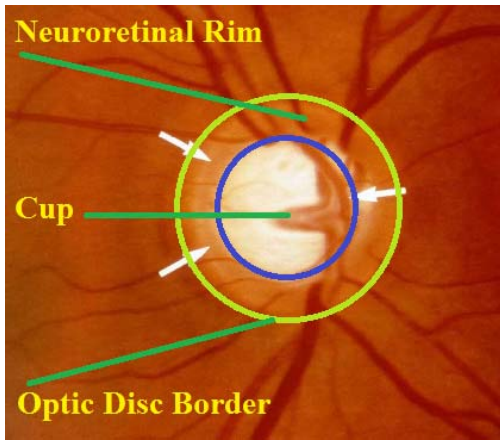


Fig. 2: Optic disc structure

The characteristic of different retinal features such as blood vessels, blood capillaries, OD, macula and fovea change due to different pathological conditions. New features such as microaneurysms, exudates, haemorrhages and cotton wool spots appear in the retina. Retinal image analysis is essential for the detection and diagnosis of various eye diseases that lead to vision loss. Fig. 3 shows the different features present in the normal and disease retina. In literature, a couple of techniques are available for the extraction of different features and measurement of the parameters for computer aided diagnosis.

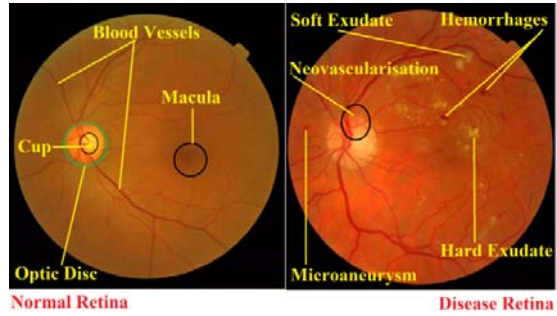


Fig. 3: Features in the retina

The different techniques for retinal image analysis available in the literature are reviewed in the Section II and the concluding remarks are made in Section III.

## II. Literature Review

Study of color fundus photographs is considered to be the best diagnostic modality available till date as it is reliable, non-invasive and easy to use. It allows recording the diagnostic data and enabling the ophthalmology consultation afterwards. The digital fundus camera easy to file images in portable format, which helps automatic diagnosis of different retinal diseases.

### A. Retinal Image Acquisition

Retinal images are acquired by a specialized camera called fundus camera. Mydriatic and non-mydriatic [9] fundus cameras are used for retinal photography. Mydriatic camera requires dilation of pupils. It provides good quality fundus images than non-mydriatic camera. Non-mydriatic cameras are smaller and easy to operate. In this case the images are worse and field of view (FOV) is smaller. The camera uses a flash lamp, which sends light to the retina through optical mirrors and lenses. The images are color images. For diagnostic purposes both the color and red free images are used. Fluorescein angiography and optical coherence tomography (OCT) [10] are also used for diagnosis of DR. Fluorescent dye (sodium fluorescein) is injected into the patient body in fluorescein angiography and the image is called angiogram. Sometime the dye causes side effect and nausea. Fluorescein angiography helps in providing the information about microaneurysms, capillary non perfusion and vessel leaking. OCT uses a broad band light (laser) to produce the two dimensional cross

sectional image of ocular tissue. It measures the reflected time delay from the different tissue layers by the help of low coherence interferometer. It produces 3-D images of retina (specially macular swelling) by composing several axial scans and several OCT images.

Other imaging modalities used in eye examination [10] are adaptive optics ophthalmoscopy, color Doppler imaging, computed tomography, confocal laser scanning microscope, magnetic resonance, ophthalmic ultrasound, retinal thickness analyzer and scanning laser polarimetry. Study of fundus image aims the prevention of DR by controlling the complications of the diabetes in eye through life style and early treatment. Automatic and semi automatic algorithms provide a potential solution for detecting eye diseases and prevent vision loss. The literature on automatic retinal image analysis [11], [12] algorithms are classified according to the following broad categories:

- 1) Pre-processing (illumination correction and contrast enhancement)
- 2) Segmentation of different features (blood vessels and OD)
- 3) Detection of lesions (microaneurysms, exudates, haemorrhages and cotton wool spots)
- 4) Determination of glaucoma and AMD

#### B. Pre-processing

Pre-processing is an essential step in retinal image analysis which attenuates image variation by normalizing the original image with a reference model. It helps in reducing the intra image as well as inter image variability. Non uniform illumination results shading artifact [13] and degrades the efficiency of image analysis. Adaptive contrast enhancement [14] overcomes this problem. Wang *et al.*, [15] uses point transformation for intensity correction. Histogram equalization [16] reduces inter image variability.

#### C. Segmentation of different features

A number of algorithms are available for the detection of different features such as blood vessels, OD and macula.

Blood vessels segmentation helps in diagnosis and treatment of ophthalmologic conditions. Gray level variations in the cross section of the retinal vessels is Gaussian shaped [17]. So, matched filter is used for

segmentation of blood vessels [17], [18]. Hatanaka *et al.*, [19] extracts the blood vessels by using density analysis. Still the performance of the segmentation algorithms to be improved for better diagnosis. Nirmala *et al.*, [20] uses wavelet based techniques to capture the information present in the blood vessels in different sub bands. Fig. 4 shows the extracted blood vessels.

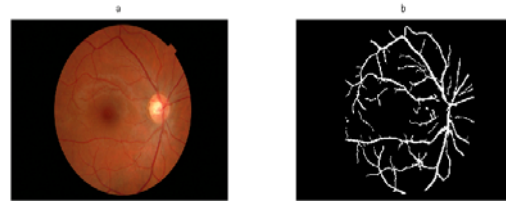


Fig. 4: Extraction of blood vessels (a) fundus image, (b) extracted blood vessels

Vascular changes such as change in width and tortuosity are usually associated with retinal disorders. Many retinal diseases are characterized by changes to retinal vessels. For example, a common condition associated with retinopathy of prematurity (ROP), characterized by increased vascular dilation and tortuosity.

Normal retinal blood vessels are straight or gently curved, but they become dilated and tortuous in a number of disease classes, including high blood flow, angiogenesis and blood vessel congestion. Tortuosity is known to track disease, one of the most important indicators in ROP [21], [22].

OD is the brightest region in the color fundus images. Lalonde *et al.*, [23] uses canny edge detector and Ghafar *et al.*, [24] uses circular hough transform for detecting OD. Youssif *et al.*, [25] detects OD by using vessel's direction matched filter. These methods are based on edge characteristics.

#### D. Detection of lesions

Microaneurysms [4], [26] are the first clinical sign for DR. Exudates are the protein deposits. Quellec *et al.*, [27] uses templet-matching based algorithm in wavelet domain to detect microaneurysms. Walter *et al.*, [28] detects the microaneurysms by morphological closing with linear structuring element. Osareh *et al.*, [6] uses image based criteria for assessing the diagnostic accuracy of an exudate detection technique.

## E. Determination of glaucoma and AMD

Glaucoma is a group of conditions defined by the progressive neuro-degeneration of the optic nerve which causes vision loss. Early diagnosis and optical treatment including screening examinations of the retinal fundus photographs [29] can minimize vision loss. One of the glaucomatous change observed in the color fundus images is the appearance of optic disc (OD) i.e., enlargement of the depression called cup and thinning of the neuroretinal rim (Fig 2). The cup to disc ratio (CDR) expresses the proportion of the disc occupied by the cup is widely accepted index for the assessment of glaucoma [7]. For normal eye it is found to be 0.3 to 0.5 [2]. As the ratio increases the more neuro-retinal degeneration occurs and the sight of vision is lost completely at the CDR value 0.8.

## III. Conclusion

Human eye can be examined noninvasively for various clinical disorders using digital retinal image. Hence quantitative analysis of different features from retinal images has usually been studied. Automated image analysis has the potential to assist in the early detection of diseases. In this paper the clinical features associated with retina and algorithms for feature detection have been discussed. The segmentation of retinal image features provides the basis for automated assessment of various eye related diseases. Hence it is essential to detect the retinal features quickly and accurately. Different measurements can then be done to help doctors in making better diagnosis.

## REFERENCES

- [1] E. N. Marieb, *Human Anatomy and Physiology*. Pearson, sixth edition ed., 2006.
- [2] <http://www.optic-disc.org/>
- [3] <http://www.nei.nih.gov/>
- [4] M. Neimeijer, B. van Ginneken, M. J. Cree, A. Mizutani, G. Quellec, C. I. S'anchez, B. Zhang, R. Hornero, M. Lamard, C. Muramatsu, X. Wu, G. Cazuguel, J. You, A. Mayo, Q. Li, Y. Hatanaka, B. Cochener, C. Roux, F. Karray, M. Garcia, Hiroshi Fujita, and M. D. Abramoff, "Retinopathy online challenge: Automatic detection of microaneurysms in digital color fundus photographs," *IEEE Transactions on Medical Imaging*, vol. 29, pp. 185–195, January 2010.
- [5] [www.maculardisease.org](http://www.maculardisease.org).
- [6] A. Osareh, B. Shadgar, and R. Markham, "A computational intelligence-based approach for detection of exudates in diabetic retinopathy images," *IEEE Transaction on Information Technology in Biomedicine*, vol. 13, pp. 535–545, July 2009.
- [7] R. Bock, J. Meier, L. G. Nyl, J. Hornegger, and G. Michelson, "Glaucoma risk index: Automated glaucoma detection from color fundus images," *Medical Image Analysis*, vol. 14, pp. 471–481, June 2010.
- [8] H. A. Quigely and A. T. Broman, "The number of people with glaucoma worldwide in 2010 and 2020," *British Journal of Ophthalmology*, vol. 90, pp. 262–267, March 2006. [hquigley@jhmi.edu](mailto:hquigley@jhmi.edu).
- [9] D. Huang, P. K. Kaiser, C. Y. Lowder, and E. I. Traboulsi, *Retinal Imaging*. Mosby Elsevier, 2006.
- [10] R. A. U, W. L. Yun, E. Y. Ng, W. Yu, and J. S. Suri, "Imaging systems of human eye: A review," *Journal of Medical Systems*, vol. 32, pp. 301–305, August 2008.
- [11] N. Pattona, T. M. Aslamc, T. MacGillivrayd, I. J. Dearye, B. Dhillonb, R. H. Eikelboomf, K. Yogesana, and I. J. Constablea, "Retinal image analysis: Concepts, applications and potential," *Progress in Retinal and Eye Research: Elsevier*, vol. 25, pp. 99–127, 2006.
- [12] R. Windera, P. Morrow, I. McRitchiea, J. Bailiee, and P. Hart, "Algorithms for digital image processing in diabetic retinopathy," *Computerized Medical Imaging and Graphics*, vol. 33, pp. 608–622, December 2009.
- [13] A. Hoover and M. Goldbaum, "Locating the optic nerve in retinal images by using fuzzy convergence of the blood vessels," *IEEE Transaction on Medical Imaging*, vol. 22, pp. 951–958, August 2003.
- [14] R. C. Gonzalez, *Digital Image Processing*. PHI, New Delhi-110001: Prentice Hall of India, Second ed., 2006.
- [15] W. H. H. W, G. KG, and L. ML, "An effective approach to detect lesions in color retinal images," pp. 1–6, *Conference on Computer Vision and Pattern Recognition, IEEE*, August 2000.
- [16] M. Petrou and C. Petrou, *Image Processing the Fundamentals*. Singapore: Wiley, second edition ed., 2010.
- [17] A. Hoover, V. Kouznetsova, and M. Goldbaum, "Locating blood vessels in retinal images by piecewise threshold probing of a matched filter response," *IEEE Transaction on Medical Imaging*, vol. 19, pp. 203–210, March 2000.
- [18] L. Zhang, Q. Li, J. You, and D. Zhang, "A modified matched filter with double sided thresholding for screening proliferative diabetic retinopathy," *IEEE Transactions on Information Technology in Biomedicine*, vol. 13, pp. 528–534, July 2009.
- [19] Y. Hatanaka, T. Nakagawa, Y. Hayashi, T. Hara, and H. Fujita, "Improvement of automated detection method of haemorrhages in fundus images," (Vancouver, British Columbia, Canada), pp. 5429–5432, EMBS, IEEE, August 2008.
- [20] S. Nirmala, S. Dandapat, and P. Bora, "Wavelet weighted blood vessel distortion measure for retinal images," *Biomedical Signal Processing and Control*, vol. 5, pp. 282–291, July 2010.
- [21] G. Dougherty, M. J. Johnson, and M. D. Wiers, "Measurement of retinal vascular tortuosity and its application to retinal pathologies," *Medical and Biological Engineering and Computing*, vol. 48, pp. 87–95, December 2009.
- [22] C. Heneghan, J. Flynna, M. O. Keefe, and M. Cahill, "Characterization of changes in blood vessel width and tortuosity in retinopathy of prematurity using image analysis," *Medical Image Analysis*, vol. 6, pp. 407–429, December 2002.

- [23] M. Lalonde, M. Beaulieu, and L. Gagnon, "Fast and robust optic disc detection using pyramidal decomposition and haussdroff based templet matching," *IEEE Transactions on Medical Imaging*, vol. 11, pp. 1193–1200, November 2001.
- [24] R. A. A. Ghafar, T. Morris, T. Rutchings, and I. Wood, "Detection and characterisation of the optic disc in glaucoma and diabetic retinopathy," in *Medical Image Understand Annual Conference*, (London, UK), pp. 23–24, September 2004.
- [25] A. A.-H. A.-R. Youssif, A. Z. Ghalwash, and A. A. S. A.-R. Ghoneim, "Optic disc detection from normalized digital fundus images by means of a vessels' direction matched filter," *IEEE Transactions on Medical Imaging*, vol. 27, pp. 11–18, January 2008.
- [26] M. Niemeijer, M. D. Abr`amoff, and B. van Ginneken, "Segmentation of the optic disc, macula and vascular arch in fundus photographs," *IEEE Transactions on Medical Imaging*, vol. 26, pp. 116–127, January 2007.
- [27] G. Quellec, M. Lamard, P. M. Josselin, G. Cazuguel, B. Cochener, and C. Roux, "Optimal wavelet transform for the detection of microaneurysms in retinal photographs," *IEEE Transactions on Medical Imaging*, vol. 27, pp. 1230–1241, September 2008.
- [28] T. Walter, P. Massin, A. Erginay, R. Ordonez, C. Jeulin, and J. -C. Klein, "Automatic detection of microaneurysms in color fundus images," *Medical Image Analysis*, vol. 11, pp. 555–566, May 2007.
- [29] <http://www.moorfields.nhs.uk/>