

Cerebrospinal Fluid Involvement in a Case of Visceral Leishmaniasis Associated with Hemophagocytic Lymphohistiocytosis

Mahmoud Fathalla, Javad Hashim, Hussein Alkindy, *Yasser Wali

تأثر السائل النخاعي في حالة الليشمانيا الاحشائية المرافقة لخلايا مرض بَلْعَمَةُ الكَرِيَّات

محمود فتح الله، جافاد هاشم، حسين الكندي، ياسر والي

الملخص: إن مرض بَلْعَمَةُ الكَرِيَّات اللَّيْمُفَاوِيَّ المُنْسِجِيَّ البلازماوي هو مرض يتميز بتكاثر حميد للخلايا المُنْسِجِيَّة المناعية بالأنسجة وتقوم هذه الخلايا بالتهام الكَرِيَّات الحُمْر . ويشمل هذا المرض نوعين أحدهما وراثي والآخر ثانوي . حدثت تغيرات في السائل النخاعي مثل تكاثر في الخلايا الليمفاوية وأحيانا حصل عملية البلعمة وأيضا تكاثر في الخلايا المناعية في النوع الوراثي فقط. وفي هذا التقرير نشرح حاله طفل ذكر عمره عشرة أشهر مصاب بالنوع الوراثي من المرض . وكان عنده بَلْعَمَةُ الكَرِيَّات في السائل النخاعي في النوع الوراثي فقط. عولج سنة 2004 دون تحسن . في فحص نقي العظم الثاني تبين أن هناك أجسام الليشمانية الدونوفانية (الليشمانيا الاحشائية). عولج على هذا الأساس وقد تحسن بشكل كبير . وعلى حد علمنا أن هذه أول حالة من مرض بَلْعَمَةُ الكَرِيَّات اللَّيْمُفَاوِيَّ المُنْسِجِيَّ البلازماوي مع وجود بَلْعَمَةُ الكَرِيَّات في السائل النخاعي .

مفتاح الكلمات: بَلْعَمَةُ الكَرِيَّات، لِيْمُفَاوِيَّ مُنْسِجِيَّ بلازماوي، ثانوي، سائل نخاعي، تقرير حالة . عمان.

ABSTRACT Hemophagocytic Lymphohistiocytosis (HLH) implies a benign generalized histiocytic proliferate with erythrophagocytosis and it includes familial hemophagocytic lymphohistiocytosis and secondary hemophagocytosis. Spinal fluid changes like mild to moderate pleocytosis (most of the cells are lymphocytes and macrophages) and sometimes hemophagocytosis are seen in primary HLH but are not reported in secondary HLH. Here we report a case of a previously healthy 10 months old male infant who was diagnosed as familial HLH with evidence of CSF hemophagocytosis. He was started on the HLH 2004 treatment protocol with no improvement. A second bone marrow aspiration revealed *leishmania donovani* antibodies and he was started on anti-leishmania treatment with dramatic response. To the best of our knowledge, this is the first case of secondary HLH with evidence of hemophagocytosis in cerebrospinal fluid.

Key words: Lymphohistiocytosis, hemophagocytic; Leishmaniasis; Cerebrospinal fluid; Case Report; Oman.

HAEMOPHAGOCYTIC LYMPHOHISTIOCYTOSIS (HLH) includes familial haemophagocytosis (FHLH) and secondary haemophagocytic syndrome. Primary (Familial) HLH is an autosomal recessive disease. By homozygosity mapping, two loci for FHLH have been identified, one each at 9q213-22 FHL1 and 10q21-22 (FHL2). The incidence of FHLH is approximately one case per 50,000 live births. Males and females are affected at equal frequencies and 80% of

cases present in the first year of life.¹ In Oman, 27 cases have been diagnosed so far, most of them (24) familial; genetic study was done in 8 families.^{2,3} The typical HLH is diagnosed on the basis of Hentel et al's guidelines.¹ Secondary HLH may occur at any age, commonly in association with immunosuppressive therapy, infection (usually viruses) and or malignancy. The central nervous system (CNS) symptoms are usually linked to familial HLH. This is a rare case of secondary HLH that

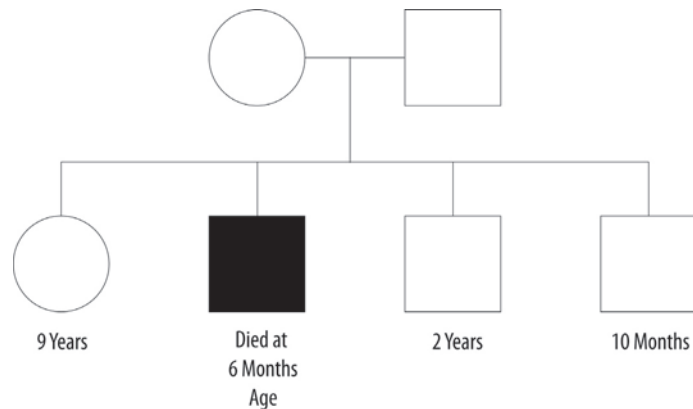


Figure 1: *There was a family history of unexplained death of one of his siblings*

presented with CNS symptoms as well as evidence of CSF haemophagocytosis.

CASE REPORT

A 10 month old Omani male infant, was referred to Sultan Qaboos University Hospital, (SQUH) Oman, from a peripheral Omani hospital as a suspected case of HLH. He was admitted to SQUH with a history of high grade fever associated with diarrhoea and vomiting for the previous two weeks. He was a product of a consanguineous marriage, with no past history of diseases or previous admissions to hospitals; however, there was the unexplained early infant death of one of his siblings in his family history.

On examination, he was sick looking, febrile, pale and had tachycardia. There was splenomegaly of 10 cm below the left costal margin and a large liver of 7 cm. After his admission, he developed generalized convulsions that responded to IV Phenytonin treatment (loading followed by maintenance).

His complete blood count showed evidence of pancytopenia with WBC $2.37 \times 10^9/L$; absolute neutrophil count was $0.36 \times 10^9/L$ and platelets were $14.1 \times 10^9/L$. Other laboratory investigations revealed: lactate dehydrogenase 829; erythrocyte sedimentation rate 47; C-reactive protein 65; albumin 24; serum ferritin 4687 ng/ml that increased to 25973 μ/ml within few days. Serum triglycerides were 3.0 mmol/L and fibrinogen was 1.9 g/L. Prothrombin time was 14 seconds and activated partial thromboplastin time was 55 seconds. Renal and liver function tests were within normal limits and hepatitis and HIV serology tests were negative. The bone marrow aspiration (BMA) was completely normal. The cerebrospinal fluid showed evidence of haemophagocytosis, Genetic study for perforin, Munc and syntaxin II genes were done in the SQUH genetic

laboratory and found to be negative. The results of these tests usually come after one month. A provisional diagnosis of primary (familial) HLH was established on the basis of the young age of presentation, the unexplained death of a 6 months old sibling and the severe clinical course.

Subsequently, treatment with HLH 2004 Protocol was started for 2 weeks. The child's fever continued to spike with no improvement. As per protocol, after 2 weeks, a second BMA was done and revealed *leishmania donovani* antibodies. The HLH 2004 protocol was stopped and IV Ambisome was started with no clinical improvement. Treatment was changed to Na-Stibogluconate (20mg/kg/day). He received a full course of 21 days and improved significantly with disappearance of the fever and organomegaly. The BMA showed no evidence of leishmania or haemophagocytosis. The patient was subsequently discharged home.

At a follow up visit after 6 months, he maintained his general well being and was completely normal.

DISCUSSION

HLH implies a benign, generalized histiocytic proliferation with erythrophagocytosis and it includes FHLH and secondary haemophagocytic syndrome^{1, 2, 4} associated with viral infections, protozoal infections and malignancy. These disorders are indistinguishable pathologically and are characterized as 'reactive' disorders of antigen-presenting and antigen-processing histiocytes. The hallmark of these disorders is marked haemophagocytosis in the lymphoreticular system.^{5, 6} The symptoms are supposed to be due to hyperactivity of macrophages.¹ The cause of the inappropriate immune activation in FHLH has been shown in some families to be due to the genetic encoding of perforin, Munc and syntaxin II.^{7, 8} The

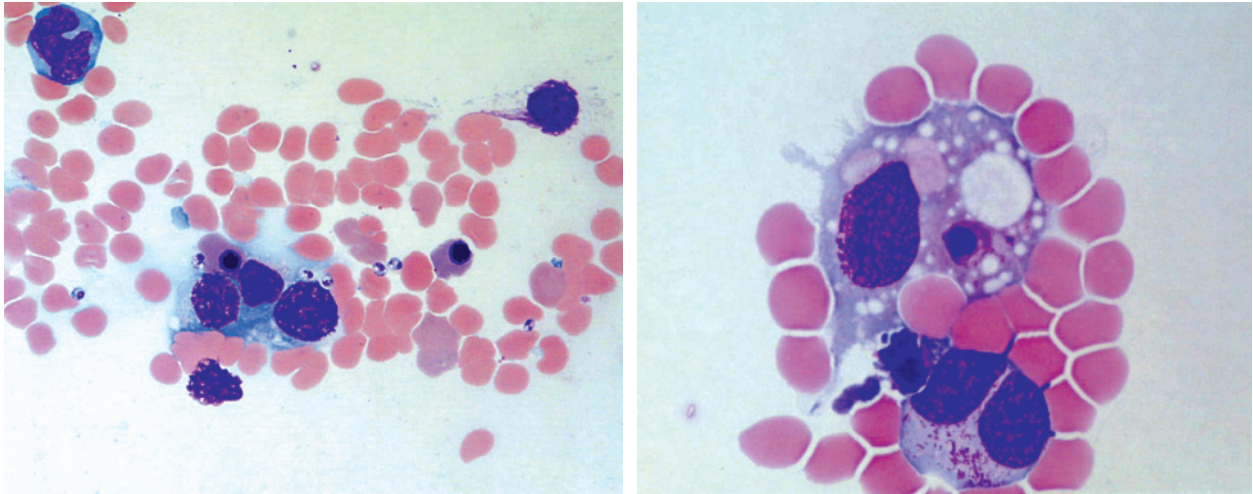


Figure 1: Cerebrospinal fluid showing histiocytes with evidence of hemophagocytosis.

typical HLH is diagnosed on the basis of Henter et al's guidelines⁹: (a) Clinical criteria: fever and splenomegaly (both to be present); (b) Laboratory criteria: cytopenias (affecting 2 of 3 lineages in the peripheral blood); haemoglobin (<9 g/L); platelets (<100 x 10⁹/L); neutrophils (<1.0x10⁹); hypertriglyceridemia and/or hypofibrinogenemia fasting triglycerides ≥ 2.0 mmol/L or ≥ 3 SD of the normal value for age; fibrinogen (≥ 1.5 g/L or ≥ 3 SD); (c) Histopathological criteria: haemophagocytosis in the bone marrow or spleen or lymph nodes, cerebrospinal fluid (CSF) and no evidence of malignancy.

Neurological symptoms may complicate and sometimes dominate the clinical course of the familial cases. Hepatic abnormalities, including elevated serum transaminases or hyperbilirubinemia, appear to be related to the degree of liver involvement. Elevated ferritin, lactate and coagulation derangement are also common during active disease.¹⁰ The haemophagocytosis mostly affects erythrocytes, but occasionally also platelets and leukocytes.^{11, 12}

Infection by the protozoan pathogen leishmania is a public health problem in certain regions of Oman such as North Batinah.¹³ Although, there are a number of different species, all of which are transmitted by phlebotomine sand flies,¹² there are only two primary types of clinical disease: cutaneous and visceral leishmania (VL).¹⁴ Visceral leishmaniasis revealed by haemophagocytic syndrome (HS) is an extremely rare event that can cause considerable diagnostic difficulty. The first case of leishmaniasis revealed by a reactive HS was reported by Matzner et al and concerned a 22 year old adult.¹⁵ CNS involvement has been almost totally linked to primary FHLH. In a retrospective study

on visceral leishmaniasis carried out on 33 Omani children from 1993 to 1999 at Sultan Qaboos University Hospital, Oman,¹⁶ there was no haemophagocytosis. Two children had CNS involvement in the form of encephalopathy, but there was no haemophagocytosis in the CSF.

In another study regarding the current status of HLH in infants and children from the Division of Pediatrics, Children's Research Hospital, Kyoto, Japan,¹⁷ 82 cases of pediatric HLH without familial inheritance were studied. There were CNS symptoms in 32.3 cases, but none of them had spinal fluid haemophagocytosis. All of the cases revealed lymphohistiocytosis with the presence of haemophagocytosis in bone marrow and reticuloendothelial cells.¹⁸ From the Indian subcontinent, there are reports of secondary HLH following malaria and leishmaniasis (also called 'kala-azar').¹⁹ In 14 cases of secondary HLH following malaria and kala-azar there were no features of CSF haemophagocytosis. This is probably the first case of secondary HLH that presented with CNS symptoms with evidence of CSF haemophagocytosis.

REFERENCES

1. Henter JI. Biology and treatment of familial hemophagocytic lymphohistiocytosis. Importance of perforin in lymphocyte-mediated cytotoxicity and triggering of apoptosis. *Med Pediatr Oncol.* 2002; 38:305-309.
2. Al Lamki Z, Wali YA, Pathare A, Ericson K, Henter IJ. Clinical and genetic study of Hemophagocytic Lymphohistiocytosis (HLH) in Oman: Need for early treatment. *Pediatr Hematol Oncol* 2003; 20:603-609.
3. Muralitahran S, Al-Lamki Z, Dennison D, Christie BS, Wali YA, Zachariah M, et al. An Inframe Perforin gene deletion in familial hemophagocytic lymphocytosis is as-

- sociated with Perforin expression. *Am J Hematol* 2005; 78:59-63.
4. Henter JI, Tondini C, Pritchard J. Histiocyte disorders. *Crit Rev Oncol Hematol*. 2004; 50:157-174.
 5. Imashuku S, Hibi S, Todo S. Hemophagocytic lymphohistiocytosis in infancy and childhood. *J Pediatr* 1997; 130:352-358.
 6. Ladisch S, HO W. Immunologic and clinical effects of repeated blood exchange in familial erythrophagocytic lymphohistiocytosis. *Blood* 1982; 60:814-820.
 7. Stepp SE, Lagelouse RD, Le Deist F, Bhawan S, Certain S, Mathew PA, et al. Perforin gene defects in familial hemophagocytic lymphohistiocytosis. *Science* 1999; 286:1957-1959.
 8. Zur Stadt U, Beutel K, Kolberg S, Schneppenheim R, Kabisch H, Janka G, et al. Mutation spectrum in children with primary hemophagocytic lymphohistiocytosis: Molecular and functional analyses of PRF1, UNC13D, STX11 and RAB27A. *Hum Mutat* 2006; 27:62-68.
 9. Henter JI, Elinder G, Ost A. Diagnostic guidelines for hemophagocytic lymphohistiocytosis. The FHL Study Group of the Histiocyte Society. *Semin Oncol* 1991; 18:29-33.
 10. Favara B. Hemophagocytic Lymphohistiocytosis: A Hemophagocytic syndrome. *Semin Diagn Pathol* 1992; 9:63-74.
 11. Stephan JL. Histiocytoses. *Eur J Pediatr* 1995; 154:600-609.
 12. Sullivan JL, Woda BA. Lymphohistiocytic Disorders. In: Nathan DG, Oski FA, eds.: *Hematology of infancy and childhood*. 5th ed. Philadelphia: WB Saunders, 1998. p.1359-1380.
 13. Elnour B, Akinbami FO, Shakeel A, Venugopalan P. Visceral leishmaniasis in Omani children: a review. *Ann Trop Pediatr* 2001; 21:159-163.
 14. Pearson RD, Sousa AQ. Clinical spectrum of leishmaniasis. *Clin Infect Dis* 1996; 2:11-13.
 15. Kinmond S, Galea P, Simpson EM. Kala-azar in a Scottish child. *Lancet* 1989; 2:325.
 16. Matzner Y, Behar A, Beeri E, Herskko C. Systemic leishmaniasis mimicking malignant histiocytosis. *Cancer* 1979; 43:398-402.
 17. IB Elnour, FO Akinbami, Shakeel A. Visceral leishmaniasis in Omani children. A review. *Ann Trop Paediatr* 2001; 21:159-163.
 18. Imashuku S, Hibi S, Todo S. Hemophagocytic lymphohistiocytosis in infancy and childhood. *J Pediatr* 1997; 130:352-356.
 19. Phawa R, Singh T, Khurana N. Hemophagocytic syndrome in malaria and kala-azar. *Indian J Pathol Microbiol* 2004; 47:348-350.