

12-15-2012

## Digital Infrared Thermal Imaging and its use in Domestic and Non-Domestic Species

Susan Denise Bowers

Follow this and additional works at: <https://scholarsjunction.msstate.edu/td>

---

### Recommended Citation

Bowers, Susan Denise, "Digital Infrared Thermal Imaging and its use in Domestic and Non-Domestic Species" (2012). *Theses and Dissertations*. 1507.  
<https://scholarsjunction.msstate.edu/td/1507>

This Dissertation - Open Access is brought to you for free and open access by the Theses and Dissertations at Scholars Junction. It has been accepted for inclusion in Theses and Dissertations by an authorized administrator of Scholars Junction. For more information, please contact [scholcomm@msstate.libanswers.com](mailto:scholcomm@msstate.libanswers.com).

Digital infrared thermal imaging and its use in domestic and non-domestic species.

By

Susan Denise Bowers

A Dissertation  
Submitted to the Faculty of  
Mississippi State University  
in Partial Fulfillment of the Requirements  
for the Degree of Doctor of Philosophy  
in Animal Physiology  
in the College of Agriculture and Life Sciences

Mississippi State, Mississippi

December 2012

Copyright by  
Susan Denise Bowers  
2012

Digital infrared thermal imaging and its use in domestic and non-domestic species.

By

Susan Denise Bowers

Approved:

---

Scott T. Willard  
Professor of Biochemistry,  
Molecular Biology, Entomology, and  
Plant Pathology  
(Major Professor)

---

Erdogan Memili  
Associate Professor of  
Animal and Dairy Sciences  
(Committee Member)

---

Peter L. Ryan  
Professor and Graduate Coordinator of  
Animal Physiology  
(Committee Member)

---

Russell Carr  
Associate Professor of Basic Sciences  
(Committee Member)

---

George M. Hopper  
Dean of The College of Agricultural  
and Life Sciences

Name: Susan Denise Bowers

Date of Degree: December 15, 2012

Institution: Mississippi State University

Major Field: Animal Physiology

Major Professor: Scott T. Willard

Title of Study: Digital infrared thermal imaging and its use in domestic and non-domestic species.

Pages in Study: 131

Candidate for Degree of Doctor of Philosophy

Digital infrared thermal imaging (DITI) is a non-invasive diagnostic technique that is used to detect symmetry and asymmetry of surface temperature gradients. DITI can examine many different aspects of thermal physiology and diagnose injury and disease. The objectives of this study were (1) to investigate the use of DITI to determine whether differences in temperature gradients exist between late gestation and non-pregnant mares, (2) to evaluate whether velvet antler (VA) temperature gradients, as measured by DITI would pattern VA growth, and (3) to determine if “normal” temperature gradients of the foot exist among elephants as detected using DITI. To investigate these objectives, three experiments were conducted to determine the value of DITI for research on mammals. Results obtained from the first study indicate DITI was able to detect pregnancy in the horse during late gestation. In the second study DITI successfully patterned the growth and hardening of VA. While in the third study DITI demonstrated its value as a tool to increase overall welfare for captive elephants. In summary these studies suggests that DITI may have value in conducting research with domestic and non-domestic species that are not able to be restrained.

## DEDICATION

I would like to dedicate this dissertation to my parents, Frank and JoAnne Bowers for all their encouragement and support throughout my courses of study.

## ACKNOWLEDGEMENTS

The author expresses her sincere appreciation to the many people that provided guidance and support throughout this journey. First of all thanks are due to Scott Willard and Peter Ryan for their time and guidance throughout this process. An extended thanks goes to Russell Carr, Erdogan Memili, Anna Chromiak, Ron Randel, and Andy Kouba for the aid and direction provided by them. Finally, I wish to express thanks to the graduate students, faculty and staff in the Department of Animal and Dairy Sciences who made this study a success; without your help, none of this was possible.

## TABLE OF CONTENTS

DEDICATION .....	ii
ACKNOWLEDGEMENTS .....	iii
LIST OF TABLES .....	vii
LIST OF FIGURES .....	viii
CHAPTER	
I. INTRODUCTION .....	1
References .....	3
II. LITERATURE REVIEW .....	4
Thermography .....	4
The Basis of Thermography .....	5
Infrared light .....	5
Infrared imagers .....	6
Applications of Thermography .....	7
Errors and Uncertainties with Thermal Assessments .....	11
Assessment of Pregnancy using Infrared Thermography .....	14
Infrared thermography and Angiogenesis .....	16
Assessment of Lameness using Infrared Thermography .....	18
Reproductive Physiology and the Mare .....	21
Pregnancy and Placentation .....	21
Endocrinology .....	22
Fetal Growth .....	24
Pregnancy in the Mare .....	26
Angiogenesis in the Placenta .....	27
Fetal and Placental Heat Production .....	30
Antler Physiology .....	31
Biology of the Antler .....	31
Nutritional Aspects .....	33
Endocrine Regulation .....	34
Antler Harvesting .....	35
Additional Applications of Thermography in Deer .....	37
Care and Maintenance of the Elephant Foot .....	38



Anatomy of the elephant foot .....	38
The Legs.....	38
The Hind Foot.....	39
The Forefoot.....	40
The Cushion .....	41
Husbandry Practices for the Elephant Foot .....	42
The Pedicure .....	44
Common Problems of the Elephant Foot.....	46
Abscesses .....	46
Cracks.....	47
Detecting Problems in the Elephant Pad.....	49
Additional Applications of Thermography in Elephants .....	50
References.....	51
 III. ASSESSMENT OF PREGNANCY IN THE LATE GESTATION MARE USING DIGITAL INFRARED THERMOGRAPHY .....	62
Introduction.....	62
Materials and methods .....	64
Animals.....	64
Statistical analysis .....	65
Results.....	66
Thermography and environmental conditions for pregnancy assessment.....	66
Using thermography to detect thermal signatures in the nonpregnant versus pregnant mare before and after foaling.....	66
Discussion .....	67
Acknowledgements.....	70
References.....	75
 IV. EVALUATING VELVET ANTLER GROWTH IN RED DEER STAGS ( <i>CERVUS ELEPHUS</i> ) USING HAND HELD AND DIGITAL INFRARED THERMOGRAPHY .....	78
Introduction.....	78
Materials and Methods.....	81
Experiment I – Hand Held SSTS Infrared Measurements.....	81
Experiment II - Digital Infrared Temperature Imaging (DITI) .....	82
Statistical Analysis.....	84
Results.....	84
Experiment I.....	84
Experiment II .....	85
Discussion .....	87
References.....	97

V.	AN ASSESSMENT OF THERMAL SIGNATURES OF THE ELEPHANT FOOT AS DETERMINED BY DIGITAL INFRARED THERMOGRAPHY .....	101
	Introduction.....	101
	Materials and Methods.....	103
	Data Collection .....	103
	Location .....	104
	Study I (Memphis Zoo).....	104
	Study II (Nashville Zoo) .....	105
	Study III and IV (Riddle Elephant Sanctuary).....	105
	Statistical Analysis.....	105
	Results and Discussion .....	106
	Study I (Memphis Zoo).....	106
	Study II (Nashville Zoo) .....	108
	Study III (Riddle Elephant Sanctuary).....	109
	Study IV (Case Studies).....	111
	Summary and Recommendations .....	113
	References.....	128
VI.	GENERAL CONCLUSION .....	131

## LIST OF TABLES

1	Correlation coefficients between ambient, background (non-animal), rectal, abdomen/flank and wither thermal measurements in pregnant, non-pregnant and foaled mares. ....	72
2	Correlation coefficients between background (chute, head and hair coat), antler base and antler tip maximum thermal measurements using SSTs in yearling and mature stags .....	93
3	Maximum tibia temperatures (°C), using DITI, during the early and late growth period in red deer stags (n=23) .....	95
4	Correlation coefficients between maximum ambient, coat, rectal, eye and main beam antler thermal measurements (Experiment II) for all red deer stags (n=31) .....	96
5	Analysis of thermal signatures of the left pads vs. right pads and fore pad vs. hind pad as determined by digital infrared thermal imaging using Circle and Shape analysis (Nashville Zoo; n = 3 female African elephants) .....	122
6	Thermal signatures of the medial, lateral, cranial and caudal aspects of the elephant fore and hind pad as determined by digital infrared thermal imaging (Nashville Zoo; n = 3 female African elephants).....	123
7	Thermal signatures of the concentric gradient of the elephant fore and hind pad as determined by digital infrared thermal imaging (Nashville Zoo; n = 3 female African elephants) .....	124
8	Thermal assessments of elephant fore and hind foot pad relative to species and genders determined by digital infrared thermal imaging circle analysis (Riddle Elephant Sanctuary).....	125
9	Thermal signatures of the medial, lateral, cranial and caudal aspects of the elephant pad relative to species and gender as determined by digital infrared thermal imaging (Riddle Elephant Sanctuary) .....	126

## LIST OF FIGURES

1	DITI measurements including left and right abdomen / flank and wither temperature were obtained weekly for 5 wk prior to predicted parturition date and for 3 wk after parturition.....	71
2	Thermal signatures as determined by digital infrared thermal imaging in pregnant and non-pregnant mares .....	73
3	Thermal images of a pregnant and non-pregnant mare acquired with the Meditherm Vet2000. ....	74
4	Thermal images of the same red deer stag (Experiment II) taken during the mid growth phase (A, day 42, main beam length 25 cm ) and the late growth phase (B, day 112, main beam length 71 cm) when the antler was beginning to harden .....	91
5	Main beam antler growth rates for yearling (n=8; panel A) and mature (n=17; Panel B) red deer stags in experiment I.....	92
6	Main beam VA length (cm) and growth rate (cm/d) in experiment II for all red deer stags (n=31). ....	94
7	Main beam antler growth (cm/d) and temperature (°C), for all stags (n=31) in experiment II using DITI, during the early, mid and late growth periods. ....	95
8	A representative thermal image of the foot pad of an African elephant at the Memphis Zoo acquired with the FLIR P60 real-time camera.....	116
9	Illustrations depicting the analysis used to determine thermal gradients and patterns of the elephant's foot .....	117
10	Thermal signatures of two African elephants (Memphis Zoo) housed in different environments (outdoor vs. indoor) over time as determined by digital infrared thermal imaging shape analysis.....	118
11	Thermal signatures (Max, Min, Avg) of the medial and lateral aspects of the elephant pad as determined by digital infrared thermal imaging in a temperature controlled environment (inside vs. outside; Memphis Zoo) .....	119

12	Thermal signatures (Max, Min, Avg) of the cranial and caudal aspects of the elephant pad as determined by digital infrared thermal imaging in a temperature controlled environment (inside vs. outside; Memphis Zoo) .....	120
13	Thermal signatures (Max temp only) of the concentric gradient of the elephant pad as determined by digital infrared thermal imaging in a temperature controlled environment (inside vs. outside; Memphis Zoo) .....	121
14	Clinical Case Studies: Panel A depicts a thermal image of a toe abscess in a female Asian elephant .....	127

## CHAPTER I

### INTRODUCTION

For medical and physiological monitoring digital infrared thermal imaging (DITI) represents a non-invasive diagnostic technique able to detect symmetry and asymmetry of surface temperature gradients. While the temperature of the skin is generally about 5°C cooler than the body core, since heat is often dissipated through the skin by evaporation and other methods to balance internal and external temperature (Adams et al., 1980), it is possible to detect infrared emissions from the skin and create a thermal map of temperature distributions by remote sensing (Purohit et al., 1985). Variations in skin temperature result from changes in tissue perfusion and blood flow (Winsor, 1971), and since there is a high degree of thermal symmetry in the normal body subtle abnormal temperature asymmetry can be easily identified (Purohit et al., 1985).

In livestock, DITI has been applied in the diagnosis of foot and leg problems in cattle and horses (Purohit 1980; Turner 1998; Cockcroft et al. 2000; Alsaad and Buscher, 2012; Stokes et al, 2012), for assessing fertility in bulls and rams (Purohit et al. 1985; Kastelic et al. 1996; Gabor et al. 1998; and Coulter et al. 1988), for characterizing the responses of cattle to hot-iron and freeze branding (Schwartzkopf-Genswein 1997), and monitoring heat load in dairy cattle (White et al. 2006.). Moreover, the use of DITI in domestic livestock has led to new approaches to study wildlife or other captive exotic species that cannot be handled. As with domestic animals, thermography has been used

as a diagnostic tool in veterinary science in detecting injury and disease in exotic animals and wildlife (McCafferty, 2007). However, researchers do not have a good understanding of what is a normal or baseline heat signature for many exotic animals. In addition, reports of the use of thermography in non-domestic species or captive wildlife have been limited in scope, aside from anecdotal reports or clinical case studies of lameness or overt manifestations of an injury (abscess, or wound; Hilsberg, 2002). Therefore, the significance of digital infrared thermal imaging and its use in non-domestic species has not been revealed.

These limitations led us to the objectives of this study which were to (1) investigate the use of digital infrared thermal imaging to determine whether differences in temperature gradients exist between late gestation and non-pregnant mares, and to help develop a model to evaluate DITI for detecting pregnancy in wildlife and exotic captive species, (2) evaluate the use of infrared temperature measurements conducted by DITI to monitor VA growth *in vivo* during antler development in red deer stags (*Cervus elephus*), and (3) to determine whether “normal” temperature gradients of the foot exist among elephants as detected using DITI and to evaluate the variations in temperature gradients of elephant feet following repeated monitoring using DITI within the management environment.

## References

- Adams, J. L. 1979. Innervation and blood supply of the antler pedicle of red deer. *NZ Vet. J.* 27: 200-201.
- Cockcroft, P. D., Henson, F. D., and Parker, C. 2000. Thermography of a septic metatarsophalangeal joint in a heifer. *Vet. Res.* 146: 258-260.
- Coulter, G. H., Senger, P.L., and Bailey, D.C. 1988. Relationship of scrotal surface temperature measured by infrared thermography of subcutaneous testicular temperature in the ram. *J. Reprod. Fertil.* 84: 417-423.
- Gabor, G. R., Sasser, G., Kastelic, J. P., Coulter, G. H., Everson, D. O., Falkay, G., Mezes, M., Bozo, S., Cook, R. B., and Csik, J. V. 1998. Endocrine and thermal responded to GnRH treatment and prediction of sperm output and viability in Holstein-Friesian breeding bulls. *Theriogenology.* 50: 177-183.
- Kastelic, J. P., Cook, R. B., Coulter, G. H., and Saake, R. G. 1996. Ejaculation increases scrotal surface temperature in bulls with intact epididymides. *Theriogenology.* 46: 889-892.
- McCafferty, D. J. 2007. The value of infrared thermography for research on mammals: previous applications and future directions. *Mammal Rev.* 37: 207-223.
- Purohit, R. C., Hudson, R. S., Riddell, M. G., Carson, R. L., Wolfe, D. F., and Walker, D. F. 1985. Thermography of the bovine scrotum. *Am. J. Vet. Res.* 46: 2388-2392.
- Schwartzkopf-Genswein, K. S. and Stookey, J. M. 1997. The use of infrared thermography to assess inflammation associated with hot-iron and freeze branding in cattle. *Can. J. Anim. Sci.* 77: 577-583.
- Turner, T. A., Purohit, R. C., and Fessler, J. F. 1986. Thermography: A review in Equine Medicine. *Compendium on Continuing Education for the Practicing Veterinarian.* 8: 855-861.
- White, M. B., Jones, M., Schmidt, S., and Willard, S. 2006. Use of digital infrared thermal imaging (DITI) for monitoring environmental physiology in dairy cattle. *J. Anim. Sci.* 84(Suppl 1): 212.
- Winsor, T. 1971. Vascular aspects of thermography. *J. Cardiovasc. Surg.* 12: 379-388.



## CHAPTER II

### LITERATURE REVIEW

#### **Thermography**

The use of physiological temperature gradients to diagnose disease and/or dysfunction is not new, and has been applied for centuries. Hippocrates was the first to recognize that the body emitted infrared radiation. He discovered this by applying a thin layer of mud on his patients' skin and watched it dry; as the mud dried a pattern was formed over the area with inflammation (Waldsmith, 1993). While the first applications for monitoring skin temperature gradients were accomplished using touch, the current field of thermal imaging now includes sophisticated thermal detection devices for military, industrial and medical applications. Thermal signatures can be obtained through technologies such as hand-held infrared temperature sensors (IRT) that take a single point measurement or more sensitive equipment such as digital thermal imaging (DITI) that can scan a complete surface or object at one time. Infrared temperature sensors use laser sighting and give the minimum, average and maximum temperature of a surface. As the distance between the temperature sensor and the object being measured increases the area of the target being measured increases. Infrared sensing technologies have been used in industrial settings for facility maintenance, HVAC system diagnostics, food safety (Kee, 1997; Ma and Tao, 2005) and a variety of other applications. For medical and physiological monitoring digital infrared thermal imaging (DITI) represents a non-

invasive diagnostic technique able to detect symmetry and asymmetry of surface temperature gradients. While the temperature of the skin is generally about 5°C cooler than the body core, since heat is often dissipated through the skin by evaporation and other methods to balance internal and external temperature (Adams et al., 1980), it is possible to detect infrared emissions from the skin and create a thermal map of temperature distributions by remote sensing (Purohit et al., 1985). Variations in skin temperature result from changes in tissue perfusion and blood flow (Winsor, 1971), and since there is a high degree of thermal symmetry in the normal body subtle abnormal temperature asymmetry can be easily identified (Purohit et al., 1985).

## **The Basis of Thermography**

### *Infrared light*

The electromagnetic spectrum includes gamma rays, X-rays, ultraviolet, visible, infrared, microwaves and radio waves. The only difference between these types of radiation is their wavelength or frequency. Wavelength increases and frequency decreases from gamma rays to radio waves. The infrared part of the spectrum spans wavelengths from 0.7 micrometers to 1000 micrometers and lies between the visible and microwave portions of the spectrum. This range can be further divided into three smaller groups, near infrared (0.76 – 1.5  $\mu\text{m}$ ), medium infrared (1.5 – 5.6  $\mu\text{m}$ ) and far infrared (5.6 – 1000  $\mu\text{m}$ ; Lahiri et al, 2012). Infrared is used to measure the heat radiated by an object, and higher the temperature of an object the more the atoms and molecules move in turn emitting increased levels of infrared. Any object that has a temperature above absolute zero radiates in the infrared (Jones, 1998). Infrared energy travels in straight lines from the source and can be reflected and absorbed by material surfaces. In the case

of most solid objects that are opaque to the human eye, part of the infrared energy striking the object's surface will be absorbed and part will be reflected. Of the absorbed energy by the object a portion will be re-emitted and part will be reflected internally. This also applies to materials which are transparent to the eye (glass, clear plastics) but in addition some of the infrared energy will pass through the object. These phenomena collectively contribute to what is referred to as the emissivity of the object. Different kinds of materials and gases have different emissivities, and will emit infrared at different intensities for a given temperature. The emissivity of a material or a gas is a function of its molecular structure and surface characteristics. A more highly polished surface, which has a low emissivity, will cause more infrared energy to be reflected, whereas a surface that is rough will have a higher emissivity because it prevents as much of the infrared energy from being reflected. An additional factor affecting emissivity of a material is the wavelength sensitivity of the sensor, known as the sensor's spectral response.

### *Infrared imagers*

Thermal infrared imagers are detector and lens combinations that give a visual representation of infrared energy emitted by objects. A thermal infrared camera detects infrared energy and converts it into an electronic signal which is then processed to produce a thermal image and perform temperature calculations. A basic design comprises a lens to collect the energy emitted by the target; a detector to convert the energy to an electrical signal; an emissivity adjustment to match the infrared camera calibration to the emitting characteristics of the object being measured; and an ambient temperature compensation circuit to ensure temperature variations within the infrared camera are not transferred to the final output. A more technical imager will have a variety

of detectors, selective filtering of the infrared signal, plus linearization and amplification of the detector output. Early infrared cameras were bulky and inconvenient to use as they required liquid nitrogen cooling (Jones, 1998). The first generation cameras used a single element detector and two scanning mirrors to produce images. The second generation cameras used two scanning mirrors along with a large linear array or small 2-D array as detectors and time delay integration algorithm for image enhancement was added. Third generation cameras are without mirrors and have large focal plane array detectors and on chip image processing which increases the reliability and sensitivity of these systems (Lahiri et al, 2012). The modern thermal cameras have many advantages when compared to their older counterparts, they are becoming cheaper, have high spatial and temperature resolutions, are either electrically cooled or uncooled, and are much more compact and portable (Diakides, 1997; Ring and Dicks, 1999; Ring and Ammer, 2012; Lahiri et al, 2012).

### **Applications of Thermography**

Thermal imaging was first used mainly in the areas of medicine and industrial settings. Clinical thermal imaging was introduced in the 70's with two technologies being used; liquid crystal contact thermography and noncontact blackbody infrared imaging (Anbar, 1998). The use of liquid crystal contact thermography became obsolete because of its low thermal and spatial resolution and the subjectivity of assessing temperature abnormalities. However, even the state of the art digital infrared thermal imaging did not yield significantly better results than liquid crystal thermography until the mid 80's (Anbar, 1998). The technology changed dramatically in the 90's when high resolution, fast scanning cameras were introduced, which in turn led to greater

advancements when thermography in the medical field. Thermal imaging has been used to noninvasively diagnose dental problems (Madura et al, 2004), vascular occlusions, deep venous thrombosis (Wheeler and Anderson, 1995), and stenosis of the carotid arteries (Friedlander and Gratt, 1994). In addition thermal angiography of the coronary arteries during open heart surgery has been commercialized for routine clinical use (Emery et al. 1996). Thermal imaging has also been used to diagnose nerve irritation or compression, such as in carpal tunnel syndrome (Ring and Ammer, 2012) or vibration white finger syndrome (McHugh et al. 1993). Another application of thermography in the medical field is its use in breast cancer detection and risk assessment (Head and Elliott, 2002). Several studies have shown that infrared imaging is a good method for risk assessment in breast cancer (Elliott et al. 1990; Head et al. 2000). These studies concluded that the presence of an abnormal asymmetric infrared heat pattern of the breast increases a woman's risk of being diagnosed with breast cancer at least 10-fold. Another use of thermography is the assessment of burn wounds. The idea is that deeper wounds are colder than more superficial ones because of less vascular perfusion near the wound surface (Watson and Vasilescu, 1972; Still et al. 2001). A more recent study has stated that more accurate results are obtained when the imaging is done within three days of sustaining the burn (Ruminski et al. 2007). More recently studies investigating arthritis have compared radiographs and thermal images and found a good correlation between increased temperature and severe changes in radiographs from osteoarthritis of knees (Warashina et al., 2002; Denoble et al., 2010). In industrial and military settings thermography has been used for a variety of applications such as surveillance (Prokoski

et al. 1992), nondestructive testing (Wu and Busse, 1998), measuring heat emissions (Azmat and Turner, 2005) and safety precautions (Sendur and Baertlein, 2000).

In livestock, DITI has been applied in the diagnosis of foot and leg problems in cattle and horses (Purohit 1980; Turner 1998; Cockcroft et al. 2000; Schmidt et al. 2003, Alsaad and Buscher, 2012; Stokes et al, 2012), for assessing fertility in bulls and rams (Purohit et al. 1985; Kastelic et al. 1995 and 1996; Gabor et al. 1998; and Coulter et al. 1988), for characterizing the responses of cattle to hot-iron and freeze branding (Schwartzkopf-Genswein, 1997), monitoring heat load in dairy cattle (White et al, 2006) and for evaluating thermal comfort in poultry (Bottcher et al, 1992). In equine medicine thermography has been used for early detection of tendon inflammation in racehorses, (Purohit, 1980a and Turner, et al., 1986). Laminitis in horses can be detected by an increase in temperature due to the greater amount of blood flow to the hoof (Turner, 1991), while horses with navicular disease had an opposite effect of a decrease in temperature due to the lack of blood flow to the hoof (Turner, 1983). Purohit et al. (1977) reported the use of thermography for detecting hind leg lameness in a bull. His findings were a localized lesion of the lateral claw close to the apical border of the sole. The thermal image displayed increased heat in the lateral claw, which revealed an abscess in the subsolar region of the affected claw. The assessment of inflammation has been used to try to measure discomfort when branding cattle. In one study the inflammation associated with the process of hot iron branding and freeze branding were compared using thermography. It was concluded that both methods caused an inflammatory response. However, hot iron branding had higher temperatures associated with the brand for a longer period of time, indicating a possibility of a more intense and prolonged

period of pain (Schwartzkopf-Genswein and Stookey, 1997). When investigating the use of thermography for assessing fertility, Purohit (1985) established normal thermographic patterns of the bovine scrotum, with the scrotum having a symmetrical and constant thermal pattern with a temperature gradient of 4 to 6 °C from the base of the apex to the scrotum. However, bulls with an abnormal testis had an increase in infrared temperature of 2.5 to 3 °C when being compared to the normal testis (Purohit, 1985). Temperature changes usually indicate a depression of spermatogenesis and testicular degenerative changes, normal thermal patterns and symmetry with reduced temperatures indicate chronic testicular degeneration with fibrosis (Purohit, 1985). As stated above, thermography has also been used in the evaluation of the thermal state of cattle. Using infrared technology the cattle were able to be evaluated without constraint and permitted the producer to evaluate cooling requirements regardless of weather conditions outside the housing system (Coppola et al. 2002).

Moreover, the use of DITI in domestic livestock has led to new approaches to study wildlife or other captive exotic species that cannot be handled (McCafferty, 2007). As with domestic animals, thermography has been a diagnostic tool in veterinary science in detecting injury and disease in exotic animals and wildlife (McCafferty, 2007). A recent study used thermal imaging to help diagnose a deformity of the paw in a captive tiger (Rahal et al, 2012), In addition thermal imaging has become useful in population surveys, being implemented from road vehicles or aircraft (Sabol and Hudson, 1995). Other applications include thermo-physiology studies such as changes in surface temperature of harbor seals from pregnancy to moult (Paterson et al, 2012), investigating surface temperature in ground squirrels and marmots during arousal from hibernation

(Phillips and Heath, 2004) and detection of pregnancy (Hilsberg, 1997). Recent studies have also shown thermography is capable of detecting surface temperature changes in response to fear and stress. The findings of Nakayama et al. (2005) showed that changes in facial surface temperature patterns of Rhesus monkeys occurred in response to capture. In addition Cook and Schafer (2002) utilized thermography to assess the stress associated in the removal of velvet antler.

### **Errors and Uncertainties with Thermal Assessments**

It is apparent that environmental conditions such as temperature and air flow can have an impact on the reliability of thermal images when conducted in an uncontrolled environment, which is usually the case in the captive management of livestock and wildlife. It has been suggested that the ideal temperature for imaging is in the range of 20°C (Love and Linstead, 1976) but a temperature below 30°C is acceptable Turner et al, 1986) since heat loss from sweating does not occur below this temperature (William, 1964); although this may vary by species and/or other aspects of the environmental conditions. A study conducted by Jones et al. (2005) investigated the use of DITI to assess pregnancy status in Holstein heifers. The average ambient temperature was 17.7°C during the study but a difference in pregnant and nonpregnant heifers only occurred when the ambient temperature was below 10°C. This could lead to speculation that the ideal temperature needs to be lower to obtain more accurate images, at least for some species, and for pregnancy detection within diverse management environments. Additional obstacles for obtaining accurate thermal images also relate to the animals phenotypic or morphological differences such as length or pattern of hair coat (Delahanty and Georgi, 1965), disease state (Schaefer et al, 2007) and location of internal structures.



Infrared radiation emitted by bare-skinned animals is regulated by the temperature of the skin surface but the radiation emitted from most mammals may originate from the skin or from the hairs themselves (McCafferty, 2007). The radiating surfaces of the hairs are at a range of temperature established by the temperature gradient between the coat surface and skin. This exchange of radiation may further be hindered by external fluxes that contribute to the heat balance of the hairs. If an animal has thick fur the surface temperature, measured by infrared thermography, is typically several millimeters beneath the actual surface of the coat (McCafferty, 2007). The equilibrium temperature of this surface is determined by the loss of heat from radiation and convection to the surrounding environment, the conduction of heat through the coat and the exchange of thermal and short wave radiation (Cena, 1974). The environment in which thermography measurements are carried out is important because of its influence on coat temperature. It has been shown that different colored coats influence solar loading at the surface, with black areas having a greater surface temperature than the white areas when the animals are standing in the sun (Cena and Clark, 1973; Benesch and Hilsberg, 2003). This phenomenon has been shown in the zebra, where the black stripes are more than 10°C warmer than white stripes when the zebra is exposed to full sun (McCafferty, 2007). In the study mentioned above by Jones et al.(2005) it was noted that there were apparent problems associated with imaging and reliability related to coat patterns (black/white patterns) of the Holstein heifers. These temperature patterns do not reflect underlying circulation or major differences in emissivity as the temperature pattern disappears after a few minutes in the shade (McCafferty, 2007; Jones et al, 2005). In addition to coat color and pattern, the thickness and density of hair covering the animal will influence

temperature. Coat variation may differ between individuals due to species or genetics and can also vary by season due to molt or shedding (McCafferty, 2007). Additional factors must also be considered when aquatic animals are being studied using thermography. Temperature errors associated with alterations in the emissivity of a wet coat are small in relation to changes in coat temperature due to evaporative cooling. Wetting the animal leads to an apparent uniformity in surface temperature due to water retention in the coat. In addition, the greater thermal conductivity of water means that heat may be rapidly conducted from warm parts of the body. This is usually noticed when aquatic animals first leave the water (McCafferty, 2007), with the temperature of the body corresponding to the temperature of the water being retained in the hair coat.

Other influences on the reliability and accuracy of thermography can go deeper than just hair coat. In domestic bitches which were used as model animals in the investigation of infrared thermography to visualize pregnancy in the giant panda (Durrant et al, 2006), thermography proved to be inconclusive with heat signatures corresponding to the mammary glands; or in some cases lack thereof. This could be due to the fat content of the mammary gland, metabolic heat in this region, or individual differences among the females. When investigating the use of thermography to determine pregnancy in the dairy cow there was variability in thermal images among sides (left and right) in the Holstein heifers. The left side images of the heifers were highly variable and were not as highly correlated as the right side to pregnancy. This could be explained by the location of the rumen in the cow on the left side, although this is just speculation (Jones et al, 2005). Disease processes can also produce significant and unpredictable changes in body temperature. Previous studies have focused mostly at humans when investigating

disease state since diagnosis is feasible, however many of the same ailments can occur in animals. Thermal imaging has been used as a tool to detect cancerous tumors because of its sensitivity to metabolic changes and tumor angiogenesis (Keyserlingk et al, 1998) but this can also lead to inaccuracies if the tumor is not known to be present. Other disease states such as circulatory problems, previous injuries and inflammation due to trauma (Schmitt and Guillot, 1984) can obscure thermal readings when the operator is not aware of the problem. Temperature can also increase due to physical exertion, the use of stimulants or other drugs (Ammer et al, 2003) and topically applied ointments (Hoogmoed et al, 2000).

### **Assessment of Pregnancy using Infrared Thermography**

Hilsberg and others (1997) at The Zoological Gardens Berlin were one of the first to use infrared thermography to diagnose pregnancy in zoo species. Initially species were tested for their suitability in the use of thermography and individual heat profiles were examined, resulting in several species being unsuitable due to thickness of their coats. However, heat signatures were detected in the abdomen of a gravid black rhinoceros and Grevy's zebra. The rhinoceros was in the 6<sup>th</sup> month of pregnancy and thermal images revealed a 1.7 °C difference the gravid rhinoceros and a non gravid rhinoceros of the same species. An even greater temperature difference (4°C) was revealed in the Grevy's zebra, which was in the 12<sup>th</sup> month of pregnancy. In an additional study, Hilsberg (1998) was able to follow a black rhinoceros throughout gestation beginning at month 7, until parturition at 14 months. In the 7 month of pregnancy a 2-4°C difference was noted when comparing the abdomen (fetal region) with other regions of the dam, as gestation length increased this difference increased to 5°C. One day after giving birth the temperature

difference of the fetal region and skin of the mother decreased to 2.6°C. In this study (Hilsberg, 1998) it was also noted that abrupt changes in environment caused the pregnancy to be undetected until the animal was able to habituate to the new environment. In addition, exercise caused the body temperature of the female rhinoceros to increase, masking the heat produced by the fetal/placental unit. In 2002, personnel at the Frankfurt and Leipzig Zoological Gardens used thermography to detect late gestation in a single giraffe (Hilsberg et al, 2002). However, they stated that additional research was required to define the working conditions, constraints and limitations of using thermography in pregnancy detection. Recently, thermography has also been used to diagnose pregnancy in the giant panda, albeit small animal numbers (n=2; Durrant et al, 2006). The giant panda housed at the San Diego Zoo was imaged weekly between Days 41 and 131 of a 150 day gestation; the second panda housed at Zoo Atlanta was imaged on Days 81 and 133. The abdomen of the gravid panda was closely shaved to facilitate accuracy of the thermal images. In addition, control animals (domestic bitch) were imaged at 18, 26, and 37 days post-LH peak. Ultrasound results and mating status of the control animals were unknown at the time of thermography. Serial thermographic analysis of the San Diego giant panda revealed heat signatures indicative of an overall perfusion of blood to both uterine horns by Day 48 after natural breeding. By day 69 discrete heat structures were observed in the area over the uterine horns and on day 134 ultrasound scans revealed two live fetuses, one in each horn, at the exact location of the two heat signatures detected by infrared thermography (Durrant et al, 2006). Thermal images of the Zoo Atlanta giant panda on days 81 and 133 revealed uniform temperatures throughout the abdomen in the area where the reproductive tract would be found. The

absence of heat structures suggested that conception did not occur or the pregnancy was lost before implantation. These findings would suggest infrared thermal imaging is capable of detecting pregnancy in the giant panda. However, in the domestic bitch (control animals) thermal imaging did not definitively diagnose pregnancy. Elevated temperatures were apparent but without a discernible pattern, with heat structures concentrated around the mammary glands in pregnant and nonpregnant animals (Durrant et al, 2006). A study conducted by Jones et al. (2005) investigated the use of infrared thermography to assess pregnancy in Holstein heifers. A temperature difference occurred in the pregnant and nonpregnant heifers but only when the ambient temperature was below 10°C. Variability in thermal patterns among sides was detected, with left-sided images not being as highly correlated to pregnancy as the right-sided images. This could be explained by the location of the rumen, which is on the left side of the cow, but this is just speculation (Jones et al, 2005).

### **Infrared thermography and Angiogenesis**

Thermal imaging has been extensively used in research and medicine over the last 50 years. It has been used successfully to study many diseases where blood flow is increased or decreased due to clinical abnormalities (Ring and Ammer, 2012). Variations in skin temperature result from changes in tissue perfusion and blood flow (Winsor, 1971) making it possible for a thermal imager to detect infrared emissions from the skin. Dynamics of surface temperature distribution is controlled by numerous factors, blood flow in the surface layer, heat conduction from deeper blood vessels and sweat evaporation from the surface (Gulyaev et al, 1995). These factors enable the use of thermography to be an effective tool for monitoring thermoregulation processes (Lahiri et

al, 2012). Some of these same dynamics allow the use of thermal imaging to detect breast cancer and other tumors. Tumors generally have an increased blood supply and increased metabolic rate which leads to higher temperatures in localized areas, enabling them to be visualized by infrared thermography (Xie et al, 2004). Gamagami (1996) studied angiogenesis by infrared thermography and reported that in some cases thermal imaging was able to detect cancers which were not recognized by mammography. The study also reported that thermography was able to visualize hypervascularity and hypothermia in 86% of cases of nonpalpable breast cancers (Gamagami, 1996). Thermography is beneficial in the diagnosis of vascular disorders, which is common in diabetes. Principal causes of foot complications in diabetes patients are due to decreased blood supply (Bharara et al, 2012). A number of diabetic subjects were examined and all of the patients had abnormal temperature patterns in their feet and hands, mainly on the toes and fingers (Branemark et al, 1967). In a clinical exam it was noted that dilated tortuous veins existed in the dorsal aspect of the foot, and the thermal image revealed a lower temperature in this area. It was proposed that this decrease in temperature is due to slow blood circulation and varicosity induced inadequate venous drainage (Bagavathiappan et al, 2009).

The ability of thermal imaging to characterize blood flow and angiogenesis is not only useful in human medicine but also in zoo and wildlife medicine and research. The deer antler can be described as vascularized, growing tissue, which develops an analogous blood, neural and cartilaginous network that ossifies and dies following hormonal induction of capillary constriction resulting in the shedding of velvet. The blood supply to the velvet antler varies as the antler grows, branches into tines and begins

to harden, allowing these phases to be investigated by infrared thermal imaging. Schafer and others (2005) used thermography as a method for predicting internal composition characteristic of velvet antler *in vivo*, *in vitro* and during cooling or warming. In addition, thermography can determine the maturation of the velvet antler by monitoring the temperature difference at the tip and base of the antler over time leading to optimal harvest times for specific market specifications (U.S. Pat. No. to Schaefer et al, 2005).

### **Assessment of Lameness using Infrared Thermography**

Thermography has been used in human medicine since the late 1950's and as the technology improved several studies were implemented to evaluate the uses of thermography in veterinary medicine and surgery (Purohit et al, 1977). Most of the latter work on veterinary thermography was performed on equine due to the fact that the horse is utilized in racing and other athletic settings. Stromberg (1974) was one of the first to use thermography in equine orthopedics. He was able to correlate thermal patterns and radiographic lesions of joints and bones and found that thermal emissions are present over pathologic areas before changes are apparent radiographically or even by physical examination. The use of thermography has been successful in clinical cases involving osteoarthritis, tendinitis, navicular disease and joint lesions (Purohit, 1980). An increase in temperature or "hot spots" can occur over a tendon one to two weeks before any signs of pain or swelling. Previous research by Vaden and others (1980) were able to correlate thermal images of subclinical osteoarthritis with racing performance. Exacerbations of joint lesions are preceded by an increase in temperature of up to 4°C, (Stromberg, 1974) and with the aid of infrared thermal imaging could be diagnosed and treated before becoming clinical. In addition thermography is beneficial in following the clinical course

of a disease or injury since the thermal pattern will return to normal with declining lameness and healing (Bowman et al, 1983). In the hoof, conditions such as abscesses and laminitis have been diagnosed with the help of infrared thermography (Purohit and McCoy, 1980). In a case study (Purohit and McCoy, 1980) a 6yr old mare presented with lameness in the right thoracic limb. Thermal images exhibited increased heat over the lateral areas of the heel bulb and a spot of increased heat in the lateral quarter of the sole when compared with the medial areas of the same foot. Clinical examination revealed sensitivity to hoof testers over the lateral quarter and heel and a diagnosis of an abscess was made. Recently, infrared thermography has been implemented in the detection of lameness and claw injuries in dairy cattle. Munsell (2004) reported that claws that had at least one sole lesion had significantly higher temperature at the coronary band than claws without lesions. Nikkah et al. (2005) found an increased temperature at the coronary band associated with sole ulcers and hemorrhages in early lactating cows. Infrared thermography also has potential to be a reliable method for detecting digital dermatitis in dairy cattle (Stokes et al, 2012) and as a diagnostic tool for discovery of hoof lesions by detecting inflammation in the coronary band (Alsaad and Buscher, 2012).

Infrared thermography is an ideal method to diagnose inflammation and lameness in wildlife and zoo species since it requires no direct animal contact or immobilization. In large herbivores it is difficult to observe locations of injuries on limbs especially when no external lesions are visible (Hilsberg, 2002) or when the incident is not observed by zoo caretakers. In four clinical cases infrared thermography was used to diagnose lameness in African and Asian elephants (Hilsburg, 2002). In three of the cases the inflammation and pain was caused by joint injuries, the fourth case was thought to be



joint related, however thermal images revealed no changes in temperature over any joint. As additional images were acquired a change in temperature was noted where the skin of the knee connects to the rump, resulting in the diagnosis of a muscle fibre rupture. In addition thermal imaging was utilized to diagnosis joint and muscle injuries in a black rhinoceros, two giraffes and a hippopotamus. The case involving the hippopotamus should be noted. As the animal came out of the water, the radiation over the right carpal joint started to increase disproportionally from that over his other legs and from the other hippopotamus in the enclosure. A temperature difference of more than 3°C was measured 15 minutes after the hippopotamus ventured onto dry land (Hilsberg, 2002). Foot problems are also successfully diagnosed with infrared thermography. Captive elephants develop lesions of the toenails and abscesses in the pad of the foot quite often. In the following case lesions on the toenails of an Asian elephant were observed with infrared thermography at an early stage, which allowed for prompt treatment with altering therapies. The elephant was followed over a 2 yr period and infrared thermography revealed that the first therapy was not successful and the inflammation of the nails had increased to include the carpal joint. Surgery was performed, leading to a reduction in the infection but thermal imaging was able to confirm that the infection would flare up periodically (Hilsberg, 2002). In another study Asian elephants, with no known ailments, were systematically examined with a thermographic camera. In this particular study temperature variation was as 8°C due to environmental factors. Even with these variations inflamed toes showed a strong increase in temperature above the coronary band (Schmidt-Burbach, 2008). Recently, a thermographic imaging protocol was described for the use of infrared thermography in dogs (Loughin and Marino, 2007).

Investigators examined normal thermographic patterns for certain limbs of healthy dogs and specifically tried to determine whether there was symmetry between left and right side of each dog. Success rate (image pattern analysis) was high for the hind legs (90%) but lower for the front legs (60%). The authors propose that with further standardization in the image acquisition process this lower success rate may be resolved (Loughin and Marino, 2007). Changes in thermal patterns, gradients and alteration of symmetry indicate thermal abnormalities. If evaluated carefully, early diagnosis can be made thus leading to early treatment and maybe even prevention. Infrared thermography can also be implemented as a diagnostic aid to determine if healing processes have taken place (Purohit, 1980).

## **Reproductive Physiology and the Mare**

### **Pregnancy and Placentation**

Mammalian embryos can be subdivided primarily into two main groups. In the first group, domestic animals and herbivores, the preattachment phase is several weeks. In the second group, primates, the blastocyst implants very soon after it enters the uterus (Senger, 2003). For this review the emphasis will be placed on the first group that includes large herbivores. During early gestation the embryo remains free from attachment as it moves from the oviduct into the uterus. During this time the chorion and amnion are developing. In addition the allantois continues to expand and will make contact with the chorion becoming the allantochorion. This membrane is the fetal contribution to the placenta and will provide a place for attachment to the endometrium (Senger, 2003). Placentation is the process by which chorionic villi extend into the endometrium forming a union. The placenta is composed of a fetal component derived

from the chorion and a maternal component derived from modifications of the uterine endometrium. Only after placentation can the embryo derive nutrients and transfer waste products through maternal blood. In most mammals placentation begins in the early part of gestation, with the attachments being quite fragile (Senger, 2003).

## **Endocrinology**

In order for early embryogenesis to continue into a pregnancy, luteolysis of the corpus luteum must be prevented. Levels of progesterone must be maintained at sufficient levels so that embryogenesis and attachment of the conceptus to the endometrium can occur. The conceptus must signal its presence before luteolysis occurs or the drop in progesterone concentrations will cause loss of the pregnancy (Senger, 2003). The process of maternal recognition varies among species. In some species, such as the ewe and cow, the blastocyst produces specific proteins that provide the signal for prevention of luteolysis. These interferons are glycoproteins produced by leukocytes, fibroblasts, lymphocytes and trophoblastic cells and they act on the endometrial cells of the uterus to inhibit the production of oxytocin receptor synthesis (Senger, 2003). In the sow the conceptus produces estradiol, which serves as the signal for maternal recognition. The production of estrogen causes  $\text{PGF}_2\alpha$  to be secreted away from the submucosal capillaries and toward the uterine lumen, which has little access to circulation. In the mare the conceptus must travel within the uterus from one horn to the other for maternal recognition to take place. The migration must occur between 12 and 14 times a day during days 12, 13 and 14 of pregnancy in order to inhibit  $\text{PGF}_2\alpha$  (Allen, 2005). The conceptus of the horse also produces proteins which have some effect on the recognition of pregnancy but the specific roles are unknown (Stout and Allen, 2001). Other non-

domestic species show different signals for maternal recognition. In marsupials the embryo within the uterus does not interrupt the estrous cycle. Therefore, pregnancy recognition is apparently caused by the attachment of the prematurely born fetus to the teat, which arrests cyclicity (Renfree, 2000). Other species go through embryo diapause or delayed implantation. Diapause is thought to occur to allow the embryo to develop under more favorable conditions (Lopes et al. 2004). In mammals the onset, maintenance and termination of embryo diapause is under maternal control (Lambert et al. 2001), and environmental factors and lactation influence these even further (Lopes et al. 2004). Even with these specialized signals the overall concept is the same, as long as maternal recognition signals are provided, progesterone will remain high, the conceptus will grow and the placenta will form to provide a link between the mother and fetus.

The placenta is a multifaceted organ that is responsible for mediating the maternal environment necessary for normal fetal development. As an active endocrine gland the placenta is capable of synthesizing and secreting a number of protein and steroid hormones (Senger, 2003). Included in this category of hormones are gonadotropins that are found in the horse and in most primates. In the horse the placenta produces equine chorionic gonadotropin (eCG) which provides a stimulus for maintenance of the primary corpus luteum. This gonadotropin is also responsible for controlling the formation and maintenance of accessory corpora lutea (Senger, 2003). In primates the placenta produces human chorionic gonadotropin (hCG). The role of hCG in the primate is to provide a luteotropic stimulus for the transition of the ovulatory corpus lutea to the CL of pregnancy (Senger, 2003). The placenta also produces progesterone and estrogen which are both important hormones during pregnancy. In addition, the placenta also produces

placental lactogen which stimulates the growth of the mammary gland and is thought to be similar to growth hormone and helps promote the growth of the fetus. Relaxin is also produced by the placenta in some species and helps with parturition (Senger, 2003).

### **Fetal Growth**

The weights of the fetal fluids, fetal membranes and maternal uterus increase exponentially as gestation progresses (Reynolds and Redmer, 1995). Just before parturition in the cow, the fetal fluids weigh about 15.5 kg and the fetal membranes weigh about 3.8 kg. The uterus will increase in size from about 1.0 kg to 10 kg during the course of pregnancy. Even with this tenfold increase in the size of the uterus, the fetus and its associated fluids and membranes will account for about 85% of the total weight of the uterus. In mammalian species placental growth occurs primarily in the first half of gestation, while the fetus starts to quicken growth mid-gestation and continues until birth (Owens, 1991). However the placenta continues to develop during late gestation, undergoing changes that ensure the placental function can keep up with fetal growth. In late gestation a significant proportion of placental glucose utilization is directed towards lactate production which is released into umbilical circulation (Ferrell and Ford, 1980). There is a strong correlation between placental and fetal weight; if placental function is reduced fetal growth is restricted in a wide range of species (Owens et al, 1989). In sheep and cattle uterine blood flow increases three- to four fold from mid- to late gestation (Reynolds et al, 1986). Additionally umbilical blood flow also increases throughout gestation, and blood flow per kilogram of fetus remains constant during the last half of gestation (Reynolds and Ferrell, 1987). The large increase in gravid uterine and fetal

uptake of glucose, lactate and nitrogen from mid to late gestation depends primarily on the increase in uterine and umbilical blood flow (Reynolds et al, 1986).

Early fetal growth is related to the processes of tissue differentiation and organogenesis. Multiple studies have shown that IGF-II is an important systemic/paracrine coordinating factor in embryonic growth (Le Roith et al. 2001; Haig and Graham, 1991). When IGF-II is overexpressed, or when clearance of IGF-II is impaired (by knockout of IGF-II receptor) overgrowth of the embryo occurs. Conversely, knockout of IGF-II leads to poor fetal embryonic growth (Gluckman and Pinal, 2003). The major substrates for growth and energy by the gravid uterus are oxygen, glucose and amino acids. Oxygen deficit in utero is associated with significant reductions in fetal growth and birth weight (Owens et al, 1989). Cross-breeding studies have suggested that normal fetal growth in late gestation is constrained by uteroplacental factors and that it is the maternal phenotype that determines the size of the fetus at birth (Morel et al. 1994). It is believed that it is the delivery of nutrients to the fetus that is constrained, preventing overgrowth and dystocia. However, the nature of this constraint is not understood (Gluckman and Pinal, 2003). The fetal IGF-1 system is also sensitive to maternal nutrition. In fetal sheep, short term maternal malnutrition leads to cessation of fetal growth associated with reduced fetal IGF-1 levels and altered IGF binding proteins (Gallaher et al. 1994). In another study ewes were undernourished but then restored to normal nutrition for the remainder of pregnancy. These ewes had slower fetal growth in late gestation which was associated with insulin resistance and altered placental lactogen production (Harding, 1997). Macro- and micronutrients can also affect the pattern of human and livestock fetal growth. Patterns of fetal growth in early and late

pregnancy may be linked to the maternal intake of carbohydrates (Godfrey et al. 1996), and there is evidence that micronutrient availability can have major influence on the somatotrophic and insulin axes ( Boucher, 1998; Faure et al. 1997).

### **Pregnancy in the Mare**

Several features of pregnancy in the mare are unusual and differ from other domestic animal species. In the mare the embryo enters the uterine lumen around 6 days after ovulation, and remains mobile until day 16 or 17 (Allen, 2005). Movement of the embryonic vesicle is passive, and is thought to be important in signaling maternal recognition in the dam. Once the embryonic vesicle becomes fixated (day 16 after ovulation) it changes in shape becoming more triangular (Ginther, 1983). The conceptus begins to attach to the endometrium around day 40 to 45 of gestation. The attachment is gradual, and full placental attachment occurs by day 150. Unique to the equine placenta is formation of endometrial cups around day 30 of gestation (Allen, 2005) . The endometrial cups attain maximum size at about day 70 of gestation and will begin to undergo degeneration and will be sloughed by day 130 of gestation. The endometrial cups secrete equine chorionic gonadotropin which assists in the formation of accessory corpora lutea which helps sustain the primary corpora lutea during pregnancy (Holtan et al, 1979). The allantois is not discernible in the mare until day 20 (Van Niekerk and Allen, 1975) , but it grows quickly to provide the dominant blood supply to the chorion. The fused allantois and chorion then attaches to the endometrium to form the placenta. One unusual feature of the equine fetal membranes is the complete separation of the allanto-chorion and amnion by the expanding allantoic cavity (Van Niekerk and Allen, 1975). This results in the umbilical cord being divided into allantoic and amniotic parts.

Microcotyledons form over the entire area of the allanto-chorion. The chorionic components of the microcotyledons are villous, and the endometrial side is made up of crypts corresponding to the villi. The allantoic side of the membrane is smooth and the fetal blood vessels are prominent on its surface (Van Niekerk and Allen, 1975). The allanto-amnion completely envelops the fetus and blood vessels are evident between the two layers of the membrane. The umbilical cord contains two umbilical arteries and one umbilical vein which provide the interchange of blood between the fetal and placental circulations. Maternal circulation to the microcotyledon comes from branches of the uterine artery that break over the rim on the microcotyledon and develop into a dense vascular network in walls of the maternal crypts, then drain to a single uterine vein. The chorionic villi are fed and drained by the branches of the umbilical arteries and veins (Van Niekerk and Allen, 1975). A healthy and extensive microcotyledonary placenta attached to fully functional endometrium is a prerequisite for a healthy live foal (Allen, 2005).

### **Angiogenesis in the Placenta**

Angiogenesis is the formation of new blood vessels or neovascularization, and is an essential component of tissue growth and development. The female reproductive organs contain some of the few tissues that exhibit rapid periodic growth and regression. Similar rapid growth is observed in uterine and placental tissues (Rosenfeld et al. 1974, Ferrell, 1989). The rapid growth and regression of reproductive materials are accompanied by rapid changes in rates of blood flow to the reproductive organs. When fully functional, ovarian, uterine and placental tissues receive some of the greatest rates of blood flow, on a weight specific basis, of any tissues in the body (Rosenfeld et al.



1974). Placental vascular growth begins early in pregnancy and continues throughout gestation in association with a continual and dramatic increase in rates of uterine and umbilical blood flows (Rosenfeld et al. 1974, Ferrell, 1989, Reynolds et al. 1995). Increased blood flow to placental tissues satisfies the steady increasing metabolic demands of fetal growth (Ferrell, 1989), and may also influence the rate of physiological exchange between the maternal and fetal systems later in gestation (Reynolds et al. 1995). Establishment of functional fetal and placental circulations are some of the earliest events during placental development. Research has shown that the large increase in transplacental exchange, which supports fetal growth late in gestation, depends primarily on the dramatic growth of the placental vascular beds and the resultant large increases in uterine and umbilical blood flows (Reynolds et al. 1995). Factors that influence development and function of the vasculature of the placenta have a dramatic impact on fetal growth and development, which in turn affects neonatal survival and growth (Reynolds et al. 1995).

In sheep, by day 24 after mating, structural vascular volume of the endometrium exhibits a twofold increase in the gravid uterine horn, the non-gravid horn also exhibits angiogenesis but not until day 30 after mating (Reynolds et al. 1992). Vascular density of maternal placental tissues continues to increase slowly throughout gestation, whereas vascular density of the fetal placental cotyledons remains relatively constant through midgestation and increases during the last third of gestation (Barcroft and Barron, 1946 as referenced by Reynolds and Redmer, 2001). These patterns of angiogenesis coincide with the dramatic increases that have been reported for uterine and umbilical blood flows. It

has also been reported that umbilical blood flow increases more rapidly than uterine blood flow during the last third of gestation (Reynolds et al. 1992).

Numerous factors have been implicated in angiogenesis, but recent studies have led to the identification of the major factors regulating the angiogenesis process, including those involved in placental vascularization. These angiogenic factors include the vascular endothelial growth factor (VEGF), fibroblast growth factor (FGF), and the angiopoietin (ANG) protein families (Klagsbrun and D'Amore, 1991). Recent evidence has implicated VEGF in fetal and placental angiogenesis during late pregnancy in mice (Breier et al. 1997). In addition, VEGF is present in human fetal and placental tissues, and is also produced by sheep placental tissues throughout gestation (Cooper et al. 1995, Zheng et al, 1995). During early pregnancy expression of VEGF mRNA is great in fetal placental compared with maternal placental tissues, as the pregnancy progresses VEGF remains high in placentome and intercotyledonary fetal membranes. During early pregnancy VEGF protein localizes to the developing cotyledonary microvasculature, however in late pregnancy VEGF protein is found primarily in the microvessels of the maternal caruncle villi, with only a portion of the fetal cotyledonary arterioles exhibiting VEGF protein (Reynolds and Redmer, 2001). The FGFs are also potent angiogenic factors that stimulate proliferation of both uterine arterial and fetal placental arterial endothelial cells (Klagsbrun and D'Amore, 1991). In addition to their role in placental angiogenesis, both VEGF and FGF may be involved in regulating placental blood flow (Magness, 1998).

## **Fetal and Placental Heat Production**

The main factors controlling heat exchange across the placenta are the maternal-fetal temperature difference, the placental permeability and the arrangement of bloodstreams (Schroder and Power, 1997). It is expected that the placenta does not limit the diffusion of heat between fetal and maternal bloodstreams, and that any limitation of the pathway is due to limited heat transfer capacity of the umbilical circulation (Schroder and Power, 1997). It is assumed that heat flux in the placenta is not confined to the exchange area but also occurs between small umbilical vessels as they enter or leave the placenta. The contribution of the placental heat production to the fetal-maternal temperature difference has been estimated to be  $0.07^{\circ}\text{C}$  (Schroder et al. 1988). Research has shown that fetal tissues are warmer than the maternal tissues, with the fetus exceeding maternal temperatures by  $0.5^{\circ}\text{C}$  to  $1.0^{\circ}\text{C}$  in many mammalian species (Schroder et al. 1987). If the maternal temperature rises, the fetal tissues will also rise resulting in a positive fetal-maternal temperature difference (Schroder and Power, 1997). Fetal heat production can be deduced from fetal oxygen consumption and by differential calorimetry. The results of these techniques indicate fetal heat production for fetal sheep late in gestation to be  $3$  to  $4 \text{ W (kg fetal body weight)}^{-1}$  (Power et al. 1984). The total heat conductance between fetus and mother can be calculated from the maternal-fetal temperature difference and the fetal heat production as  $7 \text{ W kg}^{-1} \text{ }^{\circ}\text{C}^{-1}$  (Schroder and Power, 1997). It has been suggested that heat may move along two pathways, a convective pathway via the umbilical circulation towards the placenta, and a conductive pathway from fetal surfaces, through the surrounding fluids, towards the uterine wall. The conductance of the fetal surfaces controls heat transfer from the fetus into the

amniotic/allantoic fluid, and the conductance of the uterine wall influences heat flux from the extra fetal fluids into the wall of the uterus (Schroder and Power, 1997). The amount of heat produced by the placenta and the uterine wall is reported to be 2.1 W/kg of tissue (Power, 1989), which will also increase the fetal temperature. Gilbert et al. (1985) stated that in sheep heat readily passes across the placenta when compared to transfer across the fetal skin. They found that 85% of heat that is produced by the fetal lamb is transferred to the mother by the umbilical circulation, where the remaining 15% is dissipated through the fetal skin to the amnion, and then passes through the uterine wall to the maternal abdomen (Gilbert et al. 1985).

## **Antler Physiology**

### **Biology of the Antler**

The antler can be described as a vascularized, growing tumor, which develops an analogous blood, neural and cartilaginous network that ossifies and dies following hormonal induction of capillary constriction resulting in shedding of the velvet.

In mammals the antler is the only organ that is fully regenerated, moreover the antler is the only organ composed of bone to be regenerated by any vertebrate (Haigh and Hudson, 1993). Deer antlers are deciduous appendages which grow from permanent bony protuberances, the pedicles, which are prerequisites for normal antler growth. Antlers are grown and cast annually, however the development of the pedicles is a once in a lifetime event. The developing pedicles grow about 2 cm left and right of the median of the frontal bone. They develop postpartum from a region of thickened periosteum during a period that is species specific (Bubenik, 1990). In red deer pedicle initiation starts around 19 weeks after birth when daylight length is decreasing and at a body weight of  $41.2 \pm$

1.07 kg when the deer were fed to appetite (Suttie and Kay, 1982). In fallow deer, pedicle development is reported to start around six to seven months of age (Chapman, 1975). From the onset of initiation, the pedicle grows continuously to a height of several centimeters, and is covered by skin and hair of the scalp. Further elongation of the pedicle leads to the growth of the first set of antlers (Goss, 1983). The onset of antler growth in red deer appears around 28 weeks of age (Suttie and Kay, 1982) reaching an average length of 30 cm. However, if the onset of pedicle initiation was delayed, the antler growth will be delayed as well (Fennessy and Suttie, 1985). The first pair of antlers are usually unbranched spikes, that will undergo an annual cycle of calcification, cleaning, casting and regeneration. In fallow deer the first antler is usually an unbranched spike of 1 to 20 cm in length, and becomes hard bone when the animal is 15 months old (Asher, 1992). It has been reported that these first antlers are retained until the animal is two years old (Chapman, 1975).

The developing antler is innervated mainly by the infratrochlear and zygomaticotemporal branches of the fifth cranial nerve (Adams, 1979). The infratrochlear nerve innervates the rostral and medial sides, where the zygomaticotemporal nerve innervates the lateral and caudal aspects of the antler. In some deer a further third branch from the auriculopalpebral nerve can supply the medial antler (Adams, 1979). The growing antler is highly vascularized and richly innervated. Arterial supply to the antler is formed by branches of the superficial temporal artery, which arises from the carotid artery (Adams, 1979). The lateral branch supplies the antler and the medial branch the pedicle. A smaller artery supplying the pedicle arises from the superficial temporal artery and runs dorsally on the pedicle. The lateral and medial arteries to the pedicle form a

vascular ring which encircles the pedicle. From this ring, 9-12 branches pass distally up the pedicle (Adams, 1979). Early in growth, considerable arterial supply and venous drainage is available through the pedicle, but this diminishes as calcification progresses. Venous drainage is provided by ventral veins (Adams, 1979) to the superficial temporal vein (Haigh and Hudson, 2003). The growing antler is covered with velvet which is separated from the antler by connective tissue. The blood supply is present in this layer of connective tissue (Haigh and Hudson, 2003). Changes in the vascular system initiate velvet shedding before calcification of the antler is complete. Velvet shedding occurs as circulating testosterone levels are rising which may cause direct constriction of coronal arteries. Testosterone may also interfere with tissue metabolism, resulting in necrosis and consequent arterial constriction (Haigh and Hudson, 2003).

### **Nutritional Aspects**

Normal development of the pedicle and first set of antlers can be influenced by a number of factors, including nutrition. It has been proposed that animal weapons have low growth priority and are more affected by shortage of food (Clutton-Brock and Albon, 1989). Deterioration of habitat or rising population density can also produce a rapid decline in antler size. The interaction between nutrition and photoperiod on antler development in red deer calves has been investigated by restriction of food during November to May (Suttie and Kay, 1982). The restricted stags began pedicle development later at about 31 weeks of age compared to the normal 19 weeks after birth. However, when considering body weight at the onset of pedicle initiation the restricted group did not differ from the unrestricted group (Suttie and Kay, 1982). Throughout the growth of the first antler the deer that received proper nutrition began each stage of antler

development earlier than the restricted group, but each stage occurred when stags had obtained the same body weight. This led Suttie and Kay (1982) to conclude that the major stages of development of the first antler appear to be related to the nutritional status of the deer.

### **Endocrine Regulation**

Temperate deer species exhibit a pronounced annual cycle in reproduction and secondary sex characteristics. This includes antler cycles, changes in testicular activity and neck circumference. The annual recurrence of these events is triggered by seasonal fluctuations of daylight length which influence the production of melatonin by the pineal gland (Webster et al. 1991, Bubenik, 1990).

Pedicle growth can be activated by testosterone, (Kierdorf, 2002) or inhibited by estrogens. In most species, the antlers are produced only in males and grow under the stimulus of testosterone from the testes during the sensitive phase for pedicle development (Bubenik, 1990). A study conducted by Suttie et al. (1991) investigated luteinizing hormone (LH) and testosterone changes in red deer from the age of 3 to 15 months. The deer were sampled once a month for 24 hrs and showed a pulsatile secretion of LH in three phases with consecutive testosterone pulses. The first phase (March until August, Southern Hemisphere) was characterized by a slow increase of LH and testosterone pulses. This coincided with the onset of pedicle growth. In the second phase (August until November/December), when the velvet is growing, LH and testosterone concentrations declined. This is followed by the third phase (November/December until March) by a rapid increase in LH and testosterone pulses. Testosterone concentrations were high at the time of antler calcification and stripping of the integument (Suttie et al.

1991). The role of testosterone is further supported by the fact that removal of the testes before the onset of puberty prevents pedicle and antler growth (Jaczewski, 1982). It is suggested that testosterone is necessary for the organization of antler tissue into Haversian bone (Fennessy and Suttie, 1985). The application of antiandrogens or castration when the antler is in the hard state leads to premature antler casting (Kierdorf, 1993). Growth hormone (GH) is known to have a growth promoting effect on cartilage (Suttie et al. 1989). Growth hormone also stimulates the release of insulin-like growth factor 1 (IGF-1). Peak levels of IGF-1 coincide with the peak of velvet antler growth, and it has been concluded that IGF-1 may be responsible for velvet antler growth (Suttie et al. 1989, Suttie et al. 1991).

### **Antler Harvesting**

The harvesting of velvet antler from farmed red deer stags is a renewable resource of economic significance to the deer farming industry. Velvet antler removal has been an accepted deer farming practice in China for centuries (Zhang 1982). Deer farming became a lucrative industry in the western world around 30 years ago, and the harvesting of VA soon became a driver of industry growth (Wallis 1993). In the deer industry, welfare is a significant priority and velvet antler removal is one of the most sensitive issues (Loza 2001). Compliance standards for removal of velvet antler from stags in New Zealand, Australia and Canada are described in the deer industry “Programmes” (Campbell 1993, Wilson et al. 2001, Church and Church 2001). The removal of velvet antler is prohibited in some countries including Ireland and the United Kingdom. In other countries it is not practiced because animal welfare legislation is interpreted as



forbidding it, while in other countries there is no general animal welfare legislation in place (Wilson and Stafford, 2002).

Velvet antler removal is the surgical amputation of living, vascular and innervated tissue (Wilson et al., 2001). It is usually performed on young stags prior to harvest, or older stags farmed specifically for this purpose or while maintained as breeding sires (Wilson and Stafford, 2002). Restraint is necessary for administration of analgesia for velvet antler removal, which is required for welfare purposes to reduce the pain and stress associated with the removal of the antler.

Velvet antler is usually harvested based on tissue, age, morphology, conformation and/or size of the antler, which is not always the time of peak growth. Grades of velvet antler are assigned based on size, shape, degree of mineralization, blood content, color and damage (Haigh and Hudson, 2003). The most important decision is when to cut, with the optimum being defined by the trade-off of size and mineralization. The Korean market wants large, thick pieces with cross sections showing an even distribution of blood and little mineralization, a delay of several days past prime leads to serious downgrading of velvet antler. Mineralization is difficult to assess until after harvest, so most farmers use antler shape as a guide (Haigh and Hudson, 2003).

Velvet antler has been used for thousands of years in the Orient as an essential component in herbal medicine (Sunwoo and Sim, 2000). It has been said to have functions to enhance body metabolism and cure various maladies. Studies originating in the Orient show that antler products influence body metabolism (Zhang, 1982), promote immune functions (Li and Wang, 1990) and slow the aging process (Chen et al, 1992). In vitro experiments have investigated the ability of extracts of growing antler to accelerate

wound healing (Bubenik, 1990) and stimulate the activity of protein and RNA synthesis in tissue culture (Wang et al, 1990). More recently, research into the use of velvet antler for the treatment of heart failure (Shao et al, 2012) and physical and neurological development of offspring (Chen et al, 2012) has been performed. In additional work, Zha and others (2012) treated burn-wounded rats with a polypeptide of velvet antler from sika deer. These treated rats exhibited significant increases in the rate of wound contraction, tensile strength and epithelialization as comparison to untreated control rats. Furthermore, the wound healing effect was more marked when the rats were treated with 0.05% velvet antler ointment compared to 0.02% (Zha et al, 2012).

### **Additional Applications of Thermography in Deer**

In addition to monitoring angiogenesis and velvet antler growth, which has been discussed previously, infrared thermography has been implemented in population counting, stress response and disease detection in deer. Cook and Schaefer (2002) investigated the use of thermal imaging to detect stress in wapiti by measuring radiated heat loss. Previous studies have indicated that stress has been shown to alter heat patterns in beef cattle and swine (Schaefer et al, 1988, 1989). Cook and Schaefer (2002) found that there was an average temperature increase over the harvesting process of 1.13°C. This metabolic response, measured by infrared thermography, was very similar to responses observed for cattle and swine (Schaefer et al, 1988, 1989) and also patterned adrenocortical responses (Cook and Schaefer, 2002). An additional study by Cook and others (2005) showed an increase in eye temperature, measured by thermal imaging, in response to velvet antler removal in elk and reindeer. Thermal imaging has been used extensively in veterinary medicine in detecting lameness and infectious diseases such as

foot and mouth disease (Rainwater-Lovett et al, 2009). Dunbar and others (2009) proposed thermal imaging could detect heat changes associated with sites of infection with foot and mouth disease in infected mule deer. Results of the study indicated the thermal imaging has potential for screening animals for clinical examination of foot and mouth. Mule deer infected with the virus had a significant foot temperature rise over the course of infection, thermograms of the feet indicated increases in heat up to 20 hours before clinical signs were observed (Dunbar et al, 2009). Thermal imaging has also been utilized in population surveys, mainly of white tailed deer (Wiggers and Beckerman, 1993) but also as to aid in detection for deer capture (Butler et al, 2006).

### **Care and Maintenance of the Elephant Foot**

#### **Anatomy of the elephant foot**

The anatomy of the elephant foot has been the focus of few studies, and most of these studies involved a low number of specimens. The components of Asian and African elephants' feet are similar with the major differences being the shape of the rear foot and the number of phalanges and toenails.

#### *The Legs*

Elephants are ungulates with a modified digitigrade stance on the forefoot and semiplantigrade on the hind foot (Mikota et al, 1994). Both forelimbs and hind limbs have little angulation when compared to other mammals. The legs are straight, and the articular surfaces are in line with the axis of the leg. The limbs avoid excess strain by flexing minimally during locomotion (Hildebrand 1995). The bones of the limb are massive and lack a marrow cavity. The radius and ulna are fixed in a prone position

(Eales 1928). The fibula is separate from the tibia. The forelimb is longer than the hind leg. The increase in the leg length is accomplished by lengthening the proximal limb segments but not the distal limb segments. There is little exterior definition of leg segments, and there are no externally identifiable digits (Eisenberg, 1981).

### *The Hind Foot*

The hind foot is smaller than the forefoot and laterally compressed; resulting in an ovoid shaped sole which is more pronounced in the African elephant (Ramsey and Henry, 2001). The tarsus (T) is composed of seven bones, arranged in three rows. Each tarsal bone articulates with its corresponding metatarsal bone (Smuts and Bezuidenhout, 1994). The metatarsal (MT) bones have an expanded distal extremity for articulation with the proximal phalanx. The elephant possesses a prehallux, which is a cartilaginous segment that extends distally from MT-1 and T-1. The prehallux attaches to the sole medial to the midline. The prehallux's function is unknown, but it appears to help in stabilizing the tarsus over the digital cushion (Benz et al, 2005). The hind foot has five digits (D) that radiate in a craniocaudal (head to tail) orientation. In the African elephant, D-1 is represented by a single sesamoid bone (Smuts and Bezuidenhout, 1994), where in the Asian elephant this digit is described as having one phalanx without a sesamoid bone (Mariappa, 1986). The other digits have paired sesamoid bones. In the African elephant, D-2 has two phalanges, and in the Asian elephant D-2 has three phalanges (Mariappa, 1986). Digits three and four are larger than the other digits in both species, and each has three phalanges. Digit five has two phalanges in both species (Ramsey and Henry, 2001). The number of toenails is reported to vary between species and in the African elephant between subspecies. The African elephant is generally considered to have three

subspecies (Grzimek, 1975): the cape, the savannah, and the forest elephant. The cape and savannah elephants have three toenails on the hind foot, whereas the forest African elephant may have four toenails on the hind foot. The Asian elephant has four toenails on each hind foot corresponding to D-2 to D-5.

The digital cushion occupies the area under the tarsus and plantar to the digits. This cushion compresses and expands the foot during weight bearing (Weissenburger and Forstenpointer, 2004). The cushion also helps distribute the animal's weight over the entire sole. The foot structure is digitigrade, however extension of the digits during weight bearing may cause the hind feet to become semiplantigrade (Mikota et al, 1994). The digital cushion is poorly vascularized and there are numerous fatty masses within it (Sikes, 1971). In the Asian elephant, the digital cushion is supplied by the plantar digital arteries and palmar digital nerves (Mariappa, 1986). The foot sole, is a flexible, 4 to 12 cm thick, keratinized pad covering the plantar surfaces of the feet. Upon removing the sole, numerous indentations are seen in the foot, which are projections of the sole that extend into the sensitive dermis of the foot (Evans 1961). The toenail is a plate-like cornification of the outer layers of the epidermis, corresponding to the distal ends of certain digits. The medial aspect of the nail contains vertical horny leaves, or laminae, that interdigitate with laminae on the distal digit (Evans 1961).

### *The Forefoot*

In the forefoot the carpal bones are arranged in two rows of four (Smuts and Bezuidenhout, 1995). The proximal row includes the radial, ulnar, intermediate and accessory carpal bones. The distal row of bones is referred to as carpal bones one to four (C1-4). These carpal bones articulate with their corresponding metacarpal (MC) bones. In

the Asian elephant the three carpal joints each contain its own synovial sac (Mariappa, 1986). The region distal to the carpus of the forefoot resembles the hind foot (Smuts and Bezuidenhout, 1995). There is a prepollux, extending from the C-1 and MC-1 and attaching to the sole medial to the midline (Weissengruber et al, 2006). In the Africa elephant D-1 has one phalanx and a single sesamoid bone, in the Asian elephant D-1 has two phalanges and a single sesamoid bone. The other digits have paired sesamoid bones plantar to the metatarsal-phalangeal articulation. Digit five has two phalanges and digits two, three and four have three phalanges, similar to the hind foot, and digit three is the largest. The cape and savannah African elephant have four toenails on the forefoot. The forest African elephant and the Asian elephant have five toenails on the forefoot. The sole of the forefoot of both species is round (Mariappa, 1986; Grzimek, 1975).

In the Asian elephant the median artery passes with the median vein and nerve down the medial aspect of the antebrachium to the carpus where it becomes the metacarpal artery. Branches of the median artery include the interosseous artery, which descends to the lateral aspect of MC-5 and continues as the fifth digital artery (Mariappa, 1986). The metacarpal artery then branches laterally and ventrally to become the deep palmar arch. This arch then branches the metacarpal arteries, which become the palmar digital arteries. The median nerve courses with the median artery and vein to the level of the carpus. Below the carpus it divides into four terminal branches becoming the palmar digital nerves. (Mariappa, 1986).

### *The Cushion*

The cushions of the elephant foot are complex structures of adipose tissue and fibrous connective tissue which occupies the space between the bones, tendons and

ligaments of the foot (Weissengruber et al, 2006). Small blood vessels are visible throughout the cushion but larger vessels are absent, except for one large bundle of larger vessels, nerves and fibrous tissues that run into the central portion of the cushion. However, the main vessels of the foot lie adjacent to the bones and on the outside of the cushion (Weissengruber et al, 2006). Examining the cushion of the foot microscopically reveals that the sole is covered by a thick keratinized squamous epithelium, which lies on a massive layer of connective tissue forming the dermis (Weissengruber et al, 2006). The dermis is rich in blood vessels and nerves that lie within the connective tissue. The subcutaneous vascular network proximal to the sole and the superficial vessels surrounding the entire foot are visible even macroscopically (Weissenburger et al, 2006). When loaded the hindfoot cushion is compressed and expands medially, laterally and plantarly (Ramsay and Henry, 2001), however when the sole is unloaded the surface is convex (Smuts and Bezuidenhout, 1994). In the forefoot the surface of the sole remained flattened even when unloaded which may be due to the different structure and shape of the cushion (Weissengruber et al, 2006). The main difference in cushion structure between the African and Asian elephant is the Asian elephant seems to have more connective tissue within the cushions when compared to the African species (Benz, 2005). Overall the cushions in the feet of elephants are highly specialized and adapted to allow pain-free weight bearing and locomotion of the largest animal that walks on land (Weissengruber et al, 2006).

### **Husbandry Practices for the Elephant Foot**

There are numerous approaches to maintaining elephants in captivity, which leads to numerous ways of caring for the elephant foot. Usually each institution develops their

own philosophy on the best way to care for their elephants depending on type of contact allowed and the knowledge of the institution's handlers. An additional factor is the disposition of the elephant. The easier it is to handle the elephants the easier it will be to implement a foot care program (Roocroft and Oosterhuis, 2001).

Adequate exercise is one of the most important aspects of proper elephant care. To keep the feet healthy the joints, tendons and ligaments need to be used on a regular basis. When proper exercise is not provided foot problems appear, especially in older or aged elephants. One to two hours of walking each day should be considered the minimum amount of time an elephant needs for cardiovascular activity (Roocroft and Oosterhuis, 2001). In the wild, elephants visit water holes twice a day to drink, swim and socialize. This provides wild elephants with exercise but also cleans and rejuvenates their skin, in addition to the sand scrubbing between the nails and cuticles of the foot. When an elephant is in captivity their feet are exposed to feces and urine. To reduce the negative effects of these conditions the elephant's legs and feet should be washed daily using a hard bristle brush. In addition most zoo habitats for elephants consist of cement or asphalt floors (Dimeo-Ediger, 2001). Floors that are resilient but have yielding surfaces are a much better substitute than concrete for the elephant enclosure (Meller et al, 2007). Substrates that allow digging will increase the use of the legs and feet and strengthen the leg and foot muscles, tendons and joints (Gage, 1999). Unlike elephants in the wild, captive elephants rarely wear down their pads resulting in the pads becoming overgrown and cracked. This requires correct, well implemented pedicures of the foot on a regular basis. These pedicures are essential for a captive elephant's health.



### *The Pedicure*

Captive African and Asian elephants have two distinctly different foot care needs (Roocroft and Oosterhuis, 2001). African elephants need little nail care, with most of the foot care being directed towards trimming the pad. This is probably a result of the wild African elephant traveling many miles on hard, dry surfaces looking for food and water. In contrast, the Asian elephant, whose natural environment is moist and lush, needs considerable nail and cuticle work and relatively little pad care. In general, both species need more care as they get older, especially elephants that are not receiving adequate amounts of exercise (Roocroft and Oosterhuis, 2001).

To begin a foot care program the proper tools are essential. The basic tools needed are two sizes of hoof knives with appropriate hones for sharpening and a hoof rasp. Some individuals use power tools when performing pedicures, but this is discouraged due to the fact that it is very easy to remove too much of the foot too fast which can cause serious damage (Fowler, 1993). Another tool is the standard elephant tub, which helps position the foot for trimming. A normal sized tub is comfortable for the average elephant for long periods of time. Older elephants may need a car or trailer tire, as a cushion, placed on top of the tub to help alleviate pressure on the knee (Roocroft and Oosterhuis, 2001). For elephants maintained in a protected contact system different types of stirrups and foot cradles have been developed. The interval between pedicures in an Asian elephant that is exposed to regular, supervised exercise or activity is three months. Elephants standing in a zoo exhibit with little exercise will need foot care more often (Roocroft and Oosterhuis, 2001).

Filing the surface of the nail requires an awareness of the thickness of the nail and the anatomy of the tissue behind it. If the nail is filed too thin, it will expose the sensitive laminar tissue, which will dry and crack. Many circus trainers have had elephants hit their feet on tent posts or stakes and since filing may compromise the strength of the nail it is common practice to leave the nail a little thick (Houck, 1993). In addition, the nail is one region where differences between African and Asian elephants are apparent. The African elephant is a browser and uses its trunk to obtain food, whereas the Asian elephant uses its feet to assist the trunk in obtaining grass and roots. The nails of the Asian elephant act like chisels, digging deep into the soil so it is thought this is why the Asian elephant's nails grow much quicker and need additional care (Roocroft and Oosterhuis, 2001). The pads are also different between African and Asian elephants (Benz, 2005). The Asian elephant in the wild walks on soft, yielding surfaces, while the African elephant walks on grass, sand, and the hard dry surfaces of semiarid deserts (Roocroft and Oosterhuis, 2001). The pads of an elephant in the wild are not smooth or well manicured; rather they have deep grooves and cracks. These pads are not in disrepair because the elephant walks great distances to feed and obtain water. In the process they wear their pads and nails sufficiently and maintain healthy feet. Elephants in captivity are not subjected to this kind of exercise and urine and feces collect in the cracks of the pads (Roocroft and Oosterhuis, 2001). However, over trimming the pad is a common occurrence in captivity. The deeper the trim, the lighter in color the sole of the foot becomes. Cracks in the pad can be trimmed and reduced over the course of several pedicures. It is also common that the elephant will continue to rub and wear its newly trimmed pad on a concrete floor, because of the unusual feeling. If sufficient pad is not left the elephant itself can do

substantial damage to the foot. Overgrowth is the most common problem associated with the cuticle of an elephant's foot (Fowler, 1993). The overgrowth takes on the appearance of feathering and removal is very difficult and painful. Another condition that occurs in relation to the cuticle is the development of fluid pockets behind the overgrown cuticles. It appears that when the sweat glands are covered by an untrimmed cuticle they become blocked, causing small pockets of fluid to develop. This creates pressure and pain when the elephant walks, which is evident by a more flat footed gait (Fowler, 1993).

### **Common Problems of the Elephant Foot**

#### *Abscesses*

In the elephant, abscesses are commonly seen and are usually not due to a puncture or insult to the foot. It is thought the abscesses are caused by internal blood supply disruption, which is a sign or symptom of the problems associated with elephants in captivity (Roocroft and Oosterhuis, 2001). The lack of exercise, the added weight and the surfaces a captive elephant is housed on combined with abnormal behavior and poor conformation provides an environment suitable to the development of abscesses (Meller et al, 2007). Any abnormal pressure on the nails will result in a disruption of the blood supply to the sensitive tissue behind the nail. When this tissue is subjected to constant or intermittent abnormal pressure it will eventually become devitalized and then form an abscess. This abscess will usually rupture toward the surface at the cuticle line or at the border between the bottom of the nail and the pad (Roocroft and Oosterhuis, 2001). Abscesses can also occur in the pad of the foot and can be caused in the same way as nail abscesses; from tissue devitalization. When dealing with the pad, this tissue devitalization can be caused by a single insult to the pad (stone bruise) or by improper

trimming (Roocroft and Oosterhuis, 2001). In addition, excessive walking on hard surfaces can wear the pad too thin and cause devitalization of the underlying tissue, which will result in an abscess that will rupture at the surface, usually in the heel area. In all of these cases it is vital that the developing abscess be recognized early so it can be dealt with as soon as it ruptures so additional tissue is not involved (Fowler and Mikota, 2006). Constant removal of the necrotic material and keeping the wound open to allow for draining are the most important ways to allow for rapid healing. If bacteria are allowed to colonize the abscess, they will invade the surrounding tissue and cause tissue destruction that an elephant's immune system cannot fight (Fowler and Mikota, 2006). Another important aspect of abscess treatment is soaking the foot in warm water and a disinfectant solution such as chlorhexadine or tamed iodine. If the abscess begins to infect the internal structures of the foot more drastic measures must be taken. Radiographs are used to determine if bones are involved, surgical procedures are performed to remove necrotic tissue and administration of systemic antibiotics will occur (Fowler and Mikota, 2006). At this point a boot is used to cover the foot and hold packing material in place, however the boot must be removed at least twice daily to allow for proper draining and wound care (Woodle et al, 2001).

### *Cracks*

Cracks are normal in the pads of an elephant's foot but not in the nails (Roocroft and Oosterhuis, 2001). Nail cracks are usually the result of a repetitive movement (rocking) that puts abnormal pressure on the nail. If an elephant sleeps on the same side each night on a hard surface any slight movement can file down the surface of the lateral toenails. The nails may become so thin that they crack when the elephant puts lateral

pressure on them. Moreover, if an elephant gets up and down frequently on hard surfaces, the middle nail on the rear foot can also be subjected to cracking (Roocroft and Oosterhuis, 2001). These examples are exacerbated when the elephant is overweight or if the nails are allowed to grow too long. Nail cracks can also occur due to poor conformation. Any abnormality in leg posture or gait can predispose these elephants to foot problems. If a nail crack is not cared for it can result in a chronic problem, especially if it extends upward to the cuticle and damages the nail's germinal tissue. In addition, nail cracks can also lead to the formation of abscesses (Roocroft and Oosterhuis, 2001).

There are many ways to care for a crack in the nail of an elephant's foot. The underlining goal in any treatment is to stop the progression of the crack and allow the nail to grow out until the crack is eliminated. In elephants the best method seems to involve using the edge of the rasp to open the crack at the bottom and up along its course (Roocroft and Oosterhuis, 2001). A small hoof knife is then used to remove debris from the crack and get to healthy tissue. The base of the nail is then rasped down and rounded off to take pressure off the nail and crack when the elephant walks. Maintenance of the crack is a continual and frequent process. It requires many trims until the nail grows out, which can take up to six months (Roocroft and Oosterhuis, 2001). The crack should be inspected daily and washed and scrubbed to remove any dirt or debris. Cracks in the pad are normal and should not be removed, but if the pad is allowed to overgrow the cracks can become deep and angled, which in turn can trap small stones and cause bruises or punctures to the foot, which could then lead to abscesses (Roocroft and Oosterhuis, 2001).

## **Detecting Problems in the Elephant Pad**

Thermography and its ability to detect lameness and inflammation in the elephant foot has been discussed previously in the review of the literature, however it is important to also consider other methods of assessing the elephant foot. The Association of Zoos and Aquariums states that each elephant facility must have a written protocol for routine foot care and show evidence that this plan has been implemented. In addition, baseline foot radiographs or thermographs of all adult elephants must be taken and kept on file (AZA, 2003). Most elephant foot radiography reports have focused on conventional analog radiography techniques (Siegal-Willott et al, 2008). Recently, the use of digital radiography to assess foot pathology in elephants has become common. Digital radiography offers the advantage of consistent, rapid and obtainable diagnostic foot radiographs in free and protected contact settings. In addition the need for film, processing chemicals and light boxes are eliminated, since images may be adjusted and displayed on computer monitors (Siegal-Willott et al, 2011). Direct digital radiography can be conducted on site and evaluated patient side, a great benefit when evaluating large mammals that are not brought into the hospital. Direct radiography systems also have a wider exposure operating range, allowing for the possibility of viewing soft tissues and bony structures on the same image (Siegal-Willott et al, 2011). Just as in thermal imaging the foot must be clean of all debris to minimize artifacts that could occur. The elephant must also be trained to only put minimal weight on limb to be radiographed (Siegal-Willott et al, 2011).

### **Additional Applications of Thermography in Elephants**

In addition to detecting lameness and inflammation (discussed earlier) thermal imaging has also been implemented to study thermoregulation in elephants. The elephant has a low surface to volume ratio and a small surface area for heat transfer (Williams, 1990). Many studies have suggested elephants overcome this by using thermal windows (Wright, 1984), which are body areas responsible for heat exchange. Heat dissipation is further restricted due to their lack of sweat glands (Mariappa, 1986) and the absence of panting (Robertshaw, 2006). Weissenbock and others (2010) used thermal imaging to visualize skin temperature of African elephants at different ambient temperatures. They found that the ear surface not only acts as a thermal window but sections of the ear are able to act as a window also, and that the temperature of the ears can be controlled independently. Thermal windows were also observed on the remaining body surface as well, and they varied in number, shape and size. These observations indicate that thermal windows of African elephants seem to be more developed and used more often than once assumed (Weissenbock et al, 2010).

## References

- Adams, J. L. (1979). Innervation and blood supply of the antler pedicle of the Red deer. *New Zealand Veterinary Journal*, 27(10), 200-201.
- Alsaad, M., & Büscher, W. (2012). Detection of hoof lesions using digital infrared thermography in dairy cows. *Journal of dairy science*, 95(2), 735-742.
- Ammer K., P. Melnizky, and O. Rathkolb. 2003. Skin temperature after intake of sparkling wine, still wine or sparking water. *Thermology International* 13(3)99-102.
- Anbar, M. (1998). Clinical thermal imaging today. *IEEE Eng Med Biol Mag*, 17(4), 25-33.
- Anderson, F. A., & Wheeler, H. B. (1995). Venous thromboembolism. Risk factors and prophylaxis. *Clinics in chest medicine*, 16(2), 235-251.
- Asahara, T., Bauters, C., Zheng, L. P., Takeshita, S., Bunting, S., Ferrara, N., et al. (1995). Synergistic Effect of Vascular Endothelial Growth Factor and Basic Fibroblast Growth Factor on Angiogenesis In Vivo. *Circulation*, 92(9), 365-371.
- Azmat, Z., & Turner, D. J. (2005, 8-10 May 2005). *Infrared thermography and its role in rural utility environment*. Paper presented at the Rural Electric Power Conference, 2005.
- Bagavathiappan, S., Saravanan, T., Philip, J., Jayakumar, T., Raj, B., Karunanithi, R., et al. (2009). Infrared thermal imaging for detection of peripheral vascular disorders. *J Med Phys*, 34(1), 43-47.
- Barcroft, J., & Barron, D. H. (1946). Observations upon the form and relations of the maternal and fetal vessels in the placenta of the sheep. *The Anatomical Record*, 94(4), 569-595.
- Boucher, B. J. (1998). Inadequate vitamin D status: does it contribute to the disorders comprising syndrome 'X'? *British Journal of Nutrition*, 79(04), 315-327.
- Brånemark, P., Fagerberg, S., Langer, L., & Säve-Söderbergh, J. (1967). Infrared thermography in diabetes mellitus a preliminary study. *Diabetologia*, 3(6), 529-532.
- Breier, G., Damert, A., Plate, K. H., & Risau, W. (1997). Angiogenesis in embryos and ischemic diseases. *Thrombosis and haemostasis*, 78(1), 678-683.
- Broxmeyer, H. E., Cooper, S., Li, Z. H., Lu, L., Song, H. Y., Kwon, B. S., et al. (1995). Myeloid progenitor cell regulatory effects of vascular endothelial cell growth factor. *International journal of hematology*, 62(4), 203-215.



- Butler, D. A., Ballard, W. B., Haskell, S. P., & Wallace, M. C. (2006). Limitations of Thermal Infrared Imaging for Locating Neonatal Deer in Semiarid Shrub Communities. *Wildlife Society Bulletin*, 34(5), 1458-1462.
- Campbell, AC. 1993. Implementation of the velvet harvesting code of conduct. *Proceedings of a Deer Course for Veterinarians, No. 10, Deer Branch of the New Zealand Veterinary Association*: 17-22.
- Cao, L. G., & Wang, Y. L. (1990). Mechanism of the formation of contractile ring in dividing cultured animal cells. II. Cortical movement of microinjected actin filaments. *The Journal of Cell Biology*, 111(5), 1905-1911.
- Cena, K., & Clark, J. A. (1974). Heat balance and thermal resistances of sheep's fleece. *Phys Med Biol*, 19(1), 51-65.
- Chapman D.I., 1975. Bones of contention. *Mammal Review* 5:121-162.
- Chen, X., Jia, Y., & Wang, B. (1992). [Inhibitory effects of the extract of pilose antler on monoamine oxidase in aged mice]. *Zhongguo Zhong Yao Za Zhi*, 17(2), 107-110, 128.
- Clark, J. A., Cena, K., & Monteith, J. L. (1973). Measurements of the local heat balance of animal coats and human clothing. *Journal of Applied Physiology*, 35(5), 751-754.
- Clutton-Brock, T. H., Albon, S. D., & Guinness, F. E. (1989). Fitness costs of gestation and lactation in wild mammals. *Nature*, 337(6204), 260-262.
- Denoble, A. E., Hall, N., Pieper, C. F., & Kraus, V. B. (2010). Patellar skin surface temperature by thermography reflects knee osteoarthritis severity. *Clin Med Insights Arthritis Musculoskelet Disord*, 3, 69-75.
- Duchaine, B., & Nakayama, K. (2006). The Cambridge Face Memory Test: Results for neurologically intact individuals and an investigation of its validity using inverted face stimuli and prosopagnosic participants. *Neuropsychologia*, 44(4), 576-585.
- Dunbar, M. R., Johnson, S. R., Rhyan, J. C., & McCollum, M. (2009). Use of infrared thermography to detect thermographic changes in mule deer (*Odocoileus hemionus*) experimentally infected with foot-and-mouth disease. *Journal of Zoo and Wildlife Medicine*, 40(2), 296-301.
- Durrant, B. S., Ravida, N., Spady, T., & Cheng, A. (2006). New technologies for the study of carnivore reproduction. *Theriogenology*, 66(6-7), 1729-1736.

- Eales, N. B. (1928). XXV.—The Anatomy of a Foetal African Elephant, *Elephas africanus* (*Loxodonta africana*). Part II. The Body Muscles. *Earth and Environmental Science Transactions of the Royal Society of Edinburgh*, 55(03), 609-642.
- Eisenberg, J.F. 1981. The Mammalian Radiations: An Analysis of Trends in Evolution, Adaptation and Behavior. Chicago: The University of Chicago Press.
- Elliott, R. L., J.F. Head, and D.K. Werneke. 1990. Thermography in breast cancer: Comparison with patient survival, TNM classification and tissue ferritin concentration,” in *Proc. Amer. Soc. Clin.Oncol.*, 9: 99.
- Emery, R. W., Emery, A. M., Flavin, T. F., Nissen, M. D., Mooney, M. R., & Arom, K. V. (1996). Revascularization using angioplasty and minimally invasive techniques documented by thermal imaging. *Ann Thorac Surg*, 62(2), 591-593.
- Evans, G.H. 1961. Elephants and their diseases: A treatis on elephants. (1910; reprint, Rangoon, Burma: Supert., Govt. Print. and Staty).
- Ferrel, C. L. 1989. Placental regulation of fetal growth. In: D.R. Campion, G.J. Hausman, and R.J. Martin (Ed.) *Animal Growth Regulation*. Pp 1-19. Plenum New York.
- Ferrell, C. L., & Ford, S. P. (1980). Blood flow steroid secretion and nutrient uptake of the gravid bovine uterus. *Journal of Animal Science*, 50(6), 1113-1121.
- Friedlander, A. H., & Gratt, B. M. (1994). Panoramic dental radiography as an aid in detecting patients at risk for stroke. *Journal of oral and maxillofacial surgery : official journal of the American Association of Oral and Maxillofacial Surgeons*, 52(12), 1257-1262.
- Gage, L. (1999). Radiographic techniques for the elephant foot and carpus. *Zoo and Wild Animal Medicine. Current Therapy 4th Ed.. FOWLER, ME.(Ed), WB Saunders Company, Philadelphia*, 517-520.
- Gallaher, B., Oliver, M., Eichhorn, K., Kessler, U., Kiess, W., Harding, J., et al. (1994). Circulating insulin-like growth factor II/mannose-6-phosphate receptor and insulin-like growth factor binding proteins in fetal sheep plasma are regulated by glucose and insulin. *European Journal of Endocrinology*, 131(4), 398-404.
- Gamagami, P. 1996. Indirect signs of breast cancer: Angiogenesis study, Atlas of Mammography, Blackwell Science, Cambridge, MA, pp. 231–258.
- Gilbert, R. D., Schroder, H., Kawamura, T., Dale, P. S., & Power, G. G. (1985). Heat transfer pathways between fetal lamb and ewe. *Journal of Applied Physiology*, 59(2), 634-638.

- Ginther, O. J. (1983). Mobility of the early equine conceptus. *Theriogenology*, 19(4), 603-611.
- Gluckman, P. D., & Harding, J. E. (1997). The Physiology and Pathophysiology of Intrauterine Growth Retardation. *Hormone Research in Paediatrics*, 48(Suppl. 1), 11-16.
- Gluckman, P. D., & Pinal, C. S. (2003). Regulation of Fetal Growth by the Somatotrophic Axis. *The Journal of Nutrition*, 133(5), 1741S-1746S.
- Godfrey, K., Robinson, S., Djf, B., Osmond, C., & Cox, V. (1996). Maternal nutrition in early and late pregnancy in relation to placental and fetal growth. *BMJ*, 312.
- Grzimek, B. 1975. Grzimek's Animal Life Encyclopedia. New York: Van Nostrand Reinhold Co.
- Gulyaev, Y. V., Markov, A. G., Koreneva, L. G., & Zakharov, P. V. (1995). Dynamical infrared thermography in humans. *Engineering in Medicine and Biology Magazine, IEEE*, 14(6), 766-771.
- Head, J. F., & Elliott, R. L. (2002). Infrared imaging: making progress in fulfilling its medical promise. *Engineering in Medicine and Biology Magazine, IEEE*, 21(6), 80-85.
- Head, J. F., Wang, F., Lipari, C. A., & Elliott, R. L. (2000). The important role of infrared imaging in breast cancer. *Engineering in Medicine and Biology Magazine, IEEE*, 19(3), 52-57.
- Hellstrom, A., Perruzzi, C., Ju, M., Engström, E., Hård, A.-L., Liu, J.-L., et al. (2001). Low IGF-I suppresses VEGF-survival signaling in retinal endothelial cells: Direct correlation with clinical retinopathy of prematurity. *Proceedings of the National Academy of Sciences*, 98(10), 5804-5808.
- Hilsberg, S. (1998). Infrared-thermography in zoo animals: new experiences with this method, its use in pregnancy and inflammation diagnosis and survey of environmental thermoregulation in zoo animals. Paper presented at the Proceedings of the 2nd scientific meeting of the European Association of Zoo and Wildlife Veterinarians.
- Hilsberg, S., Eulenberger, K., & Zahorszki, F. Application of infrared thermography in pregnancy diagnosis in giraffes. *Jahrestagung Physiologic und Pathologie der Fortpflanzung, Veterinar-Humanmed Gemeinschaftstagung, Universitat Leipzig Proceedings (February 14-15, 2002) W*, 2.
- Holtan, D. W., Squires, E. L., Lapin, D. R., & Ginther, O. J. (1979). Effect of ovariectomy on pregnancy in mares. *J Reprod Fertil Suppl*, 27, 457-463.

- Houck, R. 1993. Veterinary Care of Performing Elephants. In Zoo and Wild Animal Medicine: Current Therapy, 3d ed., edited by M.E. Fowler, pp. 147-148. Philadelphia: W.B. Saunders Company.
- Jiongran Chen, Murray R. Woodbury, Jane Alcorn, and Ali Honaramooz. 2012. Dietary Supplementation of Female Rats with Elk Velvet Antler Improves Physical and Neurological Development of Offspring. Evidence-Based Complementary and Alternative Medicine, vol (2012), Article ID 640680.
- Jones, B. F. (1998). A reappraisal of the use of infrared thermal image analysis in medicine. *Medical Imaging, IEEE Transactions on*, 17(6), 1019-1027.
- Jones, M., Denson, A., Williams, E., Graves, K., Dos, Santos A., Kouba, A., and Willard, S. 2005. Assessing pregnancy status using digital infrared thermal imaging in Holstein dairy heifers. *J. Anim. Sci.* 83(Suppl 1): 40.
- Kee, W. 1997. Thermography: There's more to it than meets the eye. *Electrical Construction and Maintenance*. 96: 33-40.
- Keyserlingk, J. R., Ahlgren, P. D., Yu, E., & Belliveau, B. (1998). Infrared imaging of breast: Initial reappraisal using high-resolution digital technology in 100 successive cases of stage I and II breast cancer. *The Breast Journal*, 4, 241-251.
- Kierdorf, U., & Kierdorf, H. (2002). Pedicle and first antler formation in deer: Anatomical, histological, and developmental aspects. *Zeitschrift für Jagdwissenschaft*, 48(1), 22-34.
- Klagsbrun, M., & D'Amore, P. A. (1991). Regulators of Angiogenesis. *Annual Review of Physiology*, 53(1), 217-239.
- Kolle, R., Kierdorf, U., & Fischer, K. (1993). Effects of an antiandrogen treatment on morphological characters and physiological functions of male fallow deer (*Dama dama* L.). *J Exp Zool*, 267(3), 288-298.
- Lahiri, B. B., Bagavathiappan, S., Jayakumar, T., & Philip, J. (2012). Medical applications of infrared thermography: A review. *Infrared Physics & Technology*, 55(4), 221-235.
- Lambert, R., Ashworth, C., Beattie, L., Gebbie, F., Hutchinson, J., Kyle, D., et al. (2001). Temporal changes in reproductive hormones and conceptus-endometrial interactions during embryonic diapause and reactivation of the blastocyst in European roe deer (*Capreolus capreolus*). *Reproduction*, 121(6), 863-871.
- Li C. and Wang W.Y. 1990. Review of studies on the effective compounds of velvet antler. *Chinese Special Wild Economic Animal and Plants Research* 4:19-22.

- Lopes, F. L., Desmarais, J. A., & Murphy, B. D. (2004). Embryonic diapause and its regulation. *Reproduction*, 128(6), 669-678.
- Loughin, C. A., & Marino, D. J. (2007). Evaluation of thermographic imaging of the limbs of healthy dogs. *American journal of veterinary research*, 68(10), 1064-1069.
- Loza, MJ. 2001. Sensitive issues for the deer industry. *Proceedings of a Deer Course for Veterinarians, No. 18, Deer Branch of the New Zealand Veterinary Association* : 73-78.
- Ma, L. and Tao, Y. 2005. An infrared and laser range imaging system for non-invasive estimation of internal temperatures in chicken breasts during cooking. *Transactions of the American Society of Agricultural Engineers*. 48: 681-690.
- Madura, H., Dąbrowski, M., Dulski, R., Żmuda, S., & Zaborowski, P. (2004). Thermographic method for evaluation of thermal influence of Nd:YAG laser on a tooth root during sterilization process. *Infrared Physics & Technology*, 46(1-2), 167-171.
- Magness, R. R., Phernetton, T. M., & Zheng, J. (1998). Systemic and uterine blood flow distribution during prolonged infusion of 17 $\beta$ -estradiol. *American Journal of Physiology - Heart and Circulatory Physiology*, 275(3), H731-H743.
- Mariappa, D. 1986. *Anatomy and Histology of the Indian Elephant*. Oak Park, Michigan: Indira Publishing House.
- McCafferty, D. J. (2007). The value of infrared thermography for research on mammals: previous applications and future directions. *Mammal Review*, 37(3), 207-223.
- McHugh, N., Elvins, D., & Ring, E. (1993). Elevated anticardiolipin antibodies in a patient with vibration-white-finger, valvular heart disease and psoriatic arthritis. *Clinical Rheumatology*, 12(1), 70-73.
- Meller, C. L., Croney, C. C., & Shepherdson, D. (2007). Effects of rubberized flooring on Asian elephant behavior in captivity. *Zoo Biol*, 26(1), 51-61.
- Morbach, S., Furchert, H., Gröbblinghoff, U., Hoffmeier, H., Kersten, K., Klauke, G.-T., et al. (2012). Long-Term Prognosis of Diabetic Foot Patients and Their Limbs. *Diabetes Care*, 35(10), 2021-2027.
- Morel, P. C. H., Blair, H. T., Ormsby, J. E., Breier, B. H., McCutcheon, S. N., & Gluckman, P. D. (1994). Influence of fetal and maternal genotype for circulating insulin-like growth factor I on fetal growth in mice. *Journal of Reproduction and Fertility*, 101(1), 9-14.

- Munsell, B. 2004. The use of infrared thermography to determine surface temperature for the coronary band of dairy cows as a tool for lameness detection. Thesis, Doctorate of Philosophy, Michigan State University.
- Nikkah, A., J.C. Plaizier, M.S. Einarson, R.J. Berry, S.L. Scott, A.D. Kennedy. 2005. Short communication: Infrared thermography and visual examination of hooves of dairy cows in two stages of lactation. *Journal of Dairy Science*, 88; 2749–2753
- Owens, J. (1991). Endocrine and substrate control of fetal growth: placental and maternal influences and insulin-like growth factors. *Reproduction, Fertility and Development*, 3(5), 501-517.
- Owens, J. A., Falconer, J., & Robinson, J. S. (1989). Glucose metabolism in pregnant sheep when placental growth is restricted. *American Journal of Physiology - Regulatory, Integrative and Comparative Physiology*, 257(2), R350-R357.
- Paterson, W., Sparling, C. E., Thompson, D., Pomeroy, P. P., Currie, J. I., & McCafferty, D. J. (2012). Seals like it hot: Changes in surface temperature of harbour seals (*Phoca vitulina*) from late pregnancy to moult. *Journal of Thermal Biology*, 37(6), 454-461.
- Phillips, P. K., & Heath, J. E. (2004). Comparison of surface temperature in 13-lined ground squirrel (*Spermophilus tridecemlineatus*) and yellow-bellied marmot (*Marmota flaviventris*) during arousal from hibernation. *Comparative Biochemistry and Physiology Part A: Molecular & Integrative Physiology*, 138(4), 451-457.
- Pitman, C. R. S. (1971). A Field Guide to the Birds of Southern Africa, by O. P. M. Prozesky. Collins, £2.50 A Field Guide to the Snakes of Southern Africa, by V. F. M. FitzSimons. Collins, £2.10. *Oryx*, 11(01), 69-75.
- Power, G. G. (1989). Biology of temperature: The mammalian fetus. *Journal of Developmental Physiology*, 12(6), 295-304.
- Power, G. G., Schroder, H., & Gilbert, R. D. (1984). Measurement of fetal heat production using differential calorimetry. *Journal of Applied Physiology*, 57(3), 917-922.
- Prokoski, F. J., Riedel, R. B., & Coffin, J. S. 1992. *Identification of individuals by means of facial thermography*. Paper presented at the Security Technology, 1992. Crime Countermeasures, Proceedings. Institute of Electrical and Electronics Engineers 1992 International Carnahan Conference.
- Purohit RC, Bergfeld WA, McCoy MD, Thompson WM, Sharman RS. Value of clinical thermography in veterinary medicine. *Auburn Veterinarian* 1977;104-108.

- Purohit, R. C., & McCoy, M. D. (1980a). Thermography in the diagnosis of inflammatory processes in the horse. *Am J Vet Res*, 41(8), 1167-1174.
- Purohit, R. C., & McCoy, M. D. (1980b). Thermography in the diagnosis of inflammatory processes in the horse. *American journal of veterinary research*, 41(8), 1167-1174.
- Purohit, R. C., Hudson, R. S., Riddell, M. G., Carson, R. L., Wolfe, D. F., & Walker, D. F. (1985). Thermography of the bovine scrotum. *American journal of veterinary research*, 46(11), 2388-2392.
- Rainwater-Lovett, K., Pacheco, J. M., Packer, C., & Rodriguez, L. L. (2009). Detection of foot-and-mouth disease virus infected cattle using infrared thermography. *The Veterinary Journal*, 180(3), 317-324.
- Renfree, M. (2000). Maternal recognition of pregnancy in marsupials. *Reviews of Reproduction*, 5(1), 6-11.
- Reynolds, L. P., & Ferrell, C. L. (1987). Transplacental clearance and blood flows of bovine gravid uterus at several stages of gestation. *American Journal of Physiology - Regulatory, Integrative and Comparative Physiology*, 253(5), R735-R739.
- Reynolds, L. P., & Redmer, D. A. (1995). Utero-placental vascular development and placental function. *Journal of Animal Science*, 73(6), 1839-1851.
- Reynolds, L. P., & Redmer, D. A. (2001). Angiogenesis in the Placenta. *Biology of Reproduction*, 64(4), 1033-1040.
- Reynolds, L. P., Ferrell, C. L., Robertson, D. A., & Ford, S. P. (1986). Metabolism of the gravid uterus, foetus and utero-placenta at several stages of gestation in cows. *The Journal of Agricultural Science*, 106(03), 437-444.
- Reynolds, L. P., Killilea, S. D., & Redmer, D. A. (1992). Angiogenesis in the female reproductive system. *The FASEB Journal*, 6(3), 886-892.
- Ring, E. F., & Ammer, K. (2012). Infrared thermal imaging in medicine. *Physiological measurement*, 33(3), R33-46.
- Roocroft A. and J. Oosterhuis. (2001). Chapter 5: Foot Care for Captive Elephants. In *The Elephant's Foot*, (pp21-52). Iowa:Iowa State University Press.
- Ruminski, J., Kaczmarek, M., Renkielska, A., & Nowakowski, A. (2007). Thermal Parametric Imaging in the Evaluation of Skin Burn Depth. *Biomedical Engineering, IEEE Transactions on*, 54(2), 303-312.

- Schaefer, A. L., Jones, S. D. M., Murray, A. C., Sather, A. P., & Tong, A. K. W. (1989). Infrared thermography of pigs with known genotypes for stress susceptibility in relation to pork quality. *Canadian journal of animal science.*, 69(2), 491-495.
- Schaefer, A. L., Jones, S. D. M., Tong, A. K. W., & Vincent, B. C. (1988). The effects of fasting and transportation on beef cattle. 1. Acid-base-electrolyte balance and infrared heat loss of beef cattle. *Livestock Production Science*, 20(1), 15-24.
- Schaefer, A.L., Suttie, J.M., Lawrence, R.A., Desroches, G.B., and Lepage P. 2005. Method for the evaluation of velvet antler. U.S. Pat. No. 2,375,870.
- Schmitt M. and Guillot Y. 1984. Thermography and muscle injuries in sports medicine. Recent advances in medical thermography. ed. E.F.J. Ring and J. Philips (London:Plenum) pp 439-45.
- Schroder, H., & Power, G. (1997). Engine and radiator: fetal and placental interactions for heat dissipation. *Experimental Physiology*, 82(2), 403-414.
- Schroder, H., Gilbert, R. D., & Power, G. G. (1988). Computer model of fetal-maternal heat exchange in sheep. *Journal of Applied Physiology*, 65(1), 460-468.
- Schwartzkopf-Genswein, K. S., & Stookey, J. M. (1997). The use of infrared thermography to assess inflammation associated with hot-iron and freeze branding in cattle. *Canadian Journal of Animal Science*, 77(4), 577-583.
- Sendur, I. K., & Baertlein, B. A. (2000). Numerical simulation of thermal signatures of buried mines over a diurnal cycle. 156-167.
- Siegal-Willott, J., Isaza, R., Johnson, R., & Blaik, M. (2008). Distal Limb Radiography, Ossification, and Growth Plate Closure in the Juvenile Asian Elephant (*Elephas maximus*). *Journal of Zoo and Wildlife Medicine*, 39(3), 320-334.
- Smuts, M. M., & Bezuidenhout, A. J. (1994). Osteology of the pelvic limb of the African elephant (*Loxodonta africana*). *Onderstepoort J Vet Res*, 61(1), 51-66.
- Still, J. M., Law, E. J., Klavuhn, K. G., Island, T. C., & Holtz, J. Z. (2001). Diagnosis of burn depth using laser-induced indocyanine green fluorescence: a preliminary clinical trial. *Burns*, 27(4), 364-371.
- Stokes, J. E., Leach, K. A., Main, D. C. J., & Whay, H. R. (2012). An investigation into the use of infrared thermography (IRT) as a rapid diagnostic tool for foot lesions in dairy cattle. *The Veterinary Journal*, 193(3), 674-678.
- Stout, T., & Allen, W. (2002). Prostaglandin E(2) and F(2 alpha) production by equine conceptuses and concentrations in conceptus fluids and uterine flushings recovered from early pregnant and dioestrous mares. *Reproduction*, 123(2), 261-268.



- Stromberg, B. (1974). Morphologic, Thermographic and  $^{133}\text{Xe}$  Clearance Studies on Normal and Diseased Superficial Digital Flexor Tendons in Race Horses. *Equine Veterinary Journal*, 5(4), 156-161
- Suttie, J. M., Fennessy, P. F., Corson, I. D., Laas, F. J., Crosbie, S. F., Butler, J. H., et al. (1989). Pulsatile growth hormone, insulin-like growth factors and antler development in red deer (*Cervus elaphus scoticus*) stags. *Journal of Endocrinology*, 121(2), 351-360.
- Suttie, J. M., White, R. G., Breier, B. H., & Gluckman, P. D. (1991). Photoperiod Associated Changes in Insulin-Like Growth Factor-I in Reindeer. *Endocrinology*, 129(2), 679-682.
- Turner, T. A. (1991). Thermography as an aid to the clinical lameness evaluation. *The Veterinary clinics of North America. Equine practice*, 7(2), 311-338.
- Turner, T. A., Fessler, J. F., Lamp, M., Pearce, J. A., & Geddes, L. A. (1983). Thermographic evaluation of horses with podotrochlosis. *Am J Vet Res*, 44(4), 535-539.
- Turner, T. A., Purohit, R. C., & Fessler, J. F. (1986). Thermography: A review in equine medicine. *Comp. Cont. Educ. Pract. Vet.*, 8(11), 855-861.
- Van Hoogmoed, L., Snyder, J. R., Allen, A. K., & Waldsmith, J. D. (2000). Use of infrared thermography to detect performance enhancing techniques in horses. *Equine Veterinary Education*, 12(2), 102-107.
- Van Niekerk, C. H., & Allen, W. R. (1975). Early embryonic development in the horse. *J Reprod Fertil Suppl*, 23, 495-498.
- Wallis, T. 1993. History and evolution of deer farming and the early velvet industry in New Zealand. Pages 21-24 in I. Woodhouse, ed. A Salute to World Deer Farming-Proceedings of the First World Deer Congress. New Zealand Deer Farmers Association, Christchurch.
- Warashina, H., Hasegawa, Y., Tsuchiya, H., Kitamura, S., Yamauchi, K. I., Torii, Y., et al. *Clinical, radiographic, and thermographic assessment of osteoarthritis in the knee joints*: Ann Rheum Dis. 2002 Sep;61(9):852-4.
- Watson, A. C., & Vasilescu, C. (1972). Thermography in plastic surgery. *J R Coll Surg Edinb*, 17(4), 247-252.
- Webster, J. R., Suttie, J. M., & Corson, I. D. (1991). Effects of melatonin implants on reproductive seasonality of male red deer (*Cervus elaphus*). *Journal of Reproduction and Fertility*, 92(1), 1-11.

- Weissenböck, N. M., Weiss, C. M., Schwammer, H. M., & Kratochvil, H. (2010). Thermal windows on the body surface of African elephants (*Loxodonta africana*) studied by infrared thermography. *Journal of Thermal Biology*, 35(4), 182-188.
- Weissengruber, G. E., & Forstenpointner, G. (2004). Musculature of the crus and pes of the African elephant (*Loxodonta africana*): insight into semiplantigrade limb architecture. *Anatomy and Embryology*, 208(6), 451-461.
- Weissengruber, G. E., Egger, G. F., Hutchinson, J. R., Groenewald, H. B., Elsässer, L., Famini, D., et al. (2006). The structure of the cushions in the feet of African elephants (*Loxodonta africana*). *Journal of Anatomy*, 209(6), 781-792.
- Williams, T. (1990). Heat transfer in elephants: thermal partitioning based on skin temperature profiles. *J. Zool., Lond.* 222, 235-245.
- Wilson, P. R., & Stafford, K. J. (2002). Welfare of farmed deer in New Zealand. 2. Velvet antler removal. *New Zealand Veterinary Journal*, 50(6), 221-227.
- Winsor, T. (1971). Vascular aspects of thermography. *Journal of Cardiovascular Surgery*, 12(5), 379-388.
- Woodle, K., T. Kepes and C. Doyle. (2001). Chapter 18: Making a Protective Boot for an Asian Elephant. In *The Elephant's Foot*, (pp 103-105). Iowa: Iowa State University Press.
- Wright, P.G. (1984). Why do elephants flap their ears? *S. Afr. J. Zool.*, 19:266–269
- Wu, D., & Busse, G. (1998). Lock-in thermography for nondestructive evaluation of materials. *Revue Générale de Thermique*, 37(8), 693-703.
- Xie, W., McCahon, P., Jakobsen, K., & Parish, C. (2004). Evaluation of the ability of digital infrared imaging to detect vascular changes in experimental animal tumours. *International Journal of Cancer*, 108(5), 790-794.
- Zha, E., Gao, S., Pi, Y., Li, X., Wang, Y., & Yue, X. (2012). Wound healing by a 3.2 kDa recombinant polypeptide from velvet antler of *Cervus nippon* Temminck. *Biotechnology Letters*, 34(4), 789-793.
- Zhang P. (1982). China. Pages 11-14 in D. Yerex, ed. *The Farming of Deer: World Trends and Modern Techniques* Agricultural Promotion Associates Ltd, Wellington.

# CHAPTER III

## ASSESSMENT OF PREGNANCY IN THE LATE GESTATION MARE USING DIGITAL INFRARED THERMOGRAPHY

### **Introduction**

Digital infrared thermal imaging (DITI) is a non-invasive diagnostic technique that is used to detect symmetry and asymmetry of surface temperature gradients. The temperature of the skin is about 5°C cooler than the body core since heat is often dissipated through the skin by evaporation and other means (Adams et al, 1980) to balance internal and external temperature. Therefore, thermal imaging is the most efficient and noninvasive technique for the study of temperature distribution by measuring bi-lateral anatomical sites and identifying significant changes among thermal images (Medical Monitoring Systems, 1999). The surface of the skin is a highly efficient radiator and it is possible to detect infrared emissions from the skin and create a thermal map of temperature distribution by non invasive methods (Purohit et al, 1985). Variations in skin temperature result from changes in tissue perfusion and blood flow (Winsor, 1971), and since there is a high degree of thermal symmetry in the normal body subtle abnormal temperature asymmetry can be easily identified and may relate to underlying abnormalities or changes in physiology (Purohit et al, 1985).

In livestock, DITI has been applied in the diagnosis of foot and leg problems in cattle and horses (Purohit 1980; Turner 1998; Cockcroft et al. 2000; Schmidt et al. 2003),

for assessing fertility in bulls and rams (Purohit et al. 1985; Kastelic et al. 1995 and 1996; Gabor et al. 1998; and Coulter et al. 1988), for characterizing the responses of cattle to hot-iron and freeze branding (White et al. 2006 ), monitoring heat load in dairy cattle (Schwartzkopf-Genswein 1997) and for evaluating thermal comfort in poultry (Bottcher et al, 1992). Moreover, the use of DITI in domestic livestock has led to new approaches to study wildlife or other captive exotic species that can not be handled (McCafferty, 2007). In 2002, groups at the Frankfurt and Leipzig Zoological Gardens used thermography to detect late gestation in a single giraffe (Hilsberg et al, 2002). However they stated that additional research is required to define the working conditions, constraints and limitations of using thermography in pregnancy detection (Hilsberg et al, 2002). Earlier work by this same group detected heat signatures in the abdomen of a gravid black rhinoceros and Grevy zebra, and these heat signatures were not present in non-pregnant animals of the same species (Hilsberg et al, 1997). Recently thermography has also been used to detect pregnancy in the giant panda, however this study also had a limited number of animals, using only two giant pandas (Durrant et al, 2006). In addition, thermal imaging of the control animals (domestic bitch) was less informative and did not definitively diagnose pregnancy (Durrant et al, 2006). Finally, the use of thermography to detect pregnancy in dairy heifers has also been investigated but did not result in discrimination between pregnant and non pregnant animals (Jones et al, 2005).

The objective of this study was to investigate the use of digital infrared thermal imaging to determine whether differences in temperature gradients exist between late gestation and non-pregnant mares. The results of this study were intended to help

develop a model to evaluate DITI for detecting pregnancy in wildlife and exotic captive species.

## **Materials and methods**

### **Animals**

Data collection began in March and continued through May with 24-h ambient temperatures ranging from 4.2°C to 28.9°C. All animals were housed at the Leveck Animal Research Center (Equine Unit), Mississippi State University (MSU) on rye grass pastures and fed 1.4 kg of a commercial 10% protein sweet feed (All-stock Sweet 10, Country Acres Feed Co, Brentwood, MO, USA) once daily. The mares were vaccinated against rhinopneumonitis at 5, 7 and 9 months of gestation. On each day of data collection (imaging), pregnant mares ( $n = 10$ ; beginning at  $292.4 \pm 1.4$  d of gestation) and nonpregnant mares ( $n = 17$ ) were brought into an enclosed barn and debris was removed from the coat. The mares were then normalized to environmental temperatures in the covered barn for at least 30 min prior to imaging. On each collection day pregnant mares and non-pregnant mares were paired so that a non-pregnant mare was imaged first, between pregnant mares, and last. In addition, the mares were also matched according to three levels of coat color; light (palomino, gray), medium (chestnut, sorrel) and dark (black, bay). The same focal distance was maintained for each data collection with the camera distance ranging from 147.3 to 157.5 cm from the mare. Ambient temperature, DITI measurements: including left and right abdomen/flank and wither temperature (used as a skin control site; Figure 1) of the horse, background temperature (wall inside the barn behind where the mares were imaged), and rectal temperatures were obtained weekly for 5 wk prior to predicted parturition date and for 3 wk after parturition. The

total number of images of the abdomen/flank for the right and left side combined were as follows: pregnant mares (74 images), non-pregnant mares (130 images) and foaled mares (70 images). Thermal images were acquired using a Meditherm vet2000 (Compix Inc. Tualatin, OR, USA) with emissivity set at 1 and analyzed using the Wintes Software. Temperature (°C) was quantified using the maximum temperature of the abdomen/flank and wither.

This study was reviewed and approved by the MSU Institutional Animal Care and Use Committee and followed the General Guidelines for Animal Husbandry as described in the Guide For the Care and Use of Agricultural Animals in Agricultural Research and Teaching (FASS, Savoy, IL, USA).

### **Statistical analysis**

Statistical analysis was performed using ANOVA (factorial and repeated measures where appropriate) to ascertain physiological status (pregnant vs. non-pregnant vs. foaled), time (weeks) and respective interactions. Where interactions were not apparent in relation to time, factorial ANOVA and mean separation among weeks and temperature were used to address significant trends in the data. For mean separation of study parameters, the Student's t test was employed and data expressed throughout as the mean  $\pm$  SEM. Pearsons correlations with Fishers r to z transformations were used to determine the relationship among flank, wither, ambient and background temperatures.

## **Results**

### **Thermography and environmental conditions for pregnancy assessment**

Thermal imaging was conducted for three months (March through May) with the ambient temperature ranging from 4.2°C to 28.9°C. Background temperature was positively correlated with flank and wither temperature ( $R=0.48$ ,  $R=0.58$ , respectively;  $P<0.01$ ) regardless of group (pregnant, non-pregnant, foaled) and was positively correlated with ambient temperature ( $R=0.92$ ;  $P<0.01$ ; Table 1). Flank temperature and wither temperature were positively correlated with one another ( $R=0.72$ ;  $P<0.01$ ) and were positively correlated with ambient temperature ( $R=0.48$  and  $0.64$ , respectively;  $P<0.01$ ; Table 1) in all groups. Rectal temperature was not significantly correlated ( $P > 0.10$ ) with any of the environmental measurements or with any of the thermal image measurements (flank, wither). Moreover, there were no differences ( $P > 0.10$ ) in rectal temperature ( $37.73 \pm 0.12^{\circ}\text{C}$ ) between the pregnant, non-pregnant or foaled mares.

### **Using thermography to detect thermal signatures in the nonpregnant versus pregnant mare before and after foaling**

There were no differences ( $P > 0.10$ ) in temperature of the left and right flank or coat color within group (pregnant and non-pregnant), therefore data were pooled within group for further analysis. The pregnant mares had higher ( $P < 0.05$ ) average flank temperatures than the nonpregnant and foaled mares ( $36.0 \pm 0.2^{\circ}\text{C}$  vs.  $34.2 \pm 0.2^{\circ}\text{C}$  vs.  $34.29 \pm .92^{\circ}\text{C}$ , respectively). Moreover, the difference in flank temperature between the pregnant and non-pregnant mares was greater ( $P < 0.05$ ; Figure 2) when the ambient temperature was below  $19^{\circ}\text{C}$  ( $3.09 \pm 0.58^{\circ}\text{C}$  difference) than when the ambient temperature was above  $20^{\circ}\text{C}$  ( $1.81 \pm 0.59^{\circ}\text{C}$  difference). In addition, the thermal images

demonstrated a more asymmetrical color pattern for the pregnant mares versus the open mares (Figure 3). As stated above, flank temperature and wither temperature were positively correlated with one another ( $R=0.72$ ;  $P<0.01$ ), however, wither temperature did not differ ( $P > 0.10$ ) between the pregnant and non-pregnant mares. When evaluating the flank temperature of the pregnant mares before and after they foaled the same pattern was noted, with a greater difference occurring when the ambient temperature was below  $19^{\circ}\text{C}$  ( $1.63 \pm$  difference) than when the ambient temperature was above  $20^{\circ}\text{C}$  ( $1.05 \pm$  difference; Figure 2).

### **Discussion**

The horse is a suitable model for the study of thermography and pregnancy detection in a number of exotic herbivores. The horse is morphologically similar to large exotic herbivores, such as the giraffe and zebra, and the depth and location of the reproductive tract is also comparable.

In this study thermographic imaging was able to detect pregnancy in the horse during late gestation. The difference in temperature between pregnant and nonpregnant animals is most likely due to the proliferation of tissues, metabolic and/or hormonal interactions, protein synthesis or other associations with pregnancy that relate to the placenta and the fetus itself. The proliferation of these tissues involves angiogenesis which in turn produces heat (Adams et al, 1980). The metabolic rate of the fetus in regard to tissue weight is high when compared to that of an adult. In a previous study heat production by fetal lambs were found to be approximately twice that of an adult, per unit of body weight (Gilbert et al, 1985). In addition, heat is transferred to the fetus via the placenta and the uterus, resulting in a  $0.3^{\circ}\text{C}$  to  $0.5^{\circ}\text{C}$  higher temperature than that of the



mother (Power, 1989). A recent study using thermography to detect pregnancy in the giant panda reported that heat signatures were present which were indicative of an overall perfusion of blood to both uterine horns. As the pregnancy continued heat structures were observed in the area over the uterine horns. Ultrasonography was used to confirm the pregnancy and two live fetuses were present at the exact location of the heat signatures (Durrant et al, 2006). The pregnant mares on average had a 1.8°C higher abdomen/flank temperature than the nonpregnant mares with the highest difference reaching 3.09°C when the ambient temperature was lower than 19°C. Hilsberg and others (1997) reported a 1.7°C difference between a pregnant and non-pregnant black rhinoceros and an even greater difference (4°C) between the pregnant and nonpregnant Grevy's zebra. However other studies have shown that thermography does not always definitively diagnose pregnancy (Hilsberg et al, 1997 and 2002). These discrepancies in diagnosis could be related to the environment or interference in thermal conductance by areas of fat, hair or fur, reduced blood flow or other internal structures (Purohit et al, 1977).

It is apparent that environmental conditions such as temperature and air flow can have an impact on the reliability of thermal images when conducted in an uncontrolled environment which is usually the case in the captive management of livestock and wildlife. It has been suggested that the ideal temperature for imaging is in the range of 20°C (Love and Linsted, 1976) but a temperature below 30°C is acceptable (Turner et al, 1986) since heat loss from sweating does not occur below this temperature (William, 1964); although this may vary by species and/or other aspects of the environmental conditions. In this study the ambient temperature did not reach above 28.9°C while

images were taken, which is in the acceptable range. In addition, a greater difference between the pregnant and nonpregnant mares occurred at temperatures below 20°C which has been stated to be more of the ideal temperature. A study conducted by Jones and others (Jones et al, 2005) investigated the use of DITI to assess pregnancy status in Holstein heifers. The average ambient temperature was 17.7°C during the study but a difference in pregnant and nonpregnant heifers only occurred when the ambient temperature was below 10°C. This could lead to speculation that the ideal temperature needs to be lower to obtain more accurate images, at least for some species, and for pregnancy detection within diverse management environments. Additional obstacles for obtaining accurate thermal images also relate to the animals phenotypic or morphological differences such as length or pattern of hair coat (Delahanty and Georgi, 1965), disease state (Schaefer et al, 2007) and location of internal structures. In the study mentioned above by Jones and others (2005) it was noted that there was variability in DITI among sides (left and right) in the Holstein heifers. The left side images of the heifers were highly variable and were not as highly correlated as the right side to pregnancy. This could be explained by the location of the rumen in the cow on the left side, although this is just speculation, and apparent problems associated with imaging in this study were also noted related to coat patterns (black/white patterns) of the Holstein heifers (Jones et al, 2005). In domestic bitches which were used as model animals in the investigation of infrared thermography to visualize pregnancy in the giant panda (Durrant et al, 2006), DITI proved to be inconclusive in determining pregnancy in the domestic bitch with heat signatures corresponding to the mammary glands; or in some cases lack thereof. This could be due to the fat content of the mammary gland, metabolic heat in this region, or

individual differences among the females. However some patterns were noted in certain pregnant females which led the researchers to indicate a need for further analysis (Durrant et al, 2006).

Further analysis is also warranted with the current study. This study only used late gestation mares in which the fetus and the surrounding membranes/tissues were fully formed and had ample blood supply. To obtain an accurate indication of how useful thermography is in detecting pregnancy the entire gestation of the horse or other species used as a model needs to be taken at various stages of pregnancy in conjunction with non-pregnant animals. As stated previously, the environment plays a large role in the reliability of thermal images and artifacts may yield false positive, or negative, results if not properly controlled. More intense work comparing a controlled environment vs. a management environment could lead to a better understanding of the challenges needed to be overcome to enable more routine use of DITI in the large animal management environment which rarely can be controlled completely. In addition, since the completion of this study thermal imaging technologies (sensitivity, range, etc.) has advanced and the increased sensitivity may increase the effectiveness of DITI for these applications. Thus, additional research is still needed to fully explore the limits of thermal imaging in regards to pregnancy confirmation or detection in livestock, wildlife and captive species.

### **Acknowledgements**

This study was funded by USDA/ARS through the Biophotonics Initiative (#58-6402-3-0120) and the Mississippi Agricultural and Forestry Experiment Station. The authors thank Donny Ray and Gavin Olsen for technical assistance and study support.

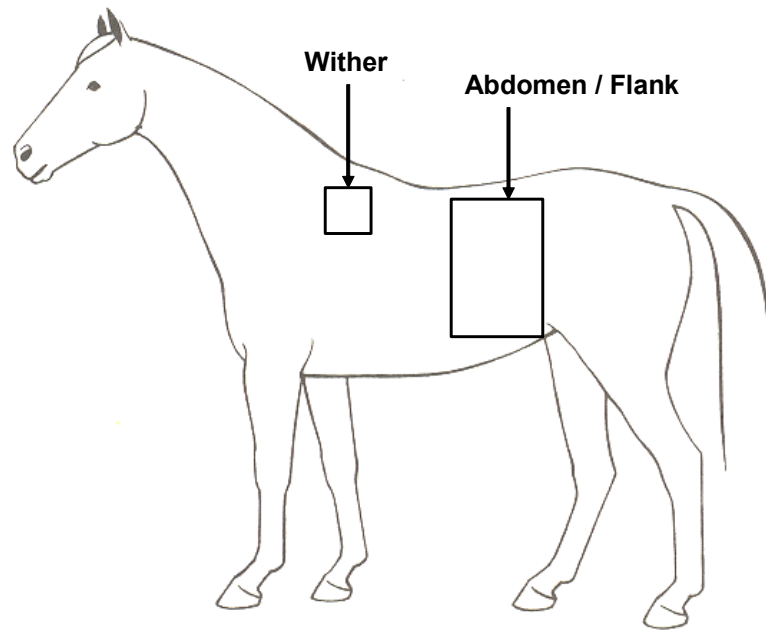


Figure 1 DITI measurements including left and right abdomen / flank and wither temperature were obtained weekly for 5 wk prior to predicted parturition date and for 3 wk after parturition

Table 1 Correlation coefficients between ambient, background (non-animal), rectal, abdomen/flank and wither thermal measurements in pregnant, non-pregnant and foaled mares.

<u>Pregnant mares</u>				
	Ambient	Rectal	Flank	Wither
Background	.966*	.202	.478*	.509*
Wither	.612*	.240	.737*	
Flank	.555*	.197		
Rectal	.301			
<u>Non-pregnant mares</u>				
	Ambient	Rectal	Flank	Wither
Background	.917*	.084	.542*	.551*
Wither	.594*	.176	.869*	
Flank	.552*	.154		
Rectal	.229			
<u>Foaled mares</u>				
	Ambient	Rectal	Flank	Wither
Background	.922*	.140	.604*	.762*
Wither	.778*	.176	.520*	
Flank	.483*	.152		
Rectal	.164			

\* Environmental temperatures (background and ambient) were positively correlated ( $P < 0.05$ \*) with each other and with thermal images of the mare's flank and wither regardless of group.

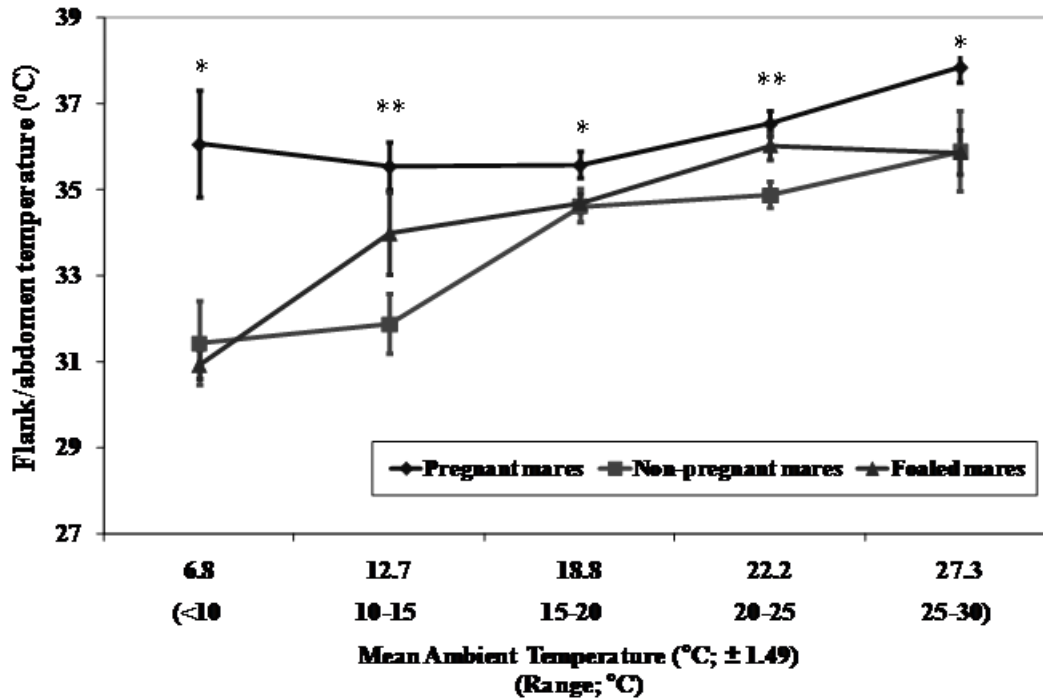


Figure 2 Thermal signatures as determined by digital infrared thermal imaging in pregnant and non-pregnant mares

The pregnant mares had higher ( $P < 0.05$ ) average flank temperatures than the non-pregnant and foaled mares. The overall mean ( $\pm$  SE) flank temperatures for the pregnant, non-pregnant and foaled mares were  $36.32 \pm 0.42^{\circ}\text{C}$ ,  $33.74 \pm 0.88^{\circ}\text{C}$ , and  $34.29 \pm 0.92^{\circ}\text{C}$ , respectively.

\*Pregnant mares had significantly ( $P < 0.05$ ) higher flank/abdomen temperatures than the non-pregnant and foaled mares. \*\*Pregnant mares had significantly ( $P < 0.05$ ) higher flank/abdomen temperatures than the non-pregnant mares only

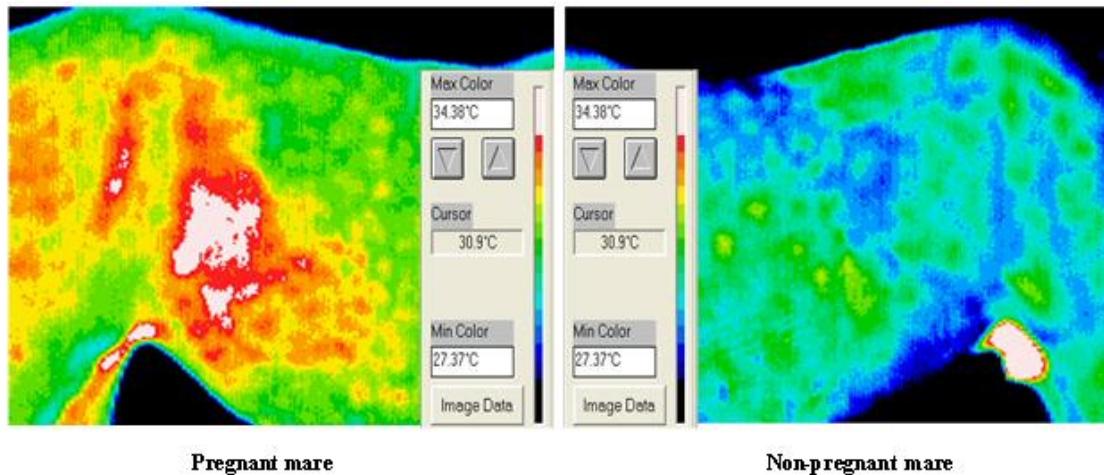


Figure 3 Thermal images of a pregnant and non-pregnant mare acquired with the Meditherm Vet2000.

The pregnant mare has a higher flank/abdomen temperature than the non-pregnant mare. These higher temperatures are shown in white and multiple shades of red on the pregnant mare's flank. In addition, the pregnant mare has a more asymmetrical pattern than the non-pregnant mare. As a note, the heat signature inside the leg of both mares is emitted from the medial saphenous vein.

## References

- Adams T, Heisey SR, Smith MC, Steinmetz MA, Hartman JC, Fry HK. Thermodynamic techniques for the quantification of regional blood flow. *Am J Physiol* 1980;238:682-696.
- Medical Monitoring Systems, Pty Ltd. Operating instructions for the vet2000 and manual of equine thermography. Meditherm, Beaufort NC 1999.
- Purohit RC, Hudson RS, Riddell MG, RL Carson, DF Wolfe, DF Walker. Thermography of the bovine scrotum. *Am J Vet Res* 1985;46:2388-2392.
- Winsor T. Vascular aspects of thermography. *J Cardiovasc Surg* 1971;12:379-388.
- Purohit RC. The diagnostic value of thermography in equine medicine. Proceedings from the Annual Convention of the American Association of Equine Practitioners. 1980;26:317-326.
- Turner AT. Thermography as an aid in the localization of upper hind limb lameness. *Equine Athletics* 1998;11:38-42.
- Cockcroft PD, Henson FD, Parker C. Thermography of a septic metatarsophalangeal joint in a heifer. *Vet Res* 2000;146:258-260.
- Schmidt S, Bowers S, Graves K, Carroll R, White J, Willard S. Use of infrared thermography to assess thermal temperature gradients and pathologies of the bovine claw. *J Anim Sci* 2003;81(Suppl 1):323.
- Kastelic JP, Coulter GH, Cook RB. Scrotal surface, subcutaneous, intratesticular and intraepididymal temperatures in bulls. *Theriogenology* 1995;44:147-152.
- Kastelic JP, Cook RB, Coulter GH, Saake RG. Ejaculation increases scrotal surface temperature in bulls with intact epididymides. *Theriogenology* 1996;46: 889-892.
- Gabor GR, Sasser G, Kastelic JP, Coulter GH, Everson DO, Falkay G, Mezes M, Bozo S, Cook RB, Csik JV. Endocrine and thermal responded to GnRH treatment and prediction of sperm output and viability in Holstein-Friesian breeding bulls. *Theriogenology* 1998;50:177-183.
- Coulter GH, Senger PL, Bailey DC. Relationship of scrotal surface temperature measured by infrared thermography of subcutaneous testicular temperature in the ram. *J Reprod Fertil* 1988;84:417-423.
- Schwartzkopf-Genswein KS, Stookey JM. The use of infrared thermography to assess inflammation associated with hot-iron and freeze branding in cattle. *Can J Anim Sci* 1997; 77:577-583.



- White MB, Jones M, Schmidt S, Willard S. Use of digital infrared thermal imaging (DITI) for monitoring environmental physiology in dairy cattle. *J Anim Sci* 2006;84(Suppl 1):212.
- Bottcher RW, Pardue SL, Brake JT, Jacobsen BM, Driggers LB, Baughman GR. Thermography for evaluating thermal comfort in poultry. *Am Soc Ag Eng* 1992;10:92-4539.
- McCafferty DJ. The value of infrared thermography for research on mammals: pervious applications and future directions. *Mammal Rev.* 2007;37:207-223.
- Hilsberg S, Eulenberger K, Zahorszki F. Application of infrared thermography in pregnancy diagnosis in giraffes. *Leipzig* 2002:14-15.
- Hilsberg S, Goltenboth R, Eulenberger K. Infrared thermography of zoo animals, first experience in its use for pregnancy diagnosis. *Verh Ber Erkr Zootiere* 1997;38:187-190.
- Durrant BS, Ravidia N, Spady T, Cheng A. New technologies for the study of carnivore reproduction. *Theriogenology* 2006;66:1729-1736.
- Jones M, Denson A, Williams E, Graves K, Dos Santos A, Kouba A, Willard S. Assessing pregnancy status using digital infrared thermal imaging in Holstein dairy heifers. *J Anim Sci* 2005;83(Suppl. 1):40.
- Gilbert RD, Schroder H, Kawamura T, Dale PS, Power GG. Heat transfer pathways between fetal lamb and ewe. *J Appl Physiol* 1985;59:634-638.
- Power GG. Biology of temperature: the mammalian fetus. *J Dev Physiol* 1989;12:295-304.
- Purohit RC, Bergfeld WA, McCoy MD, Thompson WM, Sharman RS. Value of clinical thermography in veterinary medicine. *Auburn Veterinarian* 1977;104-108.
- Love TJ, Linsted RD. Theoretical basis for use of skin temperature as a plethysmographic indicator. *Am Soc Mech Eng 75-WA/Bio* 1976;6:1-4.
- Turner TA, Purohit RC, Fessler JF. Thermography: A review in Equine Medicine. *Compendium on Continuing Education for the Practicing Veterinarian* 1986;8:855-861.
- William KL. Infrared thermometry as a tool in medical research. *Ann NY Acad Sci* 1964;121:99-112.
- Delahanty DD, Georgi JR. Thermography in equine medicine. *JAVMA* 1965;147:235-238.

Schaefer AL, Cook NJ, Church JS, Basarb J, Perry B, Miller C, Tong AKW. The use of infrared thermography as an early indicator of bovine respiratory disease complex in calves. *Res Vet Sci.* 2007;83:376-384.

CHAPTER IV

EVALUATING VELVET ANTLER GROWTH IN RED DEER STAGS (*CERVUS*  
*ELEPHUS*) USING HAND HELD AND DIGITAL  
INFRARED THERMOGRAPHY

**Introduction**

The harvesting of velvet antler (VA) from farmed red deer stags is a renewable resource of economic significance to the deer farming industry. Velvet antler removal has been an accepted deer farming practice in China for centuries (Zhang 1982). Deer farming became a lucrative industry in the western world more than 30 years ago, and the harvesting of VA soon became a driver of industry growth (Wallis 1993). Velvet antler removal is the surgical amputation of living, vascular and innervated tissue (Wilson et al. 2001). It is usually performed on young stags prior to harvest, or older stags farmed specifically for this purpose or while maintained as breeding sires (Wilson and Stafford 2002). Velvet antler is usually harvested based on tissue, age, morphology, conformation and/or size of the antler, which is not always the time of peak growth. Velvet weights have moderately high heritability (Moore et al. 1988) and are a major factor in the deer farming industry when determining selection of stags for VA farming. However, as the stags mature, variation in velvet weight is increased (van den Berg and Garrick 1997). Grading systems, for different species of deer and countries, have been developed and categorize VA on the basis of size, shape, degree of mineralization, blood content, color

and damage (as described by Haigh and Hudson 1993, American Elk Products Board). However, methods for objectively evaluating optimal VA harvest time and pre-harvest quality are lacking. Since VA is a highly proliferative tissue, it has been suggested that thermal signatures obtained through the use of thermal sensing technologies may be used as a non-invasive indicator of antler development.

Thermal signatures can be obtained through technologies such as hand-held infrared temperature sensors that take a single point (spot) measurement, or more sensitive equipment such as digital infrared temperature imaging (DITI) that can scan complete surfaces or whole objects at one time for whole-field temperature analysis. Infrared sensing technologies have been used in industrial settings for facility maintenance, high voltage-alternating current diagnostics, food safety (Kee 1997; Ma and Tao 2005) and a variety of other applications. For medical and physiological monitoring, DITI has been used as a non-invasive diagnostic technique to detect infrared emissions and create thermal maps displaying temperature distributions. These thermal maps are used when diagnosing breast cancer (Head and Elliott, 2002) and can also be instrumental in diagnosing vascular occlusions and deep venous thrombosis (Wheeler and Anderson, 1995). While the temperature of the skin is generally about 5°C cooler than the body core, since heat is often dissipated through the skin by evaporation and other methods to balance internal and external temperature (Adams et al. 1980), it is possible to detect infrared emissions from the skin and create a thermal map of temperature distributions by remote sensing (Purohit et al. 1985). Variations in skin temperature result from changes in tissue perfusion and blood flow (Winsor 1971), and since there is a high degree of thermal symmetry in the normal body, subtle abnormal temperature asymmetry can be

easily identified (Purohit et al. 1985). In livestock, DITI has been applied in the diagnosis of lameness in cattle and horses (Purohit 1980; Turner 1998; Cockcroft et al. 2000; Schmidt et al. 2003), for assessing fertility in bulls and rams (Purohit et al. 1985; Kastelic et al. 1995 and 1996; Gabor et al. 1998; and Coulter et al. 1988), and monitoring heat load in dairy cattle (White et al. 2006). Additional applications for DITI have developed from public concern regarding animal welfare and stress associated with commercial farm practices. DITI has been used for characterizing the responses of cattle to hot-iron and freeze branding (Schwartzkopf-Genswein 1997), as a non-invasive tool for measuring stress and assessing animal welfare (Stewart et al. 2005), and for early detection of infection and disease (Schaefer et al. 2004 and 2007). Moreover, the use of DITI in domestic livestock has led to new approaches to study wildlife or other captive exotic species that cannot be handled (McCafferty 2007). Specifically in deer, studies have examined the effects (ie. stress and inflammation) of antler removal (Cook and Schaefer 2002) and have used thermography to help with population census and capture (Wiggers and Beckerman 1993; Butler et al. 2006). In addition thermography has been used as a method for predicting internal composition characteristics of VA (U.S. Pat. No. to Schaefer, et al. 2005).

The antler can be described as vascularized, growing tissue, which develops an analogous blood, neural and cartilaginous network that ossifies and dies following hormonal induction of capillary constriction resulting in shedding of the velvet. The blood supply to the VA varies as the antler grows, branches into tines and begins to harden, allowing these phases to be investigated and mapped by infrared thermography. Given this, thermal gradients of the antler may permit the harvesting of VA at its peak in

the growth phase, which would be an invaluable tool to optimize harvesting to meet specific VA markets; similar to how live animal carcass ultrasonography is used in making feeding and harvesting decisions based on quality grading predictions in beef cattle (Hassen et al. 1999). The objective of this study was to evaluate the use of infrared temperature measurements conducted by single-spot infrared temperature sensor (SSTS; Experiment I) and whole-field DITI (Experiment II) to monitor VA growth *in vivo* during antler development in red deer stags (*Cervus elephus*).

### **Materials and Methods**

All stags were housed on improved pastures within 0.8 ha paddocks at the Texas AgriLife Research Center in Overton, TX. Water was provided ad libitum, and ~1.0 kg of grain supplement per stag (3:1 crushed corn to soybean meal ratio) was provided twice daily. On each sampling day, the stags were moved to the deer handling facility and restrained in a drop-floor chute for data collection. The deer were brought into the covered handling facility approximately 30 min prior to sampling, to reduce the effects of solar loading and allow them to acclimatize to the area. This study followed the General Guidelines for Animal Husbandry, as described in the Guide for the Care and Use of Agricultural Animals in Agricultural Research and Teaching (FASS, Savoy, IL), and was approved by the Texas A&M University Institutional Animal Care and Use Committee.

#### **Experiment I – Hand Held SSTS Infrared Measurements**

Data collection began in May and continued until July, with the ambient temperature ranging from 18.8°C to 29.3°C. Velvet antler growth rates and SST measurements (right antler only) were obtained from yearling ( $n = 8$ ;  $72.50 \pm 1.67$  kg)

and mature ( $n = 17$ ;  $136.80 \pm 1.94$  kg and  $> 2$  yr of age) red deer stags. Single-spot temperatures were acquired of VA surfaces with a Raynger®ST™ ProPlus non-contact thermometer (Raytek, Santa Cruz, CA). The Raynger is a hand-held infrared temperature sensor, in which a spotting laser is used to localize the area from which the thermal signatures on the surface of the antler tissue were measured. The temperature range for the Raynger is  $-32^{\circ}\text{C}$  to  $760^{\circ}\text{C}$  and has an accuracy of  $\pm 1\%$  of reading or  $\pm 1^{\circ}\text{C}$ , whichever is greater, at temperatures above  $23^{\circ}\text{C}$  (as per manufactures descriptions). Body weights and the length of the right and left antler main beam were recorded in cm with a flexible tape every 14 days following eruption (day 0) through day 56 in yearlings and day 112 in stags. Measurements (maximum temperatures) included main beam VA base and tip SST, in addition to background SST which included surface of the skin/hair coat on the neck, head (directly below the pedicle) and handling chute walls. To ensure that SST was collected from a consistent distance from the animal, the operator of the SSTS always stood on the same spot on the floor, which was marked prior to sampling (approximately 30 cm from the deer).

## **Experiment II - Digital Infrared Temperature Imaging (DITI)**

Data collection began in March and continued through August, with ambient temperatures ranging from  $14.4^{\circ}\text{C}$  to  $31.7^{\circ}\text{C}$ . Velvet antler growth rates from the right and left antler and digital infrared thermal images (right antler only) were obtained from yearling ( $n = 11$ ;  $77.73 \pm 2.55$  kg) and mature ( $n = 20$ ;  $134.23 \pm 4.88$  kg and  $> 2$  yr of age) red deer stags. Thermal images (Figure 4) were recorded using the Meditherm Vet 2000 Digital Infrared Thermal Imager (Compix Inc., Tualatin OR) and analyzed using Wintest Software (version 1.051011; Compix Inc.) in which square or rectangular areas

(depending on antler location) were drawn electronically on the images for temperature determinations. The ambient temperature (°C) inside the sampling area was recorded (Kestrel 3000, Nielsen-Kellerman Co., Boothwyn, PA) and entered into the camera to calibrate it for atmospheric conditions, and an emissivity set at 1.0 was used. To ensure that images were taken from a consistent distance from the animal, the camera was attached to a tri-pod stand, which was positioned at a marked distance of 152 cm from the animal. The stand was adjusted laterally to account for antler length but was not moved from the marked area. In addition, to facilitate accurate image collection, manual restraint by a handler was used to minimize head movements. The maximum temperature of the right antler was recorded (following eruption) within three main areas (the main beam base, midpoint, and tip) every 14 days and for individual tines as they erupted. In addition, maximum temperature of the eye and coat surface was recorded using DITI , and rectal temperatures (GLA M500 Hi-Performance Digital Thermometer, Agricultural Electronics, San Luis Obispo, CA) were recorded once every sampling period. Other measurements included body weight and scrotal circumference which were also obtained every 14 days. A single blood sample was collected for each animal during each sampling period by jugular venous puncture (vacutainer blood collection system; Becton, Dickinson and Co., Franklin Lakes, NJ). Blood samples were centrifuged for 20 min at 3,000 rpm for the collection of serum, stored at -20° C, and later analyzed for serum concentrations of testosterone using radioimmunoassay (RIA) procedures (Diagnostic Systems Laboratories, Inc; Webster, Texas), following manufacturer guidelines for assay procedures. Intra- and inter-assay coefficients of variation of testosterone were 3.43% and 7.81% respectively. Any yearling stag that did not achieve an antler length of at least



10 cm by day 70 ( $n = 6$ ) was removed from all analysis. Once those yearlings were removed, the yearling and mature stages ( $n=25$ ) were combined. For analysis, antler growth patterns were split into three time periods: Early (day 0-28), Mid (day 28-70) and Late (day 70-112) growth phases and were normalized relative to day of eruption (d 0). Antler tines were further categorized according to location (as described in Haigh and Hudson 1993; i.e., brow, bez, trez, royal and sur royal tines) and categorized into two time periods: Early and Late eruption.

### **Statistical Analysis**

There were no differences ( $P > 0.10$ ) in growth rates between the right and left VA for either stag age class, therefore data were pooled within age class for further analysis. Statistical analysis of the data was performed using ANOVA (factorial and repeated measures where appropriate) to ascertain antler location temperature (base vs. tip in Experiment I; base, mid, tip, tine in Experiment II), time, age class and respective interactions. For mean separation of study parameters, the Student's  $t$  test was employed and data expressed throughout as the mean  $\pm$  SEM. Pearson's correlations with Fisher's  $r$  to  $z$  transformations were used to determine the relationship among antler, eye, background and rectal body temperatures.

## **Results**

### **Experiment I**

In the yearling stags, body weight increased ( $P < 0.05$ ) from  $72.50 \pm 1.67$  kg on day 0 to  $77.27 \pm 1.86$  kg on day 56. In the mature stags, body weight increased ( $P < 0.05$ ) from  $136.80 \pm 1.94$  kg on day 0 to  $167.10 \pm 4.31$  kg on day 126. Yearling VA

growth rates increased ( $P < 0.01$ ) from  $0.16 \pm 0.03$  cm/d between eruption and day 14 to  $0.34 \pm 0.04$  cm/d between day 42 and 56 of growth (Figure 5). In mature stags, VA growth peaked at  $1.30 \pm 0.03$  cm/d between days 28 to 42, and declined thereafter (Figure 5). Length of the antler main beams for both the yearling and mature stags were positively correlated ( $r = 0.61$  and  $0.79$  respectively;  $P < 0.001$ ) with body weight. In the yearling stags, base and tip SST increased ( $P < 0.01$ ) from day 14 to day 28; however, from day 28 through day 56 no significant change in SST was observed ( $P > 0.10$ ). In addition, average base SST ( $36.2 \pm 0.4^{\circ}\text{C}$ ) was higher overall ( $P < 0.05$ ) than tip SST ( $35.9 \pm 0.5^{\circ}\text{C}$ ). In the mature stags, base and tip SST increased ( $P < 0.01$ ) from day 42 to 56. Tip SST remained unchanged from day 56 through day 112; however, base SST paralleled background SST measurements for the duration of the trial. Base and tip VA SST were positively correlated with one another ( $r = 0.43$ ;  $P < 0.05$ ) in yearling stags (Table 2). However, both measurements were also positively correlated with background SST (head and chute temperature). The same pattern was noted with the mature stags. Base and tip VA SST were positively correlated with one another ( $r = 0.49$ ;  $P < 0.05$ ); however, both measurements were positively correlated with background SST (head and chute temperature; Table 2).

## Experiment II

During the time of VA growth, scrotal circumference was positively correlated ( $P < 0.01$ ) with body weight ( $r = 0.70$ ). Scrotal circumference increased ( $P < 0.01$ ) from  $15.90 \pm 0.50$  cm on day 0 to  $20.50 \pm 0.70$  cm on day 112. Body weight increased ( $P < 0.01$ ) from  $113.0 \pm 5.40$  kg on day 0 to  $137.20 \pm 6.90$  kg on day 112. Mean serum concentrations of testosterone increased ( $P < 0.01$ ) from  $0.09 \pm 0.02$  ng/ml during the

early growth period to  $1.20 \pm 0.12$  ng/ml during the late growth period (time of hardening). Velvet antler length increased ( $P < 0.05$ ) from  $5.90 \pm 0.90$  cm on day 0 to  $63.30 \pm 2.70$  cm on day 112 (Figure 6). The greatest increase in VA growth rates occurred between day 14 and 28 with peak growth occurring at day 70 ( $1.37 \pm 0.10$  cm/d). After day 70, VA growth rates began to decline. During the early growth phase, VA temperatures were higher at the midpoint of the antler than at the base, with the tip of the antler falling in between (Figure 7). During the mid growth phase, there was a tendency ( $P < 0.10$ ) for the tip ( $38.4 \pm 0.2^\circ\text{C}$ ) to have a higher temperature than the base ( $37.9 \pm 0.2^\circ\text{C}$ ). In contrast during the late growth period, temperatures were higher ( $P < 0.01$ ) at the base ( $36.8 \pm 0.3^\circ\text{C}$ ) than at the tip ( $35.7 \pm 0.3^\circ\text{C}$ ) of the antler. Velvet antler base, midpoint and tip temperatures were positively correlated ( $P < 0.05$ ;  $r = 0.52, 0.54, 0.68$  respectively) with VA growth. As the tines began to develop, the temperature of the tip of the main beam decreased. However, once the growth of the tines declined the temperature of the tip increased. In addition, tine temperatures were higher ( $P < 0.01$ ) during the early growth period ( $38.5 \pm 0.4^\circ\text{C}$ ) than the late growth period ( $34.5 \pm 0.5^\circ\text{C}$ ; Table 3). With respect to rectal, eye and coat temperatures, rectal temperature was not correlated with any of the antler measurements or ambient temperature, whereas eye DIT was positively correlated with rectal temperatures (albeit at a low correlative value; Table 4;  $P < 0.05$ ). Eye DIT was positively correlated ( $P < 0.05$ ) to all antler measures, whereas eye and ambient temperatures were negatively correlated ( $P < 0.05$ ). Coat temperature was positively correlated ( $P < 0.05$ ) with ambient temperature and base of the antler, with no correlations observed in relation to eye, rectal or other antler locations with coat measurements.

## **Discussion**

Velvet antler growth in experiment I was comparable to other studies (Goss 1983; Fennessy et al. 1992) with mature stags' peak growth around 1 cm/d. In this study, SSTS measurements were not able to reliably signify changes in antler growth rates. Some anomalies were noted with SST in the yearling and mature stags. However, in both groups the SST of the antlers (base and tip) were positively correlated with background SST. It is apparent that environmental conditions such as temperature and air flow can have an impact on the reliability of thermal images when conducted in an uncontrolled environment, which is usually the case in the captive management of livestock and wildlife. It has been suggested that the ideal temperature for imaging is in the range of 20°C (Love and Linsted 1976) but a temperature below 30°C is acceptable (Turner et al. 1986) since heat loss from sweating does not occur below this temperature (William 1964); although this may vary by species and/or other aspects of the environmental conditions. In experiment I, the ambient temperature did not reach above 29.3°C during sampling, which is in the acceptable range. However, since the surface temperature of the antler in experiment I closely modeled the environmental temperature, the ambient temperature may have been too high for the sensitivity of this type of thermal imaging. In addition, SSTS may not have been sensitive enough to detect the changes in temperature related to the blood supply of the antler.

The growing antler is covered by velvet and short hair. The velvet is separated from the growing antler by undifferentiated connective tissue equivalent to the periosteum, and the blood supply is present in this layer. The velvet and hair covering the antler may have impeded the ability of the SSTS to detect not only the changes in the

different sections of the antler but also the changes occurring as the antler developed and calcified. Interference in thermal conductance by areas of fat, hair, fur, or other internal structures have been reported in other studies using thermography (Purohit et al. 1977). It has been shown that the temperature of a mammal is influenced by the thickness, density and quality of hair covering different parts of the body (McCafferty 2007). In addition different colored coats (black vs. white) and coat patterns influence solar heating at the surface (Benesch and Hilsberg 2003; Jones et al. 2005). Red deer in this study (Experiment II) had similar coat color and density, and our results demonstrated that coat surface temperatures correlated with ambient environmental temperatures and ambient temperatures were correlated with antler mid and tip temperatures. Infrared thermography has been used previously for monitoring heat load in livestock (dairy cattle: White et al., 2006; poultry: Bottcher et al., 1992). While the deer in the present investigation were equilibrated to a shaded environment prior to sampling, the influence of ambient conditions, which cannot be completely controlled in a management environment, cannot be ignored. Correlations in this study were also observed between eye DIT and rectal temperatures, as has been reported for a number of other species (Willard et al., 2006ab; Willard et al., 2007; Godfrey et al., 2007; Dray et al., 2008), and may have value as a non-invasive measure of body temperature and thermal load.

Digital infrared thermography (Experiment II) paralleled antler growth rates and depicted anomalies in antler and tine growth. The ambient temperature did not reach above 30.0°C, with the exception of the last sampling day, therefore most of the images were taken within the acceptable range. During the early growth period (0-28 d) the midpoint of the VA had the highest temperature, while as VA growth continued into the

mid growth period (28-70 d) temperatures at the tip of the antler increased. In contrast, during the late growth phase (70-112 d), temperatures were higher at the base of the antler. Moreover, a negative correlation was shown between the temperature of the VA and ambient temperature, providing evidence that DITI was able to pattern VA growth. The growing antler is highly vascularized and richly innervated. The blood supply is predominantly from the superficial temporal artery, which has a number of branches that supply both the lateral and medial aspects of the pedicle (Adams 1979). Early in growth, appreciable arterial supply and venous drainage is available through the pedicle, but this diminishes as calcification progresses (Adams 1979). During the early growth period there is ample blood supply which is allowing the antler to grow. This is shown using DITI, with the highest temperatures in the mid point of the antler. This blood supply also allows growth to begin in the brow and bez tines which usually occurs during this early growth period. As VA entered the mid growth period, the peak time of antler growth, temperature at the tip of the antler increased. Additional blood supply is needed during this time to promote antler growth and for the additional tines to develop. In the current study, as the VA reached the mid growth period, the trez and royal tines began to develop. Sur royal tines began to develop toward the end of the mid growth period and the beginning of the late growth period. As the VA reaches the late growth period the antler is beginning to harden. There is a gradient of progressive tissue differentiation from the tip toward the base of the antler. At the very tip, under the surface layers, there is a zone of fibroblasts; which changes to successive layers of cartilage, calcified cartilage and finally, bone (Haigh and Hudson 1993). This aspect of antler biology was clearly observed by changes in DIT. As the antler hardened the temperature decreased in

the tip of the antler and in the various tines. The base was the only area receiving an ample supply of blood, which is where DITI recorded the highest temperatures. These findings are in agreement with previous work by Schaefer et al. (2005), which states that as the antler enters the late harvest season it displays a greater degree of calcification, and the temperature difference between the tip and base of the antler is less.

As the antler hardened an increase in serum testosterone concentrations was recorded; with similar trends in scrotal circumference and body weight as might be expected. This is comparable with other studies (Suttie et al. 1984; Suttie et al. 1992) that have concluded that velvet shedding occurs as circulating testosterone concentrations rise. Testosterone may cause direct constriction of coronal arteries, or the steroid may interfere with tissue metabolism, resulting in necrosis and consequent arterial constriction leading to velvet shedding (Haigh and Hudson 1993).

There are many variables when it comes to harvesting VA for nutraceutical purposes. One variable, mineralization, is difficult to assess so farmers use antler shape as a guide, which could hasten or delay cutting and can result in serious downgrading of the VA. In addition, environmental conditions and nutrition impose considerable impact on VA weights, but could also provide opportunities to improve VA production by non-genetic means (van den Berg and Garrick 1997). Since DITI successfully paralleled the growth and hardening of VA its use could provide farmers additional insight for determining when mineralization may occur, and hopefully lead to better quality of VA and less downgrading. In addition, DITI could prove to be a useful tool for future research involving environmental x nutrition interactions focused on their effects on quality of VA harvested and to non-invasively monitor enhanced antler regeneration.

Sensitivity and practical use of SSTS has limitations for monitoring dynamic changes in antler physiology, whereas DITI may profile antlers for a more comprehensive gradient analysis. New technologies and enhanced sensitivity of thermal imaging devices than those used in the present investigation may reveal new uses for monitoring antler physiology as applied to deer management, however controlling ambient influences within production-management or free-ranging environments will remain a challenge.

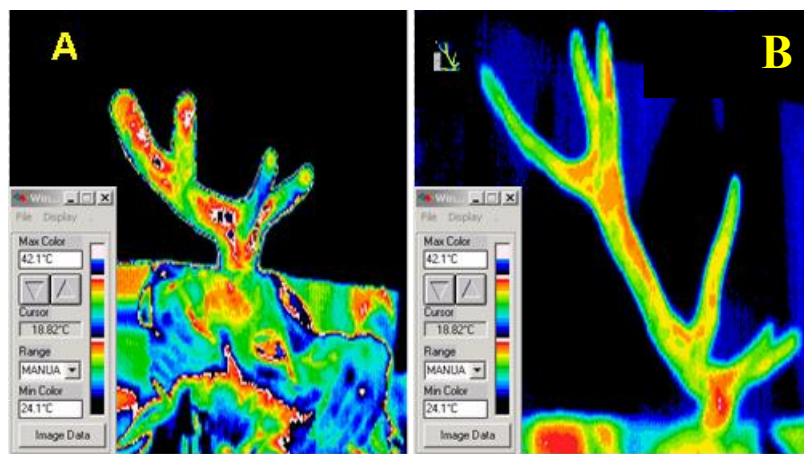


Figure 4 Thermal images of the same red deer stag (Experiment II) taken during the mid growth phase (A, day 42, main beam length 25 cm ) and the late growth phase (B, day 112, main beam length 71 cm) when the antler was beginning to harden

These pictures were taken at the same distance, however the camera was mounted on a tri-pod allowing for lateral adjustment to facilitate growth of the antler. During the mid growth phase (Panel A) there is a greater blood supply to the antler, which in turn causes higher temperatures to be present and is shown in white and multiple shades of red. As the antler hardens (Panel B) the blood supply surrounding the antler diminishes and the highest temperatures are shown in the pedicle and base of the antler



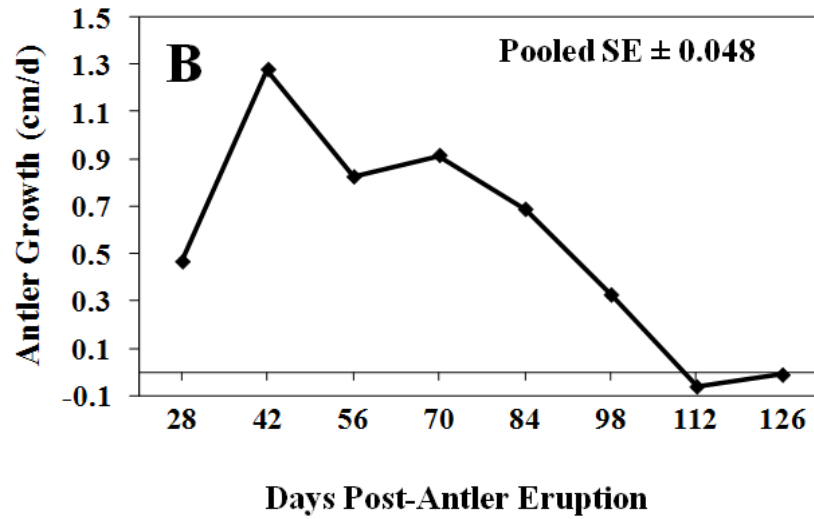
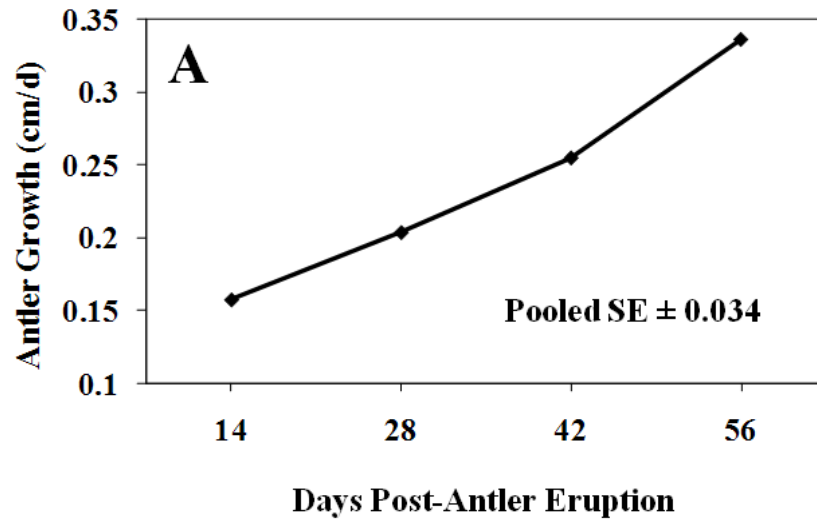


Figure 5 Main beam antler growth rates for yearling (n=8; panel A) and mature (n=17; Panel B) red deer stags in experiment I

Table 2 Correlation coefficients between background (chute, head and hair coat), antler base and antler tip maximum thermal measurements using SSTS in yearling and mature stags

	Head Temp <sup>y</sup>	Hair Coat Temp <sup>x</sup>	Chute Temp	Antler Base Temp
Yearling Stags (n=8)				
Hair Coat Temp	-0.051			
Chute Temp	0.284	0.077		
Antler Base Temp	0.368 <sup>z</sup>	0.007	0.481 <sup>z</sup>	
Antler Tip Temp	0.528 <sup>z</sup>	0.216	0.495 <sup>z</sup>	0.434 <sup>z</sup>
Mature Stags (n=17)				
Hair Coat Temp	0.152			
Chute Temp	0.681 <sup>z</sup>	0.063		
Antler Base Temp	0.645 <sup>z</sup>	0.115	0.624 <sup>z</sup>	
Antler Tip Temp	0.361 <sup>z</sup>	0.204 <sup>z</sup>	0.295 <sup>z</sup>	0.497 <sup>z</sup>

<sup>z</sup>P<0.05

<sup>y</sup>Head temperature was measured directly below the pedicle

<sup>x</sup>Hair coat temperature was measured on the neck of the stag.

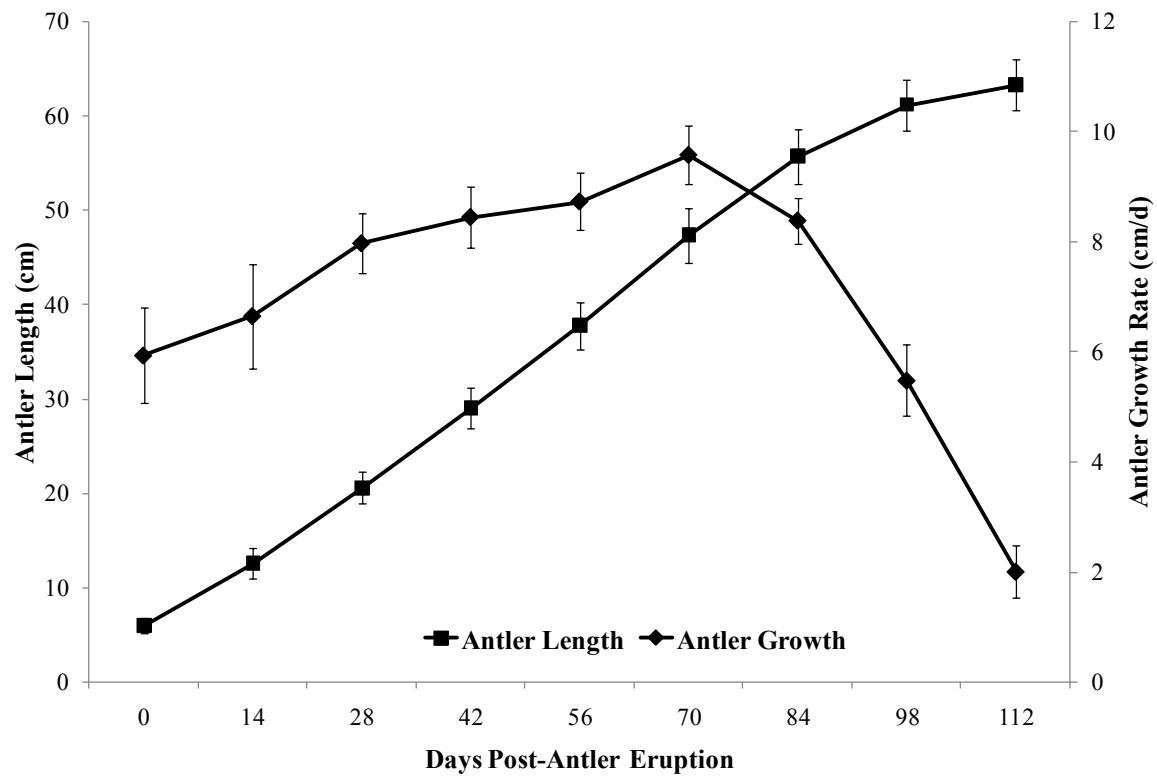


Figure 6 Main beam VA length (cm) and growth rate (cm/d) in experiment II for all red deer stags (n=31).

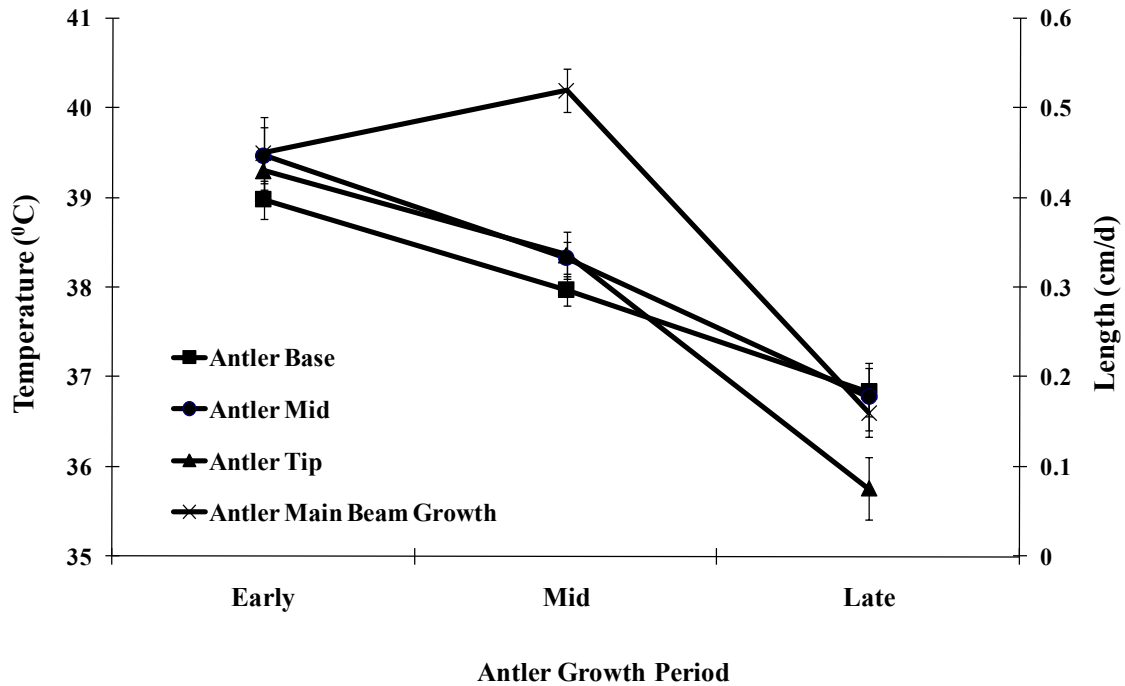


Figure 7 Main beam antler growth (cm/d) and temperature (°C), for all stags (n=31) in experiment II using DITI, during the early, mid and late growth periods.

Table 3 Maximum tine temperatures (°C), using DITI, during the early and late growth period in red deer stags (n=23)

	Early Growth Period	Late Growth Period	P-Value
Brow	39.71 ± 0.36	34.38 ± 0.55	<0.0001
Bez	38.44 ± 0.28	34.37 ± 0.47	<0.0001
Trez	38.41 ± 0.26	34.97 ± 0.45	<0.0001
Royal	38.10 ± 0.50	34.20 ± 0.69	<0.01
Sur Royal	37.64 ± 0.55	34.64 ± 0.96	<0.05

Table 4 Correlation coefficients between maximum ambient, coat, rectal, eye and main beam antler thermal measurements (Experiment II) for all red deer stags (n=31)

	Ambient Temp	Antler Base Temp	Antler Mid Temp	Antler Tip Temp	Rectal Temp	Eye Temp
Antler Base Temp	-0.081					
Antler Mid Temp	-0.258 <sup>z</sup>	0.885 <sup>z</sup>				
Antler Tip Temp	-0.315 <sup>z</sup>	0.807 <sup>z</sup>	0.857 <sup>z</sup>			
Rectal Temp	-0.248	0.191	0.220	0.284		
Eye Temp	-0.567 <sup>z</sup>	0.491 <sup>z</sup>	0.524 <sup>z</sup>	0.562 <sup>z</sup>	0.263 <sup>z</sup>	
Coat Temp	0.419 <sup>z</sup>	0.435 <sup>z</sup>	0.183	0.112	-0.039	-0.059

<sup>z</sup>P<0.05

<sup>y</sup>All temperature relationships represent maximum temperatures

## References

- Adams, J. L. 1979. Innervation and blood supply of the antler pedicle of red deer. NZ Vet. J. 27: 200-201.
- Adams, T., Heisey, S. R., Smith, M. C., Steinmetz, M. A., Hartman, J. C., and Fry, H. K. 1980. Thermodynamic techniques for the quantification of regional blood flow. Am. J. Physiol. 238: 682-696.
- Benesch, A. R. and Hilsberg, S. 2003. Infrared thermographic study of surface temperature in zebras. Zoologische Garten. 73: 74-82.
- Butler, D. A., Ballard, W. B., Haskell, S. P., and Wallace, M.C. 2006. Limitations of thermal infrared imaging for locating neonatal deer in semiarid shrub communities. Wildlife Society Bulletin. 34: 1458-1462.
- Cockcroft, P. D., Henson, F. D., and Parker, C. 2000. Thermography of a septic metatarsophalangeal joint in a heifer. Vet. Res. 146: 258-260.
- Cook, N. J. and Schaefer, A. L. 2002. Stress responses of wapiti (*Cervus elaphus canadensis*) to removal of velvet antler. Can. J. Anim. Sci. 82: 11-17.
- Coulter, G. H., Senger, P.L., and Bailey, D.C. 1988. Relationship of scrotal surface temperature measured by infrared thermography of subcutaneous testicular temperature in the ram. J. Reprod. Fertil. 84: 417-423.
- Dray, S. M., Vann, R. C., Chromiak, A. B., Lyons, J. K., Welsh T. H., Randel, R. D., and Willard, S. T. 2008. Ocular thermography as a measure of body temperature in beef cattle: Influences of environmental factors. J. Anim. Sci. 86(Suppl 2): 470.
- Fennessey, P. F. 1992. Deer: possibilities and experiences with expanding the gene pool. Proceedings of the Australian Association of Animal Breeding and Genetics. 10: 195-199.
- Gabor, G. R., Sasser, G., Kastelic, J. P., Coulter, G. H., Everson, D. O., Falkay, G., Mezes, M., Bozo, S., Cook, R. B., and Csik, J. V. 1998. Endocrine and thermal responded to GnRH treatment and prediction of sperm output and viability in Holstein-Friesian breeding bulls. Theriogenology. 50: 177-183.
- Godfrey, R.W., Driscoll, R.C., and Willard S.T. 2007. Use of infrared thermal imaging to measure changes in body temperature following lipopolysaccharide (LPS) administration in hair sheep ewes. J. Anim. Sci. 85(Suppl 1): 676.
- Goss, R. J. 1983. Deer antlers: Regeneration, function and evolution. New York: Academic Press.

- Haigh, J. C. and Hudson, R. J. 1993. Farming Wapiti and Red Deer. St. Louis, Missouri: Mosby-Year Book, Inc..
- Hassen, A., Wilson, D. E., and Rouse, G. H. 1999. Evaluation of carcass, live, and real-time ultrasound measures in feedlot cattle: II. Effects of different age end points on the accuracy of predicting the percentage of retail product, retail product weight, and hot carcass weight. *J. Anim. Sci.* 77: 283-290.
- Jones, M., Denson, A., Williams, E., Graves, K., Dos, Santos A., Kouba, A., and Willard, S. 2005. Assessing pregnancy status using digital infrared thermal imaging in Holstein dairy heifers. *J. Anim. Sci.* 83(Suppl 1): 40.
- Kastelic, J. P., Coulter, G. H., and Cook, R. B. 1995. Scrotal surface, subcutaneous, intratesticular and intraepididymal temperatures in bulls. *Theriogenology*. 44: 147-152.
- Kastelic, J. P., Cook, R. B., Coulter, G. H., and Saake, R. G. 1996. Ejaculation increases scrotal surface temperature in bulls with intact epididymides. *Theriogenology*. 46: 889-892.
- Kee, W. 1997. Thermography: There's more to it than meets the eye. *Electrical Construction and Maintenance*. 96: 33-40.
- Love, T. J. and Linsted, R.D. 1976. Theoretical basis for use of skin temperature as a plethysmographic indicator. *Am. Soc. Mech. Eng.* 75-WA/Bio. 6: 1-4.
- Ma, L. and Tao, Y. 2005. An infrared and laser range imaging system for non-invasive estimation of internal temperatures in chicken breasts during cooking. *Transactions of the American Society of Agricultural Engineers*. 48: 681-690.
- McCafferty, D. J. 2007. The value of infrared thermography for research on mammals: previous applications and future directions. *Mammal Rev.* 37: 207-223.
- Medical Monitoring Systems, Pty Ltd. 1999. Operating instructions for the vet2000 and manual of equine thermography. Meditherm, Beaufort, NC.
- Moore, G. H., Littlejohn, R. P., and Cowie, G.M. 1988. Liveweights, growth rates, and antler measurements of farmed red deer stags and their usefulness as predictors of performance. *New Zealand J. Agric. Res.* 31: 285-291
- Purohit, R. C., Bergfeld, W. A., McCoy, M. D., Thompson, W. M., and Sharman, R.S. 1977. Value of clinical thermography in veterinary medicine. *Auburn Veterinarian*. 104-108.
- Purohit, R. C. 1980. The diagnostic value of thermography in equine medicine. *Proceedings from the Annual Convention of the American Association of Equine Practitioners*. 26: 317-326.

- Purohit, R. C., Hudson, R. S., Riddell, M. G., Carson, R. L., Wolfe, D. F., and Walker, D. F. 1985. Thermography of the bovine scrotum. *Am. J. Vet. Res.* 46: 2388-2392.
- Schaefer, A.L., Cook, N., Tessaro, S.V., Deregt, D., Desroches, G., Dubeski, P.L., Tong, A.K.W., and Godson, D.L. 2004. Early detection and prediction of infection using infrared thermography. *Can. J. Anim. Sci.* 84: 73-80.
- Schaefer, A.L., Suttie, J.M., Lawrence, R.A., Desroches, G.B., and Lepage P. 2005. Method for the evaluation of velvet antler. U.S. Pat. No. 2,375,870.
- Schaefer, A.L., Cook, N.J., Church, J.S., Basarab, J., Perry, B., Miller, C., and Tong, A.K.W. 2007. The use of infrared thermography as an early indicator of bovine respiratory disease complex in calves. *Res. Vet. Sci.* 83: 376-384.
- Schmidt, S., Bowers, S., Graves, K., Carroll, R., White, J., and Willard, S. 2003. Use of infrared thermography to assess thermal temperature gradients and pathologies of the bovine claw. *J. Anim. Sci.* 81(Suppl 1): 323.
- Schwartzkopf-Genswein, K. S. and Stookey, J. M. 1997. The use of infrared thermography to assess inflammation associated with hot-iron and freeze branding in cattle. *Can. J. Anim. Sci.* 77: 577-583.
- Stewart, M., Webster, J.R., Schaefer, A.L., Cook, N.J., and Scott, S.L. 2005. Infrared thermography as a non-invasive tool to study animal welfare. *Animal Welfare.* 14: 319-325.
- Suttie, J. M., Lincoln, G. A., and Kay, R. N. B. 1984. The endocrine control of antler growth in red deer stags. *J. Reprod. Fert.* 71: 7-15.
- Suttie, J. M., Fennessy, P. F., Corson, I. D., Veenvliet, B. A., Littlejohn, R. P., and Lapwood, K. R. 1992. Seasonal patterns of luteinizing hormone and testosterone pulsatile secretion in young adult red deer stags (*Cervus elaphus*) and its association with the antler cycle. *J. Reprod. Fert.* 95: 925-933
- Turner, T. A., Purohit, R. C., and Fessler, J. F. 1986. Thermography: A review in Equine Medicine. *Compendium on Continuing Education for the Practicing Veterinarian.* 8: 855-861.
- Turner, T. A. 1998. Thermography as an aid in the localization of upper hind limb lameness. *Equine Athletics.* 11: 38-42.
- Van den Berg, G. H. J. and Garrick, D. J. 1997. Inheritance of adult velvet antler weights and live weights in farmed red deer. *Livestock Production Science.* 49: 287-295.



- Wallis, T. 1993. History and evolution of deer farming and the early velvet industry in New Zealand. Pages 21-24 in I. Woodhouse, ed. A Salute to World Deer Farming-Proceedings of the First World Deer Congress. New Zealand Deer Farmers Association, Christchurch.
- White, M. B., Jones, M., Schmidt, S., and Willard, S. 2006. Use of digital infrared thermal imaging (DITI) for monitoring environmental physiology in dairy cattle. *J. Anim. Sci.* 84(Suppl 1): 212.
- Wiggers, E. P. and Beckerman, S. F. 1993. Use of thermal infrared sensing to survey white tailed deer populations. *Wildlife Society Bulletin.* 21: 263-268.
- Willard, S.T., Vinson, M. C., and Godfrey R.W. 2006a. Digital infrared thermal imaging of the eye as correlated to rectal and vaginal temperature measurements in the ewe. *J. Anim. Sci.* 84(Suppl. 1): 434.
- Willard, S., Ryan, P., Sykes, D., Crenshaw, M., Vann, R., Randel, R., Welsh, T., Bowers, S., Jones, M., and Chromiak, A. 2006b. Effectiveness of ocular thermography for the determination of body temperature in livestock: A multi-species analysis. *J. Anim. Sci.* 84(Suppl 1): 354.
- Willard, S., Dray, S., Farrar, R., McGee, M., Bowers, S., Chromiak, A., and Jones, M. 2007. Use of infrared thermal imaging to quantify dynamic changes in body temperature following LPS administration in dairy cattle. *J. Anim. Sci.* 85(Suppl 2): 26
- William, K.L. 1964. Infrared thermography as a tool in medical research. *Ann. NY Acad. Sci.* 121: 99-112.
- Wilson, P.R., Mellor, D.J., Stafford, K.J., and Haigh, J.C. 2001. Velvet antler removal: international welfare, ethical and legal issues. In: Sim, J.S., Sunwoo, H.H., Hudson, R.J., and Jeong, B.T. (eds.) *Antler Science and Product Technology*, Pp 363-386. Antler Science and Product Technology Research Center, Edmonton.
- Wilson, P. R. and Stafford, K. J. 2002. Welfare of farmed deer in New Zealand. 2. Velvet antler removal. 50: 221-227.
- Winsor, T. 1971. Vascular aspects of thermography. *J. Cardiovasc. Surg.* 12: 379-388.
- Zhang P. 1982. China. Pages 11-14 in D. Yerex, ed. *The Farming of Deer: World Trends and Modern Techniques* Agricultural Promotion Associates Ltd, Wellington.

## CHAPTER V

### AN ASSESSMENT OF THERMAL SIGNATURES OF THE ELEPHANT FOOT AS DETERMINED BY DIGITAL INFRARED THERMOGRAPHY

#### **Introduction**

The welfare of elephants in captivity is a great concern for zoos from both an animal husbandry and a public perception perspective. The size of the elephant, its roaming habits and its structured social life create a challenge for zoos to maintain a high standard of care for this animal. One major challenge when dealing with elephant care is maintaining the health and function of the foot. Foot problems constitute the single most important ailment of captive elephants, and can lead to life threatening conditions if not detected and treated early (Fowler, 2001). Abscessation or cracking of the sole or toenails, overgrowth of the cuticle, toenails or sole, foot rot and degeneration of the sole and skin are just a few of the ailments that a captive elephant may face in captivity (Roocraft and Oosterhuis, 2001). Early detection is vital when dealing with these ailments, or they can evolve into very severe conditions which are much harder to treat. Thermography has been used in the diagnosis of lameness in cattle and horses (Purohit 1980; Turner 1998; Cockcroft 2000; Schmidt et al. 2003) and could be used as a screening device in the elephant to detect foot problems.

For medical and physiological monitoring, digital infrared thermography (DITI) has been used as a non-invasive diagnostic technique to detect infrared emissions and

create thermal maps displaying temperature distributions. While the temperature of the skin is generally about 5°C cooler than the body core, since heat is often dissipated through the skin by evaporation and other methods to balance internal and external temperature (Adams et al. 1980), it is possible to detect infrared emissions from the skin and create a thermal map of temperature distributions by remote sensing (Purohit et al. 1985). Variations in skin temperature result from changes in tissue perfusion and blood flow (Winsor 1971), and because there is a high degree of thermal symmetry in the normal body subtle abnormal temperature asymmetry can be easily identified (Purohit et al. 1985). In livestock, DITI has been applied in the diagnosis of foot and leg problems in cattle and horses (Purohit 1980; Turner 1998; Cockcroft 2000; Schmidt 2003), for assessing fertility in bulls and rams (Purohit et al. 1985; Kastelic et al. 1995 and 1996; Gabor et al. 1998; and Coulter et al. 1988), for characterizing the responses of cattle to hot-iron and freeze branding (Schwartzkopf-Genswein 1997), and monitoring heat load in dairy cattle (White et al. 2006). Moreover, the use of DITI in domestic livestock has led to new approaches to study wildlife or other captive exotic species that cannot be handled (McCafferty 2007). In 2003 the AZA's Standards for Elephant Management and Care guidelines recommended that every elephant in North American zoos have either a radiograph or thermograph of their feet on record, so zoos could have a baseline on each elephant's foot in case a problem should develop (AZA, 2003). However, researchers do not have a good understanding of what is a normal or baseline heat signature for an elephant's foot. In addition, reports of the use of thermography in elephants have been limited in scope, aside from anecdotal reports or clinical case studies of lameness or overt manifestations of an injury (abscess, or wound; Hilsberg, 2002). These limitations led us

to the objectives of this study which were to determine whether “normal” temperature gradients of the foot exist among elephants as detected using DITI and to evaluate the variations in temperature gradients of elephant feet following repeated monitoring using DITI within the management environment.

## **Materials and Methods**

Due to the fact that many facilities can only manage to house a small number of elephants, three locations were used in this investigation. Multiple locations not only increased numbers but also allowed data collection from African and Asian male and female elephants. However due to the differences among locations (temperature, management areas, data collection etc.) the analysis for each location was completed independently and will be reported as such in the results section.

### **Data Collection**

Thermal images (Figure 8) were acquired of the foot pad of all 4 feet with the FLIR P60 real-time camera (Flir Systems, Danderyd, Sweden) with emissivity set at 1 and analyzed using ThermaCAM Researcher Pro (version 2.7, ). All images were collected at a distance of 1 meter from the elephant’s foot and the focal plane and orientation of the camera were kept constant among elephants. If the elephants were moved from an outdoor environment to an indoor facility they were allowed to acclimate for a minimum of 20 min. However, not all locations housed the elephants in a controlled temperature environment. In these cases care was taken to insure thermal images were not acquired in direct sunlight. In both environments the ambient temperature and relative humidity was recorded (Kestrel 3000, Nielsen-Kellerman Co., Boothwyn, PA).

The elephant's foot was positioned for routine trimming or maintenance. At all locations the foot pad was dried (if needed) and debris from the foot pad was removed with a brush and then allowed to acclimate before the image was taken.

To determine thermal gradients of the elephant's whole foot two different analyses were investigated using the software program ThermoCAM Researcher Pro. In the first analysis (circle analysis) a circle was drawn inside the perimeter of the thermal image of the elephant pad, in the second analysis (shape analysis) multiple lines were connected forming a decagon inside the perimeter of the thermal image of the elephant pad (Figure 9). Additional analysis was performed by classifying the foot pad into regional quadrants (medial, lateral, cranial, caudal) and concentric gradients (inner core, middle, outer peripheral; Figure 9). At the Memphis Zoo environmental data (outside vs. inside management environments) was also included in the analysis. Data were expressed as maximum, average and minimum temperature along with standard deviation; which can be used as a measure of temperature variability within the area being investigated. If a pre-existing foot condition or injury was known or identified the foot pad was re-imaged at a closer focal range for greater resolution of the affected area, and these elephants were classified as "case studies".

## **Location**

### *Study I (Memphis Zoo)*

Serial imaging was conducted at the Memphis Zoo (Memphis, TN) on (n = 2) female African Elephants. The first thermal imaging session began on June 17, 2004 and concluded July 26, 2004, with images being collected in the outside management environment in 2 to 7 day intervals. During these months the temperature ranged from

22.5 to 31°C, with the average temperature being 26.9 °C. In the second thermal imaging session (year 2), image collection began on May 24, 2005 and concluded June 30, 2005. Once again thermal images were collected in 2 to 7 day intervals; however, images were collected indoors in a controlled temperature environment in addition to images being collected in the outside management environment.

### *Study II (Nashville Zoo)*

A single imaging session was conducted on August 16, 2005, at the Nashville Zoo at Grassmere (Nashville, TN) on (n = 3) female African Elephants. The imaging session was conducted indoors in a controlled temperature environment with the temperature ranging from 22.0°C to 24.2°C and the relative humidity ranging from 77% to 81%.

### *Study III and IV (Riddle Elephant Sanctuary)*

A single imaging session was conducted on July 8, 2004 at the Riddle Elephant Sanctuary (Greenbriar, AR) on African (n = 3 female, n = 5 male) and Asian (n = 4 female, n = 1 male) Elephants. While conducting the imaging session, the elephants used for Experiment IV (case studies) were identified. Images were collected indoors and outside in management environments. During this imaging session the temperature and relative humidity ranged from 26.5°C to 32.3°C and 61% to 86% respectively.

## **Statistical Analysis**

Statistical analysis was performed using ANOVA to ascertain foot pad parameters (fore vs. hind, left side vs. right side, medial vs. lateral, cranial vs. caudal, and concentric analysis), differences among species, and respective interactions. For mean separation of

study parameters, the Student's t test was employed and data expressed throughout as the mean  $\pm$  SEM.

## **Results and Discussion**

### **Study I (Memphis Zoo)**

There were no differences ( $P > 0.10$ ) in fore vs. hind or left vs. right thermal gradients or values, so all foot pad data were combined when analyzing shape analysis in the two different environments (Figure 10). Since only two elephants were used in the analysis all data is descriptive. When the elephants were housed outdoors the temperature of the pad ranged from 27°C to 40°C and followed the pattern of the temperature outside. When thermal imaging was conducted indoors the temperature of the pad ranged from 25°C to 30°C. In addition when the thermal images were acquired in the outside environment the standard deviation of the temperatures within the pad were greater numerically ranging from 0.2°C to 1.0°C compared to the standard deviation of the images taken inside ranging from 0.2°C to 0.4°C. When analyzing medial vs. lateral, cranial (toe) vs. caudal (heel), and concentric gradients data were combined within year and location. Numerically there were no differences in temperature between medial vs. lateral (Figure 11), however when the elephants were housed outside the MAX and MIN temperature for both measurements were numerically higher than when housed indoors (36°C vs. 27°C; 32°C vs. 24°C respectively). The same pattern was noted when analyzing cranial vs. caudal (Figure 12). There were no numerical differences within the pad but the temperatures of the pad were numerically greater when the images were taken in the outside environment vs. the inside environment (MAX: MIN:). Concentric analysis also showed the same temperature pattern with the images taken in the outside

environment having a higher temperature than those in the inside environment. In addition the concentric parameters (inner, middle and outer; Figure 13) from the outside images had similar temperature gradients (33°C, 33.3°C, 33.5°C respectively) compared to the images taken indoors that numerically showed a greater range when comparing the inner and outer parameters (26.1°C vs. 27.45°C, respectively). These findings coincide with previous studies reporting that environmental conditions can play a role in the accuracy of thermal imaging when conducted in an uncontrolled environment, which is usually the case in the captive management of livestock and wildlife. It has been suggested that the ideal temperature for imaging is in the range of 20°C (Love and Linsted, 1976) but a temperature below 30°C is acceptable (Turner et al, 1986). In the current study the outside temperature did reach above 30°C, in year one the Max ambient temp was 31.0°C and year two the Max ambient temperature reached 32.6 °C which does not seem exceptionally higher than the acceptable limit . However, it must be taken into consideration that the surface temperature of the enclosure was probably much higher due to the absorption of heat. This heat would be transferred to the elephant pad resulting in the higher temperatures noted when the elephants were housed outdoors and would also explain the difference in the range of temperatures, with a greater temperature range of the elephant's pad being evident in the indoor environment. In a previous study (Bowers et al, 2009), a greater difference in thermal temperature gradients between pregnant and nonpregnant mares occurred at temperatures below 20°C which has been stated to be a more ideal temperature (Love and Linsted, 1976). Previous findings coupled with the findings of the present study suggest the accuracy of thermal imaging increases when the subject is in a temperature controlled environment below 30°C. If a temperature



controlled environment is not available the animal should be removed from direct sunlight and the ambient conditions should be recorded for comparison with future images.

## **Study II (Nashville Zoo)**

The elephants at the Nashville Zoo consisted of 3 African females; therefore all were included in data analysis. Circle versus shape analysis was performed on all the elephant pad thermal images and were compared (Table 5) by side (left vs. right) and limb (fore vs. hind). A significant difference ( $P < 0.05$ ) was found when comparing max temp for the left side in circle vs. shape analysis. However this temperature difference was minimal with the difference in temperature being  $1.16^{\circ}\text{C}$ . This would suggest that either method of analysis (circle vs. shape) is appropriate when examining thermal images as long as the method is consistent within animal. There were no differences ( $P > 0.10$ ) in fore and hind leg temperatures when analyzing medial, lateral, cranial or caudal, so data were pooled for the purposes of data presentation (Table 6). There were no differences ( $P > 0.10$ ) in MAX temperature in medial vs. lateral ( $27.55^{\circ}\text{C}$  vs.  $27.79^{\circ}\text{C}$ ) or cranial vs. caudal ( $27.26^{\circ}\text{C}$  vs.  $27.54^{\circ}\text{C}$ ) parameters. The temperatures among the four parameters were similar ranging from  $24.03^{\circ}\text{C}$  (MIN) to  $28.03^{\circ}\text{C}$  (MAX). In the concentric analysis (Table 7) the inner temperature of the hind limb was significantly lower ( $1.28^{\circ}\text{C}$ ) than the fore limb, however as the temperature gradient moves to the outer area of the pad there is no significant difference ( $P > 0.10$ ) in the temperature of the hind and fore limbs. There was also a difference ( $P < 0.05$ ) in the MAX temperature of the hind limb when comparing the inner concentric gradient to the outer most gradient ( $25.15 \pm 0.2^{\circ}\text{C}$  vs.  $27.50 \pm 0.59^{\circ}\text{C}$ ). Both of these findings could be explained by the

morphology of the elephant's foot. The elephant's hind foot is more oval in shape and when unloaded the sole surface is convex (Weissengruber et al, 2006), causing the sole to bulge outward. This bulging of the sole could decrease blood flow to the center of the foot and distribute flow to the outer peripheral areas. The fore foot of the elephant does not act in the same way and remains flat regardless of weight load (Weissengruber et al, 2006). It is important to note that only 3 animals were investigated in this analysis of the present study, and to elucidate a more accurate thermal pattern of the elephant pad additional animals would be required.

### **Study III (Riddle Elephant Sanctuary)**

The Riddle Sanctuary houses African and Asian elephants of both genders. This housing arrangement allowed not only data to be investigated among males and females of the same species, but also to compare species. However there was only one Asian male elephant so all data pertaining to this animal's foot pads are descriptive. The circle analysis was used to interpret the images of the fore and hind pads for both male and female elephants of both species. There were no differences ( $P > 0.10$ ) in right vs. left so data were pooled within elephant (Table 8). Within the circle analysis the fore foot had a higher ( $P < 0.05$ ) MAX temperature than the hind foot in the African elephants regardless of sex (Males:  $32.2 \pm 0.31$  °C vs.  $29.7 \pm 0.32$  °C; Females:  $32.9 \pm 0.33$  °C vs.  $31.2 \pm 0.74$  °C). This same pattern was noted in male African elephants with MIN temperature of the fore foot being higher than the hind foot ( $28.3 \pm 0.52$  °C vs.  $27.3 \pm 0.28$  °C), however there were no differences ( $P > 0.10$ ) in MIN temperature when analyzing fore vs. hind foot in the female African elephants. In addition, when comparing male vs. female, the MAX temperature of the hind feet of the female African elephants were higher ( $P < 0.05$ ;

$31.2 \pm 0.74$  °C vs.  $29.7 \pm 0.32$  °C) then the male African elephants. The forelimbs of the elephant support about 60% of the body weight dynamically and statically (Alexander et al, 1979) which could explain the higher temperature of the forefoot. Morphological differences also exist between the fore and hind foot with the hind foot being smaller and more compressed than the fore foot (Ramsey and Henry, 2001). When the hindfoot is unloaded the sole surface is convex, by contrast when the forelimb is unloaded the sole surface remains flat which could be due to the difference structure and shape of the metacarpal cushion (Weissengruber et al, 2006). However, in the Asian females there were no differences ( $P > 0.10$ ) in MAX or MIN temperatures of the fore vs. hind feet. The Asian elephant is like the African elephant with the forelimbs supporting almost 60% of body weight, however the Asian elephant is smaller in height and weight than the African elephant and the shape and lateral compression of the hind foot is not as apparent (Ramsey and Henry, 2001). Significant differences ( $P < 0.05$ ) in temperature of the fore vs. hind feet were also seen among species. African female elephants had higher temperatures of the fore (MAX:  $32.9 \pm 0.33$  °C vs.  $31.0 \pm 0.42$  °C; MIN:  $29.5 \pm 0.44$  °C vs.  $26.9 \pm 0.34$  °C) and hind (MIN:  $28.5 \pm 0.55$  °C vs.  $27.1 \pm 0.48$  °C) feet than the Asian females when looking at MAX and MIN temperatures. When looking at the Asian male elephant the temperature of the hind and fore feet are numerically lower than all the other elephants but this elephant was housed indoors during the acquisition of the thermal images. The analysis of medial vs. lateral and cranial vs. caudal temperatures yielded no significant differences ( $P > 0.10$ ; Table 9) between male or female elephants when grouped in the same gender and species. However, when comparing species the female African elephants had higher ( $P < 0.05$ ) MAX, MIN and AVG medial, lateral, cranial and

caudal temperatures except for the comparison of MAX temperature of the cranial portion of the foot. These temperature differences ranged from 1.2 °C to 2.4 °C. These differences could be attributed to the difference in size and weight between species or due to morphological differences. The musculature and vasculature of Asian and African elephants are similar but minor differences have been reported (Ramsay and Henry, 2001). It has been reported that Asian elephants also seem to have more connective tissue within the cushions than the African species (Benz, 2005) which could alter thermal patterns. African elephants are also known to have more proliferative pad growth than the Asian most likely due to natural environment. This additional pad growth requires the African elephant to need more foot care or trimming to the pad (Roocroft and Oosterhuis, 2001). Recent trimming or lack thereof could alter the thickness of the pad, in turn changing the degree of vascularity that the thermal camera can detect. Therefore, since variations in skin temperature result from changes in blood flow (Winsor 1971) this could lead to differences in thermal patterns. The elephants in this study were not trimmed recently and a detailed history of foot trimming was not available which highlights the need for record keeping when using thermal imaging since numerous factors can affect the accuracy of the heat signatures. In order to confirm differences in heat signatures among species of elephants and gender more information and animal numbers are needed.

#### **Study IV (Case Studies)**

In the first case study a 57 year old Asian elephant had a toe abscess in her right fore-limb (Figure 14; Panel A). This abscess was noted by the keeper and was already receiving treatment. The maximum temperature of the affected toe ( $32.8 \pm 1.6$ ) was

higher ( $P < 0.05$ ) than the adjacent two unaffected toes and the center of the pad ( $28.5 \pm 0.2$ ,  $28.8 \pm 0.2$  and  $30.0 \pm 0.4$ , respectively). In addition the standard deviation, which is a measure of variability, of the affected toe was also higher, suggesting asymmetry which is indicative of changes in tissue perfusion and blood flow (Winsor 1971). The second case study involved a 20 yr old male African elephant with a foot pad abscess in the left fore-limb (Figure 14; Panel B). As before, the abscess was noted by the keeper and was already receiving treatment. The temperature in the affected part of the pad was higher ( $P < 0.05$ ) compared to the unaffected pad area ( $33.0 \pm 0.6$  vs.  $31.4 \pm 0.1$ ). These findings are consistent with previous research investigating the use of thermography to detect lameness and inflammation in the horse (Eddy et al., 2001; Turner, 1991, Purohit and McCoy, 1980). Heat is one of the main signs of inflammation or infection. When heat or hot spots are found they are typically described as being at least  $1^{\circ}\text{C}$  higher than normal and in an unexpected area. Turner (1991) stated that temperature differences greater than  $1^{\circ}\text{C}$  between any of the hooves of the horse are abnormal and should be examined. In the aforementioned case studies, the temperature difference of the elephant pad or toe affected by the abscess was greater than  $1^{\circ}\text{C}$  when compared to the unaffected tissue, which indicates abnormality in the area according to an investigation led by Turner (1991). Stromberg (1973) found that thermal emissions are found over pathological areas before changes are apparent radiographically or by physical examination. This is true for lesions of the joints, bones, tendonitis, synovitis and degenerative joint disease. Purohit and others (1986) were able to diagnosis a subsolar abscess in a mare using thermography. Thermal images showed an increase temperature over the lateral areas of the heel bulb and a spot of increased heat in the lateral quarter of the sole. Clinical

examination revealed sensitivity to the hoof testers, indicative of a hoof abscess, over the lateral quarter and heel where the thermal images depicted the area of increased heat. These previous studies examining the use of thermography to detect injuries in the horse and the results of thermal imaging of the present case studies in the elephant provide a positive outlook on the accuracy of thermal imaging to detect foot pad abnormalities in the elephant.

### **Summary and Recommendations**

Digital infrared thermography has been used in veterinary medicine with success in diagnosing lameness and joint disease. It appears that infrared thermography would be successful in monitoring the elephant pad but certain guidelines have to be followed to get an accurate depiction of temperature. Regardless of location, gender or species the individual fore leg foot pads did not differ in temperature nor did the hind leg foot pads. This supports previous research by Purohit and others (1985) that there is symmetry in the normal body and this symmetry should be taken into account when evaluating foot gradients of the elephant pad. At the Nashville location the inner ring of the fore foot pad was higher in temperature than the inner ring of the hind foot pad. This pattern was also noted at the Riddle Sanctuary, with the whole fore foot pad being at a greater temperature than the hind foot pad in African elephants, but not in the Asian elephants. The forelimbs support up to 60% of the body weight of the elephant, and the foot pad of the fore foot is larger than that of the hind foot, which could account for the temperature differences. Moreover, the temperature of the African female elephant's foot pads were higher than those of the Asian elephants in all parameters (medial vs. lateral, cranial vs. caudal). These differences could be attributed to the difference in size and weight between species

or due to morphological differences. When implementing thermography for foot pad screening it is important to image all four feet of the elephant and to compare within individual. When performing analysis on the thermal images, shape or circle analysis is appropriate but should be consistent throughout. Within species it does not seem necessary to divide the foot pad into medial, lateral, cranial or caudal but to look at the foot pad as a whole for outlying temperatures. Some differences were noted with the concentric analysis resulting in the inner core of the hind foot pad being lower in temperature than the out ring but this should be accounted for when comparing left and right hind foot pad. The findings in this study do not support comparing pad temperatures among African and Asian elephants when looking for abnormalities; however more animals are needed to confirm this observation.

In previous work it has been indicated that environmental temperature plays a large role in the reliability of the thermography image. Cooler temperatures are ideal, and it has been suggested that the ideal temperature for imaging is in the range of 20°C (Love and Linsted, 1976) but a temperature below 30°C is acceptable (Turner et al, 1986) since heat loss from sweating does not occur below this temperature (William, 1964); although this may vary by species and/or other aspects of the environmental conditions. In regards to using thermography on the elephant pad it would be ideal to have the animal housed inside in a temperature controlled environment ranging from 20°C to 30°C for at least 30 minutes to allow any heat from the outside environment to dissipate and allow for more accurate detection of thermal signatures and/or abnormalities. The heat from the surface of the elephant's enclosure could cause inaccurate thermal patterns of the pad due to heat absorption. This inaccuracy could lead to a wrong diagnosis or change in the

management and care of the elephant's pad when not necessary. The current study at the Memphis Zoo showed a thermal gradient pattern of the elephant pad when the animals were housed indoors compared to outside. When the elephants were housed outside the temperature of the pad mimicked the temperature of the environment masking any abnormalities that could have been present, in addition to having greater fluctuations of temperature due to the change of ambient temperature. To improve accuracy it is important to recognize that each animal possesses their own individual thermal signature, and it has been shown that there is symmetry in the normal body (Purohit et al, 1985). Thus it is recommended to use symmetry in evaluation of the elephant pad within animal. Differences among animals are normal and comparisons between animals could lead to false observations. When evaluating foot gradients of the elephant pad, care should be taken to compare patterns of the fore legs, and patterns of the hind legs within the same animal. Moreover, more frequent thermograms are needed to detect subtle changes. As more information is gathered from each individual animal, such as effect of foot trimming or pad wear, a more accurate depiction of the thermal pattern of the pad can be obtained, in turn leading to earlier detection of abnormalities or infection. Using personnel trained in thermography to acquire and assess elephant pad images also leads to improved accuracy and understanding of the thermal patterns. For thermography to become a popular diagnostic tool in assessing elephant pad health continued research is needed especially in tracking injuries and lameness. Multiple studies have shown thermography is able to detect heat and infection (Purohit et al, 1986; Cockcroft et al, 2000; McCafferty, 2007); however in the elephant it has not been determined how early thermography will be able to detect a manifestation of an abnormality. To gain a better



understanding of what is normal and abnormal in the thermal pattern of the elephant pad frequent images must be acquired. During this time if an abnormality is suspected the elephant should be imaged daily to acquire data pre- and post- condition; something difficult to obtain since the diagnostician is usually called in when a problem already exists. This additional information will provide a better understanding of what is normal and what is a sign of an injury. Early detection of a pad or nail injury could lead to better management and care of the elephant. Moreover thermography could help improve pad management in regards to trimming and how environmental conditions impact the elephant foot. Thermal assessments could lead to better welfare overall for captive elephants and help zoological gardens maintain their high standard of care of these animals.

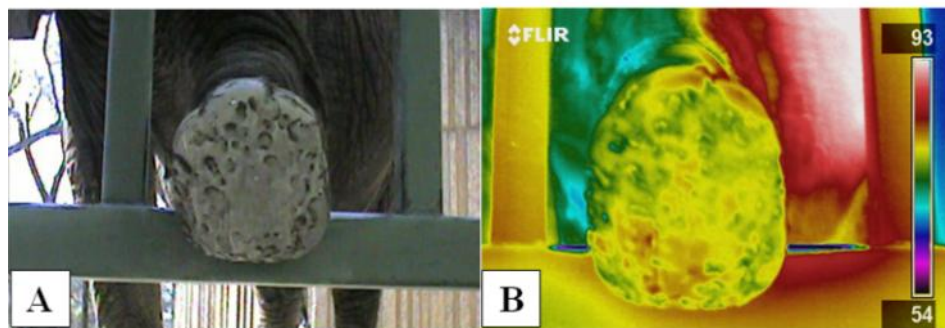


Figure 8 A representative thermal image of the foot pad of an African elephant at the Memphis Zoo acquired with the FLIR P60 real-time camera

Note contours and landscape of the footpad with varying degrees of relief patterns across the footpad (A); some of which are discernable on the thermal profile (B)

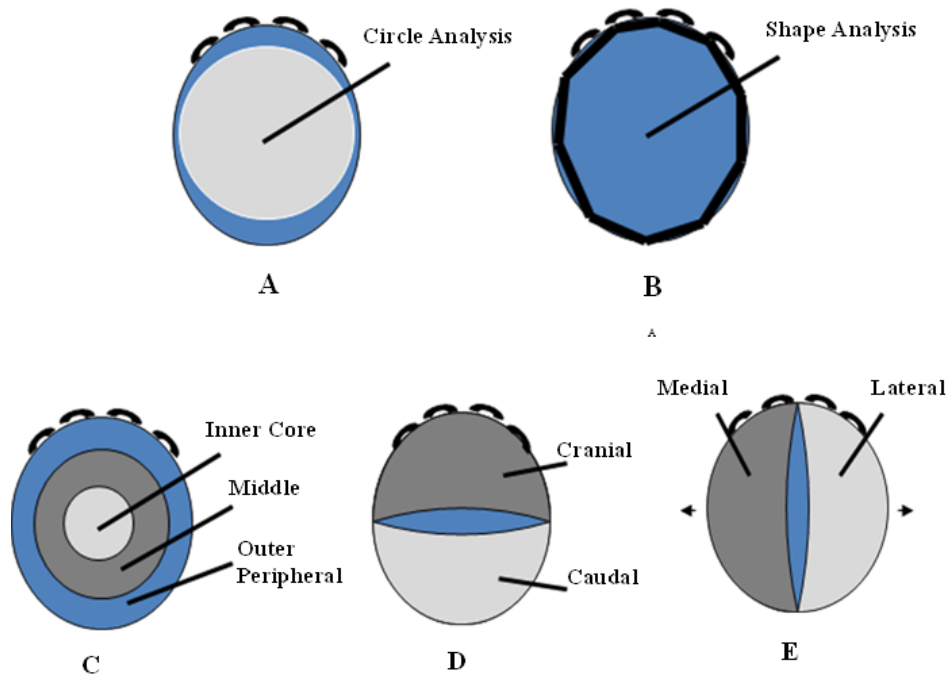


Figure 9 Illustrations depicting the analysis used to determine thermal gradients and patterns of the elephant's foot

Circle (A) and shape (B) analysis are used to determine temperatures of the whole foot, whereas the bottom three pictures depict how the foot pad was divided for analysis of specific areas of the pad; concentric ring analysis (C), cranial vs. caudal (D) and medial vs. lateral (E).

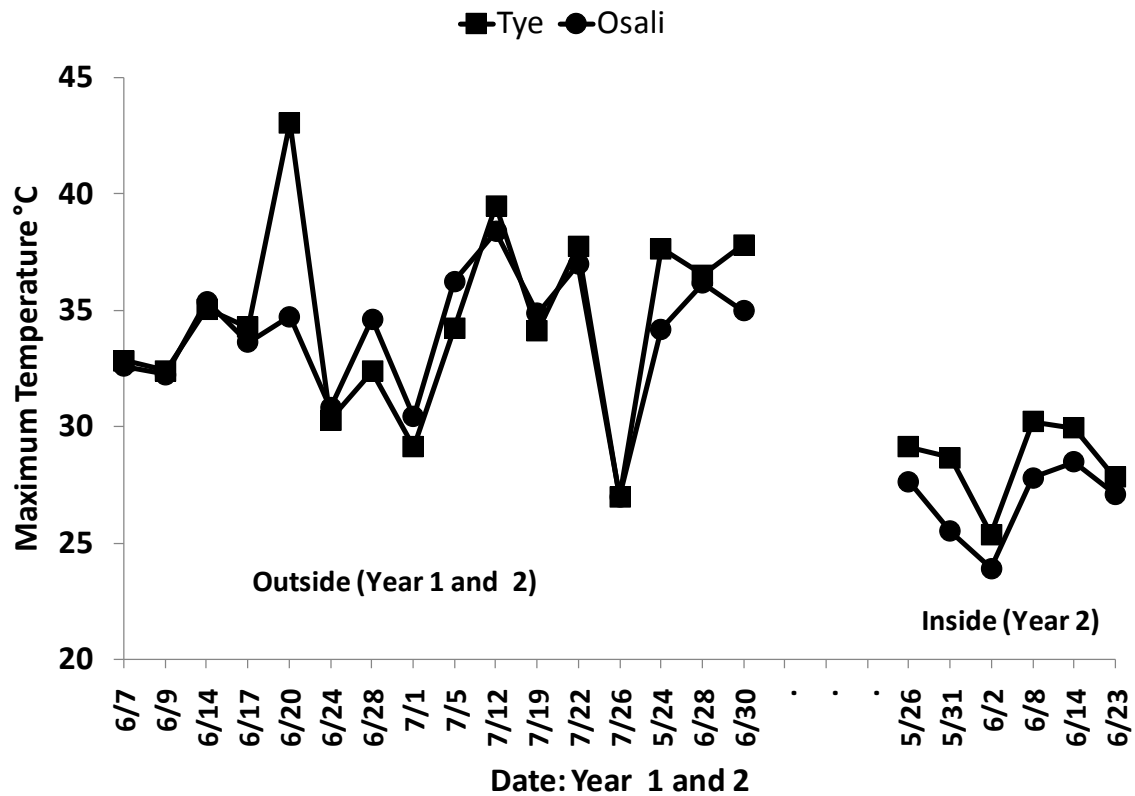


Figure 10 Thermal signatures of two African elephants (Memphis Zoo) housed in different environments (outdoor vs. indoor) over time as determined by digital infrared thermal imaging shape analysis

The outside ambient temperature ranged from 22.5°C to 32.6°C (year 1 and 2 combined). The inside ambient temperature ranged from 15.6°C to 25.6°C.

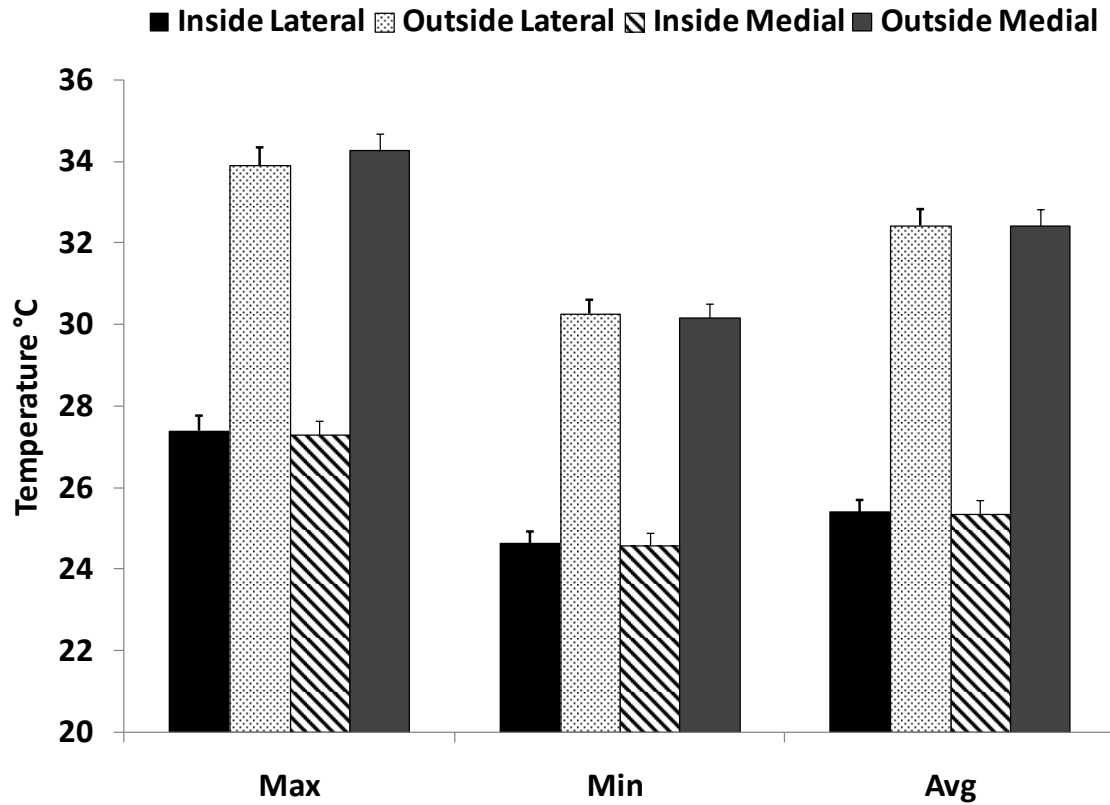


Figure 11 Thermal signatures (Max, Min, Avg) of the medial and lateral aspects of the elephant pad as determined by digital infrared thermal imaging in a temperature controlled environment (inside vs. outside; Memphis Zoo)

These data show (descriptively) that no numerical differences in medial vs. lateral thermal signatures exist; however, when elephants were housed outdoors the temperature of the pad was numerically greater than when housed indoors.

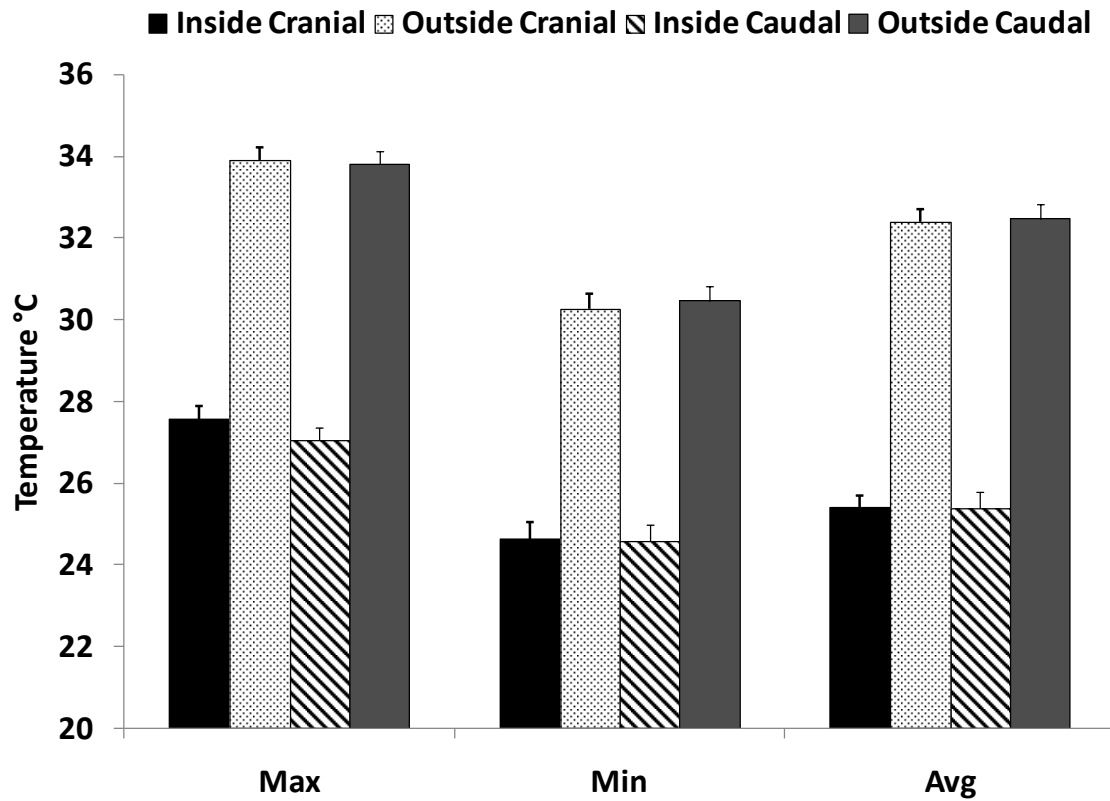


Figure 12 Thermal signatures (Max, Min, Avg) of the cranial and caudal aspects of the elephant pad as determined by digital infrared thermal imaging in a temperature controlled environment (inside vs. outside; Memphis Zoo)

These data show (descriptively) that no numerical differences in cranial vs. caudal thermal signatures exist; however, when elephants were housed outdoors the temperature of the pad was numerically greater than when housed indoors.

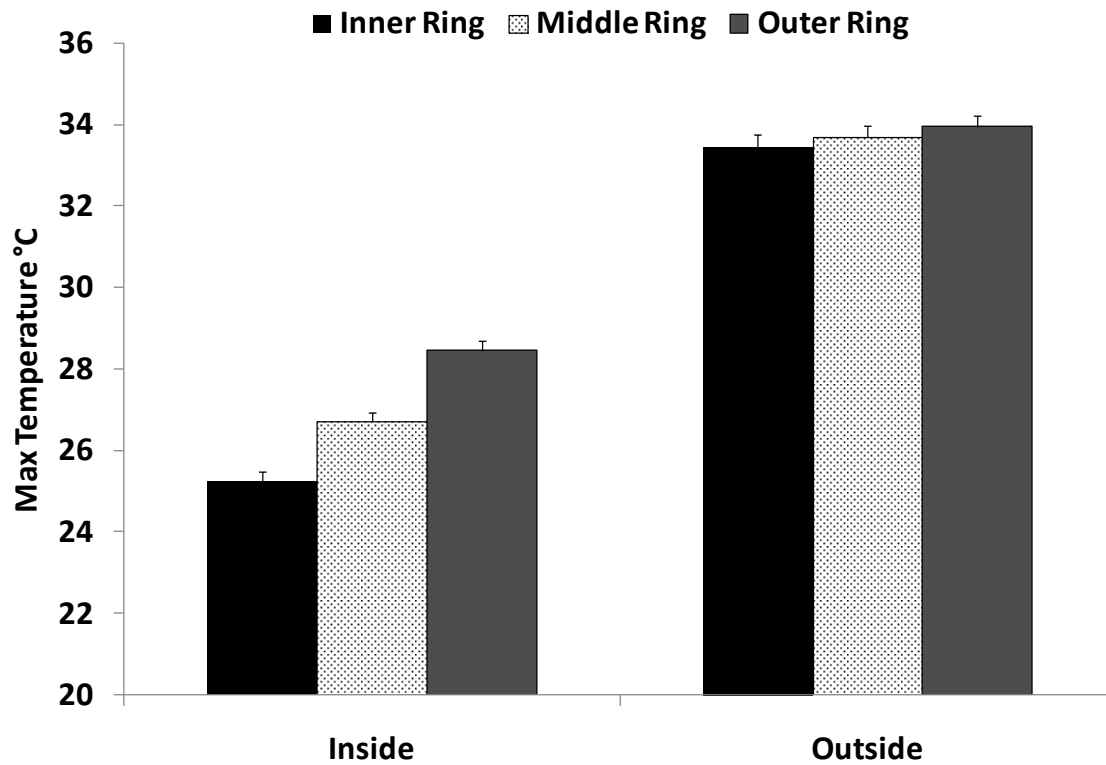


Figure 13 Thermal signatures (Max temp only) of the concentric gradient of the elephant pad as determined by digital infrared thermal imaging in a temperature controlled environment (inside vs. outside; Memphis Zoo)

When elephants were housed outdoors the temperature of the pad was numerically greater than when housed indoors. In addition, when the elephants were housed indoors a greater range of temperatures were noted when comparing the inner and outer concentric gradients

Table 5 Analysis of thermal signatures of the left pads vs. right pads and fore pad vs. hind pad as determined by digital infrared thermal imaging using Circle and Shape analysis (Nashville Zoo; n = 3 female African elephants)

Temperature (°C)				
<b>Circle</b>	<b>Max</b>	<b>Min</b>	<b>Avg</b>	<b>St. Dev.</b>
<b>Side</b>				
<b>Left</b>	<b>27.32 ± 0.55*</b>	<b>24.08 ± 0.18</b>	<b>24.83 ± 0.17</b>	<b>0.42 ± 0.09</b>
<b>Right</b>	<b>27.45 ± 0.18</b>	<b>24.13 ± 0.14</b>	<b>24.93 ± 0.20</b>	<b>0.40 ± 0.44</b>
<b>Limb</b>				
<b>Fore</b>	<b>27.08 ± 0.25</b>	<b>24.22 ± 0.14</b>	<b>25.12 ± 0.16</b>	<b>0.38 ± 0.05</b>
<b>Hind</b>	<b>27.68 ± 0.49</b>	<b>24.00 ± 0.17</b>	<b>24.65 ± 0.15</b>	<b>0.43 ± 0.09</b>
<b>Shape</b>				
<b>Side</b>				
<b>Left</b>	<b>28.48 ± 0.44*</b>	<b>24.05 ± 0.16</b>	<b>25.02 ± 0.14</b>	<b>0.57 ± 0.11</b>
<b>Right</b>	<b>27.62 ± 0.23</b>	<b>24.13 ± 0.14</b>	<b>25.07 ± 0.20</b>	<b>0.48 ± 0.05</b>
<b>Limb</b>				
<b>Fore</b>	<b>27.78 ± 0.16</b>	<b>24.22 ± 0.14</b>	<b>25.23 ± 0.14</b>	<b>0.47 ± 0.05</b>
<b>Hind</b>	<b>28.32 ± 0.51</b>	<b>23.97 ± 0.15</b>	<b>24.85 ± 0.16</b>	<b>0.58 ± 0.11</b>

\*P<0.05

A significant difference was noted when comparing Max temp for the left side in circle vs. shape analysis, with the difference in temperature being 1.16°C.

Table 6 Thermal signatures of the medial, lateral, cranial and caudal aspects of the elephant fore and hind pad as determined by digital infrared thermal imaging (Nashville Zoo; n = 3 female African elephants)

	Medial	Lateral	Cranial (toe)	Caudal (heel)
<b>Max (n = 6)</b>				
<b>Fore</b>	<b>27.47 ± 0.19</b>	<b>27.55 ± 0.11</b>	<b>27.48 ± 0.50</b>	<b>27.45 ± 0.21</b>
<b>Hind</b>	<b>27.63 ± 0.55</b>	<b>28.03 ± 0.35</b>	<b>27.05 ± 0.71</b>	<b>27.63 ± 0.38</b>
<b>Min (n = 6)</b>				
<b>Fore</b>	<b>24.35 ± 0.15</b>	<b>24.28 ± 0.17</b>	<b>24.27 ± 0.15</b>	<b>24.33 ± 0.12</b>
<b>Hind</b>	<b>24.05 ± 0.16</b>	<b>24.03 ± 0.16</b>	<b>24.08 ± 0.17</b>	<b>24.03 ± 0.16</b>
<b>Avg (n = 6)</b>				
<b>Fore</b>	<b>25.32 ± 0.17</b>	<b>25.12 ± 0.13</b>	<b>25.15 ± 0.15</b>	<b>25.22 ± 0.11</b>
<b>Hind</b>	<b>24.80 ± 0.16</b>	<b>24.82 ± 0.15</b>	<b>24.83 ± 0.25</b>	<b>24.80 ± 0.12</b>
<b>St. Dev. (n = 6)</b>				
<b>Fore</b>	<b>0.42 ± 0.06</b>	<b>0.42 ± 0.04</b>	<b>0.42 ± 0.06</b>	<b>0.45 ± 0.06</b>
<b>Hind</b>	<b>0.48 ± 0.10</b>	<b>0.60 ± 0.10</b>	<b>0.42 ± 0.12</b>	<b>0.53 ± 0.12</b>

There were no differences ( $P > 0.10$ ) in Max, Min, Avg or St. Dev. in medial vs. lateral or cranial vs. caudal parameters



Table 7 Thermal signatures of the concentric gradient of the elephant fore and hind pad as determined by digital infrared thermal imaging (Nashville Zoo; n = 3 female African elephants)

	Inner (Core)	Middle	Outer (Peripheral)
<b>Max (n = 6)</b>			
Fore	26.43 ± 0.28	26.92 ± 0.30	27.02 ± 0.11
Hind	25.15 ± 0.20	26.13 ± 0.47	27.50 ± 0.59
<b>Min (n = 6)</b>			
Fore	24.67 ± 0.18	24.42 ± 0.17	24.25 ± 0.15
Hind	24.15 ± 0.18	24.05 ± 0.17	24.05 ± 0.16
<b>Avg (n = 6)</b>			
Fore	25.23 ± 0.20	25.11 ± 0.17	25.12 ± 0.12
Hind	24.53 ± 0.18	24.57 ± 0.16	24.86 ± 0.15
<b>St. Dev. (n = 6)</b>			
Fore	0.28 ± 0.05	0.38 ± 0.07	0.40 ± 0.05
Hind	0.15 ± 0.03	0.25 ± 0.07	0.34 ± 0.14

In Row: \* P < 0.05

In Column: \* P < 0.05

The inner Max temperature of the hind limb was lower (P < 0.05) than the fore limb, however this difference does not continue as the gradient moves to the outer area of the pad. A difference ( P < 0.05) was also noted in the Max temperature of the hind limb when moving from the inner concentric gradient to the outer most gradient

Table 8 Thermal assessments of elephant fore and hind foot pad relative to species and genders determined by digital infrared thermal imaging circle analysis (Riddle Elephant Sanctuary)

<u>African</u>		<u>Asian</u>		
	Male	Female	Male	Female
Number (n)	5	3	1	4
Mean Age (yr)	22.2 ± 0.4	21.3 ± 1.1	16	41.5 ± 2.7
Age Range (yr)	20 – 25	17 – 26	---	31 – 57
Fore – MAX	32.2 ± 0.31 <sup>a</sup>	32.9 ± 0.33 <sup>c</sup>	28.4	31.0 ± 0.42
Hind – MAX	29.7 ± 0.32 <sup>b</sup>	31.2 ± 0.74 <sup>d</sup>	29.1	30.5 ± 0.45
Fore – MIN	28.3 ± 0.52 <sup>c</sup>	29.5 ± 0.44	24.8	26.9 ± 0.34
Hind – MIN	27.3 ± 0.28 <sup>d</sup>	28.5 ± 0.55	25.4	27.1 ± 0.48
Fore – AVG	29.4 ± 0.52	31.3 ± 0.38	25.5	28.5 ± 0.37
Hind – AVG	28.6 ± 0.31	29.9 ± 0.69	26.2	28.7 ± 0.51
Fore – St. Dev.	0.55 ± 0.09 <sup>a</sup>	0.42 ± 0.05	0.40	0.53 ± 0.06 <sup>a</sup>
Hind – St. Dev.	0.34 ± 0.03 <sup>b</sup>	0.37 ± 0.03	0.40	0.38 ± 0.03 <sup>b</sup>

Within column: ab  $P < 0.05$ , cd  $P < 0.05$ ,

Within row: bd  $P < 0.05$

The fore foot had a higher ( $P < 0.05$ ) Max temperature than the hind foot in the African elephants regardless of gender. This pattern continued in the male African elephants with Min temperature of the fore foot being higher than the hind. When comparing male vs. female African elephants the female elephants' hind feet had a higher ( $P < 0.05$ ) temperature than that of the males. There were no differences ( $P > 0.10$ ) in the temperature gradients of the Asian elephants' feet.

Table 9 Thermal signatures of the medial, lateral, cranial and caudal aspects of the elephant pad relative to species and gender as determined by digital infrared thermal imaging (Riddle Elephant Sanctuary)

	<b>African</b>		<b>Asian</b>	
	<b>Male (n = 5)</b>	<b>Female (n = 3)</b>	<b>Male (n = 1)</b>	<b>Female (n = 4)</b>
<b>Max</b>				
Medial	31.21 ± 0.33	32.70 ± 0.35	29.55 ± 0.65	30.95 ± 0.31
Lateral	31.20 ± 0.39	32.84 ± 0.40	29.28 ± 0.82	30.89 ± 0.26
Cranial	31.30 ± 0.36	32.09 ± 0.46	29.68 ± 0.72	31.16 ± 0.42
Caudal	30.84 ± 0.36	32.18 ± 0.42	27.43 ± 0.47	30.08 ± 0.32
<b>Min</b>				
Medial	29.00 ± 0.31	31.28 ± 0.34	25.93 ± 0.25	28.59 ± 0.27
Lateral	27.83 ± 0.30	29.60 ± 0.32	25.08 ± 0.23	26.81 ± 0.25
Cranial	27.78 ± 0.31	29.01 ± 0.35	25.15 ± 0.27	26.65 ± 0.27
Caudal	27.76 ± 0.30	29.14 ± 0.44	25.05 ± 0.21	27.20 ± 0.27
<b>Avg</b>				
Medial	29.00 ± 0.31	31.28 ± 0.34	25.93 ± 0.25	28.59 ± 0.27
Lateral	29.02 ± 0.32	31.30 ± 0.35	25.78 ± 0.29	28.70 ± 0.26
Cranial	29.03 ± 0.32	30.56 ± 0.41	25.98 ± 0.28	28.48 ± 0.29
Caudal	28.92 ± 0.31	30.66 ± 0.43	25.73 ± 0.21	28.48 ± 0.30

There were no differences ( $P > 0.10$ ) between male and female elephants when grouped in the same gender or species. However, the female African elephants had higher ( $P < 0.05$ ) Max, Min, and Avg temperatures in all parameters except for Max temperature of the cranial portion of the pad.

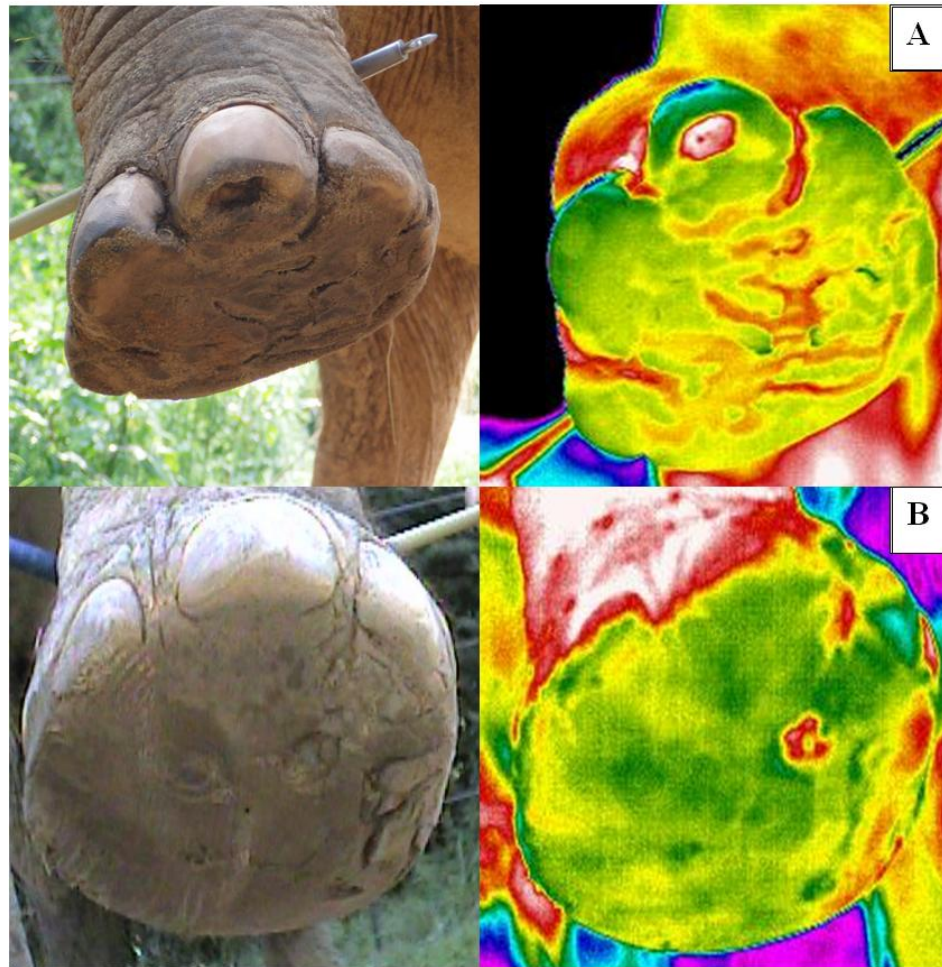


Figure 14 Clinical Case Studies: Panel A depicts a thermal image of a toe abscess in a female Asian elephant. Panel B depicts a thermal image of a foot pad abscess in a male African elephant.

## References

- Adams, T., Heisey, S. R., Smith, M. C., Steinmetz, M. A., Hartman, J. C., & Fry, H. K. (1980). Thermodynamic technique for the quantification of regional blood flow. *American Journal of Physiology - Heart and Circulatory Physiology*, 238(5), H682-H696.
- Alexander, R. M., Maloiy, G. M. O., Hunter, B., Jayes, A. S., & Nturibi, J. (1979). Mechanical stresses in fast locomotion of buffalo (*Syncews coffer*) and elephant (*Loxodonta africana*). *Journal of Zoology*, 189(2), 135-144.
- Benz, A., Zenker, W., Hildebrandt, T. B., Weissengruber, G., Eulenberger, K., & Geyer, H. (2009). Microscopic morphology of the elephant's hoof. *J Zoo Wildl Med*, 40(4), 711-725.
- Bowers, S., Gandy, S., Anderson, B., Ryan, P., & Willard, S. (2009). Assessment of pregnancy in the late-gestation mare using digital infrared thermography. *Theriogenology*, 72(3), 372-377.
- Cockcroft, P. D., Henson, F. M. D., & Parker, C. (2000). Thermography of a septic metatarsophalangeal joint in a heifer. *Veterinary Record*, 146(9), 258-260.
- Coulter, G. H., Senger, P. L., & Bailey, D. R. C. (1988). Relationship of scrotal surface temperature measured by infrared thermography to subcutaneous and deep testicular temperature in the ram. *Journal of Reproduction and Fertility*, 84(2), 417-423.
- Eddy, A. L., Van Hoogmoed, L. M., & Snyder, J. R. (2001). The Role of Thermography in the Management of Equine Lameness. *The Veterinary Journal*, 162(3), 172-181.
- Murray E. Fowler. (2001). Chapter 1: An overview of foot conditions in Asian and African elephants. In *The Elephant's Foot*, (pp3-7). Iowa:Iowa State University Press.
- Gábor, G., Sasser, R. G., Kastelic, J. P., Coulter, G. H., Everson, D. O., Falkay, G., et al. (1998). Endocrine and thermal responses to GnRH treatment and prediction of sperm output and viability in Holstein-Friesian Breeding Bulls. *Theriogenology*, 50(2), 177-183.
- Hilsberg, S., Eulenberger K, Zahorszki F. Application of infrared thermography in pregnancy diagnosis in giraffes. Jahrestagung Physiologie und Pathologie der Fortpflanzung, Veterinar-Hummanmedizinische Gemeinschaftstagung, Universitat Leipzig, Proceedings – February 14-15. 2002:W2.2.

- Kastelic, J. P., Cook, R. B., Coulter, G. H., & Saacke, R. G. (1996). Ejaculation increases scrotal surface temperature in bulls with intact epididymides. *Theriogenology*, 46(5), 889-892.
- Kastelic, J. P., Coulter, G. H., & Cook, R. B. (1995). Scrotal surface, subcutaneous, intratesticular, and intraepididymal temperatures in bulls. *Theriogenology*, 44(1), 147-152.
- Love, T. J. (1980). Thermography as an indicator of blood perfusion. *Annals of the New York Academy of Sciences*, 335(1), 429-437.
- McCafferty, D. J. (2007). The value of infrared thermography for research on mammals: previous applications and future directions. *Mammal Review*, 37(3), 207-223.
- Purohit, R. C., Hudson, R. S., Riddell, M. G., Carson, R. L., Wolfe, D. F., & Walker, D. F. (1985). Thermography of the bovine scrotum. *American journal of veterinary research*, 46(11), 2388-2392.
- Purohit, R. C., & McCoy, M. D. (1980b). Thermography in the diagnosis of inflammatory processes in the horse. *Am J Vet Res*, 41(8), 1167-1174.
- Ramsay C. Edward and Robert W. Henry. (2001). Chapter 2: Anatomy of the Elephant Foot. In *The Elephant's Foot*, (pp9-12). Iowa:Iowa State University Press.
- Roocroft A. and J. Oosterhuis. (2001). Chapter 5: Foot Care for Captive Elephants. In *The Elephant's Foot*, (pp21-52). Iowa:Iowa State University Press.
- Schmidt, S. J., Bowers, S. D., Graves, K. B., Carroll, R., White, J., & Willard, S. T. (2003). Use of digital infrared thermography to assess thermal temperature gradients and pathologies of the bovine claw. *J. Dairy Sci*, 86(SUPPL. 1), 322.
- Schwartzkopf-Genswein, K. S., & Stookey, J. M. (1997). The use of infrared thermography to assess inflammation associated with hot-iron and freeze branding in cattle. *Canadian Journal of Animal Science*, 77(4), 577-583.
- Stromberg, B. (1973). Morphologic, Thermographic and <sup>133</sup>Xe Clearance Studies on Normal and Diseased Superficial Digital Flexor Tendons in Race Horses. *Equine Veterinary Journal*, 5(4), 156-161.
- Turner, T. A. (1991). Thermography as an aid to the clinical lameness evaluation. *The Veterinary clinics of North America. Equine practice*, 7(2), 311-338.
- Turner, T. A. (1998). Use of thermography in lameness evaluation. *Proceedings of the ... annual convention - American Association of Equine Practitioners.*, 44, 224-226.
- Turner, T. A., Purohit, R. C., & Fessler, J. F. (1986). Thermography: A review in equine medicine. *Comp. Cont. Educ. Pract. Vet.*, 8(11), 855-861.

- White MB, Jones M, Schmidt S and Willard S. Use of digital infrared thermal imaging (DITI) for monitoring environmental physiology in dairy cattle. *J Anim Sci* 2006;84 (Suppl 1):212.
- Weissengruber, G. E., Egger, G. F., Hutchinson, J. R., Groenewald, H. B., Elsässer, L., Famini, D., et al. (2006). The structure of the cushions in the feet of African elephants (*Loxodonta africana*). *Journal of Anatomy*, 209(6), 781-792.
- Williams, K. L. (1964). Infrared thermometry as a tool in medical research. *Annals of the New York Academy of Sciences*, 121(1), 99-112.
- Winsor, T. (1971). Vascular aspects of thermography. *Journal of Cardiovascular Surgery*, 12(5), 379-388.

## CHAPTER VI

### GENERAL CONCLUSION

These studies suggest that DITI may have value in conducting research with domestic and non-domestic species that are not able to be restrained. It is apparent that environmental conditions such as temperature and air flow can have an impact on the reliability of thermal images when conducted in an uncontrolled environment which is usually the case in the captive management of livestock and wildlife. Additional obstacles for obtaining accurate thermal images also relate to the animals phenotypic or morphological differences such as length or pattern of hair coat, location of internal structures and just normal variation within animal. These studies will help to elucidate the abilities of DITI under certain management and production environments and provide a better understanding of what is normal and abnormal in thermal patterns of some wildlife species.