

5-4-2018

Hematological and Histopathological Changes associated with Chronic Diazinon Exposure in Alligator gar, *Atractosteus spatula*

Ahmad Salem Omar Ali

Follow this and additional works at: <https://scholarsjunction.msstate.edu/td>

Recommended Citation

Omar Ali, Ahmad Salem, "Hematological and Histopathological Changes associated with Chronic Diazinon Exposure in Alligator gar, *Atractosteus spatula*" (2018). *Theses and Dissertations*. 2480.
<https://scholarsjunction.msstate.edu/td/2480>

This Dissertation - Open Access is brought to you for free and open access by the Theses and Dissertations at Scholars Junction. It has been accepted for inclusion in Theses and Dissertations by an authorized administrator of Scholars Junction. For more information, please contact scholcomm@msstate.libanswers.com.

Hematological and histopathological changes associated with chronic diazinon exposure
in alligator gar, *Atractosteus spatula*

By

Ahmad Salem Omar Ali

A Dissertation
Submitted to the Faculty of
Mississippi State University
in Partial Fulfillment of the Requirements
for the Degree of Doctor of Philosophy
in Veterinary Medical Science
in the Department of Basic Science, College of Veterinary Medicine

Mississippi State, Mississippi

May 2018

Copyright by

Ahmad Salem Omar Ali

2018

Hematological and histopathological changes associated with chronic diazinon exposure
in alligator gar, *Atractosteus spatula*

By

Ahmad Salem Omar Ali

Approved:

Lora Petrie-Hanson
(Major Professor)

Russell Carr
(Committee Member)

Wes A. Baumgartner
(Committee Member)

Peter J. Allen
(Committee Member)

Larry Hanson
(Graduate Coordinator)

Kent H. Hoblet
Dean
College of Veterinary Medicine

Name: Ahmad Salem Omar Ali

Date of Degree: May 4, 2018

Institution: Mississippi State University

Major Field: Veterinary Medical Science

Major Professor: Lora Petrie-Hanson

Title of Study: Hematological and histopathological changes associated with chronic diazinon exposure in alligator gar, *Atractosteus spatula*

Pages in Study 96

Candidate for Degree of Doctor of Philosophy

Extensive use of the organophosphate diazinon has led to its accumulation in aquatic environments and negative effects on fish health. Most studies focus on the effects of short term exposure to high levels of organophosphate pesticides. This research was conducted to assess the effect of chronic sub-lethal exposure to 0, 0.01, and 0.1 mg/L diazinon for 15 and 30 days on blood parameters and histopathological damage in alligator gar, *Atractosteus spatula*. Fish exposed to either concentration were motionless, produced excess mucous, had lighter skin color, and had skin lesions. Blood indices of red blood cells, leukocytes and hematocrit values significantly decreased but there was no significant change in mean cell volume. Hemoglobin values significantly increased in fish exposed to the low dose for 15 days, but significantly decreased for the other exposure doses and times. On the contrary, mean corpuscular hemoglobin, and mean corpuscular hemoglobin concentration values significantly increased in fish exposed to both concentrations and duration times. Leukocyte differentials showed significant decreases in lymphocytes with significant increases of monocytes in fish exposed to the high dose in both exposure times. The most frequent biomarker for exposure to

organophosphate pesticides is the inhibition of cholinesterase (ChE). Diazinon significantly reduced plasma ChE activity in a dose-dependent manner, with 62% and 72% in the low and high concentrations for 30 days, respectively. Plasma ChE could be determined from peripheral blood samples and did not require sacrifice of the fish. Fish exposed to either diazinon concentration or duration time developed histopathological changes in skin, gills, liver, and kidney tissues. The skin lesions were on the head and body, and progressed into deep ulcerations. The histopathological changes in the liver included hepatic vacuoles, swollen hepatocytes, steatosis, aggregation of macrophages, necrosis, and hepatic fibrosis. Also, exposed fish demonstrated vacuolar degeneration in the hematopoietic tissues of the kidney. Gills showed epithelial hyperplasia in the secondary lamellae. In conclusion, long term exposure to sub-lethal concentrations of diazinon induced significant changes in hematological indices and histopathological alteration in various tissues. Plasma ChE can be used to monitor diazinon exposure in wild gar populations.

DEDICATION

I am dedicating this dissertation to my loving parents “Dr. Salem Al-Ferjani and Mrs. Faiza” for their love, prayers, caring, support, and sacrifices for educating and preparing me for my future. I also dedicate this dissertation to my loving and supportive wife ‘Amel’ and my three wonderful children “Abdelmalek, Zakaria, Alaa” for their love, understanding, prayers, support, and encouragement during the challenges of graduate school and life. Also I would like this opportunity to thank to my brothers and sisters for their support and prayers. I am truly thankful for having you all in my life.

ACKNOWLEDGEMENTS

At the end of my dissertation I would like to thank all those people who made this dissertation possible and an unforgettable experience for me.

First, I would like to express my deep and sincere gratitude to my advisor “Dr. Lora Petrie-Hanson” who offered her continuous advice, support, guidance, and encouragement throughout the course of this research. I appreciate all the faith that she has put in me especially during the many trials and tribulations of scientific research. I am so grateful for all the knowledge she has shared with me.

Also, I would like to express my deepest appreciation to my committee members, Dr. Russell Carr, Dr. Wes A. Baumgartner, and Dr. Peter J. Allen, for their direction, and invaluable advice along this research.

I would like to acknowledge and thank my wonderful lab-mates, Beth Peterman and Preeti Muire for the help, support, and encouragement. I am lucky to have made such great friends.

TABLE OF CONTENTS

DEDICATION	ii
ACKNOWLEDGEMENTS	iii
LIST OF TABLES	vii
LIST OF FIGURES	viii
CHAPTER	
I. INTRODUCTION	1
1.1 Alligator gar life history	1
1.2 What is diazinon?	3
1.3 What is the air breathing organ in fish?.....	4
1.4 Significance of this research.....	5
1.5 The objectives of this study are:	6
II. LITERATURE REVIEW	8
III. EFFECTS OF LONG TERM EXPOSURE TO SUB-LETHAL CONCENTRATIONS OF DIAZINON ON BLOOD PARAMETERS OF ALLIGATOR GAR (<i>ATRACTOSTEUS SPATULA</i>)	12
3.1 Introduction	12
3.2 Materials and methods.....	13
3.2.1 Chemical and experimental animals.....	13
3.2.2 Experimental water and stock solution.....	14
3.2.3 Chronic exposure.....	15
3.2.4 Blood sampling.....	15
3.2.5 Statistical analysis	16
3.3 Results	17
3.3.1 General observations	17
3.3.2 Hematological analysis after 15 days exposure to 0, 0.01 and 0.1 mg/L diazinon.....	18
3.3.3 Hematological analysis after 30 days exposure to 0, 0.01 and 0.1 mg/L diazinon.....	21
3.4 Discussion.....	23
3.5 Conclusion.....	25

IV.	HISTOPATHOLOGICAL CHANGES INDUCED BY CHRONIC SUB-LETHAL CONCENTRATIONS OF DIAZINON IN ALLIGATOR GAR (<i>TRACTOSTEUS SPATULA</i>)	26
4.1	Introduction	26
4.2	Materials and methods.....	27
4.2.1	Chemicals and experimental animals	27
4.2.2	Experimental water and stock solution.....	27
4.2.3	Chronic exposure.....	28
4.2.4	Tissue sampling.....	29
4.3	Results	29
4.3.1	General observations	29
4.3.2	Histopathological results after 15 days diazinon exposure	32
4.3.3	Histopathological results after 30 days diazinon exposure	35
4.4	Discussion.....	40
4.5	Conclusion.....	43
V.	AN INVESTIGATION OF PLASMA ACETYLCHOLINESTRASE ACTIVITY IN ALLIGATOR GAR (<i>TRACTOSTEUS SPATULA</i>) FOLLOWING CHRONIC EXPOSURE TO DIAZINON FOR 30 DAYS.....	44
5.1	Introduction	44
5.2	Materials and methods.....	45
5.2.1	Chemicals and experimental animals	45
5.2.2	Experimental water and stock solution.....	45
5.2.3	Chronic exposure.....	46
5.2.4	Blood sampling and biochemical assay.....	47
5.2.5	Statistical methods.....	48
5.3	Results	48
5.4	Discussion.....	50
5.5	Conclusion.....	51
VI.	FINE STRUCTURE OF THE GAS BLADDER OF ALLIGATOR GAR, <i>TRACTOSTEUS SPATULA</i>	52
6.1	Introduction	52
6.2	Materials and methods.....	53
6.2.1	Animals.....	53
6.2.2	Light microscope	54
6.2.3	Transmission electron microscopy (TEM).....	54
6.3	Results	55
6.3.1	Gross morphology	55
6.3.2	Microscopic morphology and ultrastructure	60
6.4	Discussion.....	68
6.5	Conclusion.....	72

VII.	CONCLUSION	73
VIII.	REFERENCES	77

LIST OF TABLES

3.1	Clinical observations of alligator gar chronically exposed to two levels of diazinon for 15 days and 30 days.....	18
3.2	Mean values of hematological analyses after 15 days continuous diazinon exposure.....	18
3.3	Mean values of hematological analyses after 30 days continuous diazinon exposure.....	21
4.1	Clinical signs of control and exposed alligator gar after 15 days and 30 days.....	30
4.2	MMCs number and size in control and exposed alligator gar for 15 days and 30 days.....	33
4.3	Number of alligator gar demonstrating lesions following diazinon exposure.....	40
5.1	Plasma AChE activities in control and exposed fish.....	49

LIST OF FIGURES

3.1	Differential counts of alligator gar peripheral blood leukocytes after diazinon exposure for 15 days.	20
3.2	Differential counts of alligator gar peripheral blood leukocytes after 30 days of diazinon exposure.	22
4.1	Alligator gar gross pictures for skin and liver tissues.	31
4.2	Alligator gar skin, liver, and kidney tissues from control, and fish exposed to 0.01 and 0.1 mg/L diazinon for 15 days.	34
4.3	Alligator gar skin and gill tissues from control fish, and fish exposed to 0.01, and 0.1 mg/L diazinon for 30 days.	37
4.4	Alligator gar liver and kidney tissues from control, fish exposed to 0.01, and 0.1 mg/L diazinon for 30 days.	39
5.1	Effect of diazinon on plasma AChE activity (nmoles min ⁻¹ mg protein ⁻¹) in blood plasma of alligator gar exposed daily to 0 (control), 0.01, and 0.1 mg/L diazinon for 30 days.	49
6.1	Gross pictures for alligator gar air breathing organ.	57
6.2	Alligator gar, Microscopic pictures for the pharyngeo-esophageal duct.	59
6.3	Multiple views of alligator gar air breathing organ with different stains.	63
6.4	Alligator gar; transmission electron micrographs of the gas bladder.	65
6.5	Alligator gar; transmission electron microscope (TEM) micrographs of the ABO.	67

CHAPTER I

INTRODUCTION

1.1 Alligator gar life history

Alligator gar, *Atractosteus spatula* are elongated, slender, robust, primitive fish from the family of Lepisosteids [1]. Fish in the family Lepisosteidae are holosteans and are placed phylogenetically between the chondrosteans and the teleosts [2]. The genus *Atractosteus* includes the species *A. tristoechus*, *A. tropicus*, and *A. spatula*, while the genus *Lepisosteus* includes *L. oculatus*, *L. platostomus*, *L. osseous*, and *L. platyrhincus*. *Atractosteus spatula* was included in *Lepisosteus* until 1976, but is distinguishable from this genus by its large body size and short snout. Alligator gar are descendants of ancient fish that arose around 180 million years ago [3, 4]. Gars in *Atractosteus* and *Lepisosteus* are distinguished from other fish by having nasal openings and sacs located at the end of the snout. Also, the upper and bottom jaws have different sizes of sharp needlelike teeth, and the upper jaw has two rows of enlarged teeth [1]. The scientific name *Atractosteus spatula* describes the shape of the body; Atract means spindle, osteus means bony, and spatula describes the snout shape [5]. Alligator gars live in large rivers, backwaters, oxbow lakes, and brackish water estuaries [5]

Gar skin color is grayish to dark green dorsally and white ventrally. The skin is covered with flexible armor consisting of diamond-shaped ganoid scales covering the entire body. The scales are made of a thin layer of ganoine and are bony for body

protection [5, 6]. Adult fish will attack and eat any live fish size of a proper size. The maximum size reported for this fish was 302 pounds and 9 feet long. Females live longer so they get larger in size than males. The spawning season for gar is late spring and summer in shallow vegetated areas, and the eggs are very toxic [1, 5]. Alligator gar are widely distributed along the lakes and rivers of Missouri, Ohio, Mississippi Rivers, the Gulf Coast of Mexico, Florida, and coastal waters of Nicaragua and Cuba [4, 5, 7, 8]. In overall the primitive fishes including alligator gar, have not been well studied [9]. Surveys suggest that alligator gar populations have declined within the past 50 years [5]. Alligator gar are considered endangered in Tennessee, Arkansas, Missouri, Kentucky, and Illinois [5, 10-14]. Alligator gar populations could also be declining in Gulf Coastal areas [5].

Recently alligator gar have been proposed to be used as a biological weapon against Asian carp. Efforts are now focused on how to produce alligator gar and reintroduce them to areas invaded with Asian carp [15, 16]. Asian carp were introduced into the United States in the 1970s and are now found in the Mississippi River and its tributaries. The bighead (*Hypophthalmichthys nobilis*), black (*Mylopharyngodon piceus*), grass (*Ctenopharyngodon idella*), and silver carp (*Hypophthalmichthys molitrix*) are species of particular concern because they threaten native fish populations. Many efforts have been conducted to try and contain Asian carp populations from growing, including catching, netting, and using electric barriers. The Great Lakes Restoration Initiative provides \$300 million annually to these efforts, but they have not been successful.

Human activities have led to the presence of different types of pollutants in aquatic environments, including heavy metals, pesticides, insecticides, and crude oil [17-

23]. Pesticides are used ubiquitously; not only in agricultural and veterinary fields, but in homes, parks, schools, and alongside roads. The uses of pesticides are to manage pest problems and their use has become common practice around the world. However, the extensive use and/ or the misuse of pesticides have significant impacts on non-target organisms such as mammals, birds, and fish causing direct effect on the immune system, endocrine system, and on the nervous system [18, 24-31].

In general, pesticides reach the environment either by a direct application or by indirect application such as storm runoff, farms, washed into rivers, lakes by rain events, or direct soil erosion [32, 33]. Today, insecticides and pesticides are the main causes of toxicity in fish, and it is estimated that only 0.1% of applied pesticides reach their target pests and the rest spread throughout the environment [34]. Many studies showed that water quality is affected by pollutions, and chemicals are one of the major pollutants in the aquatic environment [17-23]. These studies also revealed that pollutants such as crude oil, insecticides, and pesticides have harmful impacts on fish health. In addition, pesticides cause impairment in blood forming organs leading to impairment of the immune system of exposed fish [17-23].

1.2 What is diazinon?

Diazinon (*O,O*-Diethyl *O*-[4-methyl-6-(propan-2-yl)pyrimidin-2-yl]) is a neurotoxic agent considered to be one of the most toxic chemicals to fish [35-39]. It is the most commonly used organophosphate pesticide in homes, gardens, and agriculture.

Diazinon is also used as an ecto-parasiticide formula for small and large animals [36-38, 40, 41]. Diazinon is a synthetic chemical. It does not occur naturally in the environment, and it was first introduced in 1954 as a replacement for Dichloro-diphenyl-

trichloroethane (DDT). It was first registered in the U.S.A in 1956 [41-43]. Pure diazinon is colorless in the oily form, but in concentration of 80% it appears to be a dark-brown liquid [44].

Diazinon in the environment can last for weeks and even for months depending on the environment and the weather. The solubility of this chemical is around 40 mg/L at 20 °C, and it dissolves very easy in alcohols such as ethanol and acetone [45]. In freshwater, diazinon is moderately adsorbed by sediment and is soluble in the water column. It has a half-life of up to 14 days and even greater persistence in brackish water [46].

1.3 What is the air breathing organ in fish?

Air breathing fish is a term used to describe fishes that have the ability to breathe using gills in water, and can also breathe in aerial environments using a unique gas exchange surface for respiration. This gas exchange surface is a gas bladder or air breathing organ (ABO) [2, 47]. Air breathing fish are bimodal breathers, especially in hypoxic environments [48]. Obligatory air breathing fishes use only aerial gas exchange [47, 49-52]. Bimodal and obligatory air breathers can utilize branchial and ABO respiration simultaneously [2]. Air breathing fishes occur in fresh and salt water [2]. It is suggested that the lungs evolved in vertebrates as a result of hypoxic environments. Fish ABO have some common histological features of amphibian lungs [53-55]. Also, fishes under these two types require more than one respiratory surface actively participates at the same time [2]. The primary function of the teleost gas bladder is buoyancy [56].

There are two types of gas bladders in water breathing fishes: physostomous and physoclistic[47]. In both types, the gas bladder originates as a dorsal diverticulum of the

esophagus. The pneumatic duct lies between the esophagus and the gas bladder, and allows air to enter the gas bladder for initial inflation. The pneumatic duct remains in the physostomic gas bladder, and is observed in goldfish (*Carassius auratus*), Atlantic tarpon (*Megalops atlanticus*), lungfish (Dipnoi), and *Arapaima* (*Arapaima gigas*) [2, 47, 57-60]. The pneumatic duct degenerates soon after initial gas bladder inflation in the physoclistic gas bladder [47].

Fish gills have large surface areas and they are in direct contact with the environment. They have important functions including respiration, ion regulation, excretion of nitrogenous waste, and gas exchange surface area [56, 61-63]. Gill surface area and lamellar thickness are reduced in air breathing fishes in comparison to water breathing fishes, but still function for both O₂ uptake and as the primary location for CO₂ excretion [64-67].

1.4 Significance of this research

More than 500 million kg of different types of insecticides are used every year in the United States in agricultural and urban settings [68], and large amounts of these pesticides are washed into adjacent watersheds and affect the resident aquatic biota [69]. Many studies have investigated the effects of different aquatic pollutants on fish, but few have included alligator gar [22, 23, 70]. These fish are listed as endangered in several states. Alligator gar populations have declined as a result of overfishing, habitat loss, and pollution [70]. Among these factors, pollution is a rather unexplored factor that may have a great influence on gar's health, and no study has been conducted to investigate the effect of diazinon on their immune cells and tissues. The potential harm to fish includes compromising the immune system and concentrating in fish tissues resulting in gross and

microscopic lesions that affect fish health [17, 19-21, 71]. As a result, fish will be more susceptible to diseases.

The toxicity of diazinon differs between fish species, due to different concentrations of metabolic enzymes in the liver tissue. These enzymes can make fish more sensitive or less sensitive to diazinon depending on the levels of these metabolic detoxification enzymes [72-75]. A recent biomarker study reported that 96 h exposure to 0.304 mg/L diazinon led to decrease acetylcholinesterase activities, butyrylcholinesterase, carboxylesterase, and glutathione s-transferase, but increased activities of superoxide dismutase and alkaline and acid phosphatases in the liver of alligator gar [70]. It is important to determine the negative impact of this chemical on the health status of gar, so we can protect them from being harmed in their natural environments and increase their numbers. This research will be adding new information to the database of alligator gar.

1.5 The objectives of this study are:

- 1) To determine the effects of 15 and 30 day exposures to sub-lethal concentrations of diazinon on blood parameters in alligator gar.
- 2) To evaluate the toxic effects of 15 and 30 day exposures to sub-lethal concentrations of diazinon on tissue histology of alligator gar.
- 3) To determine the possibility of measuring AChE in blood plasma, and also to assess the effects of two different concentrations of diazinon on plasma AChE activity in alligator gar for 30 days.

- 4) To histologically describe the alligator gar air breathing organ using light and electron microscopy.

CHAPTER II

LITERATURE REVIEW

Organophosphate chemicals including diazinon are environmental contaminants that induce immunosuppression, and they have accounted for the deaths of thousands of birds and fish over the last two decades [18, 25, 76, 77]. All organophosphate pesticides are known to inhibit the action of acetylcholinesterase (AChE), and have adverse effects on different body organs [78-80]. Diazinon is persistent in aquatic environments and can be repeatedly introduced into the same areas [76, 81-83]. In major U.S.A. rivers, the levels of diazinon were between 0.04 to 0.32 mg/L [84]. Diazinon residues can be detected for four months after application to rice fields [85, 86]. The U.S. geological survey and the U.S. Environmental protection agency (USEPA) reported that diazinon is one of five pesticides that has the ability to concentrate in fog droplets, and diazinon was the highest concentrated pesticide found in rain samples [87, 88].

Chemical pollutants enter fish through one of three routes; gills, alimentary duct, or skin [89, 90]. In the liver, diazinon is metabolized to diazoxon by the cytochrome P450 enzyme. Diazoxon is more toxic than diazinon. Diazoxon is further metabolized by A-esterase enzyme, and is excreted through urine and feces [72, 91-93]. Acetylcholine is a neurotransmitter that passes brain signals between neurons and neurons to the neuromuscular. Acetylcholinesterase (AChE) is the enzyme that is responsible for inhibiting acetylcholine, and diazinon and its metabolites block acetylcholinesterase

(AChE) activity [40, 94-96]. In case of low levels of AChE, acetylcholine accumulates in cholinergic synapses and leads to hyper cholinergic activity [97, 98]. As a results of AChE inhibition, fish will show changes in feeding, erratic swimming, convulsions, increase in superficial respiratory rhythm, shaking palsy, spasms, and muscular weakness [99-102].

Diazinon use in gardening could contribute to an increased incidence of childhood cancers [103]. Farmers who used organophosphate insecticides, including diazinon, had higher rates of non-Hodgkin's lymphoma compared to non-farmers [104, 105]. Exposure to high levels of diazinon can cause nausea, vomiting, abdominal cramps, diarrhea, slow pulse, pinpoint pupils, difficulty breathing, and possible coma [106].

In fish, aquatic toxic agents significantly affect hematological parameters leading to physiological disturbances [107], and can negatively impact the fish immune system [108]. Hematological parameters in fish are good indicators of external stressors [101, 109-112]. Leukocytopenia is a low level of lymphocytes in blood, and it can be induced by many types of stresses [113]. Long term exposure to sub-lethal doses of toxicant can significantly affect growth rate, fecundity, and immune responses, increasing fish susceptibility to infectious diseases [114, 115]. Alligator gar, killifish and sea trout exposed to petroleum pollutants had significantly decreased lymphocyte counts [22, 23, 113].

Short term diazinon exposure can significantly affect biochemical and blood parameters in fish [100, 115-117]. Long term exposure to diazinon significantly affected blood parameters, and caused skin discoloration [102, 112, 118]. All these studies concluded that diazinon caused damage to blood forming organs.

Alligator gar exposed to pesticides demonstrated altered distribution of immune system cells and histopathological lesions in multiple tissues, and increased risk of infectious diseases [22, 23, 30, 119]. Chronic health effects involving multiple organ systems can arise following exposure to diazinon. Fish exposed to diazinon also developed ovarian necrosis, changes in the ovaries and testes and altered hormone levels [18, 120]. In addition, histopathological damages in the tissues of liver, kidney, gills, and brain were reported after chronic exposure to diazinon [101, 121-124].

Another indicator of the health status of fish and a biomarker for environmental contamination are melanomacrophages. These cells are macrophages that contain pigments such as lipofuscin, melanin, and hemosiderin. These cells are found in liver, spleen, and kidney tissues [125-127], and frequently aggregate to form melanomacrophage centers (MMC). The size and number of these cells significantly increase during detoxification processes when fish are being exposed to pollutants [23, 128-132].

Gars breathe using their gills, and also use their ABO /gas bladder for aerial gas exchange. They swim to the surface of the water to gulp air. This allows them to reside in hypoxic water for extended periods of time [2]. The length of time that air breathing fishes can breathe air varies from 3 minutes in *Lepisosteus osseus* to 8.5 minutes in *Amia calva* [48, 133].

The gas bladder is described as an unpaired highly vascularized sac structure that arises from the posterior side of the pharynx, and is located dorsally to the body lumen [2, 4, 134]. The ABO and amphibian lungs have similar histological features [53, 54]. Although the fish ABO and amphibian lungs function similarly, these two organs develop ontogenetically from different tissues [134]. Embryologically, the gas bladder originates

from the pharyngeo-esophageal area, as a dorsal diverticulum of the esophagus, and it is joined to the esophagus by the pneumatic duct [135, 136]. This duct remains in fish with a physostomous air bladder, but it is absent in adult fish with a physoclastic gas bladder [137].

There is a controversy surrounding the presence or absence of the pneumatic duct in lepisosteid fish (reviewed in [138]). It is attached to the body wall by dorsal retractors, allowing for contraction. The gas bladder itself contains numerous septa that provide a large vascularized area for gas exchange [139]. Most studies on the physiology of gars have utilized *Lepisosteus* species [2, 139]. Such studies confirm the function of the gas bladder in oxygen uptake and carbon dioxide release, and its necessity when fish are in hypoxic waters [2, 48, 67]. Similar functions, and presumably physiology, are seen in the alligator gar ABO [2, 140].

CHAPTER III
EFFECTS OF LONG TERM EXPOSURE TO SUB-LETHAL CONCENTRATIONS
OF DIAZINON ON BLOOD PARAMETERS OF ALLIGATOR GAR
(*ATRACTOSTEUS SPATULA*)

3.1 Introduction

The blood in the circulatory system is composed of red and white blood cells that are suspended in plasma. These cells deliver nutrition and oxygen and remove metabolic wastes. Erythrocytes are red blood cells (RBCs), and leukocytes are white blood cells (WBCs) [47, 56]. In fish, these cells are produced in hematopoietic tissues located in kidney and spleen tissues [93]. The main types of WBCs are lymphocytes, monocytes, and granulocytes. These cells are presented in specific proportions and locations in tissues based on the condition of the fish, and they are responsible for the initial defense line against any foreign materials or external stressors [141, 142].

RBCs are more abundant than WBCs, and the main function of RBCs is to carry oxygen from the gills to the tissues. These cells also pick up tissue carbon dioxide (CO₂) to be excreted at the gills. Fish RBCs are nucleated like avian and reptiles and exhibit a wide size range [47, 56]. RBC numbers also vary, depending on fish species. For example, teleosts have smaller RBCs in size and higher numbers of RBCs than in elasmobranchs [47].

Healthy fish have a specific number and size of RBCs that contain measurable hemoglobin. RBC indices include the total RBC count, hemoglobin (Hb), hematocrit (HCT), mean corpuscular volume (MCV), mean corpuscular hemoglobin (MCH), and the mean corpuscular hemoglobin concentration (MCHC). Red blood cell indices are used to classify different types of anemia, disorders, deficiency in proteins, minerals, vitamins, and liver- kidney diseases [39, 47, 56, 143-145].

Alligator gar is a primitive fish that can be found along the lakes and rivers of Missouri, Ohio, Mississippi, the Gulf Coast of Mexico, Florida, Texas, and coastal water of Nicaragua [4, 5, 7, 8]. Gars have not been well studied yet [9], and surveys have suggested that alligator gar population have been declining for years [5, 10-14]. Every year, around 500 million kg of different types of pesticides are used in the United State in agriculture [68]. Alligator gar population is declining as a result of being exposed to different types of pollutants [70]. Pollution is an unexplored factor that could have a great impact on alligator gar's health. Diazinon is an organophosphate chemical that is known to inhibit AChE and has adverse effects on different body organs [79, 80]. Diazinon is found in major US rivers at levels between 0.04- 0.32 mg/L [84], and there is no even one study conducted to investigate the effect of long term diazinon exposure in gar's health. The aim of this study was to determine how alligator gar blood parameters are effected by long term exposure to sub-lethal concentrations of diazinon for 15 and 30 days.

3.2 Materials and methods

3.2.1 Chemical and experimental animals

Diazinon (purity of 99%) was purchased from Chem Service Inc website (<https://www.chemservice.com>). Other kits and reagents were purchased from Sigma-

Aldrich (<https://www.sigmaaldrich.com>) for running blood samples. Seventy-two alligator gar were obtained from Louisiana State University, and were from broodstock from coastal Louisiana, The average weight was 773.9 gm and the average length was 53.8 cm. The fish were acclimated in fresh water at the Mississippi Agriculture and Forestry Experiment Station, South Farm Aquaculture Unit. The fish were transferred to the Basic Science Department, College of Veterinary Medicine and held in stainless steel tanks to perform the experiments. Fish were left to acclimate in the same tanks for 10 days before starting the experiments. All fish were subjected to natural light, and they were fed a pelleted feed (45% protein) (Rangen Inc / <http://www.rangen.com>) once a day.

3.2.2 Experimental water and stock solution

Each experimental tank was filled with 350 liters of well water, and an air stone was placed in each tank throughout each experiment. The water in each tank was changed every day to maintain water quality. Water temperature in each tank was maintained at 21 ± 2 °C using heaters, the dissolved oxygen averaged $7.3 \text{ ppm} \pm 0.2$, and the pH averaged 7.5 ± 0.2 .

125 μL pure diazinon was dissolved in 25 ml 100% ethanol to make the stock and used for each experiment, but fish in control tanks (vehicle) were exposed only to ethanol. A pilot study was first conducted to determine the sub-lethal dosages for each experiment by measuring acetylcholinesterase (AChE) inhibition. To determine the exact concentrations for each study we used a range of concentrations of diazinon from very low (0.00075, 0.001, and 0.01 mg/L diazinon) to high levels (0.1 and 1 mg/L diazinon). Three fish were used for each concentration for duration of 48 hours. The goal was to keep AChE inhibition levels below 25% so that fish would not die before the end of each

experiment. Based on the results from the pilot study, we determined the concentrations to use for the experiment. Stainless steel tanks were used to avoid any reaction between the chemical and tank material. Mississippi State University Institutional Animal Care and Use Committee approved fish holding and experimental protocols (protocol # 15-078).

3.2.3 Chronic exposure

Fish were exposed to 0, 0.01, and 0.1 mg/L diazinon for two different durations; 15 days and 30 days. Nine separate tanks were used with three replicates per treatment. Four fish were placed in each tank, and each tank was cleaned every day, refilled with clean water and fresh chemical was added as well. Tanks were cleaned by removing one plug and draining approximately 80% of the water and adding clean water and letting this process continues for about 8 minutes so that the remaining 20% will be eventually drained. Fish in control tanks were exposed to 3.5 ml of 100% ethanol every day after cleaning each tank. Fish status were visually monitored for about 10 minutes, 5 times a day, and any abnormal change in behavior, swimming patterns, feeding, and skin color was recorded during each experiment based on monitoring control fish. Also, opercula movement was counted per minute for both control and exposed fish. In addition, water quality was monitored though out the experiments for metabolic accumulation waste including nitrate, ammonia, and also to maintain the concentration of the added chemical.

3.2.4 Blood sampling

At the end of each exposure time, individual fish were netted out and placed in a small tank contains a solution of anesthetic (500 mg/L tricaine methanesulfonate MS-

222), and then fish were wrapped and cleaned with paper towels. Blood samples were collected through the caudal vein by evacuated blood collection system. The vacuum blood collection system consisted of a 17 gauge double-pointed needle, a plastic holder, and vacuum tubes with rubber stoppers. These types of tubes contain sodium heparin and 0.9 g/L NaCl to prevent blood from clotting. All blood samples were processed in the same day for hematological examination. The hematological analysis included counting the numbers of erythrocytes , and leukocytes , measuring hemoglobin (Hb); using Drabkin's reagent (Sigma) following the manufacturer's instructions of measuring Hb, Hematocrit (Hct), the mean corpuscular volume (MCV), the mean corpuscular hemoglobin (MCH), and the mean corpuscular hemoglobin concentration (MCHC) following the unified methods of hematological examination of fish [111]. Blood smears were prepared for each blood sample, fixed with ethanol for 45 seconds, and stained with giemsa (Sigma) following the manufacturer's instructions. Differential count for leukocytes were performed based on morphological appearance, and cells were identified based on a previous hematological study on alligator gar [22]. One hundred leukocytes were counted on each slide using light microscopy at 100X magnification. Peripheral blood differentials of alligator gar from fish exposed to 0.01, 0.1mg/L diazinon were compared with control fish.

3.2.5 Statistical analysis

All data obtained from this study were initially tested using student's t-tests. Data for blood samples were tested for normality and then were analyzed by two way analysis of variance (ANOVA) with factors of treatment and duration with three tank replicates per treatment. Significant differences were tested among measured variables of the

control and exposed fish groups. Data are presented as mean \pm standard error (SEM). All statistical analysis were performed by using SPSS[®] version 23.0 software program on windows 10, and the differences between means were considered significant if $P < 0.05$.

3.3 Results

3.3.1 General observations

Fish swam actively during the 10 days acclimation period and in the first week of both concentrations of diazinon exposure. By the second week, diazinon exposed fish were motionless and preferred to stay in the same area. However, there was no change in operculum movement, and fish gulped air normally. There was no change in fish appetite. Exposed fish developed lighter skin color by the end of second week; then it turned back to be a little bit darker again by the beginning of the fourth week. Control fish didn't develop any behavioral or physical changes. No deaths occurred in exposed fish or control fish (Table 3.1).

Table 3.1 Clinical observations of alligator gar chronically exposed to two levels of diazinon for 15 days and 30 days.

Indices	0 mg/L 15 & 30 Days	0.01mg/L 15 & 30 Days	0.1mg/L 15 & 30 Days
Appetite	Normal	Normal	Normal
Opercula movement	Normal	Normal	Normal
Swimming	Active	Motionless	Motionless
Skin color	Normal	Lighter	Lighter
Mucous	Normal	Increased	Increased
Death	No	No	No

3.3.2 Hematological analysis after 15 days exposure to 0, 0.01 and 0.1 mg/L diazinon

There were significant differences between the control fish and the two chronic exposure groups (Table. 3.2). Erythrocyte, leukocyte, and hematocrit values from low and high dose exposed fish were significantly lower than the values from the control fish. There were no significant changes in hemoglobin and MCV values from low and high dose exposed fish compared to the control group. Hemoglobin values from exposed fish were statistically higher than those from control fish.

Table 3.2 Mean values of hematological analyses after 15 days continuous diazinon exposure.

Blood parameters	Control	0.01mg/L	0.1mg/L
RBCs ($\times 10^6/\text{mm}^3$)	1.06 \pm 0.06	0.9 \pm 0.05*	0.8 \pm 0.05*
WBCs ($\times 10^3/\text{mm}^3$)	32.05 \pm 2.33	25.85 \pm 1.48*	22.50 \pm 1.63*
Hb (mg/L)	33.4 \pm 8.6	68.9 \pm 15.8*	49.4 \pm 10.7
Hct (%)	41.2 \pm 1.45	36.1 \pm 1.26*	33.3 \pm 1.14*
MCV (fl)	407.9 \pm 28.9	409 \pm 21.04	364.1 \pm 26.2
MCH (pg)	330.8 \pm 92.3	713.6 \pm 142.8*	554.8 \pm 112.3
MCHC (%)	70.7 \pm 18.1	190.7 \pm 42.7*	148.5 \pm 31.8*

*Indicates significant changes ($P < 0.05$), mean \pm SEM.

MCH values from the low dose were significantly higher than those from the control group. There was no significant difference between MCH values of high dose exposed fish compared to the control group. There was a significant increase in MCHC values from low and high dose exposed fish compared to the values from control fish.

Differential leukocyte counts showed significant decreases in lymphocyte counts in fish exposed to the high dose compared to control group (Fig. 3.1). There was no significant difference in lymphocyte count between control and low dose exposed fish. Monocyte counts from high dose exposed fish were significantly higher than in the control fish. There was no significant differences between monocyte counts from low dose exposed fish compared to control fish. Also, there was no change in granulocyte counts from either low or high dosages compared to the counts from control fish (Fig. 3.1).

15 Days Exposure

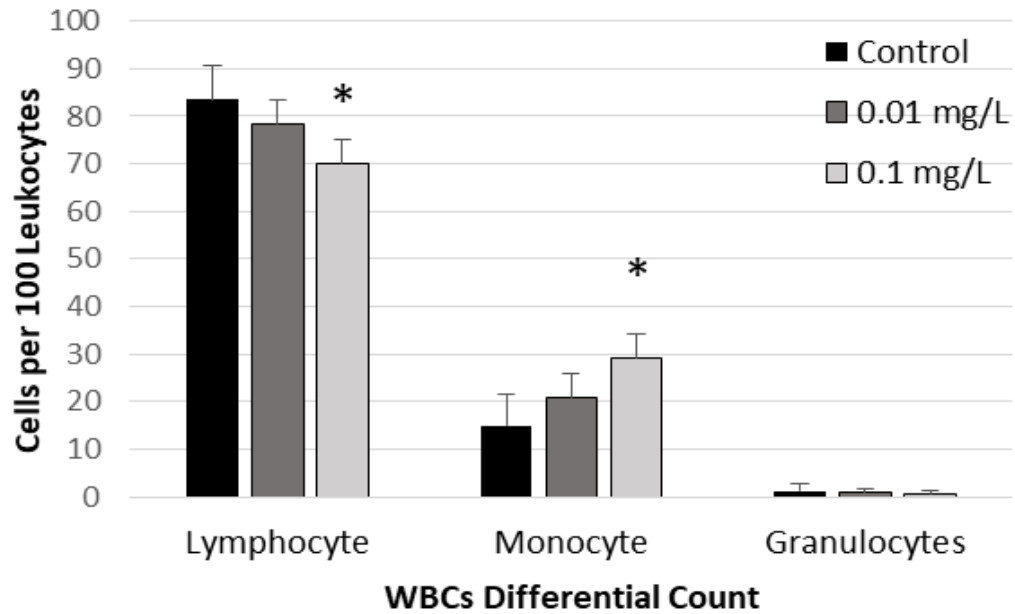


Figure 3.1 Differential counts of alligator gar peripheral blood leukocytes after diazinon exposure for 15 days.

A significant decrease in lymphocyte number was observed in 0.1 mg/L diazinon with significant increase in monocyte counts when compared to control group. No change was observed with granulocyte count in 0.1 mg/L diazinon exposed fish. There was no significant change in leukocyte counts in fish exposed to 0.01 mg/L compared to controls.

3.3.3 Hematological analysis after 30 days exposure to 0, 0.01 and 0.1 mg/L diazinon

Erythrocyte, leukocyte and hematocrit values from low and high dose exposed fish were significantly lower than the values from control fish (Table. 3.3). There were no significant changes in hemoglobin and MCV values from fish exposed to low and high doses compared to the control group.

Table 3.3 Mean values of hematological analyses after 30 days continuous diazinon exposure.

Blood parameters	Control	0.01mg/L	0.1mg/L
RBCs ($\times 10^6/\text{mm}^3$)	1.04 \pm 0.06	0.8 \pm 0.04*	0.6 \pm 0.07*
WBCs ($\times 10^3/\text{mm}^3$)	31.35 \pm 1.55	23.84 \pm 1.83*	22.84 \pm 2.13*
Hb (mg/l)	59.6 \pm 15.7	94.3 \pm 18.7	90.5 \pm 14.7
Hct (%)	40.5 \pm 0.90	36.1 \pm 1.25*	32.8 \pm 0.91*
MCV (fl)	404.4 \pm 24.9	442 \pm 19.27	405.1 \pm 21.38
MCH (pg)	586.6 \pm 142.2	1250 \pm 245.6*	1142.4 \pm 199.8
MCHC (%)	150.5 \pm 42.06	280 \pm 52.8*	285.3 \pm 51.3*

* Indicates significant change ($P < 0.05$); mean \pm SEM.

Mean corpuscular hemoglobin values from low dose exposed fish were significantly higher compared to control fish. There were significant increases in MCHC values from low and high dose exposed fish compared to the control fish.

Lymphocyte counts of fish exposed to 0.1 mg/L diazinon were significantly lower than the control group (Fig. 3.2). Lymphocyte counts from fish exposed to 0.01mg/L were not statistically different than control fish. Lymphocyte counts from high dose exposed fish were significantly lower than fish exposed to the low dose and control fish. Monocytes significantly increased in fish exposed to 0.1 mg/L while there was no change in fish exposed to 0.01 mg/L diazinon when compared to the control group. Granulocyte counts did not show any significant changes with either treatment in comparison to the control fish (Fig. 3.2).

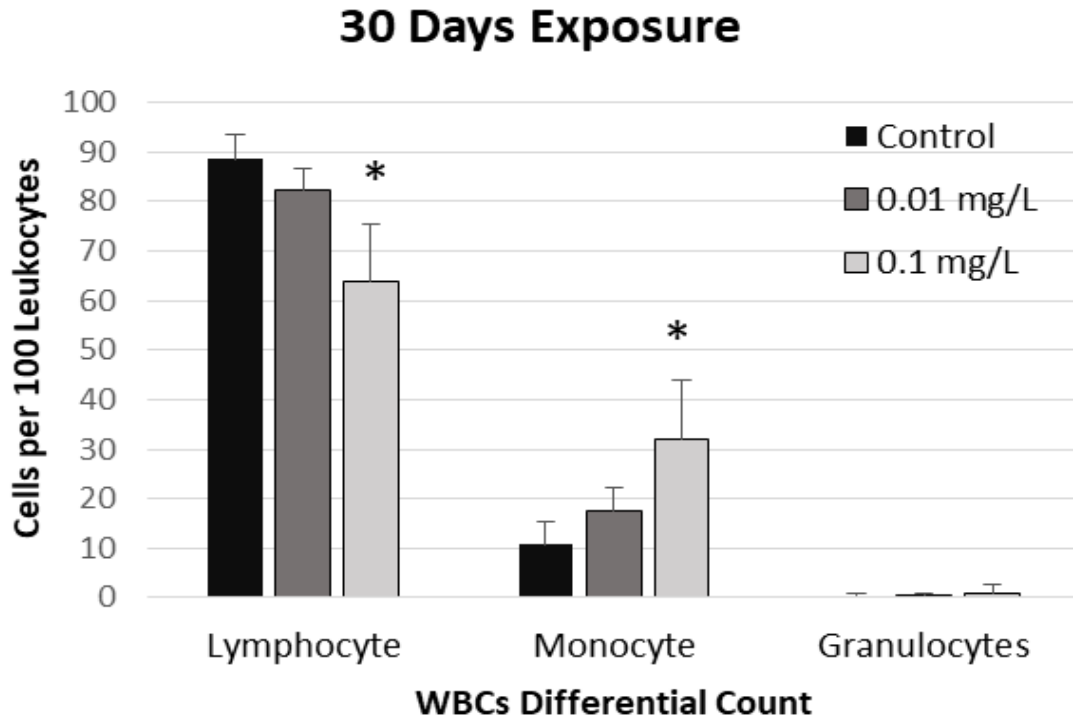


Figure 3.2 Differential counts of alligator gar peripheral blood leukocytes after 30 days of diazinon exposure.

Lymphocyte numbers significantly decreased after 30 days of 0.1 mg/L diazinon exposure while monocyte counts significantly increased. Diazinon exposure did not affect granulocyte counts.

3.4 Discussion

This study revealed that sub-lethal chronic exposure of alligator gar to low (0.01mg/L) and high (0.1mg/L) concentrations of diazinon for 15 and 30 days induced significant effects on blood parameters, behavior, and physical appearance. Blood parameters have been used as a valuable tool to diagnose many human and fish diseases [23, 93, 146, 147]. Many pollutants accumulate in aquatic ecosystems, and fish exposed to these pollutants develop pathological changes in blood forming organs [17, 22, 148]. Fish demonstrated change in behavior and activity after 7 days of low and high doses of diazinon. Operculum movement and food appetite of exposed fish were normal during all experiments in comparison to fish in control tanks. However, eating pelleted feed is not the normal feeding behavior of alligator gar. In the wild, diazinon could decrease feeding activity of gar. Changes in behavior could lead to negative impact on the predatory behavior and reproduction of gar. Normal gar skin color is grayish to dark green dorsally [5]. The lighter skin color changes we observed were similar to findings in other diazinon exposed fish [118, 149, 150]. Changes in the color of the skin could negatively impact the life history of this fish.

The hematological results showed significant reduction in the numbers of erythrocyte, leukocyte, and values of hematocrit, MCH, and MCHC in fish exposed to both concentrations and durations. This reduction in number of erythrocytes and hematocrit percentages suggest that exposed fish were suffering from hemolytic anemia or destructive effects of diazinon on blood forming organs, but the mechanism is still unknown. In addition, the reduction in erythrocyte count was statistically much lower in exposed fish to the high dose for 30 days when compared to the other concentrations for

15 and 30 days. Similar findings were reported in other studies using different types of fish exposed to diazinon [25, 101, 112, 118, 151, 152].

Total Hb elevated after 15 days of exposure to high dose, and significantly increased after 15 days exposure to the low dose. Total Hb elevated after 30 days of low and high diazinon exposure, but was not significantly greater. There was a trend of increasing Hb values. Hemoglobin values increase when Hct or RBCs decrease. This is a compensatory mechanism to maintain healthy oxygen and carbon dioxide levels in blood and tissues. Significant increases in hemoglobin values were also reported in common carp after diazinon exposure [153].

Total leukocyte counts were significantly reduced in exposed fish in both experiments. This could result from malfunctioning hematopoietic tissues due to diazinon toxicity. Many studies reported significant decreases in WBC counts in different types of fish exposed to diazinon [110, 112, 116, 117, 153]. These findings suggest that long term exposure to diazinon lowers total leukocyte counts, increasing disease susceptibility.

MCV, MCH, and MCHC provide an indication of the condition of erythrocytes, hematocrit, and hemoglobin, so, any changes in these indices correspond with the values of RBCs, Hct, and Hb. MCH and MCHC values from exposed gar significantly increased in comparison to the values from the control fish. MCV values from both experiments did not show any significant changes. Similar findings were reported in previous studies exposing fry rainbow trout and Indian carp to diazinon [25, 112, 117, 119].

In our study, alligator gar exposed to the high diazinon dose for 15 and 30 days demonstrated lymphopenia. Other studies have documented that lymphopenia occurs in

fish after exposure to pollutants, and increases the susceptibility of fish to infectious diseases [22, 23, 113, 118, 154]. In contrast, fish exposed to low and high diazinon doses for 15 and 30 days demonstrated significantly increased monocyte counts. Monocytosis resulted from long-term chemical exposure, and stress and inflammation were believed to be contributing factors [155]. No significant change was observed in granulocyte count in either experiment or duration time when compared to the results from control fish.

3.5 Conclusion

The present study shows that long term exposure to diazinon even at a low concentration, significantly affects hematological parameters in alligator gar. The main effect was decreased blood cell counts that can ultimately impact fish health. Diazinon can also have harmful effects on alligator gar behavior, and lower their survivability in a natural environment. Alligator gar are very important to maintain balance in natural fish populations, and to control invasive fish. Few studies have been conducted on gar exposed to different pollutants. This is the first study that provides blood analyses combined with general health indices associated with diazinon exposure.

CHAPTER IV
HISTOPATHOLOGICAL CHANGES INDUCED BY CHRONIC SUB-LETHAL
CONCENTRATIONS OF DIAZINON IN ALLIGATOR GAR (*TRACTOSTEUS*
SPATULA)

4.1 Introduction

Fish live in an environment that is filled with different types of pollutants, and the skin provides an effective barrier against the surrounding environment. Skin condition also has a significant impact on fish health, and is important in many disease processes [56]. Commonly reported external effects of pollutants on fish are lesions in the skin, eyes, fins, gill, and opercles [156, 157].

Organophosphate (OP) chemicals including diazinon induce oxidative stress during OP detoxification in the liver, generating reactive oxygen species (ROS) in aquatic organisms [158-160]. Oxidative stress occurs when there is a reduction in antioxidant level or excessive accumulation of reactive oxygen species (ROS) [159, 161, 162]. ROS can react with vital molecules and cause direct damage to proteins, nucleic acids, carbohydrates, lipids, and DNA, resulting in oxidative damage to fish tissues [121, 161, 163-167]. Many studies were conducted to study the effects of different aquatic pollutants on fish, but few have included alligator gar [22, 23, 70]. These fish are listed as endangered in several states. Alligator gar populations have declined as a result of overfishing, habitat loss, and pollution [70]. The aim of this study was to evaluate the

toxic effects of long term exposure of sub-lethal concentrations of diazinon on alligator gar tissues.

4.2 Materials and methods

4.2.1 Chemicals and experimental animals

Diazinon was purchased from Chem Service Inc website (<https://www.chemservice.com>). Seventy two alligator gar averaging 773.9 gm and 53.8 cm in length were obtained from Louisiana State University, and were from broodstock from coastal Louisiana, and held at the Mississippi Agriculture and Forestry Experiment Station, South Farm Aquaculture Unit at Mississippi State University. The fish were transferred to the College of Veterinary Medicine where the experiments were conducted. All fish were subjected to natural photoperiod, and they were fed a formulated diet (Rangen Inc 45% protein / <https://www.rangen.com>) to satiation once a day. Any leftover food was removed after 30 minutes.

4.2.2 Experimental water and stock solution

Each experimental tank was filled with 350 liters of well water. Air stones in all tanks maintained optimum oxygen concentration ($7.3 \text{ ppm} \pm 0.2$), and dissolved oxygen was measured three times a day. Water in each tank was changed every day to maintain water quality ($\text{pH } 7.5 \pm 0.2$) and diazinon concentrations. Water temperature in each tank was maintained at $21 \pm 2 \text{ }^\circ\text{C}$ using heaters. 125 μL pure diazinon was dissolved in 25 ml of 100% ethanol to make a stock solution, and then concentrations were calculated for each treatment. Fish in all control tanks were exposed to 3.5 ml 100% ethanol. Stainless steel tanks were used to avoid any reaction between the chemical and tank material. A

pilot study was first conducted to determine the sub-lethal dosages for each experiment by measuring acetylcholinesterase (AChE) inhibition. To determine the exact concentrations for each study we used a range of concentrations of diazinon from very low (0.00075, 0.001, and 0.01 mg/L diazinon) to high levels (0.1 and 1 mg/L diazinon). Three fish were used for each concentration for duration of 48 hours. The goal was to keep AChE inhibition levels below 25% so that fish would not die before the end of each experiment. Based on the results from the pilot study, we determined the concentrations to use for the experiment. The Mississippi State University Institutional Animal Care and Use Committee approved fish holding and experimental protocols (protocol number 15-078).

4.2.3 Chronic exposure

After 10 days acclimation period, fish were exposed to 0, 0.01, and 0.1 mg/L diazinon for 15 days and 30 days. Nine separate tanks were used for each experiment. Three control tanks with no chemical, and six other tanks were used for each concentration for a total of three replicates. Four fish were placed in every tank, and each tank was cleaned every day, filled with clean water and fresh chemical was added. Tanks were cleaned by removing one plug and draining approximately 80% of the water and adding clean water and letting this process continues for about 8 minutes so that the remaining 20% will be eventually drained. Fish in control tanks were exposed to 3.5 ml of 100% ethanol every day after cleaning each tank. Fish status were visually monitored for about 10 minutes, 5 times a day, and any abnormal change in behavior, swimming patterns, feeding, and skin color was recorded during each experiment based on monitoring control fish. Also, Opercula movement was counted per minute for both

control and exposed fish. In addition, water quality was monitored throughout the experiments for metabolic accumulation waste including nitrate, ammonia, and also to maintain the concentration of the added chemical.

4.2.4 Tissue sampling

In the end of each experiment, fish were individually netted out and placed in a small tank containing a solution of anesthetic (500 mg/L tricaine methanesulfonate; MS-222) until immobilized, and then wrapped and cleaned with paper towels. Tissues of gills, liver, spleen, kidney, gut, intestine, gas bladder, skin, heart, and brain were surgically removed from each fish. Since there were lesions on the head; the whole head for each fish was sampled and fixed in formalin for 48 h and then dipped in decalcifying fluid for 3 days before processing. All tissues were rinsed in physiological saline and fixed in 10% phosphate buffered formalin for 48 h. Tissues were processed, embedded in paraffin wax, sectioned, and stained with Hematoxylin and Eosin (H&E). All slides were viewed under light microscopy on an Olympus BX 51 (Olympus America Inc, USA.) and photographed using Picture Frame™ software. The size of tissues and cells were measured under microscope using 100x microscope eyepiece with Reticle.

4.3 Results

4.3.1 General observations

Fish swam actively during the 10 days acclimation period and in the first week of exposure to diazinon with both concentrations and duration times. By the second week, fish were less active and became motionless and stayed in the same area. There were no changes in the movement of the operculum, and fish were gulping air normally. There

was no change in fish appetite. Exposed fish developed lighter skin color by 15 days of exposure.

Fish exposed to either diazinon concentration developed skin lesions by the end of the second week. These lesions began as small white spots and later developed into skin ulcers, some with hemorrhage (Fig. 4.1. A, B, C). Interestingly, most of the skin lesions were only observed on the left side of fish exposed to 0.1 mg/L diazinon for 30 days. Skin lesions on the head were observed in both treatment levels and durations (Fig. 4.1. E, F). These lesions were more progressed and pervasive in fish exposed to the higher dose for 30 days. Control fish did not develop any changes in behavior or physical appearance. No fish died during the experiments (Table.4.1).

Table 4.1 Clinical signs of control and exposed alligator gar after 15 days and 30 days.

Indices	0 mg/L	0.01mg/L	0.1mg/L
Appetite	Normal	Normal	Normal
Operculum movement	Normal	Normal	Normal
Swimming	Active swimmer	Motionless	Motionless
Mucous	Normal	Increased	Increased
Skin color	Normal	Lighter	Lighter
Skin lesion	No	Yes	Yes
Death	No	No	No

Grossly, tissues from control fish appeared normal. Livers from fish exposed to the low and high diazinon concentrations for 30 days demonstrated changes in color (Fig. 4.1. H, I) when compared to livers from control fish (Fig. 4.1. G). The diazinon exposed livers were spotted with red, gray, or dark green. The livers from fish exposed to the high concentration seemed to be more affected than livers from fish exposed to the low concentration in comparison to livers from control fish.




Figure 4.1 Alligator gar gross pictures for skin and liver tissues.

A-C: arrows denote skin lesions on fish exposed to 0.1 mg/L diazinon for 30 days. D-F: arrows denote skin lesions on fish exposed to 0, 0.01 and 0.1 mg/L for 15 and 30 days; D control fish with no lesions. E. Head of fish exposed to 0.01 mg/L for 30 days; F. Head of fish exposed to 0.1 mg/L for 30 days. Figures G-I: arrows denote liver tissues; G. liver from control healthy fish; H. Liver tissue from fish exposed to 0.01 mg/L, I. liver from fish exposed to 0.1 mg/L. Figures H-I demonstrate the changes in color of liver tissues after diazinon exposure.

4.3.2 Histopathological results after 15 days diazinon exposure

Brain, gill, skin, liver, spleen, gut, intestine, kidney, heart, and ABO tissues from control fish were normal. Brain, gill, spleen, gut, intestine, heart, and ABO tissues from fish exposed to 0.01 and 0.1 mg/L diazinon for 15 days were normal with histopathological changes.

Alligator gar skin is divided into two main layers: the epidermis and the underlying dermis (Fig. 4.2. A). The main components of the epidermis are stratified squamous epithelial cells. Spaces between the epithelial cells are filled with mucus cells. Mucus, or Goblet cells secrete the mucus that forms a protective layer on fish skin. Fish exposed to 0.01 and 0.1 mg/L diazinon developed cranial epidermal lesions after 15 days of exposure. Grossly, these lesions appeared as white spots. Microscopically, the epidermis and dermis were absent in these areas in fish exposed to 0.01 mg/L diazinon, the muscle layer in these areas was necrotic specifically in the superficial layer. Intact epidermis adjacent to these lesions was edematous (Fig. 4.2. B). Similar findings were observed in fish exposed to 0.1 mg/L diazinon, but the lesions were more severe. Also, necrosis progressed deeper into the muscles. Intact epidermis adjacent to these lesions was necrotic, edematous, and congested (Fig. 4.2. C).

Liver tissues in fish exposed to 0.01 mg/L diazinon demonstrated steatosis, vacuolization, and focal aggregation of macrophages (Fig. 4.2. E). Liver tissue from fish exposed to 0.1 mg/L diazinon demonstrated increased melanomacrophage centers (MMCs) and macrophages, severe steatosis, marked vacuolization, swollen hepatocytes, fibrosis, and necrosis (Fig. 4.2. F). The number and size of hepatic MMCs increased significantly in fish exposed to the high dose compared to control fish. Hepatic MMCs in

fish exposed to the low dose were not significantly different than those in control fish (Table. 4.2).

Kidney hematopoietic tissues from fish exposed to both doses demonstrated vacuolar degeneration. Vacuoles were larger in size, greater in number, and higher in frequency in fish exposed to the higher diazinon dose (Fig. 4.2. H. I). Aggregations of eosinophils were observed around these vacuoles in fish exposed to the high dose (Fig. 4.2. I). No other changes were seen in kidney hematopoietic tissue (Fig. 4.2. G).

Table 4.2 MMCs number and size in control and exposed alligator gar for 15 days and 30 days.

Treatments	15 Days		30 Days	
	Number	Size	Number	Size
Control	29.7±9.5	6.5± 1.2	35±6.4	8±1.3
0.01 mg/L	37.5±8.3	7±2.2	64.5±16.3*	10±2.1
0.1 mg/L	62±6.7*	12±1.4*	78.2±11.1*	18±1.7*

* Indicates significant changes ($P<0.05$) determined by using student t- test, mean ± SD, size was measured by millimeter.

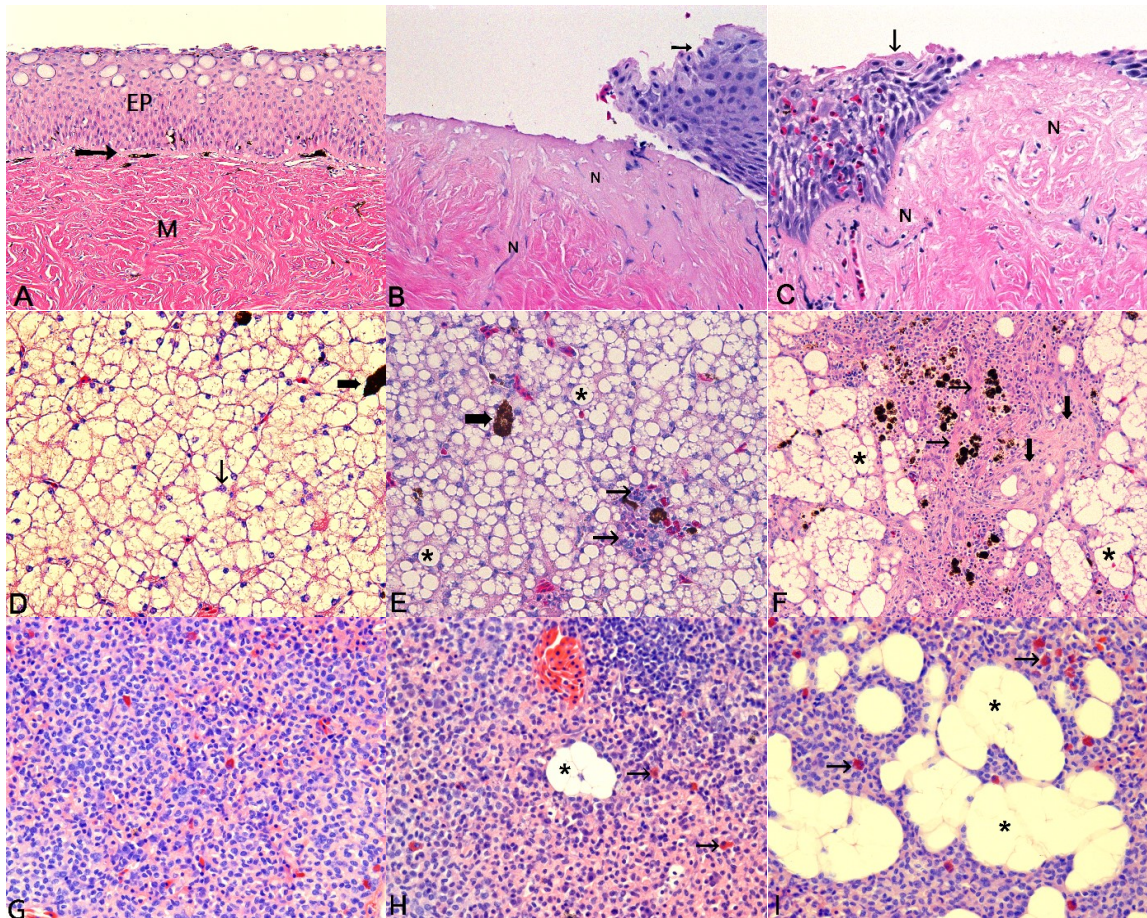


Figure 4.2 Alligator gar skin, liver, and kidney tissues from control, and fish exposed to 0.01 and 0.1 mg/L diazinon for 15 days.

A. Cranial epidermal tissue from control fish, epidermis (EP), and dermis (arrow), and muscle tissue (M) beneath the dermis. **B.** cranial epidermal lesions from fish exposed to 0.01 mg/L diazinon; demonstrates absence of epidermal layer and edematous epidermis (arrow), necrotic muscle tissues (N). **C.** cranial epidermal lesion of fish exposed to 0.1 mg/L; demonstrates absence of epidermal layer, congested and edematous epidermis (arrow), necrotic muscle tissues (N). **D.** liver from control fish demonstrates MMCs (bold arrow), hepatocyte nucleus (thin arrow). **E.** liver from fish exposed to 0.01 mg/L; demonstrates steatosis and hepatic vacuolization (asterisk), MMCs (bold arrow), aggregation of macrophages (thin arrows). **F.** Liver from fish exposed to 0.1 mg/L demonstrated severe steatosis, fibrosis (bold arrow), necrosis (thin arrow), and vacuolar degeneration in hepatic cytoplasm (asterisk). **G.** kidney hematopoietic tissue from control fish. **H.** kidney hematopoietic tissue from fish exposed to 0.01 mg/L demonstrated vacuolar degeneration (asterisk) with aggregation of eosinophils (arrows). **I.** kidney hematopoietic tissue from fish exposed to 0.1 mg/L demonstrated progressed vacuolar degeneration in size and numbers (asterisk) and eosinophilic infiltration (arrows). Hematoxylin and eosin (H&E); (200X).

4.3.3 Histopathological results after 30 days diazinon exposure

Control fish did not demonstrate any histological changes in brain, gill, skin, liver, spleen, gut, intestine, kidney, heart, and ABO tissues. No visual changes were observed in brain, gut, intestine, heart and abo tissues of fish exposed to 0.01 and 0.1 mg/L diazinon for 30 days.

Fish exposed to 0.01 mg/L diazinon developed cranial epidermal lesions. Fish exposed to 0.1 mg/L diazinon developed cranial and torsal epidermal lesions. Interestingly, the torsal epidermal lesions were observed only on the left sides of exposed fish (Fig. 4.1. A. B. C). The cranial epidermal lesions were more progressed in fish exposed to 0.1 mg/L diazinon than in fish exposed to 0.01 mg/L diazinon.

Cranial epidermal lesions in fish exposed to 0.01 mg/L diazinon demonstrated absence of the epidermal and dermal layers, and necrosis with aggregations of macrophages in the underlying muscle (Fig. 4.3. E) and (Fig. 4.3. F). In fish exposed to the high dose, torsal epidermal lesions demonstrated absence of the epidermal and dermal layers and necrosis in the underlying musculature (Fig. 4.3. B. C). Cranial epidermal lesions demonstrated absence of the epidermal and dermal layers with necrosis and multifocal hemorrhage in the underlying musculature (Fig. 4.3. G. H. I). The grade of these lesions were moderate to marked in fish exposed to the low dose and marked in fish exposed to the high dose.

Gills from fish exposed to the low diazinon dose demonstrated moderate epithelial hyperplasia in secondary lamellae (Fig. 4.3. K. L). Fish exposed to the high dose demonstrated marked epithelial hyperplasia with fusion of the secondary lamellae (Fig. 4.3. L). The diameter of the secondary lamellae was measured, and fish exposed to

diazinon had thicker secondary lamellae compared to control fish. The overall diameter for the secondary lamellae in control fish was 14 mm. The secondary lamellae diameters in fish exposed to 0.01 and 0.1 mg/L diazinon were 18 mm and 19 mm, respectively. Moreover, measuring the diameter of the severely affected secondary lamellae with epithelial hyperplasia revealed that the diameters were 45 mm and 65 mm in fish exposed to the low and high dose, respectively.

Fish exposed to 0.01mg/L diazinon demonstrated marked hepatic steatosis (Fig. 4.4. C). Fish exposed to 0.1mg/L demonstrated marked steatosis with diffuse fibrosis (Fig. 4.4. E), and necrosis with associated macrophage aggregations (Fig. 4.4. D).

Hepatic nuclei of fish exposed to the high dose were larger than hepatic nuclei of control fish. The average diameter was 5 mm, 3 mm and 2 mm in fish exposed to the high dose, low dose, and control fish, respectively. Rodlet cells were observed in the bile duct wall of fish exposed to the high dose (Fig. 4.4. F), and eosinophilic granules were seen inside the bile duct. These cells were not observed in control fish or fish exposed to the low dose. Melanomacrophage centers (MMCs) were scattered throughout the liver tissues in control and exposed fish, but higher numbers were seen in diazinon exposed fish. The average size of MMCs in the liver of fish exposed to 0.1 mg/L diazinon was significantly greater than in fish exposed to 0.01mg/L diazinon or control fish (Table. 4.2). Kidney hematopoietic tissues revealed vacuolar degenerations and eosinophilic aggregation in fish exposed to both concentrations when compared to the control fish (Fig. 4.4. H. I). No remarkable changes were seen in kidney hematopoietic tissues of control fish (Fig. 4.4. G).

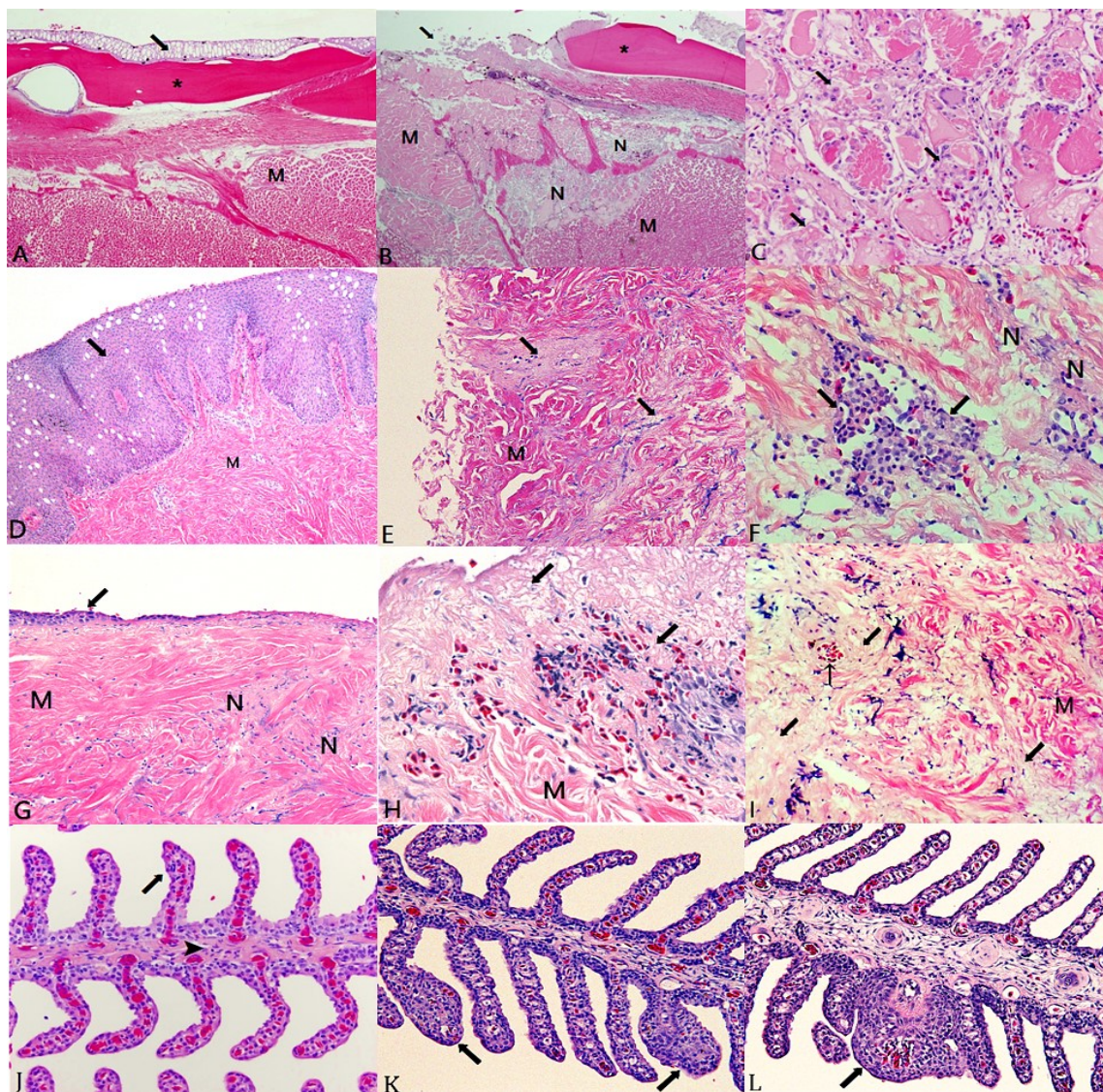


Figure 4.3 Alligator gar skin and gill tissues from control fish, and fish exposed to 0.01, and 0.1 mg/L diazinon for 30 days.

A-C: torsal epidermal tissues of control fish and fish exposed to 0.1 mg/L. **D-I:** cranial epidermal tissues of control, fish and fish exposed to 0.01, and 0.1 mg/L. **A:** control torsal epidermal tissue demonstrating epidermis (bold arrow), scale (asterisk) and dermis, muscles (M). **B:** torsal epidermal lesions from fish exposed to 0.1 mg/L diazinon demonstrating absence of epidermis and dermis (arrow), necrosis (N) in muscle tissues. Scale (asterisk), muscles (M). **C:** The necrotic area (arrows) in B under higher magnification. **D:** Cranial epidermal tissue from control fish, epidermis (arrows), and muscles tissues (M). **E-F:** Cranial epidermal lesion from fish exposed to 0.01 mg/L diazinon. **E** demonstrates an absence of epidermal and dermal layers and diffuse necrosis (arrows) throughout the musculature (M). **F:** aggregation of macrophages (arrows) and necrotic muscle (N). **G-I:** Cranial epidermal lesion from fish exposed to 0.1 mg/L. **G:**

shows the gradual loss of the epidermis and dermis (arrow), necrosis (N), muscles (M). **H:** necrosis in the muscle tissue associated with hemorrhage (arrows), muscles (M) **I:** necrosis (bold arrows) in muscle tissue, muscle (M), blood vessel (thin arrow). **J:** Gills from control fish show the primary (arrow head) and secondary lamellae (arrow). **K:** Gill tissue from fish exposed to 0.01 mg/L demonstrates epithelial hyperplasia in the secondary lamellae (arrows). **L:** Gill tissue from fish exposed to 0.1 mg/L demonstrate marked epithelial hyperplasia in the secondary lamellae (arrow). Hematoxylin and eosin (H&E) stain; (200X).

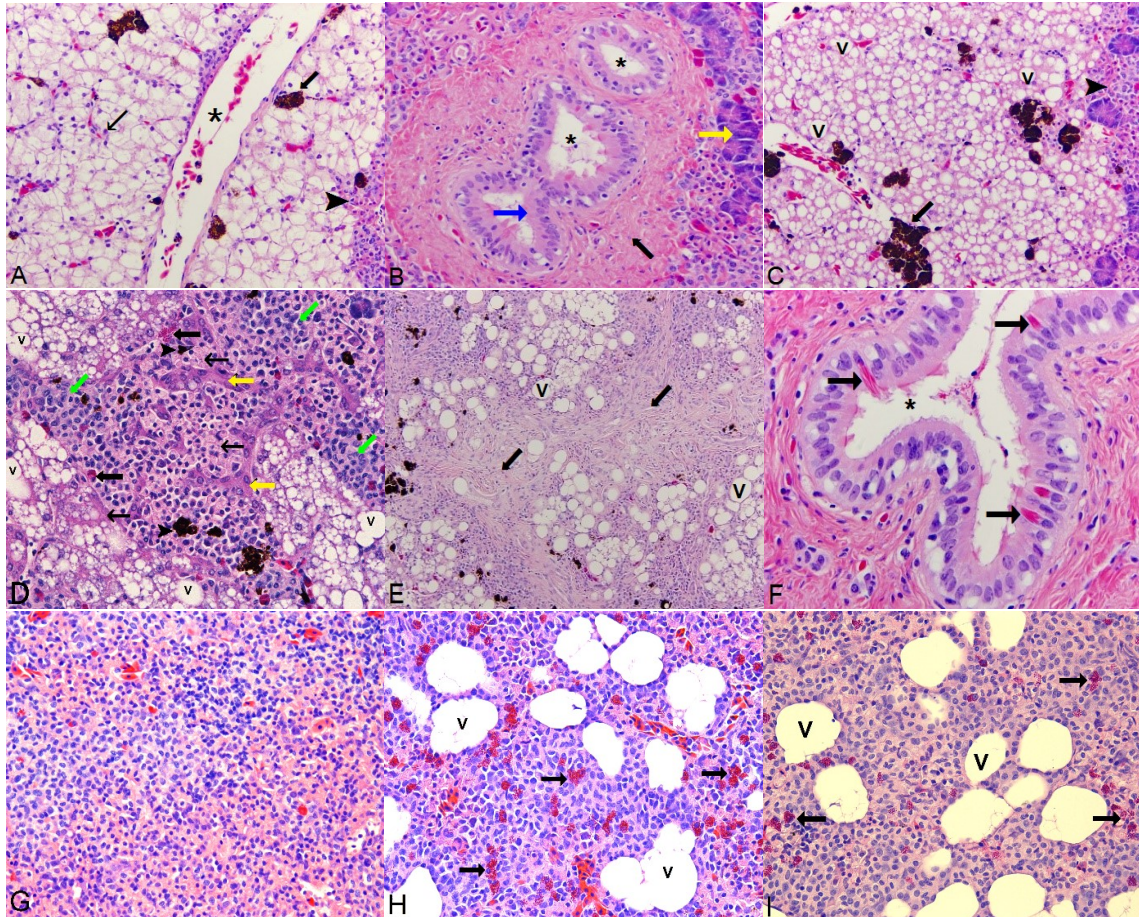


Figure 4.4 Alligator gar liver and kidney tissues from control, fish exposed to 0.01, and 0.1 mg/L diazinon for 30 days.

A. Liver tissue from control fish, thin arrow denotes hepatocyte nucleus, MMCs (bold arrow), hepatic portal vein (asterisk). **B.** Bile duct from control fish shows hepatic pancreatic tissue (yellow arrow), columnar epithelium (blue arrow), bile duct lumen (asterisk), and smooth muscle layer (black arrow). **C.** Liver tissue from fish exposed to 0.01 mg/L demonstrates severe steatosis throughout the liver with vacuolar degeneration (V), expanded MMCs (bold arrow) adjacent to portal vein, hepatic pancreatic tissue (arrowhead). **D-F** are liver tissues from fish exposed to 0.1 mg/L. **D.** Yellow arrows denote swollen and necrotic hepatocytes (thin arrows), aggregations of macrophages (green arrows) and eosinophils (black bold arrows), vacuoles (V), and MMCs (arrowhead). **E.** Liver tissues demonstrate fibrosis (bold arrows), vacuoles (V). **F.** Liver bile duct; arrows denote rod-let cells in bile duct wall, bile duct canal (asterisk). **G.** Kidney hematopoietic tissue from control fish. **H.** Kidney hematopoietic tissue from fish exposed to 0.01 mg/L demonstrate vacuolar degeneration (V), arrows denote diffuse eosinophilic infiltration, **I.** Kidney hematopoietic tissues from fish exposed to 0.1 mg/L demonstrate vacuolar degeneration (V), arrows denote diffuse eosinophilic infiltration. Hematoxylin and eosin Place all detailed caption, notes, reference, legend information, etc here (H&E) stain; (200X, 400X).

Table 4.3 Number of alligator gar demonstrating lesions following diazinon exposure.

Duration	15 Days					30 days				
	Skin		Gills	Liver	KD	Skin		Gills	Liver	KD
	Head	Body				Head	Body			
0 mg/L	0	0	0	0	0	0	0	0	0	0
0.01 mg/L	3	0	0	12	4	7	0	6	12	8
0.1 mg/L	10	0	0	12	7	12	7	9	12	11

The numbers in this table represent how many fish out of 12 fish were affected in each experiment. KD is kidney tissue.

4.4 Discussion

Histopathology is one of the fastest methods to observe effects of stresses in different body organs [168]. Even at low concentrations, pesticides in the aquatic environment have significant impact on the health of aquatic organisms [17, 22, 148, 169, 170]. This study has shown that alligator gar exposed to diazinon at 0.01 and 0.1 mg/L for 15 and 30 days developed tissue lesions (Table. 4.3). Similar findings have been reported in other studies [35, 39, 83, 120, 121, 171]. By the end of the first week, exposed fish were motionless. This is not normal activity for the alligator gar based on our observation for gars in control tanks. The actual color of gar's skin color is grayish to dark green dorsally and white ventrally [5]. One of the remarkable changes observed in this study was the change in the skin color of exposed fish to become lighter by the beginning of the second week of exposure with both diazinon concentrations and duration times. Other studies have reported similar findings in the fish skin color after being

exposed to chronic sub-lethal concentrations of diazinon [118, 149, 150]. It is been documented that the sympathetic nervous system controls the color of fish skin [149], and this could be the reason behind the change in skin color as it is well known that diazinon targets the nervous system [40, 94, 96]. Diazinon induced changes in swimming and color that could negatively impact the alligator gar in a natural setting.

Necrotizing dermatitis caused by chemicals has been reported in fish [172, 173]. Our study demonstrated that cranial and torsal epidermal lesions occurred in dose-related severity following diazinon exposure. The reason for uni-lateral occurrence of these lesions is unknown and needs to be further investigated. In our study, the epidermal lesions progressed to the point where the skin no longer provided a physical barrier. This change can result in physiological imbalances and entry sites for secondary invasion of bacteria and fungi.

After 30 days of continuous exposure, the severity of gill lesions was correlated to diazinon dose, as was observed in epidermal lesions. Similar findings were reported in studies using diazinon, quinalphos, edifenphos pesticides, and crude oil [35, 83, 172, 174-176]. The gill lesions observed markedly reduce the functional exchange surface of the gill. After 30 days of diazinon exposure, lesion were more severe, and gars could be utilizing the ABO for primary respiration, as it is functioning as a lung in these fish [177].

The liver plays a significant role in detoxification of chemicals in the body [56, 93]. If detoxification fails, high levels of reactive oxygen species result. This leads to oxidative stress and to cell damage [178]. Many studies have demonstrated ranges of liver lesions after fish were exposed to pesticides and petroleum compounds, and these changes ranged from fatty degeneration to necrosis and fibrosis [39, 93, 125, 130, 172,

174, 175, 179]. In the present study, alligator gar showed color changes after diazinon exposure. The severity of liver lesions was dose-related, as was observed in epidermal and branchial tissues.

Liver fibrosis is an accumulation of extracellular matrix proteins that includes collagen fibers. It is the culmination of chronic liver damage following chronic exposure to chemicals [180, 181]. Fibrosis can develop into cirrhosis and at that point the affected tissue can no longer function because blood cannot circulate through the fibrotic area [181]. Alligator gar liver tissue appeared to tolerate long-term exposure to the low level of diazinon. After 30 days, liver lesions were the same as after 15 days of exposure. However, the liver tissue could not tolerate the high diazinon dose, and lesion severity progressed between 15 and 30 days of exposure.

Little is known about the nature and function of rodlet cells [182]. It is suggested these cells play roles in intracellular non-specific immune responses [183, 184]. Rodlet cells are induced in response to chronic tissue inflammation in tissues or sub-lethal toxicant exposure [182, 184, 185]. In this study, we observed rodlet cells in the bile duct wall in only fish exposed to the high dose for 15 and 30 days, and this could be as a result of chronic hepatic inflammation.

Melanomacrophages centers in fish increase in size and number after exposure to environmental pollutants [23, 128, 129, 132, 186], and we previously reported aggregations of hepatic MMCs in gar exposed to crude oil [22]. In this study we saw significant increases in the number of hepatic MMCs after 30 days exposure to the low dose, and significant increases in the number and size of MMCs after 15 and 30 days exposure to the high dose.

In fish, the kidney is the equivalent of bone marrow in mammals, and it is well documented that pollutants induce histopathological alterations in fish kidney tissues [17, 187]. In this study, we observed eosinophilic infiltration with vacuolar degeneration in kidney hematopoietic tissues of exposed fish. The severity of lesions was correlated to diazinon dose. The vacuolar degeneration could be due to glycolytic processes, and it could lead to further damages and dysfunction in kidney hematopoietic tissues. These findings are similar to what we have reported in another study in gar exposed to crude oil [22], and also in other fish in different studies [93, 188].

4.5 Conclusion

This study demonstrated the long-term presence of diazinon in aquatic environments could lead to significant histopathological alterations in the skin, gills, liver, and kidney tissue of alligator gar. These changes may result in severe physiological impairment in the health of these fish. These results also demonstrate the importance of histopathology for evaluating the effect of pollutants in aquatic environments.

CHAPTER V
AN INVESTIGATION OF PLASMA ACETYLCHOLINESTRASE ACTIVITY IN
ALLIGATOR GAR (*TRACTOSTEUS SPATULA*) FOLLOWING CHRONIC
EXPOSURE TO DIAZINON FOR 30 DAYS

5.1 Introduction

The liver receives the first pass of any absorbed chemical, and detoxification occurs in this tissue. Each fish species has different metabolic enzyme levels in liver tissue, and the differences between these enzyme levels determine if the fish is more sensitive or less sensitive to a chemical [72-75]. Acetylcholine (ACh) is the main neurotransmitter in the nervous system, and is located at neuromuscular junctions, synapses in the ganglia of the visceral motor system, and at a variety sites within the central nervous system. [189, 190].

ACh plays an important role of signal transmission in the nervous system. In order to stop these signals from continuing, the brain will release acetylcholinesterase (AChE) in the cholinergic synapses. As a result, AChE will degrade ACh, and the signals will be stopped. In case of diazinon exposure, diazinon and its metabolites will attach to AChE and prevent it from degrading ACh [40, 95, 96, 189, 190].

There are two different types of cholinesterases (ChEs); (AChE) and Butyrylcholinesterase (BuChE). In general, AChE is found mainly in brain and red blood cells, while BuChE is found in high concentration in brain, pancreas, intestinal, and plasma.

However, AChE in fish is found mainly in liver and brain tissues, while BuChE is found mainly in blood plasma and liver tissue [191]. Furthermore, AChE activity is used as a biomarker indicator for post-exposure to organophosphate pesticides, and it is commonly used method in fish and other animals [192-195]. This study was designed to determine the possibility of measuring AChE in blood plasma as it is never been measured before, and to assess the effects of two different concentrations of diazinon on plasma AChE activity in alligator gar (*Atractosteus spatula*) after 30 days exposure.

5.2 Materials and methods

5.2.1 Chemicals and experimental animals

Diazinon (99% pure) was obtained from Chem Service Inc website (<https://www.chemservice.com>). Thirty two alligator gar (*Atractosteus spatula*) were used in this experiment, weighing 773.9 gm and 53.8 cm in length. Fish were obtained from Louisiana State University, and were from broodstock from coastal Louisiana, and held in fresh water at the Mississippi Agriculture and Forestry Experiment Station, South Farm Aquaculture Unit. Then, fish were transferred to the Basic Science Department, College of Veterinary Medicine, and placed in stainless steel tanks where the experiments were conducted. Fish were acclimated for 10 days prior to starting the experiment. All fish were subjected to natural light, and they were fed pellet food (45% protein) (Rangen Inc. /<https://www.rangen.com>) once a day.

5.2.2 Experimental water and stock solution

Each tank was filled with 350 liter well water, and air stones were placed in each tank during each experiment. Water in each tank was changed every day to maintain

water quality. Water temperature in each tank was maintained at 21 ± 2 °C using heaters; dissolved oxygen 7.3 ± 0.2 , pH 7.5 ± 0.2 , and the readings were taken twice a day.

125 µL pure diazinon was dissolved in 25 ml of 100% ethanol to make the stock and used for each experiment, and concentrations were calculated for each treatment. Fish in control tanks were exposed to 3.5 ml ethanol only with diazinon. A pilot study was conducted first to determine the sub-lethal dosages by measuring AChE inhibition, and we used different concentrations starting from very low levels (0.00075, 0.001, and 0.01 mg/L diazinon) to higher levels (0.1 and 1 mg/L diazinon). The goal was to keep AChE inhibition level below 25% so that fish would not die before the end of each experiment. Based on the results from the pilot study we have determined the concentrations for each of the actual experiment. Stainless steel tanks were used to avoid any reaction between the chemical and tank material. The MSU Institutional Animal Care and Use Committee approved fish holding and experimental protocols (protocol # 15-078).

5.2.3 Chronic exposure

After 10 days of acclimation period, fish were exposed to 0, 0.01, and 0.1 mg/L diazinon for 30 days. Eight separate tanks were used; two control tanks with no chemical for total of two replicates, and six other tanks were used for each concentration for total of three replicates per treatment. Four fish were placed in every tank, and each tank was cleaned every day, refilled with clean water and new fresh chemical was added as well. Tanks were cleaned by removing one plug and draining approximately 80% of the water and adding clean water and letting this process continue for about 8 minutes so that the remaining 20% will be eventually drained. Fish in control tanks were exposed to 3.5 ml

of 100% ethanol every day after cleaning each tank. Fish status were visually monitored for about 10 minutes, 5 times a day, and any change or abnormal behavior was recorded during each experiment based on monitoring control fish. In addition, water quality was monitored throughout the experiments for metabolic accumulation waste including nitrate, ammonia, and also to maintain the concentration of the added chemical.

5.2.4 Blood sampling and biochemical assay

In the end of each exposure time, fish were individually netted out and placed in a small tank containing a solution of anesthetic (500 mg/L tricaine methanesulfonate MS-222), and then fish were wrapped and cleaned with paper towels to remove mucus before collecting blood samples. Blood samples were collected through the caudal vein by an evacuated blood collection system containing sodium heparin to prevent the blood from clotting. All blood samples were placed on ice during sampling time and were centrifuged for 10 minutes at 16000 g to separate the plasma; plasma was transferred from each tube to a new labeled tube and placed in a freezer at -80°C to be processed later. Plasma AChE activity was determined for each fish by modification of the Ellman method [196]. All samples were run in duplicate with one blank tube containing 10 µl eserine. 1 mL of Tris HCL buffer-pH 7.4 was pipetted out into a test tube, in 50 µl of thoroughly mixed plasma sample and placed in a water bath at 25°C for 10 minutes. The reaction started by adding 10 µl of acetylthiocholine (AtCH) as substrate to each tube, vortexed and placed back in the water bath at 25°C for 15 minutes incubation. The reaction was stopped by adding 125 µl of a 1:5 ratio of 5'-Dithiobis-2-nitrobenzoic acid (DTNB) as the chromophore, 5% sodium dodecyl sulfate (SDS) and vortexed. All

samples were transferred to cuvette tubes, and the absorbance was taken for each tube at 412 nm. All readings were recorded for all tubes.

5.2.5 Statistical methods

Data were analyzed by analysis of variance (ANOVA) using SAS statistical package (SAS Institute Inc., Cary, NC) followed by mean separation by least squared means. Data from four fish were pooled into each replication for statistical analysis. Data are presented as mean \pm standard error and the level of significance was $p < 0.05$.

5.3 Results

Fish swam normally during the acclimation period, but after one week of exposure, fish exhibited stress signs such as producing massive amount of mucous. This was observed as the water became gooey while we have not observed this condition in control tanks. By the beginning of the second week of exposure, they became motionless and stayed at the same area for prolonged time, and they developed lighter skin color. No death occurred during the study, and there was no change in fish appetite. Plasma AChE activity was significantly different between control and exposed groups of fish (Table. 5.1). Fish exposed to either concentration had significant reduction in AChE activity when compared to the control fish (Fig. 5.1). Moreover, the percentages of AChE inhibition were 61.9 and 71.7% in fish exposed to 0.01 and 0.1 mg/L diazinon, respectively.

Table 5.1 Plasma AChE activities in control and exposed fish.

Treatment	N	Mean	SD
0 mg/L	8	2.72	0.10
0.01 mg/L	12	1.03*	0.17
0.1 mg/L	12	0.77*	0.25

N is number of fish, SD is standard deviation, asterisks (*) indicate significant differences.

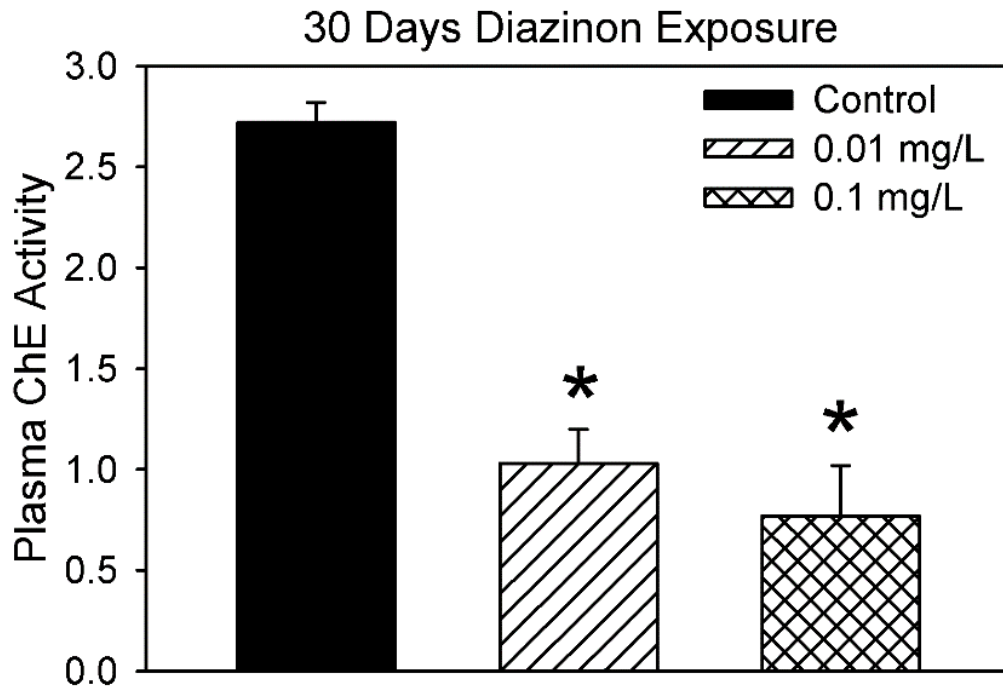


Figure 5.1 Effect of diazinon on plasma AChE activity (nmol min⁻¹ mg protein⁻¹) in blood plasma of alligator gar exposed daily to 0 (control), 0.01, and 0.1 mg/L diazinon for 30 days.

(*) indicate significantly different values compared to control values.

5.4 Discussion

The presence of chemicals in the aquatic environment can have significant impacts on fish health [22, 23, 169, 170]. Chemicals that are known as environmental contaminants, such as cadmium and heavy metals, can affect AChE activity in fish [78, 79, 96, 195, 197-201]. In this study, we found a significant inhibitory effect of long-term exposure to sub-lethal concentrations (0, 0.01, 0.1 mg/L) of diazinon on AChE activity in alligator gar (*Atractosteus spatula*). Previous studies have reported similar findings [70, 193-195, 202-206]. Most of these studies investigated the effect on the brain, and liver AChE activities after short term exposure to high levels of diazinon. It is been reported that AChE in fish is found mainly in brain and muscle tissues [191]. In this study we were able to detect AChE activities in all plasma samples from control and fish exposed to either concentration. A study conducted to assess the effects of various pollutants on spotted gar (*Lepisosteus oculatus*) in the lower Mississippi River Basin revealed a significant decrease in AChE activities in brain and liver samples [195]. In this study, AChE activity values were significantly lower in fish exposed to 0.01 (1.03 nmoles/ mg protein) and 0.1 mg/L diazinon (0.07 nmoles/ mg protein) after 30 days when compared to the values from control fish (2.72 nmoles/ mg protein). This is due to the inhibition of AChE induced by diazinon.

Our results indicated that AChE activities varied based on diazinon levels, and it was much lower in fish exposed to 0.1 mg/L diazinon than in fish exposed to 0.01 mg/L diazinon. A similar study revealed that juvenile alligator gar exposed to diazinon for 96 hours had significantly decreased AChE activity in liver samples, and the sensitivity of gar to pollutants was affected by fish age [70]. In contrast, in this study we used lower

doses of diazinon and older alligator gar, and our results showed greater reduction in plasma AChE activity. Moreover, our findings in this study are similar to a previous study that showed 70% plasma AChE inhibition in rainbow trout after diazinon exposure to 0.1 mg/L for 28 days [101]. This work has been previously published [207].

5.5 Conclusion

Our results show that the toxicity of diazinon to alligator gar, *Atractosteus spatula* for prolonged period has a significant factor affecting AChE activity in blood plasma. AChE decreased in fish exposed to the high dose suggesting a correlation between AChE inhibition and diazinon concentration. This is the first study to measure AChE activity in fish plasma, and this could be unique to alligator gar. Further investigations need to be done using different fish species. Our findings indicate that determining AChE in blood plasma of alligator gar can also be used to interpret pesticide presence in aquatic environments.

CHAPTER VI
FINE STRUCTURE OF THE GAS BLADDER OF ALLIGATOR GAR,
ATRACTOSTEUS SPATULA

6.1 Introduction

Fish need energy to perform different tasks such as swimming, growth, digestion, and reproduction. Also, they need oxygen and some organic substrate to extract energy from food to be able to power these functions [47]. Over time, fish have been evolving to cope with hypoxic water in different ways, and around 374 fish species in 49 families have been described as air breathing fishes [2]. Some fish species swim close to the surface of the water to inspire the oxygen-rich water while other fish species evolved their ability to breathe air using the air breathing organ (ABO) or gas bladder [208].

Air breathing fish is a term used to describe fishes that have the ability to breathe using gills in water, and can also breathe in aerial environments using ABO [2, 47]. Air breathing fish are bimodal breathers, especially in hypoxic environments [48]. Alligator gar, *Atractosteus spatula*, are bimodal air breathing fishes that can utilize branchial and ABO respiration simultaneously [2]. Also, gars require more than one respiratory surface actively participates at the same time [2].

In general, air breathing fishes have a single, elongated bag structure located dorsally to the body lumen. It is divided by a central canal into left and right lobes, and they are all contained within a very thin wall [2, 54, 67, 209]. Each lobe is divided into

many pairs of trabeculae subdividing the lateral sides of the gas bladder into 30 compartments which they all open onto the central duct [2]. These compartments provide large vascularized area for gas exchange [139]. There is also abundant smooth and skeletal muscle throughout the gas bladder. It is attached to the body wall by dorsal retractors, allowing for contraction. Some studies suggested a neural control over the air breathing organ for gas secretion and resorption [58, 209, 210].

Overall, there is a gap that needs to be explored on the histology of the alligator gar air breathing organ and its ability to utilize the atmospheric air for respiration, yet it has received little attention. Also, there is a controversy surrounding the presence of the pneumatic duct that connects the ABO with esophagus in gars. In order to define the function and the similarity between this organ and fully functional lungs in Amphibians; this chapter will be focusing on studying the normal histological structure of the gas bladder of alligator gar, *Atractosteus spatula*, and investigate the existence of the pneumatic duct, via light and electron microscopy. New data have been reported in this chapter for the alligator gar ABO.

6.2 Materials and methods

6.2.1 Animals

Nine alligator gars weighing 318- 320 gm and measured 42.5- 43 cm in length were obtained from a local supplier (Private John Allen National Fish Hatchery). Fish were acclimated to water conditions for 6 months at the Mississippi Agricultural and Forestry Experiment Station South Farm Aquaculture Facility, Mississippi State University following published methods [211]. All fish were placed in an overdose of anesthetic (500 mg/L tricaine methane sulfonate) individually. The gills, body wall and

other viscera were removed in order to analysis the gas bladder and pharyngeoesophageal junction.

6.2.2 Light microscope

Samples were rinsed in physiological saline and fixed in phosphate buffer 10% formalin. Tissues were processed and embedded in paraffin wax, sectioned at 4 μ m, and stained with hematoxylin and eosin (H&E) and Alcian blue stain, and immunohistochemistry for smooth muscle actin. All slides were viewed under light microscopy, and photographed on Olympus BX 51 (Olympus America Inc.) using Picture Frame™ software.

6.2.3 Transmission electron microscopy (TEM)

Samples were initially fixed in 2% glutaraldehyde in cacodylate buffer (0.1 M phosphate buffer, pH 7.2), and then post fixed in 2% osmium tetroxide at 4°C. Samples were dehydrated in solutions of increasing ethanol concentration started from 35% to 100% ETOH, and then in solutions of increasing acetone concentration. Finally, samples were embedded in Spurr's resin, and ultra-thin sections (75 nm) were made from each block by using Reichert Jung ultra-microtome, stained with toluidine blue stain for thick sections and uranyl acetate and lead citrate for the ultra-thin sections [212, 213]. All sections were viewed under transmission electron microscopy on a JEOL JEM-1230 at 80kV.

6.3 Results

6.3.1 Gross morphology

The alligator gar gas bladder is a large, dorsoventrally flattened, elongate organ that is intimately associated with the musculo-skeletal tissues of the dorsal coelom along its entire length and width (Fig. 6.1A, G). The bladder originates at the abrupt termination of the pharyngeo-esophageal duct (Fig.6.1D, asterisks), and is attached to the body wall by paired slender collagenous folds that run along its entire length on either side of the vertebral column, blending into the stroma that surrounds the aorta and cardinal veins associated with the mesonephros (Fig. 6.1G). The width of the gas bladder is proportional to the width of the body, tapering and terminating at the end of the coelom (Fig. 6.1A, B).

The pharyngeo-esophageal opening arises from the caudal pharynx, between the epipharyngeal teeth, extending caudally to the junction where pharyngeal mucosa blends into esophageal mucosa. It begins anteriorly as a single longitudinally oriented, slit-like opening between the pharyngeal dental pads, extending into the proximal esophagus (Fig. 6.2A). It is delimited by symmetrical fibrous lateral glottal ridges that initially form not only the slightly protruding lips of the slit, but also define the shape of the pharyngeo-esophageal duct lumen caudally, a circumscribed tube (Fig. 6.2C) which is laterally delimited by the same glottal ridges and lined by ciliated columnar epithelium (Fig. 6.2 B, C). The distance between the termination of the slit aperture and the beginning of the gas bladder, the pharyngeo-esophageal duct, averaged 5mm in our specimens, and was comprised of a tubular structure lined by epithelium and surrounded by a complete investment of soft tissue (duct). The duct continues caudally past the slit as a discrete tubular lumen, terminating immediately as the lumen opens into a spacious gas bladder

(Fig. 6.1D, E, F, G). Grossly, the surface margins of the slit are similar to the surrounding mucosa, being slightly thickened and blending imperceptibly into them. The alligator gar gas bladder lies caudal to the abrupt termination of the glottal ridges.

Grossly, the bladder has an extensive vascular supply, with finely arborescent vessels throughout except for a narrow midline strip of poorly vascularized tissue running along its ventral length (Fig. 6.1A, B). This strip delineates a continuous median central canal that divides the organ into symmetrical halves (Fig. 6.1A, B, F). The roof and the floor of this central canal are delicate, flat, fibrous membranes. The roof blends into the fibrous raphe that attaches the organ to the aorta (Fig. 6.1G).

Each half of the gas bladder is subdivided by smoothly interconnected, progressively finer and shorter septa forming first, second, third, and fourth order alveolar chambers (Fig. 6.1C, E, G). Septa tend to have abrupt bulbous terminations composed of dense stroma (Fig. 6.3B). The central canal is laterally delimited by the primary septa, forming an arcade of regular pillars with wide intervening ostia that lead into the gas exchange spaces. The progressing septal order divisions often form oblique angles, with a reduction in septal height by approximately half, finally terminating in low alveoli approximately 1 millimeter wide (Fig. 6.1C, E).




Figure 6.1 Gross pictures for alligator gar air breathing organ.

A: Ventro-dorsal view of the air-breathing organ (ABO), with gills, body wall, and other viscera removed. The head is to the right. Arrow indicates the central lumen, asterisks indicate the air exchange fields. Formalin fixed specimen. **B:** Ventro-dorsal view of the ABO, fresh specimen, and head is to the right. Arrow and asterisks denote features similar to that in A. **C:** Ventro-dorsal view of the ABO, with the ventral half of the organ removed. Head is to the top of the page. Arrow denotes the central canal, dorsal aspect. Asterisks denote primary and secondary septa. Formalin fixed specimen. **D:** Caudo-

rostral view of the ABO, transversely sectioned approximately 2cm from the end of the pharyngeo-esophageal duct. Asterisks denote the termination of the glottal ridges, arrow indicates the gas exchange surface. Dorsum is at the top of the page. Formalin fixed specimen. **E**: Dorso-ventral view of the ventral half of the ABO, with the dorsum removed (opposite portion of the organ compared to C). Arrow denotes the floor of the central canal. Asterisks denote primary septa. Formalin fixed specimen. **F**: Caudo-rostral view of the ABO, transversely sectioned; left lobe (arrow), septa (asterisks), the central canal is completely opened in comparison to figure D. Formalin fixed specimen. **G**: Photomicrograph of a transverse section of the entire ABO, dorsum towards the top. Hematoxylin and eosin.

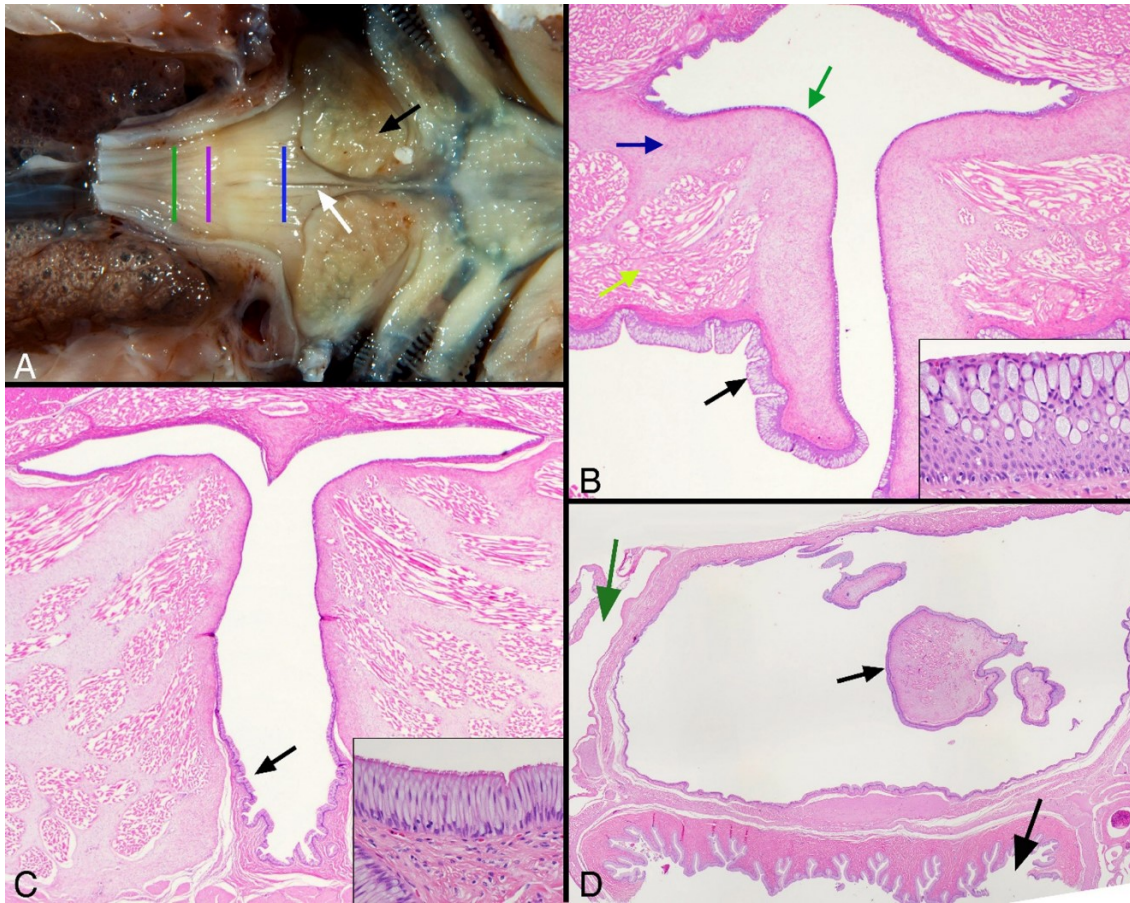


Figure 6.2 Alligator gar, Microscopic pictures for the pharyngo-esophageal duct.

A: Gross view of the dorsum of the pharyngo-esophageal junction, head is to the right, esophagus transected at the left, the ventral portion of the organ removed. Blue line indicates the level of sectioning shown in B. Purple line indicates the level of sectioning shown in C. Green line indicates the level of sectioning shown in D. Formalin fixed specimen. **B:** Photomicrograph, transverse section of pharyngo-esophageal slit denoted by blue line in figure A. A slit-like opening lined by a thick transitional epithelium (black arrow and inset) connects the gut lumen (bottom) to the beginning of the duct (top, green arrow). The glottal ridges are denoted by the green, blue, and yellow arrows, which point to the epithelium, connective tissue stroma, and muscle bundles, respectively. Hematoxylin and eosin, 20x. **C:** Photomicrograph, transverse section of pharyngo-esophageal duct denoted by purple line in figure A. The inner aspect is lined by a tall simple to pseudostratified columnar epithelium (black arrow and inset). The lumen is surrounded on all sides by thick myocollagenous stroma. Hematoxylin and eosin, 20x. **D:** Sub gross photomicrograph, transverse section of pharyngo-esophageal duct denoted by green line in figure A, at the duct termination. The small black arrow indicates the termination of the glottal ridges, as seen in figure 1 D, asterisks. A ring of skeletal muscle and tracts of smooth muscle delimit the duct. The large black arrow denotes the esophagus, the green arrow denotes the air bladder proper, hematoxylin and eosin.

6.3.2 Microscopic morphology and ultrastructure

In the glottis and pharyngeo-esophageal duct, the pharyngeal mucosa is stratified columnar epithelium that varies in thickness, from 100 to 200 micrometers, and predominantly contains large mucus cells (Fig. 6.2B, C). The glottal ridges are the protruding lips of mucosa that guard the entrance to the pharyngeo-esophageal duct. Anteriorly on transverse section, the duct forms a “T”, where a 2 to 3 millimeter long stem dorsally meets a collapsed tubule forming the bar of the “T” (Fig. 6.2B). Progressing caudally as the slit opening ends (Fig. 6.2C), the duct continues to meet the gas bladder proper. Anteriorly, pharyngeal mucosa lines the duct. Initially, a ciliated stratified columnar epithelium (esophageal type) appears in the stem of the duct, becoming the predominant cell type caudally as the duct becomes detached from the ventral esophagus, eventually entirely lining the duct (Fig. 6.2B, C, D).

In the alligator gar pharyngeo-esophageal duct, a thick cushion of mucinous areolar connective tissue containing evenly spread, fine collagen fibrils with plump stellate mesenchymal cells supports the duct mucosae (Fig. 6.2B, C). Subjacent, this stroma blends into dense fascicles of skeletal muscle admixed with small nerves and vessels. A thin layer of transverse and obliquely arranged skeletal muscle bundles overlies the dorsum of the duct, where it abuts the vertebral column, along with symmetrical, anteroposteriorly arranged thick muscle bundles (dorsal retractors).

The floor of the central canal and ventral aspects of the primary septa are lined by a stratified to pseudostratified, ciliated columnar epithelium with a prominent mucus cell component. The mucus cells contain PAS (not shown) and Alcian blue positive content, consistent with acid mucopolysaccharide (Fig. 6.3 I).

Progressing from first to fourth order septa, the epithelium gradually thins, with eventual loss of ciliated cells, giving way to a simple squamous epithelium covering capillaries and relatively few, evenly spaced, attenuated mucus cells (Fig. 6.3 C, D, E). This progression continues with eventual loss of mucus cells in the respiratory exchange surface (respiratory epithelium) (Fig. 6.3E, F, G) (Fig. 6.5A). This progressive epithelial change also occurs centrally to the periphery, where respiratory epithelium covers all alveolar surfaces; typical pneumocytes occur here. The respiratory surface is covered by irregular microvilli on squamous cells (Fig. 6.4A, B, C). Electron micrographs demonstrate that squamous cells contain numerous lamellar bodies with stacked content (Fig. 6.4C). Intercellular connections are composed of tight junctions and desmosomes with marked invagination of both adjacent cell membranes. Nuclei are irregular with a distinct thin rim of heterochromatin, abundant euchromatin, and prominent nucleoli (Fig. 6.4A, B, C) (Fig. 6.5A).

Mucus cell content was hyperchromatic (Fig. 6.4A, B, C). Mucus cells lining alveoli and septal walls included occasional neuroendocrine cells (NE) either between cells or along the basal aspects (Fig. 6.4A). Neuroendocrine cytoplasm contained many dense uniform granules approximately 100 nm wide. Occasionally, NE cells were present in small tightly packed groups associated with nerves (neuroepithelial bodies-NEBs) (Fig. 6.5B).

The central canal, septa, and alveoli consist of a similar subepithelial stroma, composed of a thin layer of densely packed collagen fibers with fibroblasts and small blood vessels. The bulk of the septa, in particular the bulbous terminae, are composed of densely packed, irregularly arranged fascicles of striated skeletal muscle (Fig. 6.3I).

Smooth muscle is also prominent, investing septal skeletal muscle bundles with particular prominence along their proximal aspects (Fig. 6.3H). Unlike skeletal muscle, smooth muscle is present throughout the stroma at all levels, and in general, forms delicate fascicles and individualized cells that admix with connective tissues. Muscle content gradually decreases caudally and peripherally.

Vessels, nerves, and unmyelinated axons run along the apical portions of the septal terminae, typically subjacent to the muscle bundles (Fig. 6.3A, B, F, G, I) (Fig. 6.4A, D) (Fig. 6.5C, D). Capillaries are regularly nestled between epithelial cells and are covered apically by thin extensions of epithelial cells, forming an air-blood barrier approximately 1 micron thick (Fig. 6.4A, B). The endothelium is continuous, overlying a collagenous lamina. Endothelial nuclei are located away from the surface, and have irregular nuclei with rims of heterochromatin (Fig. 6.4A, B). Within the delicate stroma of the floor of the central cavity, regular paired ganglia travel along the length of the organ bilaterally. Progressively smaller nerves, without neurons, are present in the septa as they become finer. There are few small, random aggregates of lymphocytes that surround blood vessels and encroach on the epithelium, with occasional areas of epithelial intercellular migration.

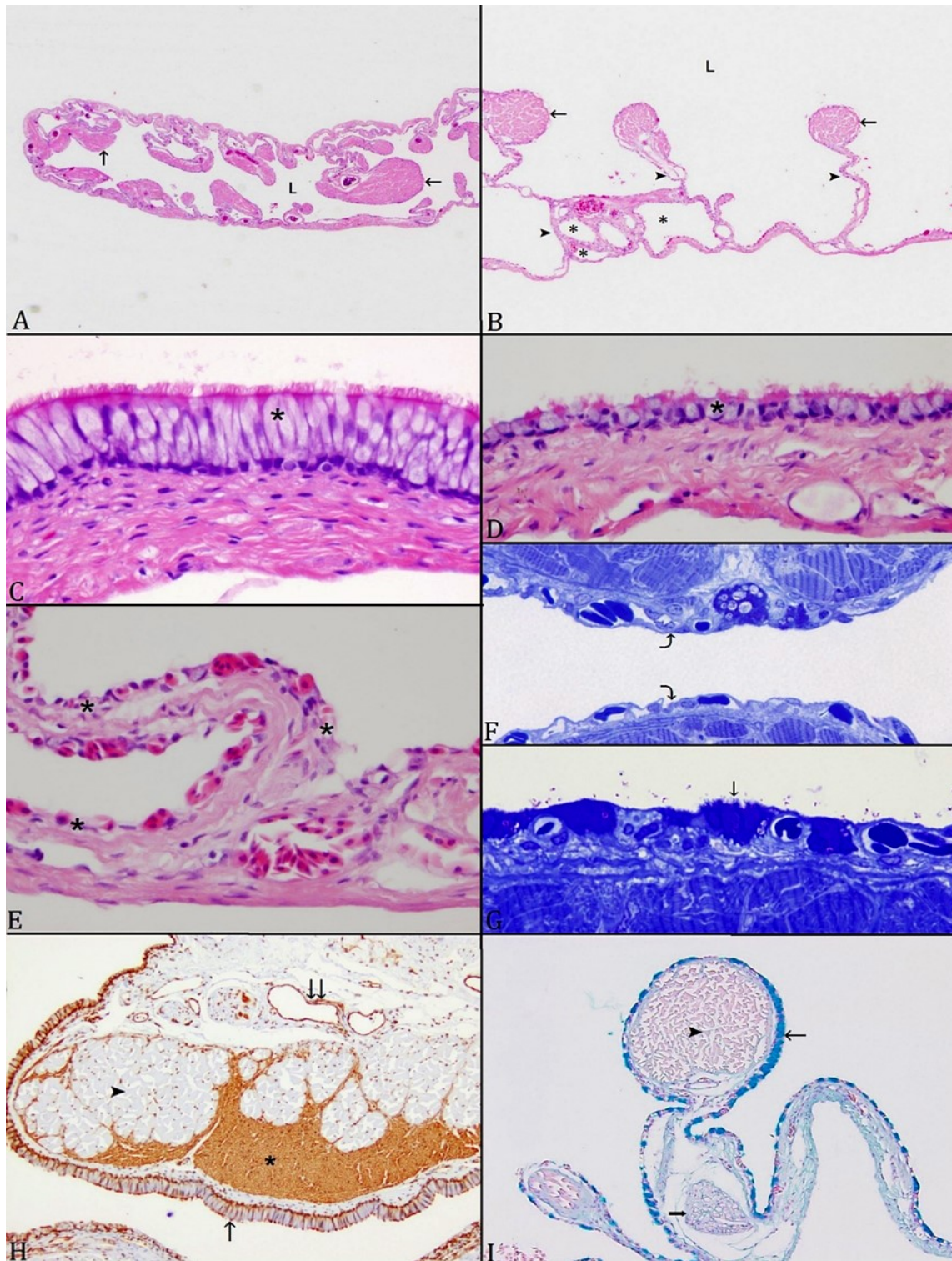


Figure 6.3 Multiple views of alligator gar air breathing organ with different stains.

A: An overview of the left lobe shows the lumen and septa. Septa are composed of striated muscles, blood vessels, and forms bundles (arrow) that are projecting toward the

lumen; lumen (L). **B**: Each lobe is subdivided into different levels of air spaces (asterisk) by series of septa (arrowhead); bundles of striated muscle are in the apical portion of septa (arrow). **C** and **D**: The internal surface is lined by a stratified to pseudostratified, ciliated columnar epithelium with prominent mucus cell components (asterisk). **E**: The internal surface gradually changes to simple squamous epithelium rich with blood vessels (asterisk) (curved arrow). **F**: resin toluidine blue stain section showing the same G: Simple squamous epithelium rich with blood vessels with few, evenly spaced, attenuated mucus cells (arrow); resin toluidine blue stain section. **H**: Cross section stained with smooth muscle actin stain; smooth muscle (asterisk) is highlighted by the antigen, and interdigitates with striated muscle (arrowhead); veins are also lined by smooth muscle (double arrow). The internal surface is lined by a stratified to pseudostratified, ciliated columnar epithelium with prominent mucus cells components (arrow). **I**: Mucus cells contain Alcian blue positive content (thin arrow), striated muscles (arrowhead); nerve fiber (thick arrow); (Alcian Blue stain).

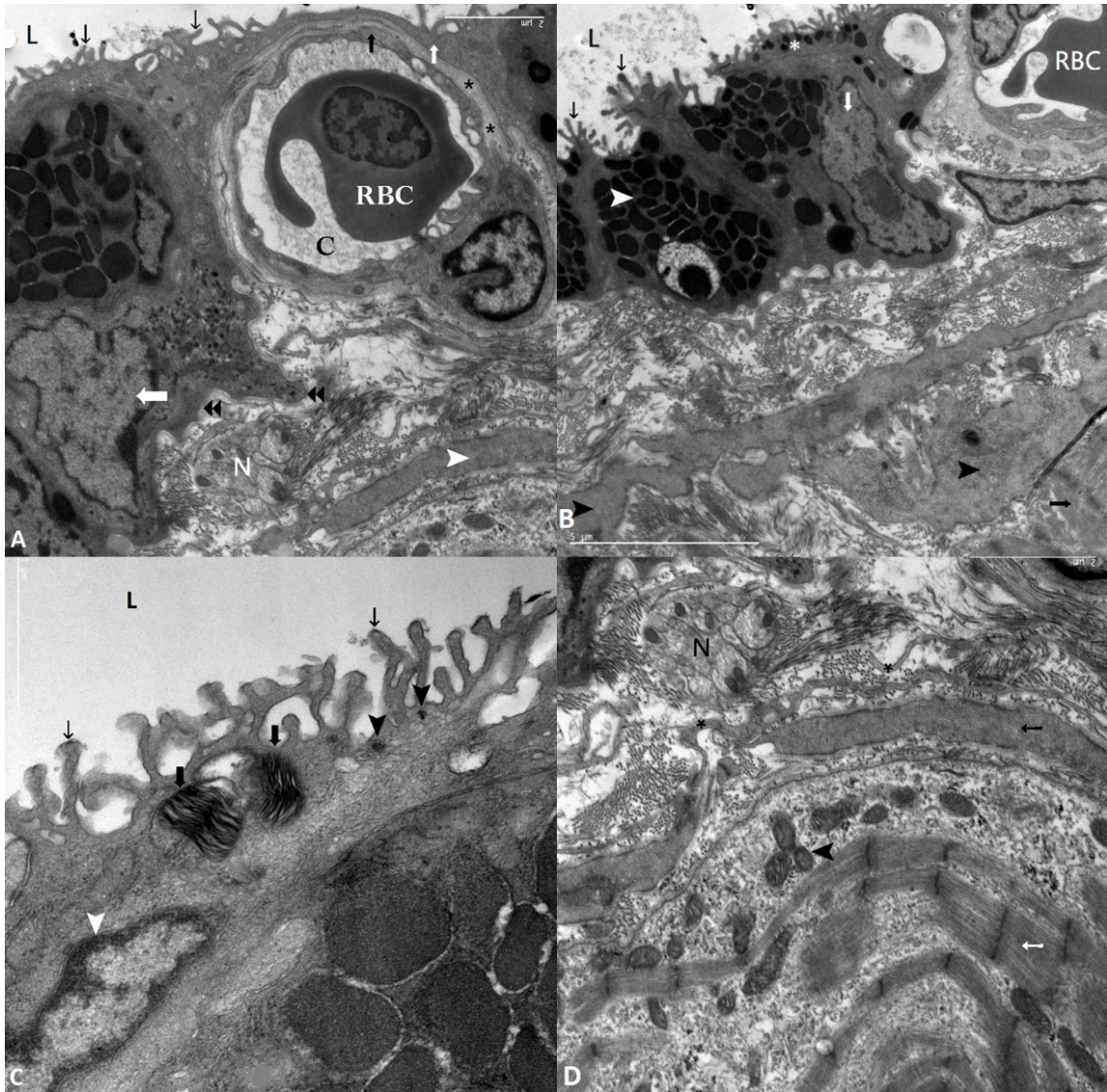


Figure 6.4 Alligator gar; transmission electron micrographs of the gas bladder.

A: The capillary barrier in the respiratory epithelium consists of an outer microvillus border (thin black arrow) with a thin cytoplasmic layer (thin white arrow), overlying a capillary (C) with a continuous endothelial lining (black arrow) and interstitial layer in between (asterisks). A red blood cell (RBC) is present in the lumen. The thin white arrowhead indicates smooth muscle with filament bundles. A nerve fiber (N), and a neuroendocrine cell (delimited by black arrowheads and thick white arrow indicates nucleus) are present. **B:** The gas bladder epithelium includes mucus cells (white arrowhead) and epithelial cells with numerous microvilli (thin black arrow); mucus nuclei (white arrow). L denotes the lumen. A red blood cell (RBC) is in the capillary. Multilamellar bodies (white asterisk) are located in the apical part of the respiratory epithelium. Smooth muscle cells (black arrowheads), and striated muscle (black arrow) are present within a loose collagenous stroma. **C:** The apical region of the epithelium

includes multilamellar bodies (thick arrows), lumen (L), dense bodies (black arrowheads), microvilli (thin black arrows), and a pneumocyte nucleus (white arrowhead). **D:** (Overlapping field with A) The lamina propria is composed of loose collagenous stroma populated by smooth muscle (black arrow) and striated muscle (white arrow) with prominent mitochondria (arrowhead). Nerves (N) are separated from the other components by fibroblast extensions (asterisk).

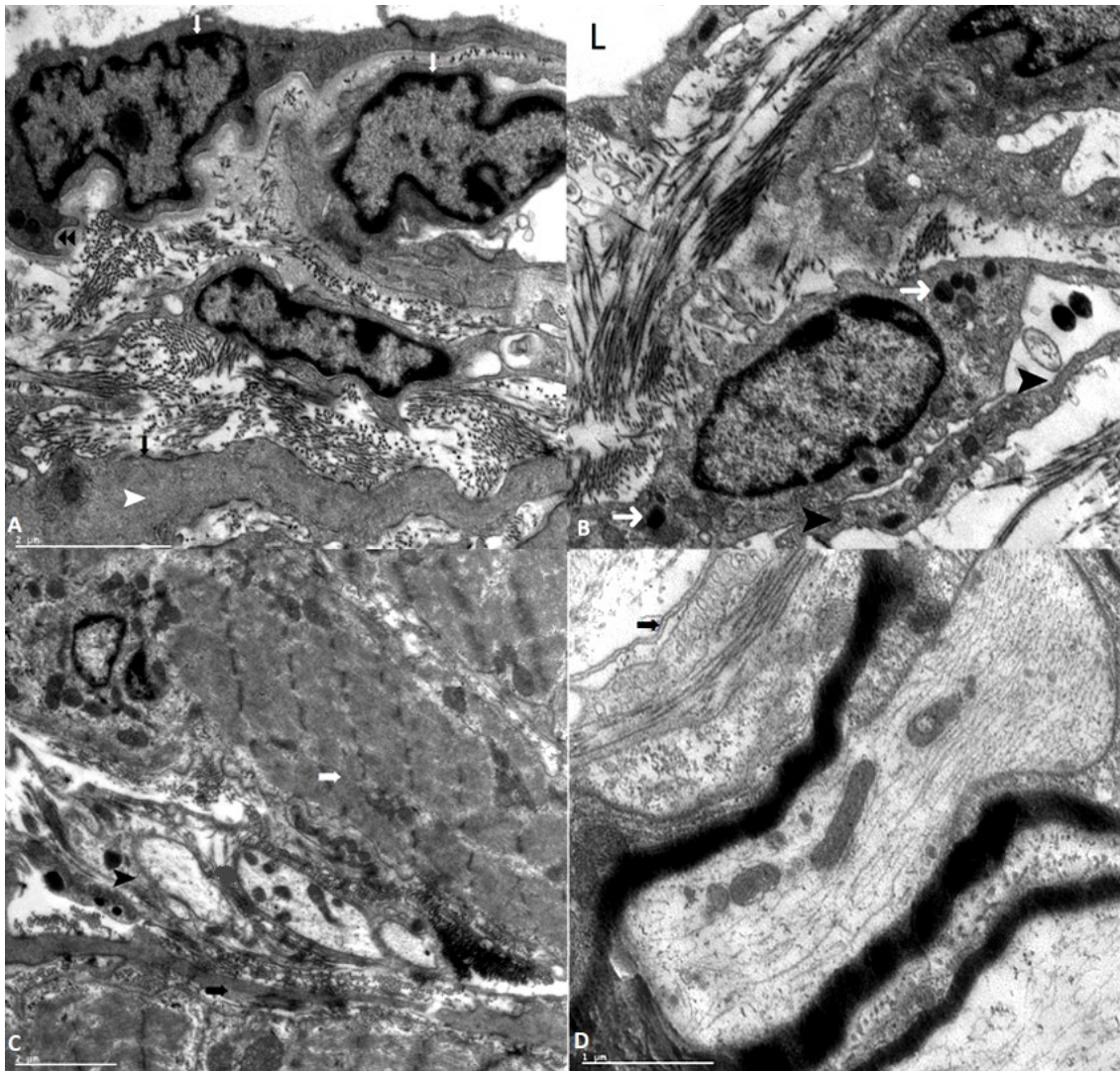


Figure 6.5 Alligator gar; transmission electron microscope (TEM) micrographs of the ABO.

A: The white arrows indicate the pneumocyte nucleus adjacent to the border of the epithelium. The double arrowheads indicates the basal cytoplasmic extension just beneath them. Filament bundle of smooth muscles (white arrowhead) show subplasmalemmal condensations (black arrow). **B:** This TEM micrograph shows the neuroendocrine cell with dense bodies/ granules (white arrow) in its cytoplasm, and the neuroendocrine is embraced with an extension of fibroblast (black arrowhead). Lumen (L). **C:** Unmyelinated axons (arrowhead) located between smooth muscles (black arrow) and striated muscles (white arrow). **D:** TEM micrograph under higher magnification shows the unmyelinated axons that are embraced by the fibroblast (asterisks).

6.4 Discussion

In air breathing fish, the general description of the gas bladder, or ABO, is an unpaired oval elongated structure arising from the posterior side of the pharynx and connected to the pharynx. It is located dorsal to the body lumen, and consists of a central canal that occupies a third of the gas bladder, and two lobes that are covered with a very thin tissue wall [2, 4, 54, 67, 134, 209]. Our findings in alligator gar were similar, the gas bladder was a large elongate organ with progressively finer and shorter septa forming first, second, third, and fourth order alveolar chambers and a central canal. The gas bladders of other air breathing fish are also described to have trabeculae dividing the gas bladder into compartments and a central canal [2, 139]. The alligator gar, *Atractosteus spatula*, gas bladder is medially divided into two alveolate portions by a central canal lined by abundant ciliated epithelium, similar to bowfins and other gar species ([54, 58, 138]. The location and abundance of ciliated cells suggests that these tissues function as a pulmonary escalator and move cell and foreign debris to the duct and then out into the pharynx.

Numerous mucus cells and surfactant bodies were identified in the respiratory epithelium, similar to that seen in spotted gar, *Lepisosteus oculatus* [54]. The mucus content in mucus cells was an acid mucopolysaccharide, similar to that seen in non-respiratory airway surfaces in reptiles and mammals. Microvilli were abundant on the gas bladder surfaces of alligator gar, as was a secreted mucus barrier. We believe the function of the microvilli, or ciliated cells, is to secrete mucus to protect the internal surface of the gas bladder, as has been suggested in other gar [214].

Throughout the organ, smooth and skeletal muscle fascicles were abundant, giving strength to this delicate, well-vascularized organ. The muscle fascicles were often intimately associated with one another. The intermediate layer of the *Lepisosteus* gas bladder was described to consist of striated muscle, smooth muscle, fibroblasts, and elastic fibers [67]. We observed nerve bundles in the connective tissue of the alligator gar gas bladder. These findings were also reported in the spotted gar gas bladder [54]. Nerve fibers were also found in the walls of the ABO of bichir (*Polypteridae polypterus*) and gars [215, 216].

The nature of the opening to the gas bladder is debated in gars [54, 138]. It has been anatomically described in multiple *Lepisosteus* species [2, 54, 58, 138]. There is one brief description of a pneumatic duct in Cuban gar, *Atractosteus tristoechus* [217]. Recent work in spotted gar, *L. oculatus* and longnose gar, *L. osseus* conclude that, in *Lepisosteus*, the alimentary canal opens into the gas bladder through a slit-like opening and that a discrete tubular structure, or “duct” is lacking [54, 138]. In our study, we found that alligator gar have a pharyngeo-esophageal duct. It is anteriorly delimited by a slit-like opening and a slender aperture that continues as an epithelium lined lumen within a tubular structure circumscribed by connective tissue. This location is similar to the gas bladder opening described in spotted gar, [54] Unlike longnose gar in which the gas bladder gradually widens from a narrow anterior point, the gas bladder in *A. spatula* begins where an abrupt termination of the glottal ridges of the pharyngeo-esophageal duct opens into a fully dilated, alveolated gas bladder with squamous respiratory epithelium. This epithelium is continuous with the central canal of the gas bladder. The glottal ridges of alligator gar are similar to those described in spotted gar and longnose gar [54, 138].

The presence of robust paired dorsal retractor muscles is also similar, and may control the size of the glottal opening.

In *Lepisosteus*, the interior surface of the respiratory epithelium is ciliated and lined with lamellar bodies and goblet cells [67]. In mammals, respiratory alveolar surfaces are lined by type I and type II pneumocytes. Type I cells are simple squamous cells, and type II cells are cuboidal [210, 218-220]. Type II cells are associated with surfactant production and retain the capacity to divide, functioning as a source for new type I cells. Our study suggests that *Atractosteus* have one type of pneumocyte that probably combines the functions of mammalian type I and II pneumocytes. This pneumocyte was similar to the amphibian pneumocyte described by Pastor [210]. Amphibians, Dipnoi (lungfish), and *L. oculatus* (spotted gar) also have one type of pneumocyte [210]. We also observed some pneumocytes that appeared to have cytoplasmic processes. Similar cells were seen in the respiratory epithelium of some amphibians [221-223]. Neuroepithelial cells occur between the pneumocytes and goblet cells in amphibians and *Lepisosteus* [209, 210].

In alligator gar, we observed that neuroendocrine cells (NECs) are located between epithelial cells, and also between the mucus cells and ciliated cells in the respiratory epithelial cells as neuroepithelial bodies (NEBs). Similar results were observed in spotted gars and long nose gars [54, 58]. The presence of neuroendocrine cells suggest neuronal control of the gas bladder [58, 209].

The internal surface of the Alligator gar gas bladder is rich in ciliated cells that are irregular in shape, and project toward the lumen of the gas bladder. These ciliated

cells reduce the area available for respiratory exchange. Similar distribution of these ciliated cells have been observed in spotted gar and amphibians [54, 222, 224].

Alligator gar neuroendocrine cells were similar to those observed in the ABO of other gars. Neuroendocrine cells (NECs) were pyramidal and occurred in the basal portion of the respiratory epithelium. These cells were characterized by the presence of dense secretory granules, Golgi bodies, rough endoplasmic reticulum, and scattered numbers of mitochondria in the basal part of the cell [210]. The presence of neuroendocrine cells in the gas bladder indicates endocrine and paracrine control over bladder function [58, 209, 210]. Neuroepithelial bodies and NEs are surrounded and invested by ciliated cells, goblet cells, and pneumocytes [58, 209, 210].

The alligator gar air breathing organ is a single air sac that emerges from the dorsal margin of the foregut, while amphibian lungs are paired organs that emerge from the ventral margin of the foregut [134, 222]. There are many similarities in the anatomy and histology of the gar ABO and amphibian lungs [54]. The alligator gar ABO has series of air spaces similar to the lung, but it lacks the bronchial tree that is observed in lungs [225, 226]. The structure of the alligator gar ABO is very similar to the ABO of the genus *Lepisosteus*. Alligator gar inhabit coastal estuaries that are prone to agricultural and petrochemical pollution. One study reported that *A. tropicus* (tropical gar) and *L. oculatus* (spotted gar) had higher tissue PCB concentrations than other fish in waters that had low, acceptable levels of contaminants [227]. Therefore, these fish are an excellent sentinel model for studying the effects of pollutants on aquatic ecosystems. This work has been previously published [177].

6.5 Conclusion

Alligator gar have a functional air breathing organ that is well developed, and it is like the lung in the higher vertebrates. Possessing such a respiratory organ will make this fish more capable of living in water under severe hypoxic conditions, and it is essentially adaptive in nature, supplying oxygen for vital functions. At the same time, gars still have fully functional gills for aquatic respiration, and both the gas bladder and gills participate in gas exchange in aquatic and aerial environments.

CHAPTER VII

CONCLUSION

Alligator gar are primitive fish that inhabit tributaries of the lower Mississippi River Valley and the Gulf Coast from Florida to Texas and Mexico. Their numbers have been greatly reduced by over fishing and habitat destruction. Many fish biologists believe this fish can be effective as a biological control for invasive Asian carps, and there is much interest in the biology of this fish. However, little is known about the alligator gar. Its swim bladder, which functions as a primitive lung, had not been described before this project. Following the Gulf oil spill, wild alligator gar blood parameters were not affected by oil exposure, presumably because it could avoid the oil and breathe air [23]. However, in a laboratory setting oil exposure resulted in lymphopenia and reduced granulocyte numbers in hematopoietic tissue [22]. Other anthropogenic factors, such as accumulated low levels of pesticide run-off, can negatively impact this fish. To better understand how environmental factors can affect alligator gar populations, this study utilized chronic, sub-lethal levels of diazinon to simulate environmental exposure that would occur in slow-moving waters in agricultural areas. This is the type of environment gar usually inhabit. The lower level used in this study has been documented in natural waterways.

We found that fish exposed to sub-lethal levels of diazinon demonstrated lighter color and inactivity. Changes in swimming activity could negatively impact the predatory

behavior and reproduction of alligator gar. A lighter skin color could negatively impact the life history of alligator gar.

Cranial and torsal epidermal lesions developed in fish exposed to diazinon for 15 days and 30 days, but the torsal epidermal lesions occurred only on the left side in fish exposed to the higher dose. The mechanism leading to these site specific lesions is unknown. The microscopic findings in this study revealed histopathological alterations in different tissue organs including liver, kidney, skin, and gills. The skin lesions ranged from loss of the epidermal and dermal layers to severe inflamed, congested, and necrotized muscles especially in exposed fish for 30 days. The gill tissues demonstrated epithelial hyperplasia in fish exposed to the low dose, and epithelial hyperplasia and fusion in the secondary lamellae in fish exposed to the high dose for 30 days. This is a typical reaction of fish gills caused by an environmental irritant. Liver tissues appeared to tolerate long-term exposure to the low level of diazinon. After 30 days, liver lesions were the same as after 15 days of exposure. However, the liver tissue could not tolerate the high diazinon dose, and lesion severity progressed between 15 and 30 days of exposure. Liver pathology demonstrated the tissue was damaged by chronic diazinon exposure. This exposure also caused damage to the kidney hematopoietic tissue, which is the likely cause of the blood changes.

Sub-lethal diazinon exposures resulted in dose-related decreases in hemoglobin and hematocrit values, and lymphopenia. This reduction in lymphocyte count suggests that these fish were stressed and immunocompromised. These changes will alter the functions of the immune system and increase the risk of infectious diseases.

Liver lesions induced by diazinon exposure can affect the ability of gar to metabolize toxins, resulting in a cycle of physiological stress. Our study showed that long term exposure to diazinon significantly inhibited plasma AChE in alligator gar. This inhibition was dose related. This is the first study to measure AChE activity in fish plasma after diazinon exposure, but we are not sure whether this finding is unique to alligator gar. Further investigations need to be done using other fish species.

Little is known about the alligator gar air breathing organ (ABO) and the gar's ability to utilize this primitive lung to extract oxygen from atmospheric air. We examined this organ by gross anatomy, light microscopy and electron microscopy. The alligator gar ABO is a single, elongated organ that is divided into right and left lobes by a central canal. Each lobe is further subdivided by short septa into first, second, third, and fourth air spaces. The epithelial lining of these air spaces is ciliated columnar mucoid cells in the first level of air spaces. This gradually thins with complete loss in ciliated columnar mucoid cells giving away to simple squamous epithelium that is rich in blood capillaries that represent the respiratory surface area for gas exchanges. There is controversy surrounding the existence of pneumatic ducts ingars. The pneumatic duct allows air movement between the esophagus and the ABO. This study documented the presence of a pneumatic duct in alligator gar. This duct was pharyngeo-esophageal in origin. In conclusion, the ABO of alligator gar has adapted to both hydrostatic function and breathing oxygen, enabling this fish to reside in highly hypoxic water for extended periods of time.

The alligator gar is a primitive and interesting fish with unique anatomical structures. It has potential as a biological control for invasive aquatic species, and it can

play a role in environmental monitoring. However, this fish can be physiologically harmed by sub-lethal levels of pollutants that can accumulate in the slow moving tributaries it inhabits. Effective stocking and management of this fish will determine if it can be used to enhance the ecosystems it inhabits.

REFERENCES

1. McEachran, J.D. and J.D. Fechhelm, Fishes of the Gulf of Mexico. Vol. 1. 1998: Austin: University of Texas Press, 1998-1st ed.
2. Graham, J.B., Air-breathing fishes: evolution, diversity, and adaptation. 1997: San Diego: Academic Press, c1997.
3. Wiley, E.O., The phylogeny and biogeography of fossil and Recent gars (Actinopterygii; Lepisosteidae). Vol. 64. 1976: University of Kansas, Museum of Natural History, Miscellaneous Publication, 64, 1-111.
4. Suttkus, R.D., Order Lepisostei. In Bigelow, H. B., and W. C. Schroeder, editors. Fishes of the western North Atlantic. . Order Lepisostei 1963: Memoirs of the Sears Foundation for Marine Research 1, Part 3. New Haven, Connecticut. . 61-88.
5. Etnier, D.A. and W.C. Starnes, The fishes of Tennessee. 1993: Knoxville: University of Tennessee Press, [1993]. 1st ed.
6. Yang, W., et al., Structure and fracture resistance of alligator gar (*Atractosteus spatula*) armored fish scales. *Acta Biomater*, 2013. 9(4): p. 5876-89.
7. Page, L.M. and B.M. Burr, A field guide to freshwater fishes: North America north of Mexico. Peterson field guide series: 42. 1991: Boston: Houghton Mifflin, 1991.
8. Mendoza Alfaro, R., C.A. González, and A.M. Ferrara, Gar biology and culture: status and prospects. *Aquaculture research*, 2008. 39(7): p. 748-763.
9. Wright, P.A., Ionic, Osmotic, and Nitrogenous Waste Regulation. Vol. 26. 2007: *Fish Physiology*. 26, 283-318. 35.
10. Starnes, W.C. and D.A. Etnier, Fishes, N. Tenn. Dept. Cons., Editor. 1980: In: D. C. Eager and R. M. Hatcher, eds. p. B1-B134.
11. Simon, T.P. and R. Wallus, Contributions the early life histories of gar (Actinopterygii: Lepisosteidae) in the Ohio and Tennessee River Basins with Emphasis on Larval Development. *Trans. Ky. Acad. Sci.*, 1989. 50: p. 59-74.

12. Warren, M.L. and R.R. Cicerello, Endangered, threatened, and rare plants and animals of Kentucky. *Trans. Ky. Acad. Sci.*, 1986. 47: p. 83-98.
13. Miller, R.R., Threatened freshwater fishes of the United States. . *Trans. Amer. Fish. Soc*, 1972. 101: p. 239-252.
14. Buchanan, T.M., Threatened native fishes of Arkansas, L.R. Ark. Dept. Planning, Editor. 1974, Arkansas natural area plan: Arkansas p. 67-92.
15. Schouten, L., The newest weapon in the Asian carp battle: Alligator fish. 2016, *The Chris. Scie. Moni.: Massachusetts, MA*.
16. Schouten, L., Goldfish or Asian carp? Why it matters in the Great Lakes. 2016, *The Chris. Scie. Moni.: Massachusetts, MA*.
17. Adams, D.H., et al., Mercury contamination in spotted seatrout, *Cynoscion nebulosus*: an assessment of liver, kidney, blood, and nervous system health. *Sci Total Environ*, 2010. 408(23): p. 5808-5816.
18. Maxwell, L.B. and H.M. Dutta, Diazinon-induced endocrine disruption in bluegill sunfish, *Lepomis macrochirus*. *Ecotoxicol Environ Saf*, 2005. 60(1): p. 21-27.
19. Bado-Nilles, A., et al., In vivo effects of the soluble fraction of light cycle oil on immune functions in the European sea bass, *Dicentrarchus labrax* (Linné). *Ecotoxicol and Environ Saf*, 2011. 74(7): p. 1896-1904.
20. Ansari, Z.A., C. Desilva, and S. Badesab, Total petroleum hydrocarbon in the tissues of some commercially important fishes of the Bay of Bengal. *Marine Pollution Bulletin*, 2012. 64(11): p. 2564-2568.
21. Yasser, A.G. and M.D. Naser, Impact of pollutants on fish collected from different parts of Shatt Al-Arab River: a histopathological study. *Environ Monit Assess*, 2011. 181(1-4): p. 175-182.
22. Omar-Ali, A., et al., Tissue PAH, blood cell and tissue changes following exposure to water accommodated fractions of crude oil in alligator gar, *Atractosteus spatula*. *Mar Environ Res*, 2015. 108: p. 33-44.
23. Ali, A.O., et al., The effects of oil exposure on peripheral blood leukocytes and splenic melano-macrophage centers of Gulf of Mexico fishes. *Mar Pollut Bull*, 2014. 79(1-2): p. 87-93.

24. Luster, M.I. and G.J. Rosenthal, Chemical agents and the immune response. *Environ Health Persp*, 1993. 100: p. 219-226.
25. Far, M.S., et al., The effects of diazinon on behavior and some hematological parameters of fry rainbow trout (*Oncorhynchus mykiss*). *Wor Jour of Fish and Mar Scie*, 2012. 4(4): p. 369-375.
26. Sanchez-Fortun, S. and M.V. Barahona, Comparative study on the environmental risk induced by several pyrethroids in estuarine and freshwater invertebrate organisms. *Chemosphere*, 2005. 59(4): p. 553-559.
27. Hamm, J.T. and D.E. Hinton, The role of development and duration of exposure to the embryotoxicity of diazinon. *Aquat Toxicol*, 2000. 48(4): p. 403-418.
28. Burkepile, D.E., M.T. Moore, and M.M. Holland, Susceptibility of five nontarget organisms to aqueous diazinon exposure. *Bull Environ Contam Toxicol*, 2000. 64(1): p. 114-121.
29. Alahyary, P., et al., The potential toxicity of diazinon on physiological factors in male rat. *Pak Jour Biol Sci*, 2008. 11(1): p. 127-130.
30. Drastichova, J., et al., Effect of cadmium on hematological indices of common carp (*Cyprinus carpio* L.). *Bull Environ Contam Toxicol*, 2004. 72(4): p. 725-732.
31. Oh, H.S., et al., Mechanism of selective toxicity of diazinon to killifish (*Oryzias latipes*) and loach (*Misgurnus anguillicaudatus*). *Aquat Toxicol Risk Asses*, 1991. 14: p. 343-353.
32. Ferrari, M.J., Pesticides in surface water of the Mid-Atlantic region / by Matthew J. Ferrari ... [et al.] ; prepared in cooperation with the U.S. Environmental Protection Agency, in Water-resources investigations report ; 97-4280. 1997, [Baltimore, Md.]: U.S. Geolog Surv; [Denver, CO: Branch of Information Services, distributor, 1997].
33. Kuivila, K.M. and C.G. Foe, Concentration, transport and biological effects of dormant spray pesticides in the San Francisco Estuary, California. *Enviro Toxicol and Chemi*, 1995. 14(7): p. 1141-1150.
34. Carriger, J.F., et al., Pesticides of Potential Ecological Concern in Sediment from South Florida Canals: An Ecological Risk Prioritization for Aquatic Arthropods. *Soil and Sedim Contam*, 2006. 15(1): p. 21-46.

35. Ghasemzadeh, J., M. Sinaei, and M. Bolouki, Biochemical and histological changes in fish, spotted scat (*Scatophagus argus*) exposed to diazinon. *Bull Environ Contam Toxicol*, 2015. 94(2): p. 164-70.
36. Monica, D., et al., Intoxication with Diazinon. *Therapeu, Pharmacol & Clini Toxicol*, 2015. 19(4): p. 152-155.
37. Roberts, T.R. and D.H. Hutson, *Metabolic pathways of agrochemicals. Part 2: insecticides and fungicides*. 1999, Roy Soci of Chemi: Cambridge; UK.
38. Sine, C., *Farm Chemicals Handbook*. Meister, Willoughby, OH, USA, 1992.
39. Sastry, K.V. and K. Sharma, Diazinon-induced histopathological and hematological alterations in a freshwater teleost, *Ophiocephalus punctatus*. *Ecotoxicol Environ Saf*, 1981. 5(3): p. 329-40.
40. Bouchard, M., et al., Biological monitoring of exposure to organophosphorus insecticides in a group of horticultural greenhouse workers. *Ann Occup Hyg*, 2006. 50(5): p. 505-515.
41. Bartsch, E., Diazinon. II. Residues in plants, soil, and water. 1974. p. 37-68.
42. Sub-stances, U.S.E.O.o.P.a.T., *Guidance for the reregistration of pesticide products containing diazinon as the active ingredien*. 1988: Washington, DC. p. 6.
43. EPA, U.S., *Quantitative usage analysis for diazinon*. 1999: Washington, DC.
44. EPA, U.S., *Reregistration Eligibility Decision Diazinon, P.a.T.S. Office of Prevention, Office of Pesticide Programs, U.S. Government Printing Office, Editor*. 2006: Washington, DC.
45. Hornsby, A.G., R.D. Wauchope, and A.E. Herner, *Pesticide properties in the environment*. 1996, United States: Springer: New York, United States.
46. Sharom, M.S., et al., Behaviour of 12 insecticides in soil and aqueous suspensions of soil and sediment. *Water Research*, 1980. 14(8): p. 1095-1100.
47. Moyle, P.B. and J.J. Cech, *Fishes: an introduction to ichthyology*. 2004: Upper Saddle River, NJ: Pearson Prentice Hall, c2004. 5th ed.
48. Smatresk, N.J. and J.N. Cameron, Respiration and acid-base physiology of the spotted gar, a bimodal breather. I. Normal values, and the response to severe hypoxia. *Journal of experimental biology*, 1982. 96: p. 263-280.

49. Moraes, M.F., et al., Morphometric comparison of the respiratory organs in the South American lungfish *Lepidosiren paradoxa* (Dipnoi). *Physiol Biochem Zool*, 2005. 78(4): p. 546-559.
50. Hughes, G.M., et al., Respiratory surface areas of an air-breathing siluroid fish *Saccobranchus* (*Heteropneustes*) *fossilis* in relation to body size. *Journal of Zoology*, 1974. 172(2): p. 215–232.
51. Perna, S.A. and M.N. Fernandes, Gill morphometry of the facultative air-breathing loricariid fish, *Hypostomus plecostomus* (Walbaum) with special emphasis on aquatic respiration. *Fish Physiology and Biochemistry*, 1996. 15(3): p. 213-220.
52. Mazon, A.F., et al., Functional morphology of gills and respiratory area of two active rheophilic fish species, *Plagioscion squamosissimus* and *Prochilodus scrofa*. *Journal of Fish Biology*, 1998. 52(1): p. 50-61.
53. Kapoor, B.G. and B. Khanna, *Ichthyology handbook* / B.G. Kapoor, Bhavna Khanna. 2004, Berlin; New York: Springer; New Delhi: Narosa Pub. House, c2004.
54. Icardo, J.M., et al., The structure of the gas bladder of the spotted gar, *Lepisosteus oculatus*. *J Morphol*, 2015. 276(1): p. 90-101.
55. Taylor, E.W., et al., The phylogeny and ontogeny of autonomic control of the heart and cardiorespiratory interactions in vertebrates. *J Exp Biol*, 2014. 217(Pt 5): p. 690-703.
56. Roberts, R.J., *Fish Pathology*. 2001: London; New York: W.B. Saunders, 2001. 3rd ed.
57. Genten, F., E. Terwinghe, and A. Danguy, *Atlas of fish histology*. 2009: Enfield, NH: Science Publishers, c2009.
58. Zaccone, D., et al., Morphology and innervation of the teleost physostome swim bladders and their functional evolution in non-teleostean lineages. *Acta Histochem*, 2012b. 114(8): p. 763-72.
59. Steen, J.B., The Swim Bladder as a Hydrostatic Organ. In: Hoar, W. J., Randall, D. J. (Eds.). *Fish Physiology*. Academic Press, New York, 1970. 4: p. 413-443.
60. Seymour, R.S., N.C. Wegner, and J.B. Graham, Body size and the air-breathing organ of the Atlantic tarpon *Megalops atlanticus*. *Comp Biochem Physiol A Mol Integr Physiol*, 2008. 150(3): p. 282-7.

61. Perry, S.F., Relationships between branchial chloride cells and gas transfer in freshwater fish. *Comp Biochem Physiol A Mol Integr Physiol*, 1998. 119(1): p. 9-16.
62. Dymowska, A.K., P.P. Hwang, and G.G. Goss, Structure and function of ionocytes in the freshwater fish gill. *Respir Physiol Neurobiol*, 2012. 184(3): p. 282-92.
63. Hwang, P.P., Ion uptake and acid secretion in zebrafish (*Danio rerio*). *J Exp Biol*, 2009. 212(Pt 11): p. 1745-52.
64. Fullarton, M.H., Notes on the Respiration of *Lepidosiren*. *Journal of Zoology*, London, 1931. 101(4): p. 1301–1306.
65. Tamura, O. and T. Moriyama, The Morphological Feature of The Gill of Amphibious and Air Breathing Fishes. *Bull. Fac. Fish. Nagasaki Univ.*, 1976. 41: p. 1-8.
66. Roy, P.K. and J.S.D. Munshi, Morphometrics of the respiratory organs of a freshwater major carp, *Cirrhinus mrigala* in relation to body weight. *Japan. J. Ichthyol*, 1986. 33: p. 269-279.
67. Potter, G., Respiratory function of the swim bladder in *Lepidosteus*. *Journal of Experimental Zoology*, 1927. 49: p. 45-67.
68. Aspelin, A.L., Pesticide Industry Sales and Usage 1992 and 1993 Market Estimates. Biological and Economic Analysis Division, Office of Pesticide Programs, U.S. Environmental Protection Agency, 1994: p. 773-K-94-001; 1-36.
69. Baker, D.B. and R.P. Richards, Transport of soluble pesticides through drainage networks in large agricultural river basins. 1990, Lewis Publishers: Chelsea, MI, United States: United States. p. 241-270.
70. Gonzalez, C.A., J. Cruz, and R.M. Alfaro, Physiological response of alligator gar juveniles (*Atractosteus spatula*) exposed to sub-lethal doses of pollutants. *Fish Physiol Biochem*, 2015. 41(4): p. 1015-1027.
71. Jung, J.H., et al., Biomarker responses in pelagic and benthic fish over 1 year following the Hebei Spirit oil spill (Taean, Korea). *Mar Pollut Bull*, 2011. 62(8): p. 1859-66.
72. Keizer, J., et al., Enzymological differences of AChE and diazinon hepatic metabolism: correlation of in vitro data with the selective toxicity of diazinon to fish species. *Sci Total Environ*, 1995. 171(1-3): p. 213-220.

73. Dutta, H., J. Marcelino, and C. Richmonds, Brain acetylcholinesterase activity and optomotor behavior in bluegills, *Lepomis macrochirus* exposed to different concentrations of diazinon. *Arch Int Physiol Biochim Biophys*, 1992. 100(5): p. 331-334.
74. Ceron, J.J., et al., Metabolic effects of diazinon on the European eel *Anguilla anguilla*. *Journal of environmental science and health. Part B: Pesticides, food contaminants, and agricultural wastes (USA)*, 1996(5): p. 1029.
75. Denton, D.L., et al., Joint acute toxicity of esfenvalerate and diazinon to larval fathead minnows (*Pimephales promelas*). *Environ Toxicol Chem*, 2003. 22(2): p. 336-341.
76. Bailey, H.C., et al., Diazinon and chlorpyrifos in urban waterways in northern California, USA. *Environmental Toxicology and Chemistry*, 2000. 19(1): p. 82-87.
77. Levin, M., et al., Immunomodulatory effects of organochlorine mixtures upon in vitro exposure of peripheral blood leukocytes differ between free-ranging and captive southern sea otters (*Enhydra lutris*). *Vet Immunol Immunopathol*, 2007. 119(3-4): p. 269-77.
78. Kappers, W.A., et al., Diazinon is activated by CYP2C19 in human liver. *Toxicol Appl Pharmacol*, 2001. 177(1): p. 68-76.
79. Abu-Qare, A.W. and M.B. Abou-Donia, Inhibition and recovery of maternal and fetal cholinesterase enzyme activity following a single cutaneous dose of methyl parathion and diazinon, alone and in combination, in pregnant rats. *J Appl Toxicol*, 2001. 21(4): p. 307-16.
80. Sultatos, L.G., Mammalian toxicology of organophosphorus pesticides. *J Toxicol Environ Health*, 1994. 43(3): p. 271-89.
81. Vryzas, Z., et al., Spatial and temporal distribution of pesticide residues in surface waters in northeastern Greece. *Water Research*, 2009. 43(1): p. 1-10.
82. Wauchope, R.D., The pesticide content of surface water draining from agricultural fields a review. . 1978. p. 459-472.
83. Banaee, M., et al., Histopathological alterations induced by diazinon in rainbow trout (*Oncorhynchus mykiss*). *International Journal of Environmental Research*, 2013. 7(3): p. 835-844.

84. Banks, K.E., D.H. Hunter, and D.J. Wachal, Chlorpyrifos in surface waters before and after a federally mandated ban. *Environment International*, 2005. 31: p. 351-356.
85. Shayeghi, M. and E.A. Javadian, Study of the residue of lindane and diazinon in the rice fields in Tonekabon city (Mazandaran Province) *Jour Environ Sci Technol*, 2001. 9: p. 51-58.
86. Arjmandi, R., M. Tavakol, and M. Shayeghi, Determination of organophosphorus insecticide residues in the rice paddies. *Inter Jour of Enviro Scie and Techno*, 2010. 7(1): p. 175-182.
87. Glotfelty, D.E., J.N. Seiber, and L.A. Liljedahl, Pesticides in fog. *Nature*, 1987. 325(6105): p. 602-5.
88. Agency, U.S.E.P., Chlorpyrifos revised risk assessment and agreement with registrants. 2000.
89. Banaee, M. and K. Ahmadi, Sub-lethal toxicity impacts of endosulfan on some biochemical parameters of the freshwater crayfish (*Astacus leptodactylus*). *Research Journal of Environmental Sciences*, 2011. 5(11): p. 827-835.
90. Schlenk, D., Chapter 6 Pesticide biotransformation in fish, in *Biochemistry and Molecular Biology of Fishes*, T.P. Mommsen and T.W. Moon, Editors. 2005, Elsevier. p. 171-190.
91. Keizer, J., G. D'Agostino, and L. Vittozzi, The importance of biotransformation in the toxicity of xenobiotics to fish. I. Toxicity and bioaccumulation of diazinon in guppy (*Poecilia reticulata*) and zebra fish (*Brachydanio rerio*). *Aquatic Toxicology*, 1991. 21(3-4): p. 239-254.
92. Fujii, Y. and S. Asaka, Metabolism of diazinon and diazoxon in fish liver preparations. *Bull Environ Contam Toxicol*, 1982. 29(4): p. 455-460.
93. Heath, A.G., *Water pollution and fish physiology 1995*, Boca Raton: Lewis Publishers, 1995.
94. Fulton, M.H. and P.B. Key, Acetylcholinesterase inhibition in estuarine fish and invertebrates as an indicator of organophosphorus insecticide exposure and effects. *Environ Toxicol And Chem* 2001. 20(1): p. 37-45.
95. Hamm, J.T., B.W. Wilson, and D.E. Hinton, Organophosphate-induced acetylcholinesterase inhibition and embryonic retinal cell necrosis in vivo in the teleost (*Oryzias latipes*). *Neurotoxico*, 1998. 19(6): p. 853-869.

96. Ansari, B.A., K. Kumar, and M. Aslam, Diazinon Toxicity: Activities of Acetylcholinesterase and Phosphatases in the Nervous Tissue of Zebra Fish, *Brachydanio rerio* (Cyprinidae). *Acta hydrochimica et hydrobiologica*, 1987. 15(3): p. 301-306.
97. Cong, N.V., N.T. Phuong, and M. Bayley, Effects of repeated exposure of diazinon on cholinesterase activity and growth in snakehead fish (*Channa striata*). *Ecotoxicol Environ Saf*, 2009. 72(3): p. 699-703.
98. Nguyen, V.C., T.P. Nguyen, and M. Bayley, Brain cholinesterase response in the snakehead fish (*Channa striata*) after field exposure to diazinon. *Ecotoxicol Environ Saf*, 2008. 71(2): p. 314-318.
99. Fernandez-Vega, C., et al., Thiobencarb-induced changes in acetylcholinesterase activity of the fish *Anguilla anguilla*. *Pesti Biochemi and Physiol*, 2002. 72(1): p. 55-63.
100. Dos Santos Miron, D., et al., Effects of the herbicides clomazone, quinclorac, and metsulfuron methyl on acetylcholinesterase activity in the silver catfish (*Rhamdia quelen*) (Heptapteridae). *Ecotoxicol Environ Saf*, 2005. 61(3): p. 398-403.
101. Banaee, M., et al., Effects of diazinon on biochemical parameters of blood in rainbow trout (*Oncorhynchus mykiss*). *Pestic Biochem and Physiol*, 2011. 99(1): p. 1-6.
102. Pohanish, R.P. and M. Sittig, *Sittig's handbook of toxic and hazardous chemicals and carcinogens Vol. 1*. 2008, Norwich, NY: William Andrew.
103. Snyder, A.L. and W.L. Clarke, Urinary glucose determinations in infants and toddlers. *Diabetes Care*, 1987. 10(4): p. 538-40.
104. Sundewall, A.C., A.K. Lefvert, and R. Olsson, Anti-acetylcholine receptor antibodies in primary biliary cirrhosis. *Acta Med Scand*, 1985. 217(5): p. 519-25.
105. Schinasi, L. and M.E. Leon, Non-Hodgkin lymphoma and occupational exposure to agricultural pesticide chemical groups and active ingredients: a systematic review and meta-analysis. *International Journal of Environmental Research and Public Health*, 2014. 11(4): p. 4449-4527.
106. Schulze, L.D., E.F. Vitzthum, and C.L. Ogg, Signs and symptoms of pesticide poisoning, in *EC; 97-2505-A*. 1997, Lincoln, Neb.: University of Nebraska Cooperative Extension.

107. Olufayo, M.O., Haematological characteristics of *Clarias gariepinus* (Burchell 1822) juveniles exposed to *Derris elliptica* root powder. *African Journal of Food, Agriculture, Nutrition and Development*, 2009. 9(3): p. 920-933.
108. Danion, M., et al., Bioconcentration and immunotoxicity of an experimental oil spill in European sea bass (*Dicentrarchus labrax* L.). *Ecotoxicology and Environmental Safety*, 2011. 74(8): p. 2167-2174.
109. Hedayati, A. and E. Hassan Nataj Niazie, Hematological changes of silver carp (*hypophthalmichthys molitrix*) in response to Diazinon pesticide. *Jour Environ Health Sci Eng*, 2015. 13: p. 52.
110. Haider, M.J. and R. A., Sub-lethal Effects of Diazinon on Hematological Indices and Blood Biochemical Parameters in Indian Carp, *Cirrhinus mrigala* (Hamilton). *Brazil Archiv of Biol and Techno*, 2014. 57(6): p. 947-953.
111. Svobodova Z., P. D., and P. J., Unified methods of hematological examination of fish. *Resea Instit of Fish Cultu and Hydrobio, Vodnany*, 1991. 31(20).
112. Adedeji, O.B., O.K. Adeyemo, and S.A. Agbede, Effects of diazinon on blood parameters in the African catfish (*Clarias gariepinus*). *Afri Jour of Biotech*, 2009. 8(16): p. 3940-3946.
113. Zapata, A.G. and E.L. Cooper, *The immune system: comparative histophysiology* 1990, Chichester; New York: Wiley, 1990.
114. Eisler, R., *Diazinon Hazards to Fish, Wildlife, and Invertebrates: A Synoptic Review*. Vol. 85. 1986. 48-48.
115. Khoshbavar-Rostami, H.A., M. Soltani, and H.M.D. Hassan, Immune response of great sturgeon (*Huso huso*) subjected to long-term exposure to sublethal concentration of the organophosphate, diazinon. *Aquacultu*, 2006. 256: p. 88-94.
116. Khoshbavar-Rostami, H., M. Soltani, and H.M.D. Hassan, Acute toxicity and some haematological and biochemical changes in giant sturgeon (*Huso huso*) exposed to diazinon. *Bull of the Europ Asso of Fish Patho*, 2004. 24(2): p. 92-99.
117. Shamoushaki, M.M.N., et al., Effects of organophosphate, diazinon on some haematological and biochemical changes in *Rutilus frisii kutum* (Kamensky, 1901) male brood stocks. *Iran Jour of Fis Sci*, 2012. 11(1): p. 105-117.
118. Svoboda, M., et al., The effect of diazinon on haematological indices of common carp (*Cyprinus carpio* L.). *Acta Veterin (Czech Republic)*, 2001(4): p. 457-265.

119. Rauf, A. and N. Arain, Acute toxicity of diazinon and its effects on hematological parameters in the Indian carp, *Cirrhinus mrigala* (Hamilton). *Turki Jour of Veter and Anim Scien*, 2013. 37(5): p. 535-540.
120. Dutta, H.M., et al., Histopathological changes induced by malathion in the liver of a freshwater catfish, *Heteropneustes fossilis* (Bloch). *Bull Environ Contam Toxicol*, 1993. 51(6): p. 895-900.
121. Shah, M.D. and M. Iqbal, Diazinon-induced oxidative stress and renal dysfunction in rats. *Food Chem Toxicol*, 2010. 48(12): p. 3345-3353.
122. Cengiz, E.I., Gill and kidney histopathology in the freshwater fish *Cyprinus carpio* after acute exposure to deltamethrin. *Environ Toxicol Pharmacol*, 2006. 22(2): p. 200-4.
123. Dalum, A.S., et al., The interbranchial lymphoid tissue of Atlantic Salmon (*Salmo salar* L) extends as a diffuse mucosal lymphoid tissue throughout the trailing edge of the gill filament. *J Morphol*, 2015. 276(9): p. 1075-88.
124. Velmurugan, B., et al., The effects of monocrotophos to different tissues of freshwater fish *Cirrhinus mrigala*. *Bull Environ Contam Toxicol*, 2007. 78(6): p. 450-454.
125. Agius, C. and R.J. Roberts, Melano-macrophage centres and their role in fish pathology. *J Fish Dis*, 2003. 26(9): p. 499-509.
126. Ferguson, H.W., The relationship between ellipsoids and melano macrophage centres in the spleen of turbot (*Scophthalmus maximus*). *Journal of Comparative Pathology*, 1976. 86(3): p. 377-380.
127. Graf, R. and J. Schluens, Ultrastructural and histochemical investigation of the terminal capillaries in the spleen of the carp (*Cyprinus carpio* L.). *Cell Tissue Res*, 1979. 196(2): p. 289-306.
128. Bucke, D., A.D. vethaak, and T. Lang, Quantitative assessment of melanomacrophage centres (MMCs) in dab *Limanda limanda* along a pollution transect in the German Bight. *Mar. Ecol. Prog. Ser.*, 1992. 91: p. 193-196.
129. Micale, V. and F. Perdichizzi, A quantitative and histochemical study on melano-macrophage centres in the spleen of the teleost fish *Diplodus annularis* L. *J. of Fish Bio*, 1990. 37: p. 191-197.
130. Suresh, N., Effect of cadmium chloride on liver, spleen and kidney melano macrophage centres in *Tilapia mossambica*. *J Environ Biol*, 2009. 30(4): p. 505-8.

131. Fernandes, M.N. and S.A. Perna-Martins, Epithelial gill cells in the armored catfish, *Hypostomus cf. plecostomus* (Loricariidae). *Braz J Biol*, 2001. 61(1): p. 69-78.
132. Herraiez, M.P. and A.G. Zapata, Structural characterization of the melano-macrophage centres (MMC) of goldfish *Carassius auratus*. *Eur J Morphol*, 1991. 29(2): p. 89-102.
133. Johansen, K., D. Hanson, and C. Lenfant, Respiration in a primitive air breather, *Amia calva*. *Respiration Physiology*, 1970. 9(2): p. 162-174.
134. Perry, S.F., et al., Which came first, the lung or the breath? *Comp Biochem Physiol A Mol Integr Physiol*, 2001. 129(1): p. 37-47.
135. Morrison, C.M., T. Miyake, and J.R. Wright, Jr., Histological study of the development of the embryo and early larva of *Oreochromis niloticus* (Pisces: Cichlidae). *J Morphol*, 2001. 247(2): p. 172-95.
136. Ünal, G., et al., Histological study of the organogenesis of the digestive system and swim bladder of the *Chalcalburnus tarichi* Pallas, 1811 (Cyprinidae). *Turkish Journal of Zoology*, 2001. 25(3): p. 217-228.
137. Doroshev, S.I. and J.W. Cornacchia, Initial swimbladder inflation in the larvae of physoclistous fishes and its importance for larval culture. In: Lasker RM, Sherman K (eds) *The early life history of fish: recent studies*. *J Cons inter Explor Mer* 1981. 178: p. 495-500.
138. Jaroszevska, M. and K. Dabrowski, Morphological analysis of the functional design of the connection between the alimentary tract and the gas bladder in air-breathing lepisosteid fish. *Ann Anat*, 2008. 190(4): p. 383-90.
139. Rahn, H., et al., Air breathing of the garfish (*Lepisosteus osseus*). *Respiration Physiology*, 1971. 11(3): p. 285-307.
140. Wilder, B.G., Notes on the North American ganoids *Amia*, *Lepidosteus*, *Acipenser*, and *Polyodon*, with three plates. Vol. 24. 1876, Salem, Mass.: Proc. Amer. Assoc. Adv. Sci.
141. Bullis, R.A., clinical pathology of temperate freshwater and estuarine fishes. *Fish Medicine*, ed. M.K.e. In: Stoskopf. 1993, Philadelphia.
142. Stoskopf, M., *Fish medicine 1993*: Philadelphia: W.B. Saunders Co., 1993.

143. Cook, J.D., Diagnosis and management of iron-deficiency anaemia. *Best Practice & Research Clinical Haematology*, 2005. 18(2): p. 319-332.
144. Bain, B.J., Diagnosis from the Blood Smear. *New England Journal of Medicine*, 2005. 353(5): p. 498-507.
145. Monzon, C.M., B.D. Beaver, and T.D. Dillon, Evaluation of erythrocyte disorders with mean corpuscular volume (MCV) and red cell distribution width (RDW). *Clin Pediatr (Phila)*, 1987. 26(12): p. 632-8.
146. Omar-Ali, A., The effect of oil exposure on the tissues and health status of Gulf of Mexico fishes. 2012, MSSTATE, Mississippi State: Mississippi State University, 2012-11-29.
147. Blaxhall, P.C. and K.W. Daisley, Routine haematological methods for use with fish blood. *Jour of Fish Bio*, 1973. 5(6): p. 771-781.
148. Velmurugan, B., et al., Histopathology of lambda-cyhalothrin on tissues (gill, kidney, liver and intestine) of *Cirrhinus mrigala*. *Environ Toxicol Pharmacol*, 2007. 24(3): p. 286-291.
149. El-Sherif, M.S., et al., Evaluation of Diazinon toxicity on Nile tilapia fish (*O. niloticus*). *Jour of Fish and Aqua Sci*, 2009. 4(4): p. 169-177.
150. Banaee, M., Physiological Dysfunction in Fish after Insecticides Exposure: Insecticides often undesired but still so Important, Edited by Stanislav Trdan. Published by InTech, 2013. 4: p. 103-142.
151. Sancho, E., J.J. Ceron, and M.D. Ferrando, Cholinesterase activity and hematological parameters as biomarkers of sublethal molinate exposure in *Anguilla anguilla*. *Ecotoxicol Environ Saf*, 2000. 46(1): p. 81-86.
152. Köprücü, S.Ş., et al., Acute toxicity of organophosphorous pesticide diazinon and its effects on behavior and some hematological parameters of fingerling European catfish (*Silurus glanis* L.). *Pesti Biochem and Physio*, 2006. 86(2): p. 99-105.
153. Ahmad, Z., Acute toxicity and haematological changes in common carp (*Cyprinus carpio*) caused by diazinon exposure. *Afri Jourof Biotech*, 2011. 10(63): p. 13852-13859.
154. Pourgholam, R., et al., Some hematological and biochemical changes in blood serum of Grass carp (*Ctenopharyngodon idella*) vaccinated with *Aeromonas Hydrophila* following exposure to sub lethal concentration of diazinon. *Iran Jour of Fish Scie*, 2013. 12(1): p. 12-23.

155. Pohanish, R.P., Sittig's handbook of toxic and hazardous chemicals and carcinogens. Vol. 1. 2011, Norwich, N.Y.: Willi Andr Elsev Sci [distributor].
156. Hinck, J.E., Biomonitoring of Environmental Status and Trends (BEST) Program: environmental contaminants and their effects on fish in the Columbia River Basin. Scientific investigations report: 2004-5154. 2004: Reston, Va.: U.S. Dept. of the Interior, U.S. Geological Survey.
157. Schmitt, C.J., Biomonitoring of Environmental Status and Trends (BEST) Program: environmental contaminants and their effects on fish in the Mississippi River basin. Biological science report: USGS/BRD/BSR--2002-0004. 2002: [Reston, VA]: U.S. Dept. of the Interior, U.S. Geological Survey, [2002].
158. Gluszczak, L., et al., Acute effects of glyphosate herbicide on metabolic and enzymatic parameters of silver catfish (*Rhamdia quelen*). *Comparative Biochemistry and Physiology Part C: Toxicology & Pharmacology*, 2007. 146(4): p. 519-524.
159. Livingstone, D.R., Contaminant-stimulated reactive oxygen species production and oxidative damage in aquatic organisms. *Mar Pollut Bull*, 2001. 42(8): p. 656-66.
160. Isik, I. and I. Celik, Acute effects of methyl parathion and diazinon as inducers for oxidative stress on certain biomarkers in various tissues of rainbowtrout (*Oncorhynchus mykiss*). *Pesticide biochemistry and physiology*, 2008. 2008(92): p. 38-42.
161. Scandalios, J.G., Oxidative stress: molecular perception and transduction of signals triggering antioxidant gene defenses. *Braz J Med Biol Res*, 2005. 38(7): p. 995-1014.
162. Ahmad, I., et al., Induction of hepatic antioxidants in freshwater catfish (*Channa punctatus* Bloch) is a biomarker of paper mill effluent exposure. *Biochim Biophys Acta*, 2000. 1523(1): p. 37-48.
163. Fraga, C.G., et al., Antioxidant defenses and mechanisms of protection against oxygen radicals. 1996: *Physiology and Biochemistry of the Fishes of the Amazon, Manaus*.
164. Parvez, S. and S. Raisuddin, Protein carbonyls: novel biomarkers of exposure to oxidative stress-inducing pesticides in freshwater fish *Channa punctata* (Bloch). *Environ Toxicol Pharmacol*, 2005. 20(1): p. 112-117.

165. Tejada, S., et al., Antioxidant response and oxidative damage in brain cortex after high dose of pilocarpine. *Brain Research Bulletin*, 2007. 71: p. 372-375.
166. Petrie-Hanson, L. and A.J. Ainsworth, Differential cytochemical staining characteristics of channel catfish leukocytes identify cell populations in lymphoid organs. *Vet Immunol Immunopathol*, 2000. 73(2): p. 129-44.
167. Trenzado, C., et al., Antioxidant enzymes and lipid peroxidation in sturgeon *Acipenser naccarii* and trout *Oncorhynchus mykiss*. A comparative study. *Aquaculture*, 2006.
168. Johnson, L.L., et al., Chemical contaminants and hepatic lesions in winter flounder (*Pleuronectes americanus*) from the northeast coast of the United States. *Environmental Science and Technology*, 1993. 27(13): p. 2759-2771.
169. Van Vuren, J.H.J., The effects of toxicants on the haematology of *Labeo umbratus* (Teleostei: Cyprinidae). *Compara Biochem and Physi. Part C.*, 1986. 83(1): p. 155-159.
170. Bucke, D., et al., Common diseases and parasites of fish in the North Atlantic: training guide for identification. *ICES Techniques in Marine Environmental* 1996: p. 19-27.
171. Banaee, M., et al., Biochemical and histological changes in the liver tissue of rainbow trout (*Oncorhynchus mykiss*) exposed to sub-lethal concentrations of diazinon. *Fish Physiol Biochem*, 2013. 39(3): p. 489-501.
172. Gaafar, A.Y., et al., Some pathological, biochemical and hematological investigations on Nile tilapia (*Oreochromis niloticus*) following chronic exposure to edifenphos pesticide. *Journal of American Science* 2010. 6(10): p. 542-551.
173. Ferguson, H.W., *Systemic pathology of fish: a text and atlas of comparative tissue responses in diseases of teleosts*. 1989: Ames: Iowa State University Press, 1989. 1st ed.
174. Altinok, I. and E. Capkin, Histopathology of rainbow trout exposed to sublethal concentrations of methiocarb or endosulfan. *Toxicol Pathol*, 2007. 35(3): p. 405-10.
175. Chamarthi, R.R., et al., Histopathological alterations in the gill, liver, and brain of *Cyprinus carpio* on exposure to quinalphos. *American Journal of Life Sciences*, 2014. 2(4): p. 211-216.

176. Haensly, W.E., et al., Histopathology of *Pleuronectes platessa* L. from Aber Wrac'h and Aber Benoit, Brittany, France: long-term effects of the Amoco Cadiz crude oil spill. *Journal of Fish Diseases*, 1982. **5**(5): p. 365-391.
177. Omar-Ali, A., et al., Fine Structure of the Gas Bladder of Alligator Gar, *Atractosteus spatula*. *International Journal of Scientific Research in Environmental Science and Toxicology*, 2016. 1(1): p. 1-8.
178. Poli, G., et al., Oxidative stress and cell signalling. *Curr Med Chem*, 2004. 11(9): p. 1163-82.
179. Hinton, D.E. and R.T. Di Giulio, *The toxicology of fishes*. 2008: Boca Raton: CRC Press, [2008].
180. Bataller, R. and D.A. Brenner, Liver fibrosis. *Journal of Clinical Investigation*, 2005. 115(2): p. 209-218.
181. Friedman, S.L., Liver fibrosis -- from bench to bedside. *J Hepatol*, 2003. 38 Suppl 1: p. S38-53.
182. Manera, M. and B.S. Dezfuli, Rodlet cells in teleosts: a new insight into their nature and functions. *Journal of Fish Biology*, 2004. 65(3): p. 597-619.
183. Bullock, W.L., *The Intestinal Histology of the Mosquito Fish, Gambia Affinis (Baird and Girard)*. *Acta Zoologica*, 1967. 48: p. 1-17.
184. Reite, O.B., The rodlet cells of teleostean fish: their potential role in host defence in relation to the role of mast cells/eosinophilic granule cells. *Fish Shellfish Immunol*, 2005. 19(3): p. 253-67.
185. Reite, O.B., Mast cells/eosinophilic granule cells of teleostean fish: a review focusing on staining properties and functional responses. *Fish & Shellfish Immunology*, 1998. 8(7): p. 489-513.
186. Fournie, J.W., et al., Utility of splenic macrophage aggregates as an indicator of fish exposure to degraded environments. *Journal of Aquatic Animal Health*, 2001. 13(2): p. 105-116.
187. Adams, S.M., *Biological indicators of stress in fish* / edited by S. Marshall Adams. *American Fisheries symposium*: 8. 1990: Bethesda, Md.: American Fisheries Society, 1990.

188. Ayoola, S.O. and O.T. Alajabo, Acute toxicity and histopathological effects of engine oil on *Sarotherodon melanotheron* (black jaw tilapia). *American-Eurasian Journal of Toxicological Sciences (AEJTS)*, 2012. 4(1): p. 48-55.
189. Gupta, R.C., *Organophosphates and Oarbamates*. In: Gupta RC, editor. *Veterinary toxicology: basic and clinical principles*. 2007: New York; London: Elsevier: Academic Press, 2007.
190. Purves, D., et al., *Neuroscience*. 4th ed ed. 2007, Sunderland, MA, U.S.A.: Sinauer Associates, Inc.
191. Habig, C. and R.T. Di Giulio, Biochemical characteristics of cholinesterases in aquatic organisms, in *Cholinesterase-inhibiting insecticides*. , P.e. In Mineau, Editor. 1991, Elsevier Science Publishers B.V.: Amsterdam; Netherlands. p. 20-33.
192. Zinkl, J.G., et al., The effects of cholinesterase inhibiting insecticides on fish, in *Cholinesterase-inhibiting insecticides. Their impact on wildlife and the environment*, P. Mineau, Editor. 1991, Elsevier Science Publishers B.V.: Amsterdam; Netherlands. p. 233-254.
193. Cerón, J.J., et al., Effects of Diazinon Exposure on Cholinesterase Activity in Different Tissues of European Eel (*Anguilla anguilla*). *Ecotoxicology and Environmental Safety*, 1996. 35(3): p. 222-225.
194. Ozcan Oruc, E., et al., Sublethal effects of organophosphate diazinon on the brain of *Cyprinus carpio*. *Drug Chem Toxicol*, 2006. 29(1): p. 57-67.
195. Huang, T.L., et al., Evaluation of liver and brain esterases in the spotted gar fish (*Lepisosteus oculatus*) as biomarkers of effect in the lower Mississippi River Basin. *Bull Environ Contam Toxicol*, 1997. 58(5): p. 688-95.
196. Ellman, G.L., et al., A new and rapid colorimetric determination of acetylcholinesterase activity. *Biochemical Pharmacology*, 1961. 7: p. 88-95.
197. Olson, D.L. and G.M. Christensen, Effects of water pollutants and other chemicals on fish acetylcholinesterase (in vitro). *Environmental Research*, 1980. 21(2): p. 327-335.
198. Devi, M. and M. Fingerman, Inhibition of acetylcholinesterase activity in the central nervous system of the red swamp crayfish, *Procambarus clarkii*, by mercury, cadmium, and lead. *Bull Environ Contam Toxicol*, 1995. 55(5): p. 746-50.

199. Labrot, F., et al., In vitro and in vivo studies of potential biomarkers of lead and uranium contamination: Lipid peroxidation, acetylcholinesterase, catalase and glutathione peroxidase activities in three non-mammalian species. *Biomarkers*, 1996. 1(1): p. 21-28.
200. Silva, K.T. and A. Pathiratne, In vitro and in vivo effects of cadmium on cholinesterases in Nile tilapia fingerlings: implications for biomonitoring aquatic pollution. *Ecotoxicology*, 2008. 17(8): p. 725-31.
201. Pretto, A., et al., Acetylcholinesterase activity, lipid peroxidation, and bioaccumulation in silver catfish (*Rhamdia quelen*) exposed to cadmium. *Arch Environ Contam Toxicol*, 2010. 58(4): p. 1008-14.
202. Hernandez-Moreno, D., et al., Different enzymatic activities in carp (*Cyprinus carpio* L.) as potential biomarkers of exposure to the pesticide methomyl. *Arch Hig Rada Toksikol*, 2014. 65(3): p. 311-8.
203. Hernandez-Moreno, D., et al., Brain acetylcholinesterase, malondialdehyde and reduced glutathione as biomarkers of continuous exposure of tench, *Tinca tinca*, to carbofuran or deltamethrin. *Sci Total Environ*, 2010. 408(21): p. 4976-83.
204. Bretaud, S., J.P. Toutant, and P. Saglio, Effects of carbofuran, diuron, and nicosulfuron on acetylcholinesterase activity in goldfish (*Carassius auratus*). *Ecotoxicol Environ Saf*, 2000. 47(2): p. 117-24.
205. Silva, J.M., et al., In vivo and in vitro inhibition of cholinesterase activity in *Colossoma macropomum* (tambaqui) fingerlings by the herbicide trifluralin. *Ecotoxicol. Environ. Contam*, 2015. 10: p. 23-30.
206. Uner, N., et al., Effects of diazinon on acetylcholinesterase activity and lipid peroxidation in the brain of *Oreochromis niloticus*. *Environmental Toxicology and Pharmacology*, 2006. 21(3): p. 241-245.
207. Omar-Ali, A., R.L. Carr, and L. Petrie-Hanson, Inhibition of Plasma Cholinesterase Activity in Alligator Gar (*Atractosteus spatula*) Following Chronic Exposure to Diazinon. *J of Toxicol and Pharmacol*, 2017. 1(3).
208. Kramer, D.L. and M. McClure, Aquatic surface respiration, a widespread adaptation to hypoxia in tropical freshwater fishes. *Environmental biology of fishes*, 1982. 7(1): p. 47-55.

209. Zaccone, D., et al., The simultaneous presence of neuroepithelial cells and neuroepithelial bodies in the respiratory gas bladder of the longnose gar, *Lepisosteus osseus*, and the spotted gar, *L. oculatus*. *Acta Histochem*, 2012a. 114(4): p. 370-8.
210. Pastor, L.M., Histology, ultrastructure and immunohistochemistry of the respiratory organs in non-mammalian vertebrates. 1995, Zaragoza, Spain: Univ. DE Murcia, Murcia. 225.
211. Schwarz, D.E. and P.J. Allen, Effects of salinity on growth and ion regulation of juvenile alligator gar *Atractosteus spatula*. *Comparative Biochemistry and Physiology. A, Molecular & Integrative Physiology*, 2014. 169: p. 44-50.
212. Bozzola, J.J. and L.D. Russell, *Electron Microscopy: Principles and Techniques for Biologists*. 1999: Sudbury, Mass.: Jones and Bartlett, c1999. 2nd ed.
213. Watson, M.L., Staining of Tissue Sections for Electron Microscopy with Heavy Metals. *Journal of Biophysics and Biochemistry Cytology*, 1958. 7(4): p. 475-478.
214. Sperry, D.G. and R.J. Wassersug, A proposed function for microridges on epithelial cells. *Anat Rec*, 1976. 185(2): p. 253-7.
215. Nilsson, S., Nervous control of fish swimbladders. *Acta Histochem*, 2009. 111(3): p. 176-84.
216. Zaccone, G., et al., Innervation and neurotransmitter localization in the lung of the Nile bichir *Polypterus bichir bichir*. *Anat Rec (Hoboken)*, 2007. 290(9): p. 1166-77.
217. Lukas, J., Visceral anatomy of the garpike, *Atractosteus tristoechus*. *Folia Zoologica*, 1989. 38(3): p. 265-274.
218. Burns, A.R., C.W. Smith, and D.C. Walker, Unique structural features that influence neutrophil emigration into the lung. *Physiol Rev*, 2003. 83(2): p. 309-36.
219. Penney, D.P., The ultrastructure of epithelial cells of the distal lung. *Int Rev Cytol*, 1988. 111: p. 231-69.
220. Kuhn, C., Ultrastructural and cellular function in distal lung. *Monogr Pathol*, 1978. 19: p. 1-20.

221. Hermida, G.N., L.E. Fiorito, and A. Farias, The lung of the common toad, *Bufo arenarum* (Anura: Bufonidae). A light and electron microscopy study. *Biocell*, 1998. 22(1): p. 19-26.
222. Hermida, G.N., A. Farias, and L.E. Fiorito, Ultrastructural characteristics of the lung of *Melanophryniscus stelzneri* (Weyenberg, 1875) (Anura, Bufonidae). *Biocell*, 2002. 26(3): p. 347-55.
223. Fernandes, M.N., et al., Morphometric partitioning of the respiratory surface area and diffusion capacity of the gills and swim bladder in juvenile Amazonian air-breathing fish, *Arapaima gigas*. *Micron*, 2012. 43(9): p. 961-70.
224. Hsia, C.C., et al., Evolution of air breathing: oxygen homeostasis and the transitions from water to land and sky. *Compr Physiol*, 2013. 3(2): p. 849-915.
225. Frappell, P.B. and C.B. Daniels, Ventilation and Oxygen Consumption in Agamid Lizards. 1991, University of Chicago Press. p. 985.
226. Stark-Vancs, V., P.B. Bell Jr, and V.H. Hutchison, Morphological and pharmacological basis for pulmonary ventilation in *Amphiuma tridactylum*. An ultrastructural study. *Cell and Tissue Research*, 1984. 238(1): p. 1-12.
227. Carvalho, F.P., et al., Ecological risk assessment of PCBs and other organic contaminant residues in Laguna de Terminos, Mexico. *Ecotoxicology*, 2009. 18(4): p. 403-16.