

THE PANETH CELL IN THE ADENOMA OF FAMILIAL POLYPOSIS COLI

BY

Takeo IWAMA, Joji UTSUNOMIYA and Eisuke HAMAGUCHI*¹

ABSTRACT

It is said that the Paneth cells are found in the large intestine in a pathological state such as ulcerative colitis or adenoma. We examined the Paneth cells in the adenomas of familial polyposis coli. Nine cases including one case of Gardner's syndrome comprised the material for the examination of the Paneth cells because the caecum was available for the examination. The remaining one case had no Paneth cells. In two cases, the Paneth cells were found among the adenomas in the areas beyond the caecum and the proximal part of the colon ascendens.

In one remarkable case, the Paneth cells were found in 43% of the adenomas in the caecum. Seven cases were carcinomas but no Paneth cells were found in or near the carcinoma. In the control cases, which were taken from the resected colon with a disease other than familial polyposis coli, the Paneth cells were found confined to the caecum. We concluded that the distribution of the Paneth cell-bearing adenomas reflects the distribution of the Paneth cells in the normal mucosa of the large intestine and that the Paneth cells in the adenoma may have differentiated in the adenoma.

INTRODUCTION

Little attention has been paid to the Paneth cells found in the adenomas of familial polyposis coli (F.P.C.).

This is our observation on the distribution and frequency of the Paneth cell-bearing adenomas in the colon and rectum of F.P.C. We compared these results with the distribution of the Paneth cells in the normal mucosa of the large intestine of the control cases.

MATERIALS AND METHODS

Nine cases of F.P.C. of which we were able to examine the caecum as well as the other areas of the large intestine, were used as the materials for the examination of the Paneth cells in the adenomas (Table 1).

One of these cases was Gardner's syndrome (Case 9). Two were autopsy cases and the other eight were surgically resected cases. The areas examined in these nine cases of F.P.C. were the part from the caecum to the sigmoid colon or to the rectum.

The entire length of the large intestine and one-third of the width were used for the serial tissue blocks. Haematoxylin and eosin stain was used for the detection of the Paneth cells and sometimes the Asan or Masson stain was added (Fig. 1-a, b). As the control we used the normal mucosa of these nine cases of F.P.C. and the normal mucosa of the large intestine taken from the surgically resected colon specimens with a disease other than F.P.C. (Table 2). The appendix was not examined.

*¹ 岩間毅夫, 字都宮謙二, 浜口栄祐: 2nd Department of Surgery (Chief: Prof. E. HAMAGUCHI), School of Medicine, Tokyo Medical and Dental University (Tokyo Ika Shika Daigaku).

Received for publication, February 24, 1975.

Table 1. Paneth cell in the colon of the familial polyposis coli

| Case | Sex and age | Area examined | Site of Paneth cell-bearing adenoma (rate of Paneth cell-bearing adenoma in caecum) | Paneth cells in normal mucosa | Carcinoma | Family and personal number |
|------|-------------|----------------------|---|-------------------------------|----------------------|----------------------------|
| 1. | F 49 | Caecum to rectum | — | — | Rectum | T63-III-1 |
| 2. | M 38 | Caecum to sigm. col. | + Caecum (only two adenomas) | + Caecum | — | T70-III-2 |
| 3. | M 54 | Caecum to rectum | ++ Caecum (34/103=33%), lower ascend. col. | + Caecum | Rectum | T78-II-f6 |
| 4*. | M 42 | Caecum to rectum | ++ Caecum (19/89=21%) | — | Rectum Sigm. col. | T78-II-f9 |
| 5. | M 53 | Caecum to rectum | ++ Caecum (59/203=29%) and lower ascend. col. | — | Rectum | T78-II-fm41 |
| 6. | F 46 | Caecum to rectum | ++ Caecum (92/215=43%) and lower ascend. col. | — | Ascend. col. | T74-III-2 |
| 7. | F 53 | Caecum to sigm. col. | + Caecum (several) | — | Sigm. col. | T89-III-4 |
| 8. | M 54 | Caecum to rectum | + Caecum | + Caecum | — | T88-III-4 |
| 9*. | M 25 | Caecum to sigm. col. | + Caecum to sigm. col. | — | — | G8-III-6 |

++=Paneth cells remarkable. +=Paneth cells scanty.

* =Autopsy cases. Case 9 is Gardner's syndrome.

Table 2. Control cases

| Case | Sex and age | Caecum | Colon | Rectum | Disease |
|------|-------------|--------|-------|--------|---------------------|
| 1. | M 62 | — | — | 0/918* | Carcinoma of rectum |
| 2. | M 70 | — | — | 0/475 | Carcinoma of rectum |
| 3. | M 48 | — | — | 0/974 | Carcinoma of rectum |
| 4. | F 62 | 2/296 | 0/589 | — | Carcinoma of caecum |
| 5. | M 19 | 1/554 | 0/916 | — | Lipoma |
| 6. | F 32 | 11/232 | — | — | Appendicitis |
| 7. | F 26 | 0/71 | 0/687 | — | Carcinoma of colon |

* Number of Paneth cell-bearing crypts/number of crypts which contact with muscularis mucosa.

RESULTS

The Paneth cell-bearing adenomas were detected in eight (89%) of nine cases of F.P.C.. In these eight cases the Paneth cell-bearing adenomas were seen in the caecum and in two of these cases the Paneth cell-bearing adenomas were also found in the distal part of the colon beyond the caecum and the colon ascendens.

The frequency of the Paneth cell-bearing adenomas in the caecum is shown in Table 1. In Case 1, no Paneth cells were found

in the adenomas and normal mucosa. In Case 2, the Paneth cells were found in only two adenomas in the caecum. In Case 6, the Paneth cells were detected in 92 out of the 215 adenomas (43%) in the caecum. In Case 3, numerous Paneth cells were seen (Fig. 1-a) in the large adenoma of the transverse colon as well as in the caecum and the proximal part of the colon ascendens. In Case 9, Gardner's syndrome, the Paneth cells were distributed in the adenomas from the caecum to the sigmoid colon. The rectum of this case could not be examined.

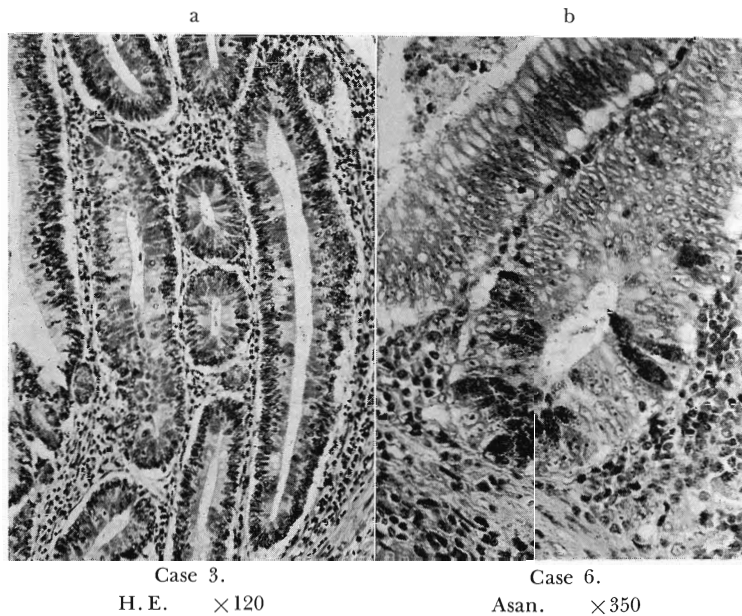


Fig. 1. The deep stained granules of the Paneth cells are seen.

In the adenomas the Paneth cells were seen in the middle and near the surface of the crypts as well as at the base.

The distribution of the Paneth cells in the adenoma was very irregular and the Paneth cells tended to form cell groups. Seven cases had carcinomas but no Paneth cells could be found in the carcinoma or in the area adjacent to it. Then we examined the normal mucosa of these nine cases of F.P.C. and found the Paneth cells in three cases (33%), confined to the base of the few crypts of the caecum.

In F.P.C., we can say that the Paneth cells are usually found in the adenomas of the caecum and the proximal part of the colon ascendens. The result of the examination of the Paneth cells in the normal mucosa of the large intestine which were obtained from the surgically resected specimens with a disease other than F.P.C. is shown in Table 2. The mucosa examined was near the tumor or the inflammation. In the control cases the Paneth cells were found at the very bottom of the crypts, con-

fined to the caecum. In the areas other than the caecum no Paneth cells were detected.

In the caecum the Paneth cells were found in three out of four cases (75%). The denominator in Table 2 is the number of the crypt, the bottom of which contacts the muscularis mucosa and the numerator is the number of the crypts, the bottom of which contain the Paneth cells. In the caecum of the control Case 6, the Paneth cells were found at the bottom in 11 out of 232 crypts (4.7%), but in other control cases the Paneth cells were seen in less than 0.7% of the crypts of the caecum.

DISCUSSION

In the small intestine the Paneth cells are seen at the very base of the crypts of Lieberkühn (Hertzog¹; Schmidt²; Lewin³).

Hally⁴ and Trier⁵ showed a close structural interrelationship between the Paneth cell granules and the Golgi complex. But little is known about the role of the Paneth cells in the small intestine (Trier⁶). Hertzog¹ and Schmidt² reported that in the

large intestine, if it is normal, no Paneth cells were seen. Keer and Lendrum⁷⁾ and Watson⁸⁾ stated that the Paneth cells were seen in the caecum occasionally, but none in the remainder of the adult large intestine.

Our result coincides with their result. On the contrary, Paterson and Watson⁹⁾ and Lauren¹⁰⁾ reported that the Paneth cells were found in the large intestine but Lauren¹⁰⁾ stated that in the more distal part of the large intestine there were less Paneth cells.

The Paneth cells appear in the large intestine when the mucosa is in an abnormal state. Paterson⁹⁾ reported that the Paneth cells number had increased enormously (even as much as 300-fold) in association with the regenerative phase of ulcerative colitis.

Watson⁸⁾ demonstrated the Paneth cells in 22 out of 23 cases in the caecum of ulcerative colitis but in only two out of 12 cases in the rectum with the same disease. Holmes¹¹⁾ observed the Paneth cells in the carcinoma of the colon.

We could not demonstrate the Paneth cells in the carcinomas of our cases. Lauren¹⁰⁾ and other authors (Schmidt²⁾; Holmes¹¹⁾; Lewin³⁾; Gibbs¹²⁾) reported on the Paneth cells found in the adenomas of the colon and rectum.

In the rectum, the frequency is low (Lemin³⁾). However, Gibbs¹²⁾ stated that the distribution of the Paneth cell-bearing adenomas is equal.

We have not found any literature on the Paneth cells in the adenomas of F.P.C. and on their distribution.

Our observation shows that in the large intestine of F.P.C. the Paneth cells are generally seen in the adenomatous polyp of the caecum and the proximal part of the colon ascendens.

Now we may conclude that the distribu-

tion of the Paneth cell bearing adenomas reflects the distribution of the Paneth cells in the normal large intestine. Then what is the origin of the Paneth cells found in the adenoma of the large intestine of F.P.C.? Watson⁸⁾ thought the Paneth cells found in ulcerative colitis are metaplastic cells. Gibbs¹²⁾ thought that the Paneth cells in the adenoma were sequestered in the adenoma. The cellular and structural morphology of the adenoma resembles the mother tissues generating the adenoma, so we believe that it is more natural to assume that the Paneth cells in the adenomas of F.P.C. differentiate in the adenoma like the goblet cells than to think that they are sequestered in the adenoma.

REFERENCES

- 1) Hertzog, A. J.: The Paneth cell. *Am. J. Pathol.*, 13: 351-359, 1966.
- 2) Schmidt, J. E.: Beiträge zur normalen und pathologischen Histologie einiger Zellarten der Schleimhaut des menschlichen Darmkanales. *Arch. Mikr. Anat.*, 66: 12-40, 1905.
- 3) Lewin, K.: The Paneth cell in disease. *Gut*, 10: 804-811, 1969.
- 4) Hally, A. D.: The fine structure of the Paneth cell. *J. Anat.*, 92: 268-277, 1958.
- 5) Trier, J. S.: Study on small intestinal crypt epithelium. *J. Cell Biol.*, 18: 599-620, 1963.
- 6) Trier, J. S.: The Paneth cells: An enigma. *Gastroenterology*, 51: 560-562, 1966.
- 7) Kerr, A. B., and Lendrum, A. C.: A chloride-secreting papilloma in the gall bladder. *Brit. J. Surg.*, 23: 615-639, 1936.
- 8) Watson, A. J., and Roy, R. D.: Paneth cells in the large intestine in ulcerative colitis. *J. Pathol. Bacteriol.*, 80: 309-316, 1960.
- 9) Paterson, J. C., and Watson, S. H.: Paneth cell metaplasia in ulcerative colitis. *Am. J. Pathol.*, 38: 243-249, 1961.
- 10) Lauren, P.: The cell structure and secretion in intestinal cancer. *Acta Pathol. Bacteriol. Scand. Suppl.* 152: 1-151, 1961.
- 11) Holmes, E. J.: Neoplastic Paneth cells. *Cancer*, 18: 1416-1422, 1965.
- 12) Gibbs, N. M.: Incidence and significance of argentaffin and Paneth cells in some tumors of the large intestine. *J. Clin. Pathol.*, 20: 826-830, 1967.