

## Case Report

DOI: 10.22114/ajem.v1i1.22

**Jejunal Perforation Following Blunt Abdominal Trauma; a Case Report**Atousa Akhgar<sup>1</sup>, Mohammad Taghi Talebian<sup>1</sup>, Mohamad Ashouri<sup>2</sup>, Shora Ghorbani<sup>1</sup>, Hadi Mirfazaelian<sup>1\*</sup>

1. Department of Emergency Medicine, Imam Khomeini Complex Hospital, Tehran University of Medical Sciences, Tehran, Iran.

2. Department of Surgery, Faculty of Medicine, Tehran University of Medical Sciences, Tehran, Iran.

**\*Corresponding author:** Hadi Mirfazaelian; Email: H-Mirfazaelian@sina.tums.ac.ir**Abstract**

**Introduction:** The possibility of intestinal injury for all patients presenting to emergency department (ED) with blunt abdominal trauma, despite minimal physical signs should be considered. To highlight the patient management, here, we report a case of hollow viscus injuries resulting from blunt abdominal trauma referring to a teaching hospital in Tehran, Iran.

**Case presentation:** A 30-year-old man presented to the ED after "falling into a hole" with his back and had direct blunt abdominal trauma by a heavy bag of cement. In physical examination, there was a mild abdominal tenderness on right upper quadrant. On bedside ultrasonography, there was small free fluid in his Morison's pouch without hypotension. So abdominal CT scan was performed which revealed free fluid in pelvic, perihepatic, and perisplenic spaces. Mural hematoma of proximal part of jejunum with mural wall hypodensity in mid jejunal loop were also revealed. The patient underwent surgery, and there was damage to the colon serosa and jejunal perforation which was primarily repaired.

**Conclusion:** The presented case highlights the importance of obtaining history and physical exam and paying attention to the nature and mechanism of injury. Emergency physicians should be aware of hollow viscus injury in traumatic patients. Any delay in diagnosis and operative management are associated with an increase in mortality.

**Key words:** Abdominal injuries; Emergency department; Intestinal perforation; Wounds, nonpenetrating

**Cite this article as:** Akhgar A, Talebian MT, Ashouri M, Ghorbani S, Mirfazaelian H. Jejunal Perforation Following Blunt Abdominal Trauma; a Case Report. *Adv J Emerg Med.* 2017;1(1):e9.

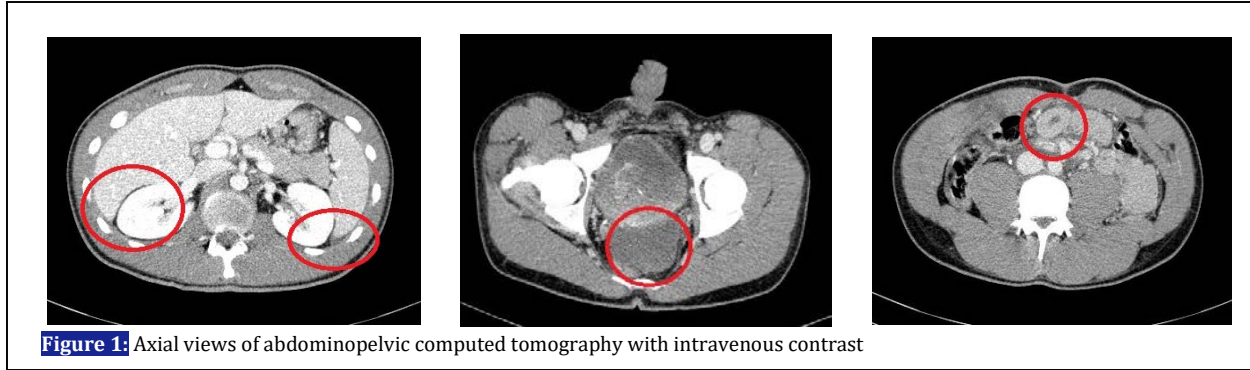
**INTRODUCTION**

Blunt abdominal trauma is one of the most prevalent complaints of patients referring to emergency departments (ED) and it can be a cause of morbidity and mortality among all ages. The possibility of intestinal injury for all patients presenting to ED with blunt abdominal trauma, despite minimal physical signs should be considered. Here, we report a case of hollow viscus injuries resulting from blunt abdominal trauma referring to a teaching hospital in Tehran, Iran.

**CASE PRESENTATION**

A 30-year-old man presented to the emergency department after "falling into a hole". The patient was a construction worker and fell with his back in a 2-meter hole which was followed by a blunt abdominal trauma due to a falling of a 30 kg bag of cement on his abdomen. The patient had no past medical history and was not on any treatment or drug abuse. On primary survey, the airway was intact and a hard collar had been put on. The breathing, lung auscultation, and O<sub>2</sub> saturation were in normal range. The blood pressure was

128/75 mmHg, pulse rate 90/min, and oxygen saturation of 96% while the patient was breathing ambient air. The patient underwent focused abdominal sonography for trauma patients (FAST) which showed small free fluid on lower pole of the right kidney. The patient was awake and fully conscious, the pupils were normal size and reactive, and there was not any neurologic deficit. The secondary survey was significant for the mild abdominal tenderness on right upper quadrant. The chest, and lateral neck portable x-rays were normal. After surgery consultation, it was planned to have an abdominopelvic computed tomography (CT) scan with intravenous contrast agent in order to pin point the problem. In few minutes, the pain had been increased in intensity which was claimed to be 7 out of 10 in numerical rating scale (NRS). The blood pressure did not show any significant change but the patient pulse rate was increased up to 110. Serial FAST exam showed increase in free fluid volume. The patient underwent CT imaging (figure 1). It showed a moderate volume of free fluid in pelvic area, perihepatic, and also



**Figure 1:** Axial views of abdominopelvic computed tomography with intravenous contrast

perisplenic spaces. Small bowel wall thickening due to mural hematoma of proximal part of jejunum with mural wall hypodensity in mid jejunal loop which are all suggestive of hollow viscus injury. There was no visible sign of solid organ damage or extra luminal free air. Regarding to the CT scan results, laparoscopy was performed. There was damage to the colon serosa and jejunal perforation which was primarily repaired. The patient was discharged 10 days later and had uneventful follow up.

#### DISCUSSION

Blunt abdominal trauma (BAT) carry great risk of morbidity and mortality due to possible missed diagnosis and being associated with multi-system injuries. Although injury to hollow viscus is uncommon, among these injuries, the intestine is the most likely to be damaged. The incidence of blunt bowel and mesenteric injuries occurs in about 5% of patients (1, 2). These injuries should be considered in presence of positive physical examination findings but even in the absence, such injuries do not preclude. The proposed mechanisms of intestinal injury in BAT include compression forces and deceleration forces which results in a spectrum of injury from intramural hematoma to perforation (3). BAT with bowel injury is occasionally difficult to diagnose specially in those with multiple injuries. So the mechanism of injury, history, serial physical examination and radiologic techniques play an important role in diagnosis. A delayed diagnosis results in a progressive septic insult and markedly increased mortality (4, 5). Patients with apparently significant blunt abdominal trauma even with minor sign and symptoms should be reviewed at frequent intervals, sometimes more investigation whether by imaging or diagnostic surgery like laparoscopy should undergo at the earliest sign of clinical deterioration (6, 7). Generally, immediate laparotomy in blunt trauma to abdomen indicates in those with peritonitis, perforation, refractory

hypotension with intra-abdominal injury, and gastrointestinal bleeding (3). Since intestinal injury usually does not lead to aforementioned condition, FAST might be helpful, in case of suspicion when the patient is hemodynamically stable, CT scanning is the diagnostic modality of choice. In fact, CT has become the standard imaging modality in high-risk patients with blunt abdominal injuries (8). Although several intra-abdominal injuries can be managed conservatively, hollow viscera injury requires operative management even in stable patient. Surgical options in cases of jejunal perforation include laparoscopy, conventional laparotomy, and endoscopic repair and we should consider that management of such cases needs to be individualized to the patient. In our case, the patient underwent laparotomy due to jejunal perforation and free fluid detected on CT scan.

#### CONCLUSIONS

Emergency physicians should be aware of possible hollow viscus injuries in patients with blunt abdominal trauma. The presented case highlights the importance of obtaining history and physical exam and paying attention to the nature and mechanism of injury.

#### ACKNOWLEDGEMENTS

We would like to thank all the ED staff whom participated in management of this case.

#### AUTHORS' CONTRIBUTION

All the authors met the standards of authorship based on the recommendations of the International Committee of Medical Journal Editors.

#### CONFLICT OF INTEREST

None declared.

#### FUNDING

None declared.

**REFERENCES**

1. Kordzadeh A, Melchionda V, Rhodes K, Fletcher E, Panayiotopolous Y. Blunt abdominal trauma and mesenteric avulsion: a systematic review. *Eur J Trauma Emerg Surg.* 2016;42(3):311-5.
2. Mehta N, Babu S, Venugopal K. An experience with blunt abdominal trauma: evaluation, management and outcome. *Clin Pract.* 2014;4(2):599.
3. Stawicki S. Trends in nonoperative management of traumatic injuries-A synopsis. *Int J Crit Illn Inj Sci.* 2017;7(1):38-57.
4. Beuran M. 18th European Congress of Trauma and Emergency Surgery. *Emergency.* 2017.
5. LaFace AR, Ciesla DJ. Blunt abdominal trauma. *Abernathy's Surgical Secrets E-Book.* 2017:112.
6. Ghazanfar A, Choudry Z, Zubair M, Nasir S, Khan S, Ahmed W. Abdominal Solid Visceral Injuries in Blunt Abdominal Trauma. An Experience in Busy Surgical Unit of Mayo Hospital, Lahore. *Ann KE Med Coll.* 2001;7(2):85-7.
7. Sandiford N, Sutcliffe R, Khawaja H. Jejunal transection after blunt abdominal trauma: a report of two cases. *Emerg Med J.* 2006;23(10):e55.
8. Diercks DB, Mehrotra A, Nazarian DJ, Promes SB, Decker WW, Fesmire FM. Clinical policy: critical issues in the evaluation of adult patients presenting to the emergency department with acute blunt abdominal trauma. *Ann Emerg Med.* 2011;57(4):387-404.