

Radial Osteochondroma in a Chilean Pure Breed Rodeo Horse:

First Case Report in this Breed

Osteocondroma radial en un caballo chileno de rodeo:

Primer reporte de caso en esta raza

Felipe Corrêa^{a,c*}, David Parra^b, Carlos González^a, Felipe Lara^a

^aEscuela de Medicina Veterinaria, Facultad de Ecología y Recursos Naturales, Universidad Andres Bello, República 440, Santiago, Chile.

^bClínica Veterinaria Las Troyas, Talagante, Chile.

^cPrograma de Doctorado en Medicina Veterinaria, Facultad de Ecología y Recursos Naturales, Universidad Andres Bello, República 440, Santiago, Chile.

*Autor de correspondencia: felipe2983@gmail.com

ABSTRACT

A 5 year-old Chilean pure breed rodeo gelding was evaluated for lameness in the right forelimb and effusion of the common carpal sheath of the digital flexor tendons. Radiographs revealed exostosis with rounded margins arising from the palmar cortex of the distal metaphysis of the radius. Ultrasonographic examination revealed a thickened and proliferative synovium, excessive anechoic fluid and a hyperechogenic mass protruding from the cortical bone. Tenoscopic exploration confirmed the presence of the mass, and removal was successfully performed through thecotomy. At 4 months postoperatively, the horse was successfully competing although present mild right forelimb lameness and improving.

Key words: Equine, tumour, lameness, carpus.

RESUMEN

Un caballo chileno de rodeo fue evaluado por claudicación en el miembro anterior derecho y efusión de la vaina sinovial carpal de los tendones digitales flexores. Las radiografías revelaron una exostosis con márgenes romos provenientes de la corteza palmar de la metafisis distal del radio. La ecografía demostró la presencia de sinovia proliferativa aumentada de tamaño, exceso de fluido anecoico y una masa hiperecoica que protruía desde

hueso cortical. La tenoscopia confirmó la presencia de la masa, y su remoción resultó exitosa a través de tecomía. A los 4 meses pos-operatorio, el caballo se encontraba compitiendo aunque presentaba una leve claudicación.

Palabras clave: Equino, tumor, cojera, carpo.

INTRODUCTION

Osteochondroma (OC) is an osseous protrusion comprised by marrow and cortical bone, with an overlying cap of cartilage (Giudici *et al.* 1993, Mavrogenis *et al.* 2008). Rather than a true neoplasm, OC can be classified as a developmental lesion that appears at a young age (Kushner *et al.* 2015). It results from disturbance of endochondral ossification and therefore can arise from any bone that forms from cartilage (Evaniew *et al.* 2015). Typical OC can be diagnosed radiographically by their characteristic attachment to bone with continuity of both the cortices and the medullary canal (Evaniew *et al.* 2015). Osteochondroma is the most common benign skeletal tumor in man, as it accounts for 10-15% of all bone tumors, with an estimated incidence of 1-2% in the general population, and demonstrates a male predominance (Kushner *et al.* 2015). This case report describes the clinical presentation, radiographic, ultrasonographic, histopathologic and tenoscopic evaluation and further removal of an OC in the palmaro-distal aspect of the radius in a Chilean pure breed rodeo horse.

MATERIAL AND METHODS

Case History: a 5 year-old Chilean pure breed gelding was evaluated for lameness in the right forelimb and effusion of the right common carpal sheath, which has been presented since 60 days earlier. The horse was been used for Chilean rodeo and there was no history of intrathecal medication or a puncture wound associated with the common carpal sheath.

Clinical findings: upon presentation, the patient was alert and responsive. A body condition score was recorded as 4/9. At trot, the horse had 3/5 grade lameness in the right forelimb, with reduction of the cranial phase of the stride, intermittent stumbling when turned in circles and a more pronounced lameness with the affected limb on the outside of the circle on soft ground, which did not change after palmar digital nerve, abaxial sesamoid or low four points and high four points nerve blocks. No forced flexion tests were performed due to the lameness intensity and the marked pain at the carpal flexion. On physical examination, there was marked effusion of the common carpal sheath, but was not painful to palpation.

Imagenology examination: radiographic examination revealed an exostosis with rounded margins arising from the palmar cortex of the distal metaphysis of the radius, which protruded 4 cms. palmary (Fig 1). Ultrasonographic examination of the affected tendon sheath revealed a thickened and proliferative synovium and excessive anechoic fluid. At the level of the distal radial metaphysis, there was an hiperechogenic mass protruding from the cortical bone in contact with the deep digital flexor musculotendinous unit (Fig 2), but no tendon or muscle fiber damage was found. The accessory ligament of the superficial digital flexor tendon (ALSDFT) was enlarged and presented an altered fiber pattern (Fig 3). Exploratory tenoscopy was recommended, as well as for removal of the bony proliferation of the distal radius.

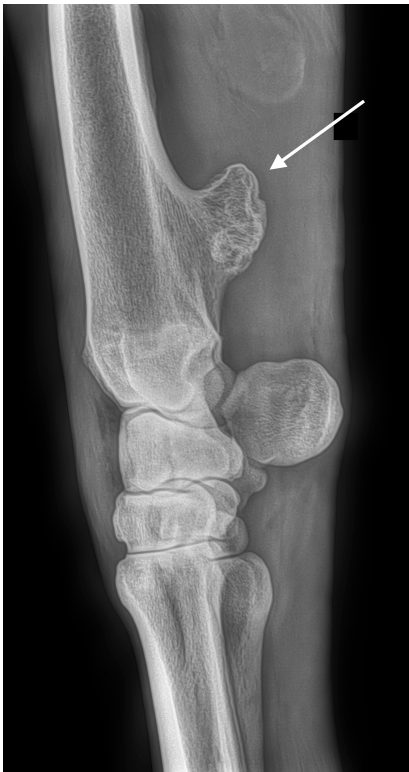

Figure 1. Latero-medial radiograph of the palmaro-distal aspect of the radius in a Chilean pure breed gelding with persistent effusion of the common carpal synovial sheath and 3/5 lameness in the right forelimb. The bony exostosis (arrow) originate from the caudal remnant of the distal physis of the radius and appear as rounded bony mass that protrudes towards the common carpal synovial sheath.

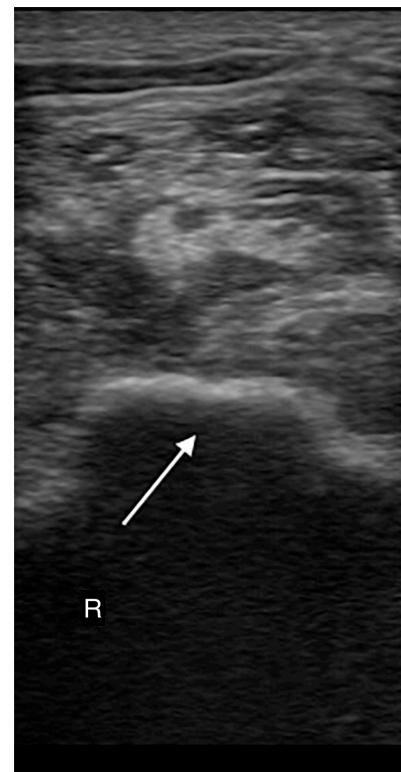


Figure 2. Ultrasonography view of the caudal distal antebrachium: Palmar radius exostosis (arrow) in contact with the deep digital flexor muscle.

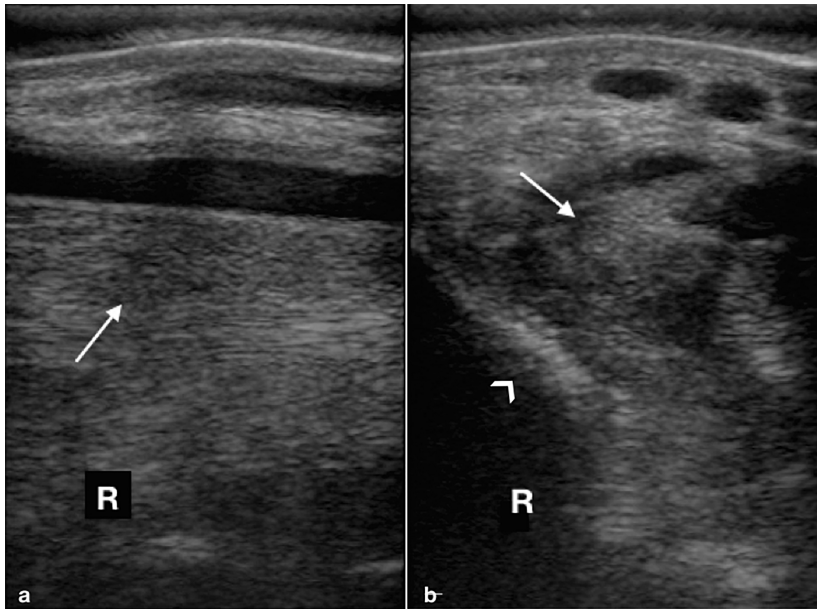


Figure 3. Ultrasonography view of the carpal canal: Longitudinal section (left): altered fiber pattern (arrow) of the accessory ligament of the superficial digital flexor tendon (ALSDFT). The left side is proximal. Transversal section (right): hypoechogenic and poor margin definition (arrow) of the ALSDFT. The left side is dorsal.

Surgical treatment: preoperatively, the horse received gentamicin sulfate (6.6 mg/kg i.v.), procaine penicillin G (22,000 IU/kg i.m.) and phenylbutazone (2.2 mg/kg i.v.). The horse was sedated with xylazine (1.1 mg/kg i.v.) and the induction protocol used was diazepam (0.09 mg/kg IV) and ketamine (2.2 mg/kg i.v.). Anesthesia was maintained with isoflurane and 100% oxygen via intermittent positive pressure ventilation. The horse was placed in dorsal recumbency and routinely prepared and draped for surgery. Centesis of the common carpal sheath yielded serosanguineous synovial fluid. The tendon sheath was distended with 60 ml isotonic lactated Ringer's solution (Baxter Healthcare, Deerfield, IL, USA) and the arthroscope entry portal was made 8 cm proximal to the lateral aspect of the distal radial physis. Exploration of the affected tendon sheath identified a mass containing nodular white material in the cranial aspect of the tendon sheath (Fig 4), extending from the distal radial physis to the most proximal reflection of the tendon sheath. There was also generalized synovial blunting and proliferation, particularly in the epitenon of the deep digital flexor tendon adjacent to the mass. No evidence of fibrin or pannus formation was observed. Complete tenoscopic removal of the mass was attempted, but excessive hemorrhage inhibited visualization. Consequently, theotomy was performed to allow complete debridement of the mass. The large size of the mass did not allow complete tenoscopic investigation of the affected carpal tunnel, making proper visualization of the ALSDFT impossible. After mass removal, digital palpation of the distal radial physis revealed no prominent osseous spicule. The tendon sheath was thoroughly lavaged with isotonic lactated Ringer's solution and the capsule and subcutaneous tissue were closed with 2-0 polyglactin 910 (Coated Vicryl, Ethicon Inc.) in a simple continuous pattern. The skin was sutured in a simple interrupted pattern using 2-0 nylon (Ethilon, Ethicon Inc.). The tendon sheath was injected with 500 mg of

amikacin before a full limb bandage was applied. The osseous mass was submitted for gross pathology and histopathological analysis.

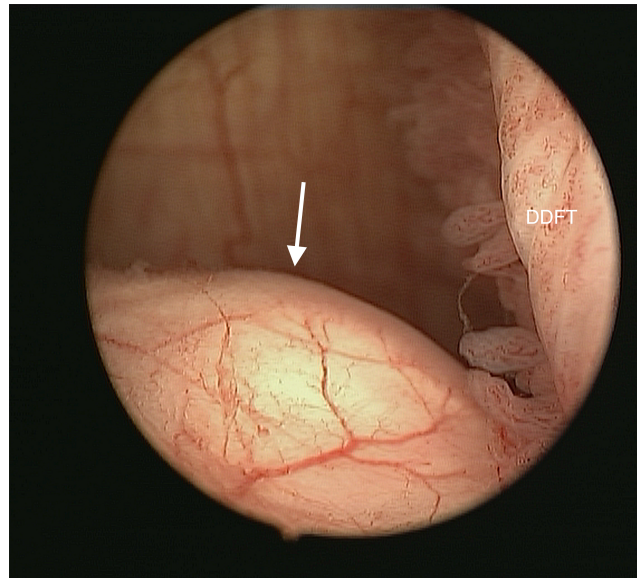


Figure 4. Tenoscopic view of the mass (arrow) in the cranial aspect of the tendon sheath, extending from the distal radial physis to the most proximal reflection of the tendon sheath. The deep digital flexor tendon can be observed in contact with the mass.

RESULTS AND DISCUSSION

Postoperatively the horse was treated for 5 days with gentamycin sulfate (6.6 mg/kg i.v., s.i.d.), potassium penicillin (22,000 IU/kg i.m., q.i.d.) and phenylbutazone (2.2 mg/kg i.v., s.i.d.). During hospitalization, the horse displayed normal clinical parameters and remained comfortable on the affected limb. It was discharged 5 days postoperatively, with instructions to administer phenylbutazone (1 g p.o., s.i.d.) for 5 days and to remain on stall rest with a full limb bandage for 4 weeks. At the time of discharge, the affected tendon sheath had mild to moderate effusion.

A follow-up examination 4 months postoperatively revealed no effusion of the affected sheath. The horse was sound at walk, but a mild lameness at trot was noticed, although the horse was successfully competing managed by systemic analgesia.

A firm, 4.5 x 2.6 x 3.2 cms. homogenous white mass was extirpated (Fig 5). A soft layer of tissue of which grossly appeared to be cartilage covered the top of the process. All the margins were blunt except for a medial protrusion that was sharp.

Histologically, the demineralized mass consisted of a core of trabecular bone covered by a cap of hyaline cartilage (Fig 6). The chondrocytes were arranged in columns, thus resembling those of a growth plate.

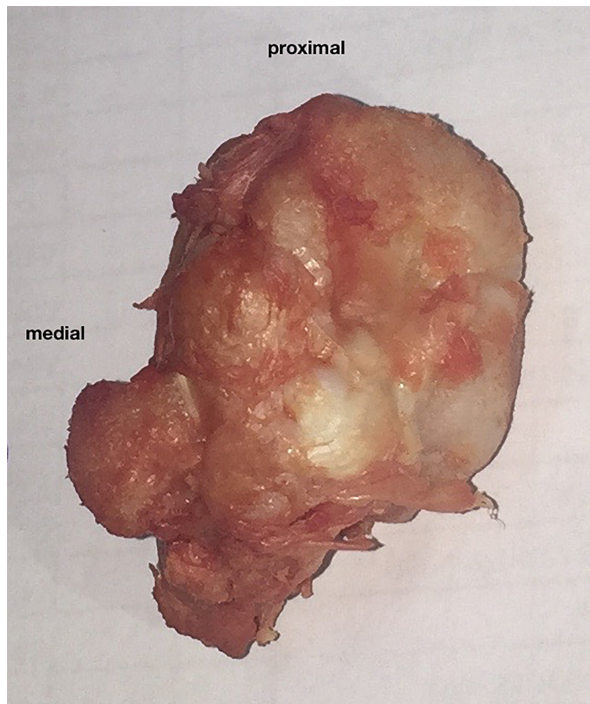


Figure 5. Firm mass of 4.5 x 2.6 x 3.2 cms after surgical removal. All the margins were blunt except for a medial protrusion that was sharp.

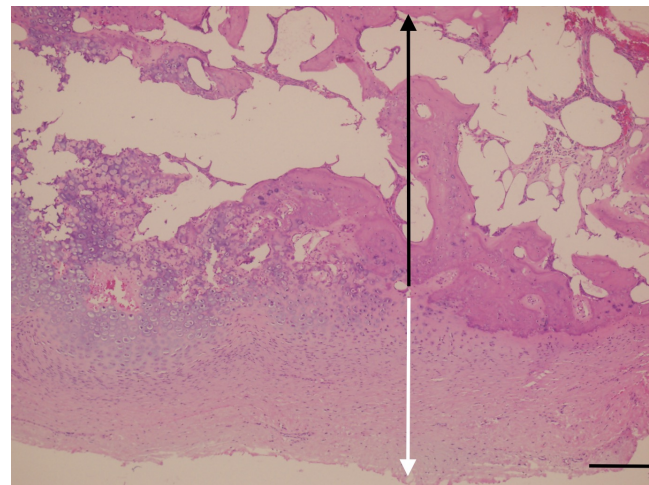


Figure 6. Periosteum appears as a fibrous capsule. The cartilage resembles disorganized growth plate with ossification towards base (white arrow). Bony trabeculae appear normal with normal appearing marrow (black arrow). No spindle cells are observed. H&E stain, bar=100um.

Based on the described findings, the clinical and radiographic findings, diagnosis of osteochondroma formation was confirmed.

Equine osteochondroma publications are uncommon as only very few case reports and retrospective studies have been reported (Stahre and Tufvesson 1967, Lundvall and Jackson 1976, Lee *et al.* 1979; Held *et al.* 1988, Squire *et al.* 1992, Southwood *et al.* 1997, Jansson 1998, Wright and Minshall 2012). Reported cases comprise different breeds and no breed predilection has been suggested (Wright and Minshall 2012). To the author's knowledge, this is the first case report of an osteochondroma in a Chilean pure breed horse.

Clinical symptoms displayed by the horse of the present case report are consistent with those described in previous publications of OC formation in horses, in which distention of the carpal canal and lameness of varying degrees are described (Stahre and Tufvesson 1967, Honnas 1992, Southwood *et al.* 1997, Jansson 1998, Stashak 2002, Wright *et al.* 2012). In this case the authors believe that the real cause of the lameness was desmitis of the ALSDFJ due to the sharp medial margin of the OC, which is supported by the reduction of the cranial phase of the stride observed in this horse.

Different space-occupying lesions in the carpal canal sheath can cause this syndrome, OC formation at the distal radial metaphysis being one of them (Jorgensen *et al.* 2015). Other space-occupying lesions to consider as clinical differential diagnoses are flexor tendon tendinitis, tenosynovitis, fracture of the accessory carpal bone, physeal reaction or exostosis of the caudodistal radius and desmitis of the ALSDF (Squire *et al.* 1992, Stashak 2002, Jorgensen *et al.* 2015).

Radiographs are the main imaging modality used in veterinary medicine to characterize the primary tumor (Jorgensen *et al.* 2015). Other diagnostic imaging modalities used in human medicine such as magnetic resonance imaging, computed tomography and nuclear scintigraphy are not available for the equine practitioner in Chile. In this case report, radiographs were taken to depict the radiographic characteristics of the bone affected by the tumor. In these views, proliferative periosteal reaction with rounded margins arising from the palmar cortex of the distal metaphysis of the radius was observed. Usually biopsy is not required due to radiographic and clinical appearance of these horses.

Different than surgical removal, no other treatment options have been reported in the literature for equine patients. In the current case, surgical excision was possible and prognosis for the horse was considered good. Clinical signs did not worsen throughout the treatment period and the horse maintained good body condition, appetite and normal behavior. Four months later the horse maintain a 1/5 lameness but it managed to perform.

In the present case, the OC was removed employing an incisional approach to the carpal canal (Lundvall and Jackson 1976, Lee *et al.* 1979, Stashak 1987, Held *et al.* 1988, Honnas 1992). Reports describing endoscopic approaches to the carpal canal sheath have been published (Squire *et al.* 1992, Southwood *et al.* 1997, Cauvin *et al.* 1997). Endoscopic surgery of the tendon sheath is performed using a 4 mm arthroscope inserted via proximo-medial (Squire *et al.* 1992) or proximo-lateral (Southwood *et al.* 1997) entry portal, a disto-lateral endoscopic approach also has been described (Cauvin *et al.* 1997). Reported advantages of the endoscopic technique when compared to the incisional approach include reduced tissue trauma and risk of infection, improved visualization within the tendon sheath, better cosmetic results and shorter surgery and convalescence times (Squire *et al.* 1992, Southwood *et al.* 1997). The incisional technique used in the present case allowed a relatively short skin incision (6 cms.), plus careful tissue handling resulted in no unwanted effects of the surgery. The convalescence regimen recommended for the present case is comparable to that reported in previous publications.

This case report has documented an OC in the distal metaphysis of the radius, and to the authors' knowledge this is the first report on a Chilean pure breed rodeo horse. Radiographic, ultrasonographic and tenoscopic evaluation are helpful in order to determine the damage on the associated anatomical structure,

although histopathology is essential to confirm the diagnosis. Given the fair outcome of this case, surgical treatment should be advised in cases of osteochondroma to improve the prognosis for return to athletic activity.

ACKNOWLEDGEMENTS

The authors would like to thank the collaboration of Universidad Andres Bello Equine Clinic and Clinica Veterinaria Las Troyas staff for their technical assistance.

REFERENCES

- Cauvin, E. R. J., Schramme, M. C. and Munroe, G. Ä. 1997. Endoscopic examination of the carpal flexor tendon sheath in horses. *Proceed. Sci. Meet. Europ. Coll. Vet. Surg.* 6, 47-48
- Evaniew, N., Bayegan, D., Popovic, S., Parasu, N. and Ghert, M. 2015. Infrapatellar fat pad osteochondroma: Three cases and a systematic review. *J Knee Surg.* 28: 229-238.
- Giudici, M.A., Moser, R.P. and Kransdorf, M.J. Cartilaginous bone tumors. 1993. *Radiol Clin North Am.* 31: 237-259.
- Held, J. P., Patton, C. S. and Shires, M. 1988. Solitary osteochondroma of the radius in three horses. *J. Am. Vet. Med. Assoc.* 193: 563-564
- Honnas, C. M. 1992. Osteochondroma In: Auer, J.A. (Ed): *Equine surgery* W.B.Saunders Company, Philadelphia.1: 038-103
- Jansson, N. 1998. Osteochondroma at the distal radius metaphysis in a horse. *Pferdeheilkunde* 14, 151-154.
- Jorgensen, J. S., Genovese, R. L., Döpfer, D. and Stewart, M. C. 2015. Musculoskeletal lesions and lameness in 121 horses with carpal sheath effusion (1999-2010). *Veterinary Radiology & Ultrasound*, 56: 307–316.
- Kushner, B.H., Roberts, S.S., Friedman, D.N., Kuk, D., Ostrovnaya, I., Modak, S., Kramer, K., Basu, E.M., Cheung, N.K. 2015. Osteochondroma in long-term survivors of high-risk neuroblastoma. *Cancer.* 15;121 : 2090-2096.
- Lee, K.C., Davies, A.M., Cassar-Pullicino, V.N. 2002. Imaging the complications of osteochondromas. *Clin Radiol.* 57:18-28.

- Lee, H. A., Grant, B. D. and Gallina, A. M. 1979. Solitary osteochondroma in a horse: a case report. *J. Equine Med. Surgery* 3: 113-115
- Lundvall, R. L. and Jackson, L. L. 1976. Periosteal new bone formation of the radius as a cause of lameness in two horses. *J. Am. Vet. Med. Assoc.* 168, 612-613
- Mavrogenis, A.F., Papagelopoulos, P.J., Soucacos, P.N. 2008. Skeletal osteochondromas revisited. *Orthopedics.* 31: 1018-1028.
- Murphey, M.D., Choi, J.J., Kransdorf, M.J., Flemming, D.J., Gannon, F.H. (2000). Imaging of osteochondroma: variants and complications with radiologic-pathologic correlation. *Radiographics.* 20: 1407-1434.
- Newman, J.C., Lustgarten, M., Berman, K.G., Vivrette, S. and Redding WR. 2014. Surgical treatment of sinovial osteochondromatosis in the carpal joint of a pony. *Equine Veterinary Education.* 26: 395-399.
- Nixon, A.J, Schachter, B.L. and Pool, R.R. 2004. Exostoses of the caudal perimeter of the radial physis as a cause of carpal synovial sheath tenosynovitis and lameness in horses: 10 cases (1999-2003). *J. Am. Vet. Med. Assoc.* 15; 224: 264-270.
- Stashak, T. S. 1987. Osteochondroma formation at the distal radius (supracarpal exostoses). In: Stashak, T.S. (Ed): *Adams' lameness in horses.* 4 th Ed. Lea & Febiger, Philadelphia, 663-665.
- Stahre, L. and Tufvesson, G. 1967. Volar, supracarpal exostoses as causes of lameness in the horse. *Nord. Vet. Med.* 19: 356-361.
- Squire, K.R.E., Adams, S.B., Widmer, W.R., Coatney, R.W. and Habig, C. 1992. Arthroscopic removal of a palmar radial osteochondroma causing carpal canal syndrome in a horse. *J. Am. Vet. Med. Ass.* 201: 1216-1218.
- Southwood, L.L., Stashak, T.S., Fehr, J.E. and Ray, C. 1997. Lateral Approach for endoscopic removal of solitary osteochondromas from the distal radial metaphysis in three horses. *J. Am. Vet. Med. Ass.* 210: 166-1168.
- Wright, I. M. and Minshall, G. J. (2012) Clinical, radiological and ultrasonographic features, treatment and outcome in 22 horses with caudal distal radial osteochondromata. *Equine Veterinary Journal*, 44: 319–324. *J. Am. Vet. Med. Ass.*