

REFERENCES

1. de Guerre LEVM, Dansey K, Li C, Lu J, Patel PB, van Herwaarden JA, et al. Late outcomes after endovascular and open repair of large abdominal aortic aneurysms. *J Vasc Surg* 2021;74:1152-60.
2. Oliveira-Pinto J, Ferreira RS, Oliveira NFG, Hoeks S, Van Rijn MJ, Raa ST, et al. Total luminal volume predicts risk after endovascular aneurysm repair. *Eur J Vasc Endovasc Surg* 2020;59:918-27.

<https://doi.org/10.1016/j.jvs.2021.05.011>

Toward a unified pathophysiology in COVID-19 acute aortopathies



The interesting article by Katsarou et al¹ about aortic intramural hematoma complicating a severe acute respiratory disease coronavirus 2 (SARS-CoV-2) infection is

compelling, and its pathophysiology needs to be elucidated further.

We consider the promoting factors of coronavirus disease 2019 (COVID-19) to be the high number of angiotensin-converting enzyme 2 receptors present in the aortic walls. These receptors directly bind COVID-19 virions and lead to abnormal apoptosis of endothelial cells.² This process can explain the direct onset of the rare acute aortitis associated with COVID-19.³ For other vascular—mainly aortic—complications of SARS-CoV-2 infection, we emphasize the important role of the secondary damage to the vasa vasorum (VV), which begins with an acute lymphocytic endotheliitis. As in other capillaries and arterioles, it consists of a diffuse endothelial

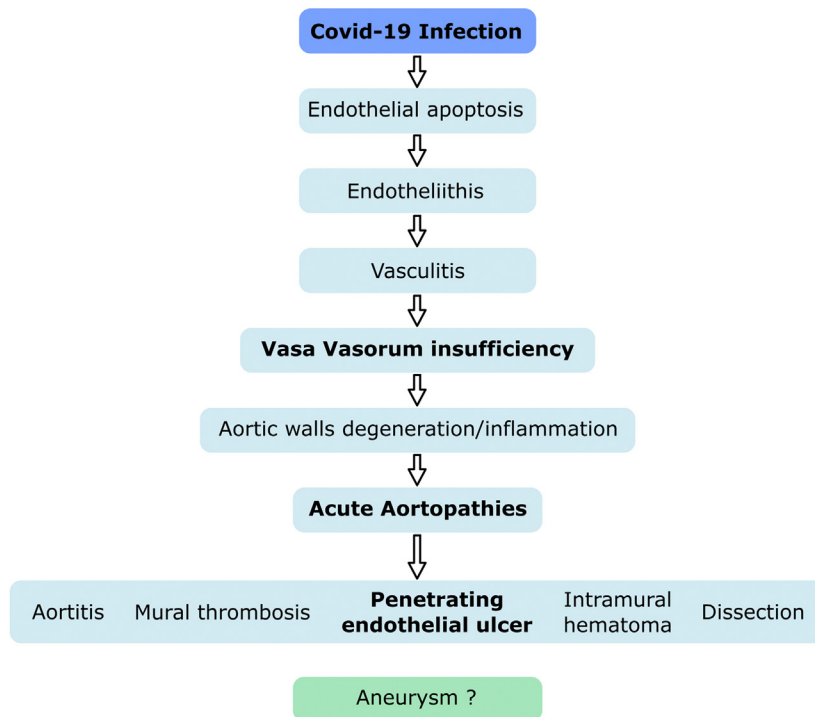
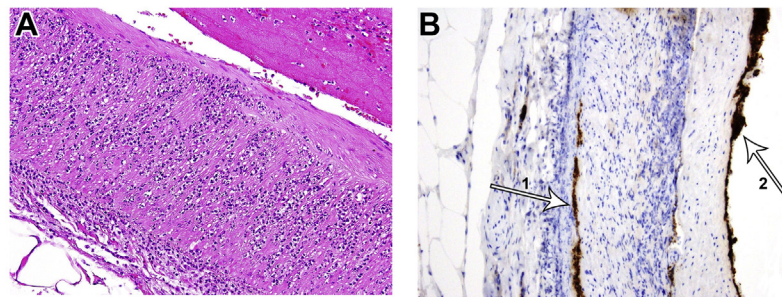


Fig. A. Leukocytoclastic vasculitis with neutrophils infiltration and karyorrhexis in the tunica media and adventitia of the abdominal aorta (stain: hematoxylin and eosin; original magnification $\times 10$). **B.** Immunohistochemistry for CD61: platelets interaggregate inside an occlusive thrombosis of an external vasa vasorum (VV) (arrow 1) and adhere to the endothelial cells (arrow 2) (2f2 clone, $\times 10$). (Modified from Roncati L, et al.⁵). Schematic flow chart: a cascade of vascular events triggered by coronavirus disease 2019 (COVID-19).

and parietal infiltration by mononuclear cells and neutrophils, followed by accelerated pyroptosis and thrombosis. This pathology can further evolve through activated B lymphocytes that generate plasma cells, in turn leading to a deposition of polyclonal immune complexes and complement fractions in vessels walls.

This immunocomplex-mediated peri/pan-arteritis, evident on histology with neutrophil infiltration and accumulation of fibrinoid materials, seems to be a more severe leukocytoclastic vasculitis (Fig, A).⁴ The associated inflammatory state causes an increased release of cytokines, typically interleukin-6, and, at the same time, recruitment of platelets to perform, in agreement with their myeloid lineage, a covercytosis against the virions. Moreover, platelets strictly adhere to damaged endothelia and surround the fibrin aggregates. Newly manufactured antiphospholipid antibodies, as in a secondary antiphospholipid-like syndrome, favor, together with the basic COVID-19 procoagulative state, local thromboses, that acquire the particular feature of immunothrombosis.

In medium and large arteries, this pathology involves the external VV as well, while the internal VV, because of their small caliber, thinner walls, and lower blood inflow, disappear as a direct result of the antecedent endothelial damage (Fig, B).⁵ As shown,⁶ the subsequent hypoxia in arterial walls produces hypoxia-inducible factor 1 α , in turn releasing other substances, such as matrix metalloproteinases, macrophages, monocytes, and chemoattractant proteins, specific for secondary degenerative-inflammatory lesions. In addition to endothelin-1 and angiotensin II type 1, vasoconstrictors are active on the VV as well.⁶ This process worsens the local preinflammatory or inflammatory conditions, already promoted by preexisting endothelial dysfunction, increases the degradation of collagen and elastic fibers, and greatly decreases the population of smooth muscle bundles in the media layer. In the VV, we have to consider, as an additional functional factor hampering blood inflow, their radial or circumferential external compression by inelastic atherosclerotic vessels, mainly when stressed by arterial hypertension. This cascade of pathological events directly explains the pathogenesis of penetrating endothelial ulcers that connect with the entire group of acute aortopathies associated with COVID-19, including mural thrombosis, intramural hematoma, and dissection (Fig). In contrast, the acute or subacute development of an aneurysm, which is in this case inflammatory, hypothesized to be caused by the decreased elasticity and increased fragility of the aortic walls, has not yet been reported.⁷ This unified anatomic-clinical notion of acute aortopathies, including different pathologies with reciprocal connections, fits well with the wide spectrum of COVID-19 features and prompts research on this disease complications, which may be otherwise overlooked.

Luca Roncati, MD

Department of Pathology
University of Modena and Reggio Emilia
Modena, Italy

Antonio Manenti, MD
Alberto Farinetti, MD
Gianrocco Manco, MD

Department of Surgery
University of Modena and Reggio Emilia
Modena, Italy

Anna Vittoria Mattioli, MD, PhD

Department of Cardiology
University of Modena and Reggio Emilia
Modena, Italy

REFERENCES

1. Katsarou M, Grassi V, Lomazzi C, Domanin M, Trimarchi S. Acute retrograde type A intramural hematoma during severe acute respiratory syndrome coronavirus 2 pandemic. *J Vasc Surg* 2021;73:2166-7.
2. Roncati L, Gallo G, Manenti A, Palmieri B. Renin-angiotensin system: The unexpected flaw inside the human immune system revealed by SARS-CoV-2. *Med Hypotheses* 2020;140:109686.
3. Dhakal P, Khadka S, Clowes JA, Chakinala RC. Aortitis in COVID-19. *IDCases* 2021;24:e01063.
4. Manenti A, Farinetti A, Manco G, Mattioli A. Vasculitis and aortitis: COVID-19 challenging complications. *J Vasc Surg* 2021;73:347-8.
5. Roncati L, Manenti A, Mattioli A. The Covid-19 arterial thromboembolic complications: from inflammation to immunothrombosis through antiphospholipid antibodies. *Ann Vasc Surg* 2021;72:216-7.
6. Kugo H, Sukketsiri W, Tanaka H, Fujishima R, Moriyama T, Zaima N. Time-dependent pathological changes in hypoperfusion-induced abdominal aortic aneurysm. *Biology (Basel)* 2021;10:149.
7. Tanaka H, Unno N, Suzuki Y, Sano H, Yata T, Urano T. Hypoperfusion of the aortic wall secondary to degeneration of adventitial vasa vasorum causes abdominal aortic aneurysms. *Curr Drug Targets* 2018;19:1327-32.

<https://doi.org/10.1016/j.jvs.2021.07.131>

Reply



We thank Dr Roncati for reading and commenting¹ on our case reporting an acute aortic intramural hematoma (IMH) in a SARS-CoV-2 positive patient.² The author¹ suggests a combination of different pathophysiologic mechanisms of aortic injury in these patients, which is undoubtedly an interesting aspect to consider in the ever-growing association between SARS-CoV-2 infection and vascular disease.³ In the clinical setting, SARS-CoV-2 is associated with hypercoagulability leading to peripheral arterial and venous thrombosis, but some aortic phenomena have been described as well.^{3,4}

Historically, acute aortic syndromes and mostly IMHs have been associated with vasa vasorum degeneration and/or rupture.⁵ Roncati et al suggest a SARS-CoV-2-related vasa vasorum "endotheliitis" driven by the innate and adaptive immune systems and also involving platelet activation. This immunothrombosis ultimately