

The influence of early orthodontic treatment on the growth of craniofacial complex in deciduous occlusion of unilateral cleft lip and palate patients

Inese Maulina, Dace Priede, Laura Linkeviciene, Ilze Akota

SUMMARY

This study evaluates dental occlusion and dental arch parameters of 5-6 year old children with unilateral cleft lip and palate (UCLP) treated and untreated orthodontically before lip plastic with noncleft children. The aim of the study was to verify whether early orthodontic treatment improves deciduous dental arch relationship of children with unilateral cleft lip and palate. 135 casts of 5-6 year old children from Riga and Vilnius were evaluated. 90 casts from children with UCLP (45 – got early orthodontic treatment, 45 – without early orthodontic treatment) and 45 casts from noncleft children. All patients with UCLP had surgically closed lip and palate; five-Year-Olds, Index was used to assess dental arch relationship of UCLP patients. Measurements of dental arch length, canine and molar arch width was taken similar to Bland and Altman method.

Statistical analysis: the difference of the mean values was tested using t-test between and within groups: UCLP-1 (without early orthodontics), UCLP-2 (treated orthodontically before lip plastic) and control group - noncleft children). Measurements were performed by two calibrated orthodontists, mean error was calculated according to the Dalberg method. Measurement error was less than 1 mm. Measurements showed that the occlusion parameters and transverse distance between deciduous molars of UCLP-1 group differed from the occlusion of UCLP-2. Children who had got early orthodontics showed better growth of the maxillae. More cases with positive overjet and meziodistal or distal deciduous molar relationship had treated with early orthodontics. Maxillary width between deciduous molars was statistically significant wider in children with UCLP who had early orthodontic treatment comparing with untreated children. Growth of mandible was not inhibited and did not differ treated and untreated children with UCLP and control group.

Key words: UCLP, growth of craniofacial complex, early orthodontics, deciduous dentition, Goslon Yardstick Index, jaw dimensions.

INTRODUCTION

Facial cleft is one of the most common congenital anomaly in craniofacial complex.

¹Riga Cleft Lip and Palate Center, Dept. of Orthodontics, Institute of Stomatology, Riga Stradins University

²Institute of Odontology, Medicine Faculty, Vilnius University

³Riga Cleft Lip and Palate Center, Dept. of Cranio-Maxillofacial and Plastic Surgery, Institute of Stomatology, Riga Stradins University

*Inese Maulina*¹ – D.D.S.

*Dace Priede*¹ – D.D.S.

*Laura Linkeviciene*² – D.D.S.

*Ilze Akota*³ – D.D.S., Dr.med., MsSc (Oslo), Professor, MRCS Ed.

Address correspondence to Dr. Inese Maulina, Dept. of Orthodontics, Institute of Stomatology, Riga Stradins University, 20 Dzirciema street, Riga LV 1007, Latvia.

Multidisciplinary team treats children with the aim to improve aesthetics, function and growth. Early orthodontic treatment have been discussed already forty years. Some authors (Pruzansky, Pahl-Andersen and Meijer) recommended to improve surgery without early orthodontic before [1, 2]. Winters and Hurwitz accept facilitate to primary surgery, but deny orthodontic benefits especially in long period. Bongaarts and Kuijpers-Jagtman disclaim any early orthodontics influence to deciduous occlusion [1, 3].

Long term effect of early orthodontics described Grabowsky, Koop, Hendri, Balagh [4, 6].

Lisson and Trankman point out that surgery must be reduced to minimum because it always has

a significant influence upon maxillary growth [5]. Following that orthodontic treatment should be planned and performed to support craniofacial growth and prevent maxillary dental arch deficiency.

Early orthodontics favorable influence on maxillary arch form and dimensions, feeding, psychological situation of the parents, speech development and influence on primary surgery was mentioned from Friede, Katsaros, Koželj, Jacobson, Rosenstein [7, 8, 9, 10]. Improvement of the palatal dimensions alike noncleft infants after early orthodontics by removing the tongue from the cleft described V. Koželj [11].

About cost ineffectiveness and difficult cooperation with little children reported Natsume [12].

Each craniofacial team is using the most available treatment protocol with the aim to achieve the best result.

The aim of this study was evaluate early orthodontics effectiveness and influence to deciduous occlusion and the maxillae growth until 5-year age of the child with unilateral cleft lip and palate.

MATERIALS AND METHODS

One hundred thirty five dental plaster casts of five-year-old children borned from 1984 to 2001:

- 45 models of UCLP operated (lip and palate surgery) patients without any orthodontic treatment (UCLP-1);

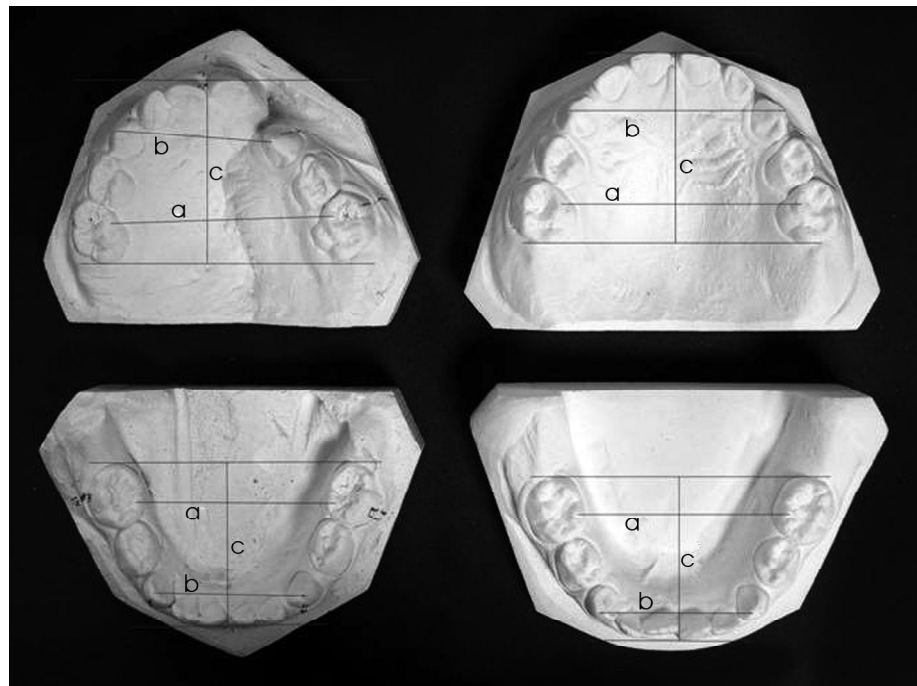


Fig. 1. Dimensions of dental arch to anatomical points by Moorees (1969): a – inter molar distance; b – inter-canine distance; c – palatal length

- 45 models of UCLP operated (lip and palate surgery) patients with early orthodontic treatment before lip plastic (UCLP-2);
- 45 models of noncleft children as a control group.

There were included 90 UCLP cases, from them: 56 male (with affected left side 41 (73%) and 15 (27%) with affected right side) and 34 female (21 female (67%) had affected left side, 10 female (33%) had affected right side).

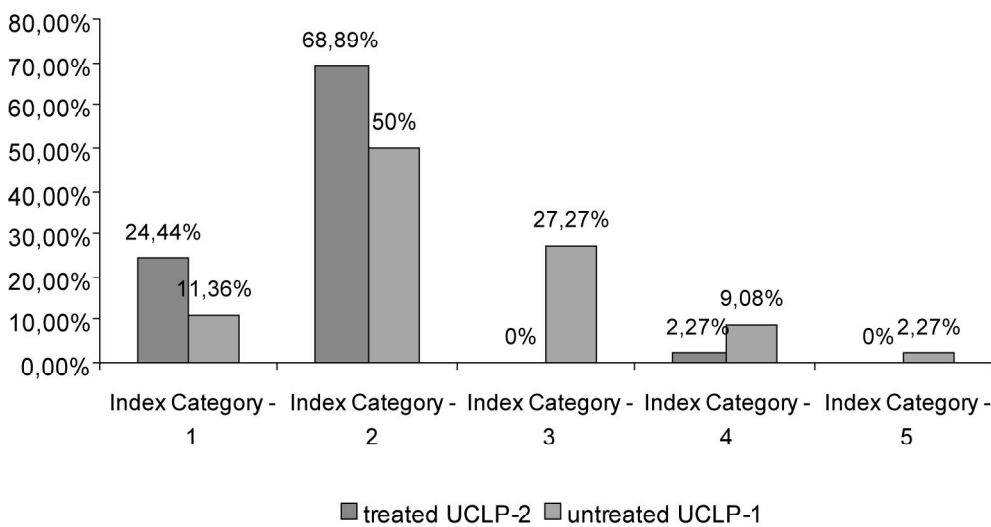
No one child from the control group had received orthodontic treatment before.

In Riga Cleft Center, lip plastics perform at 3-6 months of age, in Vilnius at 3 months of age. In Riga Cleft Center, palate is operated in two stages or in one stage in special cases and in one stage in Vilnius.

Table 1. Features of Models in the 5-Year-Old's Index

Index Category	General features	Predicted Long - Term Outcome
1	Positive overjet with average inclined or retroinclined incisors no crossbites or openbites	Excellent
2	Positive overjet with average inclined or proinclined incisors unilateral crossbite (crossbite tendency ± open bite tendency around cleft site)	Good
3	Edge to edge bite with average inclined or proinclined incisors, or reverse overjet with retroinclined incisors unilateral crossbite ± open bite tendency around cleft site	Fair
4	Reverse overjet with average inclined or proinclined incisors unilateral crossbite ± bilateral crossbite tendency ± open bite tendency around cleft site	Poor
5	Reverse overjet with proinclined incisors Bilateral crossbite Poor maxillary arch form and palatal vault anatomy	Very poor

5-Year-Old's Index



	Index Category-1	Index Category-2	Index Category-3	Index Category-4	Index Category-5
Treated UCLP-2	24,44% (11 cases)	68,89% (31 case)	0%	2,27% (1 case)	0%
Untreated UCLP-1	11,36% (5 cases)	50% (22 cases)	27,27% (12 cases)	9,08% (4 cases)	2,27% (1 case)

Fig. 2. Comparison of results of 5-Year-Old's Index in children with UCLP treated with early orthodontics or untreated

Early orthodontic treatment was performed from the first days after the birth until lip plastic

more correct and nearer to the noncleft children occlusion. More cases of UCLP-2 showed positive

surgery. Hotz appliance was used for early orthodontic treatment. Functional appliance during treatment is grinded to manage the growth of affected maxillae.

Measurements of dental arch length, canine arch width and molar arch width were taken similar to Bland and Altman method, were used points of Moores (Figure 1).

Dental arch relationships and surgical outcome on the study models was assessed using 5-year-olds index (Table 1).

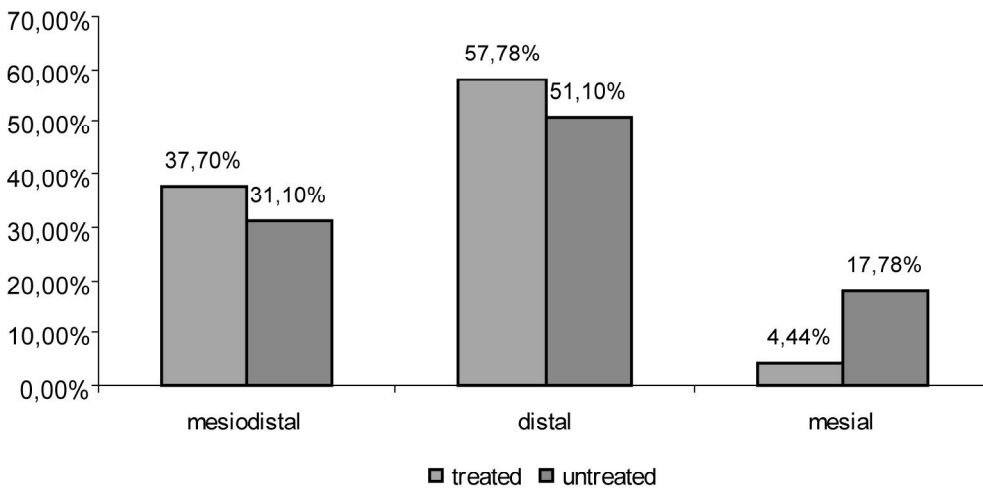
RESULTS

UCLP-2 rating was better, the occlusion was better, the occlusion was more correct and nearer to the noncleft children occlusion. More cases of UCLP-2 showed positive

Table 2. Comparison of maxillary and mandible dimensions of children with UCLP-1, UCLP-2, and control group

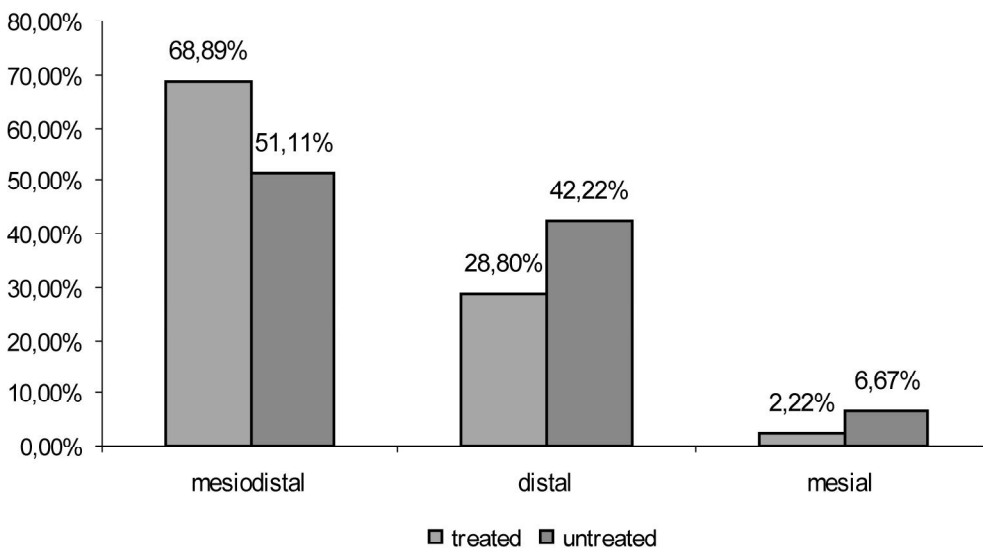
	UCLP-1		Control		p value for difference
	Mean	SD	Mean	SD	
Maxillary anterior posterior dimension	28.9	2.96	24.5	3.61	<0.0001
Mandibular anterior posterior dimension	26.3	2.47	22.2	3.72	<0.0001
Distance between maxillary molars	34.1	4.49	38.0	3.00	<0.0001
Distance between mandibular molars	31.6	3.50	33.4	2.89	0.003
Distance between maxillary canines	27.1	2.84	30.0	1.83	<0.0001
Distance between mandibular canines	24.7	2.78	24.0	1.66	0.21
	UCLP-2		Control		p value for difference
	Mean	SD	Mean	SD	
Maxillary anterior posterior dimension	26.4	1.96	24.5	3.61	0.0019
Mandibular anterior posterior dimension	24.4	1.50	22.2	3.72	<0.0001
Distance between maxillary molars	39.2	3.23	38.0	3.00	0.1
Distance between mandibular molars	35.1	2.52	33.4	2.89	0.003
Distance between maxillary canines	27.4	2.73	30.0	1.83	<0.0001
Distance between mandibular canines	23.5	2.25	24.0	1.66	0.17
	UCLP-1		UCLP-2		p value for difference
	Mean	SD	Mean	SD	
Maxillary anterior posterior dimension	28.9	2.96	26.4	1.96	<0.0001
Mandibular anterior posterior dimension	26.3	2.47	24.4	1.50	<0.0001
Distance between maxillary molars	34.1	4.49	39.2	3.23	<0.0001
Distance between mandibular molars	31.6	3.50	35.1	2.52	0.003
Distance between maxillary canines	27.1	2.84	27.4	2.73	NS
Distance between mandibular canines	24.7	2.78	23.5	2.25	0.028

Cleft side



	1st class	2nd class	3rd class
Treated	37,7% (17 cases)	57,78% (26 cases)	4,44% (2 cases)
Untreated	31,1% (14 cases)	51,1% (23 cases)	17,78% (8 cases)

Intact side



	1st class	2nd class	3rd class
Treated	68,89% (31 cases)	28,8% (13 cases)	2,22% (1 case)
Untreated	51,11% (23 cases)	42,22% (19 cases)	6,67% (3 cases)

Fig. 3. Comparison of deciduous molar occlusion

overjet without posterior serious crossbite (Figure 2).

Our measurements showed, the group UCLP-2, is more alike to noncleft child's maxillae. UCLP-2 group comparing with UCLP-1 group has better posterior palatal width between deciduous molars (Table 2). Both groups – UCLP-1 and UCLP-2 had diminished palate anterior width, comparing

with control group (Figure 3).

Distal molar occlusion was more frequent on the cleft side in both UCLP groups, but the medial occlusion is more frequently seen in UCLP-1 group (without early orthodontic treatment).

DISCUSSION

Multidisciplinary treatment of cleft lip and palate rehabilitation is impossible to replace. As surgery is the main necessary treatment in cleft patients, it must be as delicate as possible; therefore, maxilla has to be prepared in advance. Orthodontic treatment must be planned to support craniofacial growth and prevent maxillary arch deficiency (18).

In spite of congenital deficiency and surgical intervention, maxilla can grow within acceptable dimensions. Early orthodontics is a first step to normalize the most important functions – breathing, feeding, and growing. It is the guidance of separated segments of maxillary alveolus into semblance of arch configuration (13; 18; 19).

Koželj interpreted importance of nasal breathing for growth and development of oral cavity. The early orthodontic appliance prior to lip repair enables the part of nasal septum, which at birth forms part of the oral cavity roof. During early orthodontic treatment considerably improves the shape of alar base (anterior deformation of the septum and the columella). Reforming the nasal cavity allows cleft repair without subsequent mouth

breathing, and oral cavity remains in proper position (9).

Primary nasal repair is protective against poor outcome of maxillary development (14, 15).

Correct position of oral and nasal cavities is foundation for development of musculature that improves maxillae bone growth and could be explanation of our results, where maxilla and mandible anteroposterior dimension in group UCLP-2 was nearer control group comparing with UCLP-1 group. Patients with early orthodontics had mainly distal molar relations at the cleft side, and mesiodistal molar relations at the intact side. In comparison – patients without early orthodontics had more mesial molar occlusion cases at the cleft side. That approves early orthodontics favorable effect on maxillae segments before lip plastic surgery. Children with unilateral cleft lip and palate without early orthodontic treatment (UCLP-1) showed narrower maxillae between deciduous molars comparing with UCLP-2 group. This observation suggest that Hotz appliance principally plays a role in preventing lateral deviation of the segments due to outward forces exerted by the orbicularis oris muscle (16).

Occlusion and surgical results were evaluated with 5-year olds index. This index is used to assess treatment outcome in 5-year age. Congenital deficiency is the main reason and even after successful treatment, dental occlusion will be different comparing to noncleft children occlusion (20). Positive overjet could be as a factor of prediction for more favorably sagittal jaw relations, between position of mandible and the configuration of the facial profile.

The majority of patients was founded to be in

category 2. UCLP-2 group had no patients in category 5 and less in category 4, that verify early orthodontics positive investment in surgical outcome too (Figure 2).

Patients with unilateral cleft lip and palate usually have deviation in affected side. The purpose of early orthodontic treatment, was to get forward movement of the cleft maxillary bone, if possible with a forward outward rotation the affected segment, and a forward medial rotation of the non-cleft maxillary bone. That may be explained as a result of primary difference in sagittal position of two segments of the maxilla or as positive result of early orthodontic treatment, when one of the main tasks is stimulation the forward growth of cleft segment. It could be accepted, that stimulation of bone growth during early orthodontics predicts better possibility for eruption of deciduous teeth beside the cleft (4).

We did not find significant difference in deciduous molar distal relationship between UCLP-1 and UCLP-2 groups but mesial molar relationship was more frequent in UCLP-1 group which had no early orthodontics treatment (Figure 3).

CONCLUSIONS

1. In cases treated by early orthodontics there is a higher probability of achieving favorable deciduous occlusal relationships than in cases treated by purely surgical intervention.

2. Infant orthodontic does not prevent collapse in maxillae, but is a method to improve maxillary arch form.

Early orthodontics is beneficial for deciduous tooth relationship.

REFERENCES

- Bongaarts CA, Kuijpers-Jagtman AM, van 't Hof MA, Prah Andersen B. The effect of infant orthopedics on the occlusion of the deciduous dentition in children with complete unilateral cleft lip and palate (Dutchcleft). *Cleft Palate Craniofac J* 2004;41:633-41.
- Nollet PJ, Katsaros C, Van't Hof MA, Kuijpers-Jagtman AM. Treatment outcome in unilateral cleft lip and palate evaluated with the GOSLON Yardstick: a meta-analysis of 1236 patients with unilateral cleft lip and palate. *Cleft Palate Craniofac J* 2005;116:1255-62.
- Winters JC, Hurwitz DJ. Presurgical orthopedics in the surgical management of unilateral cleft lip and palate. *Plast Reconstr Surg* 1995;95:755-64.
- Koop H, Grabowski R. Presurgical orthopedic treatment of newborns with clefts: functional treatment with long-term effect [Poster]. In: 6th International Orthodontic Congress. Paris; 2005.
- Lisson JA, Schilke R, Tränkman J. Transverse changes after surgical closure of complete cleft lip, alveolus and palate. *Clin Oral Investig* 1999;3:18-24.
- Hibatulla A, Grabowski R. Results after early orthopedic treatment of newborns. In: Joint 3rd Congress of Baltic Orthodontic Association and 4th Congress of Baltic Association for Maxillofacial and Plastic Surgery. Riga; 2002.
- Jacobson BN, Rosenstein SW. Early maxillary orthopedics for the newborn cleft lip and palate patient. An impression and an appliance. *Angle Orthod* 1984;54:247-63.
- Rosenstein SW, Jacobson BN. Early maxillary orthopedics: a sequence of events. *Cleft Palate Craniofac J* 1967;4:197-220.
- Kozelj V. The basis for presurgical orthopedic treatment of infants with unilateral complete cleft lip and palate. *Cleft Palate Craniofac J* 2000; 37:26-32.
- Friede H, Katsaros C. Current knowledge in cleft lip and palate treatment from an orthodontist's point of view. *J Orofac Orthop* 1998;59:313-30.
- Kozelj V. Changes produced by presurgical orthopedic treatment before the lipoplasty in Cleft lip and palate patients. *Cleft Palate-Craniofacial J* 1999; 36:515-21.
- Natsume N. Early orthodontic therapy of cleft lip and/or palate patients. *Plast Reconstr Surg* 1998;102:269.
- Jacobson BN, Rosenstein SW. Early maxillary orthopedics for the newborn cleft lip and palate patient. An Impression and an appliance. *Angle Orthod* 1984;54:247-63.

14. Williams AC, Sandy JR. Risk factors for poor dental arch relationships in young children born with unilateral cleft lip and palate. *Plast Reconstr Surg* 2003;111:586-93.
15. Santiago PE, Grayson BH, Cutting CB, Gianoutsos MP, Brecht LE, Kwon SM. Reduced need for alveolar bone grafting by presurgical orthopedics and primary gingivo-periosteoplasty. *Cleft Palate Craniofac J* 1998;35:77-80.
16. Mishima K, Mori Y, Sugahara T, Minami K, Sakuda M. Comparison between palatal configurations in UCLP infants with and without a hotz palate until four years of age. *Cleft Palate Craniofac J* 2000;37:185-90.
17. Clark SA, Atack NE, Ewings P, Hathorn IS, Mercer NS. Early surgical outcome in 5-year-old patients with repaired unilateral cleft lip and palate *Cleft Palate Craniofac J* 2007;44:235-8.
18. Grabowski R, Kopp H, Stahl F, Gundlach KK. Presurgical orthopaedic treatment of newborns with clefts—functional treatment with long-term effects. *J Craniomaxillofac Surg* 2006;34 Suppl 2:34-44.
19. Chan KT, Hayes C, Shusterman S, Mulliken JB, Will LA. The effects of active infant orthopaedics on occlusal relationships in unilateral complete cleft lip and palate. *Cleft Palate Craniofac J* 2003;40:511-7.
20. Suzuki A, Yoshizaki K, Honda Y, Sasaguri M, Kubota Y, Nakamura N, et al. Retrospective evaluation of treatment outcome in Japanese children with complete unilateral cleft lip and palate. Part 1: five-year-olds' index for dental arch relationships *Cleft Palate Craniofac J* 2007;44:434-43.

Received: 20 08 2007

Accepted for publishing: 28 09 2007