

Descemet Membrane Endothelial Keratoplasty in Pseudophakic Bullous Keratopathy: Outcomes and Evidence-Based Suggestions

Davide Borroni^{1,3}, Melanie Ferronato², Ineta Orube¹, Renars Erts³, Svetlana Sepetiene¹, Eva Drucka¹, Zita Krumina⁴

¹ Department of Ophthalmology, Riga Stradins University, Riga, Latvia

² Faculty of Medicine, Riga Stradins University, Riga, Latvia

³ Department of Physics, Riga Stradins University, Riga, Latvia

⁴ Department of Genetics, Riga Stradins University, Riga, Latvia

Received: 03 May 2017; Accepted: 18 Dec. 2017

Abstract- The purpose of the study was to determine clinical outcomes of Descemet Membrane Endothelial Keratoplasty (DMEK) in patients with Pseudophakic Bullous Keratopathy (PBK). The study was conducted at a tertiary referral center. This was a retrospective case series. Pseudophakic eyes having undergone DMEK surgery for Pseudophakic Bullous Keratopathy was considered the object of study. The examination implied the analysis of best corrected visual acuity (BCVA or CDVA), endothelial cell density (ECD), intraocular pressure (IOP), intraoperative and postoperative complications and a follow-up in 1, 3, and 6 months. For the purposes of the study, 25 pseudophakic eyes with PBK were examined. One month after the surgery patients reached a BCVA of 0.49 ± 0.08 (M \pm SD), after 3 months - BCVA of 0.65 ± 0.12 (M \pm SD), and a BCVA of 0.78 ± 0.17 (M \pm SD) in the last follow-up in 6 months after the surgery ($P < 0.001$). The mean ECD after one month was 1661 ± 133 (M \pm SD) cells/mm², after 3 months - 1591 ± 124 (M \pm SD) cells/mm² and during the last control in 6 months - 1579 ± 128 (M \pm SD) cells/mm². The graft detachment rate was 12% (3 cases). Hypertension was observed in one eye (4%), necessitating partial air elimination through a corneal wound within the first hours after the surgery. DMEK may give excellent visual results in Pseudophakic eyes without increasing the risk of complications when compared to Descemet Stripping Automated Endothelial Keratoplasty (DSAEK) and Penetrating Keratoplasty (PKP). Anatomic repair after DMEK is associated with improved corneal clarity and BCVA.

© 2018 Tehran University of Medical Sciences. All rights reserved.

Acta Med Iran 2018;56(3):170-175.

Keywords: DMEK; Descemet membrane endothelial keratoplasty; DSAEK; Descemet stripping automated endothelial keratoplasty; PKP; Penetrating keratoplasty; PBK; Pseudophakic bullous keratopathy; Cornea; Cataract

Introduction

The endothelial layer of the cornea maintains corneal clarity and its deturgescence state. By maintaining an optimal level of corneal hydration, the endothelial cells preserve the necessary arrangement of collagen crucial for corneal transparency (1). When endothelial cell density is low, the loss of tight junctions between the cells allows more fluid to enter the stroma. In Fuchs dystrophy, the total amount of endothelial cells is low, and the existing cells may not function properly. Descemet's membrane thickens and develops excrescences that, in histopathological context, are

known as guttae. As stromal edema develops, the corneal thickness may increase to over 1,000 μ m. Usually, the average human corneal endothelial cell density is 5,000-6,000 cells/mm² at birth, decreasing to 2,500-3,000 cells/mm² until adulthood. The average cell loss is 0.6% per year (2). Corneal edema appears at 700-400 cells/mm² (2,3). When edema is severe, the corneal epithelium can detach from its basement membrane, creating painful bullae on the anterior surface of the cornea (1,4). In Pseudophakic Bullous Keratopathy (PBK), the endothelial cell loss is caused by surgery in anterior chamber area (5). Endothelial injury primarily results from a rapid focal distortion of the cellular layer,

Corresponding Author: D. Borroni

Department of Ophthalmology, Riga Stradins University, Riga, Latvia

Tel: +37 127 456241, Fax: +37 127 456241, E-mail address: info.borroni@gmail.com

similar to endothelial trauma caused by high fluid turbulence during cataract surgery. The free radical formation is another important, harmful factor. Ultrasound in aqueous solution induces cavitation. It results in the formation of hydroxyl free radicals that cause damage to corneal endothelium (6). If the corneal endothelium is damaged, the same spectrum of symptoms as in Fuchs dystrophy might develop (3). These injuries are seen as “snail-track” lesions or serpentine gray lines on the endothelium (7). Among corneal diseases, bullous keratopathy (BKP) is the major cause of the loss of eyesight (8). The incidence of bullous keratopathy is 1-2% in various parts of the world (9,10,11). Symptomatic patients are usually treated with topical hypertonic saline, mild topical steroids, and bandage contact lens till a surgical solution is planned. Penetrating keratoplasty (PK) is no longer considered the primary solution—nowadays it is more common to perform Descemet Membrane Endothelial Keratoplasty (DMEK) for patients with endothelial dysfunction only (5,12). This selective approach has several advantages over PK and Descemet Stripping Automated Endothelial Keratoplasty (DSAEK): rapid visual rehabilitation, less surgically induced astigmatism, less incidence of graft rejection, and preservation of biomechanical properties. However, the surgery is technically more complex than PK and DSAEK; it implies a longer surgeon’s learning curve and higher possibility of donor tissue damage. Also, there is a greater possibility of a postoperative graft detachment (13,14).

Currently, 89% of the patients with Fuchs’ endothelial dystrophy and 55% of the subjects with post-cataract corneal edema are treated with endothelial keratoplasty (15). The present study is aimed at evaluating the clinical outcomes after DMEK in Pseudophakic Bullous Keratopathy eyes in the period of time of 6 months after surgery.

Materials and Methods

This retrospective study comprised consecutive patients with bullous keratopathy undergoing DMEK surgery from January 2016 to March 2017 included in “DMEK-PBK” project of Riga Stradins University in collaboration with the Department of Genetic of Children Hospital, Riga, Latvia. Patients having experienced Vitreo-Retinal surgery, post-trabeculectomy, previous corneal surgeries, uveitis, Wet Macular Degeneration, birth injury and endotheliitis were not included in the study. The study was performed in accordance with the Declaration of Helsinki and

approved by the Institutional Ethics Review Board of Riga Stradins University (acceptance n. E-9(2) decision n.29/29.09.2016).

Donor preparation

Healthy donor corneas with a cell count of >2500 cells/mm² were used for the transplantations. Stripping of the endothelial Descemet membrane from the donor corneal stroma was performed just before transplantation. The donor preparation was expected to be done the day before the surgery, but it was not possible to arrange it. The donor corneoscleral rim was placed on a sterile circular surface, then scored and stained with trypan blue to highlight the scoring mark. Next, it was placed in a corneal viewing chamber containing corneal storage solution (Culture Medium I; Biochrom AG, Berlin, Germany). A circular incision with a hockey knife was made. A complete dissection of the DMEK tissue from the corneoscleral rim was achieved by grasping the peripheral free tissue flap with untoothed curvilinear forceps. A spatula was used to lift the trephinated graft off the stromal bed after complete dissection and trephination. The DM was placed in culture medium just before the surgery. During the surgery, the culture medium was carefully drained, and the DMEK roll was thoroughly rinsed with BSS. To open the tissue and create a double roll, a direct flow on the top of the tissue with BSS was applied. The tissue was stained with trypan blue.

Surgical technique

Surgeries were performed the patients being under retrobulbar anesthesia (16). A 5.0 mm tunnel incision was made in the limbus, entering the anterior chamber approximately 3.0 mm within the clear cornea. With an inverted Sinsky hook (D.O.R.C. International BV) a circular portion of Descemet membrane was scored and stripped from the posterior stroma so that an 8-9.0 mm diameter descemetorhexis was created; the central portion of Descemet membrane was removed from the eye. The size of the DMEK graft was determined, and the donor graft was trephinated using a Hessburg-Barron trephine. The donor Descemet roll was stained with a 0.06% trypan blue solution (Vision Blue, D.O.R.C. International BV) and aspirated into a purpose-designed injector (D.O.R.C International BV) to transfer the tissue from the culture medium to the anterior chamber. (17) The donor tissue roll was inserted into the anterior chamber by using the injector. The incision was sutured with 10-0 Nylon. The graft was positioned with the endothelial side downwards (donor Descemet membrane

Descemet membrane endothelial keratoplasty

facing recipient posterior stroma) by careful no-touch manipulation of the tissue with fluid from the interior and 2 canulae from outside. Iridectomy was performed in all cases. The rolling time was recorded. As the anterior chamber was maintained with fluid and air, the graft was spread gently over the iris. To facilitate the deroll of the donor tissue, the anterior chamber was decreased to facilitate the adhesion of the layer. After the creation of a 3-folded position, an air bubble was injected underneath the donor tissue to position it onto the recipient posterior stroma. The anterior chamber was completely filled with air, and the patient was positioned supine for 60 minutes (16). Patients were prescribed topical eyedrops levofloxacin and betamethasone 0.1%.

Patient assessment

Routine examinations, including slit lamp and fundus evaluation, corrected distance visual acuity (CDVA), subjective spherical equivalent (SE), subjective astigmatism, and ECD, were performed preoperatively and postoperatively after 1, 3 and 6 months. Visual acuity was measured using the standard Snellen chart. Also, CDVA was recorded. The ECD was measured using a specular microscopy system (SP-3000P, Topcon Corp.). At least 50 cells were analyzed for mean cell density calculations.

Postoperative care

Patients were re-evaluated an hour after the surgery, having laid in a supine positioning for one hour to ensure optimal graft placement. All patients were treated for one week with topical fluoroquinolone (Vigamox, Alcon, Fort Worth, TX, USA) drops in addition to a one month course of 1% prednisolone acetate (Allergan, Irvine, CA, USA) four times a day. After one month, the prednisolone was tapered one a month for a few months. In some cases, steroid-induced hypertension necessitated substitution of prednisolone acetate with fluorometholone (Allergan, Irvine, CA, USA) or loteprednol etabonate (Bausch and Lomb, Rochester, NY, USA).

Statistical methods

The data is presented in the form of means (Ms) and the standard deviations (SDs). Three groups were compared to ANOVA. All of the calculated probability values were 2-tailed, and $P < 0.05$ was chosen to indicate statistically significant differences. Statistical analyses were performed using IBM SPSS, version 23.0.

Results

A total of 25 DMEK were performed on eyes suffering from PBK. Preoperative visual criteria for the patients to undergo DMEK were visual acuity less than 0.1 or visual acuity > 0.1 with irritable eye in the form of pain, lacrimation or blepharospasm.

The average age of donors was 59.7 ± 6.8 y ($M \pm SD$), and the mean cellular endothelial count of the tissue was 2710 ± 102 cells/mm² ($M \pm SD$). The level of success was assessed by the percentage of the graft remaining clear after a follow-up period of 6 months. All graft remained clear till the last follow-up. One month after the surgery patients reached a CDVA of 0.49 ± 0.08 ($M \pm SD$), after 3 months a CDVA of 0.65 ± 0.12 ($M \pm SD$) and a CDVA of 0.78 ± 0.17 ($M \pm SD$) in the last follow-up after 6 months ($P < 0.001$) (Figure 1).

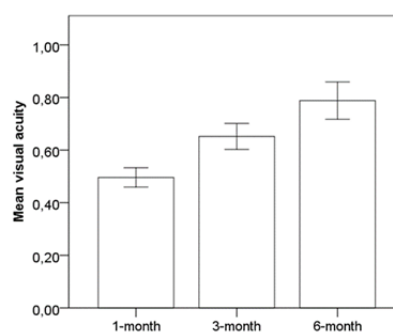


Figure 1. Improving of mean visual acuity during the first 3 follow-ups (up to 6 months)

The mean ECD after one month was 1661 ± 133 ($M \pm SD$) cells/mm², after 3 months- 1591 ± 124 ($M \pm SD$) cells/mm² and after 6 months- 1579 ± 128 ($M \pm SD$) cells/mm² (Figure2).

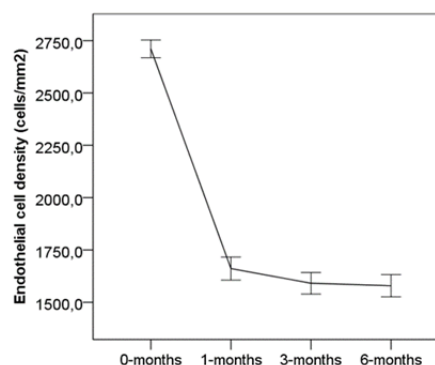


Figure 2. 6-month endothelial cells loss from baseline (0, donor cornea) among study participants undergoing DMEK

The mean endothelial cell loss percentage after 6 months was 41.74%. The graft detachment rate was 12% (3 cases). Hypertension was observed in one eye (4%) necessitating partial air elimination through a corneal wound within the first hours after the surgery. No complications, such as vitreous loss or choroidal effusion/ hemorrhage occurred intraoperatively. One patient had transient small cysts of Central Macula

Edema (CME) that resolved after 8 days. Later on, the follow-up was regular (Table 2). The relationship between Endothelial Cells loss and visual improvement over the first 6 months showed no strict correlations (Figure 3). The relationship between Endothelial Cell density loss over 6 months and the axial length of the eyes showed a statistically significant higher reduction of cells in shorter eyes.

Table 1. Biometric parameters of patients

Parameters		
Age (M±SD)		72.9±7.1 y
Sex	Male	8 (32%)
	Female	17 (68%)
Pre-surgery IOP (M±SD)		16.1±2.5 mmHg
6 months Post-surgery IOP (M±SD)		17.1±2.3 mmHg
BCVA before surgery (M±SD)		0.18±0.08
AL (M±SD)		23.72±1.00 mm
Edothelial cells density	0 (M±SD) Donor Tissues	2710±102 cells/mm ²
	1 (M±SD)	1661±133 cells/mm ²
	3 (M±SD)	1591±124 cells/mm ²
	6 (M±SD)	1579±128 cells/mm ²
	P	<0,001
Post-Surgery BCVA	1month (M±SD)	0.49±0.08
	3 (M±SD)	0.65±0.12
	6 (M±SD)	0.78±0.17
	P	<0,001

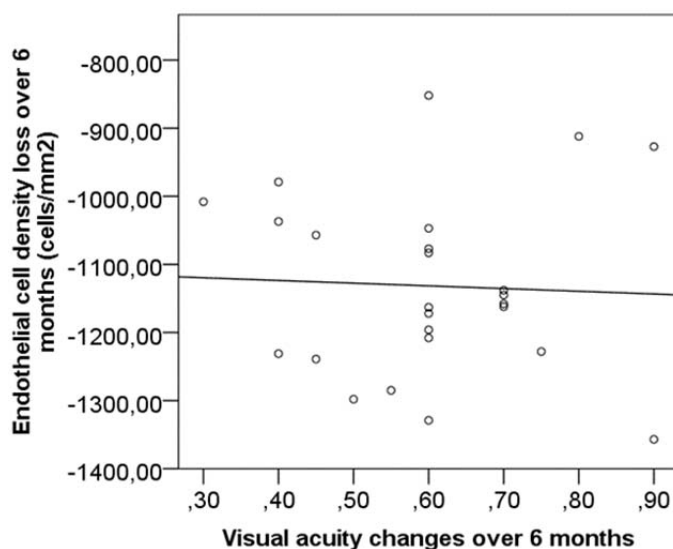


Figure 3. Six-month visual acuity improvement from baseline on decimal scale among study participants undergoing DMEK in relation to endothelial cells density loss

Table 2. Complications rate

Type of Complications	Percentage (%)
Re-bubble	3 (12%)
CME	1 (4%)
IOP spike	1 (4%)
Graft rejection	0(0%)

Discussion

This study shows the feasibility and positive outcomes of DMEK in PBK. However, the current study has limitations that must be acknowledged. First, the surgery was planned and performed by a single surgeon (DB), potentially introducing selection bias. Second, patients with bullous keratopathy resulting from birth injury, bullous keratopathy after trabeculectomy, or with the previous PKP from having DMEK were excluded as another potential source of bias.

The improvement of the mean visual acuity during the first 3 follow-ups from 0.49 ± 0.08 (M \pm SD) to 0.78 ± 0.17 (M \pm SD) (Figure 1) was considered to be a successful surgical outcome.

In comparison to DSAEK, the recovery of BCVA is faster and with greater patient satisfaction in DMEK. The reduction of 41, 74% of the cells over a 6-month follow-up is in linear with other studies present in the literature (Figure2) (18,19,20), as it shows a higher loss of cells during the first months and stabilizing over the time.

Figure 3 helps to enucleate a concept derived from evidence noticed during our clinical experience over the years: is not merely the number of cells that contribute to the clarity of cornea, but the function of residual cells present.

Figure 3 leads towards a hypothesis that improvements and changes in visual acuity are not directly linked to the reduction of cells. There is no direct or logarithmical correlation. The evidence also suggests that the final improvements in vision are not linked to the vision before the surgery, suggesting that the replacement of endothelium with a new donor tissue in a cloudy cornea will give anatomical and optical replacement of previous functions even if an advanced decompensation is present. Next, the clinical consultations and statistical data portrayed in Figure 3 show that the clarity and function of the cornea, referred by the patient with the subjective refraction of BSCVA (Best Subjective Corrected Visual Acuity), is not strictly linked to the number of endothelium cells. It supports the idea that, in order to maintain the corneal stroma dry,

the function of every single cell present in the layer is more important than the number of cells.

A greater reduction of endothelial cells after 6 months was found in shorter eyes (<24, 0 mm) respectively to the one in eyes >24, 0 mm. This is probably due to a smaller anterior chamber in shorter eyes that belongs to more surgical time (even if the Anterior Chamber became deeper after cataract surgery) or possible alteration when lowering the anterior chamber to facilitate the de-rolling of the donor tissue.

The low complication rates (Table 2), usually manageable in the perioperative time as IOP spikes (4%) or in the next days as re-bubbling (12%) and CME (4%), make DMEK the first choice for Endothelial Keratoplasties.

DMEK is a safe solution for restoring vision in PBK eyes. It should be the first choice to choose in order to give excellent visual outcomes without an increased risk of complications compared to DSAEK and PKP. Over the low rate of complications, an accurate post-surgical follow-up can avoid long-term complications. Evidence-based suggestions will guide future studies towards lamellar surgeries, development of stem cells therapies for corneal disorders, and towards the study of the stability of the corneal endothelium. Future therapies may replace corneal transplantation as the treatment of choice for patients with endothelial cell diseases.

References

1. Kumar V, editor. Robbins and cotran: Pathological basis of disease. 7th ed. Philadelphia: Saunders, 2005.
2. Edelhauser HF. The balance between corneal transparency and edema the proctor lecture. Invest Ophthalmol Vis Sci 2006;47:1755-67.
3. Bourne RR, Minassian DC, Dart JK, Rosen P, Kaushal S, Wingate N. Effect of cataract surgery on the corneal endothelium: Modern phacoemulsification compared with extracapsular cataract surgery. Ophthalmology 2004;111:679-85.
4. Borboli S, Colby K. Mechanisms of disease: Fuchs' endothelial dystrophy. Ophthalmol Clin North Am 2002;15:17-25.

5. Fernandez MM, Afshari NA. Endothelial Keratoplasty: From DLEK to DMEK. *Middle East Afr J Ophthalmol* 2010;17:5-8.
6. Takahashi H. Corneal Endothelium and Phacoemulsification. *Cornea* 2016;35:S3-7.
7. Derek W. DelMonte, MD, Terry Kim, MD. Anatomy and physiology of the cornea. *J Cataract Refract Surg* 2011;37:588-98.
8. Shimazaki J, Amano S, Uno T, Maeda N, Yokoi N, Japan Bullous Keratopathy Study Group. National survey on bullous keratopathy in Japan. *Cornea* 2007; 26:274-8.
9. Goncalves ED, Campos M, Paris F, Gomes JA, Farias CC. Bullous keratopathy: etiopathogenesis and treatment. *Arq Bras Oftalmol* 2008;71:61-4.
10. Gomes JA, Haraguchi DK, Zambrano DU, Izquierdo Junior L, Cunha MC, de Freitas D. Anterior stromal puncture in the treatment of bullous keratopathy: six-month follow-up. *Cornea* 2001;20:570-2.
11. Uchino Y, Goto E, Takano Y, Dogru M, Shinozaki N, Shimmura S, et al. Long-standing bullous keratopathy is associated with peripheral conjunctivalization and limbal deficiency. *Ophthalmology* 2006;113:1098-101.
12. Spaniol K, Holtmann C, Schwinde JH, Deffaa S, Guthoff R, Geerling G. Descemet-membrane endothelial keratoplasty in patients with retinal comorbidity-a prospective cohort study. *Int J Ophthalmol* 2016;9:390-4.
13. Patel SV. Graft survival and endothelial outcomes in the new era of endothelial keratoplasty. *Exp Eye Res* 2012;95:40-7.
14. Tourtas T, Laaser K, Bachmann BO, Cursiefen C, Kruse FE. Descemet membrane endothelial keratoplasty versus descemet stripping automated endothelial keratoplasty. *Am J Ophthalmol* 2012;153:1082-90.
15. 2012 Eye Banking Statistical Report. Eye Bank Association of America. (Accessed January 2018, 18, at http://restoresight.org/wp-content/uploads/2013/04/2012_Statistical_Report_FINAL-reduced-size-4-10.pdf).
16. Dapena I, Moutsouris K, Droutsas K, Ham L, van Dijk K, Melles GR. Standardized “no-touch” technique for Descemet membrane endothelial keratoplasty. *Arch Ophthalmol* 2011;129:88-94.
17. Parker J, Dirisamer M, Naveiras M, Tse WH, van Dijk K, Frank LE, et al. Outcomes of Descemet membrane endothelial keratoplasty in phakic eyes. *J Cataract Refract Surg* 2012;38:871-7.
18. Phillips PM, Phillips LJ, Muthappan V, Maloney CM, Carver CN. Experienced DSAEK Surgeon's Transition to DMEK: Outcomes Comparing the Last 100 DSAEK Surgeries With the First 100 DMEK Surgeries Exclusively Using Previously Published Techniques. *Cornea* 2017;36:275-9.
19. Aravena C, Yu F, Deng SX. Outcomes of Descemet Membrane Endothelial Keratoplasty in Patients With Previous Glaucoma Surgery. *Cornea* 2017;36:284-9.
20. Ang M, Mehta JS, Newman SD, Han SB, Chai J, Tan D. Descemet Membrane Endothelial Keratoplasty: Preliminary Results of a Donor Insertion Pull-through Technique Using a Donor Mat Device. *Am J Ophthalmol* 2016;171:27-34.