

Radiological Evaluation of Endodontic Treatment of Chronic Apical Periodontitis using Biphasic Calcium Phosphate Biomaterial

Madina A. Kurmanalina ^{1*}, Raisa M. Uraz ¹, Andrejs Skagers ², Janis Locs ³, Aliya A. Taganiyazova ¹, Azamat E. Omargali ¹

¹ West Kazakhstan Marat Ospanov State Medical University, Aktobe, Maresyev Str., 68, KAZAKHSTAN

² Riga Stradina University, Riga, Dzirciema Iela 20, LATVIA

³ Riga Technical University, Riga, Paula Valdena Street 3/7, LATVIA

Received 23 June 2018 • Revised 19 August 2018 • Accepted 8 September 2018

ABSTRACT

The article is dedicated to the study of the efficacy of the periapical therapy of chronic periodontitis with the use of synthetic calcium-phosphate biomaterial. 30 patients aged from 22 to 56 years participated in a clinical study. Radiological evaluation was performed by radiovisigraphy and radiodensitometry. Follow-up examination was carried out at 3, 6 and 12 months. Densitometry indicators at the destruction site showed an increase in radiodensity from 74.2 ± 9.9 units (58.2%) to 111.9 ± 10.6 units (87.8%) after 12 months. Anterior group of teeth demonstrated statistically significant high rate of lesion compaction compared to posterior teeth.

Keywords: apical periodontitis, endodontic treatment, synthetic biomaterials, biphasic calcium phosphate, radiodensitometric assessment

INTRODUCTION

Apical periodontitis (AP) is an inflammatory lesion around the apex of a tooth root as a result of release of microbes and their toxins into the periapical area. Formation of a pathological focus at the apex of the root is a kind of barrier and immunological host reaction against further spread of microbes [1].

According to Iordanishvili AK et al. chronic AP is the cause of teeth extraction in 7.2% of cases and with the exacerbation of chronic AP teeth are removed in 24.9% of cases [2]. To reduce the number of removed teeth and to increase the efficacy of conservative treatment of AP, it is necessary to develop medications that promote the regeneration of periapical bone tissue. These vehicles should be injected into the lesion in orthograde way through the root canal, without any traumatic surgical intervention.

A number of studies prove the effectiveness of osteoplastic bone grafts (biomaterials) as allogenic, xenogenic, and synthetic origin which have been extensively used in human and animal studies. Bone grafts fill the defect of bone tissue by inserting into the lesion through the root canal. Satisfactory results were shown in the treatment of periapical bone defects [3-6].

Synthetic biomaterials based on biphasic calcium phosphate (BCP) bioceramics appeared in the market relatively recent. They are used in sinus lifting operations, in implantology, and in bone fractures and osteomyelitis repair [7-9]. Being biocompatible and sterile, they are completely devoid of antigenic properties, as well as threats of infection of the patient with dangerous infectious diseases.

Thus, the purpose of this study is to evaluate the use of BCP biomaterial in the regenerative treatment of chronic apical periodontitis.

Table 1. Teeth groups distribution

	Incisors	Canines	Premolars	Molars	Total
Maxilla	8	2	3	3	16
Mandible	4	2	3	5	14
Total no. of teeth	12	4	6	8	30

MATERIALS AND METHODS

BCP biomaterial consists of bioceramic granules of hydroxyapatite calcium (HAp) and β -tricalcium phosphate (β -TCP) with a ratio of HAp / β -TCP 80/20. Biomaterial is produced in Rudolfs Cimdins Riga Biomaterials Innovations and Development Centre of Riga Technical University. Synthesis of calcium phosphate powder is carried out by aqueous precipitation technique between the suspension of calcium hydroxide $\text{Ca}(\text{OH})_2$ and the solution of phosphoric acid H_3PO_4 . The resulting powder is mixed with glycerol (purity > 99.8%, LLC BIO-VENTA, Latvia), distilled water and ammonium bicarbonate NH_4HCO_3 (Ltg. Enola, ES/BASF). Then material is treated at a temperature of 1150°C for 2 hours. Obtained granular biomaterial is ground to a microgranular state [10].

The porosity of the biomaterial is 200 μ , which creates favorable conditions for the germination and formation of young bone tissue, as well as the development of blood vessels, i.e. angiogenesis. The particle size is 0.1-0.3 mm, which allows the biomaterial to freely penetrate through the apical foramina into the pathological bone lesion.

22 to 56 years old 30 patients between 2016 and 2017 first came to the Dental Clinic of West Kazakhstan Marat Ospanov State Medical University participated in the study. Patients with periodontal disease, systemic pathology, lesion size more than 5 mm, third molars, as well as teeth underwent apical surgery were excluded from the study. Approval from Ethical Committee of West Kazakhstan Marat Ospanov State Medical University (protocol No. 12 dated 29.09.2016) and written informed consent of participation in the study were obtained from every patient. The study was conducted according to the Declaration of Helsinki.

Among included teeth 12 were incisors, 4 - canines, 6 - premolars and 8 - molar teeth. Maxillary teeth were - 16, mandibular - 14 teeth (**Table 1**).

Out of the 30 teeth, 8 were previously treated with caries lesion, 13 teeth were endodontically treated, 9 teeth were not treated.

To reveal the presence of fistula or scars and the periapical pathology an extraoral and intraoral examination, evaluation of teeth condition was carried out. Dental formula and data of radiovisiography (RVG) were recorded in patient's medical history. The periapical bone density before treatment and during the assigned follow-up visits was measured by radiodensitometric assessment. This method is based on measurements of bone density in the concerned areas of the X-ray image. Radiodensitometry provides a quantitative assessment of visual changes in X-ray image and, therefore, allows monitoring of dynamic processes in periapical tissues.

RVG and radiodensitometry were performed on the CCX Digital Trophy (France). Normal indicators of the radiodensity of bone tissue were based on studies by Kogina E.N. [11], according to which the radiodensity of bone tissue in anterior group of teeth on average is 132.5 ± 4.6 , and in posterior group - 121.5 ± 4.2 conventional units (CE) [11].

The first visit included anesthesia, preparation of carious cavity and endodontic access, determination of the length of root canals, chemomechanical preparation. Root canals were temporarily filled with antiseptic paste "Abscess Remedy" (PD, Switzerland) for 7-14 days. Teeth with AP exacerbation features BCP microgranules after the acute inflammatory reaction resolution were applied in 14-20 days.

In the second visit, an antiseptic paste was removed. The microgranules of hydroxyapatite (Hap) / β -tricalcium phosphate (TCP) ratio of 80/20 mixed with physiological solution until the pasty state were inserted by plugger over the apical foramina in to the periapical lesion on average amount 30-50 mcg. Root canals were filled with AH Plus (Dentsply) and gutta-percha (Diadent Group International) using cold lateral compaction technique. The final restoration was accomplished.

The control radiological examination was carried out immediately after the application of the biomaterial, 3, 6 and 12 months later.

Calculating of mean values $M \pm m$, where M is the average value of the exponent, m is the standard deviation were performed. In order to determine the significance of the differences in the coupled samples, a nonparametric criterion of signs was used. The significance level of the differences was set at a value of $p < 0.05$. STATISTICA, version 10, StatSoft, Inc (2011) software system was used for data analysis.

Table 2. Values of radiodensitometry according to RVG data before and after endodontic treatment (ET)

Teeth groups	Values of radiodensitometry							
	Before ET		After 3 months		After 6 months		After 12 months	
	CE	%	CE	%	CE	%	CE	%
Incisors	80.6±9.5	60.8	98.7±10.1	74.5	109.3±8.7	82.5	118.3±9.9	89.2
Canines	77.5±11.2	58.5	94.8±9.3	71.5	106.5±6.0	80.4	121.5±5.5	94.7
Premolars	64.6±4.9	53.2	87.2±3.3	71.7	95.3±3.1	78.5	104.2±3.8	85.7
Molars	70.1±4.5	57.7	89.3±4.2	73.5	95.4±4.2	78.5	103.4±5.8	85.1
Total	74.2±9.9	58.2	93.3±5.7	73.3	102.4±9.2	80.3	111.9±10.6	87.8

Table 3. Values of radiodensitometry of maxillary teeth (CE)

Teeth groups	Before ET	After 3 months	After 6 months	After 12 months
Incisors	78.9±10.5	98.3±12.2	109.4±10.3	117.1±11
Canines	87±2.7	102.5±3.5	108±1.4	122±4.2
Premolars	65.3±6.1	85±3.0	94.7±2.5	103.7±2.1
Molars	70.7±3.0	90.3±5.0	96.3±4.5	104±6.6

Table 4. Values of radiodensitometry of mandibular teeth (CE)

Teeth groups	Before ET	After 3 months	After 6 months	After 12 months
Incisors	84±7.2	99.5±5.2	109.3±5.6	120.5±8.3
Canines	68±2.8	87±2.8	105±9.9	121±8.5
Premolars	64±4.6	89.3±2.1	96±4.0	104.7±5.5
Molars	69.8±5.5	88.6±4.2	94.8±4.4	103±6.0

RESULTS

During 3, 6 and 12 months of observation patients were asymptomatic. Intraoral examination revealed the stability of permanent fillings, no sinus tract was detected, teeth percussion test was painless.

Average radiodensity of periapical bone structures was in the range of 74.2 ± 9.9 CE, which is 58.2% of normal values (Table 2).

After 3-month follow-up period values of radiodensitometry at the site of periapical bone loss showed an increase of bone density from the 74.2 ± 9.9 CE (58.2%) to 93.3 ± 5.7 CE (73.3%). At 6-month recall reduction in lesion size reached 102.4 ± 9.2 CE (80.3%), and by the of 12-month observation period radiolucent lesion was 111.9 ± 10.6 CE (87.8%) (Table 2).

Generally, at 12-month recall radiodensity of periapical lesion in incisors increased by 28.4%, in canines - 36.2%, in premolars - 21.1%, in molars - 27.4% ($p < 0.05$) (Table 2).

Percent analysis of radiodensitometric data revealed that posterior teeth had statistically significant slower rates of AP complete resolution comparing to the anterior teeth. Regarding approximately equal percentages before treatment among all groups of teeth, the incisors and canines reach 89.2% and 94.7% of the normal values of radiodensitometry at 12-month recall. Posterior teeth comparing the anterior ones bear greater physical load, therefore the volume of the lesions decreased in longer time period [4].

Overall the group of teeth canines had the highest tendency of radiodensity increasement in 12-month follow-up. Evidently, in mandible radiodensity showed positive dynamics from 68 ± 2.8 CE to 104.7 ± 5.5 CE, and in maxilla from 87 ± 2.7 CE to 122 ± 4.2 CE, i.e. by 40 % and 26.4%, respectively (Tables 3 and 4). Perhaps this fact was associated with a small number of canines - 2 teeth from each jaw. An increase of the number of observations can correct this trend.

According to RVG images before root canal treatment rarefied rounded shape bone loss located at the root apex was observed (Figures 1 and 6). Figures 2 and 7 show the extrusion of the BCP biomaterial at tooth apex and filling of bone lesion focus. Root canals are tightly obturated. The values of radiodensitometry show growth in density in the observed area.

The RVG images obtained after 3 and 6-month recall show an increase in mineral density, resorption of BCP biomaterial and replacement of radiolucent area with newly formed bone tissue (Figures 3, 4 and 8, 9). After 12 months follow-up repair of bone density in established periapical lesion (Figures 5 and 10).

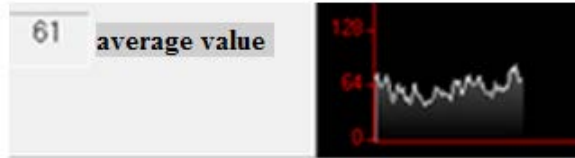
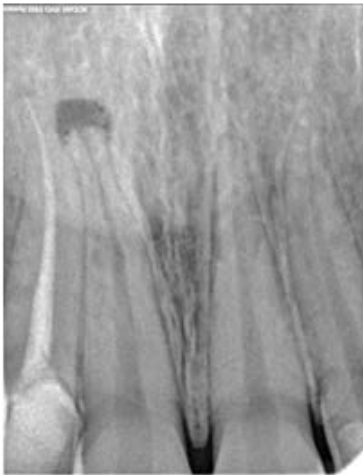


Figure 1. Patient K., 24 years old. Tooth 1.1 Before treatment

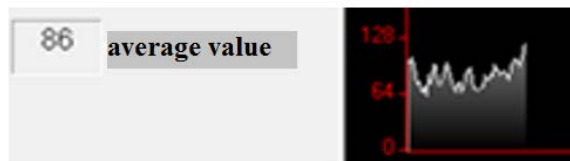
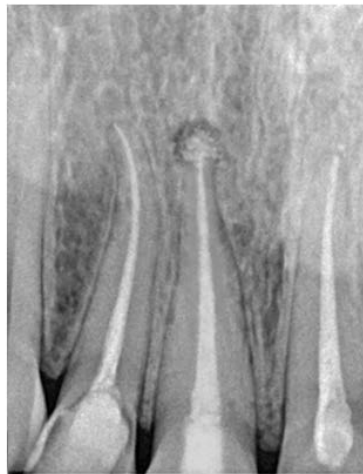
Figure 2. After root canal filling

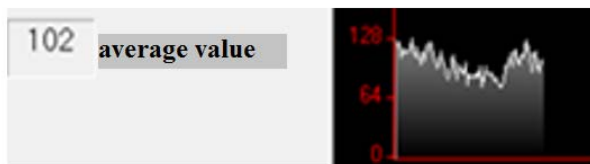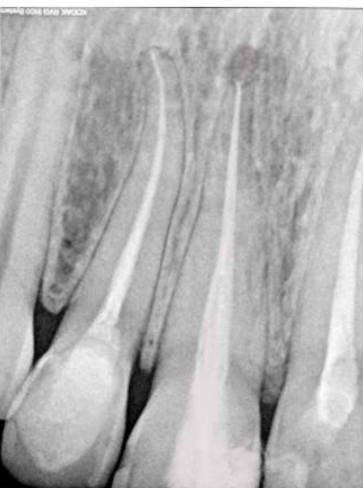


Figure 3. 3 months later

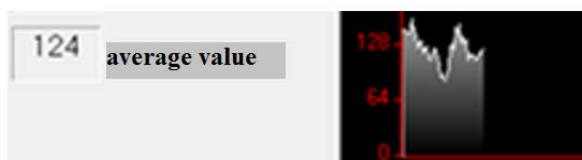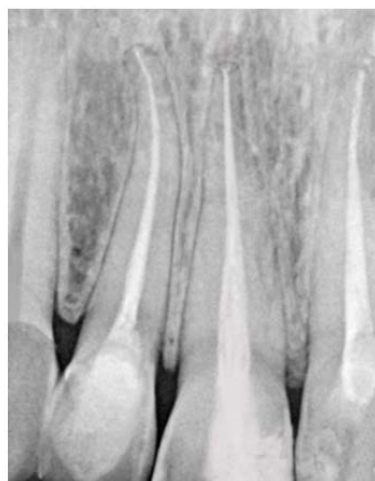


Figure 4. 6 months later

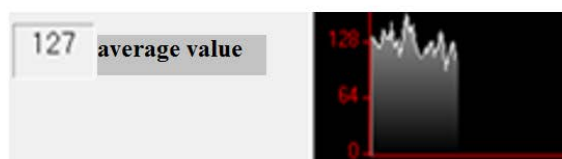
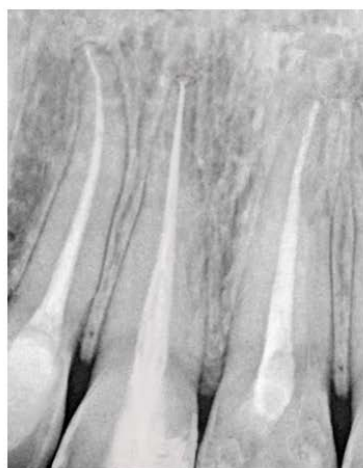
Figure 5. 12 months later

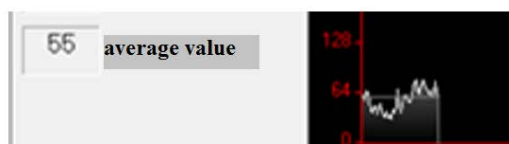
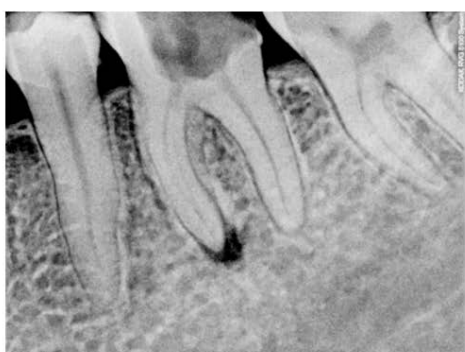
Figure 6. Patient T., 30 years old. Tooth 3.6. Before treatment

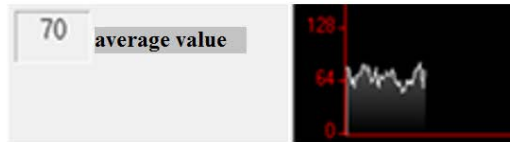
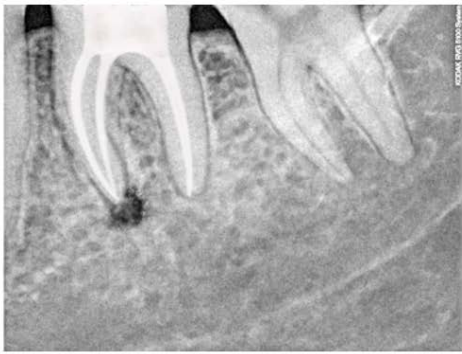
Figure 7. After root canal filling

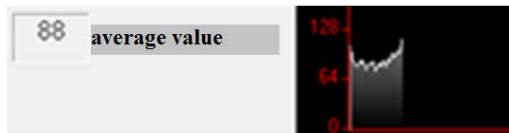
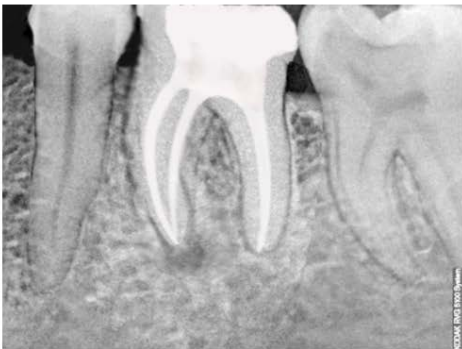
Figure 8. 3 months later

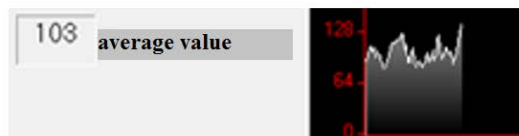
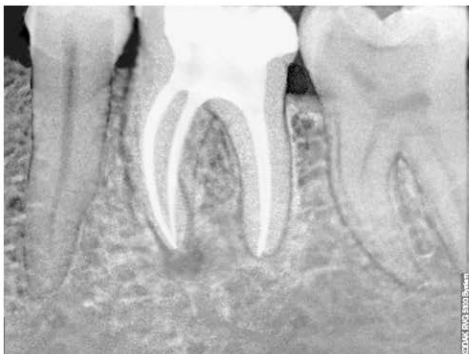
Figure 9. 6 months later

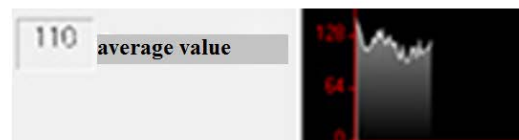
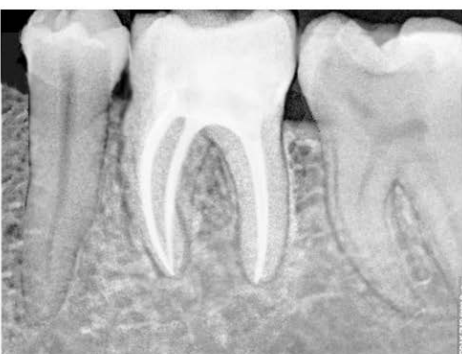
Figure 10. 12 months later

DISCUSSION

This study investigated the efficacy of biphasic calcium phosphate bioceramics in orthograde filling of periapical lesion. It is known that BCP bioceramics is utilized in dental implantology, maxillofacial reconstructive procedures, periodontology, orbital implants, traumatology and to repair various types of bone defects [7-8]. Several bone substitutes are proposed for filling periapical lesions. Application of graft materials in bone defects serves as scaffold and promotes osteoconduction, osteoblastic proliferation and bone formation.

Since there are no available human histological studies of healed periapical tissues obtained positive results are insufficient to explain possible mechanisms of regenerative processes in bone tissue. However, histological studies conducted on experimental animals indicate bone reparative abilities due to its molecular and cellular interaction with microporous surface of the calcium-phosphate biomaterial [12].

Numerous studies reveal the outcomes of calcium phosphate cements (CPC) in treatment of periapical bone lesions. The bone regenerative potency of CPC overfilled periapically was observed on maxillary incisors of monkeys. According to Hong et al. [10] microscopic evaluation after 6-month observation revealed ossification processes and new bone trabeculae formation around the implanted bioceramics. Still, at the beginning of the experiment insignificant inflammation was detected but authors considered it as mechanical trauma caused by placement of bioceramics.

There are few clinical observations evaluating synthetic biomaterial in orthograde endodontic treatment of periapical bone loss by placing BCP bioceramics. Studies of Gusiyska et al. [6] included 7 patients with periapical radiolucency. The author observed periapical healing within 12 months. Although this study was conducted in small number of patient positive outcomes were obtained. In concordance with our results apparent tendency towards more favorable outcome in single rooted teeth was observed.

In recent years, calcium hydroxyapatite and porous nickel titanium based bioactive bone-plastic materials were introduced. It is thought that pores create favorable conditions for optimizing the regeneration and mineralization of bone tissue. According to Gizatullin [13] nanostructured gel of hydroxyapatite and porous nickel titanium promotes reconstruction of periapical bone destructions. Study obtained positive outcomes in bone remodeling within 90-100 days. Degradation of the material in the periapical lesion goes in parallel with the process of bone tissue remodeling which is equal to the period of remodeling of a healthy bone.

CONCLUSIONS

This study was performed using RVG, the density of the newly formed bone was measured by radiodensitometry. BCP biomaterial showed good radiological results. Studies have shown that periapical bone loss up to 5 mm is susceptible to non-surgical reparative treatment. According to radiodensitometry after 12-month follow-up BCP biomaterial actively affected on the processes of mineralization and healing of apical periodontitis, showing positive dynamics of bone density increase by 29.6%. Reparative processes in the periapical lesion of the anterior group of teeth pass more intensively compared with the posterior group of teeth.

Our findings are promising for the future use of BCP bioceramics in endodontic treatment of periapical lesion. However, further clinical studies are necessary to assess the healing rates of the bone structures.

REFERENCES

1. Torabinejad M and Walton RE. Periradicular lesions. *Endodontics*. 1994;4:183.
2. Iordanishvili AK, Slugina AG, Lapina NV, Serikov AA. The causes of tooth loss in adults of different age groups. *Kuban scientific medical bulletin*. 2015;4(153).
3. Sorokin AP. *Diagnostics and complex treatment of chronic destructive forms of infectious periodontitis: dis.* Ufa: AP Sorokin. 2014.
4. Tairov VV, Melekhov SV. Efficiency of the combined therapy of destructive forms of the periodontitis. *Endodontia today*. 2011;2:33-39.
5. Khudyakova ES. *Optimization of the treatment of chronic forms of periodontitis with the use of osteoplastic materials. Samara: Author's abstract. dis cand. honey. Sciences.* 2009.
6. Gusiyska A, Dyulgerova E. Remodeling of periapical lesions scaffolding by biphasic calcium phosphate ceramics-a pilot study. *Journal of IMAB-Annual Proceeding (Scientific Papers) book*. 2009;2:113-118.
7. Grybauskas S, Locs J, Salma I, Salms G, Berzina-Cimdina L. Volumetric analysis of implanted biphasic calcium phosphate/collagen composite by three-dimensional cone beam computed tomography head model superimposition. *Journal of Cranio-Maxillofacial Surgery*. 2015;43(1):167-174. <https://doi.org/10.1016/j.jcms.2014.11.003>

8. Petronis S, Petronis J, Zalite V, Locs J, Skagers A, Pilmane M. New biphasic calcium phosphate in orthopedic surgery: first clinical results. In International Symposium on Biomedical Engineering and Medical Physics. Riga, Latvia. Springer, Berlin, Heidelberg. 2013:174-177.
9. Salms G, Skagers A, Zigurs G, Locs J, Berzina-Cimdina L, Feldmane L. Clinical, radiographic and pathohistological outcomes of hydroxyapatite (hap) ceramics and dental implants in atrophic posterior maxilla. *Acta Chirurgica Latviensis*. 2009;9(1):62-66. <https://doi.org/10.2478/v10163-010-0012-7>
10. Hong, Y. C., Wang, J. T., Hong, C. Y., Brown, W. E., & Chow, L. C. The periapical tissue reactions to a calcium phosphate cement in the teeth of monkeys. *Journal of biomedical materials research*, 1991;25(4):485-498. <https://doi.org/10.1002/jbm.820250406>
11. Kogina EN, Gerasimov LP, Kabirova MF and Saptarova LM. Application of the method of optical densitometry in the diagnosis of chronic apical periodontitis. *Health and education in the 21st century*. 201;618(11).
12. Wang L, Zhang B, Bao C, Habibovic P, Hu J, Zhang X. Ectopic osteoid and bone formation by three calcium-phosphate ceramics in rats, rabbits and dogs. *PloS one*. 2014;9(9):e107044. <https://doi.org/10.1371/journal.pone.0107044>
13. Gizatullin RM. The use of nano-gel of hydroxyapatite calcium and porous nickelite titanium for the treatment of destructive forms of chronic periodontitis. *Kazan Medical Journal*. 2009;90(3).

<http://www.eurasianjournals.com>