

Washington University School of Medicine

**Digital Commons@Becker**

---

Open Access Publications

---

2021

## **Cholecystitis masquerading as cardiac chest pain: A case report**

Vasudev Malik Daliparty

Behzad Amoozgar

Alejandra Razzeto

Syed Usman Mohsin Ehsanullah

Faseeha Rehman

Follow this and additional works at: [https://digitalcommons.wustl.edu/open\\_access\\_pubs](https://digitalcommons.wustl.edu/open_access_pubs)

---

Received: 2021.03.10


Accepted: 2021.06.21

Available online: 2021.08.11


Published: 2021.09.22

# Cholecystitis Masquerading as Cardiac Chest Pain: A Case Report

## Authors' Contribution:

Study Design A  
Data Collection B  
Statistical Analysis C  
Data Interpretation D  
Manuscript Preparation E  
Literature Search F  
Funds Collection GEFG 1 **Vasudev Malik Daliparty**  
EFG 1,2 **Behzad Amoozgar**  
EF 1 **Alejandra Razzeto**  
F 3 **Syed Usman Mohsin Ehsanullah**  
E 1 **Faseeha Rehman**1 Department of Internal Medicine, Jersey Shore University Medical Center, Perth Amboy Division, Perth Amboy, NJ, USA  
2 Department of Biostatistics and Epidemiology, School of Public Health, University of California, Berkeley, CA, USA  
3 Department of Internal Medicine, Washington University School of Medicine, St. Louis, MO, USA**Corresponding Author:** Behzad Amoozgar, e-mail: [behzad.amoozgar@berkeley.edu](mailto:behzad.amoozgar@berkeley.edu)  
**Financial support:** None declared  
**Conflict of interest:** None declared**Patient:** Male, 46-year-old  
**Final Diagnosis:** Cholecystitis  
**Symptoms:** Chest pain  
**Medication:** —  
**Clinical Procedure:** —  
**Specialty:** General and Internal Medicine**Objective:** Unusual clinical course**Background:** Cope's sign is the association of bradycardia with symptoms of acute cholecystitis, which can occur due to a vagal cardiobiliary reflex. The clinical and electrocardiographic changes of bradycardia or complete heart block can mimic the presentation of acute coronary syndrome. This report highlights the unique possibility that bradycardia in patients with abdominal pain and gallstones can be due to this reflex.**Case Report:** A 46-year-old obese man with hyperlipidemia and gallstones presented with chest pain suggestive of cardiac ischemia. The initial electrocardiography (EKG) was normal, although the patient subsequently developed bradycardia and a 2<sup>nd</sup>-degree atrioventricular (AV) block. The results of further cardiothoracic investigations (including echocardiography and pharmacologic stress testing) were normal. An ultrasound of the abdomen revealed acute cholecystitis. After he underwent a laparoscopic cholecystectomy, the chest pain resolved completely, and the EKG reverted to its normal sinus rhythm.**Conclusions:** Acute cholecystitis rarely presents with cardiac chest pain and EKG changes due to triggering of the vagal cardiobiliary reflex. Given this atypical presentation, patients often undergo invasive cardiac procedures in search of a nonexistent cardiac etiology coupled with the possibility of a missed diagnosis of cholecystitis. When clinicians consider a diagnosis of acute coronary syndrome in patients with bradycardia, T-wave inversion, and ST-segment elevation (especially in the inferior leads), they should add the possibility of intra-abdominal pathologies (including cholecystitis) in the differential diagnosis.**Keywords:** Acute Coronary Syndrome • Chest Pain • CholecystitisFull-text PDF: <https://www.amjcaserep.com/abstract/index/idArt/932078>

1566



3

16



## Background

Acute cholecystitis primarily presents with abdominal symptoms, including a colicky right upper quadrant and sometimes epigastric pain, nausea, vomiting, and fever [1]. It is rare that these are not the predominant manifesting symptoms. We present the case of a man with typical cardiac symptoms coupled with electrocardiographic (EKG) changes. Further investigations revealed the cause was of abdominal origin. This case report highlights the unique possibility that symptoms suggestive of cardiac ischemia in patients with abdominal pain and gallstones can be due to a cardiobiliary vagal reflex.

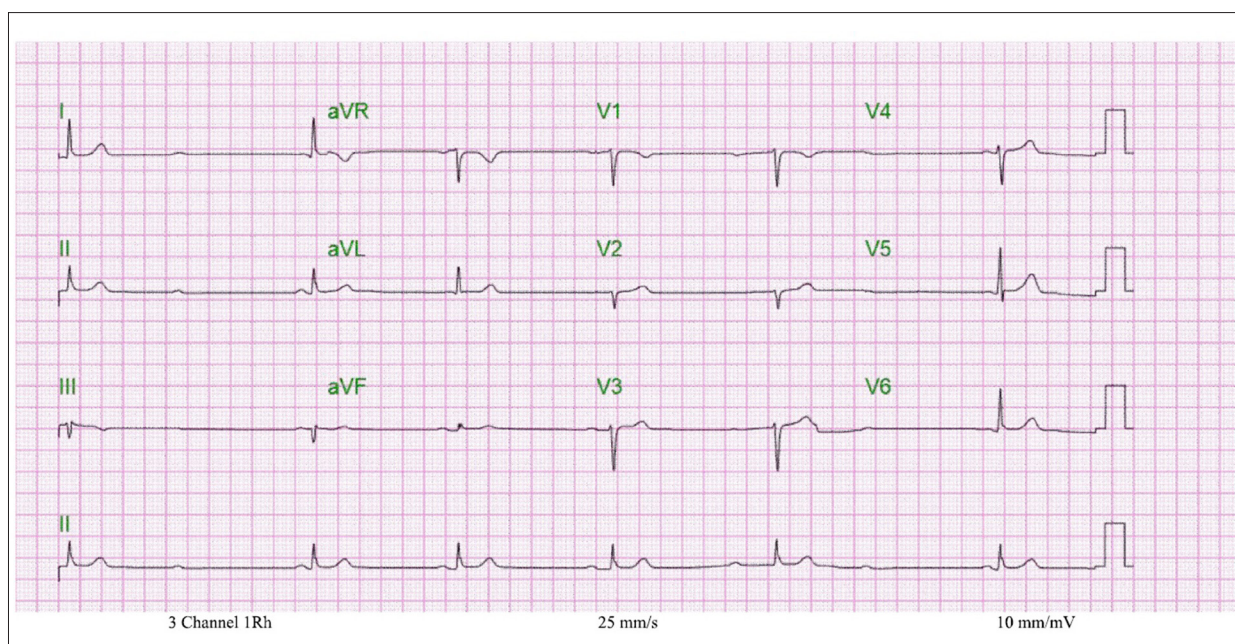
## Case Report

A 46-year-old obese man with a history of hyperlipidemia and gallstones, presented at the Emergency Department (ED) with chest pain. He reported pain that began 2 days prior to the ED presentation. He described the pain as retrosternal squeezing, which radiated to his back, and was associated with diaphoresis and nausea. At onset, the intensity of the pain was 4/10 on the severity scale and it gradually progressed to 9/10. There were no aggravating or relieving factors for the pain. He denied any other associated complaints. He was a current smoker with a 25 pack-year smoking history. He consumed alcohol socially and denied recreational drug use. There was no history of recent long-distance travel, contact with sick people, and no known exposure to COVID-19. His brother (aged 44 years) had died a sudden cardiac death. The patient had a documented history of allergic reactions to penicillin.

Upon presentation to our ED, the patient's initial vitals were blood pressure 111/83 mmHg, heart rate (HR) 63 beats/minute, body temperature 36.7°C, respiratory rate 14 cycles/minute, and oxygen saturation of 98% on room air with a calculated body mass index of 41.8 kg/m<sup>2</sup>. On physical examination, his mucous membranes were slightly dry, his neck was supple and there was no jugular venous distension. He had no significant pitting edema in the lower extremities, cyanosis, or clubbing. The cardiac examination showed tenderness to palpation, which was appreciable over the lower sternal area of the chest. On auscultation, distant heart sounds with a normal rate and regular rhythm were heard with no murmurs, gallop, or friction rub. An abdominal examination demonstrated minimal tenderness in the epigastric area and normal bowel sounds were appreciated. The respiratory system and neurological evaluation revealed normal findings.

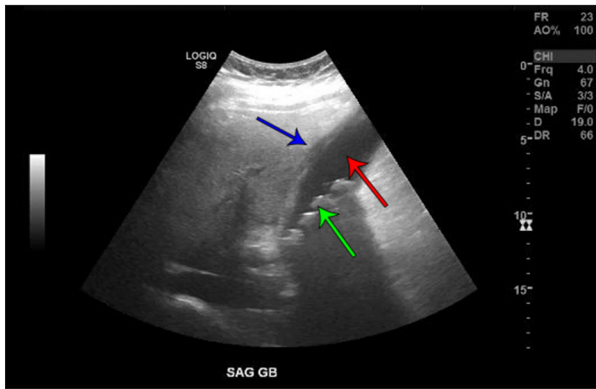
The initial EKG exhibited normal sinus rhythm with a rate of 60 beats/minute and no ST-T segment changes. Portable chest radiography did not demonstrate any evidence of cardio-pulmonary disease. The first test for troponin-I was normal (<30 ng/ml). Laboratory testing showed an elevated leukocyte count of 14.8×10<sup>3</sup>/μl (normal range, 3.6-11×10<sup>3</sup>/μl) with a high absolute neutrophil count of 9.2×10<sup>3</sup>/μl (normal range, 1.8-8×10<sup>3</sup>/μl), and hemoglobin was 14.3 g/dl (normal range, 11.6-16.8 g/dl). The serum electrolytes, and renal and liver function test results were normal.

The patient's chest pain was refractory to sublingual nitroglycerin administration. A single dose of 1 g intravenous (i.v.) acetaminophen followed by a single i.v. dose of 30 mg ketorolac



**Figure 1.** Electrocardiogram 2 hours after admission showed a Mobitz type I, 2<sup>nd</sup>-degree atrioventricular block.





**Figure 2.** Abdominal ultrasonography showed cholelithiasis (green arrow) in the gallbladder cavity (red arrow) with pericholecystic fluid and the gallbladder-wall thickening demonstrated acute cholecystitis (blue arrow) with no significant bile duct dilatation.

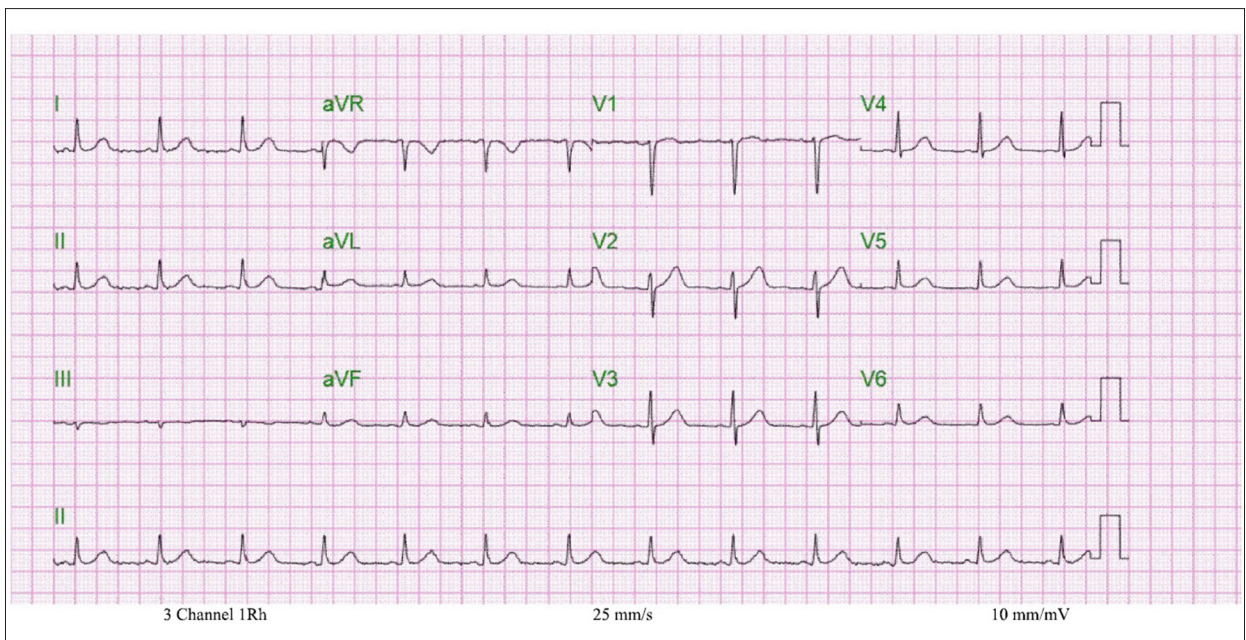
minimally alleviated his discomfort. A computed tomography angiography of the chest was performed to investigate the etiology of the pain; however, it showed no evidence of an aortic dissection or pulmonary embolus. Two hours after admission, the telemetry monitoring was suggestive of bradycardia with an HR varying from 36 beats/minute to 48 beats/minute. A subsequent EKG confirmed bradycardia with a Mobitz type I, 2<sup>nd</sup>-degree atrioventricular (AV) block (**Figure 1**). The 2<sup>nd</sup> set of serial troponin-I measurements taken and analyzed 3 hours after the first test, were negative. A cardiologic consultant assessed the patient and suggested that the probable etiology of the bradycardia was a vasovagal response secondary to the chest pain, as there was no evidence strongly suggesting

acute coronary syndrome (ACS) as a possible cause. An echocardiography performed as a further investigation was normal.

The next day, his chest pain had reduced to a tolerable intensity of 3/10, although he still reported chest heaviness. Therefore, a pharmacologic stress test was performed by infusing dipyridamole and the results were normal. No further cardiac interventions were initiated. As he had reported vague ongoing abdominal discomfort, a physical examination was performed. It revealed a new finding of tenderness in the right hypochondriac and epigastric regions and an abdominal ultrasonography was performed. This provided the diagnosis of cholelithiasis with pericholecystic fluid and gallbladder-wall thickening, raising the suspicion for acute cholecystitis with no significant bile duct dilatation (**Figure 2**). Due to the penicillin allergy, intravenous aztreonam and vancomycin were added to the treatment regimen. Upon the advice of a General Surgery consultant, the patient was scheduled for a laparoscopic cholecystectomy. The patient tolerated the procedure well and had no intra- or post-procedural complications. His chest pain and abdominal discomfort resolved completely after the surgery. An EKG prior to hospital discharge showed normal sinus rhythm with a heart rate of 76 beats/minute (**Figure 3**). He was discharged with a prescription for oral antibiotics (levofloxacin) and counseled on the importance of smoking cessation and weight loss. He was lost to follow-up; therefore, informed consent is not available for this case report.

## Discussion

Cholecystitis is an inflammation of the gallbladder, which occurs in patients with gallstone disease. Almost 10% of patients with



**Figure 3.** Electrocardiogram after the laparoscopic cholecystectomy showed normal sinus rhythm with a heart rate of 70 beats/minute.

symptomatic gallstones develop acute cholecystitis over the course of the disease [2]. The pathogenesis of this disease involves cystic duct obstruction with lysolecithin and prostaglandins triggering gallbladder irritation [3,4]. Patients with acute cholecystitis present with abdominal pain as the main symptom. The pain is often colicky and usually located in the right upper quadrant or epigastric region [4]. It characteristically radiates to the right shoulder or back and is typically preceded by a rich fatty meal. Nausea, vomiting, and fever are generally associated with the presentation [5]. Abdominal examination frequently reveals guarding with a positive Murphy's sign, which is the reproduction of pain on palpation of the gallbladder fossa, just beneath the liver edge, during deep inspiration [6].

However, in rare cases cholecystitis can present with an unusual variety of clinical manifestations. Acute cholecystitis can mimic cardiac symptoms, including chest pain and bradycardia. In some instances, it can exhibit EKG changes similar to those characteristic of ACS, including ST-segment elevation, right bundle branch block, and inversion of T waves [7]. The notion of reflex bradycardia or a cardiobiliary reflex in patients with acute cholecystitis was described for the first time by O'Reilly and Krauthamer and named Cope's sign [8-11]. The vagal nerve innervates the heart and gallbladder with spinal neurons at the T4 and T6 levels, respectively. It is hypothesized that in acute cholecystitis, the biliary inflammation leads to an increased autonomic vagal tone, which can result in a coronary vasospasm causing chest pain. Some researchers have scrutinized the presence of bradycardia in patients with acute cholecystitis. Franzen et al reported the case of a 48-year-old man who presented with cholecystitis and syncopal episodes due to an AV block. After a cholecystectomy, he showed complete resolution of the bradycardia and remained symptom-free during the 1-year follow-up after surgery [12].

In the present case report, the initial presentation and subsequent clinical course pointed toward a diagnosis of coronary artery disease as the most probable pathology. The detection of vague right upper quadrant pain culminated in the evaluation for possible intra-abdominal disease processes and led to the diagnosis of cholecystitis after performing an abdominal ultrasonography. Treatment with antibiotics and a laparoscopic cholecystectomy led to an improvement in the chest pain and bradycardia, thus sparing the patient from further cardiac studies, including cardiac catheterization. Some case reports have mentioned the resolution of symptoms without

surgery. Adequate pain control and prompt antibiotic usage are often sufficient to achieve symptom control [13].

Presentations in the form of ischemic EKG changes have been reported with the resolution of symptoms noted after management of the cholecystitis. Aksay et al presented the case of a 42-year-old man with acute cholecystitis who developed T-wave inversion in leads V3 to V5, where prompt treatment of the cholecystitis resulted in the resolution of the EKG changes [14]. Patel et al report the case of a morbidly obese young woman with significant ST elevation in multiple leads. In this case, thrombolysis was deferred after cholecystitis was diagnosed and the treatment of the cholecystitis remedied the EKG changes [15]. A larger study in Japan by Ozeki et al identified that out of the 16 patients diagnosed with ACS, 5 patients were subsequently diagnosed with acute cholecystitis [16]. It is imperative to diagnose ACS, as missing the diagnosis of acute cardiac ischemia can prove fatal. However, with the present case report, we emphasize the importance of considering other possible non-cardiac etiologies for a typical cardiac presentation.

## Conclusions

In rare instances, acute cholecystitis can present with cardiac chest pain and EKG changes due to possible cardiac ischemia as the cardiobiliary reflex or reflex bradycardia (Cope's sign) is triggered. When considering a possible diagnosis of ACS in patients with bradycardia, T-wave inversion, and ST-segment elevation (especially in the inferior leads), clinicians should always add the possibility of the presence of intra-abdominal pathologies (including cholecystitis) to the differential diagnosis. Bradycardia in patients with abdominal pain and gallstones can be due to a vagal cardiobiliary reflex.

## Department and Institution Where Work Was Done

Department of Internal Medicine, Jersey Shore University Medical Center, Perth Amboy Division, Perth Amboy, NJ, USA.

## Declaration of Figures Authenticity

All figures submitted have been created by the authors who confirm that the images are original with no duplication and have not been previously published in whole or in part.

## References:

1. Cho JY, Han HS, Yoon YS, Ahn KS. Risk factors for acute cholecystitis and a complicated clinical course in patients with symptomatic cholelithiasis. *Arch Surg.* 2010;145(4):329-33
2. Strasberg SM. Clinical practice. Acute calculous cholecystitis [published erratum appears in *N Engl J Med.* 2008;359(3): 325]. *N Engl J Med.* 2008;358(26):2804-11
3. Elwood DR. Cholecystitis. *Surg Clin North Am.* 2008;88(6): 1241-52,viii
4. Schuld J, Glanemann M. Acute cholecystitis. *Viszeralmedizin.* 2015;31(3):163-65
5. Katabathina VS, Zafar AM, Suri R. Clinical presentation, imaging, and management of acute cholecystitis. *Tech Vasc Interv Radiol.* 2015;18(4):256-65

6. Yeh DD, Chang Y, Tabrizi MB, et al. Derivation and validation of a practical Bedside Score for the diagnosis of cholecystitis. *Am J Emerg Med.* 2019;37(1):61-66
7. Demarchi MS, Regusci L, Fasolini F. Electrocardiographic changes and false-positive troponin I in a patient with acute cholecystitis. *Case Rep Gastroenterol.* 2012;6(2):410-14
8. O'Reilly MV, Krauthamer MJ. "Cope's sign" and reflex bradycardia in two patients with cholecystitis. *Br Med J.* 1971;2(5754):146
9. Krasna MJ, Flancbaum L. Electrocardiographic changes in cardiac patients with acute gallbladder disease. *Am Surg.* 1986;52(10):541-43
10. Papakonstantinou PE, Asimakopoulou NI, Kanoupakis E, et al. Cope's sign and complete heart block in a 78-year-old patient with biliary colic. *Int Emerg Nurs.* 2018;37:3-5
11. Lau YM, Hui WM, Lau CP. Asystole complicating acalculous cholecystitis, the "Cope's sign" revisited. *Int J Cardiol.* 2015;182:447-48
12. Franzen D, Jung S, Fatio R, Brunckhorst CB. Complete atrioventricular block in a patient with acute cholecystitis: A case of cardio-biliary reflex? *Eur J Emerg Med.* 2009;16(6):346-47
13. Nagappa M, Taly AB. Cholecysto-cardiac link: The heart of the matter. *Neurol India.* 2019;67(2):391-92
14. Aksay E, Ersel M, Kiyan S, et al. Acute coronary syndrome mimicked by acute cholecystitis. *Emerg Med Australas.* 2010;22(4):343-46
15. Patel N, Ariyathenam A, Davies W, Harris A. Acute cholecystitis leading to ischemic ECG changes in a patient with no underlying cardiac disease. *JSLs.* 2011;15(1):105-8
16. Ozeki M, Takeda Y, Morita H, et al. Acute cholecystitis mimicking or accompanying cardiovascular disease among Japanese patients hospitalized in a Cardiology Department. *BMC Res Notes.* 2015;8:805