



REVISTA ARGENTINA DE MICROBIOLOGÍA

www.elsevier.es/ram



BRIEF REPORT

Equine rhinosporidiosis in Buenos Aires, Argentina

Marco Antonio Tizzano^a, Romina Della Vedova^{a,*}, Ramón Andrés Lopez^d,
Verónica Amor^a, Candelaria Zubía^d, Susana Beatriz Córdoba^{a,c},
Francisco José Reynaldi^{a,b}

^a Cátedra de Micología, Facultad de Ciencias Veterinarias (UNLP), Buenos Aires, Argentina

^b CCT CONICET La Plata, Argentina

^c Instituto Nacional de Enfermedades Infecciosas Agudas-ANLIS "Dr. C. G. Malbrán", Ciudad Autónoma de Buenos Aires, Argentina

^d Cátedra de Medicina Equina, Facultad de Ciencias Veterinarias (UNLP), Buenos Aires, Argentina

Received 22 April 2020; accepted 31 December 2020

KEYWORDS

Wild horses;
Rhinosporidium
seeberi;
Argentina

Abstract Rhinosporidiosis is caused by *Rhinosporidium seeberi*, a parasitic organism of the family Rhinosporideacea family, class *Micomycozoa*. The disease is endemic in India; however, some cases were reported in Europe, Africa, North America, and South America. The aim of the present study is to report three cases of rhinosporidiosis in wild horses in different cities of Buenos Aires province, Argentina. We confirm the presence of *R. seeberi* in the analyzed samples using histopathological and PCR sequencing techniques.

© 2021 Asociación Argentina de Microbiología. Published by Elsevier España, S.L.U. This is an open access article under the CC BY-NC-ND license (<http://creativecommons.org/licenses/by-nc-nd/4.0/>).

PALABRAS CLAVE

Caballos silvestres;
Rhinosporidium
seeberi;
Argentina

Rhinosporidiosis en equinos de Buenos Aires, Argentina

Resumen La rhinosporidiosis es una enfermedad causada por *Rhinosporidium seeberi*, un organismo parasitario clasificado en la familia Rhinosporideacea, clase *Micomycozoa*. Es una enfermedad endémica de la India, pero se notificaron algunos casos en Europa, África, América del Norte y América del Sur. El objetivo del presente estudio fue describir tres casos de rhinosporidiosis en caballos de vida libre en diferentes ciudades de la provincia de Buenos Aires, Argentina. Confirmamos la presencia de *R. seeberi* en las muestras analizadas utilizando técnicas histopatológicas, PCR y secuenciación.

© 2021 Asociación Argentina de Microbiología. Publicado por Elsevier España, S.L.U. Este es un artículo Open Access bajo la licencia CC BY-NC-ND (<http://creativecommons.org/licenses/by-nc-nd/4.0/>).

* Corresponding author.

E-mail address: romidellavedova@gmail.com (R. Della Vedova).

<https://doi.org/10.1016/j.ram.2020.12.007>

0325-7541/© 2021 Asociación Argentina de Microbiología. Published by Elsevier España, S.L.U. This is an open access article under the CC BY-NC-ND license (<http://creativecommons.org/licenses/by-nc-nd/4.0/>).

Please cite this article in press as: M.A. Tizzano, R. Della Vedova, R.A. Lopez et al., Equine rhinosporidiosis in Buenos Aires, Argentina, Revista Argentina de Microbiología, <https://doi.org/10.1016/j.ram.2020.12.007>

Rhinosporidiosis is a disease caused by *Rhinosporidium seeberi*, a parasitic organism classified in the family Rhinosporideacea, class *Micromycetozoa*^{3,15}. It is an endemic disease in India; however, some cases have been reported in Europe, Africa, North America, and South America^{4,9-11}. Niño et al.¹² described an endemic area of rhinosporidiosis in the province of Chaco, northern Argentina, and reported 33 cases of equine rhinosporidiosis in 1964. *Rhinosporidium seeberi* infects mammals including humans, cats, dogs, horses, and cattle^{2-4,7,8,13}.

The natural reservoir of *R. seeberi* is lacustrine or stagnant water, in tropical and subtropical regions. In susceptible hosts, the lesions are frequently observed in nasal mucosae, partly because contaminated water is the source of infection^{7,11,14}.

Infected animals present clinical signs characterized by nasal secretion, sneezing, epistaxis, breathing noise¹, and occasionally, obstruction of the nasal cavity. Less frequently, the ocular conjunctiva can be affected causing epiphora. Taking into account that there is no drug treatment, surgical removal of the polypoid structures is the treatment of choice²; however, recurrence can occur⁴.

The microorganism does not grow in culture media, thus, the diagnosis is based on histopathological findings in tissues. The method used to identify the agent is based on the amplification of the small subunit rRNA gene sequence from infected tissue^{5,11}.

The aim of the present study is to describe three cases of rhinosporidiosis in wild horses in different cities of Buenos Aires province, Argentina identified by histopathology and PCR-sequencing trials.

For confirmation of the causal agent, the pedunculated masses of three horses were removed by surgical excision (Fig. 1A). The fractionated tissues were fixed in 10% buffered formalin for the histopathological studies. The remaining tissue was used in PCR trials. The fixed tissues were stained with periodic acid-Schiff (PAS) and spherules (sporangia) of variable size (100–300 μm) were observed. Sporangia had thin and weakly stained walls (Fig. 1B).

DNA was extracted from fresh biopsy samples (25 mg) by using a commercially available kit (DNeasy Tissue Kit, QIAGEN) according to the manufacturer's protocol. *R. seeberi* specific primers Rhino 2F (5'-TTTGTGTAGGGGTTCTCGC-3') and Rhino 2R (5'-GCAAAACCGTTGCTCCAAC-3') (7)

were used in a PCR. The *R. seeberi* specific amplification product from the 3 samples were sequenced by MacroGen (www.macrogen.com). The PCR amplified three specific fragments of 377 bp expected for *R. seeberi* (Suppl. Fig. 1). The amplification products were sequenced, showing 99% homology with *Rhinosporidium* spp. (ex *Canis familiaris*) (accession number AY372365.1). The program used to generate the phylogenetic tree was Geneious Version 2020.1 created by Biomatters (<http://www.geneious.com>) (Suppl. Fig. 2).

The three reported rhinosporidiosis cases in wild horses were from the following cities: Chascomús city located at geographical coordinates 35°34'30"S 58°00'32"O, Ensenada city at 34°51'S 57°54'O and La Plata city at 34°56'00"S 57°57'00"O (cities from Buenos Aires province, Argentina).

Two horses exhibited clinical signs of mild cough and rhinitis and the third one had epistaxis and nasal discharge. Therefore, the clinical examination was followed by a nasopharyngeal and laryngeal endoscopy, showing irregular pedunculated structures in shape and sizes (approximately 2.3 × 2.0 × 1.4 cm each). These pedunculated structures revealed the following:

- Isolate 1 (Chascomús) pedunculated masses in the larynx of a 15-year old mare.
- Isolate 2 (Ensenada) pedunculated masses in the larynx of a 10-year-old male horse.
- Isolate 3 (La Plata) pedunculated masses in the nose of a 4-year-old mare.

The polypoid structures were stained with PAS and microscopically observed. They consisted of a core of mature fibrovascular tissue superficially lined by a hyperplastic epithelium. Inside the granulated tissue and in the sub-mucosa, there were conspicuous spherules (sporangia) of variable size (100–300 μm in diameter) that showed a thin and weak wall.

The morphological features of the agent observed in all the cases presented here were characteristic, and could be presumptively identified as *R. seeberi* based on histopathological features. Nevertheless, a differential diagnosis with polypoid or granulomatous rhinitis caused by a fungal infection such as *Coccidioides immitis*, *Chrysosporium*

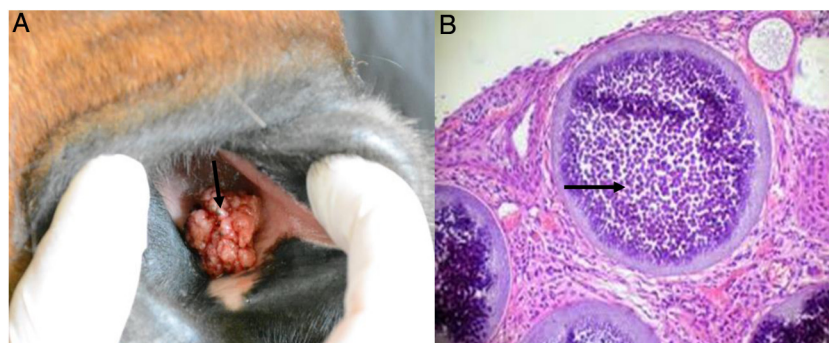


Figure 1 (A) Adult horse showing a multilobulated mass arising from the nasal mucosa (black arrow). (B) Thin section of nasal mucosa with mature sporangia (black arrow) and a myriad of endospores. Stained with PAS 100×.

parvum, *Cryptococcus neoformans*, *Conidiobolus coronatus*, and other causes, such as equine nasal amyloidosis and neoplasia^{2,6,8} is needed. For this reason, the use of a specific PCR reaction and sequencing could allow us to reach a precise diagnosis in a shorter time.

In our study, the three analyzed samples amplified a specific fragment of 377bp expected for *Rhinosporidium* spp. Moreover, the sequence analysis confirmed these findings.

In Argentina, the occurrence of rhinosporidiosis is uncommon, and is rarely suspected by clinical veterinarians, thus it is underestimated or misdiagnosed. Furthermore, if the pedunculated structures are located in anatomical sites other than in the nasal cavity or conjunctiva, the disease can be even harder to diagnose by the practitioners.

It should be remarked that since there is no specific medical treatment for rhinosporidiosis, it is very important to make a routine clinical diagnosis in wild horses, taking into account that the infected animals not only share the stagnant water and lacustrine environment but also the feeders and drinkers with the healthy animals. These clinical surveys could allow us to delimit the geographical areas with a high prevalence of rhinosporidiosis so that there could be a chance to relocate the breeder farms of polo horses or racehorses. Considering that Argentina is an exporter of highly competitive horses, the early diagnosis of this disease will contribute to its control, preventing its spread to other places.

Conflict of interest

The authors declare that they have no conflicts of interest.

Acknowledgements

This research was supported by resources from the Course of Medical Mycology, School of Veterinary Medicine, National University of La Plata, Argentina.

Appendix A. Supplementary data

Supplementary data associated with this article can be found, in the online version, at [doi:10.1016/j.ram.2020.12.007](https://doi.org/10.1016/j.ram.2020.12.007)

References

1. Bernardo FD, Pazinato FM, Fonseca Alves CE, La Cruz Bueno V, Franciscato C, Elias F. Equine nasal rhinosporidiosis in the Southern Rio Grande do Sul Brazil – case report. *Rev Bras Med Vet.* 2016;38:175–80.
2. Berrocal A, López A. Nasal rhinosporidiosis in a mule. *Can Vet J.* 2007;48:305–6.
3. Borteiro C, Etcheverze J, de León N, Nieto C, Arleo M, Martínez Debat C, Kolenc F, Ubilla M, Freire J, Dutra F. Rhinosporidiosis in a dog from Uruguay and review of the literature. *Braz J Vet Pathol.* 2018;11:92–6.
4. Burgess HJ, Lockerbie BP, Czerwinski S, Scott M. Equine laryngeal rhinosporidiosis in western Canada. *J Vet Diagn Invest.* 2012;24:777–80.
5. Fredricks DN, Jolley JA, Lepp PW, Kosek JC, Relman DA. *Rhinosporidium seeberi*: a human pathogen from a novel group of aquatic protistan parasites. *Emerg Infect Dis.* 2000;6:273–82.
6. Gardiner CH, Fayer R, Dubey JP. An atlas of protozoan parasites in animal tissues. 2nd ed. Washington, DC: Armed Forces Institute of Pathology, American Registry of Pathology; 1998. p. 78.
7. Janardhanan J, Patole S, Varghese L, Rupa V, Tirkey AJ, Varghese GM. Elusive treatment for human rhinosporidiosis. *Int J Infect Dis.* 2016;48:3–4.
8. Kennedy FA, Buggage RR, Ajello L. Rhinosporidiosis: a description of an unprecedented outbreak in captive swans (*Cygnus* spp.) and a proposal for revision of the ontogenetic nomenclature of *Rhinosporidium seeberi*. *J Med Vet Mycol.* 1995;33:157–65.
9. Krauss K, Bahamonde H, Karle M. Nasal rhinosporidiosis. New case report and review. *Rev Otorrinolaringol Cir Cabeza Cuello.* 2016;76:320–4.
10. Leeming G, Hetzel U, Campbell T, Kipar A. Equine rhinosporidiosis: an exotic disease in the UK. *Vet Rec.* 2007;160:552–4.
11. Leeming G, Smith KC, Bestbier ME, Barrelet A, Kipar A. Equine rhinosporidiosis in United Kingdom. *Emerg Infect Dis.* 2007;13:1377–9.
12. Niño FL, Freire RS. Existencia de un foco endémico de rhinosporidiosis en la provincia del Chaco. V. Estudio de nuevas observaciones y consideraciones. *Mycopathol Mycol Appl.* 1964;15:92–102.
13. Nollet H, Vercauteren G, Martens A, Vanschandevij K, Schaulvliege S, Gasthuys F, Ducatelle R, Deprez P. Laryngeal rhinosporidiosis in a Belgian warmblood horse. *Zoonoses Public Health.* 2008;55:274–8.
14. Peaty M. Equine rhinosporidiosis. *Vet Rec.* 2007;160:883.
15. Vilela R, Mendoza L. The taxonomy and phylogenetics of the human and animal pathogen *Rhinosporidium seeberi*: a critical review. *Rev Iberoam Micol.* 2012;29:185–99.