



Research article

Efficacy of topical risedronate and risedronate - Eudragit E complex in a model of cutaneous leishmaniasis induced by *Leishmania (Leishmania) amazonensis*



Ma. Florencia Peralta^{a,1}, Ma. Laura Guzman^{b,1}, Ma. Estefanía Bracamonte^c, J. Diego Marco^c,
Ma. Eugenia Olivera^b, Dolores C. Carrer^{a,*}, Paola A. Barroso^{c,**}

^a Instituto Ferreyra - INIMEC-CONICET – Universidad Nacional de Córdoba, Córdoba, Argentina

^b Unidad de Investigación y Desarrollo en Tecnología Farmacéutica – CONICET and Departamento de Ciencias Farmacéuticas, Facultad de Ciencias Químicas, Universidad Nacional de Córdoba, Córdoba, Argentina

^c Instituto de Patología Experimental – CONICET and Universidad Nacional de Salta, Salta, Argentina

ARTICLE INFO

Keywords:

Cutaneous leishmaniasis
Risedronate
Eudragit
Topical treatment
Leishmania amazonensis

ABSTRACT

An efficacious topical treatment for cutaneous leishmaniasis (CL) is highly desirable but still an ongoing challenge. Systemic risedronate (Ris) has been reported to have anti-leishmanial properties and Eudragit EPO (EuE) has shown *in vitro* activity against *L. (L.) amazonensis*. The aim of this work was to investigate the *in vivo* efficacy of topical Ris and EuE-Ris complexes on CL. Surface charge and Ris release kinetics from the different dispersions were analyzed. BALB/c mice were infected intradermally with promastigotes of *L. (L.) amazonensis*. Ulcers were treated with Ris or EuE-Ris hydrogels. All the lesions that received topical Ris or EuE-Ris showed an improvement with respect to control: reduction of ulcer average size, cicatrization, flattened edges and no signs of necrosis. In addition, a marked parasitic inhibition of 69.5 and 73.7% was observed in the groups treated with Ris and EuE-Ris, respectively, with the IgG2a levels indicating a tendency towards cure. The results are promising and the system should now be enhanced to achieve total parasite elimination.

1. Introduction

Leishmaniasis is, according to the World Health Organization, one of the most important tropical orphan diseases. This is due to inadequate treatments, especially in the case of rural populations [1]. The cutaneous form is the most prevalent, with an annual incidence of 1–1.5 million cases, and is endemic in 98 countries [2]. Its lesions are characterized by nodules, which sometimes progress to ulcers. Changes in the skin reflect the immune response to the infection, resulting in hyperplasia, epidermal thickening, and commonly a strong inflammation with destruction of the epidermis resulting in an ulcer [3].

The current first line pharmacotherapy involves the use of pentavalent antimonials, which have a high toxicity and significant side-effects, administered parentally or orally [4, 5]. A standard therapy involves daily intramuscular injections for 20–30 days, which is distressing and requires specialized professionals. An efficacious topical treatment would

improve patient compliance due to ease of use, diminished hurt, decreased side effects and the possibility of use in a rural context with low medical infrastructure. Depending on the size or number of the lesions, topical paromomycin ointment may be recommended, with several topical formulations of paromomycin having been developed for the treatment of CL with variable results [6, 7, 8]. Nevertheless, there is still no commercial formulation available.

Macrophage-like cells, or osteoclasts, are targets of bisphosphonate antiresorptive drugs, and it has been observed that risedronate (Ris) have considerable activity against leishmania parasites. The literature shows Ris anti-leishmanial efficacy *in vitro* in amastigotes strain of *L. (L.) donovani*, and low toxicity indices in macrophages [9]; efficacy was also demonstrated in promastigotes strain of *L. infantum* [10]. The *in vivo* efficacy of Ris was demonstrated in a visceral leishmaniasis (*L. (L.) donovani*) model of mice after its intra-peritoneal administration [11], with more than 85 % suppression of the amastigotes load in the liver,

* Corresponding author.

** Corresponding author.

E-mail addresses: dolorescarrer@immf.uncor.edu (D.C. Carrer), barrosopaola75@gmail.com (P.A. Barroso).

¹ These authors contributed equally to this article.

without apparent toxicity. *In vivo* efficacy of other bisphosphonates such as pamidronate after intra-peritoneal administration has also been described in a cutaneous leishmaniasis model (*L. mexicana amazonensis*), with the disappearance of the lesions and more than 99 % of the amastigotes at the site of the lesion [12]. However, Ris topical efficacy in cutaneous leishmaniasis (CL) has not yet been tested.

Eudragit EPO (EuE, a basic polyelectrolyte) has shown good *in vitro* activity in an *L. (L.) amazonensis* model with a high selectivity index [13]. *In vitro* studies have shown that the complexation of Ris with EuE gives rise to a new material, referred to as EuE-Ris, which has advantageous properties. These include high loading capacity and high affinity for the phosphonate groups of the drug, leading to a controlled Ris release [14]. This material has also shown a reduction in the topical irritation potential in a gastric model.

In the present study, our aim was to investigate the efficacy of topical administration of Ris and EuE-Ris complexes in an animal model of CL.

2. Materials and methods

2.1. Preparation of EuE-Ris and Ris hydrogels

A Ris (risedronate monosodium monohydrate, kindly provided by IVAX Argentina S.A.) aqueous solution was first prepared. Then, in order to facilitate its topical application, hydroxypropyl methylcellulose (HPMC, Parafarm®, Argentina) was added to the Ris solution, producing a hydrogel. A final concentration of 2 % HPMC and 20 mg/mL of Ris was obtained. This concentration was selected according to doses used in the literature for experimental leishmaniasis *i.p.* formulations [9, 11].

The EuE-Ris complex was prepared as previously described in Guzman *et al.* [14]. HPMC was added to an aqueous dispersion of this complex, to give an hydrogel with a final concentration of 20 mg/mL of Ris, 40 mg/mL of EuE and 2 % of HPMC. Both hydrogels are thus named Ris-_{HPMC} and EuE-Ris-_{HPMC} respectively.

2.2. EuE-Ris-_{HPMC} and Ris-_{HPMC} hydrogels physicochemical characterization

The pH was determined in all the systems obtained, using a Mettler Toledo Seven Multi pH meter equipped with a combined Ag/AgCl electrode (Mettler Toledo DG 115-SC). The surface charge was analyzed using a Zetasizer NanoSerie DTS 1060 (Malvern Instruments S.A., Worcestershire, UK). The hydrogels were diluted (1:10) in deionized water, and zeta potential (ZP) was determined at 25 °C in triplicate.

Bicompartmental Franz cells were used to study the release behavior of the hydrogels obtained. One (1) mL of EuE-Ris-_{HPMC} (pH = 5.5) and Ris-_{HPMC} (pH = 5.2) containing 5 mg of Ris was used. An aqueous Ris solution (pH = 4.8) and EuE-Ris (pH = 4.7) dispersion containing equivalent Ris concentration were used as references. Ris concentration for the assay was selected in order to reach *sink* conditions. For that, the volume of the receptor compartment, sampling frequency and concentration of Ris in the donor compartment were considered. The experiments were performed as described in Guzman *et al.* [14] with the receptor compartment filled with milli Q water or physiological solution (NaCl 0.9 %). Ris concentrations were determined by UV spectroscopy at $\lambda = 262$ nm. For comparison, Ris release slopes from Ris solutions were used. Slopes were calculated using the initial portion of the linear section of the curve.

2.3. *In vivo* anti-leishmanial efficacy of hydrogels

2.3.1. Leishmania parasites

L. (L.) amazonensis promastigotes (MHOM/BR/73/M2269) were taken from liquid nitrogen stocks and maintained by serial passages in the tail base of BALB/c mice. Isolation was performed by seeding lesion

homogenates in Difco blood agar (USMARU) medium containing 20 % of defibrinated rabbit blood plus Proline Balanced Salt Solution (PBSS) containing 100 U/mL penicillin and 50 μ g/mL streptomycin (P-S, Invitrogen Life Technologies, Carlsbad, CA, USA.) at 24 °C. During the stationary phase, parasites were harvested, washed in PBSS pH 7 with 1 % penicillin/streptomycin, and re-suspended in PBSS at the concentration required for mice inoculation.

2.3.2. Animal model

BALB/c female mice (6–8 weeks old) from the Animal Facility of the Institute of Experimental Pathology, Salta, Argentina were used. Animals were infected according to Peralta *et al.* protocol [15]. The base of the tail was intradermally inoculated with 1–2 x 10⁷ parasites (50 μ L), and after approximately five weeks of inoculation, the lesions became ulcerated.

Animals were maintained in a controlled environment of 55 % relative humidity and 26 °C, with food and water *ad libitum*. All animal protocols were approved by the Institutional Committee for the Care and Use of Laboratory Animals of the School of Health of Universidad Nacional de Salta, Argentina (Res. CD N° 745-17). This study also complies with the Arrive guide for the care and use of laboratory animals [16].

2.3.3. Treatments

Animal treatments started five weeks after infection, when the lesions had become ulcerated. A 100 μ L dose of hydrogel containing 2 mg Ris or an equivalent dose from EuE-Ris complex was applied with a syringe and spread over the lesion. Two doses a day were applied 5 days a week for 22 days and the mice were observed after gel administration for approx. 30 minutes.

Animals were divided into the following three groups: group 1 received Ris-_{HPMC} hydrogel; group 2 was given EuE-Ris-_{HPMC} hydrogel; and the control animal group (group 3) received no treatment. Each experimental group had 5 mice.

2.3.4. Lesion size

Lesion areas (ulcers) were determined by measuring the ulcer diameters throughout the treatment (over 22 days) with a digital caliper. Two diameters (L and W; at right angles to each other) of the ulcer were measured, and the size (mm²) was determined according to Eq. (1).

$$\text{Lesion size (LS)} = (L * W) / (4 * \pi) \quad (1)$$

Results are informed as each group's lesion average area for each day's treatment. The area of lesions with completely flattened edges was taken to be 0 mm².

2.3.5. Lesion macroscopic appearance

Animal lesions were photographed at the end of treatment and classified in terms of severity. At the beginning of the experiment, all lesions were ulcers. Flattened edges were considered to be a sign of cure of the lesion.

Leishmania related lesions are initially papular. Gradually they take on a darker reddish tone, while becoming infiltrated and bigger. The lesions then progress into nodular lesions, or a deeply infiltrated plaque, at the center of which a seropurulent exudate begins to sprout, whose desiccation may give rise to a tightly adhering scab. In this phase, the ulcerative lesion may have a variable dimension; the skin that covers it has a wine-violaceous red tone and is often surrounded by an edematous and indurated area. Dermal necrosis may also be seen [17].

The stages of the lesions, which are related to their severity, were classified as follows:

- a) Necrotic ulcer: dry and regular rounded edges with lesions having a dark red/black color in the center.

- b) Ulcer: hollow injury covered with furfuraceous scales, at the center of which sprouts a seropurulent exudate, with thick high borders.
- c) Partially flattened edges: ulcerated lesion that begins to heal and flatten, but still having an ulcerated area that is less than 50 % of the initial area.
- d) Flattened edges: where the ulcer has disappeared and the edges are flattened in the whole perimeter of the lesion.

2.3.6. Immunoglobulin levels

At the end of treatment, blood was extracted in order to measure immunoglobulin levels.

Parasite-specific IgG1 and IgG2a from serum were measured by ELISA as described in a previous work [15].

2.3.7. Smears

The presence of parasites in the lesions was examined after sacrificing the animals. Skin tissue samples were aseptically excised with scissors, smeared in glass slides and dyed using DiffQuick (Biopur Diagnosis) to enable recognition of the nucleus and cytoplasm of the macrophages and parasites. By this technique, the parasites in the lesions could be observed and identified by the kinetoplast joined to the nucleus. Photographs were taken in a Zeiss optical microscope at 40X.

2.3.8. Parasitic inhibition in the lesion

The number of parasites (amastigotes) remaining in the lesions after the end of treatment was determined from macerates of the skin lesion area. To obtain the amastigotes from the tissue, a protocol described in Peralta et al [18] was followed. Briefly, 5 skin tissue samples were homogenized and the parasites were separated through mechanical tissue disruption using a glass grinder. The percentage of parasite inhibition with regard to controls was calculated as: (Total number of amastigotes in treated group) \times 100/(Total number of amastigotes in control group).

The viability of the remaining parasites was examined by using an aliquot of each homogenate (1 mL) cultured in Difco blood agar (USMARU) medium containing 20 % of defibrinated rabbit blood plus P-S [19, 20] at 23 °C under agitation. These cultures were then examined for the presence of leishmania promastigotes after one week.

2.3.9. Statistical analysis

The results of lesion sizes and immunoglobulin levels were analyzed using the unpaired Mann-Whitney test, with $p < 0.05$ denoting significant differences. GraphPad Prism (v.6) software was used for this analysis. The results are presented as means and standard error. The macroscopic aspect of the lesions at the end of the treatments was plotted as a percentage of case frequency for each experimental group.

3. Results and discussion

3.1. EuE-Ris-HPMC and Ris-HPMC hydrogels physicochemical characterization

The preparation method produced translucent semisolid homogeneous hydrogels of EuE-Ris-HPMC and Ris-HPMC without tendency for phase separation, with an adequate viscosity that allowed easy expelling through the syringe and manual administration.

EuE-Ris-HPMC hydrogels presented a pH value of 6.0 ± 0.5 , Ris-HPMC hydrogel pH was 5 ± 0.4 . Zeta potential of EuE-Ris-HPMC was high and positive (20.6 ± 0.2) and Ris-HPMC zeta potential was 5.5 ± 0.9 .

Ris release towards physiological NaCl solution or water in bicompartamental Franz cells from all dispersions is shown in Figure 1. When the receptor compartment was filled with water, a faster diffusion of Ris from Ris-HPMC hydrogel was observed in comparison to the release from EuE-Ris-HPMC hydrogel. When water in the receptor compartment was replaced by a solution of NaCl, the release rate from the EuE-Ris-HPMC hydrogel was significantly increased. Such behaviour can be associated with the ionic exchange produced by the diffusion of Na^+ and Cl^- to the

donor compartment, which has been previously observed with other EuE complexes [21, 22]. No modifications in release rate from Ris-HPMC hydrogel were observed in NaCl vs water (Figure 1).

The presence of HPMC in Ris-HPMC and EuE-Ris-HPMC dispersions slowed Ris release in both media evaluated as compared to Ris solution or EuE-Ris aqueous dispersion. Ris-HPMC dispersion slope was lower than that of Ris in water (Slope Ris-HPMC/Slope Ris = 0.69) and in physiologic solution (Slope Ris-HPMC/Slope Ris = 0.67). For EuE complexes, Slope EuE-Ris-HPMC/Slope EuE-Ris were 0.8 and 0.54 in water and NaCl respectively.

The decrease in the release rate of Ris in Ris-HPMC dispersions can be related to the higher viscosity and hence a slower diffusion of Ris to the receptor compartment. Drug diffusion depends on the crossover and chain expansion of the polymers (i.e. increased viscosity and elasticity) [23]. The presence of HPMC in EuE-Ris-HPMC dispersions also produced a decrease in the release rate of Ris, but in this case the release mechanism is dependent on ionic exchange and hence, when water was used as receptor media, the decrease was not significant.

The pH values of the receptor compartments recorded at the end of the experiments were 4.4 ± 0.3 , 5.0 ± 0.2 when water and physiological solution, respectively, were used.

3.2. In vivo anti-leishmanial efficacy of hydrogels

As shown in Figure 2C, in this model of CL the mice develop a single lesion, at the inoculation site. Topical Ris-HPMC and EuE-Ris-HPMC treatment resulted in a reduction of the size of the lesions compared to untreated mice. In the group treated with EuE-Ris-HPMC, the lesions borders started to partially flatten and the ulcer to show cicatrization from the first week of treatment. From day 19, lesions had completely flattened borders and no ulcers were visible in this group. We described this behavior as 0 mm² lesion area at days 19 and 22 in Figure 2A.

In the group treated with Ris-HPMC, the lesions started to flatten, show cicatrization and diminish size at day 19. All the lesions treated with either Ris-HPMC or EuE-Ris-HPMC showed an improvement in lesion appearance, with flattened edges either in a part or in the complete perimeter of the lesion, along with a recovery of the epidermis in the previously ulcerated central region. At the end of treatment 100 % and 50 % of the lesions treated with EuE-Ris-HPMC and Ris-HPMC, respectively, showed flattened edges in the complete perimeter of the lesion and cicatrization of the ulcer (Figure 2B). Even in animals treated with Ris-HPMC showing only a partially flattened edge, the ulcer showed cicatrization (Figure 2B and C). While 60 % of untreated control mice developed necrosis, this was never observed in the groups treated with Ris-HPMC or EuE-Ris-HPMC. A marked parasitic inhibition in the lesions at the end of treatment was found in the groups treated with Ris-HPMC or EuE-Ris-HPMC (69.5 % and 73.7 % respectively, Table 1). No animals were kept alive after treatment completion to evaluate recidivism, since we found approx. 2×10^7 parasites in each lesion at the end of treatment. Since this amount of parasites is enough to produce a recidiva of the lesion, the animals cannot be considered cured.

Smears from the control group lesions revealed a higher amount of amastigotes per field than those of Ris-HPMC and EuE-Ris-HPMC groups. Both Ris-HPMC and EuE-Ris-HPMC groups showed development of promastigotes when the recovered lesions were cultured in USMARU, indicating the presence of viable remaining parasites at the end of treatment. However, the amastigotes found in the lesions treated with EuE-Ris-HPMC showed vacuoles and a less compact nucleus (Figure 3A). The cytoplasmic vacuolization in the parasites treated with EuE-Ris-HPMC suggest that autophagy is the mechanism underlying leishmania death [24]. However, specific experiments should be performed to confirm if EuE itself is the responsible for this mechanism or it is potentiating Ris anti-leishmanial activity.

Concerning the anti-leishmanial serum immunoglobulin levels, the difference of IgG2a/IgG1 ratios was not significant between groups although the ratios tended to increase in the treated groups after

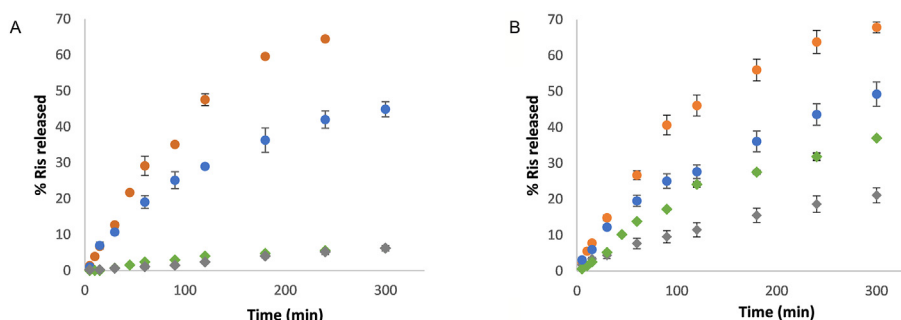


Figure 1. Risedronate release kinetics from different dispersions. Ris release from EuE-Ris_{HPMC} (♦) and Ris_{HPMC} (●) towards water (A) and physiological NaCl solution (B). EuE-Ris (■) and RisNa (●) water dispersions were used as references.

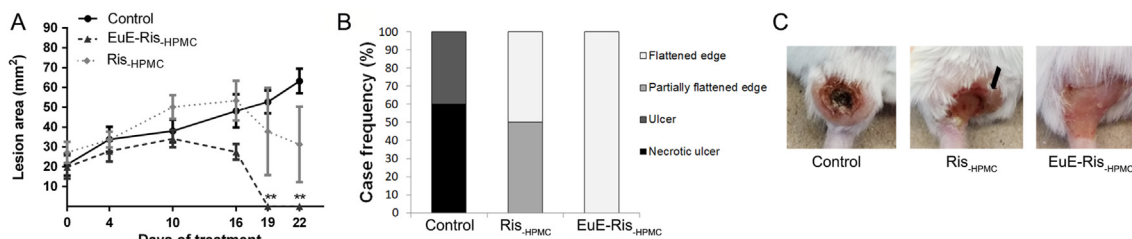


Figure 2. Macroscopic appearance of lesions. A) Ulcer sizes in BALB/c mice infected with *L. (L.) amazonensis* after topical Ris_{HPMC} or EuE-Ris_{HPMC} treatment. Lesion areas were determined using the formula: $(L * W)/(4 * \Pi)$, where L and W are two perpendicular diameters. Lesions with completely flattened edges and no ulcers were recorded as having 0 mm² areas. **P < 0.005 (treatments vs control group). N = 5. B) Percentage case frequency of lesions with flattened edges in the entire perimeter of the lesion, partially flattened edges (only in part of the perimeter), ulcers or necrotic ulcers, determined from observations of the images. C) Representative photos of each experimental group. Note the presence in the control lesion of a necrotic center. In the case of Ris_{HPMC} treated animals, the lesions edge persists in part of the perimeter of the lesion (black arrow), but the ulcer appears closed. In EuE-Ris_{HPMC} treated animals, there is complete flattening of the lesion, ulcer cicatrization and absence of protruding edges.

treatments (Figure 3B). In the BALB/c - *L. (L.) amazonensis* model, the progression of the disease seven weeks after infection normally shows greatly increased IgG1 levels and decreased IgG2a levels [25]. This was observed in the control untreated group. After treatment with Ris_{HPMC} or EuE-Ris_{HPMC}, the IgG2a/IgG1 ratio continued to be lower than 1, which is typical since normalization of the immune profile after treatment requires a long time [26], and we measured the IgG levels immediately at the end of treatment. However, the IgG2a/IgG1 ratio tended to increase with the treatments, implying a tendency to a Th1 response. This is crucial because the activation of infected macrophages produces leishmanicidal products such as nitric oxide radicals, which are toxic for the parasite [27, 28].

Other topical drugs, including imiquimod and amphotericin B, have been tested in clinical trials, but results are equivocal and no major breakthroughs have yet been achieved [29, 30]. Very recently, three manuscripts have reported the good efficacy of topical Miltefosine or Miltefosine/AnfotericineB dispersions in CL animal models produced by different species of leishmania [31, 32, 33], including our own work (M.F. Peralta, et al 2021) [15]. Leishmania is however a parasite that is notable for showing a highly variable response to pharmacological therapy, depending not only on species but even also on geographical

Table 1. Parasitic inhibition in BALB/c mice infected with *L. (L.) amazonensis*. Amastigotes recovered from the lesions at the end of treatment and counted in an optical microscope with a Neubauer chamber after topical Ris_{HPMC} and EuE-Ris_{HPMC} treatments.

Treatment	Number of parasites per lesion	Percentage suppression of parasite burden in lesions
Control	7.6×10^7	0
Ris _{HPMC}	2.3×10^7	69.5
EuE-Ris _{HPMC}	2.0×10^7	73.7

region. Consequently, the formulation of an effective pharmacotherapy containing a different kind of drug such as Risedronate is extremely important in the fight against the disease.

By flattening the borders of the lesions and eliminating ulcers, topical Ris_{HPMC} was effective against *L. (L.) amazonensis*. We did not observe significant differences between Ris_{HPMC} and EuE-Ris_{HPMC} regarding parasitic burden decrease, but a clearly higher efficacy in healing the lesions by EuE-Ris_{HPMC} was observed. This is especially important since untreated lesions produce unsightly anthropic scars [34]. EuE may have enhanced by itself the anti-leishmanial activity of Ris_{HPMC} in the complex [13]. In order to verify this, *in vitro* studies should be performed. Unfortunately, we were unsuccessful in performing *in vitro* studies due to the insolubility of Ris and EuE-Ris in culture media since aminobisphosphonates form insoluble complexes with calcium or other divalent cations [14, 35] and EuE precipitates at pH values above 5 [36].

Although the release of Ris from EuE-Ris_{HPMC} was slower than from Ris_{HPMC}, we observed a higher efficacy as anti-leishmanial, which may be related to the complementary action of EuE. This increased activity might be explained by the mode of action of individual components. Recently, Gadelha et al. proposed a mechanism of action for Ris in *Leishmania infantum*. Leishmania synthesizes ergosterol and Ris strongly inhibits farnesyl diphosphate synthase (FPPS) enzyme, a key intermediate for ergosterol biosynthesis. Moreover, they observed that promastigotes treated *in vitro* with Ris showed small vesicles in the Golgi region near the kinetoplast, mitochondrial swelling, blebbing of the plasma membrane, as well as nuclear pyknosis and chromatin condensation [10]. They also reported phosphatidylserine (PS) exposure on the membrane of the parasites, which indicates early apoptosis. In addition, bisphosphonates have been shown to accumulate in tissues susceptible to infection by some of these parasites and to possess immunomodulatory effects [37].

In line with that observation, our *in vivo* results showed that lesions treated with EuE-Ris_{HPMC} present vacuoles near the kinetoplast and

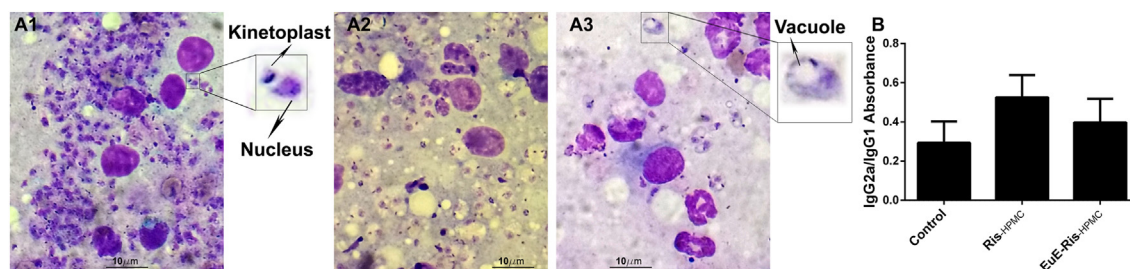


Figure 3. A) Optical microscopy images of smears from lesions. The intracellular amastigotes are identified by the rod-shaped kinetoplast and the circular nucleus in lesion smears of the control group without treatment (A1), Ris-_{HPMC} group (A2) and EuE-Ris-_{HPMC} group (A3). The amplified sections (4x digitally amplified from original images) show amastigotes morphology. B) Serum anti-leishmanial antibodies at the end of treatment. Ratio of IgG2a/IgG1 (Absorbance) levels found in the serum of animals at the end of treatments. Measurements were obtained by ELISA. N = 5.

pyknosis, and also that chromatin condensation occurred in the nucleus of the parasites (Figure 3 A3), suggesting that the combined therapy with EuE and Ris can improve anti-leishmanial efficacy. Considering that EuE is a polycation and EuE-Ris-_{HPMC} presents a high and positive zeta potential, an increased capability of interaction with the negatively charged PS present in parasites membrane could be playing a role. In fact, once EuE-Ris-_{HPMC} reaches the macrophages vacuoles, the interaction with PS can produce severe damage and parasite death [24, 38]. However, more research is necessary to elucidate such mechanisms and to confirm if the combined therapy produces additive or synergistic effects.

Cutaneous wound healing in mammals is a complex multi-step process. It has also been suggested that microbes of lesions play significant roles in impaired wound healing, i.e., in complex chronic injury, microbiome have a detrimental effect on wound closure [39, 40]. A moist wound environment is considered to promote the wound healing process, favoring the granulation step. In our case, Ris-_{HPMC} and EuE-Ris-_{HPMC} were dispersed in a hydrogel system containing polymers that could facilitate the re-epithelialization process by diminishing water loss [41]. Besides, by causing a reduction of the parasite load, EuE-Ris-_{HPMC} presumably had complementary effects in healing.

A re-epithelialization process of the ulcers was observed, but with parasites still remaining in the dermis below the lesions, which may imply a persistence/recurrence of the disease. The persistence of leishmania in skin or mucosal tissues was also reported in patients who achieved therapeutic cure of CL [42]. In fact, at present, the exact factors related to parasite persistence or elimination are unknown.

Being highly polar, Ris is a molecule with a very low permeability [43]. Thus, in order to reach dermal parasites it is probably necessary that Ris application takes place while there is still an ulcer, when there are no well-formed epidermal skin layers to penetrate. Thus, to improve parasite reduction, the dosage or frequency of administration could be increased, or combinations tried with other components of proven activity. Meanwhile, the repurposing of both Ris and EuE for topical treatment of CL is worth being explored.

This could be strategic since they are approved compounds, which can reduce time, cost and risk, and it is a particularly attractive approach for neglected tropical diseases where new medications are needed urgently to treat the poorest of people, making their translation to clinical use more feasible. In this sense, translational research, built on the solid foundation of existing and ongoing basic research, is a priority.

4. Conclusions

The development of novel chemotherapeutic approaches for CL is of great importance. The use of bisphosphonates is of interest as they have already been used for other clinical indications. Ris produced moderately encouraging results in the treatment of CL caused by *L. (L.) amazonensis* in an experimental animal model. The EuE-Ris-_{HPMC} complex led to lesion cicatrization and a slightly higher reduction in the parasitic

burden. Future work should be aimed at optimizing the concentration, dose frequency, drug or excipient combinations and system characteristics in order to attain total parasite elimination. To the best of our knowledge, this is the first report on the efficacy of bisphosphonates against CL as a topical treatment.

Declarations

Author contribution statement

Ma. Florencia Peralta: Conceived and designed the experiments; Performed the experiments; Analyzed and interpreted the data; Wrote the paper.

Ma. Laura Guzman: Conceived and designed the experiments; Performed the experiments; Analyzed and interpreted the data; Wrote the paper.

Ma. Estefanía Bracamonte: Performed the experiments.

J. Diego Marco: Analyzed and interpreted the data; Contributed reagents, materials, analysis tools or data.

Ma. Eugenia Olivera: Contributed reagents, materials, analysis tools or data.

Dolores C. Carrer: Conceived and designed the experiments; Analyzed and interpreted the data; Contributed reagents, materials, analysis tools or data; Wrote the paper.

Paola A. Barroso: Conceived and designed the experiments; Performed the experiments; Analyzed and interpreted the data; Contributed reagents, materials, analysis tools or data; Wrote the paper.

Funding statement

Ma. Laura Guzman, Ma. Eugenia Olivera and Dolores C. Carrer were supported by Secretaría de Ciencia y Tecnología - Universidad Nacional de Córdoba; Dolores C Carrer was supported by Fundación Bunge y Born and by PUE - CONICET 2016- 22920160100135CO; Paola A. Barroso was supported by FONCYT, Agencia Nacional de Promoción de la Investigación, el Desarrollo Tecnológico y la Innovación, Argentina.

Data availability statement

Data included in article/supplementary material/referenced in article.

Declaration of interests statement

The authors declare no conflict of interest.

Additional information

No additional information is available for this paper.

Acknowledgements

Authors would like to thank Federico Ramos and Alejandro D. Uncos for their help with animal experiments.

References

- [1] J.-C. Dujardin, L. Campino, C. Canavate, J.-P. Dedet, L. Gradoni, K. Soteriadou, A. Mazeris, Y. Ozbek, M. Boelaert, Spread of vector-borne diseases and neglect of Leishmaniasis, Europe, *Emerg. Infect. Dis.* 14 (2008) 1013–1018.
- [2] T. Garnier, S.L. Croft, Topical treatment for cutaneous leishmaniasis, *Curr. Opin. Invest. Drugs* 3 (2002) 538–544.
- [3] V.S. Amato, F.F. Tuon, A.M. Siqueira, A.C. Nicodemo, V.A. Neto, Treatment of mucosal leishmaniasis in Latin America: systematic review, *Am. J. Trop. Med. Hyg.* 77 (2007) 266–274.
- [4] B.L. Herwaldt, Leishmaniasis, *Lancet* 354 (1999) 1191–1199.
- [5] S.H. Al-Natour, Update in the treatment of cutaneous leishmaniasis, *J. Fam. Commun. Med.* 16 (2009) 41–47.
- [6] R.X. Armijos, M.M. Weigel, M. Calvopiña, M. Mancheno, R. Rodriguez, Comparison of the Effectiveness of Two Topical Paromomycin Treatments versus Meglumine Antimoniate for New World Cutaneous Leishmaniasis 91, 2004, pp. 153–160.
- [7] G. Faghihi, R. Tavakoli-kia, Treatment of cutaneous leishmaniasis with either topical paromomycin or intralesional meglumine antimoniate, *Clin. Exp. Dermatol.* 28 (2003) 13–16.
- [8] F. Irají, A. Sadeghinia, Efficacy of paromomycin ointment in the treatment of cutaneous leishmaniasis: results of a double-blind, randomized trial in Isfahan, Iran, *Ann. Trop. Med. Parasitol.* 99 (2005) 3–9.
- [9] M.B. Martin, J.S. Grimley, J.C. Lewis, H.T. Heath, B.N. Bailey, H. Kendrick, V. Yardley, A. Caldera, R. Lira, J.A. Urbina, S.N.J. Moreno, R. Docampo, S.L. Croft, E. Oldfield, Bisphosphonates inhibit the growth of *Trypanosoma brucei*, *Trypanosoma cruzi*, *Leishmania donovani*, *Toxoplasma gondii*, and *Plasmodium falciparum*: a potential route to chemotherapy, *J. Med. Chem.* 44 (2001) 909–916.
- [10] A.P.R. Gadelha, C.M. Brigagao, M.B. da Silva, A.B.M. Rodrigues, A.C.R. Guimarães, F. Paiva, W. de Souza, C. Henriques, Insights about the structure of farnesyl diphosphate synthase (FPPS) and the activity of bisphosphonates on the proliferation and ultrastructure of *Leishmania* and *Giardia*, *Parasites Vectors* 13 (2020) 168.
- [11] V. Yardley, A.A. Khan, M.B. Martin, R. Teri, F.G. Araujo, S.N.J. Moreno, S.L. Croft, E. Oldfield, T.R. Slifer, R. Docampo, Vivo activities of farnesyl pyrophosphate synthase inhibitors against *leishmania donovani* and *toxoplasma gondii*, *Am. Soc. Microbiol.* 46 (2002) 929–931.
- [12] N. Rodriguez, B.N. Bailey, M.B. Martin, E. Oldfield, J.A. Urbina, R. Docampo, Radical cure of experimental cutaneous leishmaniasis by the bisphosphonate pamidronate, *J. Infect. Dis.* 186 (2002) 138–140.
- [13] D.R. Serrano, A. L. M.A. Dea-Ayuela, Engineering synergistically active and bioavailable cost-effective medicines for neglected tropical diseases; the role of excipients, *Curr. Top. Med. Chem.* 17 (2017) 2888–2900.
- [14] M.L. Guzman, E.A. Soria, C. Laino, R.H. Manzo, M.E. Olivera, Reduced food interaction and enhanced gastrointestinal tolerability of a new system based on risedronate complexed with Eudragit E100: mechanistic approaches from in vitro and in vivo studies, *Eur. J. Pharm. Biopharm.* 107 (2016) 263–272.
- [15] M.F. Peralta, M.E. Bracamonte, M.L. Guzman, M.E. Olivera, J.D. Marco, D.C. Carrer, P.A. Barroso, Efficacy of topical miltefosine formulations in an experimental model of cutaneous leishmaniasis, *Drug Deliv. Transl. Res.* (2021).
- [16] For the C. And U. of L.A. Committee for the Update of the Guide, Guide for the Care and Use of Laboratory Animals, 2011.
- [17] A.C. Santi, Úlceras por leishmaniasis, *Flebología.* 43 (2017) 43–48.
- [18] M.F. Peralta, M.L. Guzmán, A.P. Pérez, G.A. Apezteguia, M.L. Fórmica, E.L. Romero, M.E. Olivera, D.C. Carrer, Liposomes can both enhance or reduce drugs penetration through the skin, *Sci. Rep.* 8 (2018) 13253.
- [19] D. Evans, Handbook on Isolation, Characterization and Cryopreservation of *Leishmania*, WHO, Geneva, 1989.
- [20] J.D. Marco, P.A. Barroso, M. Calvopiña, H. Kumazawa, M. Furuya, M. Korenaga, S.P. Cajal, M.C. Mora, M.M.J. Rea, C.E. Borda, M.A. Basombrio, N.J. Taranto, Y. Hashiguchi, Species assignment of *Leishmania* from human and canine American tegumentary leishmaniasis cases by multilocus enzyme electrophoresis in North Argentina, *Am. J. Trop. Med. Hyg.* 72 (2005) 606–611.
- [21] D.A. Quinteros, V.R. Rigo, A.F.J. Kairuz, M.E. Olivera, R.H. Manzo, D.A. Allemandi, Interaction between a cationic polymethacrylate (Eudragit E100) and anionic drugs, *Eur. J. Pharmaceut. Sci.* 33 (2008) 72–79.
- [22] M.L. Guzmán, R.H. Manzo, M.E. Olivera, Eudragit E100 as a drug carrier: the remarkable affinity of phosphate ester for dimethylamine, *Mol. Pharm.* 9 (2012) 2424–2433.
- [23] C. Alvarez-Lorenzo, R. Duro, J.L. Gómez-Amoza, R. Martínez-Pacheco, C. Souto, A. Concheiro, Influence of polymer structure on the rheological behavior of hydroxypropylmethylcellulose–sodium carboxymethylcellulose dispersions, *Colloid Polym. Sci.* 279 (2001) 1045–1057.
- [24] A. Bera, S. Singh, R. Nagaraj, T. Vaidya, Induction of autophagic cell death in *Leishmania donovani* by antimicrobial peptides, *Mol. Biochem. Parasitol.* 127 (2003) 23–35.
- [25] R.P. Almeida, M. Barral-Netto, A.M.R. De Jesus, L.A.R. De Freitas, E.M. Carvalho, A. Barral, Biological behavior of *Leishmania amazonensis* isolated from humans with cutaneous, mucosal, or visceral leishmaniasis in BALB/c mice, *Am. J. Trop. Med. Hyg.* 54 (1996) 178–184.
- [26] A. Caldas, C. Favali, D. Aquino, V. Vinhas, J. van Weyenbergh, C. Brodskyn, J. Costa, M. Barral-Netto, A. Barral, Balance of IL-10 and Interferon- γ plasma levels in human visceral leishmaniasis: implications in the pathogenesis, *BMC Infect. Dis.* 5 (2005) 113.
- [27] B.L.S. Campos, Análise de imunogenicidade e proteção gerada pelos imunógenos de terceira geração pVAX1-FSD e pVAX1-SP contra a leishmaniose tegumentar americana experimental, 2015.
- [28] M. Rostamian, S. Sohrabi, H. Kavosifard, H.M. Niknam, Lower levels of IgG1 in comparison with IgG2a are associated with protective immunity against *Leishmania tropica* infection in BALB/c mice, *J. Microbiol. Immunol. Infect.* 50 (2017) 160–166.
- [29] S. Espuelas, J. Schwartz, E. Moreno, Nanoparticles in the topical treatment of cutaneous leishmaniasis, *Nanosci. Dermatol.* (2016).
- [30] L. López, I. Vélez, C. Asela, C. Cruz, F. Alves, S. Robledo, B. Arana, A phase II study to evaluate the safety and efficacy of topical 3% amphotericin B cream (Anfoleish) for the treatment of uncomplicated cutaneous leishmaniasis in Colombia, *PLoS Neglected Trop. Dis.* 12 (2018), e0006653.
- [31] L.F. Neira, J.C. Mantilla, P. Escobar, Anti-leishmanial activity of a topical miltefosine gel in experimental models of New World cutaneous leishmaniasis, *J. Antimicrob. Chemother.* 74 (2019) 1634–1641.
- [32] M.J. Dar, S. Khalid, C.A. McElroy, A.R. Satoskar, G.M. Khan, Topical treatment of cutaneous leishmaniasis with novel amphotericin B-miltefosine co-incorporated second generation ultra-deformable liposomes, *Int. J. Pharm.* 573 (2020) 118900.
- [33] Z. Kaviani, S.H. Alavizadeh, S. Golmohammadzadeh, A. Badiee, A. Khamesipour, M.R. Jaafari, Development of topical liposomes containing miltefosine for the treatment of *Leishmania major* infection in susceptible BALB/c mice, *Acta Trop.* 196 (2019) 142–149.
- [34] D.B. Thornburgh, The histopathology of cutaneous leishmaniasis in Panama, *Trans. R. Soc. Trop. Med. Hyg.* 46 (1952) 550–554.
- [35] W.A. Cilley, R.J. Grabenstetter, Polynuclear complex formation in solutions of calcium ion and 1-hydroxyethylene-1,1-diphosphonic acid. I. Complexometric and pH titrations, *J. Phys. Chem.* 75 (1971) 676–682.
- [36] A.J. Chang, R. K. Y. Peng, N. Trivedi, Shukla, polymethacrylates, in: M.E. Rowe, R.C. Sheskey, P.J. Quinn (Eds.), *Handb. Pharm. Excipients*, sixth ed., Pharmaceutical Press, London, UK, 2009, p. 525, 523.
- [37] V. Kunzmann, E. Bauer, J. Feurle, F. Weissinger, H.P. Tony, M. Wilhelm, Stimulation of gammadelta T cells by aminobisphosphonates and induction of antiplasma cell activity in multiple myeloma, *Blood* 96 (2000) 384–392.
- [38] A. Banerjee, J. Roychoudhury, N. Ali, Stearylamine-bearing cationic liposomes kill *Leishmania parasites* through surface exposed negatively charged phosphatidylserine, *J. Antimicrob. Chemother.* 61 (2008) 103–110.
- [39] A.F. Jebran, U. Schleicher, R. Steiner, P. Wentker, F. Mahfuz, H.-C. Stahl, F.M. Amin, C. Bogdan, K.-W. Stahl, Rapid healing of cutaneous leishmaniasis by high-frequency electrocauterization and hydrogel wound care with or without DAC N-055: a randomized controlled phase IIa trial in Kabul, *PLoS Neglected Trop. Dis.* 8 (2014), e2694.
- [40] I. Pastar, O. Stojadinovic, N.C. Yin, H. Ramirez, A.G. Nusbaum, A. Sawaya, S.B. Patel, L. Khalid, R.R. Isseroff, M. Tomic-Canic, Epithelialization in wound healing: a comprehensive review, *Adv. Wound Care* 3 (2014) 445–464.
- [41] P. Rousselle, F. Braye, G. Dayan, Re-epithelialization of adult skin wounds: cellular mechanisms and therapeutic strategies, *Adv. Drug Deliv. Rev.* (2018).
- [42] A.J. Martínez-Valencia, C.F. Daza-Rivera, M. Rosales-Chilama, A. Cossio, E.J. Casadiego Rincón, M.M. Desai, N.G. Saravia, M.A. Gómez, Clinical and parasitological factors in parasite persistence after treatment and clinical cure of cutaneous leishmaniasis, *PLoS Neglected Trop. Dis.* 11 (2017), e0005713 e0005713.
- [43] I. Fogelman, L. Smith, R. Mazess, M.A. Wilson, J.A. Bevan, Absorption of oral diphosphonate in normal subjects, *Clin. Endocrinol.* 24 (1986) 57–62.