



Bio-archaeological analysis of a tooth from a human burial. Summit of Cerro Madre e Hija (Santa Cruz, Argentina)

Juan Pablo Atencio

CONICET, Museo de La Plata, Universidad Nacional de La Plata (La Plata, Argentina)
jp6.atencio@gmail.com

Lucía Magnin

CONICET, Museo de La Plata, Universidad Nacional de La Plata (La Plata, Argentina)
lmagnin@fcnym.unlp.edu.ar

Laura Blanco

CONICET, Museo de La Plata, Universidad Nacional de La Plata (La Plata, Argentina)
laurablanca061@gmail.com

Abstract

As part of a current investigation a number of stone structures have been registered throughout the locality of Santa Cruz (Argentina), which have been assigned to various functions such as hunting blinds, cairns, bases of awnings and "chenques" or funerary structures. Associated to one of these funerary structures, which is located at the top of Cerro Horqueta or Madre e Hija, human skeletal remains were recorded. In February of 2018, the structure was visited with the aim of obtaining a sample for radiocarbon dating and DNA analysis. The present work aims to generate bio-archaeological information, which is currently non-existent for the studied area. Specifically, we present here a bio anthropological analysis on a tooth recovered in the mentioned context. We determined it is a human, permanent upper left canine that belonged to an adolescent or young adult. The presence of a process of incipient hypercementosis, which can be interpreted as indicative of the use of the dentition for para-masticatory purposes, and the burial structure in which the tooth was found allow us to think that the individual may have belonged to an indigenous hunter-gatherer group.

Key words: stone structure, Santa Cruz, Argentina, funerary structures.

1. INTRODUCTION

The Bosques Petrificados de Jaramillo National Park (BPJNP) is a natural area protected under the categories of Natural Monument and National Park. Of recognized paleontological, geological, floristic and faunal importance, its cultural patrimonial value is highlighted by the archaeological research developed since 1997. With the support of the National University of La Plata, the National Scientific and Technical Research Council (CONICET), National Agency for Scientific and Technological Promotion (ANPCyT) and the National Parks Administration (APN), those studies have provided insights on the process of human peopling of this sector of the Central Plateau of Santa Cruz (Argentina) by mobile hunter-gatherer groups that occupied the region since the end of the Pleistocene (Miotti 2003, Miotti and Salemme 2004). The development of a systematic surface survey plan has contributed with new archaeological data, enriching the interdisciplinary study of this landscape and its evolution (Magnin



2016). As part of the investigations several stone structures have been registered throughout the locality, which have been assigned to various functions such as hunting blinds, cairns, bases of awnings and "chenques" or funerary structures. Associated to one of these funerary structures, which is located at the top of Cerro Horqueta or Madre e Hija (Figure 1), human skeletal remains were recorded in an advanced state of weathering (Magnin et al. 2018). In February of 2018, the structure was visited with the aim of obtaining a sample for radiocarbon dating and DNA analysis. Thus, two bone elements were taken: a fragment of a temporal bone and a tooth.

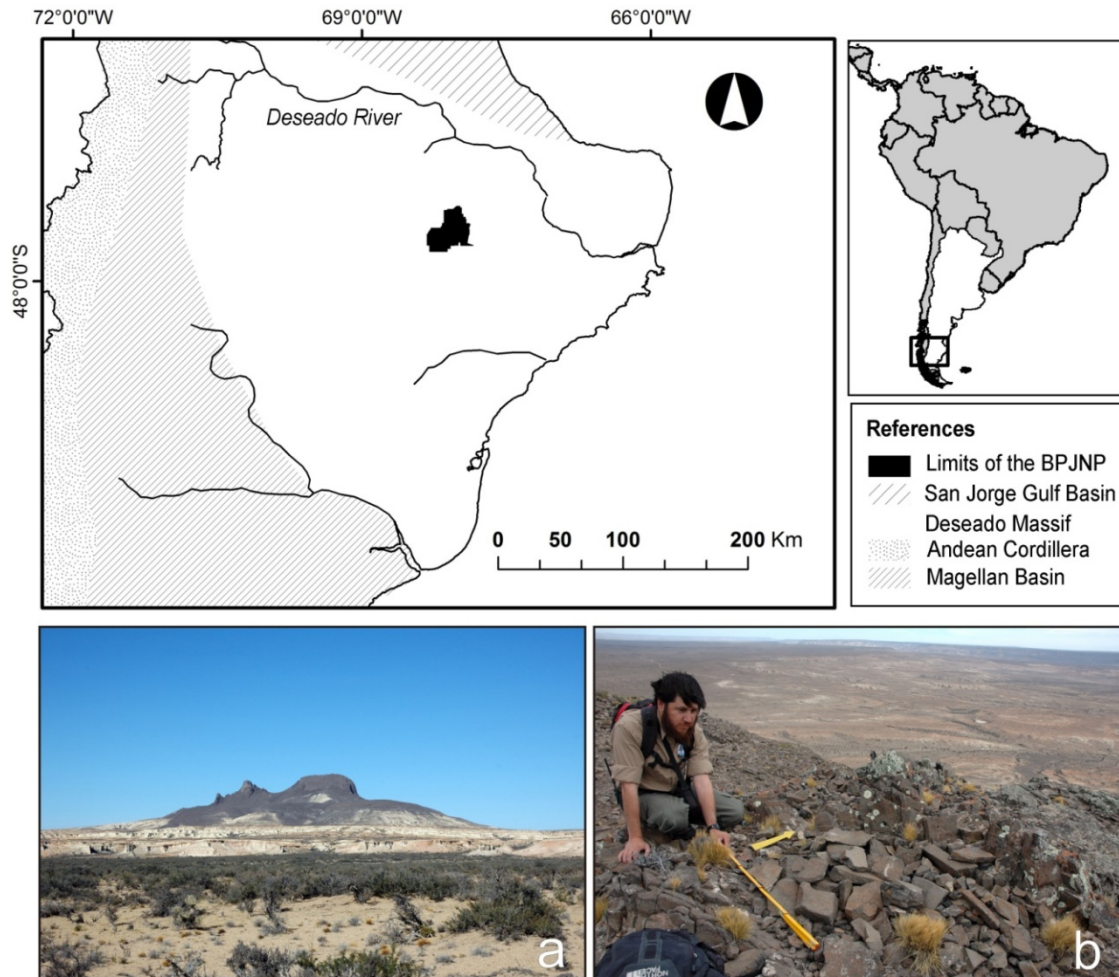


Figure 1. Location of the Petrified Forest National Park of Jaramillo, in the north of the Deseado Massif, Santa Cruz. a) View from the SE of Cerro Horqueta or Madre e Hija; b) Staff of the National Park next to the stone structure where the tooth was found.

The present work aims to generate bio-archaeological information, which is currently non-existent for the studied area. Specifically, we present here a bio anthropological analysis on the recovered tooth. First, we characterize the tooth, describe its state of preservation and analyse if it could be determined as human. Second, we proceed to estimate the most likely age of death of the individual and to evaluate the presence of dental pathologies and para-masticatory use indicators. Finally, we discuss the implications our findings regarding the individual's life.



Due to the advanced state of deterioration presented by the analysed anatomic unit the morphological evaluation was carried out scopically, by direct observation and using high resolution photographs. Four lines of analysis were considered in the elaboration of this work, namely: state of conservation of the piece, dental morphology, degree of macro-wear, and evaluation of paleo-pathological indicators. The specific criteria used in each of these approaches are described in the respective sections.

2. GENERAL CHARACTERIZATION OF THE TOOTH AND ITS STATE OF CONSERVATION

The analysed tooth is structurally compromised due to its state of preservation. The crown has been almost entirely lost, only remaining a minor fragment of it, which is separated from the rest of the piece. The fragment corresponds to a section of the enamel coating of the lingual surface and to a portion of the associated dentine (Figures 2 and 3). It is also possible to observe some remnants of enamel and dentin on the mesial and distal sides of the tooth, close to the cemento-enamel junction (Figure 4). The major preserved portion of the tooth corresponds to a uniradicular root which is almost complete, except for the absence of the cement casing at the apex and at some portions of the distal and lingual root surfaces.

As already stated, the tooth was found isolated at the time of collection, not implanted in its alveolar cavity. The analysed tooth is a fully developed tooth, not showing any sign of pathology or trauma on its root that could be considered as cause for pre mortem lost. An interesting feature is the fact that the tooth shows loss of the enamel coating while preserves the underlying dentin without any modification and keeps the cervical line noticeable on the buccal surface and on some parts of the mesial and distal surfaces. Another significant aspect of the retrieved tooth are the differences in dental cement's colour and texture between two sections of the root. Most of it presents a dark beige patina with a soft texture on the cervical third and the distinctive grainy texture of initial hyper-cementosis on the remaining two thirds, the dark brown coloration observed at Figures 3 and 4 are the result of sediments' residues. This is not the case on a portion of the root that comprises the cervical and middle thirds of the lingual and distal surfaces (at the latter restricted to the lingual aspect of it). Here the cement presents a white-light grey coloration and a chalky texture.

There are also structural integrity differences between these two particularized areas of the root, with the former presenting three major longitudinal fractures, located on the mesial, distal and buccal surfaces, which represent the main structural compromise for the tooth preservation. The rest of this surface is mostly unaltered, except for the cement losses previously mention. Meanwhile the white-light grey area located on the lingual surface of the root presents numerous fissures of varied extension, all aligned along the major axis of the tooth and parallel one to each other. Here the cement is absent, and the cemento-enamel junction is unnoticeable. Finally, it should be noted that the area in question has a clearly defined contour and its shape is not defined by straight lines or angles but by a curved line.

The existence of differences in dental cement's coloration between the two previously mentioned areas of the root, the marked difference in the texture of their surfaces, and the differences in the type, extension and magnitude of the structural damage these two portion of the root present indicates these two areas have been exposed to different depositional conditions (Hillson et al. 2005, Scott 2008, 2012). Moreover, all these elements are coincident with what has been observed in bio-archaeological cases in which a process of recession of the alveolar bone tissue has taken place due to pathological causes (e.g. periodontal disease); thus exposing the upper thirds of the root surface in the affected area (Hillson 1996).



This allows us to hypothesize that the tooth was implanted at the moment of the death of the individual and that the area to which we refer in detail was exposed directly to the action of the taphonomic factors of the external environment, while those factors were mediated by the alveolar bone tissue in which the piece was inserted on the rest of the root. Hence, based on the indicators detailed before, it is possible to infer that the tooth detached from its socket postmortem.

In turn, the aforementioned indicators added to the presence of numerous fractures in the occlusal and lingual aspect of the crown, the right angles that present the planes of fracture to each other, and the existence of longitudinal fractures along the axis of the root (and in radial form with respect to the cavity and the pulp canal), allow us to infer that the fragmentation and structural compromise of the piece is mainly the result of taphonomic processes that occur from the moment of the death of the individual until the tooth it was collected for analysis; possibly related to the drying of the tissues of the tooth and to the action of climatic factors such as temperature and humidity of the substrate where the piece was buried (Gutiérrez 2004, Evans 2014, Higgs and Pokines 2014).

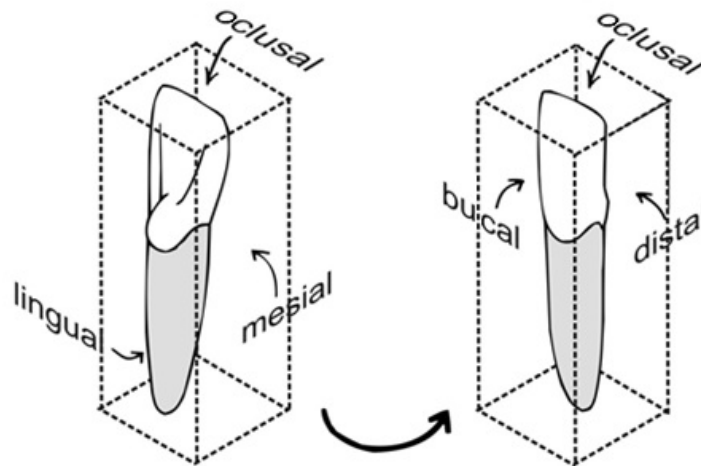


Figure 2. Faces of a tooth (modified from Hillson 2005).

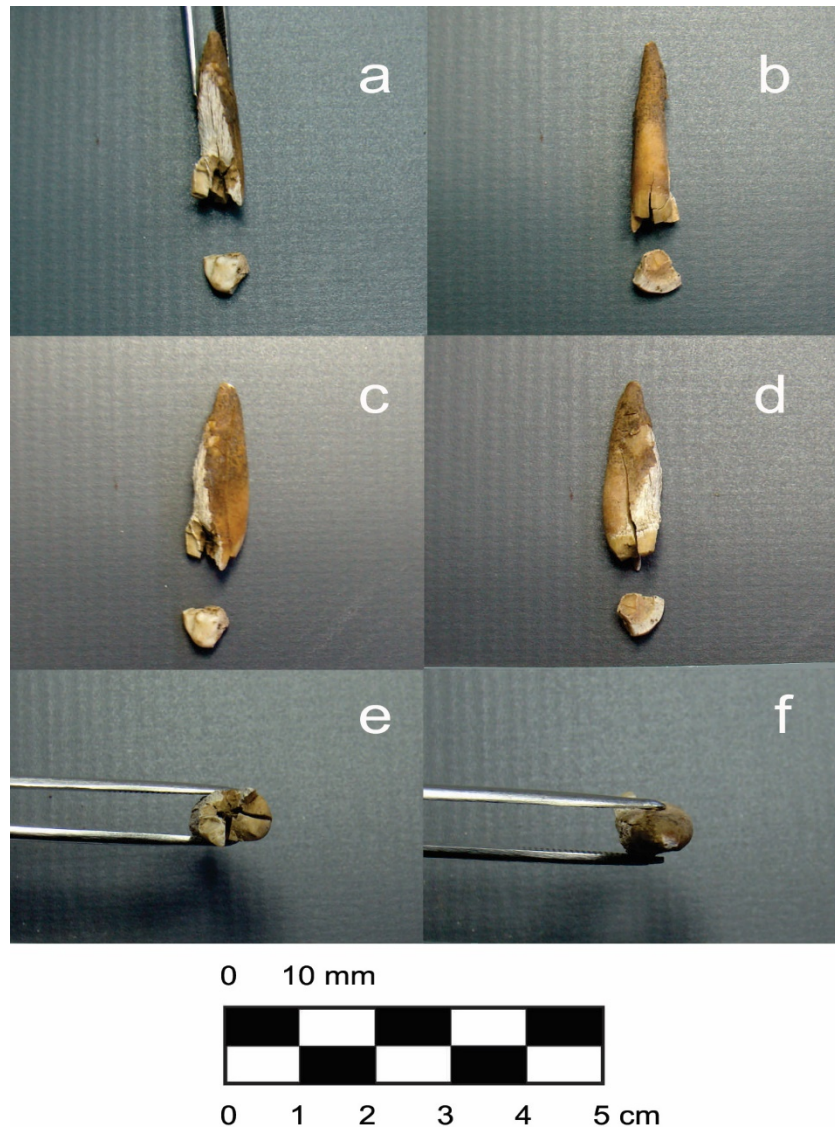


Figure 3. a) Lingual view of the analyzed tooth; b) bucal view: in the mesial and distal ends (left and right, respectively) of the greater fragment, remnants of dentin and enamel of the crown can be observed; c) mesial view; d) distal view; e) oclusal view; f) apical view.

3. MORPHOLOGICAL ANALYSIS

The general morphology of the root, as well as that of the remaining portion of the crown and the cement-adamantine union pattern allowed to identify the analysed piece as part of the permanent dentition of a human individual. The morphological analysis was carried out using the determination and morphodental schemata of Steele and Bramblett (1988), Pineda Paz (2004), Hillson (2005), White and Folkens (2005), and Nelson and Ash (2010).

As previously stated much of the tooth is deteriorated, presenting fracture lines at its root and the almost total loss of its crown as a result of numerous fractures. In the only coronal fragment that allows to analyse



diagnostic structures (Figure 3 a) it is possible to clearly observe the presence of a cuspid apex that is located centrally on a rounded incisal edge and that continues, in the direction of the root, in a central ridge that culminates in the apical portion of a cingulum. On one side of this ridge it is possible to observe the presence of a groove parallel to it, which at the same time clearly delimits the presence of a marginal ridge.

The analysis of the morphology of the root, allows to determine that it is a uniradicular piece. Its length and morphology in cross section, make it possible to establish that it corresponds to a superior anterior tooth. It is also possible to observe that the root is slightly inclined in its main axis (coronal - radicular) with respect to that of the remnants of the crown, and the existence of a relatively marked curvature in the third of the root apex, in the opposite direction (Figure 3a). When evaluating the area of the adamantine cement union it is observed that in the mesial and distal faces it curves in its middle part in a coronal direction generating a concave design; this curvature being much more marked on the mesial aspect than on the distal one (in which it is comparatively barely perceptible).

Depending on the diagnostic indicators and structures mentioned so far, it is possible to identify the tooth studied as a left upper canine, whose complete morphology can be observed in the scheme shown in Figure 4. In turn, the root of the tooth is fully formed, what makes possible to establish for the individual a minimum age between 12 and 15 years (AAPD, 2017).




Figure 4. Upper left canine a) bucal view, b) distal view, c) mesial view (scientific illustration by Laura Blanco).



4. SCOPIC ANALYSIS OF DENTAL WEAR AND PALEOPATHOLOGICAL EVALUATION

The poor state of preservation of the piece prevented the use of typological sequences for the scopic description of the degree of dental wear and made impossible an integral evaluation of indicators of oral paleopathological processes. It has not been possible to evaluate the presence of caries or the deposition of. However, it is worth noting that the preserved fragments of the crown don't show any evidence of the dental wear. Also, based on a series of indicators described in detail in the previous section, it is possible to infer a process of alveolar recession on the bone that covered part of the cervical and middle thirds of the face of the analysed root.

On the other hand, the granular aspect, the greater roughness, and the apparent thickening of the surface that presents the apical third of the root are indicators of an incipient process of hypercementosis (Consolaro et al. 2012). This process occurs more frequently in people of middle or advanced age, and is characterized by the formation of secondary cement deposits in the middle and apical thirds of the root as a defensive response of periapical tissues to chronic periapical or pulpal infections, or as a result of the hyper or hypofunction of the teeth (Peral et al. 2013). An example of hyperfunction is the instrumental use of the dentition (Margvelashvili et al. 2013). However, such possible implications regarding the oral health of the individual be contrasted in this case due to the state of conservation of the tooth and the loss of the alveolar bone structure where it was implanted.

5. CONCLUSIONS

The odontoscopic analysis of the tooth from the funerary structure located in the Cerro Madre e Hija allowed to establish that it is a human tooth, specifically a permanent upper left canine. It belonged to an individual of undetermined sex, possibly adolescent, 12 to 20 years old, or young adult, 20 to 35 years old (Buikstra and Ubelaker 1994); depending on the limited dental wear observed in the remnant crown and the presence of incipient hypercementosis in the root apex.

Usually, dental pieces are used to determine biological distances between human populations and in the allocation of unidentified human remains into a group of origin, allowing in some cases even elucidating the identity of the person. Such approximations are based on the study of the individual's full dentition, or at list a considerable part of it, and on a complete knowledge of the dental characteristics of the possible groups to which the subject could possibly belongs. Such conditions are not met in the current study, being the case an isolated tooth with a poor state of conservation and almost no knowledge of the dental peculiarities of the human groups that inhabited the region since the late Pleistocene. However, it is possible to use the dental considerations previously expressed in this work and the archaeological context information of the analysed tooth to develop a hypothesis of the individual's populational ancestry. The presence of a process of incipient hypercementosis in a presumably young individual, which can be interpreted as indicative of the use of the dentition for para-masticatory purposes, and the burial structure in which the tooth was found allow us to think that the individual may have belonged to an indigenous hunter-gatherer group which inhabited the territory that currently includes the Petrified Forests of Jaramillo National Park. Future work on human remains from the study area, including the analysis of ancient DNA, will make it possible to test this hypothesis; providing support to it or allowing to reject it.



Acknowledgements

The research was possible thanks to Projects 021-CPA-renovation "Arqueología de Cazadores-recolectores del Macizo Central de Santa Cruz. Análisis cuantitativos de patrones espaciales"; UNLP Promotional Research and Development Projects (PPID / N20 -UNLP 2017-2018) "Investigación sobre paisajes de cazadores-recolectores mediante aplicación de tecnologías de información geográfica (Macizo del Deseado, Santa Cruz, Argentina)"; and PICT-CONICET 2015- 0102, "Lugares, caminos y redes de interacción social entre los cazadores-recolectores de las mesetas patagónicas del Deseado y de Somuncurá". We also thank the APN-Southern Patagonia, which provided the research permits; to Arnaldo Dalmasso and other staff of APN for providing support to the PNBPJ; Santiago Medel and Jaime Carballo, who participated in the fieldwork; and Mariano Del Papa, for his advice and for putting the authors of this article in contact.

References

- Buikstra, J., Ubelaker, D. (1994). *Standards for data collection from human skeletal remains*. Fayetteville.
- Consolaro, A., Consolaro, R.B., Francischone, L.A. (2012). Cementum, apical morphology and hypercementosis: a probable adaptive response of the periodontal support tissues and potential orthodontic implications. *Dental Press J Orthod*, 17(1), 21-30. <https://doi.org/10.1590/S2176-94512012000100003>
- Evans, T. (2014). Fluvial taphonomy, pp. 115-142. En Pokines, J.T., Symes, S.A. (eds). *Manual of forensic taphonomy*. CRC Press.
- Gutiérrez, M.A. (2004). *Análisis tafonómico en el área interserrana (provincia de Buenos Aires)*. Manuscrito para optar por el título de Doctor en Ciencias Naturales, Facultad de Ciencias Naturales y Museo de La Plata. La Plata.
- Higgs, N.D., Pokines, J.T. (2014). Marine environmental alterations to bone, pp. 143-180. En Pokines, J.T., Symes, S.A. (eds). *Manual of forensic taphonomy*. CRC Press.
- Hillson, S. (1996). *Dental anthropology*. Cambridge University Press.
- Hillson, S. (2005). *Teeth*. Cambridge University Press.
- Hillson, S., Fitzgerald, C., Flinn H. (2005). Alternative dental measurements: proposals and relationships with other measurements. *Am J Phys Anthropol* 126(4), 413-426. <https://doi.org/10.1002/ajpa.10430>
- Margvelashvili, A. et al. (2013). Tooth wear and dentoalveolar remodeling are key factors of morphological variation in the dmanisi mandibles. *PNAS* 110(43): 17278-17283. <https://doi.org/10.1073/pnas.1316052110>
- Magnin, L. (2016). Arqueología del parque nacional Bosques Petrificados de Jaramillo. Nuevos datos para un estudio regional (Santa Cruz, Argentina). *Actas del XIX Congreso Nacional de Arqueología Argentina, San Miguel de Tucumán*. Serie monográfica y didáctica 54, 749-754.
- Magnin, L., Miotti, L., Hermo, D. (2018). Perspectivas del estudio arqueológico del paisaje en el parque nacional Bosques Petrificados de Jaramillo (Santa Cruz, Argentina). *Revista del Museo de La Plata* 3(1), 132-147. <https://publicaciones.fcnym.unlp.edu.ar/rmlp/article/view/2206>

Atencio, J; Magnin, L; Blanco, L. (2020). Bio-archaeological analysis of a tooth from a human burial. Summit of Cerro Madre e Hija (Santa Cruz, Argentina). *Revista Chilena de Antropología* 41: 70-78. <https://doi.org/10.5354/0719-1472.2020.57903>



- Miotti, L. (2003). Patagonia: a paradox for building images of the first Americans during the Pleistocene/Holocene transition. *Quaternary International*, 109–110, 147-173.
[https://doi.org/10.1016/S1040-6182\(02\)00210-0](https://doi.org/10.1016/S1040-6182(02)00210-0)
- Miotti, L., Salemme, M. (2004). Poblamiento, movilidad y territorios entre las sociedades cazadoras-recolectoras de Patagonia. *Complutum*, 15, 177-206.
<https://revistas.ucm.es/index.php/CMPL/article/view/CMPL0404110177A>
- Nelson, S.J., Ash, M.M. (2010). *Wheeler's dental anatomy, physiology and occlusion*. WB Saunders.
- Peral, D. et.al. (2013). Hipercementosis radicular en un individuo de la necrópolis islámica de Pontezuelas (Badajoz), pp. 1-21. *V Jornada Científica de la Asociación Española de Antropología y Odontología Forense*.
- Pineda Paz, C. (2004). *Atlas de anatomía dental*. SAM.
- Scott, G.R. (2008). Dental morphology. En: Katzenberg, M.A., Saunders, S.R. (eds). *Biological anthropology of the human skeleton*, pp. 265-298. Wiley-Liss.
- Scott, G.R. (2012). Dental anthropology, pp. 1-8. *Encyclopedia of global archaeology*. Springer-Verlag.
- Steele, D.G., Bramblett, C.A. (1988). *The anatomy and biology of the human skeleton*. Texas A & M University Press.
- White, T.D., Folkens, P.A. (2005). *The human bone manual*. Elsevier Academic Press.

Recibido el 2 ene 2020

Aceptado el 15 may 2020