



DR. PABLO PINEYRO (Orcid ID : 0000-0002-0884-7762)

DR. MARIA GABRIELA ECHEVERRIA (Orcid ID : 0000-0001-9644-3583)

Article type : Rapid Communication

First detection and genetic characterization of porcine circovirus type 3 (PCV3) in Argentina and its association with reproductive failure

M.S. Serena ^{1,2}, J.A. Cappuccio ^{2,3}, H. Barrales ⁴, G.E. Metz ^{1,2}, C.G. Aspitia ^{1,5}, M. I. Lozada ⁴, C.J. Perfumo ⁵, M.A. Quiroga ⁵, P. Piñeyro ^{6*}, M.G. Echeverría ^{1,2}

¹ Laboratorio de Virología, Facultad de Ciencias Veterinarias, Universidad Nacional de La Plata, La Plata, Argentina

² Consejo Nacional de Ciencia y Tecnología, CONICET, Argentina

³ Grupo Sanidad Animal, EEA Marcos Juarez, INTA. Córdoba, Argentina

⁴ Cátedra de Medicina Porcina, Facultad de Ciencias Veterinarias, Universidad Nacional de La Plata

*Corresponding author:
Veterinary Diagnostic Laboratory
1850 Christensen Drive
Iowa State University, Ames, Iowa 50011
Phone: 1-515-449-2358. E-mail: pablop@iastate.edu

This article has been accepted for publication and undergone full peer review but has not been through the copyediting, typesetting, pagination and proofreading process, which may lead to differences between this version and the [Version of Record](#). Please cite this article as [doi: 10.1111/tbed.13893](https://doi.org/10.1111/tbed.13893)

This article is protected by copyright. All rights reserved

⁵ Laboratorio de Patología Especial Veterinaria, Facultad de Ciencias Veterinarias, Universidad Nacional de La Plata

⁶ Department of Veterinary Diagnostic and Production Animal Medicine, College of Veterinary Medicine, Iowa State University, Ames, Iowa, USA

Accepted Article

ABSTRACT

Porcine circovirus type 3 (PCV3) is considered a new circovirus and since its first description has been widely reported in most of the swine producing countries. Multisystemic inflammation and reproductive failure are consistent and concerning issues associated with PCV3 infection. This report describes the clinical and pathological features of a chronic reproductive disorder in a swine-herd in Argentina associated with the presence of PCV3. Mummified (n=42) and stillborn piglets (n=20) from a case of chronic reproductive disorder (Study A) and mummified and stillborn piglets (n=141) from normal deliveries (Study B) were retrospectively assessed for the presence of multiple reproductive pathogens (PCV3, PCV2, ADV, PPV, *Leptospira* spp., and *Brucella* spp). On study, A PCV3 and PPV were detected in 15 and 8 pools respectively with a coinfection rate of 100% in all PPV positive cases. Three out of 131 fetuses from three different sows from Study B were positive only for PCV3. Histological evaluation of hearts from stillborn also showed lesions similar to those previously described in the literature for PCV3-reproductive disease. Partial genome of PCV3 was amplified and phylogenetic analysis showed that strains of Study A and B clustered within the PCV3a and PCV3b clades respectively. This study demonstrates, for the first time, the PCV3 has been circulating in Argentina at least since 2016 and its potential role in reproductive disorders. Further studies are warranted to determine the role of PCV3 in the reproductive disease complex and its prevalence in the swine industry in Argentina.

KEYWORDS: Porcine Circovirus 3, reproductive failure, genetic characterization, Argentina

1. INTRODUCTION

Porcine circovirus (PCV) is a small, circular, non-enveloped, single-stranded DNA virus belonging to the family *Circoviridae*, genus *Circovirus*. The genome encodes two major open reading frames (ORFs): ORF1 encodes a replication-associated protein (rep), while ORF2 encodes the viral capsid (cap) protein that determines the antigenic characteristics of the virus (Mankertz et al., 2004). Until recently, only two species of circovirus had been reported in pigs (Allan & Ellis, 2000). Porcine circovirus 1 (PCV1) was first identified as a cell culture contaminant and is considered non-pathogenic in pigs. In contrast, PCV2 is a ubiquitous, economically significant pathogen that has been associated with a broad range of clinical presentations, including PCV2 systemic disease (PCV2-SD), respiratory and enteric disease, reproductive failure, and porcine dermatitis and nephropathy syndrome (PDNS) (Segalés, 2012). In 2015, a new circovirus species named porcine circovirus type 3 (PCV3), was detected for the first time in the United States (US). The first clinical reports included increased reproductive failures (mummies, spontaneous abortions, and stillbirths) and sows with lesions consistent with dermatitis and nephropathy-like syndrome (PDNS) (Palinski et al., 2017) as well as pigs with multisystemic inflammation (Li et al., 2018; Phan et al., 2016).

The first PCV3 description revealed that it has the same genomic organization as PCV2 but is genetically distinct. PCV3 is a circular, single-stranded DNA virus with a size of 2000 nt that contains two major ORFs, similar to PCV2. The Cap and Rep proteins of PCV3 share only 26% and 48% amino acid (aa) identity compared to PCV2 (Palinski et al., 2017). The first phylogenetic studies proposed that the PCV3 identified in the US was related to canine circovirus (CanineCV) (Palinski et al., 2017). Additional phylogenetic studies proposed that this new PCV was closely related to clade 1 bat circoviruses (Fu et al., 2018) and also suggested that CanineCV and clade 2 bat circovirus may share a common ancestor within the cluster containing PCV1 and PCV2 (Li et al., 2018). Phylogenetic analysis of contemporary and retrospective samples has shown a consistent mutation in certain amino acids of the Cap protein that could be used as potential molecular markers to classify PCV3 into two genotypes named PCV3a and PCV3b and five sub-genotypes called PCV3a-1, PCV3a-2, PCV3a-3, PCV3b-1, and PCV3b-2 (Li et al., 2018).

Since its original report in the US (Palinski et al., 2017), PCV3 has been described in most swine-producing countries, including China (Wen et al., 2018), Korea (Kim et al., 2018), Thailand

(Kedkovid et al., 2018), and many European countries including Poland, Italy, Spain, Denmark, Germany, Sweden, and the United Kingdom (Collins, McKillen, & Allan, 2017; Faccini et al., 2017; Fux et al., 2018). In South America, this virus has been described in Brazil (Saraiva et al., 2019) and Colombia thus far (Vargas-Bermudez, Campos, Bonil, Mogollon, & Jaime, 2019). Reported clinical signs associated with PCV3 infection vary in the literature and include respiratory and enteric disease and neurological disorders; however, multisystemic inflammation and reproductive failure are consistent and concerning issues associated with PCV3 infection (Palinski et al., 2017; Phan et al., 2016). Although the pathogenesis of PCV3 remains unclear, recent studies have demonstrated the presence of PCV3 nucleic acid by *in situ* hybridization in clinical samples, providing substantial evidence that supports the role of PCV3 in systemic inflammation and reproductive failure (Arruda et al., 2019)

Since its first description, there have been numerous advances regarding the molecular epidemiology and diagnosis of PCV3. However, few reports have been focused on the detection of PCV3 and its association with clinical presentation and lesions (Arruda et al., 2019; Kim et al., 2018; Palinski et al., 2017; Phan et al., 2016). This report describe the genetic characterization of porcine circovirus type 3 (PCV3) in Argentina and its association with reproductive failure

2. MATERIAL AND METHODS

Mummified and stillborn piglets from a case of chronic reproductive failure in a commercial sow farm (Study A) and a retrospective assessment of stillbirths and mummies from normal deliveries (Study B) were evaluated for the presence of PCV3.

Since 2016, a 600 sows, farrow-to-finish farm located in the Santa Fe Province, Argentina reported a chronic reproductive disorder characterized by increase in abortions, mummified fetuses and stillborn pigs (Study A). During the 2017 production cycle, reproductive records were below the normal values in comparison with five reference farms with the same genetic source and belonging to the same management system. The breeding stock comprised 27% of first-parity sows, 21% of second parity sows, 45% of third to fifth parity sows, and 7% of sows with more than six parities. During the acclimation period, the gilts were vaccinated twice with PCV2, porcine parvovirus (PPV), *Leptospira* spp., and *Erysipelothrix rhusiopathiae*. This farm is included in the national control program of

disease and hold a free status for Aujeszky's disease virus (ADV) as well as the porcine reproductive and respiratory syndrome virus (PRRSV). Fresh samples were collected from mummified (n=42) and stillborn piglets (n=20) from 16 sows with reproductive problems. The fetuses were placed in individual sterile bags and preserved at 4°C until they arrived at the laboratory (Laboratorio de Virología, FCV-UNLP). From each fetus, a fresh tissue-pool that included tonsil, lung, liver, heart, and kidney was collected and processed for PCV3 polymerase chain reaction (PCR) detection. The presence of other significant reproductive pathogens, including PCV2, ADV, PPV, *Leptospira spp.*, and *Brucella spp.*, was also evaluated by PCR.

A retrospective evaluation (Study B) of PCV3 was also conducted using fetal samples collected in 2016 (Serena et al., 2019). Briefly, 131 mummified and stillborn piglets belonging to 74 sows were collected from a 2500-sow, multi-site farrow-to-finish farm located in the Santa Fe Province Argentina. The reproductive parameters of this farm were within normal limits, and the farm was free of significant reproductive pathogens, including *Brucella spp.*, ADV, PRRVS, or classical swine fever virus. Stillbirths and mummies were collected from randomly selected normal deliveries (<2% of stillbirths and >11 born alive) (Serena et al., 2019).

Briefly, for viral PCR detection, the total DNA was extracted from sample homogenates using a Wizard Genomic DNA Purification Kit (Promega-USA) according to the manufacturer's instructions. The extracted DNA was pooled per sow and preserved at -20°C. For PCV3 detection by PCR, previously described specific primers targeting the ORF2 (Wen et al., 2018) were used with the following cycling conditions: pre-denaturation at 94°C for 5 min, followed by 35 cycles of 95°C for 60 s, 62°C for 60 s, 72°C for 60 s, and a final elongation step at 72°C for 7 min. DNA from positive samples was used to amplify the partial ORF1 gene (Wen et al., 2018). The PCR products were purified according to the manufacturer's protocols using Wizard SV Gel and a PCR Clean-Up System (Promega, Madison, WI, USA). Sequencing reactions were performed in both strands using an automated sequencer (ABI3730xl Genetic Analyzer, Applied Biosystems, USA) and Macrogen support.

The sequences were edited using BioEdit software, version 7.2.1. In total, 36 PCV3 sequences from different geographical locations were downloaded from GenBank (<https://www.ncbi.nlm.nih.gov/genbank/> accession date 04/22/2020). Partial sequences of ORF1 were

aligned in the MEGA program, version 7.0, using the ClustalW algorithm. The phylogenetic trees were constructed using the MEGA program with the Maximum Likelihood method, which is based on the Kimura 2-parameter model.

Thirteen hearts from stillborn pigs (Study A) were processed for histopathology evaluation. The samples were fixed in 10% neutral-buffered formalin, embedded in paraffin, and stained with hematoxylin and eosin and Van Giesson stains.

3. RESULTS AND DISCUSSION

On study A, based on the historic reproductive data evaluated during the last two years previous to this study, amongst the reproductive disorders, the presence of mummified piglets from different ages of gestation were the most important findings. In addition, in cases with mummified fetus the proportion of single and multiple mummies per sow was 28% and 35%, respectively. No dermatological lesions or clinical signs resembling PDNS were reported amongst sows that presented with reproductive failure. All samples evaluated were negative for PCV2, ADV, *Leptospira spp.*, and *Brucella spp.* Out of the 16 evaluated litters, PPV and PCV3 were detected in 8 and 15 pools, respectively. Interestingly, all PPV-positive litters were also positive for PCV3. The samples from a retrospective study (Study B) were analyzed by PCR to detect PCV3, and 3 out of 131 fetuses from three different sows were positive. In addition, all these samples were classified as stillborn and tested negative for PPV, PCV2, ADV, *Leptospira spp.*, and *Brucella spp.*

Thus, this is the first report of PCV3 infection associated with reproductive failure in Argentina. A wide spectrum of clinical signs are associated with PCV3 infection, including reproductive failure, multisystemic inflammation, and PDNS-like lesions (Klaumann et al., 2018). Common manifestations of PCV3 reproductive disorders include an increase in the abortion rate, an increase in the proportion of mummies and stillborn piglets, and a reduction of the conception rate (Faccini et al., 2017; Palinski et al., 2017). The reproductive performance of the affected farm was compared with five reference farms belonging to the same genetic system, with the same husbandry, and within the same geographical region, and production period. This comparison showed that the affected farm had an increase in the percentage of mummies (7% vs. 3.2%) and stillborn pigs (7.2% vs. 4.2%) and a decrease in the number of total pigs born alive (86% vs. 92%). No clinical correlation between reproductive failures and gestational age or sow parity was observed following an evaluation

of all reproductive records. Previous reports of reproductive failures associated with PCV3 showed that the abortion rate increased by approximately 10% (Kim et al., 2018; Palinski et al., 2017): the stillbirths and mummies varied from 3.5 to 5%, and there was an increase in embryonic losses along with a reduction in both the conception rate by 0.6% and the farrowing rate by 5 to 8% (Arruda et al., 2019; Palinski et al., 2017).

Previous studies have shown that the most common lesions observed in fetuses and mummies associated with PCV3 reproductive failure are consistent with lymphoplasmacytic myocarditis (Arruda et al., 2019). The histological evaluation of hearts from 13 stillborn pigs revealed that five PCV3-positive piglets presented marked lymphoplasmacytic and histiocytic perivasculitis in subepicardium and myocardium associated with marked interstitial fibrosis, edema, and areas of hemorrhage. Myocardial lesions varied from individual myocardiocytes with swollen cytoplasm to coagulative necrosis, myocytolysis, and dystrophic mineralization (Figure 1). No other vascular changes were observed in the rest of the tissues that were evaluated. Other viruses, such as PRRSV and classical swine fever virus, can also produce vasculitis (Phan et al., 2016); however, none of these viruses are currently circulating in Argentina. Common causes of vasculitis prevalent in Argentina, such as PCV2 and ADV, were ruled out by specific PCR. In this study, it was not possible to establish a clear causal relationship between PCV3 and vasculitis by complementary studies, such as immunohistochemistry or *in situ* hybridization analysis. However, the original histopathological evaluation and the presence of these myocardial lesions redirected the etiological diagnosis to search for PCV3. Although the causative role of PCV3 in these types of lesions is still unknown, previous reports (Arruda et al., 2019; Phan et al., 2016) have demonstrated the presence of viral mRNA in the tunica media of affected vessels and thus provided some evidence of the causative role of PCV3 in these neonatal lesions.

In this study, PCV3 was identified in mummies and stillborn piglets as either a single infection or a co-infection along with PPV. Several other viruses, including PCV2, PRRSV, and PPV, have been reported to be associated with PCV3 infection (Ouyang, Zhang, Liu, & Ren, 2019). The reported coinfection rate of PCV3 and PCV2 varies from 12.5 - 70% (Klaumann et al., 2018). Although PCV2 is endemic in Argentina and most farms use PCV2 vaccines, no PCV3/2 co-infections were detected

in this study. In addition, PRRSV circulation has not yet been reported in the swine production industry in Argentina.

PPV is probably the most important cause of reproductive failure in pigs worldwide. Seven genotypes have been identified (PPV1 to PPV7) (Cotmore et al., 2014; Streck, Canal, & Truyen, 2015) with PPV1 as the only clinically relevant detected in Argentina thus far (Serena et al., 2019). Clinically, PPV infection in naive sow's results in litters delivered with a combination of normal pigs and mummified fetuses. PPV infection after completion of organogenesis results in mummified fetuses of different gestational ages in the same litter (Truyen & Streck, 2019). Although in this study (Study A), 50% of sows had a PPV/PCV3 coinfection, 28% of litters on the affected farm contained a single mummy, which is an uncommon feature of PPV infection. PPV and PCV2 coinfection can exacerbate this clinical presentation (Segalés, Allan, & Domingo, 2019), however but the role of PCV3 and PPV1 coinfection is still unknown.

The partial genome of PCV3 was amplified from 2 out of 15 positive pools in Study A (MT919228 and MT919229) and in 1 of the 3 positive pigs in Study B (MT919230). The genotypic classification of the three PCV3 strains detected in this study was based on a comparison with 36 PCV3 reference sequences representing the PCV3a and PCV3b clades (Li et al., 2018; Sun et al., 2019). The phylogenetic analysis of the partial ORF1 gene sequences revealed that both strains (MT919228 and MT919229) detected in Study A (chronic reproductive failure) had a 99.81% homology, were clustered within the PCV3a clade, and showed a closest relation with strains reported from the US (99.5%) (KX966193) and China (99.4%) (KY075989). In contrast, the strain (MT919230) detected in Study B (retrospective study) belonged to the PCV3b clade and showed a 99.81% homology with strains reported from the US (KT869077), South Korea (MF611876 and MF611877), China (KY075986 and MG250180), and Brazil (MF079253). The percentage of nucleotide identity between sequences from both studies varied from 99.42 to 99.61%, and their homology with the reference strains ranged from 97.68 to 99.81% (Figure 2).

The phylogenetic analysis based on the amino acid sequence showed no changes in clustering of the three strains detected in this study (data not shown). A previous structural analysis of the Rep showed two variant sequences of amino acids 122 (S and A) (Sun et al., 2019). Studies on genetic evolution have suggested that the PCV3a and PCV3b clades have very specific amino acid

combinations on the Rep and Cap proteins. Thus, Rep (A^{122th}) and Cap (^{24th}VRRK^{27th} or ^{24th}LRRR^{27th} or ^{24th}VRRR^{27th}) are representative sequences of the PCV3a clade, while Rep (S^{122th}) and Cap (^{24th}ARRK^{27th}, ^{24th}VRRK^{27th}, and ^{24th}ARRR^{27th}) represent the PCV3b clade (Sun et al., 2019). Both strains detected in Study A (chronic reproductive failure) were Rep (A^{122th}), while the strain identified in Study B (retrospective study) was Rep (S^{122th}). Even though this study only analyzed the ORF1, the clade classification based on A122S aa yielded the same clustering results, which suggests that Rep 122 aa is important for PCV3 genotype classification and the Cap aa analysis could be more important when determining the origin of sub-genotype classification.

The possible origin of PCV3 has been widely evaluated; despite the similar genomic organization, PCV3 is only distantly related to other circoviruses. However, it has been postulated to have a certain relationship with bat and avian circoviruses (Franzo et al., 2019). Previous studies on viral evolution propose that an analysis of the Rep protein should be conducted to determine the origin of porcine circoviruses (Li et al., 2018). Thus, in this study, the three sequences appeared to be more related with bat circovirus strains. Despite a potential cross-species jump, PCV3 circulation was detected in swine populations in retrospective samples long before its first description in 2016 (Palinski et al., 2017). Several retrospective studies have shown the presence of PCV3 in China since 1966, in Europe since 1993, and in Brazil and Thailand since 2006 (Collins et al., 2017; Faccini et al., 2017; Fux et al., 2018; Kedkovid et al., 2018; Saraiva et al., 2019; Wen et al., 2018). The samples in the retrospective portion of this study were collected in 2016, long before the first report of PCV3 (Palinski et al., 2017).

In conclusion, this report describes the presence of PCV3 as a single or coinfection with PPV in a case of chronic reproductive failure characterized by increase abortions, mummies, and stillborn piglets in gilts and sows in Argentina. Histological lesions in aborted fetuses were similar to those previously associated with PCV3 reproductive disease. A retrospective study also showed that PCV3 was circulating subclinically in Argentina since at least since 2016. A phylogenetic analysis indicated that in Argentina, PCV3 is represented by at least two clades (PCV3a and PCV3b) and demonstrates close genetic similarity with other PCV3 strains reported worldwide. Further studies are warranted to determine the role of PCV3 in the reproductive disease complex and its prevalence in the swine

industry in Argentina, as well as a full genotypic characterization to evaluate the genetic diversity and its potential association with different pathotypes.

ACKNOWLEDGEMENTS

This work was supported by grants V251 and V260, National University of La Plata, Argentina; PICT 2015-1232, PICT 2016-1380 and PICT 2017-1075, Science and Technology Agency, Argentina and Grants I003 and I103 INTA.

CONFLICT OF INTEREST

The authors declare no conflict of interest.

DATA AVAILABILITY STATEMENT

The nucleotide data that generated in the present study and support the findings of this study are openly available in NCBI (<https://www.ncbi.nlm.nih.gov>).

4. REFERENCES

- Allan, G. M., & Ellis, J. A. (2000). Porcine Circoviruses: A Review. *Journal of Veterinary Diagnostic Investigation*, 12(1), 3-14. doi:10.1177/104063870001200102
- Arruda, B., Piñeyro, P., Derscheid, R., Hause, B., Byers, E., Dion, K., . . . Schwartz, K. (2019). PCV3-associated disease in the United States swine herd. *Emerging Microbes & Infections*, 8(1), 684-698. doi:10.1080/22221751.2019.1613176
- Collins, P. J., McKillen, J., & Allan, G. (2017). Porcine circovirus type 3 in the UK. *Veterinary Record*, 181(22), 599-599. doi:10.1136/vr.j5505
- Cotmore, S. F., Agbandje-McKenna, M., Chiorini, J. A., Mukha, D. V., Pintel, D. J., Qiu, J., . . . Davison, A. J. (2014). The family Parvoviridae. *Archives of Virology*, 159(5), 1239-1247. doi:10.1007/s00705-013-1914-1
- Faccini, S., Barbieri, I., Gilioli, A., Sala, G., Gibelli, L. R., Moreno, A., . . . Nigrelli, A. (2017). Detection and genetic characterization of Porcine circovirus type 3 in Italy. *Transboundary and Emerging Diseases*, 64(6), 1661-1664. doi:10.1111/tbed.12714
- Franzo, G., He, W., Correa-Fiz, F., Li, G., Legnardi, M., Su, S., & Segalés, J. (2019). A Shift in Porcine Circovirus 3 (PCV-3) History Paradigm: Phylodynamic Analyses Reveal an Ancient Origin and Prolonged Undetected Circulation in the Worldwide Swine Population. *Advanced Science*, 6(22), 1901004. doi:10.1002/advs.201901004
- Fu, X., Fang, B., Ma, J., Liu, Y., Bu, D., Zhou, P., . . . Zhang, G. (2018). Insights into the epidemic characteristics and evolutionary history of the novel porcine circovirus type 3 in southern China. *Transboundary and Emerging Diseases*, 65(2), e296-e303. doi:10.1111/tbed.12752
- Fux, R., Söckler, C., Link, E. K., Renken, C., Krejci, R., Sutter, G., . . . Eddicks, M. (2018). Full genome characterization of porcine circovirus type 3 isolates reveals the existence of two distinct groups of virus strains. *Virology Journal*, 15(1), 25. doi:10.1186/s12985-018-0929-3
- Kedkovid, R., Woonwong, Y., Arunorat, J., Sirisereewan, C., Sangpratum, N., Lumyai, M., . . . Thanawongnuwech, R. (2018). Porcine circovirus type 3 (PCV3) infection in grower pigs from a Thai farm suffering from porcine respiratory disease complex (PRDC). *Veterinary Microbiology*, 215, 71-76. doi:https://doi.org/10.1016/j.vetmic.2018.01.004

Kim, S.-H., Park, J.-Y., Jung, J.-Y., Kim, H.-Y., Park, Y.-R., Lee, K.-K., . . . Park, C.-K. (2018).

Detection and genetic characterization of porcine circovirus 3 from aborted fetuses and pigs with respiratory disease in Korea. *J Vet Sci*, *19*(5), 721-724.

Klaumann, F., Correa-Fiz, F., Franzo, G., Sibila, M., Núñez, J. I., & Segalés, J. (2018). Current Knowledge on Porcine circovirus 3 (PCV-3): A Novel Virus With a Yet Unknown Impact on the Swine Industry. *Frontiers in Veterinary Science*, *5*(315). doi:10.3389/fvets.2018.00315

Li, G., He, W., Zhu, H., Bi, Y., Wang, R., Xing, G., . . . Su, S. (2018). Origin, Genetic Diversity, and Evolutionary Dynamics of Novel Porcine Circovirus 3. *Advanced Science*, *5*(9), 1800275. doi:10.1002/advs.201800275

Mankertz, A., Caliskan, R., Hattermann, K., Hillenbrand, B., Kurzendoerfer, P., Mueller, B., . . . Finsterbusch, T. (2004). Molecular biology of Porcine circovirus: analyses of gene expression and viral replication. *Vet Microbiol*, *98*(2), 81-88. doi:10.1016/j.vetmic.2003.10.014

Ouyang, T., Zhang, X., Liu, X., & Ren, L. (2019). Co-Infection of Swine with Porcine Circovirus Type 2 and Other Swine Viruses. *Viruses*, *11*(2). doi:10.3390/v11020185

Palinski, R., Piñeyro, P., Shang, P., Yuan, F., Guo, R., Fang, Y., . . . Hause, B. M. (2017). A Novel Porcine Circovirus Distantly Related to Known Circoviruses Is Associated with Porcine Dermatitis and Nephropathy Syndrome and Reproductive Failure. *J Virol*, *91*(1). doi:10.1128/JVI.01879-16

Phan, T. G., Giannitti, F., Rossow, S., Marthaler, D., Knutson, T. P., Li, L., . . . Delwart, E. (2016). Detection of a novel circovirus PCV3 in pigs with cardiac and multi-systemic inflammation. *Virol J*, *13*(1), 184. doi:10.1186/s12985-016-0642-z

Saraiva, G. L., Vidigal, P. M. P., Assao, V. S., Fajardo, M. L. M., Loreto, A. N. S., Fietto, J. L. R., . . . Silva-Junior, A. (2019). Retrospective Detection and Genetic Characterization of Porcine circovirus 3 (PCV3) Strains Identified between 2006 and 2007 in Brazil. *Viruses*, *11*(3). doi:10.3390/v11030201

Segalés, J. (2012). Porcine circovirus type 2 (PCV2) infections: Clinical signs, pathology and laboratory diagnosis. *Virus Research*, *164*(1), 10-19. doi:https://doi.org/10.1016/j.virusres.2011.10.007

- Segalés, J., Allan, G. M., & Domingo, M. (2019). Circoviruses. In J. J. Zimmerman, L. A. Karriker, A. Ramirez, K. J. Schwartz, G. W. Stevenson, & J. Zhang (Eds.), *Diseases of Swine* (pp. 473-487).
- Serena, M. S., Cappuccio, J. A., Metz, G. E., Aspitia, C. G., Dibárbora, M., Calderón, M. G., & Echeverría, M. G. (2019). Detection and molecular characterization of porcine parvovirus in fetal tissues from sows without reproductive failure in Argentina. *Heliyon*, 5(11), e02874. doi:<https://doi.org/10.1016/j.heliyon.2019.e02874>
- Streck, A. F., Canal, C. W., & Truyen, U. (2015). Molecular epidemiology and evolution of porcine parvoviruses. *Infection, Genetics and Evolution*, 36, 300-306. doi:<https://doi.org/10.1016/j.meegid.2015.10.007>
- Sun, W., Wang, W., Xin, J., Cao, L., Zhuang, X., Zhang, C., . . . Jin, N. (2019). An epidemiological investigation of porcine circovirus 3 infection in dogs in the Guangxi Province from 2015 to 2017, China. *Virus Research*, 270, 197663. doi:<https://doi.org/10.1016/j.virusres.2019.197663>
- Truyen, U., & Streck, A. F. (2019). Parvoviruses. In J. J. Zimmerman, L. A. Karriker, A. Ramirez, K. J. Schwartz, G. W. Stevenson, & J. Zhang (Eds.), *Diseases of Swine* (pp. 611-621).
- Vargas-Bermudez, D. S., Campos, F. S., Bonil, L., Mogollon, D., & Jaime, J. (2019). First detection of porcine circovirus type 3 in Colombia and the complete genome sequence demonstrates the circulation of PCV3a1 and PCV3a2. *Veterinary Medicine and Science*, 5(2), 182-188. doi:[10.1002/vms3.155](https://doi.org/10.1002/vms3.155)
- Wen, S., Sun, W., Li, Z., Zhuang, X., Zhao, G., Xie, C., . . . Jin, N. (2018). The detection of porcine circovirus 3 in Guangxi, China. *Transboundary and Emerging Diseases*, 65(1), 27-31. doi:[10.1111/tbed.12754](https://doi.org/10.1111/tbed.12754)

Figures legends:

Figure 1: The histopathological study of hearts from stillborn (Study A) revealed a marked mononuclear and histiocytic perivascularitis in subepicardium and myocardium in association with a marked interstitial fibrosis, edema and areas of hemorrhage. H&E (a and b); Van Giesson (c and d).

Figure 2: Phylogenetic tree obtained by the Maximum Likelihood method based on the Kimura 2-parameter model and bootstrap analyses using 1000 replicates from the analysis of the partial ORF1 gene amplified by polymerase chain reaction of Argentinean and PCV3 referent strains. Sequence highlighted with dots represent strain detected on study A and B.

Figure 1

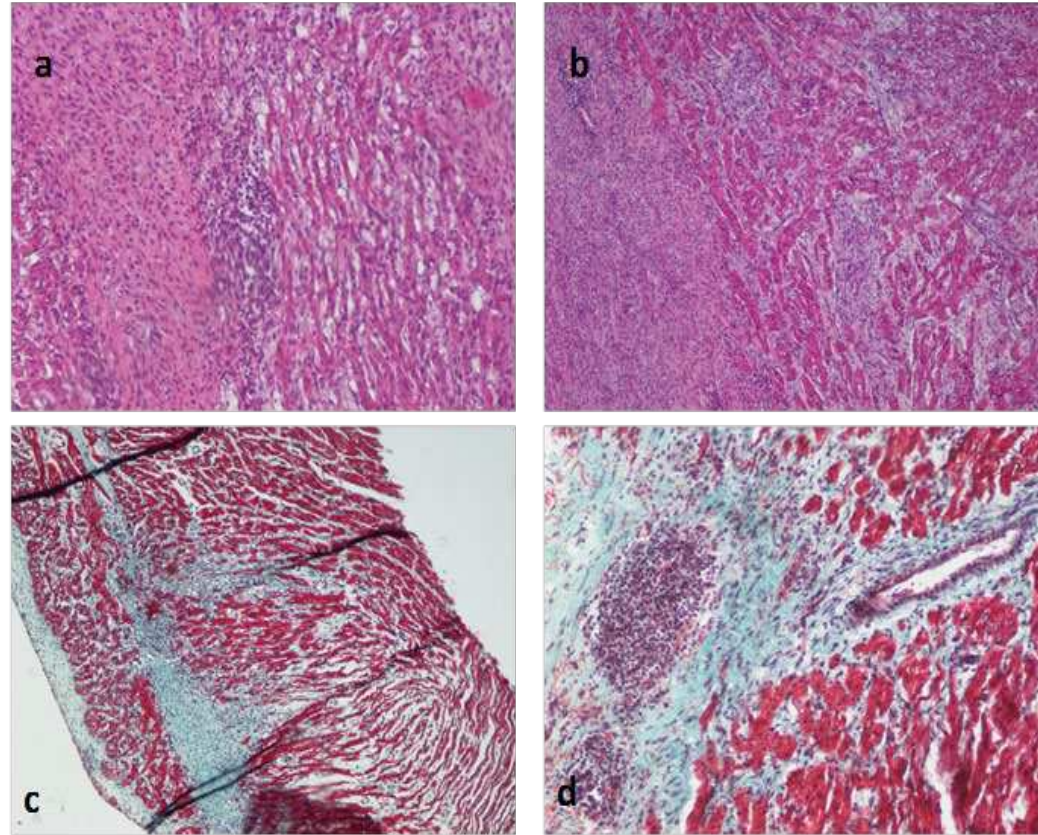


Figure 1

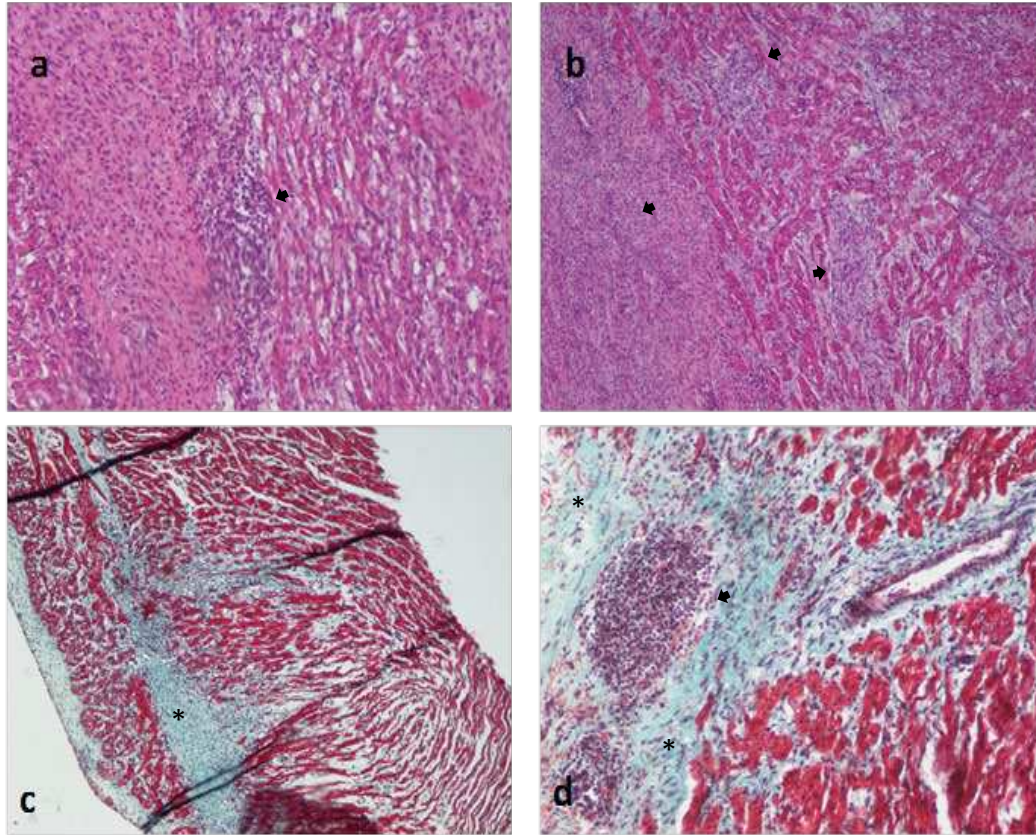


Figure 2

