

**UCC Library and UCC researchers have made this item openly available.
Please [let us know](#) how this has helped you. Thanks!**

Title	CALR-positive essential thrombocythaemia preceded by immune thrombocytopaenia
Author(s)	Barrett, A.; Cahill, Mary R.
Publication date	2021
Original citation	Barrett, A. and Cahill, M. R. (2021) 'CALR-positive essential thrombocythaemia preceded by immune thrombocytopaenia', Irish Medical Journal, 114(4), P338 (4pp). Available at: http://imj.ie/calr-positive-essential-thrombocythaemia-preceded-by-immune-thrombocytopaenia/ (Accessed: 23 July 2021)
Type of publication	Article (peer-reviewed)
Link to publisher's version	http://imj.ie/calr-positive-essential-thrombocythaemia-preceded-by-immune-thrombocytopaenia/ https://imj.ie/irish-medical-journal-april-2021-vol-114-no-4/ Access to the full text of the published version may require a subscription.
Rights	© 2021, Irish Medical Journal. All rights reserved.
Item downloaded from	http://hdl.handle.net/10468/11588

Downloaded on 2021-11-27T15:03:59Z

CALR-positive Essential Thrombocythaemia Preceded by Immune Thrombocytopaenia

A. Barrett, M.R. Cahill

Department of Haematology, Cork University Hospital.

Abstract

Presentation

The patient initially presented with gum bleeding and a petechial rash.

Diagnosis

The patient was found to be severely thrombocytopaenic and bone marrow biopsy showed a marked excess of megakaryocytes consistent with a diagnosis of immune thrombocytopaenia (ITP). She underwent splenectomy. Seven years following splenectomy, her platelet count began to rise again, and repeat bone marrow sampling revealed an increase in megakaryocytes with evidence of clustering. On further testing the calreticulin (CALR) exon 9 variant was found and a diagnosis of essential thrombocythaemia (ET) was made.

Treatment

Thromboprophylaxis and cytoreductive therapy (hydroxyurea) were initiated following ET diagnosis.

Discussion

Possible mechanisms of ET (platelet excess) following ITP (platelet deficiency) include the known associations of autoimmune conditions and malignancy and the effects of immunosuppression and splenectomy in tumorigenesis. To our knowledge, this is the first recorded case of ITP preceding later development of CALR- positive ET.

Introduction

ITP is an autoimmune condition characterised by peripheral destruction of platelets.¹ ET is one of the myeloproliferative neoplasms (MPNs) and is characterised by overproduction of platelets, leading to increased risk of thrombosis. Greater than 95% of ET cases are associated with the Janus kinase (*JAK*)-2, *CALR* or myeloproliferative leukaemia virus oncogene (*MPL*) gene mutations.²

Case Report

A 57-year-old female presented in 2004 with a history of gum bleeding and a petechial rash on a background of hypothyroidism. A full blood count (FBC) performed by her General Practitioner revealed a platelet count of $20 \times 10^9/l$ with a haemoglobin (Hb) of 147g/l and white cell count (WCC) of $7.9 \times 10^9/l$. Her blood film showed thrombocytopenia only and her renal and liver function were within normal limits. Her coagulation, serum protein electrophoresis, haematinic, virology and autoimmune screen were normal. Lactate dehydrogenase (LDH) levels were elevated at 596 units/l (normal value 220-450 units/l). Bone marrow biopsy showed a marked excess of megakaryocytes consistent with a diagnosis of ITP. She was commenced on high-dose prednisolone therapy which led to rapid normalisation of her platelet count. Following steroid withdrawal, she relapsed and was referred for splenectomy. Postoperatively she had a significant rebound thrombocytosis with a platelet count increase to $1237 \times 10^9/l$. Repeat bone marrow sampling showed normal megakaryocytes and increased erythropoiesis consistent with a recovering marrow.

Seven years following splenectomy, her platelet count began to rise (see figure 1). *JAK-2* mutational analysis was negative. She was initially started on aspirin but following development of paroxysmal atrial fibrillation (PAF) this was switched to apixaban. Repeat bone marrow sampling following an episode of significant haematoma in her thigh showed an increase in megakaryocytes with evidence of clustering. The *CALR* exon 9 variant was found, confirming a diagnosis of ET. Cytoreductive therapy (hydroxycarbamide) has been commenced.

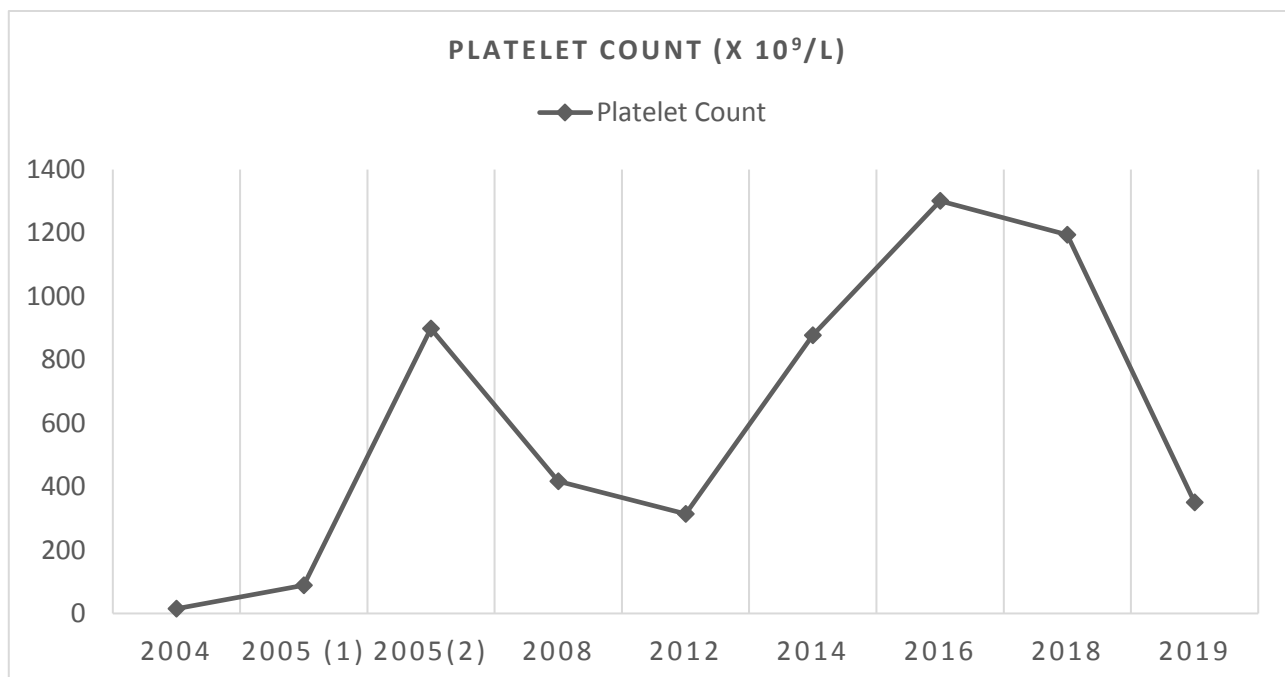


Figure 1: Changes in platelet count during disease course.

Discussion

To our knowledge, this is the first time a patient has developed ET caused by the *CALR* mutation following initial ITP diagnosis. Three patients have previously been described with initial ITP and then ET with an associated *JAK2* mutation.^{3,4,5}

A prior history of any autoimmune disease has been shown to be associated with an increased risk of MPN (odds ratio (OR)=1.2; P=0.021).⁶ It is likely that the chronic inflammatory state inherent in an autoimmune condition could contribute to tumorigenesis and thus provoke an MPN. Also, use of multiple immunosuppressants could allow a clone to escape apoptosis and promote malignancy (although less likely in our case, where the patient proceeded relatively rapidly to splenectomy). Finally, there may be a shared genetic susceptibility with autoimmune conditions and cancer that renders an individual predisposed to the development of both.

It is possible that splenectomy, when performed for ITP, may unmask ET by removing the function of the spleen in immune-mediated cellular destruction.⁴ ET has been seen post-splenectomy for non-ITP causes in patients with initially normal blood counts.^{7,8,9}

A key challenge for these patients concerns the diagnosis and management of cytopaenias in the context of both cytoreductive therapy and the potential relapse of ITP. A suggested approach to this is to withhold cytoreductive therapy and treat with immunosuppression, prior to restarting cytoreduction once the platelet count reaches an appropriate threshold.

In summary, this is to our knowledge the first recorded case of ITP preceding later development of *CALR*- positive ET and is illustrative of the complexities of management of patients with concurrent haematological diagnoses.

Declaration of Conflicts of Interest:

The authors have no relevant conflicts of interest to declare.

Corresponding Author:

A. Barrett,
Department of Haematology,
Cork University Hospital.
Email: aibarret@tcd.ie

References:

1. Lambert M, Gernsheimer T. Clinical updates in adult immune thrombocytopenia. *Blood*. 2017;129(21):2829-2835.
2. Chuzi S, Stein B. Essential thrombocythemia: a review of the clinical features, diagnostic challenges, and treatment modalities in the era of molecular discovery. *Leukemia & Lymphoma*. 2017;58(12):2786-2798.
3. Sobas M, Wróbel T, Zduniak K, Podolak-Dawidziak M, Rybka J, Biedroń M et al. Immune Thrombocytopenia and JAK2V617F Positive Essential Thrombocythemia: Literature Review and Case Report. *Case Reports in Hematology*. 2017;2017:1-4.
4. Huang, C., Chen, Y., Liu, J., Ho, H., Li, C. and Chen, C., 2016. JAK2 V617F mutation in immune thrombocytopenia. *Thrombosis Research*, 144, pp.149-151.
5. Caocci G, Atzeni S, Usai M, La Nasa G. Essential thrombocythemia following immune thrombocytopenia with JAK2V617F mutation. *Leukemia Research Reports*. 2018;9:14-15.

6. Kristinsson, S., Landgren, O., Samuelsson, J., Bjorkholm, M. and Goldin, L., 2010. Autoimmunity and the risk of myeloproliferative neoplasms. *Haematologica*, 95(7), pp.1216-1220.
7. Hatsuse, M., Taminishi. Y., Maegawa-Matsui, S., Fuchida, Sl., Inaba, T., Murakami, S., et al., 2019. *Rinsho Ketsueki*, 60(5):387–391.
8. Akcan T, Strati P, Yan M, Idowu M. A Rare Case of Triple-Negative Essential Thrombocythemia in a Young Postsplenectomy Patient: A Diagnostic Challenge. *Case Reports in Hematology*. 2018;2018:1-5.
9. Das R, Kaur U, Garewal G. Splenectomy in a case of splenic vein thrombosis unmasks essential thrombocythemia. *Clinical and Laboratory Haematology*. 2002;24(2):131-133.