



This is a repository copy of *Vaccine-induced immune thrombotic thrombocytopenia (VITT) - update on diagnosis and management considering different resources.*

White Rose Research Online URL for this paper:
<https://eprints.whiterose.ac.uk/180420/>

Version: Published Version

Article:

Greinacher, A., Langer, F., Makris, M. orcid.org/0000-0001-7622-7939 et al. (4 more authors) (2021) Vaccine-induced immune thrombotic thrombocytopenia (VITT) - update on diagnosis and management considering different resources. *Journal of Thrombosis and Haemostasis*. ISSN 1538-7933

<https://doi.org/10.1111/jth.15572>

Reuse

This article is distributed under the terms of the Creative Commons Attribution-NonCommercial (CC BY-NC) licence. This licence allows you to remix, tweak, and build upon this work non-commercially, and any new works must also acknowledge the authors and be non-commercial. You don't have to license any derivative works on the same terms. More information and the full terms of the licence here:
<https://creativecommons.org/licenses/>

Takedown

If you consider content in White Rose Research Online to be in breach of UK law, please notify us by emailing eprints@whiterose.ac.uk including the URL of the record and the reason for the withdrawal request.



eprints@whiterose.ac.uk
<https://eprints.whiterose.ac.uk/>

Vaccine-induced immune thrombotic thrombocytopenia (VITT): Update on diagnosis and management considering different resources

Abstract

Vaccine-induced immune thrombotic thrombocytopenia (VITT) is a rare but severe immunological reaction to the non-replicable adenoviral vector-based COVID-19 vaccines. Extreme activation of platelets and the coagulation system leads to a high risk of death from venous or arterial thrombosis or secondary hemorrhage. Public and clinician awareness has reduced mortality of VITT by nearly 90%. The World Health Organization provided a guideline in July 2021 on diagnosis and management of VITT (also called thrombosis with thrombocytopenia syndrome, or TTS). Since July 2021, new, clinically relevant information has become available. This update has been summarized by the authors in an informal process with recommendations for low resource environments. We provide new available evidence on VITT to empower clinicians to recognize VITT early, then effectively diagnose and treat the disorder to reduce morbidity and mortality. We strongly encourage production of clear management pathways for primary care settings and hospital settings.

where the vaccination campaign was accompanied by a widespread educational program on VITT (<https://www.tga.gov.au/periodic/covid-19-vaccine-weekly-safety-report-23-09-2021>). This indicates that education of the public and health-care workers can substantially lower the burden of the adverse vaccination effect and may support acceptance of the vaccination campaign. The planned roll-out of at least 1 billion doses of the ChAdOx1 COVID-19 vaccine (AstraZeneca) starting in October 2021 to low- and middle-income countries requires urgent availability of educational material.

The World Health Organization (WHO) has developed a comprehensive document guiding diagnosis and management of thrombosis with thrombocytopenia syndrome (TTS) following vaccination to prevent coronavirus disease (COVID-19); interim guidance 19 July 2021 (<https://apps.who.int/iris/bitstream/handle/10665/342999/WHO-2019-nCoV-TTS-2021.1-eng.pdf>). However, since its publication in July, additional new information that is relevant for patient management has become available. To bridge the time required for updating the WHO guidelines, international authors summarized the most up-to-date information in October 2021. The summary was then reviewed by three experts in the field.

We distinguish VITT, which is a unique and specific syndrome, from TTS, which may occur in other disorders such as heparin-induced thrombocytopenia (HIT), severe antiphospholipid syndrome (APS), cancer-associated disseminated intravascular coagulopathy, and thrombotic thrombocytopenic purpura (TTP). VITT most commonly presents with cerebral venous sinus thrombosis, but splanchnic vein thrombosis, deep vein thrombosis and pulmonary embolism (venous thromboembolism [VTE]), and arterial thrombosis are also common, as is involvement of multiple vascular beds.

1 | BACKGROUND

Vaccine-induced immune thrombotic thrombocytopenia (VITT) is a rare but severe immunological reaction to the non-replicable adenoviral vector-based COVID-19 vaccines. Extreme activation of platelets and the coagulation system leads to a high risk of death from venous or arterial thrombosis or secondary hemorrhage. Public and clinician awareness has reduced mortality of VITT from about 50%, in the first case series reported in April 2021 to 22% by June 2021 in the UK and more recently to about 5% observed in Australia,

Manuscript handled by: David Lillicrap

Final decision: David Lillicrap, 22 October 2021

This is an open access article under the terms of the Creative Commons Attribution-NonCommercial License, which permits use, distribution and reproduction in any medium, provided the original work is properly cited and is not used for commercial purposes.

© 2021 The Authors. *Journal of Thrombosis and Haemostasis* published by Wiley Periodicals LLC on behalf of International Society on Thrombosis and Haemostasis.

2 | GOALS

- Empower clinicians to recognize VITT early, then effectively diagnose and treat the disorder to reduce morbidity and mortality.
- Empower the public to be aware of VITT without causing undue alarm or overburdening the health-care system.

- Produce clear management pathways for: primary care settings and hospital settings, with recommendations for low-resource environments.
- Inform on the existence of treatment.
- Emphasize the real frequency of VITT and the overall benefit of vaccination.

3 | FUNDAMENTALS OF DIAGNOSIS AND LABORATORY TESTING

- VITT occurs after vaccination with non-replicant adenovirus vector-based vaccines (ChAdOx1, AstraZeneca/COVISHIELD; Ad26COV2.S, Janssen, Johnson & Johnson).
- Symptoms suggestive of VITT: persistent and severe headache, occurring with a time delay following vaccination (discussed subsequently), with red flags, such as progressive worsening and resistance to symptomatic treatment; persistent and severe abdominal or back pain; focal neurological symptoms (including blurred or double vision); shortness of breath; persistent and severe chest pain; swelling and redness of a limb; or pallor and coldness of a limb.
- Symptoms begin 5 or more days after vaccination, and typical presentations do not occur beyond 30 days except in some patients with isolated deep vein thromboses and pulmonary emboli, where the disease may remain subclinical for longer.
- Patients may have multiple organ thrombosis, and in VITT patients with new symptoms or symptoms from different organs or systems, additional thromboses must be ruled out.
- Platelet count and D-dimer are the most important screening laboratory tests.
- Two scenarios to consider after the platelet count result:
 - a. VITT UNLIKELY: Persistently normal platelet count ($\geq 150\ 000/\mu\text{L}$). This does not rule out thrombosis due to other causes. Clinicians should work up alternative diagnoses, including non-VITT thrombosis. If no alternative diagnosis is found, patients should be encouraged to seek care immediately (and have a repeat platelet count) if symptoms worsen. Note: Especially in patients with a high platelet count before onset of VITT even a substantial decrease in platelet count may not cause platelet count numbers $< 150\ 000/\mu\text{L}$, or it may take longer until the platelet count decreases to $< 150\ 000/\mu\text{L}$. If symptoms clinically persist, a repeat blood cell count should be performed. Note: if D-dimer is less than 2000 fibrinogen equivalent units (FEU; or four times the upper limit of normal), VITT is unlikely.
 - b. VITT LIKELY: New onset platelet count $< 150\ 000/\mu\text{L}$ (check whether patient has previous platelet counts available), 5–30 days post adenoviral vaccination. If D-dimer is elevated > 4000 FEU (and more than eight times the upper limit of normal) and is not better explained by another disorder (e.g., COVID-19 infection), VITT is likely, even if the patient does not have confirmed thrombosis. If D-dimer is not available, see below.

- What to do if no D-dimer assay is available:
 - a. Refer to the histogram of the automated particle counter; it will show a broadened curve not reaching baseline and not the typical smooth semi-logarithmic appearance. In addition, a blood film should be performed. In VITT, it will typically show multiple small platelet aggregates of 5–10 platelets. These small aggregates are not present in immune thrombocytopenic purpura patients (Figure 1).

4 | ADVANCED LABORATORY TESTING

- Standard laboratory testing.
 - a. If available, an international normalized ratio/prothrombin time (INR/PT), activated partial thromboplastin time (APTT), and fibrinogen level can confirm and serially monitor for disseminated intravascular coagulopathy (DIC), an important feature of VITT. Take blood sample before anticoagulation is started to avoid interference of anticoagulants with test results. Note that INR/PT and APTT is not consistently abnormal in all patients. Note also that patients on argatroban may have falsely reduced fibrinogen levels *in vitro* when the Clauss or PT-derived methods are used.
 - b. If available and if splanchnic vein thrombosis is suspected, a bilirubin, aspartate transaminase, alanine transaminase, and alkaline phosphatase can be useful to understand the extent and impact of the thrombus.
- Antibody testing.
 - a. The diagnosis of VITT can be confirmed with ELISA plate-based platelet factor 4 (PF4)/heparin (polyanion) antibody tests, which will demonstrate anti-PF4 antibodies. No PF4/heparin ELISA recognizes all VITT patients (for specialists: sensitivity of different commercial tests see 10.1111/jth.15362). A negative test makes VITT unlikely but does not necessarily exclude the diagnosis. Antibodies persist for at least 4 weeks (and usually much longer) in all patients, and (unlike platelet activation assays) ELISA reactivity is not inhibited by treatment with high-dose intravenous immunoglobulin (IVIG); thus, diagnosis can be confirmed retrospectively using either acute serum/plasma (if available) or usually serum/plasma obtained several weeks or months after initial presentation.
 - b. Rapid tests (including point of care tests using lateral flow technology) do not reliably detect these antibodies and should not be used.
 - c. Consideration should be given to setting up regional referral centers that are capable of performing high sensitivity anti-PF4 antibody testing by validated ELISA techniques. Antibodies are stable in whole blood or serum shipped (at room temperature) to referral centers for at least 3 days.
 - d. If no PF4 test is available, store serum sample at -20°C for later testing. Valid data on the prevalence of VITT in different

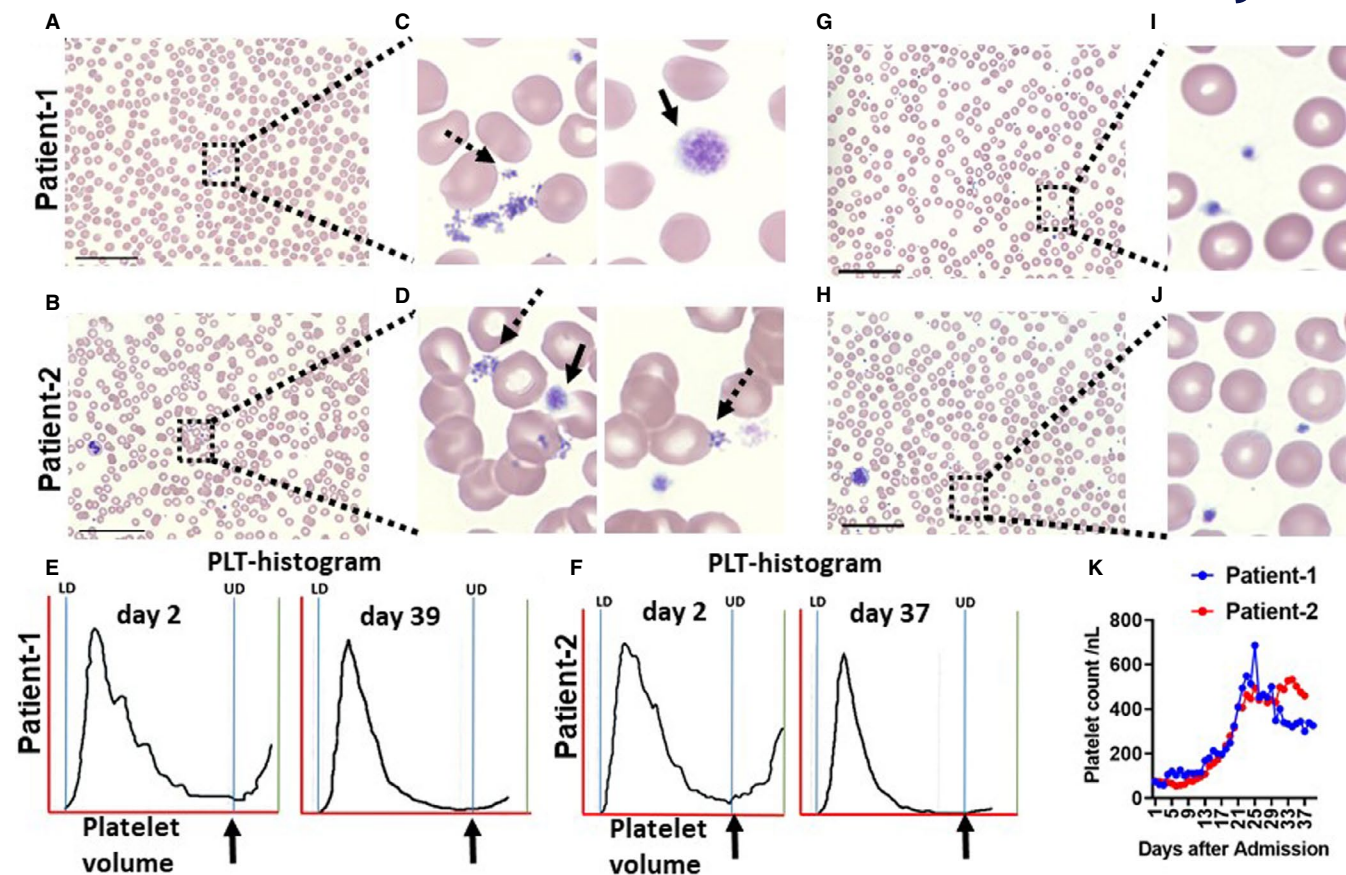


FIGURE 1 May-Grünwald stained blood smear analysis (A-J, microscopic analysis) and platelet histograms (E,F) from two patients with reduced platelet counts (K) suggestive of vaccine-induced immune thrombotic thrombocytopenia (VITT). Blood counts revealed thrombocytopenia in both patients. In routine blood smears aggregated (A-D; dotted arrows, platelet aggregates) and enlarged platelets (C-D, solid arrows; May-Grünwald Giemsa stain; scale bar 50 μ m) were readily detectable upon hospitalization. Increased platelet volume was confirmed by impedance measurement (E,F; PLT histograms; LD = lower discriminator, UD = upper discriminator). The patients received intravenous argatroban and 2g/kg immunoglobulin on days 3 and 4 (patient 1) or on day 1 and 2 (patient 2) post hospitalization. Within 6–9 days, the platelet changes observed upon hospitalization normalized (G-K). Obtained from: Zimmermann S, Federbusch M, Isermann B, Kohli S. Vaccine induced thrombotic thrombocytopenia: insights from blood smear. *Thromb Haemost*. 2021 Oct 28. doi: 10.1055/a-1681-7286. Online ahead of print, used with permission of authors and editor.

ethnicities are urgently needed and stored samples can be used for this purpose.

- Functional assays.
 - a. Consideration should be given to setting up regional referral centers that are capable of performing functional assays of platelet activation to confirm the diagnosis of VITT and differentiate it from HIT. Blood samples for functional tests should be obtained before treatment with IVIG is started (IVIG inhibits functional assays).

5 | FUNDAMENTALS OF IMAGING

- Cerebral venous sinus thrombosis (CVST) is potentially the most serious and life-threatening form of VITT. Unenhanced computed tomography (CT) of the brain is a reasonable first diagnostic imaging test for suspected CVST, as it can rule out alternative diagnoses (including intracranial hemorrhage) that have similar

symptoms and may show indirect signs. However, it is not sensitive enough to rule out CVST. In case of suspicion of VITT with CVST, both parenchymal and vascular imaging are required, either with an urgent non-contrast CT head and a CT venogram, or with an urgent magnetic resonance (MR) head and a contrast enhanced MR venogram.

In centers where imaging is not readily available and there is a high clinical suspicion of VITT, appropriate empiric treatment should be initiated while imaging is arranged; therapeutic dose anticoagulation is justified by typical symptoms (e.g., persistent and severe headache with red flags, such as progressive worsening and resistance to symptomatic treatment, and no better explanation for the patient's thrombocytopenia and elevated D-dimer), and objective confirmation of CVST can be done after starting anticoagulation.

In case of uncertainty of the diagnosis, the unlikely, possible, probable, definite criteria (Table 1) have been shown to be clinically easy to apply.

TABLE 1 Modified from Pavord et al.^{*}

Case definition criteria		
Likelihood of VITT	Clinical and laboratory features	Recommended management
	Onset of symptoms 5–30 days post COVID-19 vaccine (or up to 42 days if isolated DVT/PE) Documented thrombosis or severe and persistent headache Thrombocytopenia (platelet count <150 000/ μ L) D-dimer >4000 FEU (and >8 \times ULN) Positive anti-PF4/heparin IgG ELISA assay	
Definite VITT	Meets all five criteria	Anticoagulation, IVIG
Probable VITT	D-dimer > 4000 FEU (and >8 \times ULN), but one criteria not fulfilled (timing, thrombosis, thrombocytopenia, anti-PF4/heparin antibodies) or D-dimer unknown or 2000–4000 FEU (4–8 \times ULN) with all other criteria present	Anticoagulation, IVIG
Possible VITT	D-dimer unknown or 2000–4000 FEU (4–8 \times ULN) with one other criteria not fulfilled or two criteria not fulfilled (timing, thrombosis, thrombocytopenia, anti-PF4/heparin antibodies)	Anticoagulation, close clinical monitoring,
Unlikely	Platelet count <150 000/ μ L without thromboses, D-dimer <2000 FEU (<4 \times ULN), regardless of anti-PF4/heparin antibody result, and/or alternative diagnosis more likely	Anticoagulation only if thrombosis is present. Consider if ITP treatment is needed

Abbreviations: DVT, deep vein thrombosis; FEU, fibrinogen equivalent units; ITP, immune thrombocytopenic purpura; IVIG, intravenous immunoglobulin; PE, pulmonary embolism; PF4, platelet factor 4; ULN, upper limit of normal; VITT, vaccine-induced immune thrombotic thrombocytopenia.

^{*}Pavord S, Scully M, Hunt BJ, Lester W, Bagot C, Craven B, Rampotas A, Ambler G, Makris M. Clinical features of vaccine-induced immune thrombocytopenia and thrombosis. *N Engl J Med*. 2021 Aug 11. 10.1056/NEJMoa2109908. Online ahead of print.

6 | FUNDAMENTALS OF MANAGEMENT

- Management pathways should be put in place before mass vaccination campaigns begin, and should be tailored to local diagnostic and therapeutic capacity. There should be a very clearly labelled flowchart in the hospital emergency department. The neurology and hematology teams should also be available to assist as needed.
- Patients can deteriorate very quickly and treatment should not be delayed.
- Patients with likely or confirmed VITT should ideally be treated in the inpatient setting, where they can be monitored for complications and disease progression until they considerably improve clinically.
- Anticoagulation is the first pillar of treatment in VITT. It should be started in all patients with probable or definite VITT. Safe anticoagulants include oral and parenteral direct thrombin inhibitors (DTI), oral factor Xa inhibitors, and fondaparinux. They should be dosed similarly to the dose used to treat uncomplicated VTE. Renal and hepatic impairment, the ability to monitor parenteral DTI, as well as the ability to take oral medication, may influence dosing and choice of agent.
- A minority of VITT patients (number is likely <5%) present without overt thrombosis. Many of these patients have a presenting symptom of severe headache that started with a delay of 5 days after vaccination with negative neuroimaging studies, raising the possibility of microvascular thrombosis that has not progressed to macrovascular CVST. Despite absence of documented thrombosis, these individuals are still at high risk of thrombosis (similar to HIT without thrombosis), and should be managed no differently from patients with VITT who have overt thrombosis. In these cases, repeat imaging should be performed about 1 week after start of anticoagulation to confirm absence of thrombosis (relevant for duration of anticoagulation).
- Heparin does not appear to be dangerous in the vast majority of VITT patients. Heparin inhibits platelet activation in VITT by competitive binding *in vitro*. About 5% of VITT patients have antibodies that cross-react with PF4/heparin complexes. The hesitancy to use heparin likely stems from the fact that rapid exclusion of heparin cross-reactivity is usually not possible. (Waiting for functional testing can cause unacceptable treatment delays.) For this reason, it is recommended to use a non-heparin anticoagulant for initial treatment. However, if non-heparin anticoagulants are not available, heparin should be used to treat probable and definite VITT. Delaying anticoagulation in this intensely prothrombotic condition is much more dangerous than giving heparin.
- Dampening of the immune response is the second pillar of VITT treatment. This is best done with administration of high-dose IVIG, which helps to inhibit platelet activation and downregulates anti-PF4 antibody. An initial dose of 1 g/kg of actual body weight should be given. For treatment of CVST and splanchnic thrombosis, a second dose of 1 g/kg of actual body weight should be given on the next day. For all other patients, the second dose can be reserved for cases in which the platelet count and D-dimer fail to respond (generally by day 3 or 4), or the patient worsens clinically.
- If IVIG is not available, steroids (e.g., prednisone 1–2 mg/kg/day; or dexamethasone 40 mg/day for 4 days) are a reasonable choice.

- In very severe cases with platelet counts $<30\,000/\mu\text{L}$ and severe thrombosis, plasma exchange seems to improve outcome based on small case series.
- Thrombocytopenia is not a contraindication to therapeutic dose anticoagulation in VITT. In fact, individuals with the lowest platelet counts may well be at highest risk of thrombosis. It is critical to begin IVIG in patients with VITT and profound thrombocytopenia, as raising the platelet count in concert with anticoagulation should mitigate bleeding risk.
- The duration of anticoagulation is still unclear. In general, treatment must continue as long as the platelet count is low, and the D-dimer is elevated. The optimal duration is likely similar to non-VITT thrombosis (e.g., 3–6 months for venous thrombosis). Extended duration treatment can be challenging in areas with limited access to non-heparin anticoagulants.
- In a small subset of VITT patients, platelet activating anti-PF4 antibodies persist for at least 5 months. Especially in patients who show persistently reduced platelet count numbers, D-dimer should be retested after stop of anticoagulation. An increase in D-dimer without other explanation indicates ongoing clotting activation and anticoagulation should be resumed.

7 | THERAPIES TO AVOID

- Vitamin K antagonists must be avoided in acute VITT. They can cause protein C deficiency, and if the patient is already in a strongly hypercoagulable state (such as in VITT, HIT, malignancy, shock liver), they increase the risk for microcirculatory thrombosis. Vitamin K antagonists may be considered in the subacute period of VITT, that is, when the platelet count has normalized and remains stable for at least a week.
- Aspirin must be avoided in acute VITT. Aspirin does not prevent or treat VITT. It does not prevent platelet activation in this condition and could increase the risk of bleeding. In patients with anti-platelet drug medication before onset of VITT, continuation should be discussed with the cardiologist balancing bleeding risk and underlying indication.
- It is not clear if platelet transfusions worsen thrombosis in VITT. Platelet transfusion should only be considered for patients presenting with a life-threatening bleed, or requiring urgent major surgery and should ideally be given under the guidance of a hematologist.

8 | SPECIAL CONSIDERATIONS AROUND PREGNANCY AND LACTATION

- Pregnant and lactating patients can safely have CT scans and MRIs to diagnose possible CVST. These imaging modalities are also important to rule out other causes of severe and persistent headache, including intracranial hemorrhage or space-occupying lesions. Consultation with radiologists should be sought to ensure appropriate shielding is used if CT scanning is done. Appropriate

imaging should not be withheld in probable or definite VITT.

- In pregnant and lactating patients with probable or definite VITT, anticoagulation should not be withheld. The only suitable options for anticoagulation are heparin/low molecular weight heparin; or if available danaparoid or fondaparinux (very limited data). Direct oral factor Xa inhibitors are not recommended. IVIG is safe in pregnant and lactating patients. IVIG should not be withheld in probable or definite VITT.
- If IVIG is not available, steroids should be given in probable or definite VITT. Uncontrolled VITT is far more harmful to maternal and fetal health than any potential risks of steroid use. Short courses of steroids are safe in pregnant and lactating patients. Obstetricians and maternal fetal medicine specialists should be involved in patient management, particularly to advise on the risks and benefits of corticosteroid use, especially during the first trimester.

9 | STRATEGIES AROUND VACCINATION

- Dosing interval for ChAdOx1 nCov-19 vaccine.
 - a. The recommended interval of 3 months should be maintained, as this will reduce the risk that an individual who developed platelet-activating anti-PF4 antibodies after first vaccination will receive the second vaccination shot while these antibodies are still circulating. We know from HIT that use of heparin in an individual who has circulating heparin-dependent platelet activating antibodies can induce acute abrupt onset HIT. (Background information: In HIT for one individual with clinically evident HIT, there are about ten asymptomatic individuals despite circulating platelet activating antibodies. However, these asymptomatic individuals can experience “clinical breakthrough,” when heparin is given.)
- Second vaccination in patients with confirmed VITT.
 - a. Second dose mRNA vaccine is safe in patients with a history of VITT. The second (and subsequent) vaccination in patients should ideally be with an mRNA vaccine, regardless of whether VITT antibodies are still circulating or not.
 - b. Likely also inactivated virus vaccines are safe but no data are available yet.
 - c. We believe a second vaccination with the ChAdOx1 nCov-19 vaccine would be tolerated by most of these patients. An analogy would be HIT, in which re-exposure to heparin does not cause problems in most patients. Moreover, though there are reported cases of VITT associated with a second dose ChAdOx1 nCov-1, the vast majority have been found to be anti-PF4 antibody negative. VITT appears to be almost exclusively a “first dose problem.”

9.1 | Background information

If VITT patients must be re-exposed to the ChAdOx1 nCov-19 vaccine, due to resource/availability/access issues, all efforts should be

made to collect information on their clinical course. When robust evidence becomes available that the ChAdOx1 nCov-19 vaccine can be safely used a second time in VITT patients without adverse effects, this will make management of those patients in countries without ready access to non-adenoviral vector vaccines much easier.

We strongly support full vaccination—with a complete series of—in all patients globally, including heterologous prime-boost vaccination (“mix and match” vaccines) in VITT patients if they have access to mRNA vaccines. We appreciate that global vaccine inequity is a major concern, and not all global citizens have the same access to vaccines, and to vaccine choice. The rise of highly transmissible COVID-19 variants is most concerning in areas with low vaccine coverage. Therefore, we do not support a strategy of incomplete vaccination in individuals with a history of VITT, as this leaves them and their fellow citizens who are immunocompromised and/or are unable to receive the vaccine for whatever reason, susceptible to COVID-19 complications. All efforts should be made to get these individuals fully vaccinated and optimally protected from COVID-19.

10 | SURVEILLANCE AND SUPPORT

- Though VITT is a rare vaccine-related adverse event, cases will certainly present in any setting where adenoviral vector COVID-19 vaccines are administered. This condition causes considerable morbidity and mortality, so clinicians must be prepared to effectively diagnose and treat it. Moreover, effective surveillance systems must be in place to facilitate case finding, and effective reporting structures must be in place to facilitate thorough data collection and rapid clinical support. Clinicians (and patients) should be encouraged to report cases, in the spirit of transparency and vaccine safety.
- We recommend organized national/international help centers for VITT, providing round-the-clock support and telemedicine functionality.

Selected relevant VITT references published after June 2021.

11 | VITT CLINICAL

Clinical Features of Vaccine-Induced Immune Thrombocytopenia and Thrombosis.

Pavord S, Scully M, Hunt BJ, Lester W, Bagot C, Craven B, Rampotas A, Ambler G, Makris M. *N Engl J Med*. 2021 Oct 28;385:1680-1689.

Vaccine induced immune thrombocytopenia and thrombosis: summary of NICE guidance.

Pavord S, Hunt BJ, Horner D, Bewley S, Karpusheff J; Guideline Committee. *BMJ*. 2021 Oct 1;375:n2195. 10.1136/bmj.n2195. PMID: 34598931 No abstract available.

Prevalence of thrombocytopenia, anti-platelet factor 4 antibodies and D-dimer elevation in Thai people After ChAdOx1 nCoV-19 vaccination.

Uaprasert N, Watanaboonyongcharoen P, Vichitrachaneekorn R, Trithiphen S, Akkawat B, Sukperm A, Tongbai T, Jantarabenjakul W, Paitoonpong L, Rojnuckarin P. *Res Pract Thromb Haemost*. 2021 Sep 18;5(6):e12580. 10.1002/rth2.12580. eCollection 2021 Aug. PMID: 34568726 Free PMC article.

Declining mortality of cerebral venous sinus thrombosis with thrombocytopenia after SARS-CoV-2 vaccination.

van de Munckhof A, Krzywicka K, Aguiar de Sousa D, Sánchez van Kammen M, Heldner MR, Jood K, Lindgren E, Tatlisumak T, Putaala J, Kremer Hovinga JA, Middeldorp S, Levi M, Arnold M, Ferro JM, Coutinho JM. *Eur J Neurol*. 2021 Sep 18. 10.1111/ene.15113. Online ahead of print. PMID: 34536256

Venous Thromboembolism and Mild Thrombocytopenia after ChAdOx1 nCoV-19 Vaccination.

Gabarin N, Patterson S, Pai M, Afzaal T, Nazy I, Sheppard JI, Arnold DM, Warkentin TE. *Thromb Haemost*. 2021 Aug 12. 10.1055/a-1585-6182. Online ahead of print. PMID: 34384129 No abstract available.

Secondary Immune Thrombocytopenia (ITP) Associated with ChAdOx1 Covid-19 Vaccination - A Case Report.

Koch M, Fuld S, Middeke JM, Fantana J, von Bonin S, Beyer-Westendorf J. *TH Open*. 2021 Jul 30;5(3):e315-e318. 10.1055/s-0041-1731774. eCollection 2021 Jul. PMID: 34377889 Free PMC article.

Cerebral venous thrombosis after vaccination against COVID-19 in the UK: a multicentre cohort study.

Perry RJ, Tamborska A, Singh B, Craven B, Marigold R, Arthur-Farraj P, Yeo JM, Zhang L, Hassan-Smith G, Jones M, Hutchcroft C, Hobson E, Warcel D, White D, Ferdinand P, Webb A, Solomon T, Scully M, Werring DJ, Roffe C; CVT After Immunisation Against COVID-19 (CAIAC) collaborators. *Lancet*. 2021 Sep 25;398(10306):1147-1156. 10.1016/S0140-6736(21)01608-1. Epub 2021 Aug 6. PMID: 34370972 Free PMC article.

12 | VITT NO THROMBOSIS

Vaccine-Induced Thrombocytopenia with Severe Headache.

Salih F, Schönborn L, Kohler S, Franke C, Möckel M, Dörner T, Bauknecht HC, Pille C, Graw JA, Alonso A, Pelz J, Schneider H, Bayas A, Christ M, Kuramatsu JB, Thiele T, Greinacher A, Endres M. *N Engl J Med*. 2021 Sep 15. 10.1056/NEJMc2112974. Online ahead of print.

Delayed headache after COVID-19 vaccination: a red flag for vaccine induced cerebral venous thrombosis.

García-Azorín D, Do TP, Gantenbein AR, Hansen JM, Souza MNP, Obermann M, Pohl H, Schankin CJ, Schytz HW, Sinclair A, Schoonman GG, Kristoffersen ES. *J Headache Pain*. 2021 Sep 17;22(1):108. 10.1186/s10194-021-01324-5. PMID: 34535076 Free PMC article.

VITT following Ad26.COVS2.S vaccination presenting without radiographically demonstrable thrombosis.

Kennedy VE, Wong CC, Hong JM, Peng TA, Brondfield S, Reilly LM, Cornett P, Leavitt AD. *Blood Adv*. 2021 Sep 29: bloodadvances.2021005388. 10.1182/bloodadvances.2021005388. Online ahead of print. PMID: 34587255 Free PMC article.

13 | VITT NORMAL PLATELET COUNT

Vaccine-induced immune thrombotic thrombocytopenia presenting with normal platelet count.

Page D, Zhu N, Sawler D, Sun HW, Turley E, Pai M, Wu C. *Res Pract Thromb Haemost*. 2021 Sep 14;5(6):e12596. 10.1002/rth2.12596. eCollection 2021 Aug. PMID: 34532632 Free PMC article.

Venous Thromboembolism and Mild Thrombocytopenia after ChAdOx1 nCoV-19 Vaccination.

Gabarin N, Patterson S, Pai M, Afzaal T, Nazy I, Sheppard JI, Arnold DM, Warkentin TE. *Thromb Haemost*. 2021 Aug 12. 10.1055/a-1585-6182. Online ahead of print. PMID: 34384129 No abstract available.

14 | VITT ANTIBODY PERSISTENCE

Decline in Pathogenic Antibodies over Time in VITT.

Schönborn L, Thiele T, Kaderali L, Greinacher A. *N Engl J Med*. 2021 Sep 8:NEJMc2112760. 10.1056/NEJMc2112760. Online ahead of print. PMID: 34496199 Free PMC article. No abstract available.

15 | VITT LABORATORY TESTING OF ANTI-PF4 ANTIBODIES

Laboratory testing for post ChAdOx1 nCoV-19 vaccination VITT: A challenge. Comment on: Recommendations for the clinical and laboratory diagnosis of VITT against COVID-19: Communication from the ISTH SSC Subcommittee on Platelet Immunology.

Vercruyse K, Devreese KMJ. *J Thromb Haemost*. 2021 Sep;19(9):2355-2357. 10.1111/jth.15457. Epub 2021 Jul 27. PMID: 34312992 Free PMC article. No abstract available.

Frequency of positive anti-PF4/polyanion antibody tests after COVID-19 vaccination with ChAdOx1 nCoV-19 and BNT162b2.

Thiele T, Ulm L, Holtfreter S, Schönborn L, Kuhn SO, Scheer C, Warkentin TE, Bröker BM, Becker K, Aurich K, Selleng K, Hübner NO, Greinacher A. *Blood*. 2021 Jul 29;138(4):299-303. 10.1182/blood.2021012217. PMID: 33988688 Free PMC article.

Evaluation of laboratory assays for anti-platelet factor 4 antibodies after ChAdOx1 nCoV-19 vaccination.

Platton S, Bartlett A, MacCallum P, Makris M, McDonald V, Singh D, Scully M, Pavord S. *J Thromb Haemost*. 2021 Aug;19(8):2007-2013. 10.1111/jth.15362. Epub 2021 Jul 5. PMID: 33973336 Free PMC article.

A flow cytometric assay to detect platelet-activating antibodies in VITT after ChAdOx1 nCoV-19 vaccination.

Handtke S, Wolff M, Zaninetti C, Wesche J, Schönborn L, Aurich K, Ulm L, Hübner NO, Becker K, Thiele T, Greinacher A. *Blood*. 2021 Jul 1;137(26):3656-3659. 10.1182/blood.2021012064.

PF4 Immunoassays in Vaccine-Induced Thrombotic Thrombocytopenia.

Vayne C, Rollin J, Gruel Y, Pouplard C, Galinat H, Huet O, Mémier V, Geeraerts T, Marlu R, Pernod G, Mourey G, Fournel A, Cordonnier C, Susen S. *N Engl J Med*. 2021 Jul 22;385(4):376-378. 10.1056/NEJMc2106383.

16 | VITT IVIG AND STEROIDS

Cooling down VITT with IVIG.

Lentz SR. *Blood*. 2021 Sep 16;138(11):921-922. 10.1182/blood.2021012819. PMID: 34529019 Free PMC article.

Adjunct Immune Globulin for Vaccine-Induced Immune Thrombotic Thrombocytopenia.

Bourguignon A, Arnold DM, Warkentin TE, Smith JW, Pannu T, Shrum JM, Al Maqrashi ZAA, Shroff A, Lessard MC, Blais N, Kelton JG, Nazy I. *N Engl J Med*. 2021 Aug 19;385(8):720-728. 10.1056/NEJMoa2107051. Epub 2021 Jun 9. PMID: 34107198 Free PMC article.

The use of IV immunoglobulin in the treatment of vaccine-induced immune thrombotic thrombocytopenia.

Uzun G, Althaus K, Singh A, Möller P, Ziemann U, Mengel A, Rosenberger P, Guthoff M, Petzold GC, Müller J, Büchsel M, Feil K, Henkes H, Heyne N, Maschke M, Limpach C, Nagel S, Sachs UJ, Fend F, Bakchoul T. *Blood*. 2021 Sep 16;138(11):992-996. 10.1182/blood.2021012479. PMID: 34166507 Free PMC article. No abstract available.

17 | VITT MECHANISM

Insights in ChAdOx1 nCoV-19 Vaccine-induced Immune Thrombotic Thrombocytopenia (VITT).

Greinacher A, Selleng K, Palankar R, Wesche J, Handtke S, Wolff M, Aurich K, Lalk M, Methling K, Volker U, Hentschker C, Michalik S, Steil L, Reder A, Schönborn L, Beer M, Franzke K, Büttner A, Fehse B, Stavrou EX, Rangaswamy C, Mailer RK, Englert H, Frye M, Thiele T, Kochanek S, Krutzke L, Siegerist F, Endlich N, Warkentin TE, Renné T. *Blood*. 2021 Sep 29: blood.2021013231. 10.1182/blood.2021013231. Online ahead of print. PMID: 34587242 Free PMC article.

Immune complexes, innate immunity, and NETosis in ChAdOx1 vaccine-induced thrombocytopenia.

Holm S, Kared H, Michelsen AE, Kong XY, Dahl TB, Schultz NH, Nyman TA, Fladeby C, Seljeflot I, Ueland T, Stensland M, Mjaaland S, Goll GL, Nissen-Meyer LS, Aukrust P, Skagen K, Gregersen I, Skjelland M, Holme PA, Munthe LA, Halvorsen B. *Eur Heart J*. 2021

Aug 18;ehab506. 10.1093/eurheartj/ehab506. Online ahead of print. PMID: 34405870 Free PMC article.

Antibody epitopes in vaccine-induced immune thrombotic thrombocytopenia.

Huynh A, Kelton JG, Arnold DM, Daka M, Nazy I. *Nature*. 2021 Aug;596(7873):565-569. 10.1038/s41586-021-03744-4. Epub 2021 Jul 7. PMID: 34233346

Antibody-mediated procoagulant platelets in SARS-CoV-2-vaccination associated immune thrombotic thrombocytopenia.

Althaus K, Möller P, Uzun G, Singh A, Beck A, Bettag M, Bösmüller H, Guthoff M, Dorn F, Petzold GC, Henkes H, Heyne N, Jumaa H, Kreiser K, Limpach C, Luz B, Maschke M, Müller JA, Münch J, Nagel S, Pöttsch B, Müller J, Schlegel C, Viardot A, Bänzner H, Wolf M, Pelzl L, Warm V, Willinek WA, Steiner J, Schneiderhan-Marra N, Vollherbst D, Sachs UJ, Fend F, Bakchoul T. *Haematologica*. 2021 Aug 1;106(8):2170-2179. 10.3324/haematol.2021.279000. PMID: 34011137 Free PMC article.

KEYWORDS

adenoviral vector-based vaccine, AstraZeneca, cerebral vein sinus thrombosis, platelets, SARS-CoV-2 vaccine, vaccine-induced immune thrombotic thrombocytopenia

ACKNOWLEDGMENT

The support of and valuable discussions with Dr. David Garcia Azorin is highly appreciated.

CONFLICTS OF INTEREST

FL has received personal fees for lectures, advisory boards, or consultancy and/or research support from Aspen, Bayer, Boehringer Ingelheim, Bristol-Myers Squibb, CSL Behring, Daiichi Sankyo, LEO Pharma, Mitsubishi Tanabe Pharma, Octapharma, Pfizer, Sanofi, Viatrix, and Werfen, outside the submitted work. HT has received honoraria for advisory board participation, research support, or educational lectures from Bayer, CSL Behring, Novo Nordisk, Pfizer, Roche, and Sanofi outside the submitted work. MM is the project lead for the European Haemophilia Safety Surveillance System (EUHASS), which received funding from Bayer, Biomarin, BPL, CSL Behring, Kedrion, NovoNordisk, Octapharma, Pfizer, Roche, Sanofi, Sobi, and Takeda. MP has received honoraria for a lecture from Novartis, and has provided expert witness testimony relating to thrombotic disorders. SP has received honoraria for educational lectures, chairing and participation in advisory boards, or sponsorship for running courses from SOBI, Amgen, Alexion, Sanofi, CSL Behring, Novartis, Pharmacosmos, and Vifor Pharma, outside the submitted work. TEW has received lecture honoraria from Alexion and Instrumentation Laboratory, and royalties from Informa (Taylor & Francis); has provided consulting services to Aspen Canada, Aspen Global, Bayer, CSL Behring, Ergomed, and Octapharma; has received research funding from Instrumentation Laboratory; and has provided expert witness testimony relating to heparin-induced thrombocytopenia (HIT)

and non-HIT thrombocytopenic and coagulopathic disorders. AG reports grants and non-financial support from Aspen, Boehringer Ingelheim, MSD, Bristol Myers Squibb (BMS), Paringenix, Bayer Healthcare, Gore Inc., Rovi, Sagent, Biomarin/Prosensa; personal fees from Aspen, Boehringer Ingelheim, MSD, Macopharma, BMS, Chromatec, Instrumentation Laboratory; non-financial support from Boehringer Ingelheim, Portola, Ergomed, GTH e.V. outside the submitted work.

AUTHOR CONTRIBUTIONS

All authors wrote the manuscript and contributed their national and regional experience. All authors approved the final version of the manuscript.

Andreas Greinacher¹ 

Florian Langer²

Mike Makris³

Menaka Pai⁴

Sue Pavord⁵

Huyen Tran⁶

Theodore E. Warkentin⁴ 

¹*Institut für Immunologie und Transfusionsmedizin, Abteilung Transfusionsmedizin, Universitätsmedizin Greifswald, Germany*

²*Zentrum für Onkologie, II. Medizinische Klinik und Poliklinik, Universitätsklinikum Eppendorf, Hamburg, Germany*

³*Department of Infection, Immunity and Cardiovascular Disease, University of Sheffield, UK*

⁴*Departments of Pathology and Molecular Medicine, and Medicine, McMaster University, Hamilton, Ontario, Canada*

⁵*Department of Haematology, Oxford University Hospitals NHS Foundation Trust, Oxford, UK*

⁶*Australian Centre for Blood Diseases, Clinical Haematology Department, Monash University, Melbourne, Victoria, Australia*

Correspondence

Andreas Greinacher, Institut für Immunologie und Transfusionsmedizin, Abteilung Transfusionsmedizin, Sauerbruchstrasse, 17487 Greifswald, Germany.
Email: andreas.greinacher@med.uni-greifswald.de

ORCID

Andreas Greinacher  <https://orcid.org/0000-0001-8343-7336>

Theodore E. Warkentin  <https://orcid.org/0000-0002-8046-7588>

How to cite this article: Greinacher A, Langer F, Makris M, et al. Vaccine-induced immune thrombotic thrombocytopenia (VITT): Update on diagnosis and management considering different resources. *J Thromb Haemost*. 2021;00:1-8.
doi:[10.1111/jth.15572](https://doi.org/10.1111/jth.15572)