



## Appendectomy and women's reproductive outcomes: a review of the literature

Lucia Merlino · Alessandra Chiné · Giulia Carletti · Federica Del Prete · Massimo Codacci Pisanelli · Luca Titi · Maria Grazia Piccioni 

Received: 2 February 2021 / Accepted: 12 March 2021  
© The Author(s) 2021

### Summary

**Background** The most frequent abdominal surgery performed for benign disease in females of fertile age is appendectomy, which remains among the most common surgeries and is a possible cause of peritoneal adhesions. The fact that appendectomy can cause adhesions may lead one to think that this may be a relevant risk factor for infertility; however, there is no universal agreement regarding the association between appendectomy and fertility. The aim of this review is to evaluate whether appendectomy may have a relevant impact on female fertility.

**Methods** The search was conducted in PubMed and there was no limitation set on the date of publication. All studies regarding populations of female patients who had undergone appendectomy for inflamed appendix, perforated appendix, or negative appendix between childhood and the end of the reproductive period were included.

**Results** Some authors believe that pelvic surgery can cause adhesions which can potentially lead to tubal infertility by causing tubal obstruction or by altering motility of fimbriae, tubal fluid secretion, and embryo transport. On the other hand, the most recent evidence reported that removal of the appendix seems to be associated with an increased pregnancy rate in large population studies.

**Conclusion** Despite the existence of contrasting opinions concerning fertility after appendectomy, the most recent evidence suggests that appendectomy may actually lead to improved fertility and decreased time to pregnancy. Appendectomy seems to be correlated with improved fertility and higher pregnancy rates.

**Keywords** Infertility · Complicated appendicitis · Abdominal surgery · Abdominal adhesions and reproduction · Tubal occlusion

### Introduction

The World Health Organization defines infertility as the failure to conceive after more than 1 year of unprotected sexual intercourse. It has been estimated that 50 to 80 million women worldwide are diagnosed with infertility every year [1].

Some of the most common causes of infertility are reproductive system diseases (endometriosis, uterine leiomyomas, previous urinary tract infections, and surgeries or other invasive procedures), endocrine imbalances, advanced age at conception, drugs and

L. Merlino · A. Chiné · G. Carletti · F. Del Prete ·  
M. G. Piccioni (✉)

Department of Maternal and Child Health and Urological Sciences, Policlinico Umberto I, "Sapienza" University of Rome, Viale del Policlinico 155, 00161 Rome, Italy  
mariagrazia.piccioni@uniroma1.it

L. Merlino  
lucia.merlino@uniroma1.it

A. Chiné  
alessandra.chine@uniroma1.it

G. Carletti  
giulia.carletti95@gmail.com

F. Del Prete  
federica.delprete@uniroma1.it

M. Codacci Pisanelli  
Department of Surgery "Pietro Valdoni", Policlinico Umberto I, "Sapienza" University of Rome, Rome, Italy  
massimo.codaccipisanelli@uniroma1.it

L. Titi  
Department of Anesthesiology, Section Obstetrical Care, "Sapienza" University of Rome, Policlinico Umberto I, Rome, Italy  
luca.titi@uniroma1.it

alcohol abuse, altered immune responses, stress, and chronic diseases [2]. Currently, the most common cause of infertility in women is probably fallopian tube dysfunction and in particular a compromised tubal patency [3]. Tubal occlusions and pelvic adhesions are major causes of infertility and have been estimated to account for approximately 35% of infertility in couples and for more than 50% of female infertility [4, 5]. According to recent literature, up to 5% of infertility cases can be ascribed to iatrogenic interventions which are thought to interfere with fertility by favoring the formation of intraabdominal adhesions, thereby leading to fallopian tube dysfunction [6]. Adhesions are known to be the consequence of tissue trauma during surgery and it would appear that scar tissue formation may result in infertility by distorting adnexal anatomy, thus interfering with embryo transport [7]. Despite a recent decline in the frequency of appendectomy due to the increasingly popular conservative approach and improved diagnostic workup [8–10], appendectomy remains the most frequent benign abdominal surgery performed in females of fertile age and consequently remains a major cause of intraabdominal adhesions [11]. Possible causes of adhesions in this setting are the acute inflammatory response of appendicitis itself, the trauma of surgery, and postoperative inflammation due to a foreign body reaction [11, 12].

The evidence that appendectomy can cause formation of pelvic adhesions may lead one to think that this could be an important risk factor for infertility. In the literature there is controversy about this correlation and some studies have found no evidence for tubal infertility after appendectomy [13–15]. Other studies have rather found that appendectomy with or without pathologically confirmed appendicitis could be indirectly associated with an increased rate of infertility by virtue of an increase in the rate of ectopic pregnancies [16, 17]. Complicated appendicitis associated with perforation, peritonitis, or pelvic abscess has been associated by some authors with normal fertility [18–24], and by others with substantially reduced fertility [25–29]. Similarly, appendectomy, regardless of the severity of appendicitis and even in case of negative appendicitis, has been associated by some authors with normal fertility [12, 14, 15] and by others with significantly reduced fertility [16, 17].

The aim of this review is to bring attention to this controversial topic and to evaluate whether benign abdominal surgery and appendectomy in particular may have an impact on female fertility.

## Materials and methods

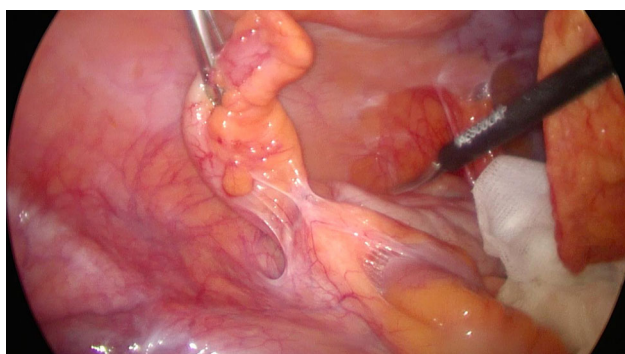
The search was conducted in the PubMed database and shall be deemed updated as of December 2020. There was no limitation set on the date of publication. The keywords used for the PubMed search were appendicitis, complicated appendicitis, infertility,

appendectomy, appendectomy complications, and reproductive outcomes. Cohort studies, case-control studies, meta-analysis, reviews, and systematic reviews were analyzed. All studies regarding populations of female patients who had undergone appendectomy for inflamed appendix, perforated appendix, or negative appendix between childhood and the end of the reproductive period were included in the current review. Excluded were benign abdominal surgery for causes other than appendectomy and non-English studies.

## Results

In our literature search we have found contrasting opinions regarding the impact of appendectomy on fertility.

In the past, several studies suggested an association between complicated appendicitis and female infertility [18, 21, 26, 28, 29]. Thompson et al. and Mueller et al. found that appendiceal perforation increased the risk of primary tubal infertility and of secondary tubal infertility [18, 33]. It was also stated in several old textbooks that perforated appendicitis in childhood is associated with an increased risk of tubal infertility [30, 31]. Brikeenfield et al. in 1982 and Lalos et al. in 1988 found an increased appendectomy rate of 20% and 29%, respectively, in women seeking care at a fertility clinic compared to 7–10% in the general population [14, 32]. In a review about the risk factors for tubal infertility, Lalos et al. found that out of 120 women with diagnosed tubal dysfunctions, 59% had a positive history for pelvic surgery and 42% had history of pelvic inflammation. Based on these assumptions it was suggested that previous pelvic surgery and inflammation could be relevant factors for development of tubal infertility [14]. More recently in 2019, Becker et al. also noticed a correlation between appendectomy and infertility. They reported that almost 25% of women seeking care at their fertility clinic had a positive history of appendectomy, suggesting a possible association. However, after further investigation, Becker et al. did not find impaired tubal patency on chromopertubation. Based on this, the authors hypothesized that the observed increased rate of infertility after appendectomy may possibly be linked to factors other than tubal patency such as fibrosis in and around the ovarian capsule, decreased ciliary movements and secretion of tubal fluid, or alterations in movements of the fimbriae which could have been compromised by local inflammation after appendicitis [33]. Bellati et al. in 2014, in a study about female fertility after unilateral ovariectomy, found a lower birth rate in patients with a history of appendectomy and stated that despite not being statistically significant, it was not possible to exclude that this difference could be ascribed to development of tubal infertility following appendicitis [6].



**Fig. 1** Laparoscopic appendectomy

Other than the long-term effects of appendicitis and or appendectomy, there are a few case reports in the literature on some acute post-appendectomy complications likely to have an impact on fertility. Singh-Ranger et al. in 2008 reported the case of a 17-year-old girl who developed acute coliform salpingitis 3 months after appendectomy [34]. Nyogi et al. in 2009 and Limberg et al. in 2015 described two similar cases of recurrent hydrosalpinx ensuing after surgery for perforated appendicitis [35, 36]. Vyas et al. in 2008 presented a case of tubal/ovarian abscess due to an appendicolith that appeared to have migrated into the right fallopian tube [37].

In the literature there are contrasting opinions regarding the incidence of postsurgical adhesions in laparoscopic and open appendectomy (Fig. 1). Some authors believe that the risk of developing anterior abdominal wall adhesions is likely to be lower after laparoscopy than after laparotomy because the risk seems to be correlated to the length of the abdominal incisions [13]. Moreover, postoperative surgical scar infection, another factor known to favor adhesion, is significantly lower after laparoscopy than after laparotomy [7]. Lundorff et al. observed fewer adhesions after laparoscopic tubal surgery than after open surgery [38]. De Wilde et al. performed a second-look laparoscopy 3 months after either open or laparoscopic surgery for acute appendicitis and found that 80% of the patients who underwent open appendectomy had abdominal adhesions, whereas after laparoscopic appendectomy adhesions were found in only 20% of patients [39]. Vrijland et al. came to the same conclusion, stating that laparoscopic surgery appears to induce fewer adhesions than open surgery [40]. In contrast, other authors have found that the benefit of a laparoscopic approach in terms of adhesion prevention is not as certain as suggested by the previous clinical impression and by the results of early laparoscopic adhesiolysis. In fact, with the exception of tubal sterilization, procedures performed by laparotomy and laparoscopy were followed by identical rates of readmissions due to postoperative adhesion complications [41, 42].

The role of adjuvants in preventing postoperative adhesion formation has been demonstrated in vari-

ous clinical experiments. Hyaluronic acid-based materials reduced adhesions after intestinal and gynecological surgery [33, 38, 43]. Mechanical barriers are considered effective in surgery for subfertility. In some clinical studies, adjuvants such as dexamethasone, Ringer's lactate, and dextran have never been proved to be effective [40, 44]. In a recent review by Canis et al., several devices for prevention of adhesions were compared: GoreTex (W.L. Gore & Associates, Inc, Newark, DE, USA), Interceed (Johnson & Johnson, New Brunswick, NJ, USA), Seprafilm (Baxter, Deerfield, IL, USA), Icodextrin, Hyalobarrier (Nordic Pharma, Ismaning, Deutschland). Although no study has shown superiority of one product over another, some studies have noticed a decrease in the adhesions observed in the treated groups at second-look laparoscopy [45]. Despite the results not being statistically significant, considering the fact that no adverse effects were reported, the use of these devices could be suggested.

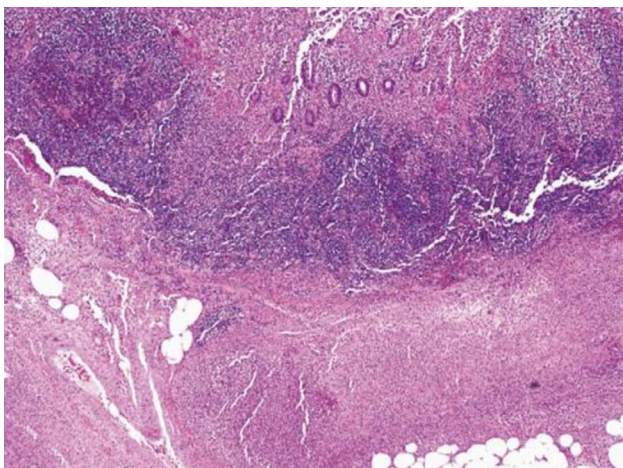
On the other hand, no evidence was found regarding the efficacy of surgical barriers, or antiinflammatory agents in reducing the risk of postsurgical adhesions [7].

The abovementioned findings would apparently further support the hypothesis that appendicitis or, more specifically, perforated appendicitis could be directly linked to tubal pathology and therefore tubal infertility.

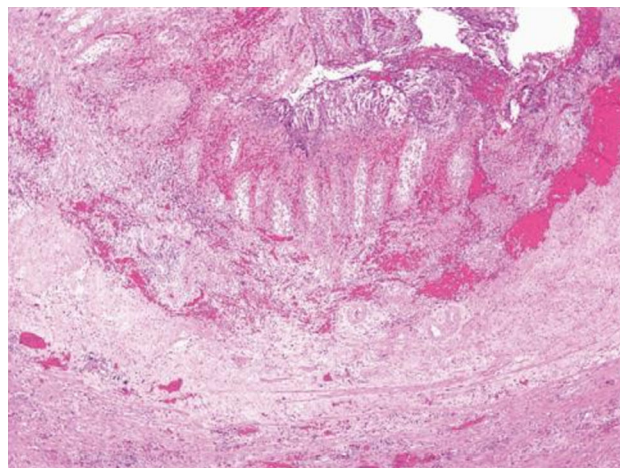
However, several authors have published evidence that appears to be in strong contrast to these findings. When looking into the most recent literature, very interesting data have emerged which seem to suggest the exact opposite of what was once believed to be the effect of appendectomy on fertility. In fact, according to several recent articles, it would appear that appendectomy could actually increase fertility.

In 1977, Geerdsen reported that perforated appendicitis in girls showed no correlations with infertility. It would in fact appear that the inflammatory process caused by perforated appendicitis resolves completely with appendectomy and adequate antibiotic treatment [26]. Also, Puri et al. reported that perforated appendicitis in prepubertal children has no impact on the development of tubal infertility. With improved diagnostic tests, earlier surgery, and the use of antibiotics directed against anaerobes like *Bacteroides* spp., the incidence of intraabdominal abscess after perforated appendicitis is significantly diminished and this is likely to further minimize any risk of tubal damage arising from perforated appendix ([20, 46]; Fig. 2). Mueller et al. have estimated that the proportion of tubal infertility attributable to appendiceal perforation is 0.9% [29].

Urbach et al., considering the low prevalence of appendix perforation and the low level of evidence correlating infertility to appendiceal perforation, consider it unlikely that appendix perforation has a relevant impact on the burden of infertility at a population level.



**Fig. 2** Acute suppurative appendicitis showing diffuse mucosal ulceration and transmural acute inflammation with extension into the periappendiceal fat (H&E stain)



**Fig. 3** Gangrenous appendicitis with necrosis of the wall of the appendix (H&E stain)

They reported that women with a positive history of perforated appendicitis had comparable rates of first birth and parity to the control women [24]. These findings are in line with data reported in a recent meta-analysis by Elraiyah et al., which showed that appendectomy is not associated with infertility but is instead significantly associated with an increased risk of ectopic pregnancy [47].

In addition to demonstrating that appendectomy did not affect female fertility, in recent years, various authors have reported that the execution of this surgery could improve the female pregnancy rate. In an epidemiological study published in 1999, Andersson et al. were the first to report that women who had negative appendectomy showed an increased first birth rate and had their first child at an earlier age on average, reaching a higher parity than control women. They showed an increased pregnancy rate after appendectomy for non-perforated appendicitis with an HR (hazard ratio) of 1.11 (95% CI: 1.07–1.15) as well as after removal of a normal appendix with an HR of 1.48 (95% CI: 1.42–1.54). Perforated appendicitis did not show any significant change in pregnancy rate with an HR of 0.95 (95% CI: 0.88–1.04) [23]. More recent studies on this topic such as those of Li Wei et al. would appear to corroborate the theory according to which appendectomy could improve female fertility and subsequently lead to higher pregnancy rates [11, 48]. In a cohort study on this topic, Wei et al. reported a statistically significant increase in pregnancy rate after appendectomy and early appendicitis. More specifically, in the appendectomy cohort, the subgroup with complicated purulent or gangrenous appendicitis had lower pregnancy rates when compared with the group who had negative appendectomy but similar pregnancy rates to the comparator cohort (Fig. 3; [46]). Wei's explanation for the association between appendectomy and increased pregnancy rate is that acute abdominal pain in the right iliac fossa leading to ex-

ploration and appendectomy might have been caused by ovulation-related pain leading to negative appendectomy and at the same time acting as a surrogate marker of increased fertility [11]. In a recent systematic review about the long-term complications of appendectomy published in 2018, five cohort studies reporting on fertility were included [11, 23, 26, 48]. Four of these studies had similar outcomes, suggesting that patients with a positive history of appendectomy had an increased pregnancy rate when compared to control groups. Three of the studies included in the review assessed the adjusted HR for first pregnancy, showing increased pregnancy rates for the appendectomy groups with HRs of 1.20 (95% CI: 1.10–1.31), 1.34 (95% CI: 1.32–1.35), and 1.54 (95% CI: 1.52–1.56), respectively [49].

However, none of these studies included information about perforated and non-perforated appendicitis. Some authors suggested that since the majority of acute appendicitis cases occur in the luteal phase of the menstrual cycle, the fluctuations of female sex hormones might play a direct role in the development of the inflammatory process in the appendix [50, 51].

Thus, female sex hormone fluctuations may influence the initial inflammatory process in the lymphoid tissue of the appendix, which subsequently becomes engorged and obstructs the lumen, leading to acute appendicitis [52]. Wei et al. gave other possible explanations for this phenomenon in a second larger cohort study. In this cohort study it was reported that not only appendectomy but also tonsillectomy seemed to be correlated with an increased pregnancy rate and decreased time to pregnancy. This study included a total of 54,675 appendectomy patients, 112,607 tonsillectomy patients, and 10,340 patients who had both appendectomy and tonsillectomy. The pregnancy rate was 54.4% in the appendectomy-only cohort, 53.4% in the tonsillectomy-only cohort, and 59.7% in the cohort undergoing both surgeries, while in the compara-

tor cohort the pregnancy rate was 43.7% in a mean follow-up of 14.7–9.7 years. Time to achieve pregnancy was shortest in patients who received both appendectomy and tonsillectomy, followed by patients who underwent appendectomy only, and then tonsillectomy only compared with the rest of the population [48].

According to the authors, one possible explanation for this phenomenon is that as any lymphoid organ, appendix and tonsils may be susceptible to episodic, chronic, and/or recurrent inflammation, either de novo or after previous acute attacks [22, 24, 27]. For this reason, by surgically removing these organs the degree of chronic inflammation and acute inflammatory attacks can be hampered, resulting in improved wellbeing of young women, including a more favorable uterine, tubal, and ovarian environment for pregnancy [48].

## Discussion

Opinions in the literature regarding the consequences of appendectomy on female fertility are conflicting. Some authors believe that pelvic surgery can cause adhesions which can potentially lead to tubal infertility by causing tubal obstruction or by altering fimbrial motility, tubal fluid secretion, and embryo transport. On the other hand, the most recent evidence reported that removal of the appendix seems to be associated with an increased pregnancy rate in large population studies. The underlying pathophysiological mechanism by which this occurs must be further investigated, but an immunological process may be implicated.

## Conclusion

Despite contrasting opinions in the literature concerning fertility after appendectomy, the most recent findings suggest that appendectomy may actually lead to improved fertility and to decreased time to pregnancy, thus suggesting that a more aggressive operative approach in female patients of fertile age with suspected appendicitis could be reasonable. Moreover, the minimally invasive laparoscopic approach seems likely to reduce tissue trauma as well as scar length, and consequently, by reducing the inflammatory process responsible for scarring and adhesions, might further minimize the negative impact of appendectomy on tubal fertility.

**Acknowledgements** Thanks to Riccardo Carbonaro, MD, for scientific contributions to the manuscript.

**Author Contribution** All authors read and approved the final version of the manuscript; Lucia Merlino: Conceptualization, methodology, writing; Alessandra Chiné: Data curation, writing; Giulia Carletti: Data curation, writing; Federica Del Prete: Conceptualization, methodology, writing; Massimo Codacci-Pisanelli: Supervision; Luca Titi: Visualization; Maria Grazia Piccioni: Supervision.

**Funding** Open access funding provided by Università degli Studi di Roma La Sapienza within the CRUI-CARE Agreement.

## Declarations

**Conflict of interest** L. Merlino, A. Chiné, G. Carletti, F. Del Prete, M. Codacci Pisanelli, L. Titi, and M.G. Piccioni declare that they have no competing interests.

**Open Access** This article is licensed under a Creative Commons Attribution 4.0 International License, which permits use, sharing, adaptation, distribution and reproduction in any medium or format, as long as you give appropriate credit to the original author(s) and the source, provide a link to the Creative Commons licence, and indicate if changes were made. The images or other third party material in this article are included in the article's Creative Commons licence, unless indicated otherwise in a credit line to the material. If material is not included in the article's Creative Commons licence and your intended use is not permitted by statutory regulation or exceeds the permitted use, you will need to obtain permission directly from the copyright holder. To view a copy of this licence, visit <http://creativecommons.org/licenses/by/4.0/>.

## References

1. Sudha G, Reddy KSN. Causes of female infertility: a cross-sectional study. *Int J Latest Res Sci Technol*. 2013;2:119–23.
2. Deyhoul N, Mohamaddoost T, Hosseini M. Infertility-related risk factors: a systematic review. *Int J Womens Health Reprod Sci*. 2017;5:24–9.
3. Templeton A. Infertility-epidemiology, aetiology and effective management. *Health Bull*. 1995;53:294–8.
4. Behrman SJ, Kistner RWA. Rational approach to the evaluation of infertility. In: *Progress in infertility*. 2nd ed. Boston: Little, Brown; 1975.
5. Piccioni MG, Tabacco S, Merlino L, Del Negro V, Mazzeo A, Logoteta A, et al. Does hysterosalpingo-foam sonography have any therapeutic effect? A systematic review. *Minerva Ginecol*. 2020;72(1):55–8.
6. Bellati F, Ruscito I, Gasparri ML, Antonilli M, Pernice M, Vallone C, et al. Effects of unilateral ovariectomy in female fertility outcomes; gynecologic endocrinology and reproductive medicine. *Arch Gynecol Obstet*. 2014;290:349–53.
7. Practice Committee of the American Society for Reproductive Medicine in collaboration with the Society of Reproductive Surgeons. Pathogenesis, consequences, and control of peritoneal adhesions in gynaecologic surgery: a committee opinion. *Fertil Steril*. 2006;86(Suppl 4):S1–S5.
8. Bisset AF. Appendectomy in Scotland: a 20-year epidemiological comparison. *J Public Health Med*. 1997;19:213–8.
9. Primatesta P, Goldacre MJ. Appendectomy for acute appendicitis and for other conditions: an epidemiological study. *Int J Epidemiol*. 1994;23:155–60.
10. Donnelly NJ, Semmens JB, Fletcher DR, Holman CD. Appendectomy in Western Australia: profile and trends, 1981–1997. *Med J Aust*. 2001;175:15–8.
11. Wei L, MacDonald T, Shimi S. Association between appendectomy in females and subsequent pregnancy rate: a cohort study. *Fertil Steril*. 2012;98(2):401–5.
12. Lehmann-Willenbrock EL, Meckea H, Riedel H-H. Sequelae of appendectomy, with special reference to intra-abdominal adhesions, chronic abdominal pain, and infertility. *Gynecol Obstet Invest*. 1990;29:241–5.
13. Levrant SG, Bieber EJ, Barnes RB. Anterior abdominal wall adhesions after laparotomy or laparoscopy. *J Am Assoc Gynecol Laparosc*. 1997;4:353–6.

14. Lalos O. Risk factors for tubal infertility among infertile and fertile women. *Eur J Obstet Gynecol Reprod Biol.* 1988;29:129–36.
15. Cromartie AD, Kovalcik PF. Previous appendectomy does not predispose to right-sided ectopic pregnancies. *Arch Surg.* 1978;113:905.
16. Nordenskjold F, Ahlgren M. Risk factors in ectopic pregnancy. Results of a population-based case-control study. *Acta Obstet Gynecol Scand.* 1991;70:575–9.
17. Michalas S, Minaretzis D, Tsionou C, Maos G, Kioses E, Aravantinos D. Pelvic surgery, reproductive factors and risk of ectopic pregnancy: a case controlled study. *Int J Gynaecol Obstet.* 1992;38:101–5.
18. Thompson WM, Lynn HB. The possible relationship of appendicitis with perforation in childhood to infertility in women. *J Pediatr Surg.* 1971;6:458–61.
19. Puri P, Guiney EJ, O'Donnell B, et al. Effects of perforated appendicitis in girls on subsequent fertility. *Br Med J.* 1984;288:25–6.
20. Puri P, McGuinness EPJ, Guiney EJ. Fertility following perforated appendicitis in girls. *J Pediatr Surg.* 1989;24(6):547–9.
21. Forsell P, Pieper R. Infertility in young women due to perforated appendicitis? *Acta Chir Scand Suppl.* 1986;530:59–60.
22. Coste J, Job-Spira N, Fernandez H, et al. Risk factors for ectopic pregnancy: a case-control study in France, with special focus on infectious factors. *Am J Epidemiol.* 1991;133:839–49.
23. Andersson R, Lambe M, Bergstrom R. Fertility patterns after appendectomy: historical cohort study. *BMJ.* 1999;318:963–7.
24. Urbach DR, Marrett LD, Kung R, et al. Association of perforation of the appendix with female tubal infertility. *Am J Epidemiol.* 2001;153:566–71.
25. Powley PH. Infertility due to pelvic abscess and pelvic peritonitis in appendicitis. *Lancet.* 1965;1:27–9.
26. Geerdsen J, Hansen JB. Incidence of sterility in women operated on in childhood for perforated appendicitis. *Acta Obstet Gynecol Scand.* 1977;56:523–4.
27. Trimpos-Kemper T, Trimpos B, van Halle E. Etiological factors in tubal infertility. *Fertil Steril.* 1982;37:384–8.
28. Wiig JN, Janssen CW, Fuglesang P, et al. Infertility as a complication of perforated appendicitis: late follow-up of a clinical series. *Acta Chir Scand.* 1979;145:409–10.
29. Mueller BA, Daling JR, Moore DE, et al. Appendectomy and the risk of tubal infertility. *N Engl J Med.* 1986;315:1506–8.
30. Mastroianni L Jr. Tubal occlusion. In: Keller PJ, editor. *Female Infertility.* Basel: Karger; 1978. pp. 114–31.
31. Cloud DT. Appendicitis. In: Holder TM, Ashcraft KW, editors. *Pediatric surgery.* Philadelphia: Saunders; 1980. p. 506.
32. Birkenfeld AS, Brzezinski A, Schenker JG. Post appendectomy mechanical sterility. *Acta Eur Fertilitatis.* 1982;13:173–6.
33. Becker VM, Silver S, Seufert R, Muensterer JO. The Association of Appendectomy, Adhesions, Tubal Pathology, and Female Infertility. *JSLs.* 2019;23(1):e2018.00099.
34. Singh-Ranger D, Sanusi A, Hamo I. Coliform pyosalpinx as a rare complication of appendectomy: a case report and review of the literature on best practice. *J Med Case Rep.* 2008;2:97.
35. Niyogi A, Dalton J, Clarke S, et al. Recurrent unilateral hydrosalpinx: a rare complication of acute perforated appendicitis. *Arch Gynecol Obstet.* 2009;280:835.
36. Limberg J, Ginsburg H, Lala S, Tomita S. Recurrent pelvic infections and salpingitis after appendicitis. *J Pediatr Adolesc Gynecol.* 2015;28(6):e177–e8.
37. Vyas R, Sides C, Klein D, et al. The ectopic appendicolith from perforated appendicitis as a cause of tubo-ovarian abscess. *Pediatr Radiol.* 2008;38:1006.
38. Lunderoff P, Hahlin M, Kallfelt B, Thorburn J, Lindblom B. Adhesion formation after laparoscopic surgery in tubal pregnancy: a randomized trial versus laparotomy. *Fertil Steril.* 1991;55:911–5.
39. De Wilde RL. Goodbye to late bowel obstruction after appendectomy. *Lancet.* 1991;338:1012.
40. Vrijland WW, Jeekel J, van Geldorp HJ, Swank DJ, Bonjer HJ. Abdominal adhesions Intestinal obstruction, pain, and infertility. *Surg Endosc.* 2003;17(7):1017–22.
41. Bruhat MA, Mage G, Manhes H, Pouly JL. Laparoscopy procedures to promote fertility ovariolysis and salpingolysis. Results of 93 selected cases. *Acta Eur Fertil.* 1983;14(2):113–5.
42. Surgical and Clinical Research (SCAR) Group, Lower AM, Hawthorn RJ, Clark D, et al. Adhesion-related readmissions following gynaecological laparoscopy or laparotomy in Scotland: an epidemiological study of 24 046 patients. *Hum Reprod.* 2004;19:1877–85.
43. Vrijland WW, Tseng LNL, Eijkman HJM, Hop WCJ, Jakimowicz JJ, Leguit P et al. Less intraperitoneal adhesions due to hyaluronic acid-carboxymethylcellulose membrane: a randomized clinical trial. *Ann Surg.* 2002;235:193–9.
44. Farquhar C, Vandekerckhove P, Watson A, Vail A, Wiseman D. Barrier agents for preventing adhesions after surgery for subfertility. *Cochrane Database Syst Rev.* 2000; <https://doi.org/10.1002/14651858.CD000475>.
45. Canis M, Botchorishvili R, Bourdel N, Gremeau AS, Curinier S, Rabischong B. Pelvic adhesions and fertility: where are we in 2018? *J Visc Surg.* 2018;155(Suppl 1):S11–S5.
46. Lamps LW. Beyond acute inflammation: a review of appendicitis and infections of the appendix. *Diagn Histopathol.* 2008;14(2):68–77.
47. Ekraiyah T, Hashim Y, Elamin M, Erwin PJ, Zarroug AE. The effect of appendectomy in future tubal infertility and ectopic pregnancy: a systematic review and meta-analysis. *J Surg Res.* 2014;192(2):368–374.e1.
48. Wei L, MacDonald T, Shimi S. Association between prior appendectomy and/or tonsillectomy in women and subsequent pregnancy rate: a cohort study. *Fertil Steril.* 2016;106(5):1150–6.
49. Rasmussen T, Fonnes S, Rosenberg J. Long-term complications of appendectomy: a systematic review. *Scand J Surg.* 2018;107(3):189–96.
50. Arnbjornsson E. Relationship between the removal of the non acute appendix and the menstrual cycle. *Ann Chir Gynaecol.* 1983;72:329–31.
51. Arnbjornsson E. Acute appendicitis risk in various phases of the menstrual cycle. *Acta Chir Scand.* 1983;149:603–5.
52. Arnbjornsson E, Bengmark S. Obstruction of the appendix lumen in relation to pathogenesis of acute appendicitis. *Acta Chir Scand.* 1983;149:789–91.

**Publisher's Note** Springer Nature remains neutral with regard to jurisdictional claims in published maps and institutional affiliations.