

## LETTER TO THE EDITOR

# Recurrent COVID-19 pneumonia in the course of chemotherapy: Consequence of a weakened immune system?

To the Editor,

During the currently ongoing coronavirus disease 2019 (COVID-19) pandemic, one of the objectives that the scientific community is pursuing is to understand whether acquired immunity and antibodies positivity against acute coronavirus 2 (severe acute respiratory syndrome coronavirus 2 [SARS-CoV-2]) protect against reinfection.<sup>1,2</sup> Some reports have described re-positivization of nose-pharyngeal swab polymerase chain reaction real time test (NPST), and have discussed possible interpretations for clinical healing or relapse of COVID-19.<sup>3</sup>

Genomic analysis have proved that there is chance of reinfection with different strains rather than the same strain.<sup>4</sup>

Herein, we report a case of recurrent COVID-19 pneumonia in a vulnerable patient.

A 69-year-old man, heavy smoker with history of sudden weight loss (10 kg in 2 months), was hospitalized for persistent fever and diarrhea lasting 2 weeks. NPST for SARS-CoV-2 resulted positive and high-resolution chest tomography (HRCT) revealed bilateral parenchymal consolidations and ground-glass areas (Figure 1). The patient was treated with hydroxychloroquine, lopinavir or ritonavir and then tocilizumab. During hospitalization, histological diagnosis of classic Hodgkin's lymphoma with mixed cellularity was also established.

Fifty days after hospital admission serum analysis has revealed immunoglobulin G (IgG) seroconversion for Sars-Cov-2 (Figure 2).

After three months of hospitalization symptoms resolved, and two consecutive NPST were negative. Therefore, the patient was discharged, and chemotherapy treatment for Hodgkin's lymphoma was initiated.

Forty-one days after discharge, the patient attends a hospital emergency department for fever, dyspnea, anemia (Hgb 6,7 g/dl), and leukopenia (WBC  $2,11 \times 10^3$ ) detected during hematologic follow-up. A new NPST for SARS-CoV-2 was positive, and a subsequent HRCT revealed focal areas of parenchymal hyperdensity, frosted glass appearance located at the peripheral-subpleural level at the basal pyramid of the right lower lobe with thickening of the intra-interlobular septa with a crazy paving picture. Consolidation area with aerial bronchogram, frosted glass adjacent to the apical segment of the left lower lobe. Chemotherapy treatment was suspended and was started the same therapy of the first time. After

64 days of hospitalization pneumonia resolved and the patient was discharged being resulted negative in two consecutive NPST.

A vulnerable population that could be prone to COVID-19 recurrence is certainly oncological and hematological patients also due to immunosuppressive therapies.<sup>5</sup>

Patients with hematological tumors have a 3.5-fold higher risk of severe infection leading to hospitalization in intensive care, mechanical ventilation, and death than those without cancer. Moreover, these patients are at increased risk of COVID 19, partly due to their underlying disease, but also due to elevated age, increased risk of co-morbidity, and enhanced age-related production of angiotensin converting enzyme 2, a key enzyme for coronavirus infectivity.<sup>6,7</sup>

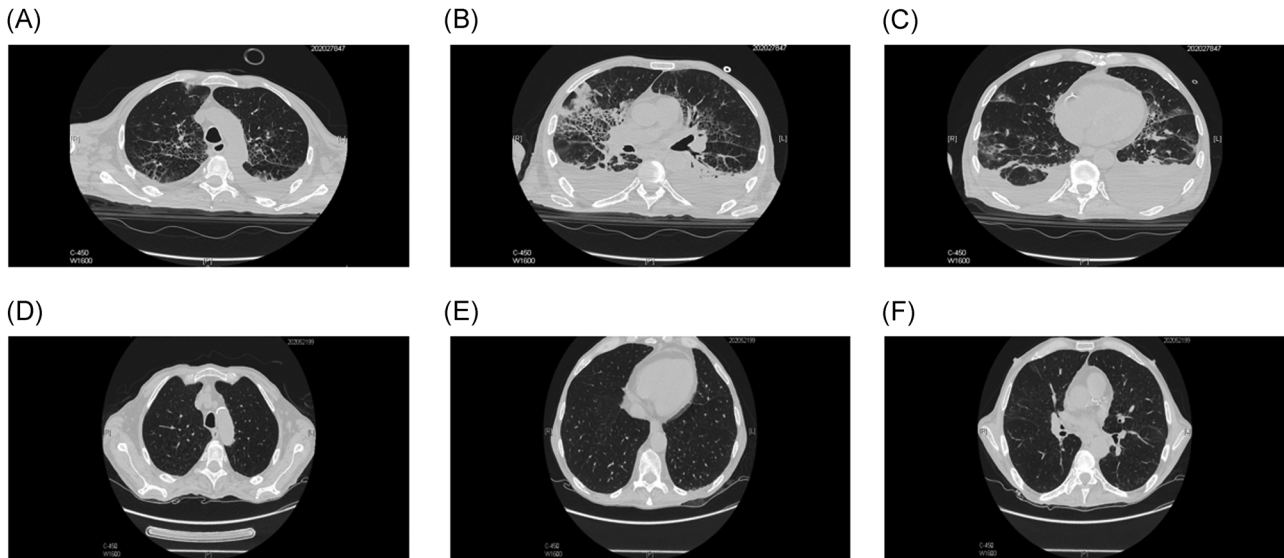
Patients affected by solid and hematological cancer are at an increased risk of recurrent infections by SARS-CoV-2 due to impaired response to infection.<sup>6-8</sup> Accordingly, a study by Long et al.<sup>9</sup> has shown that, unlike antibody responses in individuals with SARS-CoV and MERS-CoV infection lasting up to 24 months, in a high proportion of individuals who recovered from SARS-CoV-2 infection, IgG levels, and neutralizing antibodies decrease within 2-3 months.

It is plausible to think that onco-hematological subjects have memory specific B cell line maturation defects which therefore cannot respond effectively and quickly to a possible reinfection.<sup>10</sup>

Reinfection from COVID-19 in patients with onco-hematological pathology is not asymptomatic but exhibit a wide range of respiratory symptoms in association with fever, HRTC features typical of COVID-19 interstitial pneumonia.<sup>8</sup> The respiratory symptoms in these immunodeficient patients are often associated with multiorgan failure due to the extensive tropism of the virus that requires early diagnosis and medical treatment.<sup>11</sup>

Clinical outcome of these subjects is strongly correlated to older age, which has been shown to be associated with worse in-hospital outcome including higher rate of cardiac complications and death.<sup>12,13</sup>

We can therefore conclude that, since hematological or oncological patients are at higher risk of developing infectious problems due to a deficiency of the immune system, they cannot follow a control protocol for virus negativization that can be attributed to the one generally used for all other patients. We can



**FIGURE 1** HRTC at the emergency room (1a, 1b, 1c) Multiple areas of frosted glass hyperdensity are observed, mainly located in the sub-pleural area with spotted distribution. In the context of these areas there is fibrous thickening of the inter and intra lobular septa (crazy paving pattern) and increase in the size of the vessels. There are some areas of parenchymal consolidation with aerial bronchogram in the context, especially in the right upper lobe and middle lobe. The parenchymal alterations described are localized to all the pulmonary lobes. HRTC at the discharge (1d, 1e, 1f) Previous injuries described have almost completely regressed. HRTC, high-resolution chest tomography

hypothesize the necessity of different guidelines to define healing in onco-hematological patients that could be delineate by at least four consecutive negative buffers.

In our opinion, the start of chemotherapy should be postponed to a safe stage of COVID-19 negativity but if not possible, a follow-up should be recommended: we can hypothesize that patients undergoing chemotherapy will be subjected to two NPST per week for the entire duration of the treatment. The rules of hygiene and protection of these patients should be much stricter, creating special day hospital or extended hospitalization pathways for the entire period of the therapy in such a way as to avoid the slightest contact with any external source that could be extremely dangerous.

**CONFLICT OF INTERESTS**


The authors declare that there are no conflict of interests.

**AUTHOR CONTRIBUTIONS**

Michelangelo Luciani participated in article preparation. All authors materially participated in the research and data collection. Luciano De Biase, Paolo Martelletti, and Georgio Sesti have approved the final article.

**ETHICS STATEMENT**

Written informed consent was obtained by the patient for publication of this case report and accompanying images. Prot. n. 52 SA\_2020 del Registro Pareri Rif. CE 5773\_2020.



**FIGURE 2** Timeline of severe acute respiratory syndrome coronavirus 2 infection. IgG, immunoglobulin G; PCR, polymerase chain reaction

Michelangelo Luciani MD<sup>1</sup>   
 Enrico Bentivegna MD<sup>1</sup>   
 Valerio Spuntarelli MD<sup>2</sup>  
 Piera Amoriello Lamberti MD<sup>1</sup>  
 Giulio Cacioli MD<sup>3</sup>  
 Flavia Del Porto PhD<sup>1</sup>   
 Giorgio Sesti PhD<sup>1</sup>  
 Paolo Martelletti PhD<sup>2</sup>   
 Luciano De Biase PhD<sup>2,4</sup>

<sup>1</sup>Internal Medicine Unit, Department of Clinical and Molecular Medicine, Faculty of Medicine and Psychology, Sant'Andrea University Hospital, Sapienza University, Rome, Italy

<sup>2</sup>Emergency Medicine COVID-19 Unit, Department of Clinical and Molecular Medicine, Faculty of Medicine and Psychology, Sant'Andrea University Hospital, Sapienza University, Rome, Italy

<sup>3</sup>Cardiology Unit, Department of Clinical and Molecular Medicine, Faculty of Medicine and Psychology, Sant'Andrea University Hospital, Sapienza University, Rome, Italy

<sup>4</sup>Heart Failure Unit, Department of Clinical and Molecular Medicine, Faculty of Medicine and Psychology, Sant'Andrea University Hospital, Sapienza University, Rome, Italy

#### Correspondence

Michelangelo Luciani, MD, Internal Medicine Unit, Department of Clinical and Molecular Medicine, Faculty of Medicine and Psychology, Sant'Andrea University Hospital, Sapienza University, Via di Grottarossa, 1035-1039, Rome 00189, Italy.  
 Email: [michelangelo.luciani@uniroma1.it](mailto:michelangelo.luciani@uniroma1.it)

#### ORCID

Michelangelo Luciani  <http://orcid.org/0000-0002-6038-8874>

Enrico Bentivegna  <http://orcid.org/0000-0001-6655-9905>

Flavia Del Porto  <http://orcid.org/0000-0001-9041-3543>

Paolo Martelletti  <http://orcid.org/0000-0002-6556-4128>

#### REFERENCES

- Kirkcaldy RD, King BA, Brooks JT. COVID-19 and postinfection immunity: limited evidence, many remaining questions. *JAMA*. 2020;323:2245. <https://doi.org/10.1001/jama.2020.7869>
- Roy S. COVID-19 reinfection: myth or truth? *SN Compr Clin Med*. 2020;2:710-713. <https://doi.org/10.1007/s42399-020-00335-8>
- Bentivegna E, Sentimentale A, Luciani M, Speranza ML, Guerritore L, Martelletti P. New IgM seroconversion and positive RT-PCR test after exposure to the virus in recovered COVID-19 patient. *J Med Virol*. 2020;jmv.26160.
- Tillett RL, Sevinsky JR, Hartley PD, et al. Genomic evidence for reinfection with SARS-CoV-2: a case study. *The Lancet*. 2020. [https://doi.org/10.1016/S1473-3099\(20\)30764-7](https://doi.org/10.1016/S1473-3099(20)30764-7)
- Tan L, Wang Q, Zhang D, et al. Lymphopenia predicts disease severity of COVID-19: a descriptive and predictive study. *Signal Transduct Target Ther*. 2020;5:33. <https://doi.org/10.1038/s41392-020-0148-4>
- Office for National Statistics. Cancer registration statistics, England, 2013. *Stat Bull*. 2015;196.
- Vaduganathan M, Vardeny O, Michel T, McMurray JJV, Pfeffer MA, Solomon SD. Renin-angiotensin-aldosterone system inhibitors in patients 198 with covid-19. *N Engl J Med*. 2020;382:1653-1659. <https://doi.org/10.1056/NEJMs2005760>
- Liang W, Guan W, Chen R, et al. Cancer patients in SARS-CoV-2 infection: a nationwide analysis in China. *Lancet Oncol*. 2020;21:335-337. [https://doi.org/10.1016/S1470-2045\(20\)30096-6](https://doi.org/10.1016/S1470-2045(20)30096-6)
- Long QX, Tang XJ, Shi QL, et al. Clinical and immunological assessment of asymptomatic SARS-CoV-2 infections. *Nat Med*. 2020;26:1200-1204. <https://doi.org/10.1038/s41591-020-0965-6>
- Cox RJ, Brokstad KA. Not just antibodies: B cells and T cells mediate immunity to COVID-19. *Nat Rev Immunol*. 2020;20:581-582. <https://doi.org/10.1038/s41577-020-00436-4>
- Spuntarelli V, Luciani M, Bentivegna E, et al. COVID-19: is it just a lung disease? A case-based review. *SN Compr Clin Med*. 2020;2:1-6. <https://doi.org/10.1007/s42399-020-00418-6>
- Bentivegna E, Luciani M, Spuntarelli V, et al. Extremely severe case of COVID-19 pneumonia recovered despite bad prognostic indicators: a didactic report. *SN Compr Clin Med*. 2020;2:1204-1207. <https://doi.org/10.1007/s42399-020-00383-0>
- Arcari L, Luciani M, Cacciotti L, et al. Incidence and determinants of high-sensitivity troponin and natriuretic peptides elevation at admission in hospitalized COVID-19 pneumonia patients. *Intern Emerg Med*. 2020;15:1467-1476. <https://doi.org/10.1007/s11739-020-02498-7>