

Giant Aortic Arch Aneurysm in Elderly Patient

Stefano Sechi^{1*}, Angelo De Luca², Tommaso Dezi³, Maurizio Taurino³ and Riccardo Sinatra²

¹"ParideStefanini" Department Policlinico "Umberto I", "Sapienza" Università di Roma, Rome, Italy

²Cardiac Surgery Department, OspedaleSant'Andrea, "Sapienza" Università di Roma, Rome, Italy

³Vascular Surgery Department, OspedaleSant'Andrea, "Sapienza" Università di Roma, Rome Italy

Abstract

Here we present you a Type II of Crawford classification aortic aneurysm. Our patient 89-year-old woman with history of hypertension, diabetes mellitus, smoking habits and polyposis of descending/sigmoid colon came to our attention for rectorrhagia, asthenia, dyspnoea and dizziness.

A computer tomography exam revealed an aortic arch aneurysm, aortic ectasia at a level of aortic hiatus and infra-renal aortic aneurysmal dilation.

In accord to aortic team meeting and patient decision, to refer this lady to medical therapy instead to surgery/hybrid treatment for age patient, comorbidities and high mortality relates to intervention. Aortic arch pathologies are unusual and their treatment is challenging.

The aetiology of aortic arch diseases is congenital, chronic, post traumatic, inflammatory, infectious, mechanical and anastomatic, but most frequently is degenerative. Furthermore, the improvement in diagnostic imaging and the aging populations, aortic arch aneurysms have increasingly diagnosed.

The incidence of aortic arch diseases is 10-11% and many patients were asymptomatic. Otherwise, many patients came to hospital with catastrophic, life-threatening events and urgent treatment is required.

Despite the progress and new technologies have produced new therapeutic options for both cardiac and vascular surgeons is important to highlight the primary role of the aortic team, an interdisciplinary assessment, to find the best tailored treatment, both in acute and chronic setting, for the interest of each patient.

Keywords: Aorta; Aortic; Arch aneurysm

Case Presentation

We report a case of an 89-year-old woman with a past medical history of hypertension, diabetes mellitus, smoking habits, and polyposis of descending and sigmoid colon. She came to our attention for rectorrhagia, asthenia, dyspnea and dizziness within the last 4 days.

A total body Computer Tomography (CT) was made at the admission. The exam revealed giant distal aortic arch aneurysm (12 cm), aortic aneurysm at level of aortic hiatus and infra-renal aortic aneurysm (Figure 1) (Type II of Crawford classification) with no signs of rupture or dissection nor evidence of bleeding. There are no compression phenomena of the esophagus, trachea, left pulmonary artery and lower lobe of the left lung (Figure 2). The aetiology of this specific case is very likely atherosclerotic.

In accord to aortic team meeting and patient decision, we refer this lady to medical therapy instead surgery/hybrid treatment for age patient, comorbidities and high mortality relates to intervention and led a follow-up with CT scan exam every twelve months.

***Corresponding author:** Stefano Sechi, "ParideStefanini" Department Policlinico "Umberto I", "Sapienza" Università di Roma, 00185 Rome, Italy, Tel: +39 0633775593; Fax +39 0633776317 E-mail: s.sechi@uniroma1.it

Received Date: December 03, 2020

Accepted Date: December 11, 2020

Published Date: December 18, 2020

Citation: Sechi S, De Luca A, Dezi T, Taurino M, Sinatra R (2020) Giant Aortic Arch Aneurysm in Elderly Patient. J Case Repo Imag 4: 028.

Copyright: © 2020 Sechi S, et al. This is an open-access article distributed under the terms of the Creative Commons Attribution License, which permits unrestricted use, distribution, and reproduction in any medium, provided the original author and source are credited.

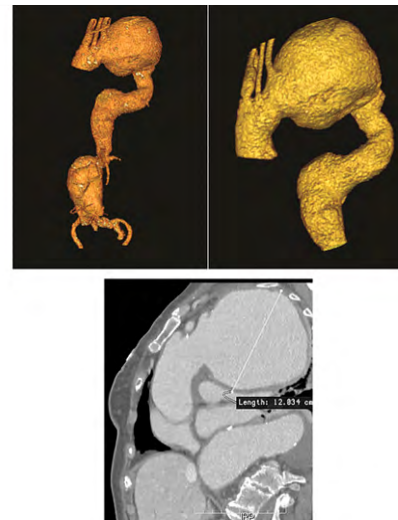


Figure 1: Computer tomography 3D reconstruction of Crawford Type II aortic aneurysm. Maximum diameter was 12 cm at level of aortic arch.

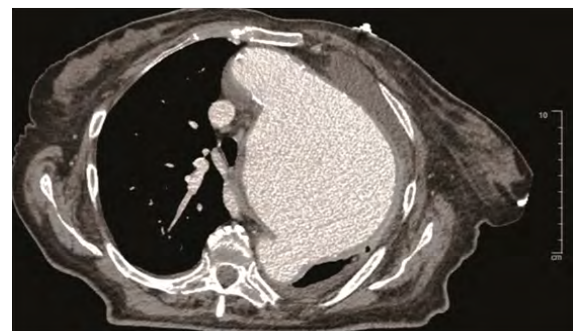


Figure 2: Computer tomography image showed compression phenomena of the left thoracic structures.

Discussion

Aortic aneurysm is defined as a permanent focal or extensive dilatation of the aorta that involves all layers of the aortic wall with a diameter of the vessel is at least 50% greater than the normal size. The aetiology of the aortic arch aneurysm is varied. The main causes are congenital, post traumatic, inflammatory, infectious, mechanical and anastomotic, but most frequently is degenerative [1].

The aortic arch aneurysms have been increasingly diagnosed for the incremental usage of diagnostic imaging and the increase aging populations, but there is no controlled trial either prior study that specifically looked at the natural history and the expansion rate of aortic arch disease [2].

Risk factors for growing aortic diameter include age, female gender, chronic obstructive airway disease, hypertension, aortic diameter and a family history of aneurysms. The progressive increment of aortic arch size is often asymptomatic process and may lead to various scenarios. The worst complications represent the rupture and dissection. Davies and co workers reported an aortic expansion rate of 1 mm per year and a yearly rupture risk of 6.9% in aneurysms with more than 6 cm of diameter [3].

Yiu, et al. in their study showed, in a cohort of 45 patients, an aneurysmal growth rate about 2.5 mm per years with 22% of aneurysm rupture in relationship with maximum diameter of 6.5 cm and also with hyperlipidemia [4].

It is important to underline that growth rates vary according to the underlying disease and the absolute size of the aneurysm and risk of aneurysm rupture increases generally with aneurysm size. The prevalence of aortic aneurysms in the general population is difficult to determine because of under estimated of these aneurysms in mortality statistics. In 2002, the prevalence was 16.3 per 100,000 per year for men and 9.1 per 100,000 per year for women [1,5].

The most common anatomical location of thoracic aortic aneurysms is the ascending aorta and/or aortic root in 51% of cases, while the descending aorta is affected in approximately 38%. Specifically the incidence of aortic arch diseases is 11% and many patients were asymptomatic [6,7].

Otherwise, many patients came to hospital with catastrophic, life-threatening events and urgent treatment is required [1]. Progress and new technologies have produced new therapeutic options for both cardiac and vascular surgeons. The treatment of aortic arch disease may be surgical, hybrid repair or endovascular repair but it remains challenging [8,9].

Preoperative management of aortic arch pathology and risk stratification for each patient allow to take the best treatment choice.

In the literature some case reports showed an aortic arch aneurysm that was treated by surgical or hybrid/interventional fashion. Hela, et al. reported a case of 77-years old woman affected by ascending aorta and aortic arch aneurysm with a maximum diameter of 13.97 cm at level of ascending aorta without history of hypertension and cardiac symptoms or family history. This patient was treated by open surgery. Their patient died 4 days after surgery by multi-organ failure [7].

Desai, et al. in their work showed a 54-year-old man with 12 cm fusiform aneurysm of the distal aortic arch. Open surgery was made and the patient was discharged on the 10th post operative day without complications [10].

Saito and coworkers reported a 86-year-old woman referred for aortic arch aneurysm with a maximum diameter of 11 cm. For patientage, they decided to treat this patient by endovascular repair.

The patient required prolonged hospitalization because of muscolar atrophy by age and disuse [11]. Zhou, et al. reported a combined approach of open surgical debranching followed by antegrade stent grafting to treat the rest of aortic disease [12].

In our report the patient decided to not undergo any surgical or interventional treatment. In addition comorbidities and clinical presentation made a very high operative risk of mortality and morbidity. Moreover, our case showed one of the biggest distal aortic arch aneurysm in literature.

The improvement of surgical techniques had made open surgery more safely and decreased the perioperative morbidity and mortality rate, but new endovascular solutions in the treatment of aortic pathologies continue to improve the applicability of these techniques to each specific patient anatomies. In conclusion, is important to highlight the primary role of the aortic team, an inter disciplinary assessment, to find the best tailored treatment, both in acute and chronic setting, for the interest of each patient.

References

1. Kouchoukos NT, Kirklin JW (2013) Kirklin/Barratt-Boyes cardiac surgery: Morphology, diagnostic criteria, natural history, techniques, results, and indications. Elsevier/Saunders, Pennsylvania, USA.
2. Czerny M, Schmidli J, Adler S, van den Berg JC, Bertoglio L, et al. (2019) Current options and recommendations for the treatment of thoracic aortic pathologies involving the aortic arch: An expert consensus document of the European Association for Cardio-Thoracic Surgery (EACTS) and the European Society for Vascular Surgery (ESVS). *Eur J Cardiothorac Surg* 55: 133-162.
3. Davies RR, Goldstein LJ, Coady MA, Tittle SL, Rizzo JA, et al. (2002) Yearly rupture or dissection rates for thoracic aortic aneurysms: Simple prediction based on size. *Ann Thorac Surg* 73: 17-27.
4. Yiu RS, Cheng SW (2016) Natural history and risk factors for rupture of thoracic aortic arch aneurysms. *J Vasc Surg* 63: 1189-1194.
5. Cheng SWK (2016) Aortic arch pathologies-incidence and natural history. *Gefasschirurgie* 21: 212-216.
6. Isselbacher EM (2005) Thoracic and abdominal aortic aneurysms. *Circulation* 111: 816-828.
7. Hela BJ, Nesrine G, Taieb C, Abdessalem H, Aiman D, et al. (2016) Giant ascending aortic aneurysm complicated by a tracheal compression: A case report and review of the literature. *J Clin Exp Cardiol* 7.
8. Rommens KL, Estrera AL (2019) Contemporary management of aortic arch aneurysm. *Semin Thorac Cardiovasc Surg* 31: 697-702.
9. Cazavet A, Alacoque X, Marcheix B, Chaufour X, Rousseau H, et al. (2016) Aortic arch aneurysm: Short- and mid-term results comparing open arch surgery and the hybrid procedure†. *Eur J Cardiothorac Surg* 49: 134-140.
10. Desai D, Kothari J, Brahmabhatt B (2019) Management of intact giant fusiform aneurysm of distal aortic arch with impending risk of rupture using midline sternotomy. *Indian Journal of Vascular and Endovascular Surgery* 6: 320-323.
11. Saito N, Kimura T, Toma M, Kita T, Inoko M, et al. (2005) Images in cardiovascular medicine. Endovascular treatment of a giant aortic arch aneurysm with a triple-branched stent graft. *Circulation* 112: 151-152.
12. Zhou W, Reardon ME, Peden EK, Lin PH, Bush RL, et al. (2006) Endovascular repair of a proximal aortic arch aneurysm: a novel approach of supra-aortic debranching with antegrade endograft deployment via an anterior thoracotomy approach. *J Vasc Surg* 43: 1045-1048.



Henry Journal of Acupuncture & Traditional Medicine

Henry Journal of Anesthesia & Perioperative Management

Henry Journal of Aquaculture and Technical Development

Henry Journal of Cardiology & Cardiovascular Medicine

Henry Journal of Case Reports & Imaging

Henry Journal of Cell & Molecular Biology

Henry Journal of Tissue Biology & Cytology

Henry Journal of Clinical, Experimental and Cosmetic Dermatology

Henry Journal of Diabetes & Metabolic Syndrome

Henry Journal of Emergency Medicine, Trauma & Surgical Care

Henry Journal of Haematology & Hemotherapy

Henry Journal of Immunology & Immunotherapy

Henry Journal of Nanoscience, Nanomedicine & Nanobiology

Henry Journal of Nutrition & Food Science

Henry Journal of Obesity & Body Weight

Henry Journal of Cellular & Molecular Oncology

Henry Journal of Ophthalmology & Optometry

Henry Journal of Perinatology & Pediatrics

Submit Your Manuscript: <https://www.henrypublishinggroups.com/submit-manuscript/>