

## Erectile function recovery after laparoscopic decompression of pudendal artery and nerve: a documented case report

Martina Maggi<sup>1</sup>, Giacomo Maria Pirola<sup>2</sup>, Fabienne Absil<sup>3</sup>, Elea De Plaen<sup>4</sup>, Augusto Mosca<sup>5</sup>, Stefano Salciccia<sup>1</sup>, Alessandro Sciarra<sup>1</sup>, Renaud Bollens<sup>4,6</sup>

<sup>1</sup>Department of Urology, Sapienza Rome University, Policlinico Umberto I, Rome, Italy

<sup>2</sup>Department of Urology, Usl Toscana Sud Est, San Donato Hospital, Arezzo, Italy

<sup>3</sup>Department of Gynecology, Epicura Ath Hospital, Ath, Belgium

<sup>4</sup>Department of Urology, Wallonie Picarde Hospital, Tournai, Belgium

<sup>5</sup>Department of Urology, Frascati Hospital, Rome, Italy

<sup>6</sup>Department of Urology, Université Nord de France, St. Phillibert Hospital, GHICL, Lille, France

**Citation:** Maggi M, Pirola GM, Absil F, et al. Erectile function recovery after laparoscopic decompression of pudendal artery and nerve: a documented case report. Cent European J Urol. 2020; 73: 569-571.

### Article history

Submitted: Dec. 29, 2019

Accepted: Nov. 16, 2020

Published online: Dec. 3, 2020

### Corresponding author

Giacomo Maria Pirola  
Usl Toscana Sud Est  
San Donato Hospital  
Department of Urology  
Arezzo, Italy  
phone +39 349 1484489  
gmo.pirola@gmail.com

The aim of this article is to report the effectiveness of laparoscopic decompression of pudendal artery (PA) and nerve for erectile dysfunction (ED) restoration. A 32-year-old man presented with a long-term complaint of ED not responsive to medical therapy. Endocrine screening and neurological evaluation did not show any abnormalities. Color Doppler ultrasound revealed the absence of blood flow in the right PA. After failure of conservative treatments and in accordance to the patient's desire, laparoscopic pudendal artery decompression was performed. The patient reported significant amelioration of ED one month after surgery. At 8-months follow-up, Doppler ultrasound showed complete revascularization of the right PA.

**Key Words:** erectile dysfunction ↔ pudendal nerve entrapment ↔ laparoscopic surgery

## CASE PRESENTATION

A 32-year-old Caucasian man with no previous remarkable medical history presented to the hospital with a complaint of erectile dysfunction (ED) not responsive to medical therapy [phosphodiesterase type 5 (PDE-5) inhibitors for the last 3 years], and concomitant poor orgasmic sensation. He also complained of urinary urgency associated with perineal hypoesthesia, particularly on the glans, and testis pain. The symptoms started 13 years ago and have progressively deteriorated.

On physical examination, external genitalia appeared normal, although a reduced temperature

on the glans and dysesthesia of the perineum were documented. Patient's IIEF-5 score was 5. Endocrine screening and neurological evaluation did not reveal any abnormalities.

Color Doppler ultrasound (US) of the pudendal artery (PA) revealed the absence of blood flow in the right PA.

Pudendal nerve (PN) infiltration, under computed tomography (CT) guidance, led to a temporary relief of symptoms.

Since pudendal compression was the suspected etiology causing these symptoms, and in accordance to the patient's wish, right PN and artery decompression was performed through a laparoscopic approach.

## Surgical technique

With the patient under general anesthesia and in an extended Trendelenburg position, we performed a transperitoneal laparoscopic dissection technique. A peritoneal incision was made external to the right umbilical artery, with the preservation of the right vas deferens. The obturator nerve and vein were identified. Then, the internal obturator muscle was visualized and the arcus tendineus of the levator ani muscle was exposed. The fibers of the coccygeus muscle covering the sacrospinous ligament were then cut close to the ischiatic spine and the ligament itself was incised exposing and therefore decompressing the PA and PN entering Alcock's canal. At the end of the decompression, the right PA was noted to be pulsating (Figure 1).

Postoperative complications were not reported and the patient was discharged the day after, with the indication to take tadalafil 5 mg once daily until medical consultation.

As early as 1 month postoperatively, the patient reported improvement in his erectile function and

tadalafil was discontinued. In addition, testicular pain fully subsided after surgery, however the glans dysesthesia persisted.

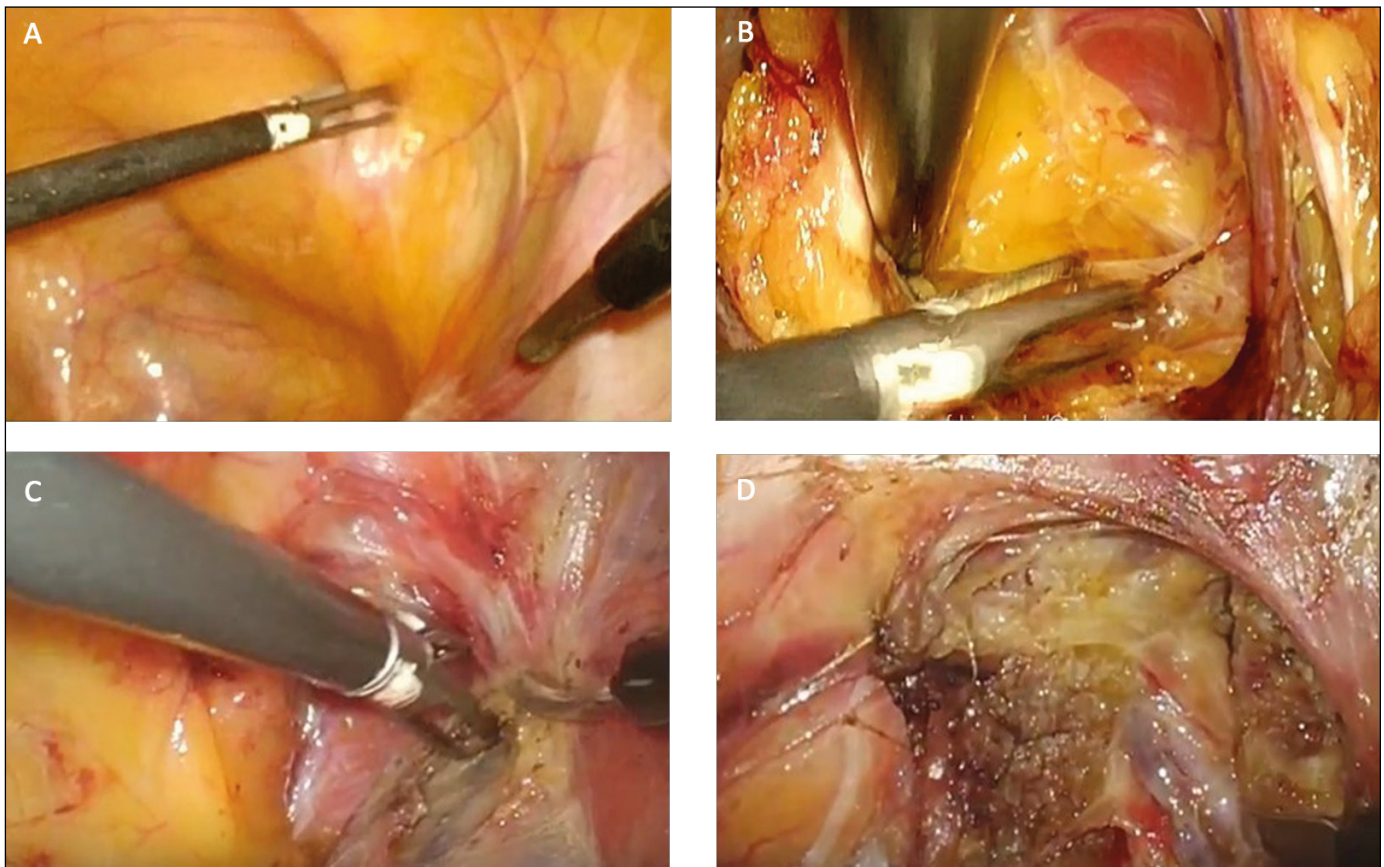
Eight months postoperatively, the Doppler US showed a normal blood flow in the right PA; moreover, the patient continued to report significant improvement in his erectile function (IIEF-5 score of 18).

The patient has been followed for a total of 2 years after surgery, reporting a full recovery of his sexual function, with no additional complaints for the time being.

## DISCUSSION

ED is a worldwide and emerging problem, with a constant increase during the recent years [1].

However, when a rare endocrinologic disorder is excluded, the etiology remains unclear, particularly in young patients. Although PDE-5 inhibitors have revolutionized the treatment of ED since 1998, some patients are resistant to medical treatment (ED is frequently multifactorial or related to both psychogenic and physiological factors) or are not keen on lifelong treatment.



**Figure 1.** Principal steps of laparoscopic PN decompression. **A.** Peritoneal incision lateral to umbilical artery. **B.** Progressive exposition of obturator? vein, internal obturator muscle and tendinous arch of levator ani muscle; **C.** Incision of sacrospinous ligament and coccygeus muscle fibers. **D.** Complete isolation of pudendal artery and nerve from its entrance into deep pelvis to Alcock's canal. Subsequent transposition of pudendal nerve from the ischiatic spine.

Pudendal nerve entrapment (PNE), also known as Alcock's canal syndrome, is a well described cause of perineal pain. Diagnosis is traditionally based on the Nantes criteria [2], centered on pain as main symptom. In our experience, there are many different functional symptoms varying according to the location of PN involvement. The most commonly reported are: anorectal (i.e. sensation of foreign body into the anus, tenesmus), vaginal (i.e. sensation of foreign body into the vagina, burning during and after sexual intercourse), sexual (decrease in orgasm quality, ED, premature ejaculation), and urinary (i.e. burning during micturition or pollakiuria, frequently diagnosed as 'sterile cystitis' or 'chronical prostatitis').

Here, we present an unusual approach to ED treatment. In this case, ED was just one symptomatic presentation of PNE, and the patient's erectile function was completely restored after surgical decompression of the PA and nerve (PDE-5 inhibitors were administered only for the first month after surgery). Poor orgasmic sensation, urinary urgency and skin hypoesthesia in the region of the glans and testis, as well as ED, were all due to chronic compression of the PN.

ED from PNE is described by only a few reports in the current literature. PNE can be caused by a neurogenic mechanism or by compression of the pudendal artery [3, 4].

The penile vascularization is ensured by several branches of the internal PA.

PA and nerve enter the deep pelvis below the sacrosacral ligament and can be therefore compressed at this site together with the PN, leading to chronic neuralgia and reduction of the penile blood supply, therefore causing ED.

After failure of conservative measures, surgical decompression is the only treatment that can achieve symptoms resolution [5].

Recently, Luther et al. reported a case of ED resulting from PNE successfully treated with bilateral pudendal neurolysis through a transgluteal approach [6].

However, as the main concerns about the open surgical techniques described to treat PNE (transperineal, transgluteal, and via the ischioanal fossa) are their invasiveness, difficulty of access and limited visibility, over the last years minimally invasive surgery has been proposed to overcome these limitations [7, 8, 9]. Described by Erdogru et al. in 2014 [7], the laparoscopic approach combines the same effectiveness of trans-gluteal approach with the high-definition visualization of the deep pelvic anatomy, and allowing for an atraumatic and blood-free dissection.

However, this surgery is performed only in few centers of excellence, and outcomes data although promising are overall lacking and not supported by randomized trials.

Based on our experience performing several laparoscopic PN and PA decompressions since 2014, surgical treatment of PNE greatly improves symptoms, with the reversal of ED being the most evident amelioration, as early as the first month after surgery. This is probably related to the vascular origin, differently from neurogenic symptoms which can require up to two years to improve.

Although larger cohorts and prospective trials are needed to validate this approach, this case report shows the effectiveness of PN laparoscopic decompression for ED restoration.

#### CONFLICTS OF INTEREST

The authors declare no conflicts of interest.

#### References

- Hatzimouratidis K, Amar E, Eardley I, et al. European Association of Urology. Guidelines on male sexual dysfunction: erectile dysfunction and premature ejaculation. *Eur Urol.* 2010; 57: 804-814.
- Labat JJ, Riant T, Robert R, Amarengo G, Lefaucheur JP, Rigaud J. Diagnostic criteria for pudendal neuralgia by pudendal nerve entrapment (Nantes criteria). *Neurourol Urodyn.* 2008; 27: 306-310.
- Shafik A. Pudendal canal decompression in the treatment of erectile dysfunction. *Arch Androl.* 1994; 32: 141-149.
- Shafik A. Pudendal artery syndrome with erectile dysfunction: treatment by pudendal canal decompression. *Arch Androl.* 1995; 34: 83-94.
- Robert R, Labat JJ, Bensignor M, et al. Decompression and transposition of the pudendal nerve in pudendal neuralgia: a randomized controlled trial and long-term evaluation. *Eur Urol.* 2005; 47: 403-408.
- Luther RD 3rd, Castellanos ME. Successful treatment of penile numbness and erectile dysfunction resulting from pudendal nerve entrapment. *Urology.* 2019; 134: 228-231.
- Erdogru T, Avci E, Akand M. Laparoscopic pudendal nerve decompression and transposition combined with omental flap protection of the nerve (Istanbul technique): technical description and feasibility analysis. *Surg Endosc.* 2014; 28: 925-932.
- Rey D, Oderda M. The first case of robotic pudendal nerve decompression in pudendal nerve entrapment syndrome. *J Laparoendosc Adv Surg Tech A.* 2015; 25: 319-322.
- Moscatiello P, Carracedo Calvo D, Yupanqui Guerra L, Rivera Martínez ME, Mendiola de la Hoza A, Sánchez Encinas M. Robot-assisted pudendal neurolysis in the treatment of pudendal nerve entrapment syndrome. *Actas Urol Esp.* 2018; 42: 344-349. ■