

Case Report

Immunity and Genetics at the Revolving Doors of Diagnostics in Primary Immunodeficiencies

Francesco Rispoli ¹, Erica Valencic ^{2,*}, Martina Girardelli ², Alessia Pin ², Alessandra Tesser ²,
Elisa Piscianz ², Valentina Boz ¹, Flavio Faletra ³, Giovanni Maria Severini ², Andrea Taddio ^{1,2}
and Alberto Tommasini ^{1,2}

¹ Department of Medical, Surgical and Health Sciences, University of Trieste, 34149 Trieste, Italy; francesco.rispoli@outlook.com (F.R.); valentina.boz@burlo.trieste.it (V.B.); andrea.taddio@burlo.trieste.it (A.T.); alberto.tommasini@burlo.trieste.it (A.T.)

² Department of Pediatrics, Institute for Maternal and Child Health—IRCCS “Burlo Garofolo”, 34137 Trieste, Italy; martina.girardelli@burlo.trieste.it (M.G.); alessia.pin@burlo.trieste.it (A.P.); alessandra.tesser@burlo.trieste.it (A.T.); elisa.piscianz@burlo.trieste.it (E.P.); giovannimaria.severini@burlo.trieste.it (G.M.S.)

³ Department of Diagnostics, Institute for Maternal and Child Health—IRCCS “Burlo Garofolo”, 34137 Trieste, Italy; flavio.faletra@burlo.trieste.it

* Correspondence: erica.valencic@burlo.trieste.it; Tel.: +39-0403785422

Abstract: Primary immunodeficiencies (PIDs) are a large and growing group of disorders commonly associated with recurrent infections. However, nowadays, we know that PIDs often carry with them consequences related to organ or hematologic autoimmunity, autoinflammation, and lymphoproliferation in addition to simple susceptibility to pathogens. Alongside this conceptual development, there has been technical advancement, given by the new but already established diagnostic possibilities offered by new genetic testing (e.g., next-generation sequencing). Nevertheless, there is also the need to understand the large number of gene variants detected with these powerful methods. That means advancing beyond genetic results and resorting to the clinical phenotype and to immunological or alternative molecular tests that allow us to prove the causative role of a genetic variant of uncertain significance and/or better define the underlying pathophysiological mechanism. Furthermore, because of the rapid availability of results, laboratory immunoassays are still critical to diagnosing many PIDs, even in screening settings. Fundamental is the integration between different specialties and the development of multidisciplinary and flexible diagnostic workflows. This paper aims to tell these evolving aspects of immunodeficiencies, which are summarized in five key messages, through introducing and exemplifying five clinical cases, focusing on diseases that could benefit targeted therapy.

Keywords: primary immunodeficiencies; recent thymic emigrants; X-chromosome inactivation; autoinflammatory diseases; lymphoproliferative immune defects; mendelian susceptibility to infections; flow cytometry; next generation sequencing



Citation: Rispoli, F.; Valencic, E.; Girardelli, M.; Pin, A.; Tesser, A.; Piscianz, E.; Boz, V.; Faletra, F.; Severini, G.M.; Taddio, A.; et al. Immunity and Genetics at the Revolving Doors of Diagnostics in Primary Immunodeficiencies. *Diagnostics* **2021**, *11*, 532. <https://doi.org/10.3390/diagnostics11030532>

Academic Editor: Antonio Amoroso

Received: 1 February 2021

Accepted: 14 March 2021

Published: 16 March 2021

Publisher's Note: MDPI stays neutral with regard to jurisdictional claims in published maps and institutional affiliations.



Copyright: © 2021 by the authors. Licensee MDPI, Basel, Switzerland. This article is an open access article distributed under the terms and conditions of the Creative Commons Attribution (CC BY) license (<https://creativecommons.org/licenses/by/4.0/>).

1. Introduction

According to an old paradigm, the possibility of a primary immunodeficiency disease (PID) should be considered in subjects with recurrence of serious infections. Whilst the easy assessment of blood cell count and immunoglobulin levels together with a careful evaluation of clinical data can address the suspicion of PID in many severe cases, the availability of specific immunological phenotyping in the last twenty years of the 20th century led to a significant advance in the diagnosing of this group of disorders [1]. Flow cytometry-based classification also facilitated studies leading to the identification of many genetic errors underlying PIDs. Even after the identification of causative genes for several defects, laboratory immune evaluation remained crucial for diagnosis of many PIDs due to

the prompt availability of the results and to the functional significance of assays that could reflect the severity of the underlying molecular defect.

More recently, the widespread use of molecular genetics greatly increased the capacity to identify PIDs, and correlations between genotypes and phenotypes have begun to be established, raising the question whether it was still justified to base a diagnosis only on a clinical and phenotypical evaluation [2,3].

With improved capability of diagnosing immune defects, a new paradigm of PID emerged, showing that immunodeficiencies can be characterized by autoimmune, lymphoproliferative, and neoplastic symptoms, in addition to infections [4]. Indeed, a search for PID is now recommended in subjects with refractory cytopenia or with multiple autoimmune manifestations. Furthermore, even a single severe infection, especially if it arises from a commensal or unusual pathogen, can raise the suspicion of a PID. Thus, according to a new paradigm, a PID should be considered in subjects with a wide range of infectious, inflammatory, and autoimmune manifestation due to an improper immune function. Even if cytometry laboratories of immunology have evolved improved panels to take into account a wider range of phenotypes [5], immunophenotyping can yield normal results in many cases, and thus, it cannot be used as the sole tool to rule out the diagnosis of a PID, with maybe the exception of Severe Combined Immunodeficiencies (SCIDs).

Conversely, improved molecular diagnostics allowed us to search for disease-causing mutations in hundreds of immune-related genes simultaneously by exploiting next-generation sequencing (NGS) capabilities. Gene panels have been implemented for distinct groups of PIDs and, more recently, clinical exome sequencing has been proposed to analyze hundreds of PID genes at once. Current guidelines recommend moving on from targeted gene panels to clinical exome data, which can be analyzed starting from nearly 400 genetic defects identified in patients with distinct primary immunodeficiency [6]. In the cases in which there is no obvious genetic explanation for the disease, the analysis may be further expanded in silico. The use of targeted gene panels can still be applied in cases in which the clinical suspicion is oriented toward a narrow set of genes, allowing higher sequences coverage and an easier first-line evaluation of results. In the selected case, whole genome sequencing can be preferred due to the possibility of identifying copy number variations, large deletions, and other genomic rearrangements [7], as reported by some authors [8–10], even though it requires complicated analysis given the large amount of data and thus should be performed as a second-line investigation. Overall, exome and genome sequencing give the opportunity to re-analyze data in the light of newly discovered disease-related genes in patients without a genetic diagnosis. However, several pitfalls can hinder the interpretation of genetic results. First, exome sequencing may miss structural defects such as gene inversions or large deletions, and some genes may be poorly covered in NGS, as in the example of *IKBKG* due to the presence of a closely related pseudogene. Moreover, disease-causing mutations present in somatic mosaicism in a proportion of cells can be hardly identified by conventional techniques, as in the case of adult-onset autoimmune lymphoproliferative syndrome. Thus, the appropriate genetic testing should be thoroughly considered based on the strength of clinical suspicion of a given condition. Lastly, genetic studies may yield lots of data of uncertain significance, requiring new immunologic studies for a definite confirmation.

We present case studies to discuss how the diagnostics of PIDs moved from a straightforward sequence, which led from the clinical picture to hematological and flow cytometry diagnostics, to a more articulated multidisciplinary workflow connecting various clinical specialties and requiring the collaboration between laboratory immunologists and geneticists. Of note, in some cases, the knowledge of molecular defects has allowed targeting the diseased mechanism with precision drugs [11–13]. This is especially true for PIDs associated with Gain-of-Function pathways [14] that can be targeted by pharmacological inhibitors, which could be already available as developed to cure cancers [15]. The early detection of such “druggable” disorders is crucial to prevent the development of severe organ damage [16].

By exploiting the discussion of a case series, we present five typical scenarios, highlighting some developments in diagnostics of PIDs. This article could scarcely describe the complex field of PIDs and is not intended to give diagnostic recommendations. It is just meant to discuss how the diagnostics of PIDs is moving in the era of NGS, requiring an intimate collaboration among various specialists in multidisciplinary teams. Some tables are provided to highlight how some key assays such as the measure of recent thymic emigrants (RTE) or the assessment of X-chromosome inactivation (XCI) could contribute together with genetic analysis to the diagnosis of PIDs. Particular attention is paid to disorders that can be effectively treated by hematopoietic stem cell transplantation, gene therapy, or molecularly targeted therapies.

2. Case Presentation

2.1. Case 1. Recent Thymic Emigrants

Case #1 was a firstborn male born at full term after a normal pregnancy without perinatal problems. At the start of weaning, around five months of age, his weight started to grow less. After some months of poor weight growth, he performed a wide range of blood tests that showed normal complete blood count (CBC), hepatic and renal function indices, electrolytes, and no antibodies for celiac disease. The only pathological finding was agammaglobulinemia. The infant had no infections until nine months of age when he was admitted to intensive care with respiratory failure due to interstitial pneumonia caused by *Pneumocystis jirovecii*. Among the investigations for PID, a flow cytometric study of lymphocyte subsets was diagnostic of T-B+ NK-SCID (supplementary materials). Male sex, the period of onset and clinical features, along with typical immunophenotype, were suggestive of X-linked SCID (X-SCID). As expected, genetic tests revealed an *IL2RG* gene mutation (c.741insG:p.S248fs) [17], confirming the clinical suspicion. At the age of 11 months, the patient received a bone marrow transplant with good outcome and no significant complications.

2.2. Case 2. X-Linked PIDs

A male baby was born by spontaneous delivery after a full-term pregnancy complicated by intrauterine growth restriction. Given his low birth weight, he was admitted to the neonatal unit for clinical observation and initiation of early feeding. At approximately three hours of life, the neonate manifested diffuse petechiae, predominantly in the trunk and back, and a left parietal cephalohematoma. Investigations for bleeding showed normal coagulation function but severe isolated thrombocytopenia (13,000/mm³, MPV 8.2 fL). Bone marrow aspirate was normocellular and showed no blastic cells, rare megakaryocytes of variable dysmorphic appearance, and no signs of dyserythropoiesis. Familial history was contributive for a maternal uncle death at two years of age from cerebral hemorrhage due to an undefined congenital platelet disease (genetic investigations were not available at the time), and a great-uncle death at four months of age from sepsis. In the first days of life, the infant developed fever, general decay, and jaundice, so he started empirical antibiotics and phototherapy. Due to the persistence of unexplained jaundice after microbiological and radiologic examination, a liver biopsy was performed, which showed a histologic picture compatible with either herpes virus hemophagocytic syndrome or maternal GVHD (graft-versus-host disease), which was supportive of an underlying immunodeficiency. Flow cytometry analysis performed in the suspicion of Wiskott–Aldrich syndrome (WAS) showed absent WASP expression (supplementary materials). Directed sequencing of the *WAS* gene on the X-chromosome led to the detection of a likely pathogenic mutation (c.708delT:p.A236AfsX24), which has never been described before (supplementary materials). The evidence of a skewed XCI pattern in the mother's peripheral blood cells (supplementary materials), together with the pedigree compatible with X-linked disorders, eventually confirmed the pathogenic role of the mutation. Unfortunately, the boy died from transplant-related complication with severe infections.

2.3. Case 3. Immunodeficiencies with Autoinflammation

A 7-year-old girl came to our attention for hepatopathy with positive antinuclear antibodies (ANA) but with normal results from liver biopsy. She also complained of recurrent aphthous stomatitis since the age of four years, with some episodes complicated by oral thrush and painful swallowing. She had been previously evaluated with the suspicion of Behçet disease, but without reaching a definite diagnosis. In the last years, she also presented a couple of episodes of paronychia, which had been considered due to the girl's habit of biting the skin of her fingers. When she referred to our hospital, laboratory investigations revealed increased aminotransferase, raised erythrocyte sedimentation rate (ESR), high-titer ANA, positive direct Coombs test, and positive anti-double-stranded DNA antibodies. Furthermore, a strikingly positive interferon score was measured in her peripheral blood (supplementary materials). A diagnosis of systemic lupus erythematosus (SLE) was made and a treatment with mycophenolate mofetil (MMF) and hydroxychloroquine started, together with on-demand fluconazole for oral candidiasis. Whilst both aminotransferase and ESR dropped to nearly normal levels, episodes of oral aphthosis with superimposed oral candidiasis persisted, as well as recurrent paronychia. Colchicine was added to reduce the recurrence of oral aphthosis. Furthermore, a PID was suspected, and targeted genetic testing was performed (supplementary materials), revealing c.862A>G mutation in the *STAT1* gene (p.T288A, rs387906765), which confers an increased activity of the STAT1 protein [18]. This condition, called "STAT1 Gain-of-function" (GOF) syndrome, is in fact characterized by the presence of chronic mucocutaneous candidiasis in almost all cases and autoimmune disease in a great proportion of affected patients [19]. Based on this genetic diagnosis, a treatment with a JAK 1/2 inhibitor (baricitinib, 2 mg once daily) was started instead of MMF, obtaining good control of the disease.

2.4. Case 4. Immunodeficiencies with Lymphoproliferation

The fourth patient is a woman with a clinical history of recurrent respiratory infections, in some cases requiring hospitalization, and a few episodes of colitis, up to 20 years of age. After a period of well-being that lasted about ten years, pulmonary and urinary infections began to recur. Immunological tests were performed that showed an IgA defect (23 mg/dL). In addition to recurring infections, she developed alopecia areata at ten years of age and eczematous lesions on knees and genitals during puberty. Over various consultations, several non-specific findings were noted: mild Diffusing capacity of the Lungs for Carbon monoxide (DLCO) reduction, dermal hyperplasia, mild gastric atrophy, mild colic eosinophilic inflammation, and a peculiar hypertrophy of the lingual tonsil. Further laboratory investigations revealed a mild lymphopenia (960/mcL) with B-cell defect. The woman was referred to our center by an Ear Nose and Throat specialist because of the uncommon finding of a lingual tonsil hypertrophy. Immunophenotyping evidenced an inversion of the CD4/CD8 ratio and increase of senescent (CD57 + CD45RA+) CD8 T cells, which, together with low IgA values, supported the hypothesis of a primary immunodeficiency (supplementary materials). Furthermore, lingual tonsil hypertrophy was noticed as a sign of abnormal lymphoproliferation. A genetic panel for PID predominantly associated with hypogammaglobulinemia evidenced the presence of the variant c.G454A:p.A152T in the *PIK3CD* gene (rs138463758) (supplementary materials), which was consistent with a possible diagnosis of activated phosphoinositide 3-kinase δ syndrome (APDS). Again, we were faced with a variant of uncertain significance (VUS), the pathogenicity of which had to be confirmed. Knowing the specific molecular pathway to which the mutated gene's protein encoded belongs, it is possible to use ancillary tests to evaluate the pathway's expression of molecules. In our case, the mutation was in *PIK3CD*, which is a molecule of the PI3K/AKT/mTOR/S6K pathway, so a test was performed to evaluate the functionality of the cascade, namely the phosphorylation of the downstream molecule S6 in B cells, which proved to be high (S6 more phosphorylated) [20] and therefore indicated that there was increased *PIK3CD* activity: that means GOF mutation. Of note, IgA deficiency, increase of senescent CD8 and lymphoproliferative features are all typical features of APDS in

addition to recurrent infections [21]. A therapeutic attempt with theophylline 200 mg daily was attempted for six months, based on a previous experience in a younger case with type II APDS (due to mutations in *PIK3R1* [22]), however without a clear benefit. The opportunity of starting a treatment with leniolisib, a specific inhibitor of PIK3CD, is currently under evaluation.

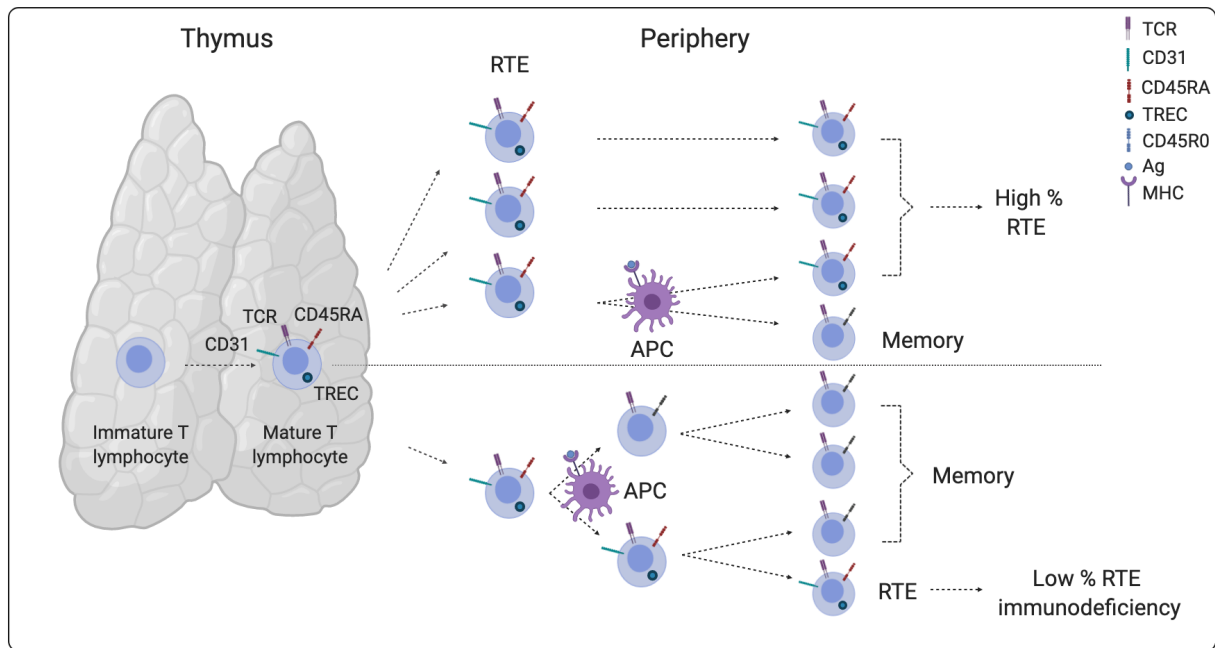
2.5. Case 5. Susceptibility to: EBV, Mycobacteria, Candida, Warts

Case #5 is about an 18-year-old boy patient admitted for mononucleosis with pulmonary, hepatic, and cerebral involvement with seizures. Polymerase chain reaction (PCR) examination on blood and bronchoalveolar lavage demonstrated the presence of high viral load Epstein–Barr virus (EBV). At the same time, signs of lymphoproliferation appeared (systemic lymphadenomegaly, hepato-splenomegaly with poor liver function indices, elevated serum lactate dehydrogenase). A worsening of respiratory function followed, with the need for intubation and transfer to ICU. Based on the diagnosis of complicated EBV infection, a treatment was started with antiviral and rituximab. After initial improvement in respiratory function and extubation, the patient had a relapse that affected the nervous system and led to a state of coma with the need for a second intubation. EBV DNA was amplified by PCR in cerebrospinal fluid, while blood examination showed moderate-to-severe anemia, hypofibrinogenemia, and hypertriglyceridemia. Overall, these data were consistent with a diagnosis of severe EBV infection complicated with hemophagocytic lymphohistiocytosis, leading to the search of genetic susceptibility to this kind of infection. Genetic analysis revealed that the boy was hemizygous for the c.3G>C p.M1I mutation in the *SH2D1A* gene, allowing the diagnosis of X-linked lymphoproliferative disorder (XLP). Based on these results, the patient underwent therapeutic conditioning followed by bone marrow transplantation, with good long-term outcome.

3. Discussion

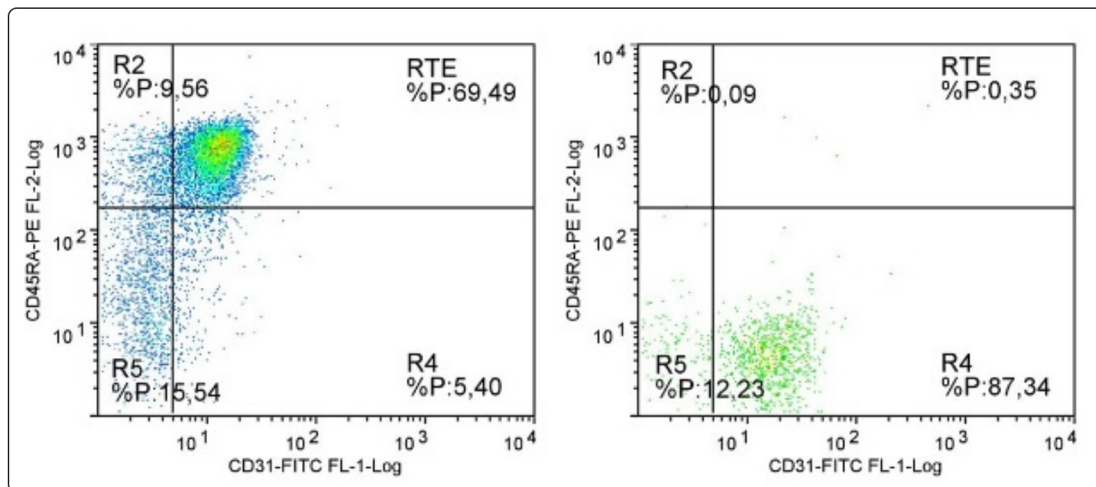
Case #1 was a typical case of SCID. The description of the case serves to illustrate the importance of reliable methods to measure thymic output both for diagnosis and in newborn screening. SCIDs are the most severe PIDs, presenting in the first year of life with various combinations of symptoms, ranging from severe infections, often from opportunist germs, to inflammatory and autoimmune manifestation, such as enteropathy, dermatitis, and autoimmune cytopenia. An SCID can be suspected also in infants with unexplained failure to thrive or with slow healing from a trivial infection. Infants with SCID usually have low lymphocyte count: attention should be paid to percentiles for age, since in the first months of life, reference values are much higher than ever [23]. Low levels of immunoglobulins can contribute to raised suspicion of PID. However, since the lymphocyte count may be normal in a few cases, lymphocyte immunophenotyping is necessary to confirm or rule out the diagnosis [5]. The most informative subset in evaluating an SCID is represented by RTE, which are a direct measure of the thymic output of naive cells, with a proper maturation of their T cell receptor. RTE are identified by the co-expression of CD3, CD45RA, and CD31 and are better evaluated on the subset of CD4 T cells [24,25]. The number of RTE well correlates with the results of the T cell receptor excision circle (TREC) assay, which measures the number of T cells bearing the genetic print of an effective receptor maturation [24,26,27] (Figure 1a). Whilst the RTE assay by flow cytometry is currently used for the analysis of cases with suspicion of a SCID, the TREC assay is best suited for analysis on dried blood spots in newborn screening for SCIDs [28]. Indeed, infants with a familial history of SCID who received the diagnosis of the disease at birth had better outcomes compared with their siblings in whom the diagnosis had been made because of symptoms, as they could be cured by hematopoietic stem cell transplantation in elective conditions [29]. This is one of the main reasons that fostered initiatives of SCID screening in several countries. The availability of the TREC assay, and of κ -deleting recombination excision circles (KREC) assays investigating B cell receptor recombination,

made it possible to add SCID among several genetic disorders screenable on Guthrie’s card blood spots [30].



(a)

Created with BioRender.com



(b)

Figure 1. Recent thymic emigrants (RTE) in healthy people and in subjects with immunodeficiencies arising from defective TCR recombination. (a) Difference in the portion of RTE lymphocytes between normal and immunodeficiency condition, at equal lymphocyte count. A subject with immunodeficiency may present a smaller fraction of thymic-matured T cells, which do not yet expand in the periphery after antigen (Ag) encounter. APC: antigen-presenting cell. MHC: major histocompatibility complex. (b) Analysis of RTE in a healthy control (left dot plot) and in a patient affected with X-linked SCID (X-SCID) (right dot plot). The cytograms are obtained after gating on CD45^{high}, CD3⁺, and CD4⁺ population. RTEs are identified by the co-expression of CD45RA and CD31 on CD4 T cells (upper right quadrant).

In the case described, the abnormal lymphocyte subpopulation pattern (lacking T cells and NK cells, but with normal numbers of B cells) and the low number of RTE allowed addressing the suspicion toward an X-SCID (Figure 1b), and the diagnosis was promptly confirmed by the sequencing of the gamma-chain gene. In this case, clinical and immunological data were sufficient to guide the right diagnosis.

In cases with a reference TREC assay at the screening, the diagnostic path is less straightforward: if results are confirmed in a second blood spot, a clinical and immunological evaluation must be performed promptly, especially in cases with undetectable TREC results. Immunophenotype must include the assessment of RTE [31]. Preterm newborns with low but not absent TREC can be followed for some weeks before intensive investigation for an SCID [32–34]. In subjects with confirmed pathological results, genetic analysis can be performed by direct gene sequencing or by NGS of several SCID-related genes at once. Immunologic investigation may be required again to improve the interpretation of results of uncertain significance obtained by NGS panels. Of note, newborns with the SCID due to adenosine deaminase deficiency (ADA-SCID) may have normal levels of TRECS, as the toxic metabolites produced because of the enzymatic deficiency are detoxified in utero through the placenta. Thus, ADA-SCID is not detected by TREC screening but by the biochemical measure of adenosine and 29-deoxyadenosine [35]. Table 1 shows a list of conditions in which the measure of RTE or TREC can be contributive for diagnosis.

Table 1. Diseases with low RTE/TREC.

Primary Immune Defects	
SCID	T-B-NK+ T-B+NK- T-B-NK- Other combinations Assessment of STAT phosphorylation can help subclassification [36,37]. Subjects with engraftment of maternal lymphocytes may have normal T cell count but have absent RTE [5].
Combined ID	CHH Pediatric onset CVIDs Del 22q11.2 syndrome and other immunodeficiencies with defective thymic development [38]. Other CID [39] CVIDs with severe lymphopenia and/or severe reduction of naïve T cells should be classified as CID [40,41] Pediatric onset CVIDs have usually low RTE [42], with the exception of NFKB2 deficiency that may display increased RTE [43,44]. Assessment of associated clinical features can help the identification of specific syndromes such as CHH [45], 22q11.2 syndrome [46–48], and APDS (<i>PIK3CD</i> and <i>PIK3R1</i> gene) [49].
Secondary Immune Defects [50]	
Preterm infant	Specific reference values for naïve T and B cells have to be considered in preterm infants [51,52]
Neonatal thymectomy	Reduced RTE [53,54]
HIV infection	Increase of RTE if HAART started < 6 months from infection [55]
HSCT	Increase of RTE if reconstitution from pre-thymic precursors [56–58]
Drugs	Cytostatic drugs, cyclosporine [59]
Elderly people	Immunosenescence [60]

Note: SCID: severe combined immunodeficiency; RTE: recent thymic emigrants; CHH: cartilage-hair hypoplasia; CVID: common variable immunodeficiency; CID: combined immunodeficiency; APDS: activated phosphoinositide 3-kinase δ syndrome; HIV: human immunodeficiency virus; HAART: highly active antiretroviral therapy; HSCT: hematopoietic stem-cell transplantation; TREC: T cell receptor excision circle.

The Case #2 description serves to illustrate how the analysis of X-chromosome inactivation still plays a significant role in diagnostics of PIDs. In this case, the diagnosis was straightforward, considering the typical clinical presentation and the familial history. Wiskott–Aldrich should always be considered in newborns with thrombocytopenia even if a small platelet volume can sometimes be missed by automatic counters, while it can be noticed by an experienced hematologist looking at peripheral blood smears. In our case, the diagnosis was supported by flow cytometry results showing absent WASP expression together with increased CD4/CD8 ratio. A skewed XCI pattern in the mother linked these results with the familial history of a death from infection in a maternal uncle.

XCI assay has been an important test supporting the suspicion of specific X-linked PIDs in the pre-genomic era [61,62]. Even if XCI tended to go into disuse with the advent of NGS, it still retains usefulness, both to reinforce suspicion of an X-linked PID and to

indirectly support the pathogenic role of variants of uncertain significance (VUS) identified by genetic analyses.

Basically, due to the random lyonization process, female cells usually display random XCI. However, a skewed pattern can be recognized if one of the two X-chromosomes bears gene mutation resulting in the reduced proliferation/survival fitness of particular types of cells [63]. For example, since functional BTK is required for the differentiation of B cells, female carriers for pathogenic BTK mutation will have only peripheral B cells expressing the wild-type allele, while staminal cells expressing the diseased BTK allele will fail to differentiate into B cells. Thus, the XCI assay will show a skewed pattern in B cells and a random one in other cell types (Figure 2) [61]. The findings from XCI in female heterozygous patients for diverse X-linked PIDs are shown in Table 2. Even if XCI analysis may be useless in cases with de novo mutation not inherited by the mother, it can be highly contributive when a skewed inactivation profile is demonstrated in the proper subset of the mother's cells. In almost all cases, female heterozygous patients for X-linked PIDs are completely healthy, but rare exceptions may exist in subjects having a skewed XCI for other reasons (Table 2). In these cases, flow cytometry analysis can show double peaks reflecting the presence of two cell populations, activating respectively the wild-type or the diseased allele (Figure 2).

Table 2. Functional assay to address suspicion or to assess relevance of genetic variants of unknown significance.

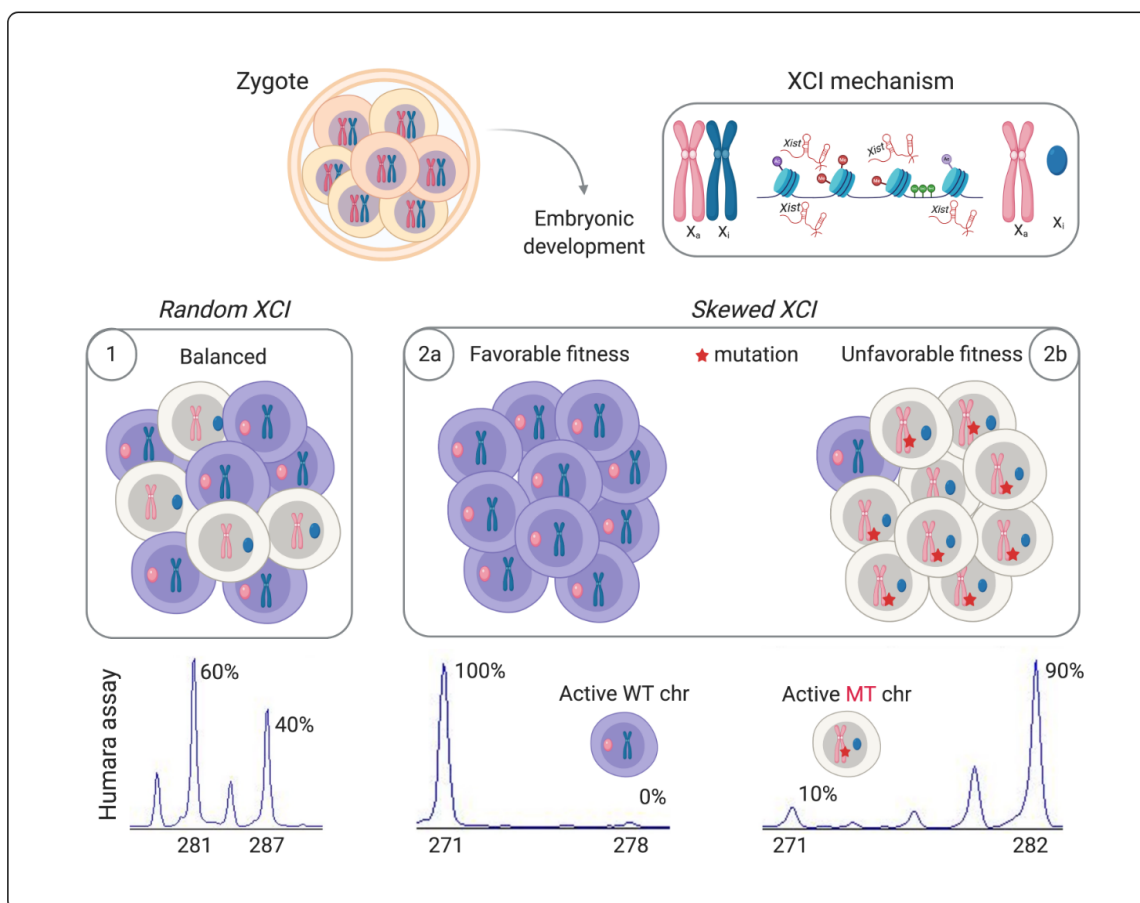
Disease (Gene)	XCI Skewed in	Routine Lab and Immunophenotype	Disease in H _z Females with Skewed Inactivation	Functional Assays
X-SCID (<i>IL2RG</i>)	T cells and NK [61]	B+ T- NK-	Not described	Proliferation; response to IL-2
WAS (<i>WAS</i>)	WBC [64]	Leukopenia; thrombocytopenia with small platelets	From XLT to WAS (due to skewed XCI [65–67] or uniparental isodisomy 6 [68])	WASP expression (cytometry); proliferation
CGD (<i>CYBB</i>)	No effect	Leukocytosis	From lupus discoid and stomatitis to CGD [69–71]	DHR or NBT test
XLA (<i>BTK</i>)	B cells [72]	Low B cells	[73]	BTK expression
IPEX (<i>FOXP3</i>)	Tregs [74]	High activation markers	Autoimmune disorders possibly associated with carrier status [75]	Measure of Tregs numbers; measure of TSDR [76]
NEMO deficiency (<i>IKBKG</i>)	WBC [77]	Non-specific	Ichthyosis pigmenti [78,79]	Response to TLRs [78,80]
Dyskeratosis congenita XLR (<i>DKC1</i>)	WBC [81]	Non-specific	[81,82]	Telomere flow-FISH [83]
XLP2 (<i>XIAP</i>)	No effect	Non-specific	HLH [84], Crohn's Disease [85]	Measure of XIAP expression [86]
XLP1 (<i>SH2D1A</i>)	No effect	Non-specific	Dysgammaglobulinemia [87,88]	Measure of SAP expression [86]
HIGM1 (<i>CD40LG</i>)	No effect	Reduced switched memory B cells	XCI [89,90]	Measure of CD40LG on activated lymphocytes
XMEN (<i>MAGT1</i>)	Leukocytes [91]	Reduced RTE	Not described	Glycosylation defect [92]

Note: XCI: X-chromosome inactivation; H_z: heterozygous; X-SCID: X-linked severe combined immunodeficiency; WAS: Wiskott–Aldrich syndrome; WBC: white blood cells; XLT: X-linked thrombocytopenia; CGD: chronic granulomatous disease; DHR: dihydrorhodamine; NBT: nitroblue tetrazolium; XLA: X-linked agammaglobulinemia; IPEX: immunodysregulation polyendocrinopathy enteropathy X-linked; TSDR: Treg-specific demethylated region; XLR: X-linked recessive; FISH: fluorescence in situ hybridization; XLP: lymphoproliferative syndrome, X-linked; HLH: hemophagocytic lymphohistiocytosis; HIGM1: X-linked hyper-IgM syndrome; XMEN: X-linked immunodeficiency with magnesium defect, Epstein-Barr virus infection, and neoplasia; RTE: recent thymic emigrants.

Today, NGS panels or clinical exome sequencing are increasingly used to assist the genetic diagnosis in the field of X-linked PIDs [93,94]. However, as discussed above, some X-linked PIDs are so well characterized to justify a provisional diagnosis based only on clinical and immunological data. For example, this is true for WAS, X-SCID and

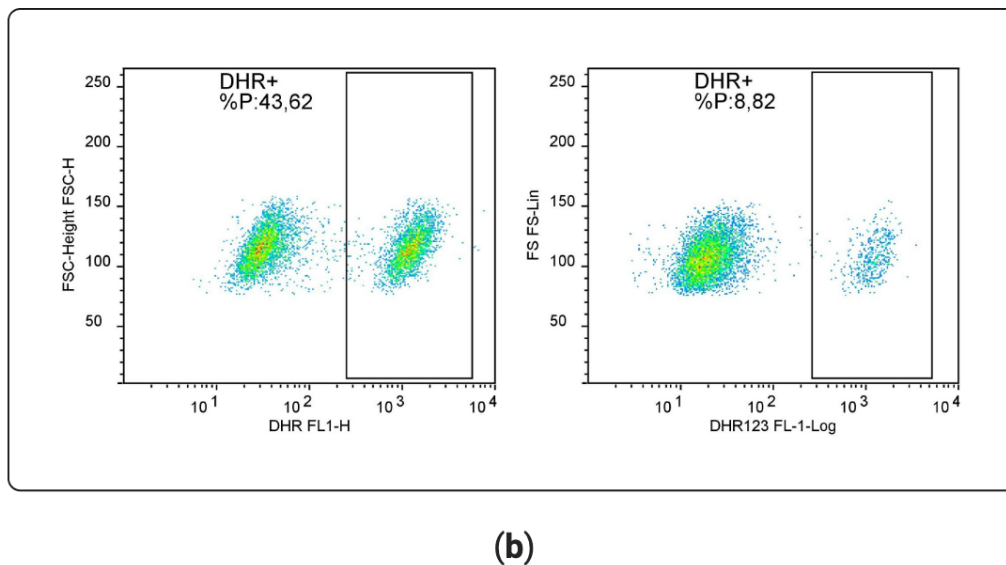
CGD. Of note, in some cases with high clinical suspicion of these disorders, exome-based genetic analysis can yield false negative results, and more complex genomic analyses are required. In such cases, the reliability of flow cytometry-based functional assays (e.g., measure of WASP protein, analysis of gamma chain signaling, assessment of superoxide production), together with the results of XCI studies in the mother, can allow making a diagnosis guiding more complex genomic analyses, for example to search for gene inversions, promoter mutations, and other rare genomic changes. The possibility of false negative exome-sequencing results was reported for WAS [10], X-SCID [95], and chronic granulomatous disease (CGD) [96]. Conversely, for some PIDs, also flow cytometry can yield false negative results, as reported about the expression of SAP protein in XLP [97]. Thus, clinical, immunological, and genomic investigations remain reciprocally necessary for a reliable diagnostic process. Flow cytometry investigations to assess PIDs with immune-dysregulation have been recently reviewed by Cabral-Marques et al. [98].

Case #3 illustrates how primary immune defects may result at a same time in susceptibility to infection and in seemingly unprovoked inflammatory activation. It also highlights how PIDs may be hidden in cases diagnosed with a rheumatological condition. Monogenic autoinflammatory diseases are included in the International Union of Immunological Societies (IUIS) classification of inborn errors of immunity [99]. Apart from the group of pure autoinflammatory disorders, some PIDs can present autoinflammatory symptoms in addition to other signs of immune deficiency. Patients with this kind of disorder can be firstly referred to rheumatologists with the suspicion of a pure autoinflammatory disorder. Table 3 lists some PIDs that can present both infectious and autoinflammatory features.



(a)

Figure 2. Cont.



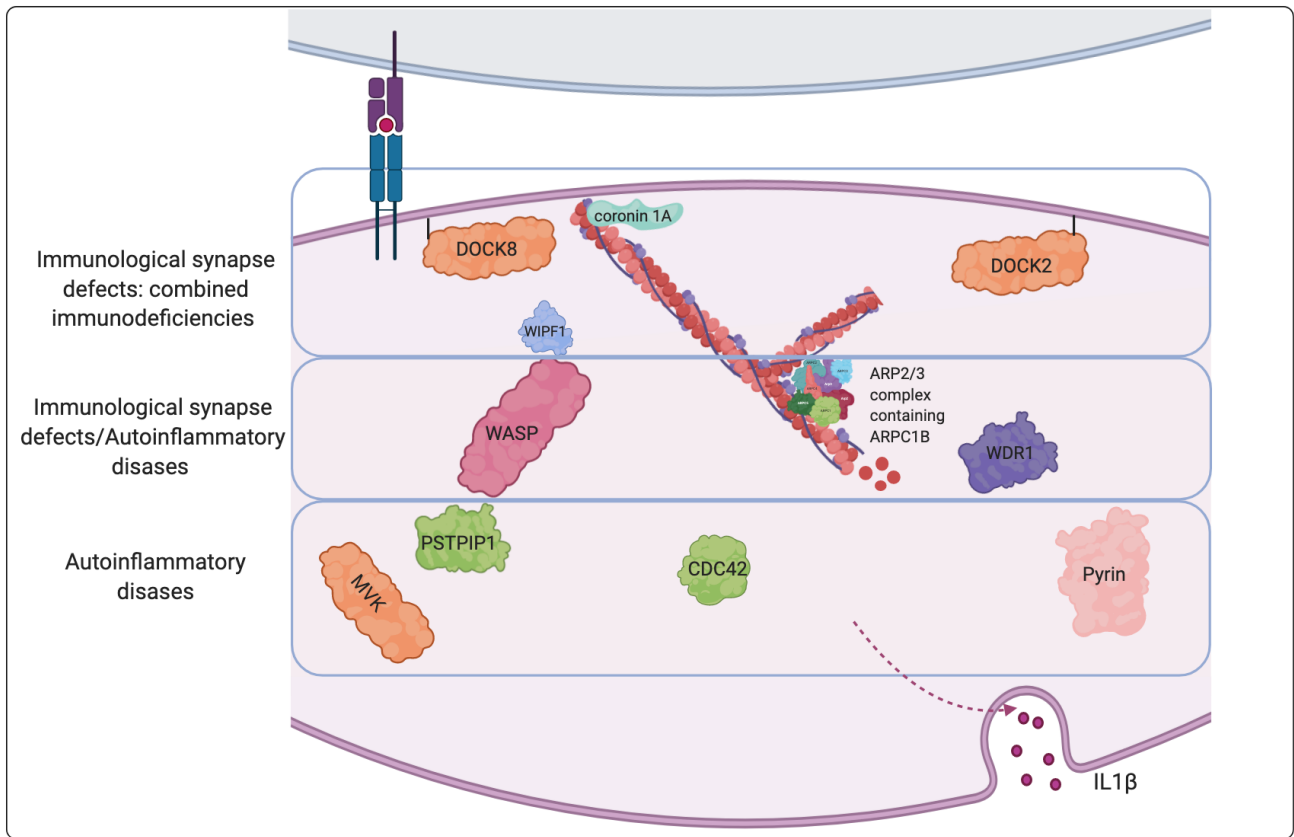
(b)

Figure 2. X-chromosome inactivation (XCI) assay in females heterozygous for X-recessive immune disorders. (a) A random X-chromosome inactivation occurs in each female during embryogenesis, and the expected inactivation percentage is estimated about 50% (1). However, nonrandom or skewed XCI may be found in peripheral blood if the female is heterozygous for a mutation affecting cell proliferation (2). For example, if a mutation is associated with defective cell maturation, only cells that activated the wild-type allele will be found in the blood of female carriers, who will be completely healthy (2a). However, in some cases, one of the two X-chromosome may be silenced due to the presence of some other structural chromosomal abnormality. In these cases, the other X-chromosome will be always active, even if it carries mutation in immune genes. In these unfavorable conditions, females may express X-recessive immunodeficiency (2b). Human androgen receptor assay (HUMARA) allows us to indirectly assess the relative activation of the two X-chromosomes. The *AR* gene presents a hypervariable CAG short tandem repeat that permits distinguishing between the paternally and maternally derived X-chromosome (the peaks present in the figure above). Exploiting methylation-sensitive restriction sites to selectively digest the active allele (unmethylated) allows us to distinguish the percentage of active (enzyme digested and not amplified with PCR) from the inactive alleles. (b) Flow cytometric analysis of the DHR test performed in two female carriers of X-linked CGD (supplementary materials). Deficiency in the *CYBB* gene associated with CGD only impacts granulocyte function and not their proliferative fitness; thus, heterozygous females normally display random XCI and are healthy (left panel); in rare cases, XCI can be skewed for other unknown factors: heterozygous females displaying skewed XCI may have too low a percentage of functional neutrophils and can thus express the disease (right panel).

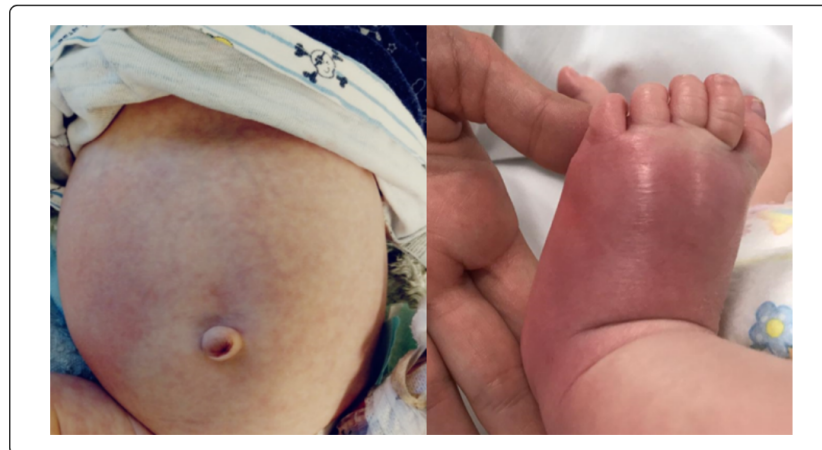Inflammatory and autoimmune manifestations can occur in almost all PIDs. However, only a few PIDs display autoinflammatory features with a prevalent involvement of a single cytokine, behaving similarly to typical autoinflammatory conditions and benefiting from specific cytokine blocking treatments. Some exemplary PIDs with autoinflammation are reported in Table 3, highlighting precision therapies, when available.

Of particular interest is the newly described group of actinopathies [100–102], in which the disturbed homeostasis the cytoskeleton can reflect both on defective formation of immune synapsis and on autoinflammatory response. Actinopathies encompass a wide spectrum of diseases ranging from severe immune deficiencies due to defective immune synapsis at one end to autoinflammatory disorders associated with an increased release of IL-1 at the other end (Figure 3). On one hand, an impaired formation of the immune synapse reflects on reduced cooperation between immune cells and defective lymphocyte activation and cytotoxic function, leading to more or less severe combined immunodeficiency, as in *DOCK2* [103], *DOCK8* [104,105], *Coronin 1*, and *WIP* deficiencies. On the other hand, defective dynamics of actin polymerization leads to abnormal activation of pyrin inflammasome and autoinflammation, as in *PAPA* syndrome [106–108], *Familial Mediterranean Fever* [108–110], *Hyper-IgD syndrome* [109], and *CDC42* deficiency [111,112]. Thus, actinopathies may predominantly present with phenotypes related to combined immunodeficiency or to autoinflammation, but some disorders may present with mixed phenotypes, as in the case of *Wiskott–Aldrich syndrome* [10,113], *ARPC1B* deficiency [114], or *WDR1*

deficiency (in which, however a defective neutrophil function is associated with the dys-regulation of IL-18 instead of IL-1 [115,116]).



(a)



(b)

Figure 3. Actinopathies. (a) Schematic representation of immune disorders associated with impaired actin cytoskeleton regulation, affecting the immune synapsis and lymphocyte activation, the regulation of IL-1 autoinflammation, or both. (b) Autoinflammatory manifestations responsive to IL-1 inhibition in a case of Wiskott–Aldrich syndrome.

In these disorders, it could be difficult to distinguish infective from autoinflammatory manifestations. In some cases, the ex-juvantibus response to IL-1 inhibition with anakinra has proved useful by providing indirect evidence of the autoinflammatory nature of clinical manifestations such as skin rashes and unexplained fever [10,111].

Of note, some patients with PID associated with autoinflammation may be initially referred to rheumatologists for complaints supportive of SLE or Behçet disease (as in the case of STAT1 GOF, A20 haploinsufficiency syndromes, WDR1 deficiency), and infective symptoms may be misinterpreted as a complication of immunosuppressive treatments [117].

Table 3. Immunodeficiencies with autoinflammation.

Disease	Gene	Predominant Cytokine	Precision Therapies for the Autoinflammatory Component
STAT1 GOF syndrome	STAT1 GOF	Interferons	JAK inhibitors
Wiskott–Aldrich syndrome	WAS [10]		
Immunodeficiency 71 with inflammatory disease and congenital thrombocytopenia	ARPC1B [114]	IL-1 *	Anakinra
Immunodeficiency with dyshematopoiesis, inflammation, and HLH	CDC42 [112]		
Autoinflammation, antibody deficiency, and immune dysregulation syndrome (APLAID)	PLGC2 GOF [118]	IL-1	Anakinra
Autoinflammatory periodic fever, immunodeficiency, and thrombocytopenia (PFIT)	WDR1 [116,119,120]	IL-18	Partial response to anakinra
Immunodeficiency 72 with autoinflammation	NCKAP1L [121]	IL-18, IFN-g	Not defined
A20 haploinsufficiency	TNFAIP3 [122]	TNF-alpha	Anti-TNF

* Disturbance of the actin cytoskeleton in these three disorders, also referred to as pertaining to the new group of actinopathies, is associated with IL-1 mediated autoinflammation responsive to anakinra [101]. Note: HLH: hemophagocytic lymphohistiocytosis.

Case #4 presentation serves to illustrate the importance of lymphoproliferative features in raising the suspicion of a PID. APDS has been only recently characterized as a specific PID. Since it may present with variable clinical pictures, subjects with APDS in the past could be classified as having common variable immunodeficiency (CVID), Hyper-IgM syndrome, or combined immunodeficiency (CID). Accordingly, the treatment for patients included prophylactic antibiotics, immunoglobulin replacement, and in some cases, hematopoietic stem-cell transplantation (HSCT). Many other diseases (e.g., CTLA4-Cytotoxic T-Lymphocyte Antigen 4- deficiency, LRBA- LPS responsive beige-like anchor protein- deficiency, CD40/CD40L deficiency), prior to the discovery of their monogenic cause, were classified as CVID, which is a heterogeneous group (the term “variable” refers to this heterogeneity) of disorders characterized by predominant antibody deficiency not due to other well-defined PIDs. More recently, widened awareness of PID together with the availability of NGS techniques led to the discovery of more and more genes underpinning PIDs [123] and to the characterization of new pathogenic mechanisms. This allowed better clustering of pathogenetic pathways and phenotype combinations (endotype) in already established PID, in some cases paving the way to the development of targeted treatments.

Therefore, when a new mutation in a specific disease-related gene is identified, this new clinical entity should be considered as independent disease, especially when the identification of the causative gene gives us a therapeutic target for precision therapies that can be implemented in addition to, or even before, conventional prophylactic treatments with antimicrobials and immunoglobulins [11].

Of particular interest are two groups of disorders, respectively characterized by hyperactivation of the PI3K–AKT–mTOR pathway, as autoimmune lymphoproliferative syndrome (ALPS), APDS, immuno-TORpathies [124,125], and by defective function of

regulatory T cell functions, such as immunodysregulation polyendocrinopathy enteropathy X-linked (IPEX), CTLA4 deficiency, and LRBA deficiency. Both groups of diseases are associated with lymphoproliferation, often with chronic enlargement of spleen and liver in addition to peripheral lymph nodes. However, the clinical phenotype and the assessment of biomarkers can help distinguish these conditions even before performing NGS. For example, high serum vitamin B12 is typically elevated in ALPS; brain, lung and gut lesions may characterize CTLA4 and LRBA deficiency, and chronic EBV infections are more typical of disorders such as X-linked immunodeficiency with magnesium defect (XMEN, already mentioned in Table 2).

Although only two cases have been described so far, enlargement of lingual tonsil might be a sign of lymphoproliferation supportive of APDS. Of note, lymphoproliferative and autoimmune symptoms in ALPS and APDS may respond to treatment with sirolimus even at a lower than usual dosage [126,127].

More interestingly, other treatments can even rescue the defective immune development, as in the case of PI3K inhibitors in APDS syndrome [128–130], or correct autoimmune features related to abnormal immune activation, as in the case of CTLA4 or LRBA deficiencies, which can strongly benefit from a therapy with abatacept, surrogating the defective regulatory function of CTLA4 [131,132].

Most of these lymphoproliferative diseases also constitute a form of susceptibility to Epstein–Barr virus (EBV) infection, and in some cases, lymphoproliferation may be evident only after such infection.

EBV infects about 90% of the population by 30 years of age, being clinically manifested during the primary infection and remaining latent in B or T/NK lymphocytes. It is known that it induces lymphoproliferation, especially of B lymphocytes, but also T and NK cells. Subjects with PID, especially those with defective T cell immunity or those with minor cytotoxic defects accounting for specific susceptibility to EBV, are less able to control the infection and have a high risk of developing EBV-positive lymphocyte proliferation diseases (LPDs) and leukemia/lymphomas, or they may show clinical manifestations consistent with chronic active EBV disease (CAEBV, XMEN) [133,134].

We do not yet know if precision treatments available for some of these PIDs with lymphoproliferation may impact on lymphoma risk. As we previously wrote [127], the experience of sirolimus in kidney transplantation suggests that this medication affects cancer risk less than other immunosuppressive treatments or even reduces it. Based on these data, we thought that mTOR inhibitors (everolimus/sirolimus) prescribed in immunological diseases with a hyperactivated PI3K–AKT–mTOR pathway (e.g., ALPS, APDS, APDS-like) might also be effective in reducing the risk of developing immune malignancies, even if there is still no clinical evidence about this (Figure 4). Table 4 shows a group of immunodeficiency with lymphoproliferation treatable with precision therapies. In general, lymphoproliferation is associated with increased risk of developing lymphoma. A more complete list of PIDs associated with immune dysregulation can be found in the updated IUIS classification [99].

Case #5 is an example of PIDs associated with susceptibility to specific infections. It is worth noting that subjects affected with these PIDs may have a completely healthy life until the encounter of a specific microbe that highlights a single weak point in the system. Indeed, the apparent redundancy of the immune system can be easily understood when we can see how apparently minor immune defects may result in serious consequences. Table 5 summarizes some conditions of specific Mendelian susceptibility to infections. In general, they concern microbes or viruses that evolved effective mechanisms to elude most (but not all) of the host's immune defenses.

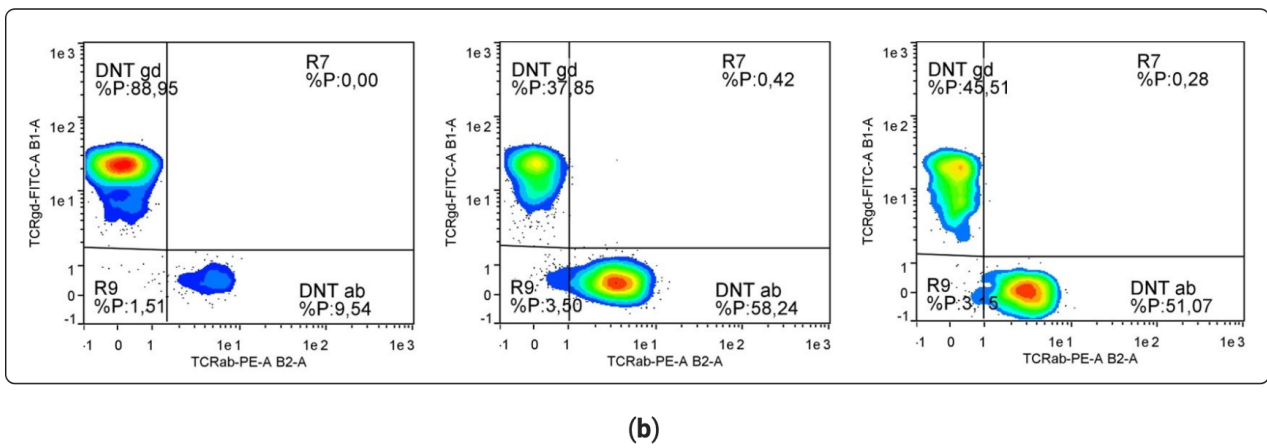
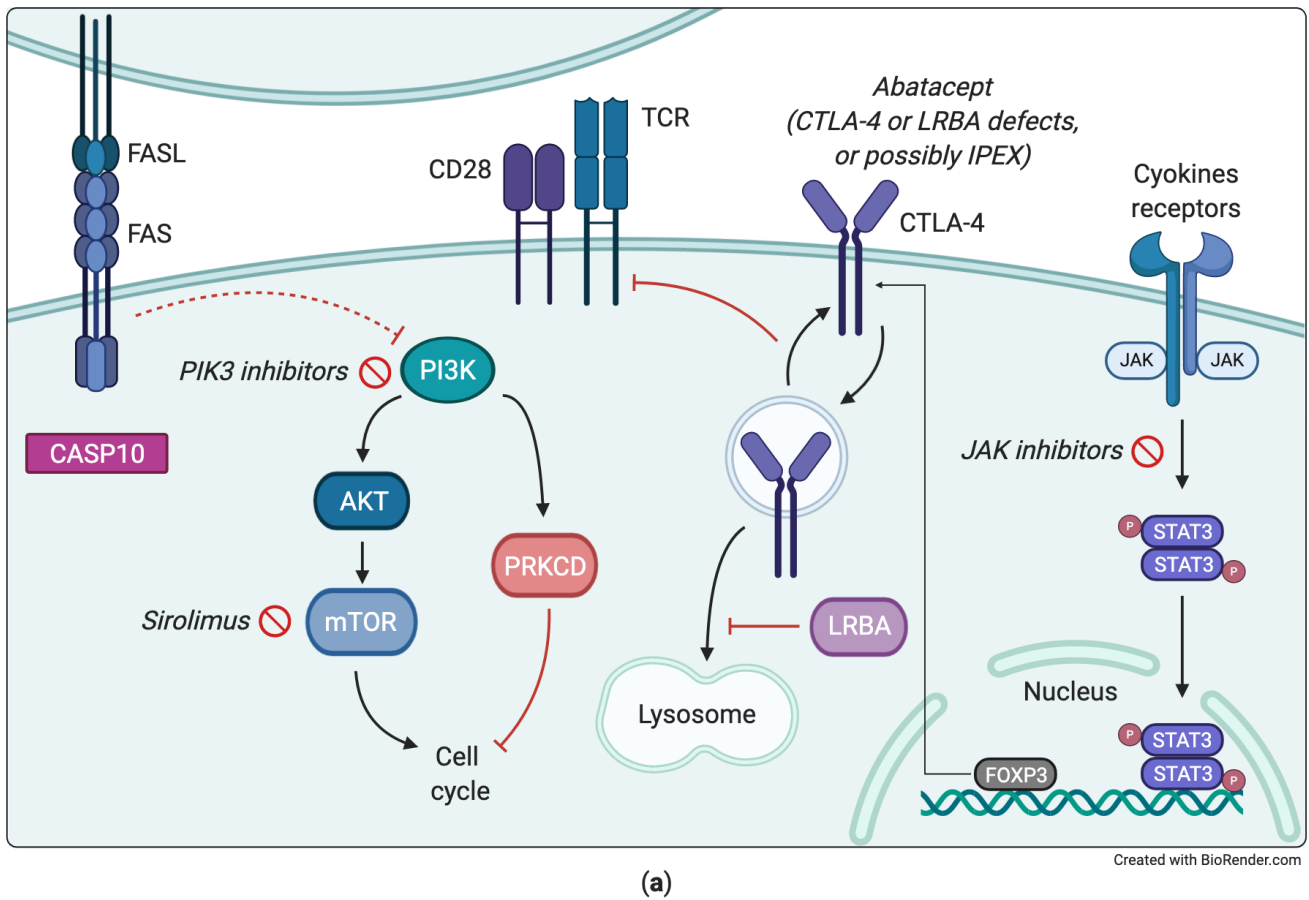


Figure 4. Examples of pathogenic mechanisms in immunodeficiencies with lymphoproliferation (a) PI3K–AKT–mTOR pathway from APDS to ALPS and immuno-TORopathies. (b) Representative flow cytometry dot plot of double negative T cells expressing alpha/beta or gamma/delta T cell receptor (supplementary materials). Percentage values shown in the graphs are calculated on CD4-CD8- T cells; percentage values of DNT alpha/beta calculated on CD3+ population are 1,4-15, 7-5. From the left to the right: healthy control, ALPS syndrome and LRBA deficiency.

Table 4. Immunodeficiencies with lymphoproliferation.

Disease	Genes	Immuno-Phenotype	Lympho-Proliferation	Autoimmune Cytopenia	Enteropathy	Infections	Inheritance	Precision Therapy
ALPS [135]	<i>FAS</i> <i>FASLG</i> <i>CASP10</i> <i>PRKCD</i>	DNT	++	++ SLE-like features	—	EBV-induced lymphoproliferation	AD, AR	Sirolimus [136,137] [127,138,139]
IPEX	<i>FOXP3</i>	Activated lymphocytes	+	++	+++	—	XLR	Sirolimus [140,141]
APDS	<i>PIK3CD</i> <i>PIK3R1</i>	Senescent CD8 CD57+ T cells; reduced switched memory B cells	++	+	+	+	AD	Sirolimus, PI3K inhibitors
STAT3 GOF	<i>STAT3</i>	DNT	++	++	—	—	AD	JAK inhibitors
CTLA4 deficiency	<i>CTLA4</i>	Sometimes, reduced CTLA4 expression	++, risk of lymphoma	++	++	+	AD	Abatacept, sirolimus
LRBA deficiency	<i>LRBA</i>	Reduced LRBA expression; reduced CTLA4 expression	++, risk of lymphoma	+	++	+	AR	Abatacept, sirolimus

Note: ALPS: autoimmune lymphoproliferative syndrome; DNT: double negative T cells; SLE: systemic lupus erythematosus; EBV: Epstein-Barr virus; AD: autosomal dominant; AR: autosomal recessive; IPEX: immunodysregulation polyendocrinopathy enteropathy X-linked; XLR: X-linked recessive; APDS: activated phosphoinositide 3-kinase δ syndrome; CTLA4: Cytotoxic T-Lymphocyte Antigen 4; LRBA: LPS responsive beige-like anchor protein; —: not present; +: mild expression; ++: moderate expression; +++: severe expression.

Table 5. Susceptibility to severe course from specific microbial infections.

Selective Susceptibility	Main Involved Pathway	Phenotypes	Reviewed	Precision Therapies
Candida	Defective Th17 function, defective sensing of candida	Mucocutaneous candidiasis, hyper-IgE syndrome, recurrent oral ulcerations, candidiasis with SLE-like overlap (STAT1 GOF), APECED (autoimmune polyendocrinopathy-candidiasis-ectodermal dystrophy)	[142]	JAK inhibitors in STAT1 GOF [143] G-CSF in CARD9 deficiency [144] Only anti-candida prophylaxis in APECED
EBV	Cytotoxic lymphocyte and NK function; CD8 T cell/APC synapse formation; CD8 T cell priming; EBV specific CD8 T cell function	CAEBV, B lymphoproliferative disorder, HLH, persistent lymphoproliferation and hematologic autoimmunity (as in ALPS and APDS syndromes)	[145,146]	Anti-CD20 therapy helps clearing the viral reservoir; donor lymphocyte infusions with whole peripheral blood or EBV-specific T cell lines; EBER cytometry to characterize the infected cells [147]
Warts and HPV related disorders	Deficiency in CD4 function; APC functions; keratinocyte innate immunity	Epidermodysplasia verruciformis, non-melanoma skin cancers, cutaneous warts, anogenital lesions	[148]	Specific inhibitors for CXCR4 for WHIM (Warts, Hypogammaglobulinemia, Infections, and Myelokathexis).
HSV	Sensing of viral components and Interferon cascade	Encephalitis (especially if recurrent), disseminated herpes virus infection	[149–153]	Antiviral therapy and prevention of relapses
Mycobacteria	Pathway of sensing mycobacterial PAMPs to the production of gamma interferon in dendritic cells, phagocytes, lymphocytes and natural killer cells	BCGitis, Disseminated atypical mycobacteriosis,	[154]	JAK inhibitors in STAT1 GOF Recombinant IFN-g in patients with IL12 cascade deficiency [155] Recognize CGD and NEMO deficiency

Note: Several other PIDs may be associated with any of these specific infections; however, in these cases, the susceptibility is not so selective. No mention is made to defects with broader susceptibility to infections. SLE: systemic lupus erythematosus; APECED: autoimmune polyendocrinopathy–candidiasis–ectodermal dystrophy; G-CSF: granulocyte-colony stimulating factor; EBV: Epstein-Barr virus; APC: antigen-presenting cells; CAEBV: chronic active EBV infection; HLH: hemophagocytic lymphohistiocytosis; ALPS: autoimmune lymphoproliferative syndrome; APDS: activated phosphoinositide 3-kinase δ syndrome; HPV: human papilloma virus; WHIM: Warts, Hypogammaglobulinemia, Infections, and Myelokathexis; HSV: herpes simplex virus; PAMPs: pathogen-associated molecular patterns; CGD: chronic granulomatous disease.

4. Conclusions

PIDs include more than 300 genetic disorders that can be classified in 10 categories according to the IUIS [99]. Clinical exome is gaining more and more indication for diagnosing, but the integration with clinical and immunological data is still critical to make a proper and defined diagnosis. In the experience of a pediatric reference hospital in Italy, in the last twenty-five years, we diagnosed 178 subjects with inborn error of immunity due to mutations in about 59 distinct genes, highlighting the high genetic heterogeneity underpinning PID (Figure 5). The five settings described in the present article are meant only for exemplary purposes. In fact, many PIDs can fit into diverse scenarios, and many others cannot fit into any of them. The aim of our presentation is just to highlight the

five general messages resumed in Summary Box. Furthermore, we chose to include some PIDs in which a proper diagnosis can allow prescribing precision therapy with a favorable prognostic impact (druggable PIDs). A similar principle is at the basis of the initiative from the Jeffrey Modell Foundation to promote a global genetic sequencing pilot program to identify specific primary immunodeficiency defects to optimize disease management and treatment [94]. Indeed, since the clinical phenotype of “druggable” PIDs may overlap with common rheumatologic or gastroenterological disorders, it is important to increase the awareness of the possible genetic diagnosis among diverse medical specialists.

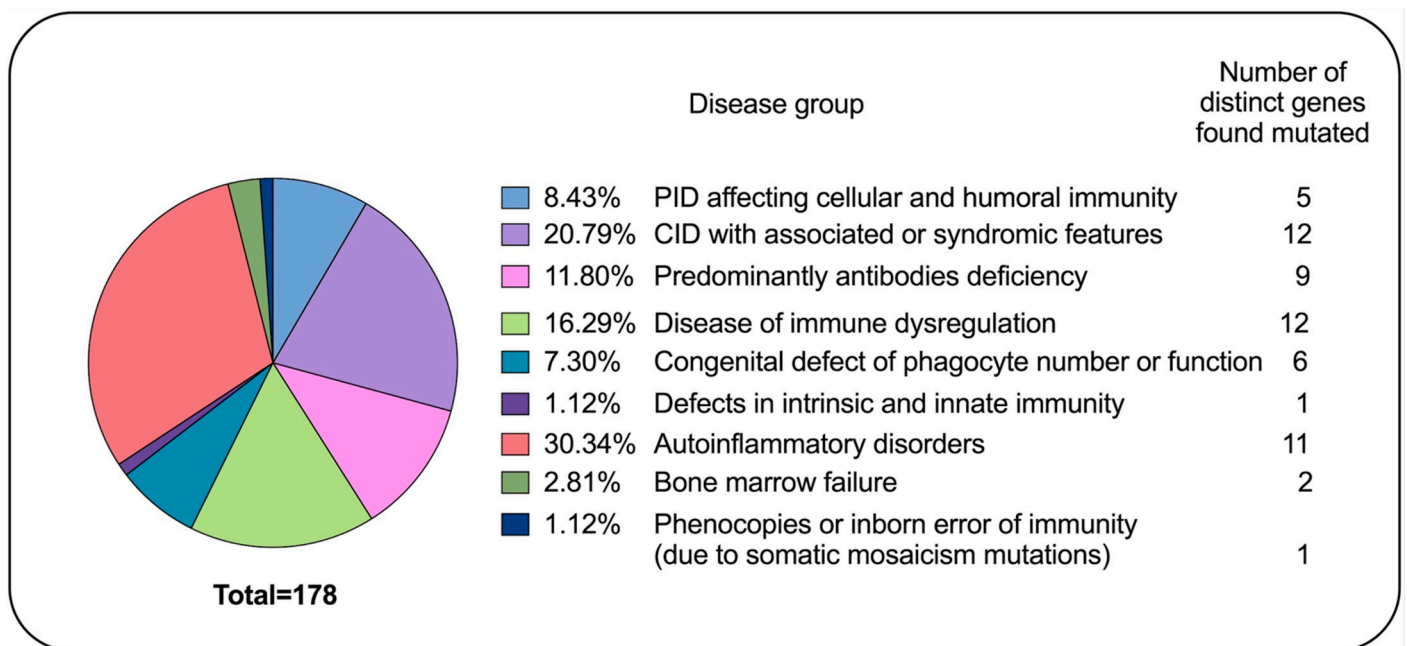


Figure 5. Primary immunodeficiency disease (PID) diagnosis in the last twenty-years in the experience of a pediatric hospital in Italy. The pie chart displays the proportion of subject affecting by distinct inborn error of immunity and the number of diverse genes mutated for each condition.

Summary Box

SCIDs can be identified and classified by basic flow cytometry. Deficiency in recent thymic emigrants (RTE) is highly indicative of SCID. Defective thymic output can be also measured by molecular techniques (TREC analysis) in dry blood spots in newborn screening. Positive results from TREC screening require further analysis to obtain a diagnosis, with both flow cytometry techniques and NGS panels.

Several PID have X-recessive inheritance. Immunological assays remain of crucial importance both for driving the diagnosis (as in the case of dihydrorhodamine (DHR) test for CGD or measure of WASP expression in WAS) and for confirming the causative role of variants of uncertain significance (VUS) detected by NGS. X-chromosome inactivation (XCI) analysis in appropriate subsets of cells from heterozygous mothers still has a role in interpreting genetic results. Moreover, the study of XCI is useful also in rare cases of heterozygous females affected because of unbalanced XCI. Other specialist tests can help diagnosis in specific disorders such as dyskeratosis congenita (telomere length analysis), ectodermal dysplasia with immunodeficiency (response to TLRs), and X-SCID (response to IL-2 stimulation).

Several PIDs can present with autoinflammatory phenotype. Distinguishing autoinflammation from infection is a critical issue. Basic flow cytometry and genetics may not be sufficient to recognize the autoinflammatory component in PIDs, whilst the assessment of serum biomarkers and transcriptomic signatures can be greatly useful. Ex-juvantibus response to selective anti-cytokine treatment can also give valuable help.

Lymphoproliferation is also a feature shared among various PIDs. Increased Double Negative T cells are typical of ALPS and can be found also in other ALPS-like conditions. The assessment of antigens related to immune regulation, such as FOXP3 and CTLA4, is also of some help, but NGS panels are increasingly adopted in subjects with immunodeficiency and lymphoproliferation. However, VUS are often encountered, which can be of challenging interpretation, especially when associated with protein gain-of-function (GOF), as in the case of activated PI3K kinase syndrome or STAT3 GOF.

Mendelian susceptibility to specific infections, such as candida, EBV, herpes viruses, and mycobacteria, is not easily detected by common immunological investigations. NGS is often used to address the diagnosis, but specialistic immune assays may be required to interpret the pathogenic role of VUS.

Supplementary Materials: The following are available online at <https://www.mdpi.com/2075-4418/11/3/532/s1> which describe in more details laboratory methods that have been used.

Author Contributions: Conceptualization, A.T. (Alberto Tommasini), F.R.; methodology, E.V., M.G., A.P., A.T. (Alessandra Tesser); software, A.P., A.T. (Alessandra Tesser), M.G., E.V.; validation, A.T. (Andrea Taddio), F.F.; formal analysis, V.B.; investigations, M.G., E.V., A.T. (Alessandra Tesser), A.P., E.P., G.M.S.; resources, A.T. (Alberto Tommasini), G.M.S.; data curation, G.M.S.; writing—original draft preparation, F.R.; writing—review and editing, A.T. (Alberto Tommasini), A.P.; visualization, V.B.; supervision, A.T. (Alberto Tommasini); project administration, A.T. (Alberto Tommasini); funding acquisition, A.T. (Alberto Tommasini). All authors have read and agreed to the published version of the manuscript.

Funding: This work was supported by the Institute for Maternal and Child Health—IRCCS “Burlo Garofolo” in Trieste (Italy) RC #24/2017, and by the Italian Ministry of Health grant RF-2016-02362384.

Institutional Review Board Statement: The study is part of the IRCCS Burlo Garofolo project RC #24/2017, approved by the Institutional Review Board and by the Friuli Venezia Giulia Independent Ethical Committee (2018-SPER-079-BURLO, N. 0039851, approved on 12 December 2018), and project RF-2016-02362384, approved by the Friuli Venezia Giulia Independent Ethical Committee (CEUR-2020-PR-13).

Informed Consent Statement: Informed consent was obtained from all subjects involved in the study.

Data Availability Statement: The data presented in this study are available on request from the corresponding author. The data are not publicly available due to preserve patients’ privacy.

Conflicts of Interest: The authors declare no conflict of interest.

References

1. De Vries, E.; Noordzij, J.G.; Kuijpers, T.W.; van Dongen, J.J. Flow cytometric immunophenotyping in the diagnosis and follow-up of immunodeficient children. *Eur. J. Pediatr.* **2001**, *160*, 583–591. [[CrossRef](#)] [[PubMed](#)]
2. Ameratunga, R.; Woon, S.T.; Neas, K.; Love, D.R. The clinical utility of molecular diagnostic testing for primary immune deficiency disorders: A case based review. *Allergy Asthma Clin. Immunol.* **2010**, *6*, 12. [[CrossRef](#)] [[PubMed](#)]
3. Notarangelo, L.D.; Sorensen, R. Is it necessary to identify molecular defects in primary immunodeficiency disease? *J. Allergy Clin. Immunol.* **2008**, *122*, 1069–1073. [[CrossRef](#)]
4. Arkwright, P.D.; Gennery, A.R. Ten warning signs of primary immunodeficiency: A new paradigm is needed for the 21st century. *Ann. N. Y. Acad. Sci.* **2011**, *1238*, 7–14. [[CrossRef](#)]
5. Kalina, T.; Bakardjieva, M.; Blom, M.; Perez-Andres, M.; Barendregt, B.; Kanderova, V.; Bonroy, C.; Philippe, J.; Blanco, E.; Pico-Knijnenburg, I.; et al. EuroFlow Standardized Approach to Diagnostic Immunophenotyping of Severe PID in Newborns and Young Children. *Front. Immunol.* **2020**, *11*, 371. [[CrossRef](#)] [[PubMed](#)]
6. Seidel, M.G.; Kindle, G.; Gathmann, B.; Quinti, I.; Buckland, M.; van Montfrans, J.; Scheible, R.; Rusch, S.; Gasteiger, L.M.; Grimbacher, B.; et al. The European Society for Immunodeficiencies (ESID) Registry Working Definitions for the Clinical Diagnosis of Inborn Errors of Immunity. *J. Allergy Clin. Immunol. Pract.* **2019**, *7*, 1763–1770. [[CrossRef](#)]
7. Yska, H.A.F.; Elsink, K.; Kuijpers, T.W.; Frederix, G.W.J.; van Gijn, M.E.; van Montfrans, J.M. Diagnostic Yield of Next Generation Sequencing in Genetically Undiagnosed Patients with Primary Immunodeficiencies: A Systematic Review. *J. Clin. Immunol.* **2019**, *39*, 577–591. [[CrossRef](#)]
8. Jung, S.; Gies, V.; Korganow, A.S.; Guffroy, A. Primary Immunodeficiencies With Defects in Innate Immunity: Focus on Orofacial Manifestations. *Front. Immunol.* **2020**, *11*, 1065. [[CrossRef](#)] [[PubMed](#)]

9. Day-Williams, A.G.; Sun, C.; Jelcic, I.; McLaughlin, H.; Harris, T.; Martin, R.; Carulli, J.P. Whole Genome Sequencing Reveals a Chromosome 9p Deletion Causing DOCK8 Deficiency in an Adult Diagnosed with Hyper IgE Syndrome Who Developed Progressive Multifocal Leukoencephalopathy. *J. Clin. Immunol.* **2015**, *35*, 92–96. [[CrossRef](#)]
10. Brigida, I.; Scaramuzza, S.; Lazarevic, D.; Cittaro, D.; Ferrua, F.; Leonardelli, L.; Alessio, M.; Forma, O.; Lanzani, C.; Viarengo, G.; et al. A novel genomic inversion in Wiskott-Aldrich-associated autoinflammation. *J. Allergy Clin. Immunol.* **2016**, *138*, 619–622. [[CrossRef](#)]
11. Valencic, E.; Smid, A.; Jakopin, Z.; Tommasini, A.; Mlinaric-Rascan, I. Repositioning Drugs for Rare Immune Diseases: Hopes and Challenges for a Precision Medicine. *Curr. Med. Chem.* **2018**, *25*, 2764–2782. [[CrossRef](#)] [[PubMed](#)]
12. Chellapandian, D.; Chitty-Lopez, M.; Leiding, J.W. Precision Therapy for the Treatment of Primary Immunodysregulatory Diseases. *Immunol. Allergy Clin. N. Am.* **2020**, *40*, 511–526. [[CrossRef](#)]
13. Brinkman, R.R.; Dube, M.P.; Rouleau, G.A.; Orr, A.C.; Samuels, M.E. Human monogenic disorders—A source of novel drug targets. *Nat. Rev. Genet.* **2006**, *7*, 249–260. [[CrossRef](#)] [[PubMed](#)]
14. Boisson, B.; Quartier, P.; Casanova, J.L. Immunological loss-of-function due to genetic gain-of-function in humans: Autosomal dominance of the third kind. *Curr. Opin. Immunol.* **2015**, *32*, 90–105. [[CrossRef](#)]
15. Conley, M.E.; Fruman, D.A. Genetics. Can cancer drugs treat immunodeficiency? *Science* **2013**, *342*, 814–815. [[CrossRef](#)] [[PubMed](#)]
16. Sacco, K.A.; Stack, M.; Notarangelo, L.D. Targeted pharmacologic immunomodulation for inborn errors of immunity. *Br. J. Clin. Pharmacol.* **2020**. [[CrossRef](#)]
17. Cirillo, E.; Cancrini, C.; Azzari, C.; Martino, S.; Martire, B.; Pession, A.; Tommasini, A.; Naviglio, S.; Finocchi, A.; Consolini, R.; et al. Clinical, Immunological, and Molecular Features of Typical and Atypical Severe Combined Immunodeficiency: Report of the Italian Primary Immunodeficiency Network. *Front. Immunol.* **2019**, *10*, 1908. [[CrossRef](#)]
18. Liu, L.; Okada, S.; Kong, X.F.; Kreins, A.Y.; Cypowyj, S.; Abhyankar, A.; Toubiana, J.; Itan, Y.; Audry, M.; Nitschke, P.; et al. Gain-of-function human STAT1 mutations impair IL-17 immunity and underlie chronic mucocutaneous candidiasis. *J. Exp. Med.* **2011**, *208*, 1635–1648. [[CrossRef](#)] [[PubMed](#)]
19. Toubiana, J.; Okada, S.; Hiller, J.; Oleastro, M.; Lagos Gomez, M.; Aldave Becerra, J.C.; Ouachee-Chardin, M.; Fouyssac, F.; Girisha, K.M.; Etzioni, A.; et al. Heterozygous STAT1 gain-of-function mutations underlie an unexpectedly broad clinical phenotype. *Blood* **2016**, *127*, 3154–3164. [[CrossRef](#)]
20. Diaz, N.; Juarez, M.; Cancrini, C.; Heeg, M.; Soler-Palacin, P.; Payne, A.; Johnston, G.I.; Helmer, E.; Cain, D.; Mann, J.; et al. Seletalisib for Activated PI3Kdelta Syndromes: Open-Label Phase 1b and Extension Studies. *J. Immunol.* **2020**, *205*, 2979–2987. [[CrossRef](#)]
21. Lougaris, V.; Faletra, F.; Lanzi, G.; Voizzi, D.; Marcuzzi, A.; Valencic, E.; Piscianz, E.; Bianco, A.; Girardelli, M.; Baronio, M.; et al. Altered germinal center reaction and abnormal B cell peripheral maturation in PI3KR1-mutated patients presenting with HIGM-like phenotype. *Clin. Immunol.* **2015**, *159*, 33–36. [[CrossRef](#)]
22. Valencic, E.; Grasso, A.G.; Conversano, E.; Lucafo, M.; Piscianz, E.; Gregori, M.; Conti, F.; Cancrini, C.; Tommasini, A. Theophylline as a precision therapy in a young girl with PI3KR1 immunodeficiency. *J. Allergy Clin. Immunol. Pract.* **2018**, *6*, 2165–2167. [[CrossRef](#)]
23. Hague, R.A.; Rassam, S.; Morgan, G.; Cant, A.J. Early diagnosis of severe combined immunodeficiency syndrome. *Arch. Dis. Child.* **1994**, *70*, 260–263. [[CrossRef](#)]
24. Kimmig, S.; Przybylski, G.K.; Schmidt, C.A.; Laurisch, K.; Mowes, B.; Radbruch, A.; Thiel, A. Two subsets of naive T helper cells with distinct T cell receptor excision circle content in human adult peripheral blood. *J. Exp. Med.* **2002**, *195*, 789–794. [[CrossRef](#)] [[PubMed](#)]
25. Kohler, S.; Thiel, A. Life after the thymus: CD31+ and CD31- human naive CD4+ T-cell subsets. *Blood* **2009**, *113*, 769–774. [[CrossRef](#)]
26. Dasouki, M.; Jabr, A.; Aldakheel, G.; Elbadaoui, F.; Alazami, A.M.; Al-Saud, B.; Arnaout, R.; Aldhekri, H.; Alotaibi, I.; Al-Mousa, H.; et al. TREC and KREC profiling as a representative of thymus and bone marrow output in patients with various inborn errors of immunity. *Clin. Exp. Immunol.* **2020**, *202*, 60–71. [[CrossRef](#)]
27. Junge, S.; Kloeckener-Gruissem, B.; Zufferey, R.; Keisker, A.; Salgo, B.; Fauchere, J.C.; Scherer, F.; Shalaby, T.; Grotzer, M.; Siler, U.; et al. Correlation between recent thymic emigrants and CD31+ (PECAM-1) CD4+ T cells in normal individuals during aging and in lymphopenic children. *Eur. J. Immunol.* **2007**, *37*, 3270–3280. [[CrossRef](#)] [[PubMed](#)]
28. Gerstel-Thompson, J.L.; Wilkey, J.F.; Baptiste, J.C.; Navas, J.S.; Pai, S.Y.; Pass, K.A.; Eaton, R.B.; Comeau, A.M. High-throughput multiplexed T-cell-receptor excision circle quantitative PCR assay with internal controls for detection of severe combined immunodeficiency in population-based newborn screening. *Clin. Chem.* **2010**, *56*, 1466–1474. [[CrossRef](#)] [[PubMed](#)]
29. Brown, L.; Xu-Bayford, J.; Allwood, Z.; Slatter, M.; Cant, A.; Davies, E.G.; Veys, P.; Gennery, A.R.; Gaspar, H.B. Neonatal diagnosis of severe combined immunodeficiency leads to significantly improved survival outcome: The case for newborn screening. *Blood* **2011**, *117*, 3243–3246. [[CrossRef](#)] [[PubMed](#)]
30. Kwok, J.S.Y.; Cheung, S.K.F.; Ho, J.C.Y.; Tang, I.W.H.; Chu, P.W.K.; Leung, E.Y.S.; Lee, P.P.W.; Cheuk, D.K.L.; Lee, V.; Ip, P.; et al. Establishing Simultaneous T Cell Receptor Excision Circles (TREC) and K-Deleting Recombination Excision Circles (KREC) Quantification Assays and Laboratory Reference Intervals in Healthy Individuals of Different Age Groups in Hong Kong. *Front. Immunol.* **2020**, *11*, 1411. [[CrossRef](#)]

31. Knight, V.; Heimall, J.R.; Wright, N.; Dutmer, C.M.; Boyce, T.G.; Torgerson, T.R.; Abraham, R.S. Follow-Up for an Abnormal Newborn Screen for Severe Combined Immunodeficiencies (NBS SCID): A Clinical Immunology Society (CIS) Survey of Current Practices. *Int. J. Neonatal Screen.* **2020**, *6*. [[CrossRef](#)]
32. Truck, J.; Prader, S.; Natalucci, G.; Hagmann, C.; Brotschi, B.; Kelly, J.; Bassler, D.; Steindl, K.; Rauch, A.; Baumgartner, M.; et al. Swiss newborn screening for severe T and B cell deficiency with a combined TREC/KREC assay—Management recommendations. *Swiss Med. Wkly.* **2020**, *150*, w20254. [[CrossRef](#)] [[PubMed](#)]
33. Frazer, L.C.; O'Connell, A.E. Primary immunodeficiency testing in a Massachusetts tertiary care NICU: Persistent challenges in the extremely premature population. *Pediatr. Res.* **2020**. [[CrossRef](#)] [[PubMed](#)]
34. van der Burg, M.; Mahlaoui, N.; Gaspar, H.B.; Pai, S.Y. Universal Newborn Screening for Severe Combined Immunodeficiency (SCID). *Front. Pediatr.* **2019**, *7*, 373. [[CrossRef](#)]
35. la Marca, G.; Canessa, C.; Giocaliere, E.; Romano, F.; Duse, M.; Malvagia, S.; Lippi, F.; Funghini, S.; Bianchi, L.; Della Bona, M.L.; et al. Tandem mass spectrometry, but not T-cell receptor excision circle analysis, identifies newborns with late-onset adenosine deaminase deficiency. *J. Allergy Clin. Immunol.* **2013**, *131*, 1604–1610. [[CrossRef](#)] [[PubMed](#)]
36. Kovanen, P.E.; Leonard, W.J. Cytokines and immunodeficiency diseases: Critical roles of the gamma(c)-dependent cytokines interleukins 2, 4, 7, 9, 15, and 21, and their signaling pathways. *Immunol. Rev.* **2004**, *202*, 67–83. [[CrossRef](#)]
37. Kanegane, H.; Hoshino, A.; Okano, T.; Yasumi, T.; Wada, T.; Takada, H.; Okada, S.; Yamashita, M.; Yeh, T.W.; Nishikomori, R.; et al. Flow cytometry-based diagnosis of primary immunodeficiency diseases. *Allergol. Int.* **2018**, *67*, 43–54. [[CrossRef](#)]
38. Giardino, G.; Borzacchiello, C.; De Luca, M.; Romano, R.; Prencipe, R.; Cirillo, E.; Pignata, C. T-Cell Immunodeficiencies With Congenital Alterations of Thymic Development: Genes Implicated and Differential Immunological and Clinical Features. *Front. Immunol.* **2020**, *11*, 1837. [[CrossRef](#)]
39. Sharapova, S.O.; Skomska-Pawliszak, M.; Rodina, Y.A.; Wolska-Kusnierz, B.; Dabrowska-Leonik, N.; Mikoluc, B.; Pashchenko, O.E.; Pasic, S.; Freiburger, T.; Milota, T.; et al. The Clinical and Genetic Spectrum of 82 Patients With RAG Deficiency Including a c.256_257delAA Founder Variant in Slavic Countries. *Front. Immunol.* **2020**, *11*, 900. [[CrossRef](#)] [[PubMed](#)]
40. Von Spee-Mayer, C.; Koemm, V.; Wehr, C.; Goldacker, S.; Kindle, G.; Bulashevskaya, A.; Proietti, M.; Grimbacher, B.; Ehl, S.; Warnatz, K. Evaluating laboratory criteria for combined immunodeficiency in adult patients diagnosed with common variable immunodeficiency. *Clin. Immunol.* **2019**, *203*, 59–62. [[CrossRef](#)] [[PubMed](#)]
41. Bertinchamp, R.; Gerard, L.; Boutboul, D.; Malphettes, M.; Fieschi, C.; Oksenhendler, E.; DEFI Study Group. Exclusion of Patients with a Severe T-Cell Defect Improves the Definition of Common Variable Immunodeficiency. *J. Allergy Clin. Immunol. Pract.* **2016**, *4*, 1147–1157. [[CrossRef](#)] [[PubMed](#)]
42. Ogulur, I.; Kiykim, A.; Baser, D.; Karakoc-Aydiner, E.; Ozen, A.; Baris, S. Lymphocyte Subset Abnormalities in Pediatric-Onset Common Variable Immunodeficiency. *Int. Arch. Allergy Immunol.* **2020**, *181*, 228–237. [[CrossRef](#)]
43. Piscianz, E.; Conversano, E.; Bianco, A.M.; Faletta, F.; Tommasini, A.; Valencic, E. Familial hypogammaglobulinemia with high RTE and naive T lymphocytes. *Inflamm. Res.* **2019**, *68*, 901–904. [[CrossRef](#)]
44. Lee, C.E.; Fulcher, D.A.; Whittle, B.; Chand, R.; Fewings, N.; Field, M.; Andrews, D.; Goodnow, C.C.; Cook, M.C. Autosomal-dominant B-cell deficiency with alopecia due to a mutation in NFKB2 that results in nonprocessable p100. *Blood* **2014**, *124*, 2964–2972. [[CrossRef](#)]
45. de la Fuente, M.A.; Recher, M.; Rider, N.L.; Strauss, K.A.; Morton, D.H.; Adair, M.; Bonilla, F.A.; Ochs, H.D.; Gelfand, E.W.; Pessach, I.M.; et al. Reduced thymic output, cell cycle abnormalities, and increased apoptosis of T lymphocytes in patients with cartilage-hair hypoplasia. *J. Allergy Clin. Immunol.* **2011**, *128*, 139–146. [[CrossRef](#)] [[PubMed](#)]
46. McLean-Tooke, A.; Barge, D.; Spickett, G.P.; Gennery, A.R. Immunologic defects in 22q11.2 deletion syndrome. *J. Allergy Clin. Immunol.* **2008**, *122*, 362–367.e4. [[CrossRef](#)] [[PubMed](#)]
47. Ricci, S.; Masini, M.; Valleriani, C.; Casini, A.; Cortimiglia, M.; Grisotto, L.; Canessa, C.; Indolfi, G.; Lippi, F.; Azzari, C. Reduced frequency of peripheral CD4+CD45RA+CD31+ cells and autoimmunity phenomena in patients affected by Del22q11 syndrome. *Clin. Immunol.* **2018**, *188*, 81–84. [[CrossRef](#)]
48. Montin, D.; Marolda, A.; Licciardi, F.; Robasto, F.; Di Cesare, S.; Ricotti, E.; Ferro, F.; Scaioli, G.; Giancotta, C.; Amodio, D.; et al. Immunophenotype Anomalies Predict the Development of Autoimmune Cytopenia in 22q11.2 Deletion Syndrome. *J. Allergy Clin. Immunol. Pract.* **2019**, *7*, 2369–2376. [[CrossRef](#)]
49. Lucas, C.L.; Chandra, A.; Nejentsev, S.; Condliffe, A.M.; Okkenhaug, K. PI3Kdelta and primary immunodeficiencies. *Nat. Rev. Immunol.* **2016**, *16*, 702–714. [[CrossRef](#)]
50. Haynes, B.F.; Markert, M.L.; Sempowski, G.D.; Patel, D.D.; Hale, L.P. The role of the thymus in immune reconstitution in aging, bone marrow transplantation, and HIV-1 infection. *Annu. Rev. Immunol.* **2000**, *18*, 529–560. [[CrossRef](#)]
51. Amatuni, G.S.; Sciortino, S.; Currier, R.J.; Naides, S.J.; Church, J.A.; Puck, J.M. Reference intervals for lymphocyte subsets in preterm and term neonates without immune defects. *J. Allergy Clin. Immunol.* **2019**, *144*, 1674–1683. [[CrossRef](#)]
52. Remaschi, G.; Ricci, S.; Cortimiglia, M.; De Vitis, E.; Iannuzzi, L.; Boni, L.; Azzari, C.; Dani, C. TREC and KREC in very preterm infants: Reference values and effects of maternal and neonatal factors. *J. Matern. Fetal Neonatal Med.* **2019**, 1–6. [[CrossRef](#)]
53. Van den Broek, T.; Delemarre, E.M.; Janssen, W.J.; Nievelstein, R.A.; Broen, J.C.; Tesselaar, K.; Borghans, J.A.; Nieuwenhuis, E.E.; Prakken, B.J.; Mokry, M.; et al. Neonatal thymectomy reveals differentiation and plasticity within human naive T cells. *J. Clin. Invest.* **2016**, *126*, 1126–1136. [[CrossRef](#)]

54. Mengrelis, K.; Kucera, F.; Shahid, N.; Watt, E.; Ross, S.; Lau, C.I.; Adams, S.; Gilmour, K.; Pils, D.; Crompton, T.; et al. T cell phenotype in paediatric heart transplant recipients. *Pediatr. Transplant.* **2020**, e13930. [[CrossRef](#)]
55. Sun, Y.; Fu, Y.; Zhang, Z.; Tang, T.; Liu, J.; Ding, H.; Han, X.; Xu, J.; Chu, Z.; Shang, H.; et al. The investigation of CD4+T-cell functions in primary HIV infection with antiretroviral therapy. *Medicine (Baltim.)* **2017**, *96*, e7430. [[CrossRef](#)]
56. Krenger, W.; Blazar, B.R.; Hollander, G.A. Thymic T-cell development in allogeneic stem cell transplantation. *Blood* **2011**, *117*, 6768–6776. [[CrossRef](#)]
57. Gaballa, A.; Clave, E.; Uhlin, M.; Toubert, A.; Arruda, L.C.M. Evaluating Thymic Function After Human Hematopoietic Stem Cell Transplantation in the Personalized Medicine Era. *Front. Immunol.* **2020**, *11*, 1341. [[CrossRef](#)] [[PubMed](#)]
58. Van den Brink, M.R.; Velardi, E.; Perales, M.A. Immune reconstitution following stem cell transplantation. *Hematol. Am. Soc. Hematol. Educ. Program* **2015**, *2015*, 215–219. [[CrossRef](#)]
59. Velardi, E.; Tsai, J.J.; van den Brink, M.R.M. T cell regeneration after immunological injury. *Nat. Rev. Immunol.* **2020**. [[CrossRef](#)] [[PubMed](#)]
60. Pinti, M.; Nasi, M.; Lugli, E.; Gibellini, L.; Bertocelli, L.; Roat, E.; De Biasi, S.; Mussini, C.; Cossarizza, A. T cell homeostasis in centenarians: From the thymus to the periphery. *Curr. Pharm. Des.* **2010**, *16*, 597–603. [[CrossRef](#)] [[PubMed](#)]
61. Schmucker, B.; Meindl, A.; Achatz, H.; Mittermuller, J.; Kruger, G.; Hergersberg, M.; Spiegel, R.; Schinzel, A.; Belohradsky, B.H.; Murken, J.; et al. A PCR based X-chromosome inactivation assay for carrier detection in X-linked immunodeficiencies using differential methylation of the androgen receptor gene. *Immunodeficiency* **1995**, *5*, 187–192.
62. Li, S.L.; Ting, S.S.; Lindeman, R.; Ffrench, R.; Ziegler, J.B. Carrier identification in X-linked immunodeficiency diseases. *J. Paediatr. Child. Health* **1998**, *34*, 273–279. [[CrossRef](#)]
63. Migeon, B.R. X-linked diseases: Susceptible females. *Genet. Med.* **2020**, *22*, 1156–1174. [[CrossRef](#)] [[PubMed](#)]
64. Fearon, E.R.; Kohn, D.B.; Winkelstein, J.A.; Vogelstein, B.; Blaese, R.M. Carrier detection in the Wiskott Aldrich syndrome. *Blood* **1988**, *72*, 1735–1739. [[CrossRef](#)] [[PubMed](#)]
65. Tornai, I.; Kiss, A.; Laczko, J. Wiskott-Aldrich syndrome in a heterozygous carrier woman. *Eur. J. Haematol.* **1989**, *42*, 501–502. [[CrossRef](#)] [[PubMed](#)]
66. Parolini, O.; Ressmann, G.; Haas, O.A.; Pawlowsky, J.; Gadner, H.; Knapp, W.; Holter, W. X-linked Wiskott-Aldrich syndrome in a girl. *N. Engl. J. Med.* **1998**, *338*, 291–295. [[CrossRef](#)]
67. Lutskiy, M.I.; Sasahara, Y.; Kenney, D.M.; Rosen, F.S.; Remold-O'Donnell, E. Wiskott-Aldrich syndrome in a female. *Blood* **2002**, *100*, 2763–2768. [[CrossRef](#)]
68. Takimoto, T.; Takada, H.; Ishimura, M.; Kirino, M.; Hata, K.; Ohara, O.; Morio, T.; Hara, T. Wiskott-Aldrich syndrome in a girl caused by heterozygous WASP mutation and extremely skewed X-chromosome inactivation: A novel association with maternal uniparental isodisomy 6. *Neonatology* **2015**, *107*, 185–190. [[CrossRef](#)]
69. Brandrup, F.; Koch, C.; Petri, M.; Schiodt, M.; Johansen, K.S. Discoid lupus erythematosus-like lesions and stomatitis in female carriers of X-linked chronic granulomatous disease. *Br. J. Dermatol.* **1981**, *104*, 495–505. [[CrossRef](#)]
70. Marciano, B.E.; Zerbe, C.S.; Falcone, E.L.; Ding, L.; DeRavin, S.S.; Daub, J.; Kreuzburg, S.; Yockey, L.; Hunsberger, S.; Foruraghi, L.; et al. X-linked carriers of chronic granulomatous disease: Illness, lyonization, and stability. *J. Allergy Clin. Immunol.* **2018**, *141*, 365–371. [[CrossRef](#)] [[PubMed](#)]
71. Cale, C.M.; Morton, L.; Goldblatt, D. Cutaneous and other lupus-like symptoms in carriers of X-linked chronic granulomatous disease: Incidence and autoimmune serology. *Clin. Exp. Immunol.* **2007**, *148*, 79–84. [[CrossRef](#)]
72. Allen, R.C.; Nachtman, R.G.; Rosenblatt, H.M.; Belmont, J.W. Application of carrier testing to genetic counseling for X-linked agammaglobulinemia. *Am. J. Hum. Genet.* **1994**, *54*, 25–35.
73. Takada, H.; Kanegane, H.; Nomura, A.; Yamamoto, K.; Ihara, K.; Takahashi, Y.; Tsukada, S.; Miyawaki, T.; Hara, T. Female agammaglobulinemia due to the Bruton tyrosine kinase deficiency caused by extremely skewed X-chromosome inactivation. *Blood* **2004**, *103*, 185–187. [[CrossRef](#)]
74. Di Nunzio, S.; Cecconi, M.; Passerini, L.; McMurphy, A.N.; Baron, U.; Turbachova, I.; Vignola, S.; Valencic, E.; Tommasini, A.; Junker, A.; et al. Wild-type FOXP3 is selectively active in CD4+CD25(hi) regulatory T cells of healthy female carriers of different FOXP3 mutations. *Blood* **2009**, *114*, 4138–4141. [[CrossRef](#)]
75. Tommasini, A.; Ferrari, S.; Moratto, D.; Badolato, R.; Boniotto, M.; Pirulli, D.; Notarangelo, L.D.; Andolina, M. X-chromosome inactivation analysis in a female carrier of FOXP3 mutation. *Clin. Exp. Immunol.* **2002**, *130*, 127–130. [[CrossRef](#)] [[PubMed](#)]
76. Barzaghi, F.; Passerini, L.; Gambineri, E.; Ciullini Mannurita, S.; Cornu, T.; Kang, E.S.; Choe, Y.H.; Cancrini, C.; Corrente, S.; Ciccocioppo, R.; et al. Demethylation analysis of the FOXP3 locus shows quantitative defects of regulatory T cells in IPEX-like syndrome. *J. Autoimmun.* **2012**, *38*, 49–58. [[CrossRef](#)]
77. Fusco, F.; Bardaro, T.; Fimiani, G.; Mercadante, V.; Miano, M.G.; Falco, G.; Israel, A.; Courtois, G.; D'Urso, M.; Ursini, M.V. Molecular analysis of the genetic defect in a large cohort of IP patients and identification of novel NEMO mutations interfering with NF-kappaB activation. *Hum. Mol. Genet.* **2004**, *13*, 1763–1773. [[CrossRef](#)]
78. Ohnishi, H.; Kishimoto, Y.; Taguchi, T.; Kawamoto, N.; Nakama, M.; Kawai, T.; Nakayama, M.; Ohara, O.; Orii, K.; Fukao, T. Immunodeficiency in Two Female Patients with Incontinentia Pigmenti with Heterozygous NEMO Mutation Diagnosed by LPS Unresponsiveness. *J. Clin. Immunol.* **2017**, *37*, 529–538. [[CrossRef](#)] [[PubMed](#)]

79. Martinez-Pomar, N.; Munoz-Saa, I.; Heine-Suner, D.; Martin, A.; Smahi, A.; Matamoros, N. A new mutation in exon 7 of NEMO gene: Late skewed X-chromosome inactivation in an incontinentia pigmenti female patient with immunodeficiency. *Hum. Genet.* **2005**, *118*, 458–465. [[CrossRef](#)] [[PubMed](#)]
80. Mooster, J.L.; Cancrini, C.; Simonetti, A.; Rossi, P.; Di Matteo, G.; Romiti, M.L.; Di Cesare, S.; Notarangelo, L.; Geha, R.S.; McDonald, D.R. Immune deficiency caused by impaired expression of nuclear factor-kappaB essential modifier (NEMO) because of a mutation in the 5' untranslated region of the NEMO gene. *J. Allergy Clin. Immunol.* **2010**, *126*, 127–132. [[CrossRef](#)] [[PubMed](#)]
81. Xu, J.; Khincha, P.P.; Giri, N.; Alter, B.P.; Savage, S.A.; Wong, J.M. Investigation of chromosome X inactivation and clinical phenotypes in female carriers of DKC1 mutations. *Am. J. Hematol.* **2016**, *91*, 1215–1220. [[CrossRef](#)] [[PubMed](#)]
82. Alder, J.K.; Parry, E.M.; Yegnasubramanian, S.; Wagner, C.L.; Lieblich, L.M.; Auerbach, R.; Auerbach, A.D.; Wheelan, S.J.; Armanios, M. Telomere phenotypes in females with heterozygous mutations in the dyskeratosis congenita 1 (DKC1) gene. *Hum. Mutat.* **2013**, *34*, 1481–1485. [[CrossRef](#)]
83. Khincha, P.P.; Dagnall, C.L.; Hicks, B.; Jones, K.; Aviv, A.; Kimura, M.; Katki, H.; Aubert, G.; Giri, N.; Alter, B.P.; et al. Correlation of Leukocyte Telomere Length Measurement Methods in Patients with Dyskeratosis Congenita and in Their Unaffected Relatives. *Int. J. Mol. Sci.* **2017**, *18*, 1765. [[CrossRef](#)] [[PubMed](#)]
84. Holle, J.R.; Marsh, R.A.; Holdcroft, A.M.; Davies, S.M.; Wang, L.; Zhang, K.; Jordan, M.B. Hemophagocytic lymphohistiocytosis in a female patient due to a heterozygous XIAP mutation and skewed X chromosome inactivation. *Pediatr. Blood Cancer* **2015**, *62*, 1288–1290. [[CrossRef](#)] [[PubMed](#)]
85. Aguilar, C.; Lenoir, C.; Lambert, N.; Begue, B.; Brousse, N.; Canioni, D.; Berrebi, D.; Roy, M.; Gerart, S.; Chapel, H.; et al. Characterization of Crohn disease in X-linked inhibitor of apoptosis-deficient male patients and female symptomatic carriers. *J. Allergy Clin. Immunol.* **2014**, *134*, 1131–1141. [[CrossRef](#)] [[PubMed](#)]
86. Gifford, C.E.; Weingartner, E.; Villanueva, J.; Johnson, J.; Zhang, K.; Filipovich, A.H.; Blesing, J.J.; Marsh, R.A. Clinical flow cytometric screening of SAP and XIAP expression accurately identifies patients with SH2D1A and XIAP/BIRC4 mutations. *Cytom. B Clin. Cytom.* **2014**, *86*, 263–271. [[CrossRef](#)]
87. Morra, M.; Silander, O.; Calpe, S.; Choi, M.; Oettgen, H.; Myers, L.; Etzioni, A.; Buckley, R.; Terhorst, C. Alterations of the X-linked lymphoproliferative disease gene SH2D1A in common variable immunodeficiency syndrome. *Blood* **2001**, *98*, 1321–1325. [[CrossRef](#)] [[PubMed](#)]
88. Liang, J.H.; Zhu, H.Y.; Xu, D.M.; Wang, L.; Wang, Y.; Qiao, C.; Wu, Y.J.; Wang, R.; Li, J.Y.; Xu, W. A new SH2D1A mutation in a female adult XLP disease with hemophagocytic lymphohistiocytosis and NK-cell leukemia. *Ann. Hematol.* **2019**, *98*, 2829–2831. [[CrossRef](#)]
89. de Saint Basile, G.; Tabone, M.D.; Durandy, A.; Phan, F.; Fischer, A.; Le Deist, F. CD40 ligand expression deficiency in a female carrier of the X-linked hyper-IgM syndrome as a result of X chromosome lyonization. *Eur. J. Immunol.* **1999**, *29*, 367–373. [[CrossRef](#)]
90. Imai, K.; Shimadzu, M.; Kubota, T.; Morio, T.; Matsunaga, T.; Park, Y.D.; Yoshioka, A.; Nonoyama, S. Female hyper IgM syndrome type 1 with a chromosomal translocation disrupting CD40LG. *Biochim. Biophys. Acta* **2006**, *1762*, 335–340. [[CrossRef](#)] [[PubMed](#)]
91. Li, F.Y.; Chaigne-Delalande, B.; Kanellopoulou, C.; Davis, J.C.; Matthews, H.F.; Douek, D.C.; Cohen, J.I.; Uzel, G.; Su, H.C.; Lenardo, M.J. Second messenger role for Mg²⁺ revealed by human T-cell immunodeficiency. *Nature* **2011**, *475*, 471–476. [[CrossRef](#)]
92. Blommaert, E.; Peanne, R.; Cherepanova, N.A.; Rymen, D.; Staels, F.; Jaeken, J.; Race, V.; Keldermans, L.; Souche, E.; Corveleyn, A.; et al. Mutations in MAGT1 lead to a glycosylation disorder with a variable phenotype. *Proc. Natl. Acad. Sci. USA* **2019**, *116*, 9865–9870. [[CrossRef](#)]
93. Al-Mousa, H.; Abouelhoda, M.; Monies, D.M.; Al-Tassan, N.; Al-Ghoniaim, A.; Al-Saud, B.; Al-Dhekri, H.; Arnaout, R.; Al-Muhsen, S.; Ades, N.; et al. Unbiased targeted next-generation sequencing molecular approach for primary immunodeficiency diseases. *J. Allergy Clin. Immunol.* **2016**, *137*, 1780–1787. [[CrossRef](#)] [[PubMed](#)]
94. Quinn, J.; Modell, V.; Holle, J.; Truty, R.; Aradhya, S.; Johnson, B.; Orange, J.; Modell, F. Jeffrey's insights: Jeffrey Modell Foundation's global genetic sequencing pilot program to identify specific primary immunodeficiency defects to optimize disease management and treatment. *Immunol. Res.* **2020**, *68*, 126–134. [[CrossRef](#)]
95. Purswani, P.; Meehan, C.A.; Kuehn, H.S.; Chang, Y.; Dasso, J.F.; Meyer, A.K.; Ujhazi, B.; Csomos, K.; Lindsay, D.; Alberdi, T.; et al. Two Unique Cases of X-linked SCID: A Diagnostic Challenge in the Era of Newborn Screening. *Front. Pediatr.* **2019**, *7*, 55. [[CrossRef](#)]
96. Defendi, F.; Decleva, E.; Martel, C.; Dri, P.; Stasia, M.J. A novel point mutation in the CYBB gene promoter leading to a rare X minus chronic granulomatous disease variant—Impact on the microbicidal activity of neutrophils. *Biochim. Biophys. Acta* **2009**, *1792*, 201–210. [[CrossRef](#)]
97. Tabata, Y.; Villanueva, J.; Lee, S.M.; Zhang, K.; Kanegane, H.; Miyawaki, T.; Sumegi, J.; Filipovich, A.H. Rapid detection of intracellular SH2D1A protein in cytotoxic lymphocytes from patients with X-linked lymphoproliferative disease and their family members. *Blood* **2005**, *105*, 3066–3071. [[CrossRef](#)] [[PubMed](#)]
98. Cabral-Marques, O.; Schimke, L.F.; de Oliveira, E.B., Jr.; El Khawanky, N.; Ramos, R.N.; Al-Ramadi, B.K.; Segundo, G.R.S.; Ochs, H.D.; Condino-Neto, A. Flow Cytometry Contributions for the Diagnosis and Immunopathological Characterization of Primary Immunodeficiency Diseases With Immune Dysregulation. *Front. Immunol.* **2019**, *10*, 2742. [[CrossRef](#)]

99. Tangye, S.G.; Al-Herz, W.; Bousfiha, A.; Chatila, T.; Cunningham-Rundles, C.; Etzioni, A.; Franco, J.L.; Holland, S.M.; Klein, C.; Morio, T.; et al. Human Inborn Errors of Immunity: 2019 Update on the Classification from the International Union of Immunological Societies Expert Committee. *J. Clin. Immunol.* **2020**, *40*, 24–64. [[CrossRef](#)] [[PubMed](#)]
100. Tangye, S.G.; Bucciol, G.; Casas-Martin, J.; Pillay, B.; Ma, C.S.; Moens, L.; Meyts, I. Human inborn errors of the actin cytoskeleton affecting immunity: Way beyond WAS and WIP. *Immunol. Cell Biol.* **2019**, *97*, 389–402. [[CrossRef](#)]
101. Sprenkeler, E.G.G.; Webbers, S.D.S.; Kuijpers, T.W. When Actin is Not Actin' Like It Should: A New Category of Distinct Primary Immunodeficiency Disorders. *J. Innate Immun.* **2020**, 1–23. [[CrossRef](#)] [[PubMed](#)]
102. Janssen, E.; Geha, R.S. Primary immunodeficiencies caused by mutations in actin regulatory proteins. *Immunol. Rev.* **2019**, *287*, 121–134. [[CrossRef](#)] [[PubMed](#)]
103. Sakai, Y.; Tanaka, Y.; Yanagihara, T.; Watanabe, M.; Duan, X.; Terasawa, M.; Nishikimi, A.; Sanematsu, F.; Fukui, Y. The Rac activator DOCK2 regulates natural killer cell-mediated cytotoxicity in mice through the lytic synapse formation. *Blood* **2013**, *122*, 386–393. [[CrossRef](#)] [[PubMed](#)]
104. Ham, H.; Guerrier, S.; Kim, J.; Schoon, R.A.; Anderson, E.L.; Hamann, M.J.; Lou, Z.; Billadeau, D.D. Deducator of cytokinesis 8 interacts with talin and Wiskott-Aldrich syndrome protein to regulate NK cell cytotoxicity. *J. Immunol.* **2013**, *190*, 3661–3669. [[CrossRef](#)] [[PubMed](#)]
105. Randall, K.L.; Lambe, T.; Johnson, A.L.; Treanor, B.; Kucharska, E.; Domaschenz, H.; Whittle, B.; Tze, L.E.; Enders, A.; Crockford, T.L.; et al. Dock8 mutations cripple B cell immunological synapses, germinal centers and long-lived antibody production. *Nat. Immunol.* **2009**, *10*, 1283–1291. [[CrossRef](#)] [[PubMed](#)]
106. Omenetti, A.; Carta, S.; Caorsi, R.; Finetti, M.; Marotto, D.; Lattanzi, B.; Jorini, M.; Delfino, L.; Penco, F.; Picco, P.; et al. Disease activity accounts for long-term efficacy of IL-1 blockers in pyogenic sterile arthritis pyoderma gangrenosum and severe acne syndrome. *Rheumatology (Oxf.)* **2016**, *55*, 1325–1335. [[CrossRef](#)]
107. Holzinger, D.; Fassl, S.K.; de Jager, W.; Lohse, P.; Rohrig, U.F.; Gattorno, M.; Omenetti, A.; Chiesa, S.; Schena, F.; Austermann, J.; et al. Single amino acid charge switch defines clinically distinct proline-serine-threonine phosphatase-interacting protein 1 (PSTPIP1)-associated inflammatory diseases. *J. Allergy Clin. Immunol.* **2015**, *136*, 1337–1345. [[CrossRef](#)] [[PubMed](#)]
108. Marzano, A.V.; Trevisan, V.; Gattorno, M.; Ceccherini, I.; De Simone, C.; Crosti, C. Pyogenic arthritis, pyoderma gangrenosum, acne, and hidradenitis suppurativa (PAPASH): A new autoinflammatory syndrome associated with a novel mutation of the PSTPIP1 gene. *JAMA Dermatol.* **2013**, *149*, 762–764. [[CrossRef](#)]
109. Park, Y.H.; Wood, G.; Kastner, D.L.; Chae, J.J. Pyrin inflammasome activation and RhoA signaling in the autoinflammatory diseases FMF and HIDS. *Nat. Immunol.* **2016**, *17*, 914–921. [[CrossRef](#)]
110. Pecher, A.C.; Igney-Oertel, A.; Kanz, L.; Henes, J. Treatment of familial Mediterranean fever with anakinra in patients unresponsive to colchicine. *Scand. J. Rheumatol.* **2017**, *46*, 407–409. [[CrossRef](#)] [[PubMed](#)]
111. Gernez, Y.; de Jesus, A.A.; Alsaleem, H.; Macaubas, C.; Roy, A.; Lovell, D.; Jagadeesh, K.A.; Alehashemi, S.; Erdman, L.; Grimley, M.; et al. Severe autoinflammation in 4 patients with C-terminal variants in cell division control protein 42 homolog (CDC42) successfully treated with IL-1beta inhibition. *J. Allergy Clin. Immunol.* **2019**, *144*, 1122–1125. [[CrossRef](#)]
112. Lam, M.T.; Coppola, S.; Krumbach, O.H.F.; Prencipe, G.; Insalaco, A.; Cifaldi, C.; Brigida, I.; Zara, E.; Scala, S.; Di Cesare, S.; et al. A novel disorder involving dyshematopoiesis, inflammation, and HLH due to aberrant CDC42 function. *J. Exp. Med.* **2019**, *216*, 2778–2799. [[CrossRef](#)] [[PubMed](#)]
113. Lee, P.P.; Lobato-Marquez, D.; Pramanik, N.; Sirianni, A.; Daza-Cajigal, V.; Rivers, E.; Cavazza, A.; Bouma, G.; Moulding, D.; Hultenby, K.; et al. Wiskott-Aldrich syndrome protein regulates autophagy and inflammasome activity in innate immune cells. *Nat. Commun.* **2017**, *8*, 1576. [[CrossRef](#)]
114. Volpi, S.; Cicalese, M.P.; Tuijnburg, P.; Tool, A.T.J.; Cuadrado, E.; Abu-Halaweh, M.; Ahanchian, H.; Alzyoud, R.; Akdemir, Z.C.; Barzaghi, F.; et al. A combined immunodeficiency with severe infections, inflammation, and allergy caused by ARPC1B deficiency. *J. Allergy Clin. Immunol.* **2019**, *143*, 2296–2299. [[CrossRef](#)]
115. Kuhns, D.B.; Fink, D.L.; Choi, U.; Sweeney, C.; Lau, K.; Priel, D.L.; Riva, D.; Mendez, L.; Uzel, G.; Freeman, A.F.; et al. Cytoskeletal abnormalities and neutrophil dysfunction in WDR1 deficiency. *Blood* **2016**, *128*, 2135–2143. [[CrossRef](#)] [[PubMed](#)]
116. Kim, M.L.; Chae, J.J.; Park, Y.H.; De Nardo, D.; Stirzaker, R.A.; Ko, H.J.; Tye, H.; Cengia, L.; DiRago, L.; Metcalf, D.; et al. Aberrant actin depolymerization triggers the pyrin inflammasome and autoinflammatory disease that is dependent on IL-18, not IL-1beta. *J. Exp. Med.* **2015**, *212*, 927–938. [[CrossRef](#)] [[PubMed](#)]
117. Papadopoulou, C.; Omoyinmi, E.; Standing, A.; Pain, C.E.; Booth, C.; D'Arco, F.; Gilmour, K.; Buckland, M.; Eleftheriou, D.; Brogan, P.A. Monogenic mimics of Behcet's disease in the young. *Rheumatology (Oxf.)* **2019**, *58*, 1227–1238. [[CrossRef](#)]
118. Chae, J.J.; Park, Y.H.; Park, C.; Hwang, I.Y.; Hoffmann, P.; Kehrl, J.H.; Aksentijevich, I.; Kastner, D.L. Connecting two pathways through Ca²⁺ signaling: NLRP3 inflammasome activation induced by a hypermorphic PLCG2 mutation. *Arthritis Rheumatol.* **2015**, *67*, 563–567. [[CrossRef](#)]
119. Standing, A.S.; Malinova, D.; Hong, Y.; Record, J.; Moulding, D.; Blundell, M.P.; Nowak, K.; Jones, H.; Omoyinmi, E.; Gilmour, K.C.; et al. Autoinflammatory periodic fever, immunodeficiency, and thrombocytopenia (PFIT) caused by mutation in actin-regulatory gene WDR1. *J. Exp. Med.* **2017**, *214*, 59–71. [[CrossRef](#)]
120. Kile, B.T.; Panopoulos, A.D.; Stirzaker, R.A.; Hacking, D.F.; Tahtamouni, L.H.; Willson, T.A.; Mielke, L.A.; Henley, K.J.; Zhang, J.G.; Wicks, I.P.; et al. Mutations in the cofilin partner Aip1/Wdr1 cause autoinflammatory disease and macrothrombocytopenia. *Blood* **2007**, *110*, 2371–2380. [[CrossRef](#)] [[PubMed](#)]

121. Castro, C.N.; Rosenzweig, M.; Carapito, R.; Shahrooei, M.; Konantz, M.; Khan, A.; Miao, Z.; Gross, M.; Tranchant, T.; Radosavljevic, M.; et al. NCKAP1L defects lead to a novel syndrome combining immunodeficiency, lymphoproliferation, and hyperinflammation. *J. Exp. Med.* **2020**, *217*. [[CrossRef](#)] [[PubMed](#)]
122. Aeschlimann, F.A.; Laxer, R.M. Haploinsufficiency of A20 and other paediatric inflammatory disorders with mucosal involvement. *Curr. Opin. Rheumatol.* **2018**, *30*, 506–513. [[CrossRef](#)]
123. Bousfiha, A.; Jeddane, L.; Picard, C.; Al-Herz, W.; Ailal, F.; Chatila, T.; Cunningham-Rundles, C.; Etzioni, A.; Franco, J.L.; Holland, S.M.; et al. Human Inborn Errors of Immunity: 2019 Update of the IUIS Phenotypical Classification. *J. Clin. Immunol.* **2020**, *40*, 66–81. [[CrossRef](#)] [[PubMed](#)]
124. Volkl, S.; Rensing-Ehl, A.; Allgauer, A.; Schreiner, E.; Lorenz, M.R.; Rohr, J.; Klemann, C.; Fuchs, I.; Schuster, V.; von Bueren, A.O.; et al. Hyperactive mTOR pathway promotes lymphoproliferation and abnormal differentiation in autoimmune lymphoproliferative syndrome. *Blood* **2016**, *128*, 227–238. [[CrossRef](#)]
125. Jung, S.; Gamez-Diaz, L.; Proietti, M.; Grimbacher, B. “Immune TOR-opathies,” a Novel Disease Entity in Clinical Immunology. *Front. Immunol.* **2018**, *9*, 966. [[CrossRef](#)]
126. Nocerino, A.; Valencic, E.; Loganes, C.; Pelos, G.; Tommasini, A. Low-dose sirolimus in two cousins with autoimmune lymphoproliferative syndrome-associated infection. *Pediatr. Int.* **2018**, *60*, 315–317. [[CrossRef](#)] [[PubMed](#)]
127. Bevacqua, M.; Baldo, F.; Pastore, S.; Valencic, E.; Tommasini, A.; Maestro, A.; Rabusin, M.; Arbo, A.; Barbi, E. Off-Label Use of Sirolimus and Everolimus in a Pediatric Center: A Case Series and Review of the Literature. *Paediatr. Drugs* **2019**, *21*, 185–193. [[CrossRef](#)]
128. Rao, V.K.; Webster, S.; Dalm, V.; Sediva, A.; van Hagen, P.M.; Holland, S.; Rosenzweig, S.D.; Christ, A.D.; Sloth, B.; Cabanski, M.; et al. Effective “activated PI3Kdelta syndrome”-targeted therapy with the PI3Kdelta inhibitor leniolisib. *Blood* **2017**, *130*, 2307–2316. [[CrossRef](#)] [[PubMed](#)]
129. Coulter, T.I.; Cant, A.J. The Treatment of Activated PI3Kdelta Syndrome. *Front. Immunol.* **2018**, *9*, 2043. [[CrossRef](#)]
130. Maccari, M.E.; Abolhassani, H.; Aghamohammadi, A.; Aiuti, A.; Aleinikova, O.; Bangs, C.; Baris, S.; Barzaghi, F.; Baxendale, H.; Buckland, M.; et al. Disease Evolution and Response to Rapamycin in Activated Phosphoinositide 3-Kinase delta Syndrome: The European Society for Immunodeficiencies-Activated Phosphoinositide 3-Kinase delta Syndrome Registry. *Front. Immunol.* **2018**, *9*, 543. [[CrossRef](#)]
131. Tesch, V.K.; Abolhassani, H.; Shadur, B.; Zobel, J.; Mareika, Y.; Sharapova, S.; Karakoc-Aydiner, E.; Riviere, J.G.; Garcia-Prat, M.; Moes, N.; et al. Long-term outcome of LRBA deficiency in 76 patients after various treatment modalities as evaluated by the immune deficiency and dysregulation activity (IDDA) score. *J. Allergy Clin. Immunol.* **2020**, *145*, 1452–1463. [[CrossRef](#)]
132. Lo, B.; Zhang, K.; Lu, W.; Zheng, L.; Zhang, Q.; Kanellopoulou, C.; Zhang, Y.; Liu, Z.; Fritz, J.M.; Marsh, R.; et al. AUTOIMMUNE DISEASE. Patients with LRBA deficiency show CTLA4 loss and immune dysregulation responsive to abatacept therapy. *Science* **2015**, *349*, 436–440. [[CrossRef](#)]
133. Kimura, H.; Cohen, J.I. Chronic Active Epstein-Barr Virus Disease. *Front. Immunol.* **2017**, *8*, 1867. [[CrossRef](#)] [[PubMed](#)]
134. Tangye, S.G.; Latour, S. Primary immunodeficiencies reveal the molecular requirements for effective host defense against EBV infection. *Blood* **2020**, *135*, 644–655. [[CrossRef](#)]
135. Sharifinejad, N.; Azizi, G.; Behniafard, N.; Zaki-Dizaji, M.; Jamee, M.; Yazdani, R.; Abolhassani, H.; Aghamohammadi, A. Protein Kinase C-Delta Defect in Autoimmune Lymphoproliferative Syndrome-Like Disease: First Case from the National Iranian Registry and Review of the Literature. *Immunol. Investig.* **2020**, *1–12*. [[CrossRef](#)] [[PubMed](#)]
136. Klemann, C.; Esquivel, M.; Magerus-Chatinet, A.; Lorenz, M.R.; Fuchs, I.; Neveux, N.; Castelle, M.; Rohr, J.; da Cunha, C.B.; Ebinger, M.; et al. Evolution of disease activity and biomarkers on and off rapamycin in 28 patients with autoimmune lymphoproliferative syndrome. *Haematologica* **2017**, *102*, e52–e56. [[CrossRef](#)]
137. Rao, V.K. Approaches to Managing Autoimmune Cytopenias in Novel Immunological Disorders with Genetic Underpinnings Like Autoimmune Lymphoproliferative Syndrome. *Front. Pediatr.* **2015**, *3*, 65. [[CrossRef](#)]
138. Teachey, D.T. New advances in the diagnosis and treatment of autoimmune lymphoproliferative syndrome. *Curr. Opin. Pediatr.* **2012**, *24*, 1–8. [[CrossRef](#)]
139. Kuehn, H.S.; Niemela, J.E.; Rangel-Santos, A.; Zhang, M.; Pittaluga, S.; Stoddard, J.L.; Hussey, A.A.; Evbuomwan, M.O.; Priel, D.A.; Kuhns, D.B.; et al. Loss-of-function of the protein kinase C delta (PKCdelta) causes a B-cell lymphoproliferative syndrome in humans. *Blood* **2013**, *121*, 3117–3125. [[CrossRef](#)]
140. Passerini, L.; Barzaghi, F.; Curto, R.; Sartirana, C.; Barera, G.; Tucci, F.; Albarello, L.; Mariani, A.; Testoni, P.A.; Bazzigaluppi, E.; et al. Treatment with rapamycin can restore regulatory T-cell function in IPEX patients. *J. Allergy Clin. Immunol.* **2020**, *145*, 1262–1271. [[CrossRef](#)] [[PubMed](#)]
141. Yong, P.L.; Russo, P.; Sullivan, K.E. Use of sirolimus in IPEX and IPEX-like children. *J. Clin. Immunol.* **2008**, *28*, 581–587. [[CrossRef](#)] [[PubMed](#)]
142. Puel, A. Human inborn errors of immunity underlying superficial or invasive candidiasis. *Hum. Genet.* **2020**, *139*, 1011–1022. [[CrossRef](#)] [[PubMed](#)]
143. Moriya, K.; Suzuki, T.; Uchida, N.; Nakano, T.; Katayama, S.; Irie, M.; Rikiishi, T.; Niizuma, H.; Okada, S.; Imai, K.; et al. Ruxolitinib treatment of a patient with steroid-dependent severe autoimmunity due to STAT1 gain-of-function mutation. *Int. J. Hematol.* **2020**, *112*, 258–262. [[CrossRef](#)] [[PubMed](#)]

144. Du, B.; Shen, N.; Hu, J.; Tao, Y.; Mo, X.; Cao, Q. Complete clinical remission of invasive Candida infection with CARD9 deficiency after G-CSF treatment. *Comp. Immunol. Microbiol. Infect. Dis.* **2020**, *70*, 101417. [[CrossRef](#)]
145. Latour, S.; Fischer, A. Signaling pathways involved in the T-cell-mediated immunity against Epstein-Barr virus: Lessons from genetic diseases. *Immunol. Rev.* **2019**, *291*, 174–189. [[CrossRef](#)]
146. Tangye, S.G. Genetic susceptibility to EBV infection: Insights from inborn errors of immunity. *Hum. Genet.* **2020**, *139*, 885–901. [[CrossRef](#)]
147. Fournier, B.; Boutboul, D.; Bruneau, J.; Miot, C.; Boulanger, C.; Malphettes, M.; Pellier, I.; Dunogue, B.; Terrier, B.; Suarez, F.; et al. Rapid identification and characterization of infected cells in blood during chronic active Epstein-Barr virus infection. *J. Exp. Med.* **2020**, *217*. [[CrossRef](#)]
148. Leiding, J.W.; Holland, S.M. Warts and all: Human papillomavirus in primary immunodeficiencies. *J. Allergy Clin. Immunol.* **2012**, *130*, 1030–1048. [[CrossRef](#)]
149. Cummings, L.; Tucker, M.; Gibson, M.; Myers, A.; Pastinen, T.; Johnston, J.; Farrow, E.; Sampath, V. Rare Genetic Variants in Immune Genes and Neonatal Herpes Simplex Viral Infections. *Pediatrics* **2021**, *147*. [[CrossRef](#)]
150. Bastard, P.; Manry, J.; Chen, J.; Rosain, J.; Seeleuthner, Y.; AbuZaitun, O.; Lorenzo, L.; Khan, T.; Hasek, M.; Hernandez, N.; et al. Herpes simplex encephalitis in a patient with a distinctive form of inherited IFNAR1 deficiency. *J. Clin. Investig.* **2020**. [[CrossRef](#)] [[PubMed](#)]
151. Zhang, S.Y.; Clark, N.E.; Freije, C.A.; Pauwels, E.; Taggart, A.J.; Okada, S.; Mandel, H.; Garcia, P.; Ciancanelli, M.J.; Biran, A.; et al. Inborn Errors of RNA Lariat Metabolism in Humans with Brainstem Viral Infection. *Cell* **2018**, *172*, 952–965. [[CrossRef](#)] [[PubMed](#)]
152. Sancho-Shimizu, V.; Zhang, S.Y.; Abel, L.; Tardieu, M.; Rozenberg, F.; Jouanguy, E.; Casanova, J.L. Genetic susceptibility to herpes simplex virus 1 encephalitis in mice and humans. *Curr. Opin. Allergy Clin. Immunol.* **2007**, *7*, 495–505. [[CrossRef](#)] [[PubMed](#)]
153. Jing, H.; Su, H.C. New immunodeficiency syndromes that help us understand the IFN-mediated antiviral immune response. *Curr. Opin. Pediatr.* **2019**, *31*, 815–820. [[CrossRef](#)] [[PubMed](#)]
154. Kerner, G.; Rosain, J.; Guerin, A.; Al-Khabaz, A.; Oleaga-Quintas, C.; Rapaport, F.; Massaad, M.J.; Ding, J.Y.; Khan, T.; Ali, F.A.; et al. Inherited human IFN-gamma deficiency underlies mycobacterial disease. *J. Clin. Investig.* **2020**, *130*, 3158–3171. [[CrossRef](#)] [[PubMed](#)]
155. Alangari, A.A.; Al-Zamil, F.; Al-Mazrou, A.; Al-Muhsen, S.; Boisson-Dupuis, S.; Awadallah, S.; Kambal, A.; Casanova, J.L. Treatment of disseminated mycobacterial infection with high-dose IFN-gamma in a patient with IL-12Rbeta1 deficiency. *Clin. Dev. Immunol.* **2011**, *2011*, 691956. [[CrossRef](#)] [[PubMed](#)]