



Asif, A., Benedetto, U., Ofoe, V., & Caputo, M. (2021). Management of rheumatic aortic valve disease using the Ozaki procedure with autologous pericardium: a case report. *European Heart Journal Case Reports*, 5(6), ytab170. [ytab170].
<https://doi.org/10.1093/ehjcr/ytab170>

Publisher's PDF, also known as Version of record

License (if available):
CC BY-NC

Link to published version (if available):
[10.1093/ehjcr/ytab170](https://doi.org/10.1093/ehjcr/ytab170)

[Link to publication record in Explore Bristol Research](#)
PDF-document

This is the final published version of the article (version of record). It first appeared online via OUP at <https://doi.org/10.1093/ehjcr/ytab170>. Please refer to any applicable terms of use of the publisher.

University of Bristol - Explore Bristol Research

General rights

This document is made available in accordance with publisher policies. Please cite only the published version using the reference above. Full terms of use are available:
<http://www.bristol.ac.uk/red/research-policy/pure/user-guides/ebr-terms/>

Management of rheumatic aortic valve disease using the Ozaki procedure with autologous pericardium: a case report

Ashar Asif ^{1*}, Umberto Benedetto ^{1,2}, Victor Ofoe ³, and Massimo Caputo ^{1,2,4}

¹University of Bristol, Medical School, Senate House, Tyndall Ave, Bristol BS8 1TH, UK; ²Bristol Heart Institute, University Hospitals Bristol and Weston NHS Trust, Terrell St, Bristol, BS2 8ED, UK; ³Children's Heart Unit for Wales, University Hospital of Wales, Heath Park Way, Cardiff, CF14 4XW, UK; and ⁴Bristol Children's Hospital, Upper Maudlin St, Bristol, BS2 8BJ, UK

Received 20 January 2021; first decision 2 February 2021; accepted 14 April 2021

Background

Rheumatic valve disease (RVD) is the most common cause of cardiovascular death in low-middle income nations. Surgical aortic valve (AV) interventions for RVD, especially in children, have proven problematic with graft failure, relapse, and poor compliance with anticoagulation. A novel technique involving neocuspidization of the aortic annulus using autologous pericardium to construct new AV leaflets (the Ozaki procedure) has shown promising outcomes in children with congenital AV disease; however, there are no previous recorded cases using this technique in children with RVD.

Case summary

We present the case of a 15-year-old male presenting with exertional angina and dyspnoea with a background of previous rheumatic fever. Echocardiography had shown a regurgitant tricuspid AV, left ventricular dilatation with mitral valve leaflet tethering. The patient underwent the Ozaki procedure for his AV regurgitation and was discharged following an uneventful post-operative recovery. The patient had full resolution of symptoms following the procedure and remains well 3 years following his operation.

Discussion

This case highlights that good outcomes with the Ozaki procedure in RVD are possible 3-years post-operatively and should prompt future studies to evaluate the procedure as a surgical option for paediatric patients in this clinical context. Additionally, the Ozaki procedure may also provide a cost-effective surgical technique requiring minimal additional operative resources and reduced follow-up demand, which would be critical in low-resource clinical settings where RVD is prevalent.

Keywords

Case report • Rheumatic valve disease • Aortic valve replacement • Ozaki procedure • Paediatric heart disease

Learning points

- We show that the Ozaki procedure can provide effective management of rheumatic aortic valve disease in a paediatric patient with no relapse after over 3 years post-operation.
- A lack of data surrounds the outcomes in paediatric rheumatic valve disease (RVD) undergoing the Ozaki procedure. Future investigations should compare this with that of other AV procedures.
- RVD is an endemic in many low-income nations. The Ozaki procedure may provide a cost-effective option in these nations.

* Corresponding author. Tel: +44 7578792969, Email: ashar.asif1@nhs.uk

Handling Editor: Poonam Velagapudi

Peer-reviewers: Amr Idris and Angel Luis Fernandez Gonzalez

Compliance Editor: Max Sayers

Supplementary Material Editor: Ross Thomson

© The Author(s) 2021. Published by Oxford University Press on behalf of the European Society of Cardiology.

This is an Open Access article distributed under the terms of the Creative Commons Attribution Non-Commercial License (<http://creativecommons.org/licenses/by-nc/4.0/>), which permits non-commercial re-use, distribution, and reproduction in any medium, provided the original work is properly cited. For commercial re-use, please contact journals.permissions@oup.com

Introduction

Rheumatic valve disease (RVD) is the leading cause of cardiovascular deaths in many low-middle income countries, especially in children.¹ A dilemma surrounds paediatric aortic valve (AV) surgery, including the implant longevity, freedom from reoperation, growth capacity of the valve substitute, and post-operative medication compliance in this age population. Outcomes from other operative AV techniques have shown poor outcomes in RVD. A novel procedure involving neocuspidization of the AV using autologous pericardium sutured directly onto the annulus (the Ozaki procedure) has shown promising short-term results in children with congenital AV malformations.²⁻⁴ However, there are currently no recorded cases of the Ozaki procedure performed in paediatric patients in the context of RVD. We present the case of a 15-year-old male undergoing the Ozaki procedure for rheumatic AV disease.

Timeline

Date	Event
2014 October 2016	The male patient, at 12-year-old was diagnosed with rheumatic valve disease with aortic and mitral valve involvement. Referral made due to exertional angina with worsening dyspnoea. Echocardiography had shown a central, broad jet of severe aortic regurgitation (AR), left ventricular (LV) dilatation with resultant mild mitral regurgitation. Peak Doppler velocity across the aortic valve was 1.6 m/s, AR pressure half-time was 337.4 ms with an AR deceleration slope of 4.1 m/s ² . The patient was a candidate for surgical intervention.
7 November 2017	The 15-year-old patient was admitted under the paediatric cardiac surgical team to undergo the Ozaki procedure for AR.
10 November 2017	Ozaki procedure performed with no intraoperative or immediate post-operative complications.
11–13 November 2017	Extubated on the evening following surgery and self-ventilating with no major post-operative complications.
22 November 2017	Pre-discharge echocardiography showed trivial AV regurgitation and mild mitral valve regurgitation. The patient was discharged on warfarin for 3 months, as well as phenoxymethylpenicillin prophylaxis, lisinopril, spironolactone, and furosemide.
February 2018	Complete resolution of dyspnoea, angina, and exercise tolerance.
January 2019	Transthoracic echocardiography had shown improved LV dimensions with mild AR.
June 2020	The patient reported to remain asymptomatic at a telephone consultation.

Case presentation

A 15-year-old male was referred to our paediatric cardiac surgery services in the UK with a history of worsening exercise tolerance, exertional chest pain and confirmed rheumatic fever whilst he was in the Philippines 3 years prior. He had no other past medical history. A grade 2/4 soft, high pitched early diastolic murmur at the 3rd left intercostal space was auscultated. The patient was not breathless at rest and all peripheral pulses were palpable.

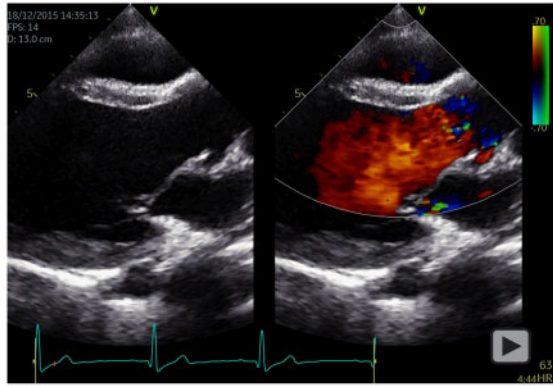
Echocardiography found a tricuspid aortic valve with a central, broad jet of severe aortic regurgitation (AR), with no stenosis of the valve. Peak Doppler velocity across the aortic valve was 1.6 m/s. The AR pressure half-time was 337.4 ms with an AR deceleration slope of 4.1 m/s². There was holo-reversal of flow in the descending aorta and abdominal aorta. The aortic root measurements were 2.45 cm,

3.24 cm, 2.69 cm, and 2.9 cm at the valve, aortic root, sinotubular junction, and ascending aorta, respectively. Left ventricular (LV) dilatation with mild mitral regurgitation secondary to tethering of the posterior leaflet was seen [end-diastolic diameter 60.4 mm (z-score 7.9), end-systolic diameter 42.1 mm (z-score 7.7)] with good function (ejection fraction 56.7%) based on the patient's weight of 36.5 kg and height of 144 cm (Videos 1 and 2). The patient's M mode echocardiography is shown in Figure 1. The patient was a candidate for surgical intervention and was planned for AV neocuspidization using autologous pericardium.

Intraoperative transoesophageal echocardiography showed a deficient left coronary cusp and a retracted right coronary cusp of the AV. Once the sternotomy was performed, a window of pericardium was removed to harvest tissue for AV cusp construction. Using the Ozaki sizers (a stencil to draw the size and shape of the leaflet), three valve cusps were outlined onto the excised pericardium, which was treated in glutaraldehyde in order to decellularize and promote cross-linking of the tissue to prevent valve calcification and degeneration. The leaflets were sutured onto the preserved aortic valve

annulus. The smoother, visceral side of pericardium was facing towards the aorta to minimise leaflet thrombosis and obstruction of the coronaries. The patient was under cardiopulmonary bypass for 124 min and on cross-clamping for 99 min with no intraoperative complications. The remainder of the pericardium was sutured closed around the heart and the sternum was closed. Immediate post-operative echo had shown perfect coaptation of the newly constructed valve leaflets, no subaortic LV outflow tract obstruction, normal flow in the descending aorta and preserved LV systolic function.

Following surgery, the patient was taken to the intensive therapy unit and was extubated that evening. Post-operative day 1, the patient's inotrope and vasopressor agents (dopamine and milrinone) were discontinued. Other than pericarditis and post-operative pneumonia which were simply treated with diclofenac and tazobactam-piperacillin, there were no complications following surgery. By post-



Video 1 A parasternal long-axis view of the pre-operative Doppler echocardiograph showing aortic valve regurgitation.

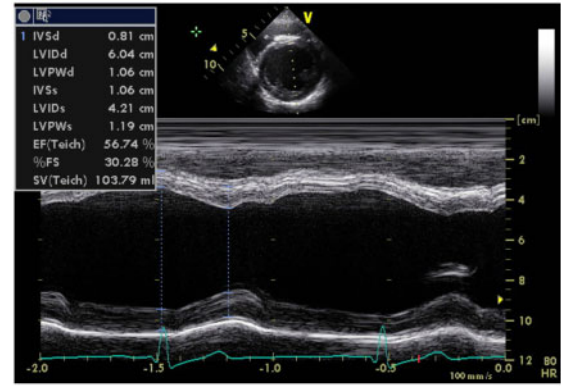
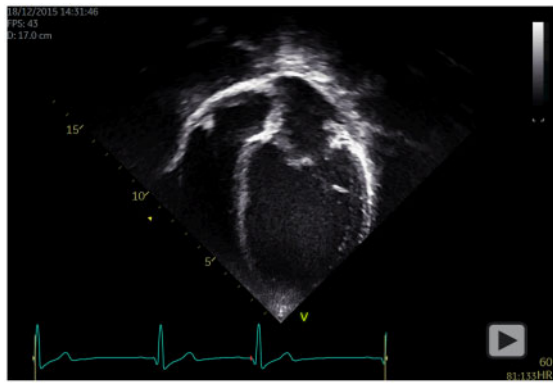
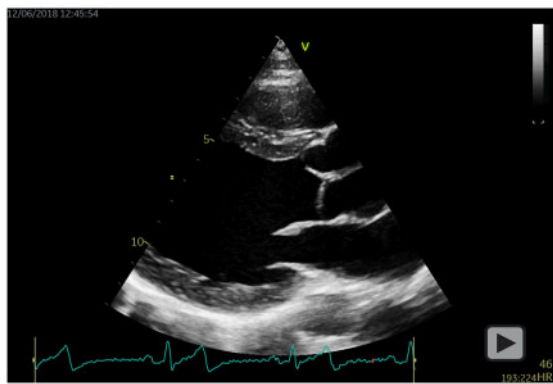


Figure 1 M-mode of the patient's pre-operative echocardiograph with left ventricular measurements.



Video 2 A four-chamber apical view of the pre-operative echocardiograph showing a dilated left ventricle.



Video 3 A parasternal long-axis view of post-operative echocardiograph at follow-up showing coaptation of the aortic valves with normal valve function.

operative day 11, the patient was stable, afebrile, well perfused and was discharged to his local paediatric services before being discharged home. The patient was planned to be on warfarin for 3 months, along with prophylactic phenoxymethylpenicillin, lisonipril, spironolactone, and furosemide.

On follow-up at 3 months, symptoms of reduced exercise tolerance had resolved, and echocardiography had shown resolution of normal valvular function (Video 3 and Supplementary material online, Video S1). At most recent follow-up at a telephone clinic (due to COVID-19 restrictions), 3 years post-operatively, the patient reported feeling well with no further symptoms.

Discussion

We describe a case that may provide a potential surgical option for a paediatric patient with RVD of the AV. There are a number of reasons why the Ozaki procedure may provide an alternative to other tissue-based AV procedures for paediatric patients with RVD.

Whilst the Ross procedure provides growth potential in paediatric patients, autograft failure is commonly seen in this clinical context.⁵⁻⁷ Bioprosthetic AV prosthesis, whilst advantageous insofar that anticoagulation therapy is avoided, has shown to have poor outcomes in paediatric patients. Bioprosthetic AV implants had significantly higher risks of mortality and reintervention compared to the Ross procedure and mechanical valve prosthesis in young adults.⁸ Their use in children has also been associated with rapid deterioration and early graft failure.⁹ The evidence surrounding these techniques show that in a paediatric population, where implant longevity is especially vital, there may be reluctance to employ these methods to provide lifelong RVD management.

Rheumatic fever is an endemic in low- and middle-income countries with 10–15:1000 cases in these nations.¹⁰ The economic burden of RVD in these nations is a heavy one to bare; in 2012, the direct costs of RVD to healthcare amount to 1.8 billion and 50 million USD in India and Uganda, respectively.¹¹ Compared to traditional AV interventions, the reduced costs from using autologous tissue

provides cost-effective method for valve replacement. Additionally, as biological tissue is being used, there is no requirement for anticoagulation, further reducing costs and follow-up monitoring.¹²

Poor autograph durability of the Ross procedure in RVD may be due to the disease pathogenesis. The autoimmune response following Rheumatic fever targets type-IV collagen found in the valve leaflets.¹³ The risk of rheumatic fever recurrence has shown to be higher in younger patients and those with symptoms of heart failure, which has demonstrated recurrent valvular pathology.¹⁴ The histological differences in the composition of pericardium and valve tissue may reduce the risk of future degeneration of the newly implanted aortic valve.¹⁵

Although we demonstrate promising outcomes with the Ozaki procedure in a paediatric patient with RVD, the current literature base for the procedure in children is sparse. It has shown to have good outcomes in paediatric congenital valvular malformations with follow-up up to 3 years, with improved aortic valve function compared to prior to surgery.^{3,4} Future investigations should aim to tackle the paucity of long-term evidence.

Lead author biography



Ashar Asif is a junior doctor based in Yorkshire, UK. He recently graduated from the University of Bristol and has an interest in congenital and paediatric cardiology as well as cardiothoracic surgery, academic surgery, and global health.

Supplementary material

Supplementary material is available at *European Heart Journal - Case Reports* online.

Slide sets: A fully edited slide set detailing this case and suitable for local presentation is available online as [Supplementary data](#).

Consent: The authors confirm that written consent for submission and publication of this case report including images and associated text has been obtained from the patients in line with COPE guidance.

Conflict of interest: None declared.

Funding: None declared.

References

1. Marijon E, Mirabel M, Celermajer D, Jouven X. Rheumatic heart disease. *Lancet* 2012;**379**:953–964.
2. Wiggins L, Mimic B, Issitt R, Ilic S, Bonello B, Marek J et al. The utility of aortic valve leaflet reconstruction techniques in children and young adults. *J Thorac Cardiovasc Surg* 2020;**159**:2369–2378.
3. Baird C, Cooney B, Chávez M, Sleeper L, Marx G, del Nido P. Congenital aortic and truncl valve reconstruction using the Ozaki technique: Short-term clinical results. *J Thorac Cardiovasc Surg* 2021;161:1567-1577.
4. Shearn AIU, Ordoñez MV, Rapetto F, Caputo M, Biglino G. Rapid prototyping flexible aortic models aids sizing the valve leaflets and planning the Ozaki repair. *JACC Case Rep* 2020;**2**:1137–1140.
5. Sampath Kumar A, Talwar S, Saxena A, Singh R. Ross procedure in rheumatic aortic valve disease. *Eur J Cardiothorac Surg* 2006;**29**:156–161.
6. Alsoufi B, Al-Halees Z, Manthiot C, McCrindle B, Al-Ahmadi M, Sallehuddin A et al. Mechanical valves versus the Ross procedure for aortic valve replacement in children: Propensity-adjusted comparison of long-term outcomes. *J Thorac Cardiovasc Surg* 2009;**137**:362–370.e9.
7. Raja S, Atamanyuk I, Kostolny M, Tsang V. In young patients with rheumatic aortic regurgitation compared to non-rheumatics is a Ross operation associated with increased incidence of autograft failure? *Interact Cardiovasc Thorac Surg* 2010;**10**:600–604.
8. Sharabiani M, Dorobantu D, Mahani A, Turner M, Peter Tometzki A, Angelini G et al. Aortic valve replacement and the Ross operation in children and young adults. *J Am Coll Cardiol* 2016;**67**:2858–2870.
9. Saleeb S, Newburger J, Geva T, Baird C, Gauvreau K, Padera R et al. Accelerated degeneration of a bovine pericardial bioprosthetic aortic valve in children and young adults. *Circulation* 2014;**130**:51–60.
10. Afifi A, Hosny H, Yacoub M. Rheumatic aortic valve disease—when and who to repair? *Ann Cardiothorac Surg* 2019;**8**:383–389.
11. Sandhu AT, Kathikeyan G, Bolger A, Okello E, Kazi DS. Clinical and economic burden of rheumatic heart disease in low-income nations: estimating the cost-of-illness in India and Uganda. *Circulation* 2018;**130**, No. Suppl_2.
12. Ozaki S, Kawase I, Yamashita H, Nozawa Y, Takatoh M, Hagiwara S et al. Aortic valve reconstruction using autologous pericardium for patients aged less than 60 years. *J Thorac Cardiovasc Surg* 2014;**148**:934–938.
13. Tandon R, Sharma M, Chandrashekhar Y, Kotb M, Yacoub M, Narula J. Revisiting the pathogenesis of rheumatic fever and carditis. *Nat Rev Cardiol* 2013;**10**: 171–177.
14. Camara E, Santos J, Alves-Silva L, Latado A. Rheumatic fever recurrence: Risk factors and clinical characteristics. *Clin Trials Regul Sci Cardiol* 2016;**19**:5–8.
15. Filova E, Burdikova Z, Stankova L, Hadraba D, Svindrych Z, Schornik D et al. Collagen structures in pericardium and aortic heart valves and their significance for tissue engineering, 2013 *E-Health and Bioengineering Conference (EHB)* 2013, pp. 1–4.