

Evaluation of facial changes in patients after maxillary transverse correction with MARPE: A systematic integrative review.

Édouard Ghislain Michel Louis CONSTANT-MARMILLON

Dissertação conducente ao Grau de Mestre em Medicina Dentária (Ciclo Integrado)

Gandra, 4 de maio de 2021

Édouard Ghislain Michel Louis CONSTANT-MARMILLON

Dissertação conducente ao Grau de Mestre em Medicina Dentária (Ciclo Integrado)

**Evaluation of facial changes in patients after maxillary
transverse correction with MARPE:**

A systematic integrative review.

Trabalho realizado sob a Orientação de Primavera SOUSA SANTOS, MD.

Declaração de Integridade

Eu, acima identificado, declaro ter atuado com absoluta integridade na elaboração deste trabalho, confirmo que em todo o trabalho conducente à sua elaboração não recorri a qualquer forma de falsificação de resultados ou à prática de plágio (ato pelo qual um indivíduo, mesmo por omissão, assume a autoria do trabalho intelectual pertencente a outrem, na sua totalidade ou em partes dele). Mais declaro que todas as frases que retirei de trabalhos anteriores pertencentes a outros autores foram referenciadas ou redigidas com novas palavras, tendo neste caso colocado a citação da fonte bibliográfica.

Comunicações Científicas em Congressos na Forma de Orais



 **EVENTOS CIENTÍFICOS IUCS** **JORNADAS CIENTÍFICAS AEIUCS** **XXIX JORNADAS CIENTÍFICAS DE CIÊNCIAS DENTÁRIAS**

DIPLOMA

O Presidente das XXIX Jornadas Científicas de Ciências Dentárias certifica que:

Constant-Marmillon E, SOUSA SANTOS P

apresentaram um trabalho científico sob a forma de **Comunicação Oral** intitulado, "Avaliação das alterações da face em paciente após correção transversal da maxila com a técnica MARPE" no âmbito das XXIX Jornadas subordinadas ao tema "Abordagens multidisciplinares da Medicina Dentária", que decorreram nos dias 14 e 15 de maio de 2021.


PROF. DOUTOR JOAQUIM MOREIRA
PRESIDENTE DAS XXIX JORNADAS CIENTÍFICAS DE CIÊNCIAS DENTÁRIAS

 **CESPU**  **CESPU**
INSTITUTO UNIVERSITÁRIO DE CIÊNCIAS DA SAÚDE

 **AEIUCS**
ASSOCIAÇÃO COLÉGIADA DE ESPECIALIDADES DENTÁRIAS DE CIÊNCIAS DA SAÚDE

 **NMD AEIUCS**
NÚCLEO MEDICINA DENTÁRIA AEIUCS

REMERCIEMENTS

Je remercie le Portugal pour son hospitalité et l'Université CESPU qui m'a permis de réaliser mon rêve.

Je remercie tout le corps enseignant pour le savoir qu'il m'a transmis, tout particulièrement:

La Pr^e D^{re} Primavera Sousa Santos pour toute l'aide apportée à ce projet, pour son exigence, sa disponibilité et son enthousiasme;

Le Pr D^r Paulo Rompante pour ses enseignements et sa grande sympathie;

Le Pr D^r Joaquim Moreira pour avoir été présent du premier jour jusqu'au dernier, pour son dévouement et son travail acharné en tant que doyen;

Le Pr D^r Hassan Bousbaa, le Pr Nuno Milhazes, le Pr D^r Daniel Mongiovi, la Pr D^r Cristina Coelho et tant d'autres.

Je remercie chaleureusement toute ma famille pour leur soutien indéfectible, dont:

Mes Parents pour leur aide financière;

Mon Père pour toutes les valeurs qu'il me transmet;

Ma Mère sans qui je ne serai pas celui que je suis aujourd'hui;

Mes Grand-Parents et mes Tantes qui ont été présents pour moi tout au long de mon cursus;

Mon Grand-Oncle Thierry et ma Grande-Tante Emmanuelle sans qui je n'aurais pas connu le CESPU et qui m'ont accompagné, aidé et hébergé à de nombreuses reprises au Portugal comme en France.

Pour terminer, je remercie tous mes amis dont mon binôme avec qui j'ai passé des moments inoubliables au Portugal et bientôt en France.

À vous tous, merci.

RESUMO:

Introdução: A Expansão Rápida Palatina Assistida por Mini-implante (MARPE) é uma técnica recente que permite a correção de deficiências maxilares enquanto limita os efeitos secundários da Expansão Rápida Palatina e da Expansão Rápida Palatina Assistida Cirurgicamente em jovem-adultos.

Objetivos: O objetivo desta revisão sistemática é avaliar, através da literatura científica, as alterações das estruturas ósseas da face e as suas possíveis repercussões nos tecidos moles faciais após tratamento MARPE em jovem-adultos.

Material e Métodos: Foi realizada uma pesquisa bibliográfica utilizando as seguintes bases de dados eletrónicas: MEDLINE/PubMed, EBSCO host e Cochrane Library. Os critérios de inclusão foram: artigos em inglês; ensaios clínicos aleatórios ou não aleatórios e estudos *in-vivo* em humanos.

Resultados: De 137 artigos, 5 foram selecionados após uma leitura completa.

Discussão: Os complexos zigomático-maxilares fazem um movimento circular de lateralização em torno de dois pontos de rotação: um em torno dos processos zigomáticos dos ossos frontais perto da sutura zigomático-frontal num plano coronal e outro em torno das partes proximais dos processos zigomáticos dos ossos temporais num plano axial. A maxila expande-se lateralmente, para cima e para a frente. O lábio superior, a região péri-nasal e as bochechas seguem a expansão descrita pela maxila. O nariz expande-se lateralmente, para baixo e para a frente.

Conclusão: MARPE tem de facto um impacto nos ossos faciais que se reflete nos tecidos moles faciais.

Palavras-chave: "MARPE"; "facial soft-tissues"; "facial bones"; "anatomic modifications"; "transversal maxillary deficiency"; "orthodontic treatment".

ABSTRACT:

Introduction: Miniscrew-Assisted Rapid Palatal Expansion (MARPE) is a recent technique that allows the correction of maxillary deficiencies while limiting the side effects of Rapid Palatal Expansion and Surgically Assisted Rapid Palatal Expansion in young adults.

Objectives: The objective of this systematic review is to evaluate, through the scientific literature, the alterations of the superficial bone structures of the face and their possible repercussions on the soft tissues of the face after MARPE treatment in young adults.

Material and Methods: The documentary search was performed using the following electronic databases: MEDLINE/PubMed, EBSCO host and the Cochrane Library. The inclusion criteria were: articles in English; randomized or non-randomized clinical trials and *in-vivo* studies in humans.

Results: Of 137 articles, 5 were selected after full reading.

Discussion: The zygomatico-maxillary complexes make a circular lateralizing movement around two points of rotation: around the zygomatic processes of the frontal bones near the zygomatico-frontal suture in a coronal plane and around the proximal parts of the zygomatic processes of the temporal bones in an axial plane. The maxilla expands laterally, upward and forward. The upper lip, the peri-nasal region and the cheeks follow the expansion described by the maxilla. The nose expands laterally, downward and forward.

Conclusion: MARPE does indeed have an impact on the facial bones reflected in the facial soft tissues.

Keywords: "MARPE"; "facial soft-tissues"; "facial bones"; "anatomic modifications"; "transversal maxillary deficiency"; "orthodontic treatment".

INDEX:

1. INTRODUCTION.....	1
2. OBJECTIVES AND HYPOTHESES.....	2
3. MATERIAL AND METHODS.....	2
3.1 ELIGIBILITY CRITERIA.....	2
3.2 INCLUSION CRITERIA.....	3
3.3 EXCLUSION CRITERIA.....	3
3.4 DATA SOURCES.....	3
4. RESULTS.....	4
4.1 STUDY SELECTION.....	4
4.2 QUALITY ANALYSIS.....	5
4.3 DATA ITEMS.....	6
5. DISCUSSION.....	11
5.1 SKELETAL CHANGES.....	11
5.2 SOFT TISSUE CHANGES.....	14
5.3 LIMITATIONS.....	17
6. CONCLUSIONS.....	17
7. REFERENCES.....	18

INDEX OF FIGURES:

Figure 1- PRISMA Flow Diagram.....4

Figure 2- Superimposed 3D images of the MSE patient showing the rotation of the zygomatico-maxillary complex with a center of rotation (CR) located near the proximal aspect of the zygomatic process of the temporal bone. (Blue: pre-expansion. White: post-expansion). Image by Cantarella et al.²⁴12

Figure 3- Superimposed 3D model of an MSE patient displaying the rotational pattern of the zygomatico-maxillary complex. (Yellow: pre-expansion. Blue: post-expansion. rF: right fulcrum. lF: left fulcrum). Image by Paredes et al.³³13

Figure 4- Superimposition of three-dimensional CBCT images acquired before (white) and after (blue) MARPE. (1 and 2, alare, right and left; 3 and 4, A-point, right and left; 5 and 6, prosthion, right and left; 7 and 8, ectocanine, right and left; 9 and 10, ectomolare, right and left; 11 and 12, processus zygomaticus, right and left). Image by Park et al.²⁵14

Figure 5- Displacement of landmarks measured by stereophotogrammetry after MARPE. The length of the arrows indicates the amount of change. (Red: x-axis. Green: y-axis. Blue: z-axis). Image by Lee et al.³⁷15

Figure 6- Vector map presents the direction of the changes between T0 (initial, right before MSE placement) and T1 (immediately after expansion) time points. Blue arrows denote vectors with $p < 0.05$, and the red ones denote vectors with $p < 0.01$. Image by Abedini et al.⁴⁰16

INDEX OF TABLES:

Table 1- Assessment of the risk of bias by the ROBINS-I tool.....5

Table 2- Description of included studies.....6

LIST OF ABBREVIATIONS AND ACRONYMS:

RPE – Rapid Palatal Expansion.

SARPE – Surgically Assisted Rapid Palatal Expansion.

MARPE – Miniscrew-Assisted Rapid Palatal Expansion.

CBCT – Cone Beam Computed Tomography.

MSE – Maxillary Skeletal Expander.

TBAT – Articular Tubercle of the Temporal Bone.

1. INTRODUCTION:

The absence of a transverse deficiency between the maxilla and mandible is necessary to achieve a correct dental occlusion. We speak of transverse deficiency when the distance between the central fossae of the maxillary first molars and the distance between the distal-buccal cusps of the mandibular first molars is not equal. The prevalence of maxillary transverse deficiency in children is 8-21% and 10% in adults.^{1,2} Maxillary transverse deficiencies may be misdiagnosed in clinical practice, which would imply higher actual percentages than those reported.³

In children, Rapid Palatal Expansion (RPE), introduced into practice by Haas in 1961,^{4,5} is the treatment of choice for restoring skeletal transverse dimension. It involves separating the midpalatal suture followed by orthopedic skeletal expansion with a palatal disjunction appliance with muco-dental support (Haas type) or, more recently, only with dental support (Hyrax type).^{6,7}

However, in adults, due to obliteration of the midpalatal suture,^{8,9} conventional expansion can result in non-opening of the midpalatal suture and multiple side effects, such as periodontal lesions and root or alveolar resorption.¹⁰⁻¹³

To overcome these side effects, Surgically Assisted Rapid Palatal Expansion (SARPE) is an alternative to open the midpalatal suture in adults.^{14,15} However, SARPE also has many disadvantages: the high cost of the operation, post-treatment morbidities, and the patients' reluctance to undergo surgical treatment.¹⁶

In 2010, Dr. Lee proposed the Miniscrew-Assisted Rapid Palatal Expansion (MARPE), a procedure designed to address the side effects of RPE and SARPE in patients with advanced skeletal maturation. His study showed effective separation of the midpalatal suture in an adult patient.¹⁷

The manufacturing protocol for the MARPE disjunction appliance consists in modifying a conventional expander: The Hyrax-type expander is manufactured in a plaster mold of the patient's palate where 4 loops intended to receive the mini-screws are added to the body part. The appliance is then placed on the palate and bonded to the patient's first premolars and molars.¹⁷ Using CBCT, the mini-screws sizes are selected and the screws installed so

that the fixation is bi-cortical to optimize separation of the midpalatal suture.^{18,19} The expander is activated once a day for 6 weeks until disjunction occurs and is then passively kept in the oral cavity for at least 3 months to allow bone formation in the disjunction space.¹⁷

A retrospective study of 69 adults after MARPE treatment demonstrated an opening of the midpalatal suture in 87% of cases and post-treatment stability after 30 months of follow-up.²⁰ Today, MARPE is recognized as a valid alternative for the treatment of maxillary transverse deficiency in young adults.²¹

Because this technique is recent, scientific studies are generally focused on the analysis of oral structures and few studies have yet been conducted on the changes in the bony and soft tissue structures of the face. However, we know that MARPE, like RPE, produces a skeletal orthopedic expansion involving several facial bones.¹⁷ These possible facial changes can be camouflaged by growth and puberty and therefore can go unnoticed in children, but in adults, where growth has already stopped, these changes can have several visible impacts on the patient's face and influence the aesthetic perception.^{22,23}

2. OBJECTIVES AND HYPOTHESES:

The aim of this systematic review is to evaluate, through scientific literature, the changes in the bone structures of the face and their possible repercussions on the facial soft tissues after MARPE treatment in young adults.

3. MATERIAL AND METHODS:

3.1 ELIGIBILITY CRITERIA

The studies included in this integrative systematic review were selected according to the following criteria, following the PICOS strategy.

PICOS:

Patients: teenagers/young adults treated with MARPE.

Intervention: the MARPE technique.

Comparison: before-after treatment.

Outcomes: facial changes.

Study design: *in-vivo* prospective or retrospective studies in humans.

3.2 INCLUSION CRITERIA

- English language.
- No time limits.
- Clinical trials, randomized clinical trials, prospective and retrospective studies.
- *In-vivo* study in human beings.
- Articles that discuss changes in the soft tissue and bones of the face after a MARPE treatment.

3.3 EXCLUSION CRITERIA

- Other languages than English.
- Systematic reviews, meta-analyses, narrative reviews or book chapters.
- Articles who do not fit the topic addressed in this study: do not discuss the MARPE technique or facial changes, discuss only airways, compare results of different techniques, post-mortem studies or computer simulations.
- Articles that do not describe their material and methods or the selection criteria.

3.4 DATA SOURCES

A literature search was conducted using the following electronic databases through February 28, 2021: MEDLINE/PubMed, EBSCO host and Cochrane Library.

The following search terms were used:

For PubMed and EBSCO:

((MARPE) OR (miniscrew assisted rapid maxillary expansion) OR (miniscrew assisted rapid palatal expansion) OR (micro implant supported skeletal expander) OR (miniscrew assisted rapid palatal expander)) AND ((bone) OR (face soft tissue) OR (nasal) OR (maxilla) OR (zygomatic) OR (nose) OR (maxillofacial)).

For Cochrane:

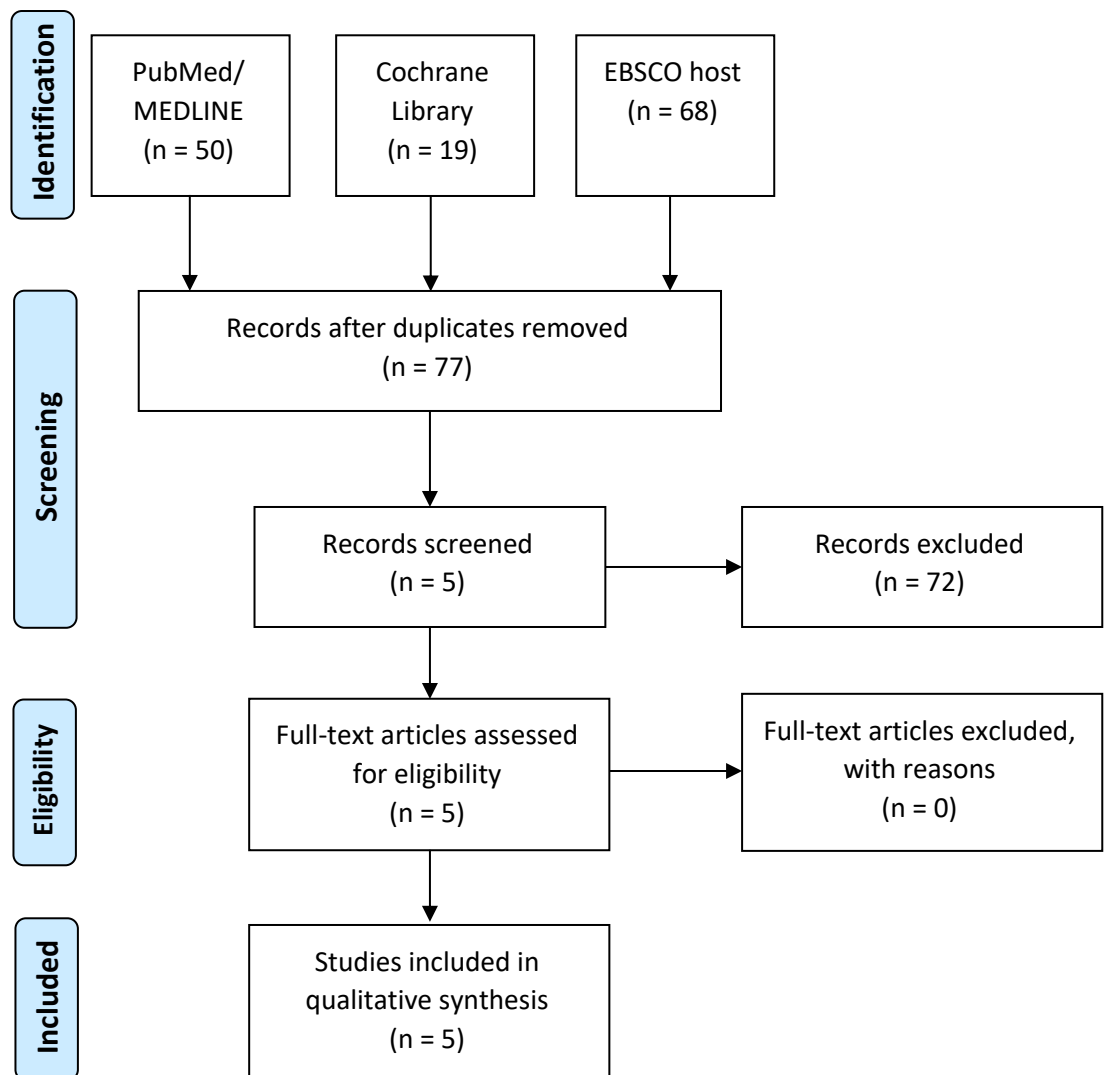
(MARPE) OR (miniscrew assisted rapid maxillary expansion) OR (miniscrew assisted rapid palatal expansion) OR (micro implant supported skeletal expander) OR (miniscrew assisted rapid palatal expander)

4. RESULTS:

4.1 STUDY SELECTION

According to the databases consulted and according to the search strategy, 137 articles were found. Duplicate articles were excluded, leaving 77 articles. After reading the title and abstract, 72 articles were excluded because they did not match the inclusion criteria. The remaining 5 articles, after full reading, were included in this integrative systematic review, which are shown in the following flowchart (Figure 1).

Figure 1- PRISMA Flow diagram.



4.2 QUALITY ANALYSIS

The assessment of risk of bias in eligible studies was analyzed according to criteria detailed in the Cochrane Collaboration Manual ROBINS-I (Table 1).

Table 1- Assessment of the risk of bias by the ROBINS-I tool.

/	Pre-intervention domains		At-intervention domain	Post-intervention domains				/
	Bias due to confounding	Bias in selection of participants into the study	Bias in classification of interventions	Bias due to deviations from intended interventions	Bias due to missing data	Bias in measurement of the outcome	Bias in selection of the reported result	
Park et al. ²⁵ 2017	LOW	LOW	MODERATE	LOW	LOW	MODERATE	LOW	MODERATE
Cantarella et al. ²⁴ 2018	LOW	LOW	LOW	LOW	LOW	LOW	LOW	LOW
Abedini et al. ⁴⁰ 2018	LOW	LOW	LOW	LOW	LOW	LOW	MODERATE	MODERATE
Paredes et al. ³³ 2020	LOW	LOW	LOW	MODERATE	LOW	MODERATE	LOW	MODERATE
Lee et al. ³⁷ 2020	LOW	LOW	LOW	LOW	LOW	LOW	LOW	LOW

4.3 DATA ITEMS

The following information was gleaned from the selected articles: author/year of publication, type of study, the aim of the study, the population, the measurement points, the results obtained, and the conclusions (Table 2).

Table 2- Description of included studies

Author/year	Type of study	Aim	Population	Measurement points	Results	Conclusions
Park et al. ²⁵ (2017)	Retrospective.	To evaluate skeletal and dentoalveolar changes after MARPE in young adults using CBCT.	14 patients with a mean age of 20.1 years (16-26 years).	<p><u>4 linear measurements:</u> the inter-zygomatic arch distance, the distance between the right and left most lateral points of the zygomatic arch; the inter-nasale distance, the distance between the right and left most lateral points of the nasal cavity; the inter-maxillary distance, the distance between the right and left points at the junction between the maxillary tuberosity outline and the zygomatic process; and the inter-mandibular distance, the distance between the right and left points of the antegonial notch.</p> <p><u>12 reference points:</u> the right and left alar point, the most infero-lateral point of the nasal aperture in a transverse plane; the right and left A-point, the posterior-most and deepest point of the anterior contour of the maxillary alveolar process in the mid-sagittal plane; the right and left zygomatic process point, the most infero-lateral point of the maxillary zygomatic process; the right and left ecto-canine point, the most infero-lateral point on the alveolar ridge opposite the center of the maxillary canine;</p>	<p>Inter-zygomatic arch distance: $+0.8 \pm 0.5$ mm ($p < 0.05$).</p> <p>Inter-nasale distance: $+1.4 \pm 1.0$ mm ($p < 0.01$).</p> <p>Inter-maxillary distance: $+2.0 \pm 1.4$ mm ($p < 0.01$).</p> <p>Inter-mandibular distance: 0.0 ± 1.3 mm ($p > 0.05$).</p> <p>The expansion decreased with the superior positioning of the anatomical structures, indicating a pyramidal pattern of maxillary expansion.</p> <p>Inter-alar distance: $+1.4$ mm ($p < 0.01$).</p> <p>Inter-A-point distance: $+3.0$ mm ($p < 0.01$).</p> <p>Inter-zygomatic process distance: $+2.8$ mm ($p < 0.01$).</p> <p>The x, y, and z axis correspond respectively to the sagittal, vertical, and transverse axis. Positive values indicate forward (z-axis), upward (y-axis) movements. Negative values indicate the opposite. For the x-axis, absolute values were used.</p>	<p>MARPE may be an effective treatment modality for the correction of transverse deficiency of the maxilla in young adults by separating the midpalatal suture.</p> <p>The maxillary expansion achieved with MARPE exhibits a pyramidal pattern. In this study, the degrees of skeletal, alveolar and dental expansion were 37.0%, 22.2% and 40.7%, respectively.</p> <p>Buccal tipping of the upper teeth in MARPE leads to the decrease in buccal alveolar bone thickness and crest height. Orthodontists should be aware of these changes.</p>

Author/year	Type of study	Aim	Population	Measurement points	Results	Conclusions
				<p>the right and left ecto-molare point, the most infero-lateral point on the alveolar ridge opposite the center of the maxillary first molar; and the right and left prosthion point, the most antero-inferior point of the maxillary alveolar margin in the mid-sagittal plane.</p>	<p><u>Axis x:</u> right and left alar point (0.8 mm), right and left A-point (1.6 mm), right and left zygomatic process point (1.2 mm), right and left ecto-canine point (0.8 mm), right and left ecto-molare point (1.6 mm), right and left prosthion point (1.6 mm) (p<0.01).</p> <p><u>Axis y:</u> right and left ecto-molare point (+0.8 mm), right and left prosthion point (+0.7 mm) (p<0.01).</p> <p><u>Z-axis:</u> right and left alar point (+0.4 mm), right and left ecto-canine point (+0.8 mm) (p<0.01).</p> <p>The reference points established in the bony tissues showed a tendency toward lateral and protrusive movements.</p>	
Cantarella et al. ²⁴ (2018)	Retrospective.	To analyze the changes in the zygomatic bone, maxillary bone and zygomatic arches and to locate the center of rotation of the zygomatic-maxillary complex in the horizontal plane after treatment with MSE using CBCT.	15 patients with a mean age of 17.2 years (13.9-26.2 years).	<p>3 linear measurements: the anterior inter-maxillary distance, from the most anterior point of the right maxilla to the most anterior point of the left maxilla; the posterior inter-zygomatic distance, between the outermost points on the right and left zygomatico-temporal sutures; and the posterior inter-temporal distance, between the most posterior point of the right and left articular tubercle of the temporal bones (TBATs).</p> <p>4 angular measurements: the right and left zygomatico-temporal angle, formed by the most anterior point on the maxilla, the most external point on the zygomatic-temporal suture, and the most posterior point on the TBAT; and the angle of the zygomatic process of the right and left temporal bone angle, formed by a line connecting the most posterior point of the</p>	<p>Anterior inter-maxillary distance: +2.76 mm (p<0.01).</p> <p>Posterior inter-zygomatic distance: +2.4 mm (p<0.01).</p> <p>Posterior inter-maxillary distance: +0.02 mm (p>0.05).</p> <p>Angles of the zygomatic process of the temporal bone: +1.7° (right) and +2.1° (left) (p<0.01).</p> <p>Zygomatico-temporal angle: -0.10° (right) and -0.04° (left) (p>0.05).</p>	<p>In the horizontal plane, the maxillary and zygomatic bones and the entire zygomatic arch were significantly displaced in a lateral direction after expansion using MSE.</p> <p>The center of rotation for the zygomatic-maxillary complex was located near the proximal portion of the zygomatic process of the temporal bone, more posteriorly and more laterally than described in the literature for tooth-borne expanders.</p> <p>A significant bone bending takes place in the zygomatic process of the temporal bone during the mini-screw-</p>

Author/year	Type of study	Aim	Population	Measurement points	Results	Conclusions
				right and left TBATs, and a line connecting the most posterior point on the TBAT to the most external point on the zygomatico-temporal suture.		supported maxillary expansion.
Abedini et al.⁴⁰ (2018)	Retrospective.	Analyze and quantify MSE-induced soft tissue facial changes using stereophotogrammetry .	25 patients with a mean age of 21.3 years (14.8-25.1 years).	3D facial imaging was used to capture facial images, generating 3D soft tissue meshes before expansion (T0), just after expansion (T1) and 1 year at retention (T2).	The 3D maps between T0 and T1 show that statistically significant changes (p<0.05) and (p<0.01) are located in the circummaxillary area (paranasal, lips and both cheeks). The vector map shows a mean displacement of 1.36 mm in the paranasal area. The right cheek shows a mean magnitude of displacement of 2.46 mm, while the left cheek has a mean of 2.95 mm. The direction of the vectors is lateral-anterior with anterior direction more dominant. These changes do not relapse after 1 year (p<0.05).	The developed protocol can be used to assess and quantify soft tissue changes due to different treatment modalities. Expansion with MSE has a statistically significant impact on the soft tissues of the face, particularly the paranasal and cheek area. The changes are stable after the 1-year retention. The mean magnitude of change is higher around the cheeks compared to the paranasal area. The soft tissue expands in a forward and lateral direction, primarily in the forward direction.
Paredes et al.³³ (2020)	Retrospective.	Quantify the differential components of the MSE expansion by calculating the fulcrum locations and applying a new angular measurement system using CBCT .	39 patients with a mean age of 18.2 years (13.3-27.3 years).	<u>2 reference points</u> : the right and left fulcrum , localized slightly above the external surface of the fronto-zygomatic suture. <u>6 linear measurements</u> : the right and left zygomatico-maxillary distance , the distance between the zygomatico-maxillary suture and the sagittal plane (passing through the anterior nasal spine, posterior nasal spine, and nasion); the right and left alveolar distance , the distance between the alveolar bone surface at the	Right zygomatico-maxillary distance: 2.31 ± 1.02 mm (p<0.01) and left: 1.37 ± 1.18 mm (p<0.01). Right alveolar distance: 0.65 ± 0.44 mm (p<0.01) and left: 0.69 ± 0.46 mm (p<0.01). Right dental distance: 0.91 ± 0.73 mm (p<0.01) and left: 1.11 ± 0.6 mm (p<0.01). These values suggest 60.16% and 56.83% (right and left sides) of skeletal expansion in relation to the total expansion (skeletal + alveolar + dental).	MSE produced almost pure skeletal rotational movement of the midcranial structures. Alveolar bone bending and dental tipping were not statistically significant with MSE. The angular measurement system from fulcrums provided much different results than the linear measurement system. The conventional linear

Author/year	Type of study	Aim	Population	Measurement points	Results	Conclusions
				<p>disto-buccal root tip of the upper first molar and the sagittal plane; and the right and left dental distance, the distance between the occlusal point located at the central groove of the upper first molar and the sagittal plane.</p> <p><u>6 angular measurements</u>: the right and left fronto-zygomatic angle, the angle between the inter-frontal distance (distance between the most external and lower points of the zygomatic processes of the frontal bones) and the line extending from fulcrum to the zygomatico-maxillary suture; the right and left fronto-alveolar angle, the angle between the inter-frontal distance and the line extending from fulcrum to the alveolar bone surface at the disto-buccal root tip of the upper first molar, and the right and left fronto-dental angle, the angle between the inter-frontal distance and the line extending from fulcrum to the occlusal point located at the central groove of the upper first molars.</p>	<p>Right fronto-zygomatic angle: $2.82^\circ \pm 1.26$ ($p < 0.01$) and left: $2.93^\circ \pm 1.49$ ($p < 0.01$).</p> <p>Right and left fronto-alveolar angle: $0.01^\circ \pm 0.03$ ($p < 0.01$).</p> <p>Right fronto-dental angle: $0.09^\circ \pm 0.17$ ($p < 0.01$) and left: $0.13^\circ \pm 0.12$ ($p < 0.01$).</p> <p>These values represent 96.58% and 95.44% (right and left sides) of the skeletal expansion in relation to the total expansion (skeletal + alveolar + dental).</p>	<p>measurements can falsely exaggerate the alveolar and dental components of MSE treatment.</p> <p>To correctly differentiate the expansion pattern of the rotating zygomaticomaxillary complex, a localization of the fulcrum should be the first step, then the angular measurements should be performed.</p> <p>Fulcrum position may vary depending on the design of the expander and the activation protocol, and a true fulcrum for each appliance should be identified for the proposed angular measurement system.</p>
Lee et al. ³⁷ (2020)	Prospective.	To evaluate nasal soft tissue changes, including landmark movements, changes in linear distances, and volumetric changes, using three-dimensional stereophotogrammetry after MARPE in adult patients.	30 patients with a mean age of 20.46 years (17.4-42.2 years).	<u>10 reference points</u> : the pro-nasale point , the most anterior midpoint of the nasal tip; the right and left alar point , the most lateral point on the right and left side alar contour; the right and left alar base point , the most lateral points of the alar base; the right and left alar curvature point , the point located on the facial insertion of the right and left side alar base; the right and left inferior nostril point , the most inferior points of the right and left nostril; and the sub-nasale point , the midpoint on the nasolabial soft-	The x, y and z axis correspond respectively to the sagittal, vertical and transverse axis. Positive values indicate forward (z-axis), upward (y-axis), and leftward (x-axis) movement. Negative values indicate the opposite. <u>X-axis</u> : left (+0.584 mm) and right (-0.407 mm) alar, left (+0.589 mm) and right (-0.619 mm) alar base, left (+0.505 mm) and right (-0.550 mm) alar curvature, left (+0.286 mm) and right (-0.313 mm) inferior nostril ($p < 0.01$); pro-nasale and sub-nasale ($p > 0.05$).	The majority of soft tissue landmarks around the nasal region show significant positional changes after MARPE in adults. The nose tends to widen and move forward and downward. Post-treatment nasal volume may also show a significant increase from the initial volume. Clinicians should explain thoroughly the anticipated changes to

Author/year	Type of study	Aim	Population	Measurement points	Results	Conclusions
				<p>tissue contour between the columella crest and the upper lip.</p> <p><u>4 linear measurements:</u> the alar width, the distance between the right and left alar points; the alar base width, the distance between the right and left alar base points; the nostrils inferior width, the distance between the right and left inferior nostril points; and the alar curvature width, the distance between the right and left alar curvature points.</p> <p><u>1 volumetric measurement:</u> the upper boundary, the plane that includes the endocanthion on both sides and is parallel to the horizontal reference plane; the lower boundary, the plane that includes the sub-nasale and is parallel to the horizontal reference plane; and the lateral boundaries, the plane that includes the alar and endocanthion and is parallel to the z-axis.</p>	<p><u>Y axis:</u> pro-nasale (-0.245 mm), sub-nasale (-0.325 mm), right (-0.183 mm) and left (-0.184 mm) alar (p<0.01); left and right alar base, left and right alar curvature, left and right inferior nostril (p>0.05).</p> <p><u>Z axis:</u> pro-nasale (+0.253 mm), left (+0.249 mm) and right (+0.312 mm) alar, left (+0.479 mm) and right (+0.576 mm) alar base, left (+0.422 mm) and right (+0.442 mm) alar curvature, left (+0.328 mm) and right (+0.447 mm) inferior nostril (p<0.01); sub-nasale (p>0.05).</p> <p>The reference points established in the nasal soft tissues showed a tendency toward lateral, protrusive, and inferior movements.</p> <p>Alar width: +0.932 mm (p<0.01). Alar base width: +1.214 mm (p<0.01). Inferior nostril width: +0.572 mm (p<0.01). Alar curvature width: +0.987 mm (p<0.01).</p> <p>Mean volume change: +993.33 mm³ (p<0.01) or an increase of 2.96%.</p>	<p>patients before MARPE initiation.</p>

5. DISCUSSION:

5.1 SKELETAL CHANGES

First, let's compile the information collected about bone tissue and its interpretations.

In an axial plane, Cantarella et al. show that the anterior inter-maxillary and posterior inter-zygomatic distances increased significantly by an average of 2.7 mm and 2.4 mm, respectively, after expansion. Their results show that the maxillary and zygomatic arches moved laterally after treatment. The temporal bones, on the other hand, did not seem to be affected by the treatment, as the measured values were not significant.²⁴

In the same plane, Park et al. found that the expansion of the midpalatal suture was similar from anterior to posterior when separation is complete.²⁵ A pyramid-shaped separation with the base of the pyramid facing forward is only observed when the pterygoid processes of the sphenoid bone are not completely separated.^{15,26-28}

In a coronal plane, Park et al. show that the inter-zygomatic arch, inter-nasal and inter-maxillary distances also increased significantly by an average of 0.8 mm; 1.4 mm and 2 mm respectively. These results also demonstrate that the measured structures move laterally following a pyramidal pattern with the base of the pyramid facing downward.²⁵

Measurements on the mandible were found to be non-significant. Therefore, it appears that MARPE does not affect the mandible.²⁵

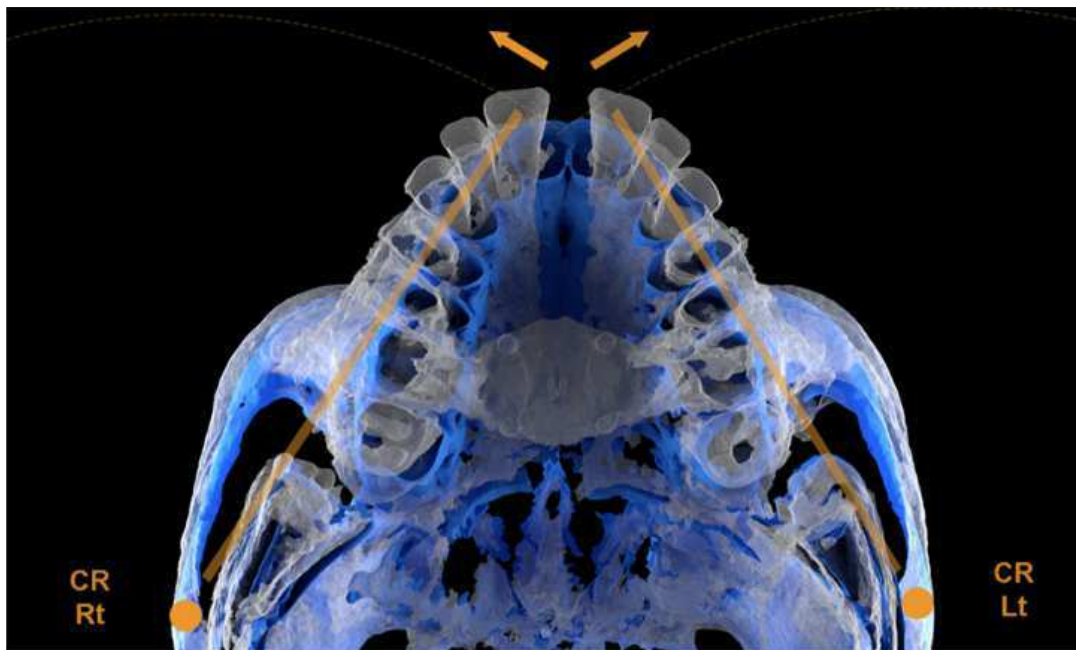
The separation of the midpalatal suture and the expansion of the bony structures adjacent to the nasal cavity result in an increase in the nasal cavity volume.²⁵ Enlargement of the nasal cavity and widening of the piriform orifice have been shown to result in increased airflow and improved nasal breathing in patients.^{6,29-31}

Relative to the angular measurements in an axial plane of Cantarella et al., the angles of the zygomatic processes of the temporal bone increased significantly by on average 1.7° on the right and 2.1° on the left. The changes in the zygomatic-temporal angle being negligible and without statistical significance, show that the zygomatico-maxillary complex and the zygomatic process of the temporal bone have maintained their angulation during expansion. Both rotate around a

common fulcrum located in the proximal part of the zygomatic process of the temporal bone.²⁴

The pivot is located there because it is the thinnest part of the zygomatic arch and therefore offers less resistance to torsional forces during expansion (Figure 2).³²

Figure 2- Superimposed 3D images of the MSE patient showing the rotation of the zygomatico-maxillary complex with a center of rotation (CR) located near the proximal aspect of the zygomatic process of the temporal bone. (Blue: pre-expansion. White: post-expansion). Image by Cantarella et al.²⁴



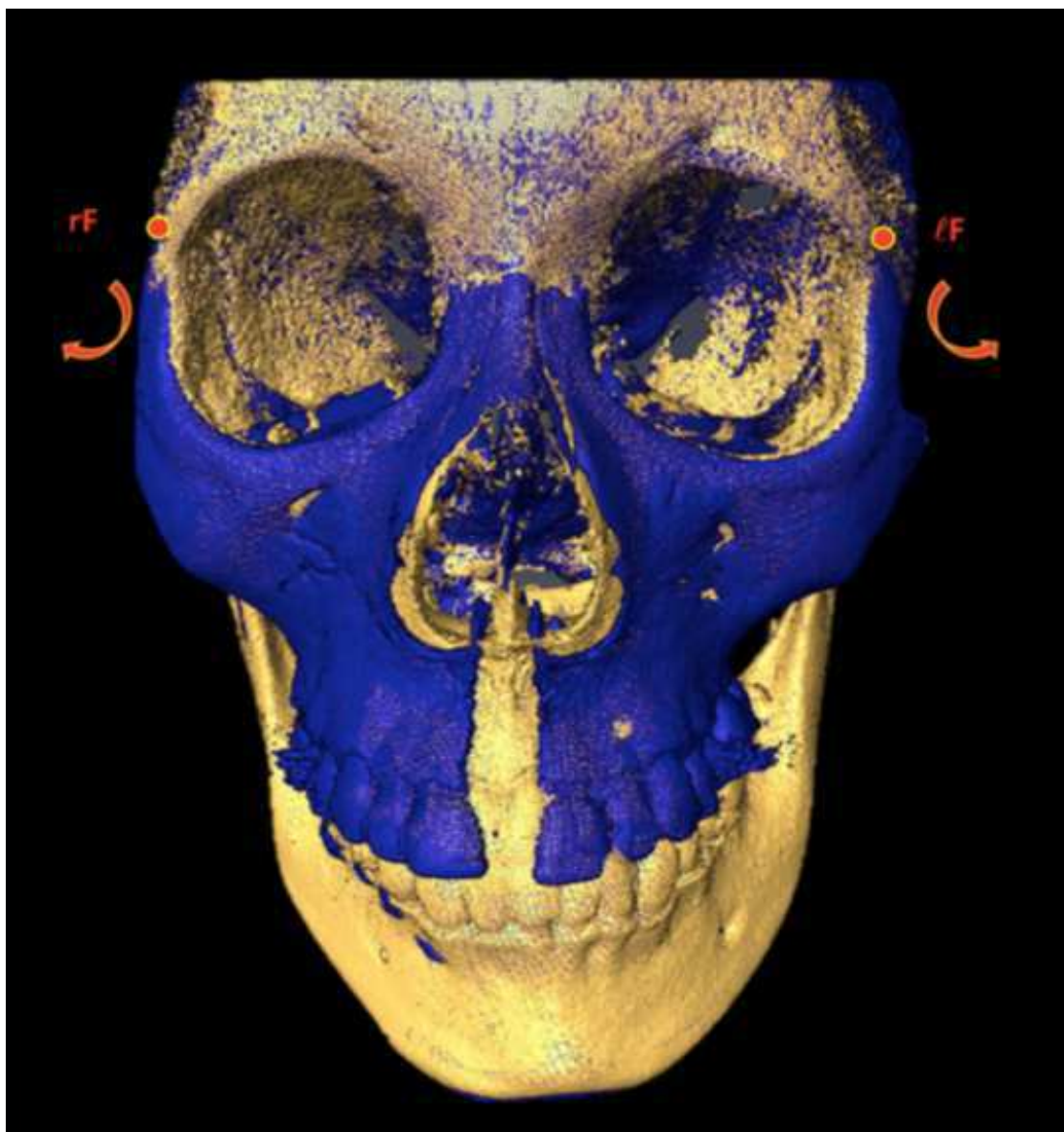
On the other hand, Paredes et al., in a coronal plane, place the fulcrum in the external and inferior part of the zygomatic processes of the frontal bones near the zygomatic-frontal suture. The sutures are weak points of the bony structures and, as in the previous case, therefore offer less resistance to the forces exerted during expansion.³³ Cantarella et al., in another study, position the center of rotation at the same point (Figure 3).³⁴

The linear measurements of Park et al. and Paredes et al. indicate respectively a skeletal, alveolar and dental expansion rate of 37,1%, 22.2% and 40.7% and 58.495%, 16.35% and 25.155%.^{25,33} According to Paredes et al, using linear measurements when the movement of the expansion is circular would necessarily lead to assessment errors. In fact, the movement of a structure further away from the fulcrum will appear to be more displaced when linear measurements are used.

Using angular measurements, Paredes et al. show respectively a skeletal, alveolar and dental expansion rate of 96.01%, 0.335% and 3.655%.³³

Paredes et al. also show in their study that MARPE minimally affects the dento-alveolar structures: alveolar bone flexion and tooth inclination are not statistically significant. According to their results, MARPE would involve an almost purely skeletal expansion.³³

Figure 3- Superimposed 3D model of an MSE patient displaying the rotational pattern of the zygomatico-maxillary complex. (Yellow: pre-expansion. Blue: post-expansion. rF: right fulcrum. lF: left fulcrum). Image by Paredes et al.³³



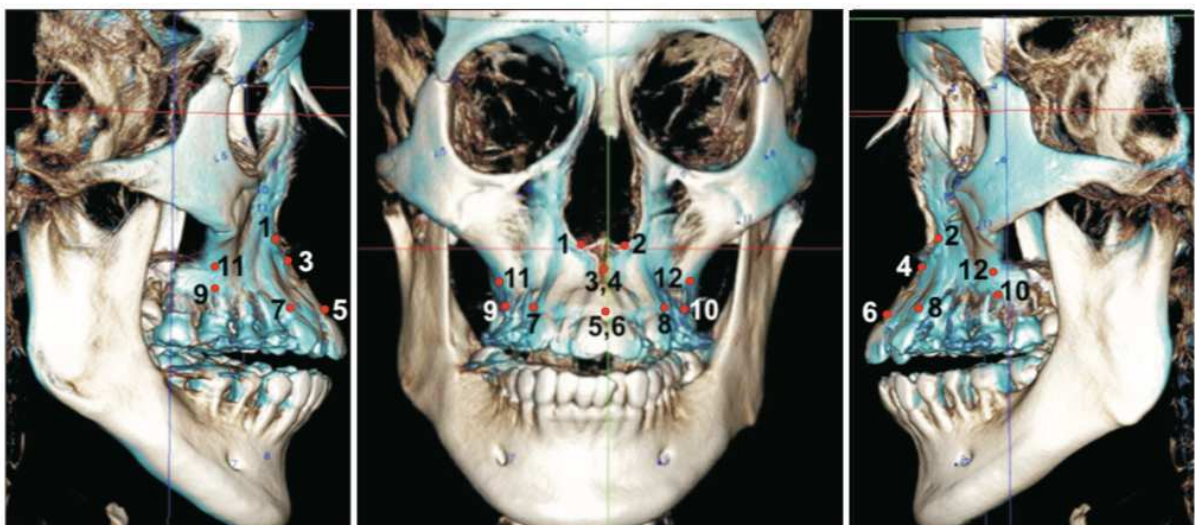
Based on the measurements and interpretations made by the authors above, we can describe the movements of the facial bone tissues as follows: the two zygomatico-maxillary complexes, after complete separation of the midpalatal suture and the pterygoid processes, will rotate around their respective fulcrums in an outward direction, following a pyramidal pattern.^{24,33}

The structures located medially and above the coronal fulcrums, as well as the structures located to the posterior of the axial fulcrums remain stable.^{24,33}

The circum-maxillary sutures, in particular the zygomatico-maxillary and fronto-maxillary sutures; the speno-occipital synchondroses and the orbital structures appear to be affected by maxillary expansion.³⁴⁻³⁶

Regarding the 3D analysis of the maxilla, Park et al. found a trend in the lateral, forward and upward displacement. Specifically, all landmarks placed on the maxilla significantly moved laterally by an average of 0.8 to 1.6 mm. Alar and ectocanine points moved significantly forward by an average of 0.4 and 0.8 mm, respectively, while ectomolar and prosthion points moved significantly upwards by an average of 0.7 and 0.8 mm, respectively (Figure 4).²⁵

Figure 4- Superimposition of three-dimensional CBCT images acquired before (white) and after (blue) MARPE. (1 and 2, alare, right and left; 3 and 4, A-point, right and left; 5 and 6, prosthion, right and left; 7 and 8, ectocanine, right and left; 9 and 10, ectomolare, right and left; 11 and 12, processus zygomaticus, right and left). Image by Park et al.²⁵



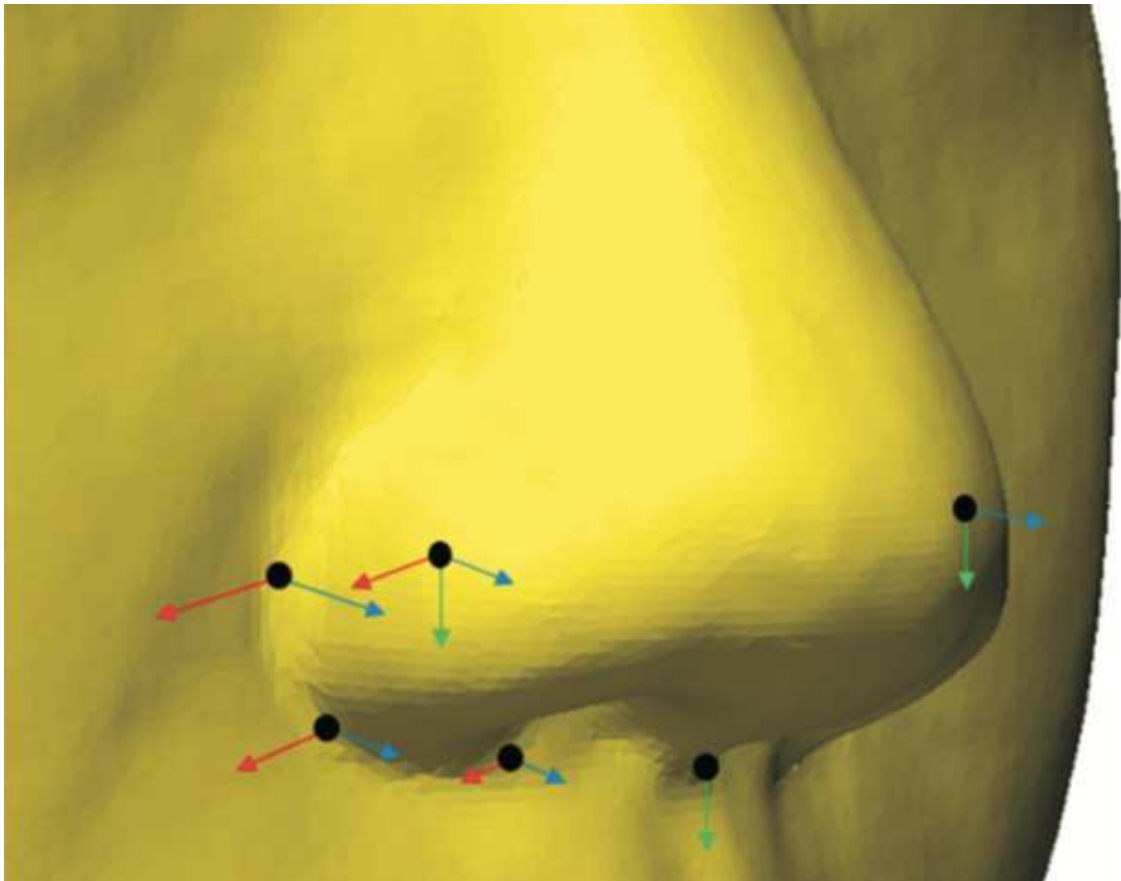
5.2 SOFT TISSUE CHANGES

In view of the fact that there are skeletal changes to the face after treatment with MARPE, the soft tissue impact following these changes will be described next.

Concerning the nose, the 4 linear measurements of the nasal base made by Lee et al. increased significantly by an average of 0.6 to 1.2 mm, which explains its lateral widening. Its volume also increased significantly by an average of 993.33 mm³, which represents a 2.96% increase from the initial volume.^{37,38} This increase in the volume of the soft and cartilaginous tissues of the nose leads to increased airflow from the airways.³⁹

Regarding the 3D analysis of the nose, all landmarks except those closest to the midline (the pro-nasal and sub-nasal) significantly moved laterally by an average of 0.48 mm. All landmarks moved forward by an average of 0.39 mm except the sub-nasal and moved down by an average of 0.24 mm except the most lateral ones (the alar base points, the alare curvature points and the inferior nostril points). After a MARPE treatment, the contours of the nose move mainly laterally and forward. To a lesser extent, some points move downwards (Figure 5).³⁷

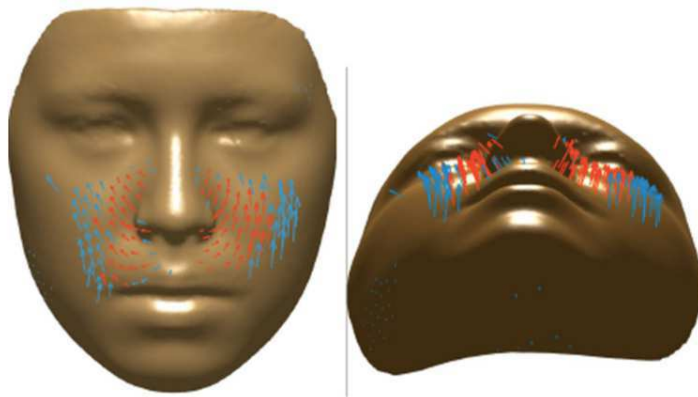
Figure 5- Displacement of landmarks measured by stereophotogrammetry after MARPE. The length of the arrows indicates the amount of change. (Red: x-axis. Green: y-axis. Blue: z-axis). Image by Lee et al.³⁷



Abedini et al. show in their study that statistically significant facial soft tissue changes ($p < 0.05$) are located in the peri-nasal area, upper lip, cheeks and zygomatic arch area with the most significant changes ($p < 0.01$) concentrated around the midline. The peri-nasal area, upper lip and cheeks show a lateralization movement, slightly upward and more predominantly forward. The peri-nasal area shows a mean displacement of 1.36 mm while the medial part of the right and left cheeks show a mean displacement of 2.46 and 2.95 mm respectively (Figure 6).⁴⁰

Abedini et al. consider that the changes are not symmetrical in individuals and remain stable after one year post-treatment.⁴⁰

Figure 6- Vector map presents the direction of the changes between T0 (initial, right before MSE placement) and T1 (immediately after expansion) time points. Blue arrows denote vectors with $p < 0.05$, and the red ones denote vectors with $p < 0.01$. Image by Abedini et al.⁴⁰



Then, it can be seen that soft tissue movements closely follow the movements of the underlying bony tissues: the upper lip, cheeks and peri-nasal region describe the same movements as those described by Park et al. in their 3D analysis of the maxilla. Both studies show lateral, forward and upward movements.^{25,40,41}

As far as the nose is concerned, there is no underlying bony support. Note that it follows the same movements of laterality and protrusion but the tip of the nose and the top of the nasal philtrum show a downward movement.³⁷

It is important to note that these soft tissue changes are measurable and observable. Therefore, it is essential to inform the patient of these changes prior to treatment in order to limit their perception as negative side effects. The enlargement of the nose in people with a thin nose can be beneficial for the final aesthetic aspect. Conversely, for adult patients who may already have a wide nose, even a small increase may have a negative impact.³³

Because the treatment of transverse deficiencies with MARPE is a relatively recent treatment, the number of studies available on the subject studied in this systematic review is still very limited. It would be interesting to observe in the near future whether new studies with larger samples followed up in the long term could confirm or refute the previous results, thus bringing more scientific weight to the study of changes in facial soft and bony tissues after MARPE treatment.

Moreover, the fact that there is no Mesh-Term associated with the MARPE method complicates the documentation search and may lead to loss of information.

6. CONCLUSIONS:

- MARPE leads to skeletal changes of the middle third of the face, which in turn influences the soft tissue changes of the face.
- MARPE produces a circular movement of the bone tissue in an axial plane around a fulcrum located in the proximal part of the zygomatic process of the temporal bone. All structures behind this point are not affected by the procedure.
- MARPE produces a circular movement of bone tissue in a coronal plane around a fulcrum located in the outer and lower part of the zygomatic processes of the frontal bones near the zygomatic-frontal suture. All structures above and medial to this point are not affected by the procedure.
- With the separation of the mid-palatal suture and the pterygoid processes, the circular expansion leads the zygomatico-maxillary complexes outward following a pyramidal pattern with the base of the pyramid facing downward in a coronal plane.
- The mandible is not affected by the MARPE technique.
- The maxilla expands laterally, upward and forward.
- The soft structure of the nose expands laterally, downward and forward.
- The upper lip, peri-nasal area and cheeks expand laterally, upward and forward.

The authors report no commercial or financial conflict of interest in this work.

7. REFERENCES:

1. Brunelle JA, Bhat M, Lipton JA. Prevalence and distribution of selected occlusal characteristics in the US population, 1988-1991. *J Dent Res* 1996;75:706–13.
2. Da Silva Filho OG, Santamaria M, Capelozza Filho L. Epidemiology of posterior crossbite in the primary dentition. *J Clin Pediatr Dent* 2007;32(1):73–8.
3. Bailey LJ, Haltiwanger L, Blakey GH, Proffit WR. Who seeks surgical-orthodontic treatment: a current review. *Int J Adult Orthodon Orthognath Surg* 2001;16(4):280–92.
4. Menon S, Manerikar R, Sinha R. Surgical Management of Transverse Maxillary Deficiency in Adults. *J Maxillofac Oral Surgery* 2010;9(3):241–6.
5. da Silva Filho OG, do Prado Montes LA, Torelly LF. Rapid maxillary expansion in the deciduous and mixed dentition evaluated through posteroanterior cephalometric analysis. *Am J Orthod Dentofac Orthop* 1995;107(3):268–75.
6. Haas AJ. Palatal expansion: Just the beginning of dentofacial orthopedics. *Am J Orthod* 1970;57(3):219–55.
7. Haas AJ. The treatment of maxillary deficiency by opening the midpalatal suture. *Angle Orthod* 1965;35:200–17.
8. Sun Z, Hueni S, Tee BC, Kim H. Mechanical strain at alveolar bone and circummaxillary sutures during acute rapid palatal expansion. *Am J Orthod Dentofac Orthop* 2011;139(3):219–28.
9. Persson M, Thilander B. Palatal suture closure in man from 15 to 35 years of age. *Am J Orthod* 1977;72(1):42–52.
10. Handelman CS, Wang L, BeGole EA, Haas AJ. Nonsurgical Rapid Maxillary Expansion in Adults: Report on 47 Cases Using the Haas Expander. *Angle Orthod* 2000;70(2):129–44.
11. Handelman CS. Nonsurgical rapid maxillary alveolar expansion in adults: A clinical evaluation. *Angle Orthod* 1997;67(4):291-305.

12. Erverdi N, Okar I, Kücükkeles N, Arbak S. A comparison of two different rapid palatal expansion techniques from the point of root resorption. *Am J Orthod Dentofac Orthop* 1994;106(1):47–51.
13. Baccetti T, Franchi L, Cameron CG, McNamara JA. Treatment Timing for Rapid Maxillary Expansion. *Angle Orthod* 2001;71(5):343–50.
14. Shetty V, Caridad J, Caputo AA, Chaconas SJ. Biomechanical rationale for surgical-orthodontic expansion of the adult maxilla. *J Oral Maxillofac Surg* 1994;52(7):742–9.
15. Asscherickx K, Govaerts E, Aerts J, Vande Vannet B. Maxillary changes with bone-borne surgically assisted rapid palatal expansion: A prospective study. *Am J Orthod Dentofac Orthop* 2016;149(3):374–83.
16. Williams BJD, Currimbhoy S, Silva A, O’Ryan FS. Complications following surgically assisted rapid palatal expansion: A retrospective cohort study. *J Oral Maxillofac Surg* 2012;70(10):2394–402.
17. Lee KJ, Park YC, Park JY, Hwang WS. Miniscrew-assisted nonsurgical palatal expansion before orthognathic surgery for a patient with severe mandibular prognathism. *Am J Orthod Dentofac Orthop* 2010;137(6):830–9.
18. Nojima LI, Nojima M da CG, da Cunha AC, Guss NO, Sant’Anna EF. Mini-implant selection protocol applied to MARPE. *Dental Press J Orthod* 2018;23(5):93–101.
19. Lee RJ, Moon W, Hong C. Effects of monocortical and bicortical mini-implant anchorage on bone-borne palatal expansion using finite element analysis. *Am J Orthod Dentofac Orthop* 2017;151(5):887–97.
20. Choi SH, Shi KK, Cha JY, Park YC, Lee KJ. Nonsurgical miniscrew-Assisted rapid maxillary expansion results in acceptable stability in young adults. *Angle Orthod* 2016;86(5):713–20.
21. Brunetto DP, Sant’Anna EF, Machado AW, Moon W. Non-surgical treatment of transverse deficiency in adults using microimplant-assisted rapid palatal expansion (MARPE). *Dental Press J Orthod* 2017;22(1):110–25.
22. Islam R, Kitahara T, Naher L, Hara A, Nakasima A. Lip morphological changes in orthodontic treatment. *Angle Orthod* 2008;79(2):256–64.

23. Shaw WC, Rees G, Dawe M, Charles CR. The influence of dentofacial appearance on the social attractiveness of young adults. *Am J Orthod* 1985;87(1):21–6.
24. Cantarella D, Dominguez-Mompell R, Moschik C, Sfogliano L, Elkenawy I, Pan HC, et al. Zygomaticomaxillary modifications in the horizontal plane induced by micro-implant-supported skeletal expander, analyzed with CBCT images. *Prog Orthod* 2018;19(1):41.
25. Park JJ, Park YC, Lee KJ, Cha JY, Tahk JH, Choi YJ. Skeletal and dentoalveolar changes after miniscrew-assisted rapid palatal expansion in young adults: A cone-beam computed tomography study. *Korean J Orthod* 2017;47(2):77–86.
26. Cantarella D, Dominguez-Mompell R, Mallya SM, Moschik C, Pan HC, Miller J, et al. Changes in the midpalatal and pterygopalatine sutures induced by micro-implant-supported skeletal expander, analyzed with a novel 3D method based on CBCT imaging. *Prog Orthod* 2017;18(1):34.
27. Pinto PX, Pinto PX, Mommaerts MY, Wreakes G, Jacobs WVGJA. Immediate postexpansion changes following the use of the transpalatal distractor. *J Oral Maxillofac Surg* 2001;59(9):994–1000.
28. Colak O, Paredes NA, Elkenawy I, Torres M, Bui J, Jahangiri S, et al. Tomographic assessment of palatal suture opening pattern and pterygopalatine suture disarticulation in the axial plane after midfacial skeletal expansion. *Prog Orthod* 2020;21(1):21.
29. El H, Palomo JM. Three-dimensional evaluation of upper airway following rapid maxillary expansion A CBCT study. *Angle Orthod* 2014;84(2):265–73.
30. Yi F, Liu S, Lei L, Liu O, Zhang L, Peng Q, et al. Changes of the upper airway and bone in microimplant-assisted rapid palatal expansion: A cone-beam computed tomography (CBCT) study. *J Xray Sci Technol* 2020;28(2):271–83.
31. Kim SY, Park YC, Lee KJ, Lintermann A, Han SS, Yu HS, et al. Assessment of changes in the nasal airway after nonsurgical miniscrew-assisted rapid maxillary expansion in young adults. *Angle Orthod* 2018;88(4):435–41.
32. Choi K, Goldstein SA. A comparison of the fatigue behavior of human trabecular and cortical bone tissue. *J Biomech* 1992;25(12):1371–81.

33. Paredes N, Colak O, Sfogliano L, Elkenawy I, Fijany L, Fraser A, et al. Differential assessment of skeletal, alveolar, and dental components induced by microimplant-supported midfacial skeletal expander (MSE), utilizing novel angular measurements from the fulcrum. *Prog Orthod* 2020;21(1):18.
34. Cantarella D, Dominguez-Mompell R, Moschik C, Mallya SM, Pan HC, Alkahtani MR, et al. Midfacial changes in the coronal plane induced by microimplant-supported skeletal expander, studied with cone-beam computed tomography images. *Am J Orthod Dentofac Orthop* 2018;154(3):337–45.
35. Bazargani F, Feldmann I, Bondemark L. Three-dimensional analysis of effects of rapid maxillary expansion on facial sutures and bones A systematic review. *Angle Orthod* 2013;83(6):1074–82.
36. MacGinnis M, Chu H, Youssef G, Wu KW, Machado AW ilso., Moon W. The effects of micro-implant assisted rapid palatal expansion (MARPE) on the nasomaxillary complex--a finite element method (FEM) analysis. *Prog Orthod* 2014;15(1):52.
37. Lee SR, Lee JW, Chung DH, Lee SM. Short-term impact of microimplant-assisted rapid palatal expansion on the nasal soft tissues in adults: A three-dimensional stereophotogrammetry study. *Korean J Orthod* 2020;50(2):75–85.
38. Nada RM, Van Loon B, Schols JGJH, Maal TJJ, de Koning MJ, Mostafa YA, et al. Volumetric changes of the nose and nasal airway 2 years after tooth-borne and bone-borne surgically assisted rapid maxillary expansion. *Eur J Oral Sci* 2013;121(5):450–6.
39. Storto CJ, Garcez AS, Suzuki H, Cusmanich KG, Elkenawy I, Moon W, et al. Assessment of respiratory muscle strength and airflow before and after microimplant-assisted rapid palatal expansion. *Angle Orthod* 2019;89(5):713–20.
40. Abedini S, Elkenawy I, Kim E, Moon W. Three-dimensional soft tissue analysis of the face following micro-implant-supported maxillary skeletal expansion. *Prog Orthod* 2018;19(1).
41. Torun GS. Soft tissue changes in the orofacial region after rapid maxillary expansion: A cone beam computed tomography study. *J Orofac Orthop* 2017;78(3):193–200.