

We are IntechOpen, the world's leading publisher of Open Access books Built by scientists, for scientists

5,600

Open access books available

137,000

International authors and editors

170M

Downloads

Our authors are among the

154

Countries delivered to

TOP 1%

most cited scientists

12.2%

Contributors from top 500 universities



WEB OF SCIENCE™

Selection of our books indexed in the Book Citation Index
in Web of Science™ Core Collection (BKCI)

Interested in publishing with us?
Contact book.department@intechopen.com

Numbers displayed above are based on latest data collected.
For more information visit www.intechopen.com



Endoscopy in Neurosurgery

Khandkar Ali Kawsar

Abstract

Introduction of endoscope was undoubtedly a great advancement in neurosurgery. It minimises trauma to the brain tissue and maximises the vision around the remote areas. The access to the ventricle and cisterns has become much easier. Development in optics, lenses, long and angled instruments made the endoscopy in neurosurgery very versatile. In this chapter, the introduction of the endoscopy in neurosurgery has been described along with its use in different branches of neurosurgery like neuro-oncology, hydrocephalus, skullbase, aneurysms, craniosynostosis etc. The details of some common and important operation have been described. Some relevant anatomy, which can be encountered in endoscopic approach, has been described which will be helpful to the readers. This chapter will also act as an eye-opener to the vast use of neuroendoscopy and will help broaden the horizon of trainee neurosurgeons, following which the further details can be sought in relevant books and literature. In brief, this chapter will tell us about the evolution to revolution of the neuroendoscopy.

Keywords: Endoscopy, Neuroendoscopy, ETV, Arachnoid cyst, Hydrocephalus, Neuro-oncology, Skullbase, Pituitary, Transphenoidal, Aneurysm, Craniosynostosis

1. Introduction

Neuroendoscopy treats the pathologies of the central nervous system applying an endoscope. With the ever improving methods to treat cranial pathologies neuroendoscopy is being applied more and more to treat different pathologies. In this chapter, we will discuss the brief history, clinical application and important neuroendoscopic approaches along with the advantages, disadvantages, complications or important considerations in the procedures.

In **Table 1**, the events those revolutionized the endoscopic neurosurgery, are summarized.

In the early 1970s, both flexible fibreoptic and high-resolution rigid endoscopes could be developed based on the technological advances in optics and electronics. Those were used successfully for operating within the ventricles. From that point of treating hydrocephalus, the neuroendoscopy has progressed to endoscope-assisted surgical procedures which began in the 1980s and 1990s. This minimally invasive procedure retained its popularity and continued till now [6].

At the initial days of neuroendoscopy, as ventricles contain the ideal medium of crystal-clear CSF, the endoscopic procedures were confined to those. Currently, the field of neuroendoscopy has extended beyond ventricular procedures and is currently applied for all types of neurosurgically treatable diseases such as intracranial cysts, intraventricular tumors, hypothalamic hamartoma (HH), skull base tumors, craniosynostosis, degenerative spine disease, and rare subtypes of hydrocephalus [7].

Year	Events	Performed by
1910	The first neurosurgical endoscopic procedure for choroid plexus fulguration using a cystoscope in two infants with hydrocephalus, one of them was successfully treated [1–3].	L’Espinasse
1922	Choroid plexectomy to treat hydrocephalus, which was unsuccessful [4].	Walter Dandy
1923	Successful endoscopic third ventriculostomy (ETV) in a 9-month-old girl with obstructive hydrocephalus, using a urethroscope [5].	Mixter
1935	Reported his initial results after using a novel endoscope equipped with a cauterizing electrode, an irrigation system to prevent ventricle collapse, and a movable operating tip to perforate the third ventricle floor [1, 3].	Scarff

Table 1.
Revolutionary events in endoscopic neurosurgery.

The benefit in minimally invasive endoscopic procedures is analogous to that of any endoscopic procedure and can be listed as follows:

1. Minimal tissue disruption
2. Enhanced visualization
3. Improved cosmetic results
4. Shorter hospital stay
5. Less surgical morbidity.

In neurosurgery, to minimize operative trauma, the surgeon tries hard to limit the size of the exposure and to avoid unnecessary brain retraction, which can cause damage by increasing pressure to the surrounding normal brain tissue and minimizing the regional cerebral blood flow [8] which has short-term and long-term knock on effect and these eventually may compromise the neurologic outcome following microneurosurgical procedures. The outcome can potentially be improved by the use of neuroendoscopy techniques. The endoscope enhances the surgeon’s view by increasing illumination and magnification [9, 10], which makes it an excellent teaching tool. A comparison of endoscope and microscope from a survey of the neurosurgeons shows that microscope is superior only for less fatigue of the hand and 3D vision which are now removed with endoscope holder and 3D view of endoscopes. This 3D view is clearly more advantageous in looking at the areas, that were difficult to visualize with microscope. With the advent of different angled endoscopes, e.g. 30°, 45°, 70°, 110°, it is possible to have a panoramic view of the field [6].

2. Equipment

The endoscopy set should include: video camera, camera control units, light source, video recorder, video monitor and a computerized system for storage of video segments or single-picture capture as shown in **Figure 1**. Endoscope positioning and fixation arms help the surgeon to avoid arm fatigue, which can disturb eye–hand coordination and flexibility may be compromised [11]. With the fixation arms, sudden movement of the hand or hand tremor can be minimized.

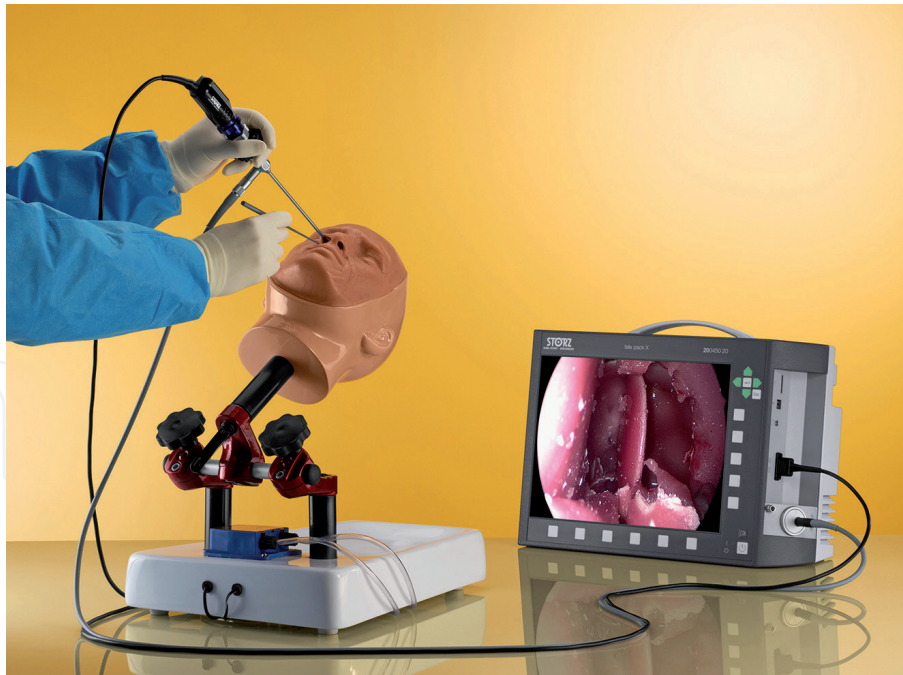

Figure 1.
Camera control units with light source and video monitor with video recorder.



Figure 2.
Endoscopic grasping forceps.

Endoscopic instruments include a pair of grabbing forceps (**Figure 2**) and scissors, a monopolar or bipolar coagulation device, an irrigation system, and a straight and one or more scopes with various angles (**Figure 3**). When the endoscope holder is not used, a knowledgeable assistant is very helpful to show the difficult areas and the surgeon can work with both hands. Video recording equipment is very helpful for capturing images on video or digital format for training and later study [12]. The scope of neuroendoscopy has gone further with the help of flexible neuroendoscope (**Figure 4**).

Frameless computerized neuronavigation has been used more in intracranial endoscopic neurosurgery to increase the accuracy and precision. This has proven to be reliable and useful in selected intracranial neuroendoscopic procedures to improve the accuracy of the endoscopic approach [12].

Modern three-chip technology provides impressive color depth and brilliant red differentiation. The latest Full HD technology delivers lag-free images even with rapid camera movements. When we learn and understand more varieties of CNS pathologies, the targets and demands for endoscopic procedures will change




Figure 3.
Straight and angled scopes.




Figure 4.
Flexible endoscope.

accordingly. Telemanipulated neurosurgery, with supervisory-controlled robotic systems, or shared control systems, or even fully robotic telesurgery along with the recent advancement in nanotechnology will be needed to address future indications for minimally or even ultramicro-access neurosurgery [13]. The relentless work is going on to improve the endoscopic system which includes improved maneuverability of the scope by reduction of the bulk and integration of the camera and fiberoptic light components with an extensive viewing angle from 0 to 70 degrees, along with the provision of maintaining surgical orientation.

3. Endoscopic third ventriculostomy

3.1 History and background

In 1952, Nulsen and Spitz began the era of ventricular cerebrospinal fluid (CSF) shunting [14]. Due to the lack of initial encouraging results, not until 1970s, an interest in ETV for treating obstructive hydrocephalus was renewed when the imaging capability of endoscopes had a remarkable improvement. In 1978, Vries described his experience treating five patients with hydrocephalus, in whom he demonstrated that ETVs were technically feasible using a fiberoptic endoscope [15]. In the small series of 24 patients with various forms of hydrocephalus, Jones and colleagues described a 50% shunt-free success rate for ETV, initially in 1990 [16]. They reported a better success rate of 61% in a series of 103 patients 4 years later [17]. Obstructive hydrocephalus which has resulted from either benign aqueductal stenosis or compressive

periaqueductal benign or malignant mass lesions are being treated primarily with ETV in the modern era. In the current time, the shunt-free success rate ranges from 80 to 95% [2].

The indications for ETV are expanding to meningocele, Chiari malformation or Dandy-Walker-related hydrocephalus cases. Few studies reported fairly good success rates after ETV for cases of communicating hydrocephalus in idiopathic normal pressure hydrocephalus [18]. In selected cases, ETV is becoming more and more preferable to ventriculoperitoneal (VP) shunt placement due to avoidance of shunt dependency and complications that come with the shunting [19]. With introduction of improved endoscopic techniques, ETV is now used to treat hydrocephalus following shunt malfunction or infection and refractory slit-ventricle syndrome [18].

3.2 Important landmarks

Recognition of critical landmarks and structures in the ventricles is very important to achieve a successful ETV. **Figure 5** is showing the instruments required for ETV and an endoscopic view showing some important landmarks. In **Table 2**, we discuss few important landmarks with which the surgeons need to be familiar to accomplish the procedure safely.

The supraoptic and paraventricular arcuate nuclei are the structures most prone to injury, which may give rise to endocrine disturbances [20].

To increase the success of the ETV endoscope needs to be progressed and Lilliequist membrane needs fenestration. Basilar artery will be seen during this stage (**Figure 7**).

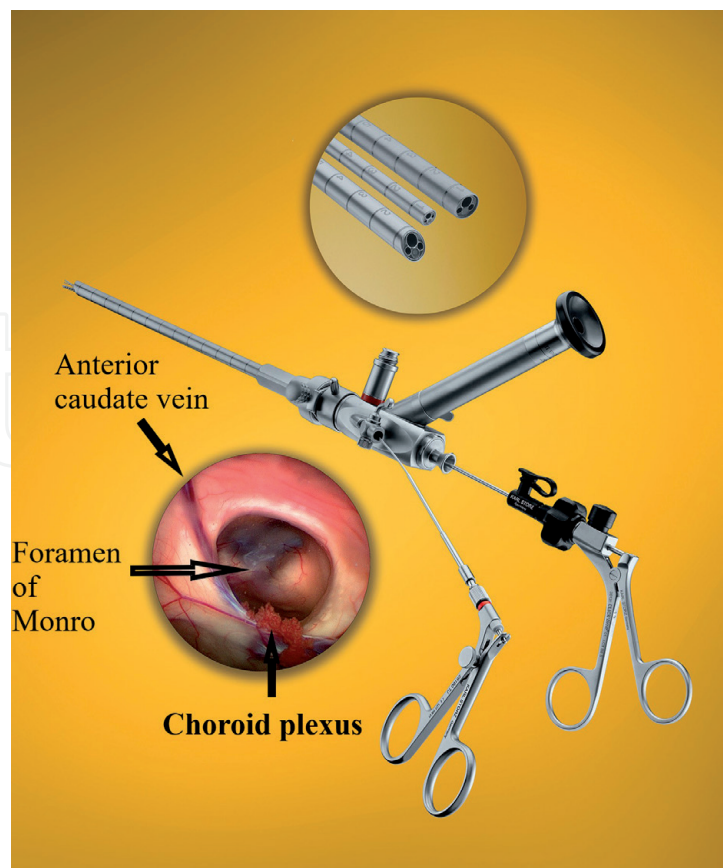


Figure 5. In the middle, ETV endoscope with side channel with working instrument (forceps for fenestration). In the upper circle, end of the ETV endoscopes. In lower circle, the endoscopic view before entering into the foramen of Monro.

Anatomical landmark	Reason of importance	Comments
Choroid plexus	This remains at choroidal fissure and gives the surgeon an important navigational tool, even with gross distortions in the ventricular anatomy.	Anterior part of choroid plexus extends to the foramen of Monro and then to the third ventricle.
Fornix	This forms the superior and anterior margin of the foramen of Monro.	Endoscope needs to be carefully advanced from lateral to third ventricle to avoid the injury to fornix and resultant memory impairment the chance of which increases with multiple passages because of the location of the fornix.
Thalamostriate vein	Being usually the largest tributary of the Internal Cerebral Veins, it is a prominent structure. It goes down to the foramen of Monro with the choroid plexus.	During advancement in third ventricle, too much deviation of endoscope laterally towards this vein, may damage the hypothalamus as it forms the lateral walls of the third ventricle.
Mamillary Bodies	Paired structure visible underneath the floor of the third ventricle.	Floor of the third ventricle is usually thinned out which needs to be fenestrated behind this paired mamillary bodies (Figure 6).

Table 2.
Landmarks for ETV [20].

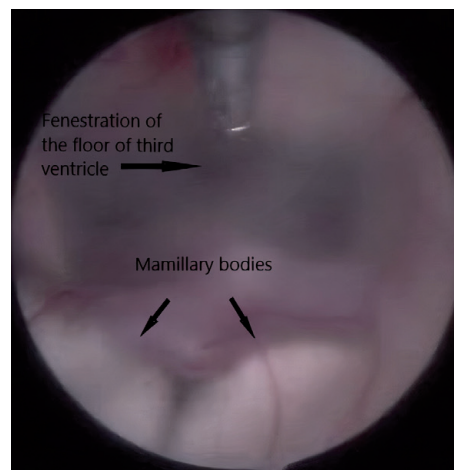


Figure 6.
Endoscopic view of the floor of the third ventricle before fenestration of the floor of the ventricle.

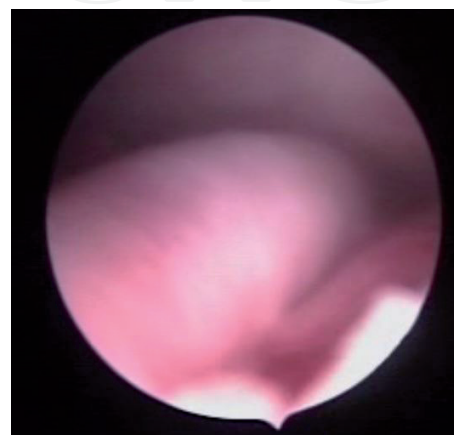


Figure 7.
Endoscopic view of basilar artery following fenestration of the floor of the third ventricle and Liliequist membrane.

3.3 Precautions

There are several precautions to take when performing ETV when there is history of previous tumors, shunting procedure or thickened floor of third ventricle. The anatomy may be difficult to interpret as it can be altered by tumors e.g. a brainstem glioma. Floor of the third ventricle may be distorted and basilar artery may be displaced forward, minimizing the safe zone of the floor for penetration. The onset of hydrocephalus resulting from tumor obstruction may be relatively acute and the floor of the third ventricle may appear opaque and non-attenuated. The procedure will pose more challenges as the penetration of the floor will be difficult and invariably requires a sharper technique without visualization of the neurovascular structures underneath the membrane for penetration, which obviously increases the risk.

3.4 Consideration for success of ETV

Patients, who have been previously shunted, are technically more difficult to perform ETV upon, because -

- i. Less marked ventricular dilatation because of shunt assisted drainage
- ii. A thicker ventricular floor
- iii. Abnormal anatomy which is not an infrequent finding.

An ETV procedure may have to be abandoned in some cases for the following reasons –

- i. Thick floor of the third ventricle
- ii. Endoscopic view is obstructed by blood and cannot be cleared
- iii. The basilar artery is very close or just under the planned site of fenestration.
- iv. The anatomy is really unclear.

Despite all these, ETV has an overall success rate of approximately 75% after 3 years. Though the success depends not only on patient selection, but also on the experience of the surgeons. The results of ETV is better than shunting specially in patients with posterior fossa tumors [21]. In addition if the expenses are taken into account; ETV is superior to shunting [22].

Early failure of ETV can occur for mostly peroperative events such as

- i. Bleeding around the fenestration site
- ii. Unnoticed additional arachnoid membranes occluding the flow of CSF
- iii. Inadequate size of the fenestration.

Late failure is the result of subsequent closure of the fenestration by gliotic tissue or arachnoid membrane. This problem is potentially serious because the failure can occur in a short period of time, may be unpredictable and presentation may be late due to a false sense of security. There are now several reports in the literature of death following late failure of ETV [23] and this remains a management problem. Tumor progression

and inadequate CSF absorption at the level of the arachnoid villi may result in early or late failure. A cohort of patients with open fenestrations who remained well for months, exhibits deterioration, the reasons of which are still not understood [24].

Procedure-related complications reported in the literature include bradycardia, hypothalamic dysfunction and hemorrhage from damage to arteries, ependymal veins, or the choroid plexus. The complications are divided into two main categories; short-term complications, which mostly resolve from intraoperative and technique-related, and long-term complications which occur at a much lower rate [25].

4. Simplifications of complex hydrocephalus and intracranial cysts

4.1 Multiloculated hydrocephalus

Multiloculated hydrocephalus is a condition in which there is isolated CSF compartments within the ventricular system that tend to enlarge even if the patient has a functioning V-P shunt. Multiloculation usually develops as a complication of meningitis, intraventricular hemorrhage, post shunt infection, head injury, ependymal trauma during shunt insertion and other inflammatory processes [26].

Following neonatal meningitis in infants, more than 30% of the survivors will develop hydrocephalus, most of these neonates have a risk of having multiloculated hydrocephalus [27]. The compartments are separated by septa that prevent accumulated CSF from being absorbed by either the ventricular catheter or normal sites of CSF absorption [28]. Even with multiple shunts, all compartments may not be drained properly. As a consequence, shunts are associated with high failure rates. There is also the risk of subsequent infections.

Endoscopy offers a simple means of communicating isolated CSF spaces and ventricles by membrane fenestration. A good analysis of the preoperative MRI scans will help to achieve a good outcome in these cases. Entry points are to be determined in a way, so that through the least number of burr holes, maximum number of cysts can be fenestrated and communication among them can be established [29]. Same burr hole as that for the placement of a ventricular catheter can also be taken into account for the fenestration procedure. Fenestration of the septum pellucidum to connect the two lateral ventricles in patients with loculated ventricles will preclude the need for two shunts in the majority of patients [20].

Spennato et al., explained high incidence of shunt obstruction in multiloculation by the chronic inflammation of the ependyma and appearance of new septa. They considered multiloculated hydrocephalus as progressive disease [30]. Akbari et al., found that 38.5% of patients with multiloculated hydrocephalus required additional endoscopic fenestrations after the initial surgery, while El-Ghandour found that in 33% of patients endoscopic fenestration was repeated during the follow-up period [31, 32].

Aqueductoplasty can be used for the treatment of trapped fourth ventricle syndrome. There is a high closure rate, which can be prevented by stenting. In these cases, endoscopic third ventriculostomy should also be done. Applied neuroendoscopic techniques have been extended to foraminoplasty of the foramina of Monro and Magendie, as well as endoscopic fourth ventriculostomy [1, 2, 11].

4.2 Intracranial cysts

The ventricular system may lodge many types of cysts like arachnoid cysts (AC), choroid plexus cysts, neoplastic cysts and infected cysts (e.g. hydatid and cysticercotic cysts). ACs, although typically extra-axial, may occur within the ventricles.

ACs can be treated with either endoscopic resection or fenestration to achieve a successful outcome in many patients [33].

Intracranial ACs comprise about 1% of all intracranial space-occupying lesions [34]. In the recent years with increased availability of computed tomography (CT) and magnetic resonance imaging (MRI), the incidence has seem to be increased as more are detected [35, 36]. Different surgical techniques are recommended. Because of the development of neuroendoscopy, pure endoscopic AC fenestration has become increasingly popular, where a communication can also be established with either ventricles or cisterns, and is actually preferred by many neurosurgeons [36, 37], especially in cases of cysts located in the suprasellar or quadrigeminal as well as in the posterior fossa [38–40].

Walker et al. reported in their preliminary series that 9 of 14 children (64%) with arachnoid cysts were successfully treated by endoscopic fenestration through a burr hole, thereby avoiding the need for craniotomy and brain manipulation [41]. Even cysts confined to the pituitary fossa are ideally suited to endoscopic trans-sphenoidal surgery. Ventriculo-cysto-cisternostomy offers long-term decompression of suprasellar arachnoid cysts without the need for shunting. Most patients with intraventricular cyst or tumors have concomitant hydrocephalus. These cases are better managed by endoscopic surgery rather than open, as procedures can be performed for both CSF diversion and tumor management simultaneously [42, 43]. Teo et al. had successful outcome in fenestrating ACs, cysts of the cavum velum interpositum, neuroepithelial cysts of the ventricle, colloid cysts and large pineal region cysts. While operating in smaller ventricles, frameless stereotactic guidance has been useful in planning the site(s) of the burr hole(s) and to plan the trajectory to these cysts. The current advancement of neuronavigation with electromagnetic guidance helps the endoscopic surgery more precise and well directed. The goal of surgery for arachnoid cysts is symptomatic improvement. This is particularly pertinent with endoscopic fenestration, as the appearance of the cyst on postoperative imaging may be only slightly diminished, despite marked clinical improvement [6].

5. Application of endoscopy to neuro-oncology

Endoscopy can be applied to neuro-oncology as it provides an ideal venue for this. The advancement of visualization of intraventricular pathology, management of tumor-related hydrocephalus, safer techniques of biopsies, and minimally invasive surgery for removal of intraventricular tumors are very useful adjuncts to traditional tumor management [6].

Once a tumor is removed, the surgeon can use the endoscope to assess the degree of resection. With the advantage of looking at the remote corners, the same surgery can be accomplished through a smaller craniotomy with the help of the endoscopes, may be with different angles, in keeping with the concept of minimally invasive surgery with maximally effective results [44]. By removing more tumor intraoperatively, endoscopy may improve the rate of survival for patients with benign tumors by reducing the less chance of recurrence and less requirement of adjuvant treatment [45, 46]. Adjunctive procedures, like third ventriculostomy and septostomy, can easily be performed through the same access points to manage concomitant problems like secondary hydrocephalus, where shunt placement can be avoided [6].

Endoscopic visualization and removal of intraaxial brain tumors using stereotactic guidance was first described in 1980 [47, 48]. In addition, stereotactic endoscopy for tumor removal through a conduit created by a bullet shaped dilator was reported in 1990 [49]. Kassam et al. described the development of a completely endoscopic system for resection of intraaxial tumors through a dilatable conduit.

The channel is created by dilatation of white matter, minimizing the neural structures by attempting to create a parafascicular approach to the tumor. The port creates an air medium that allows bimanual dissection. The instruments work parallel to the endoscope and the technique is safe as this does not deviate from the proven microsurgical principles [50].

Dr. Kelly pioneered a 20 mm diameter stereotactic tubular retraction system for the microscopic resection of deep brain tumors. Based on his work, the concept of endoscopic resection was initially developed [51–53]. As the microscope delivers a cone of light, tapering from the source until it reaches the target, the conduit that is required to deliver microscopic visualization is larger than an endoscopic conduit. In contrast, the endoscope delivers light and magnification via an inverted cone of light. Therefore, a much smaller port (11.5 mm) or conduit can be used to deliver the endoscope only very few millimeters from the target to visualize the tumor, creating a “flashlight” effect to illuminate the tumor. This advantage of the endoscope can be exploited to perform intraaxial tumor resections [50].

Although the conventional endoscope does not provide binocular vision, it has not been a major issue. Bimanual dissection allows proprioceptive feedback by which the loss of binocular vision can easily be compensated. This is similar to working from the observer’s perspective during microscopic neurosurgery. Once adequate experience is gained, the surgeon develops a good perception relying on tactile feedback from touch and movement. The development of 3D technology overcomes this limitation. Kassam et al. reported that endoscopic approach may prove to be superior to microscopic one for subcortical tumors, because the endoscope allows unrestricted and better illumination in deep regions with a closer view of the pathology. For cortical lesions, due to its location, microscope has got obvious advantages and it is preferred. But for deep-seated brain tumors, direct endoscopic view can add lot more details and significant advantages for removal. Many surgeons now prefer to have a final endoscopic visualization to confirm adequate resection for intraparenchymal tumors once the microscope has been taken out of the field [54].

Selected primary and metastatic brain tumors may be safely removed with this approach. Using dynamic retraction of the port and the method of piecemeal extirpation, a small conduit can be used for an effective removal of tumors that are much larger than the conduit itself can be effectively removed. Obviously, the long-term prognosis will ultimately be determined by the biology of the tumor. However, in the group of appropriately selected patients the port may offer a viable option to achieve the goals of surgery—that is, partial removal with a view of cytoreduction or complete removal of tumor with an acceptable level of morbidity, minimizing both corticectomy volume and white-matter dissection required for the resection of the tumor [8].

The burr hole is placed in an area of skull so that the scope should enter the ventricle from a furthest possible point towards the tumor so that the scope is directly viewing the tumor, not looking from one corner. The distal approach helps the surgeon to perceive the abnormal anatomy following an orientation of normal anatomical structures while passing the scope through non-pathological part of the brain. As most of the distal part of the scope is within the ventricle, the surgeon can move the scope in multiple directions with more flexibility without damaging the normal surrounding neural structures [6].

Endoscopic approach is not ideal for all intraventricular tumors. The suitability criteria for endoscopic removal include –

- i. Moderate to low vascularity
- ii. Soft consistency

iii. Associated secondary hydrocephalus

iv. Histologically low grade [6].

Even with the advancement of the MRI, all these criteria may always not be possible to confirm preoperatively.

Few principles should be followed during removal of the intraventricular tumor safely. The surgeon needs to choose a trajectory that avoids eloquent structures but allows a good view of the tumor. The outside of the tumor is coagulated with either monopolar electrocautery or a laser to ease the removal of the tumor. Profuse irrigation is needed for clearing the blood and debris and to prevent building up of too much heat inside the ventricle. Cysts need to be opened and the contents are either drained or sucked or removed as piecemeal. Remaining wall is removed piecemeal which allows removal of the whole pathology with a smaller access. With completion of the procedure, the scope is withdrawn while inspecting the tract for intraparenchymal bleeding [6]. Hemostasis is obtained with copious irrigation. If there is a clot noted, a cut-end foley catheter can be used with gentle aspiration to remove blood clot during intraventricular hemostasis [55].

Endoscopic tumor biopsy is a well-known procedure for the management of intraventricular tumors. It has a high diagnostic yield of more than 90% and low risk of less than 3.5%. Germ cell tumor, infiltrative hypothalamic/optic pathway glioma, and Langerhans cell histiocytosis can be addressed with endoscopic biopsy [2]. Endoscopic removal is well-established procedure for colloid cysts or tumors that are also pedunculated at the ependymal surface. Endoscopic excision of a colloid cyst is accessible and technically possible through the lateral ventricle in most cases unless the cyst is very large, which poses more risk of venous injury at the foramen of Monro [2, 56]. Transventricular endoscopic decompression of tumor cyst can temporarily or permanently treat the obstructive hydrocephalus or prevent the visual loss [7].

Hypothalamic hamartoms are rare non-neoplastic congenital malformations that arises from inferior hypothalamus and give rise to the symptoms of gelastic seizures, precocious puberty and cognitive problems. Surgical treatment is required for all patients except those with precocious puberty. Single or combination treatment are supposed to be used according to HH type as per the classification of Delalande and Fohlen [57] or Choi et al. [58] Endoscopic resection guided by stereotactic navigation has been attempted for surgical removal of small HHs, but parts of the tumors remained. Surgical resection of HHs is typically carried out in multiple steps. Despite that, recent reports indicate that endoscopic disconnection of HHs seems to be more effective and safer than other modalities [58, 59]. In spite of good visualization of the endoscopes, navigation assistance is recommended, in most cases, for obvious reason of precision in normal sized lateral and third ventricles [7].

6. Endoscope-assisted microsurgery

Endoscope-assisted microsurgery is the most rapidly growing area in endoscopic neurosurgery. Use of endoscope is the next step for surpassing the limitations of traditional microsurgery and allows the neurosurgeon to view tumor remnants such as those hidden behind eloquent brain tissue, a cranial nerve, or the tentorial edge.

Microsurgery evolved to maximize visualization and minimize retraction. Endoscopy allows the neurosurgeon to move another step further towards achieving these goals. Rigid endoscopes with various angles and flexible endoscopes help the surgeon to look around the remote corners which can be very useful in the removal of tumors and the clipping of cerebral aneurysms. Several approaches to the

extra-axial structures of the skull base have been described to improve visualization with strict adherence to the principles of standard microsurgical techniques. The most commonly adopted method is to insert the scope down the same operative field. This, obviously, creates no further morbidity but tends to clutter the already limited surgical field, which can be avoided by inserting instruments through a contralateral burr hole. The subarachnoid space can be accessed through a small supra-orbital incision and then standard microsurgical dissection is carried out to identify the pathology. Once the pathology is identified under direct vision, the endoscope should be fixed in place and the attention is focused on the ipsilateral side. This technique offers excellent visualization of the tips of an aneurysm clip or the contralateral extent of a tumor. Endoscopes are increasingly used to inspect tumors, tumor beds following resection, aneurysms and other pathologies. Various authors have described the advantages of endoscopes for these purposes [25, 60, 61].

The endoscope offers a superior and often novel view of the anatomy, which can be extremely useful for the understanding of the operative approach for the trainee neurosurgeons. Furthermore, the trainer and the learner share the same view of the surgical field, which may not always be possible even with an operating microscope.

There are risks, the most problematic of which of using the scope is the risk of friction upon structures while introducing the scope. It is of crucial importance to guide the endoscope by visualizing it along the length of its shaft, rather than watching the images on the monitor. Following placement of the scope into the surgical field, if the scope is not fixed, then small, barely noticeable movements at the tip can be the result of larger excursions at the back of the scope. Obviously, this can have potentially disastrous consequences. Hence, the endoscopic field of work should be observed and the movement of the shaft of the endoscope has to be delicate at the same time. A fixed endoscope holder can stop the unnecessary movement of the endoscope and aid the surgeon to work with both hands and to use more complex instruments, and will also prevent the endoscope from drifting against vital structures located superficially along the operative corridor [6].

7. Endoscopy for skull base lesions

The pioneering work of neuroendoscopy for skull base tumors was done by Carrau and colleagues [62], who reported their original experience of endonasal transsphenoidal hypophysectomy at the University of Pittsburgh. The endoscopic approach was expanded by de Divitiis and colleagues [4] to include other lesions of the sellar and parasellar regions. The bilateral endonasal endoscopic approach now allows for visualization of tumors at the anterior skull base up to the crista galli and down to the level of C2 [7]. **Figure 8** shows how endoscope can access and treat the pathologies in

- a. the crista galli to tuberculum sella,
- b. sella and suprasellar region,
- c. upper clival region and
- d. lower clival region upto the level of axis vertebra (C2).

The application of endoscopic endonasal surgery (EES) for excision of pituitary adenoma and craniopharyngioma has been reported with encouraging results and low morbidity [7]. The surgical corridor for the endoscopic approach for sellar or suprasellar tumors should be tailored on the basis of the extent of lesion.

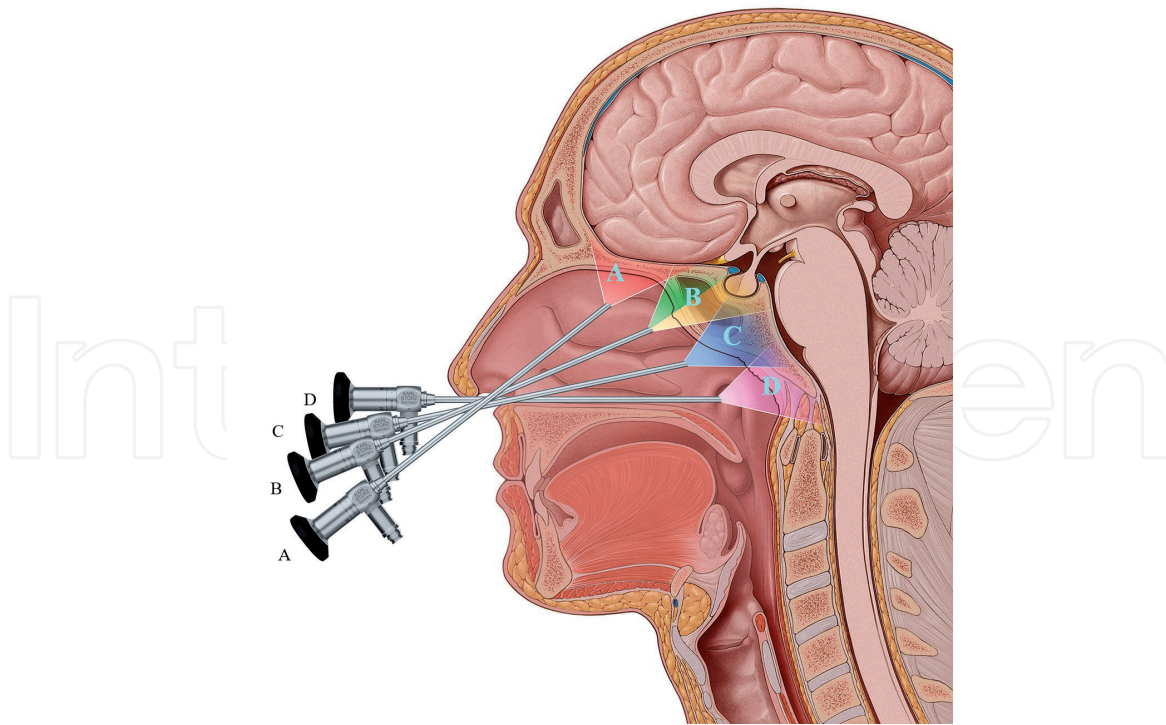


Figure 8.

Angles of endoscope by which the broad area of skull base (A. Frontal base, B. Sella, C. upper clivus, D. lower clivus) can be approached.

Supradiaphragmatic lesions can be removed via the endonasal route. On the other hand the suprasellar prechiasmatic preinfundibular lesions can be removed with the transtuberculum-transplanum sphenoidale approach [2].

Tumors of the tuberculum sellae region present different type of difficulties for endoscopic endonasal surgery. It is a compact anatomic region where fine and critical microvasculature can be seen with the potential involvement of the Circle of Willis. The endoscopic procedure may leave high flow CSF leaks which may require the use of a vascularized flap, the most common example of which is the nasal septal flap [63, 64]. A natural extension for the endoscopic endonasal approach is anteriorly along the skull base to the planum and cribriform for resection of planum/cribriform [65].

EES has become a powerful tool for treating pathology of the clivus, the petro-clival region, along with the intradural posterior fossa lesions immediately adjacent to the clivus. Traditionally, the pathologies in the clival and paraclival regions have been difficult to approach, especially for those, which have significant extension in the sagittal plain and/or had significant bilateral extension. For these tumors, often a combination of open approaches was required, as evidenced by dividing the clivus into thirds, each requiring a separate approach [66].

Expanded Endonasal Approaches (EEA) is versatile in the sagittal plain so much so that the ventral surgical corridor provides access to lesions that extend bilaterally across the midline. A single endonasal corridor can be sufficient to access large tumors that span the entire clival region. An endoscopic approach to the upper clivus provides midline access to the interpeduncular cistern, basilar artery, mammillary bodies and the floor of the third ventricle. The upper clivus or “sellar clivus” is formed by the posterior clinoid processes and the dorsum sella, which needs to be accessed and resected during this approach. A middle transclival approach provides access to the ventral pons and prepontine cistern, the basilar trunk and anterior inferior cerebellar artery, as well as the cisternal segment of the abducens nerve. The paraclival ICAs and the petroclival fissure set the lateral limit of the sphenoidal clivus. Laterally, the middle transclival exposure is limited by the interdural segment of cranial nerve VI [67].

Meckel's cave lesions can be approached by expanding the exposures laterally and inferiorly to the cavernous sinus [68–70]. The lower transclival approach through the lower segment of the clivus, which lies below the roof of the choana, allows access to the premedullary cistern and ventral medullary surface, the vertebral arteries, vertebo-basilar junction and posterior inferior cerebellar arteries and the cranial nerves IX–XII [9]. **Figures 9–11** are showing an endoscopic view of the cerebellopontine angle [71].

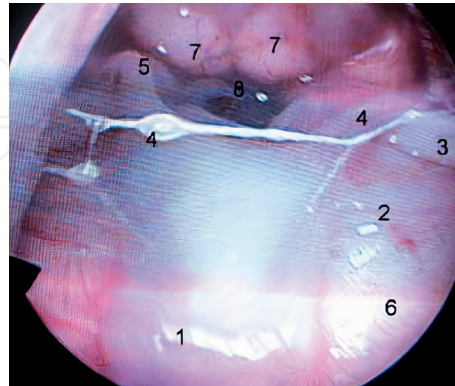


Figure 9. Endoscopic view of interpeduncular fossa and posterior part of CW. 1-basilar trunk, 2- superior cerebellar artery (SCA), 3- oculomotor nerve, 4-P1 artery, 5-posterior communicating artery, 6-basilar pons, 7- mamillary bodies & 8-Thalamoperforators.

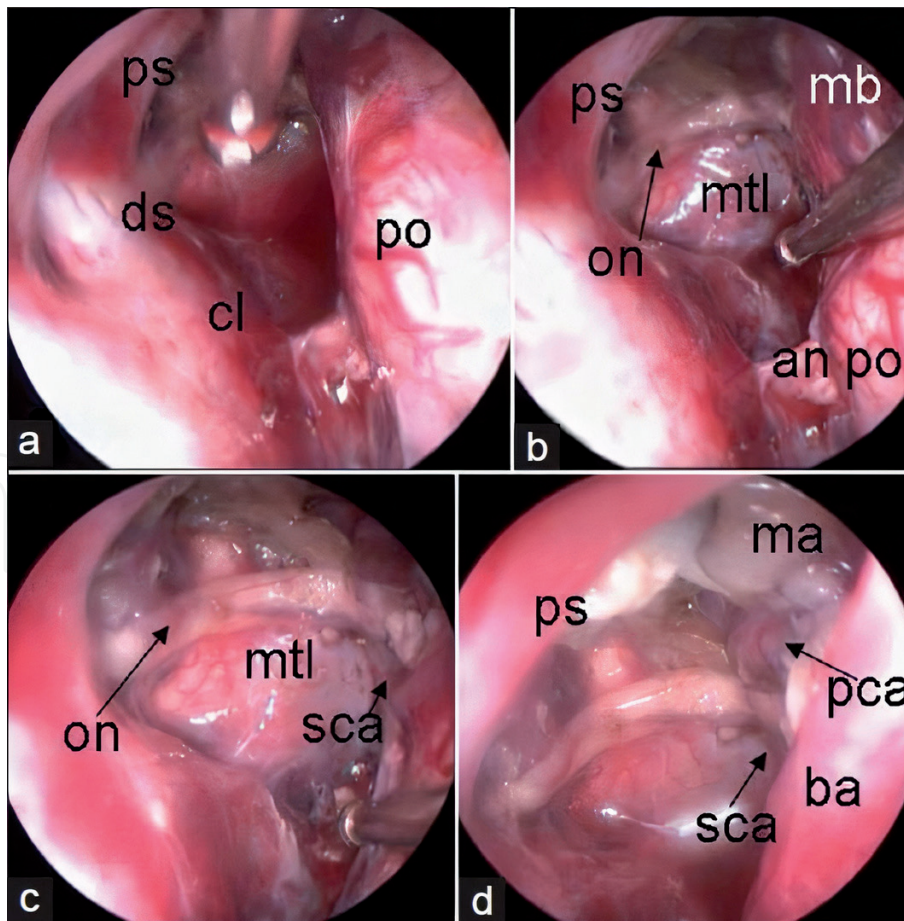


Figure 10. Endoscopic view through a cerebellopontine angle approach showing part of interpeduncular fossa and right sided medial temporal lobe. (a) Ps-pituitary stalk; po-pons; ds - dorsum sellae; and cl-clivus. (b) Ps-pituitary stalk; mtl - medial temporal lobe; on - oculomotor nerve; mb-midbrain; an-abducent nerve; po-pons. (c) On-oculomotor nerve; mtl-medial temporal lobe; and sca-superior cerebellar artery. (d) Ps-pituitary stalk; ma-right mamillary body; ba- basillar artery; pca-posterior cerebral artery; and sca-superior cerebellar artery.

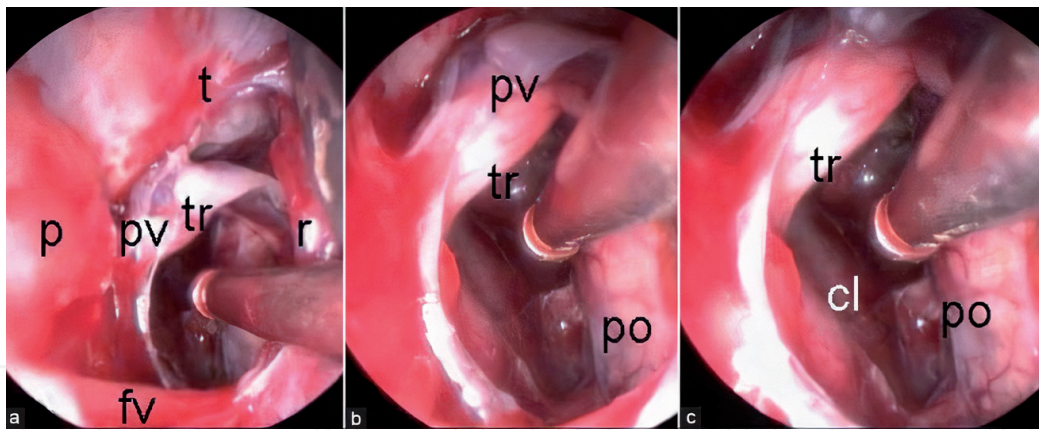


Figure 11.

Endoscopic view through a cerebellopontine angle approach showing upper pons. Fv-facial and vestibulo cochlear nerve complex; p - petrous; r-retractor; pv - petrosal vein, Tr -trigeminal nerve; Po - pons; Cl - clivus; and t - tentorium cerebelli.

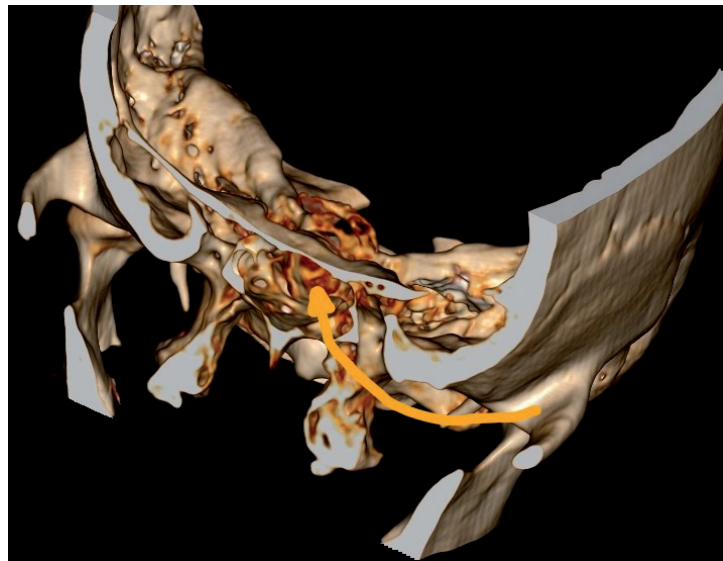


Figure 12.

Route of endoscopic transposition of vascularized TPTMF flap for CSF leak repair on a 3D reconstructed skull.

CSF rhinorrhoea, which commonly occurs as the result of trauma and iatrogenic disruption of the skull base as in EES & EEA and secondary to inflammation, neoplasm and pseudotumour syndromes, can be treated with endoscopic treatment. Skull base defects can be repaired with endoscopic remodeling of tissue planes and complete separation of the sinonasal cavities from the cranial space to carry out a multilayered reconstruction. Single layer of autologous fat or fascia, followed by tissue sealant may well be sufficient for small bony defects. Larger skull base defects with a high-volume intraoperative CSF leaks require robust closure with multiple layers. This multilayered closure can be achieved with an autologous fat graft in the bony defect followed by fascia lata, bony buttress and tissue sealant. These larger defects of skull base can be supplemented with a gasket seal closure [2, 63]. Currently, there are options of using multilayer closure with artificial dural substitutes and tissue sealants which work nicely in many cases. Sometimes, lack of vascularity may affect the integrity of the closure. Fortes et al. described endoscopic repair of CSF leak by transpterygoid transposition of a temporoparietal fascia flap [72] and Kawsar et al. showed good long-term outcome ranging from 6 months to 4 years in their small series. The pathway of the flap through the endoscopic route has been shown in **Figure 12** [73].

8. Endoscopic transsphenoidal surgery

8.1 Introduction

Gerard Guiot is recognized as the first neurosurgeon to use the endoscope in the transsphenoidal approach, although he abandoned the procedure because of inadequate visualization [74, 75]. In the late 1970s Apuzzo, et al. [76], as well as Bushe and Halves [77, 78], resurrected the application of endoscopes as a technical adjunct in the microscopic extirpation of pituitary lesions with extrasellar extension. Application of endoscopes was started initially to augment microsurgery, allowing the visualization of structures that were out of the line of vision; a view that were acquired with angled mirrors by other surgeons [75, 79]. Axel Perneczky, introduced the use of the endoscope in intracranial neurosurgery. He emphasized that endoscopic appreciation of micro-anatomy which may not be appreciated with microscope and pioneered the concept of minimally invasive neurosurgery [9, 80].

In the early 1990s, the pure endoscopic transsphenoidal technique was introduced as a result of the collaboration between neurological and otorhinolaryngological surgeons. In 1992 Jankowski and coworkers from the Central Hospital of the University of Nancy shared the experience of 3 cases of pituitary tumor in which they carried out a pure endoscopic transsphenoidal approach [81].

More recently, with other technical adjuncts such as neuronavigation and microvascular Doppler ultrasonography, endoscopic transsphenoidal surgery has been extended to the treatment of lesions outside the sella turcica, introducing the concept of extended approaches to the skull base [82, 83].

8.2 Operative procedure

The patient is intubated under general anesthesia, in supine position with the trunk elevated 10° and the head turned 10° towards the surgeon and fixed with three pin or tape in a horse-shoe headrest. Some surgeons prefer to fix with 3 pin rigid fixation and some do not; navigation is possible either way. Just before entering with the endoscope, the nasal cavities are packed with pledgets soaked in a diluted adrenaline. Some surgeons prefer cocaine or a mixture of cocaine and adrenaline. The operation can be divided in the following 3 phases.

8.2.1 Nasal phase

On entering with the endoscope, the main anatomical landmarks can be identified, such as the nasal septum medially and the inferior turbinate laterally (**Figure 13**). Following the tail of the inferior turbinate with the endoscope, choana can be reached, that is limited medially by the midline marker, vomer and, superiorly, by the floor of the sphenoid sinus.

The middle turbinate is gently pushed laterally to enlarge the virtual surgical corridor between the nasal septum and the middle turbinate. For a greater passage, some surgeons prefer to break and take the middle turbinate out, which can easily be avoided by lateralizing the turbinate. Looking upward with the endoscope, it is possible to identify the sphenoid ostium, usually located approximately 1.5 cm above the roof of the choana. If the sphenoid ostium is covered by either the superior or the supreme turbinate, these can be gently lateralized or removed, protecting the lateral lamella of the cribriform plate on which they are inserted. The removal or the lateral luxation of these turbinates should be done with extreme care in order to avoid ethmoidal plate injuries resulting in cerebrospinal fluid (CSF) leak.

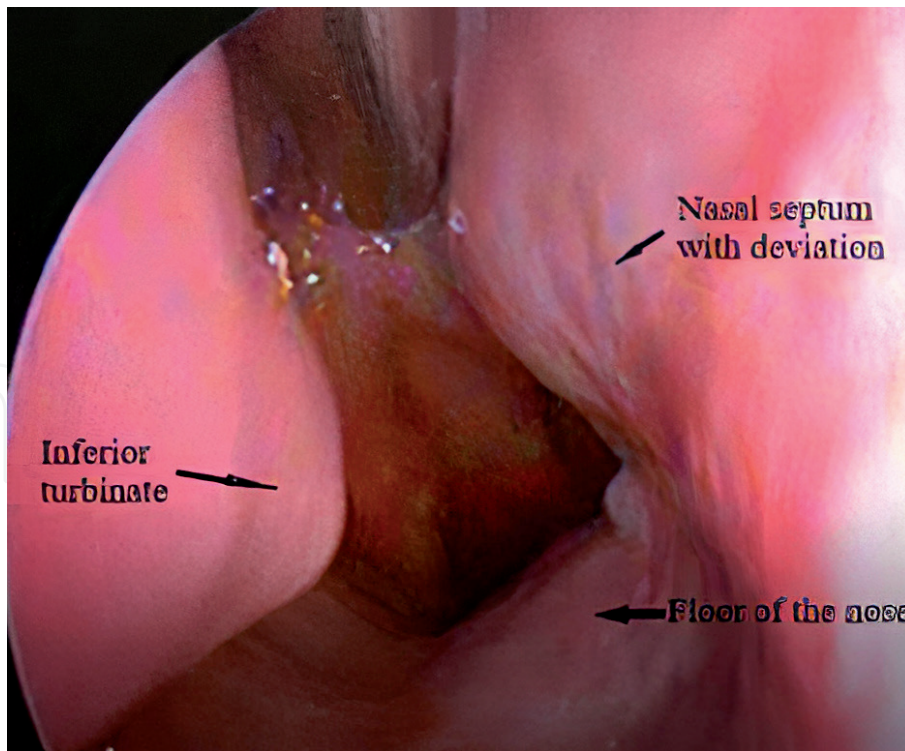


Figure 13.
Nasal stage of endoscopic pituitary surgery.

8.2.2 Sphenoid phase

To avoid arterial bleeding from septal branches of the sphenopalatine artery, the sphenoid phase of the procedure starts with the coagulation of the sphenoid recess and the area around the sphenoid ostium. The nasal septum is detached from the sphenoid rostrum by means of a microdrill. Subsequently, the anterior wall of the sphenoid sinus is widely opened with microdrill and Kerrison punches, proceeding circumferentially, with a caution not to overextend the opening in the inferolateral direction to avoid the damage to the sphenopalatine artery or its major branches.

It is important to widely expose and open the anterior face of the sphenoid to allow a proper working angle for the entire instrument when inside the sphenoid with their tips in the sella. After the removal of all the sphenoid septa, the posterior and lateral walls of the sphenoid sinus, with the sellar floor at the center, the sphenoid-ethmoid planum above it, and the clival indentation below, become visible. The bony prominences of the intracavernous carotid artery, the optic nerve and, between them, the optico-carotid recess can be visualized lateral to the sellar floor (**Figure 14**). The bony protuberances of the intracavernous carotid artery should be recognized to define the sellar floor boundaries, though the bony landmarks may not be properly identified in all cases. The superior and inferior intercavernous sinuses should be identified, bearing in mind that there are variations in anatomy and number of the intercavernous sinuses.

The sphenoid sinuses were classified into conchal, presellar and sellar types (there is also a description of mixed types) initially by Hammer and Radberg [84], a widely accepted classification as it can predict the surgical corridor used in transsphenoidal surgeries. Guldner *et al.* subdivided the sellar type into incomplete and complete types that were based on the extension of the pneumatization beyond the posterior wall of the sella [85, 86]. The modifications and the traditional system focus on the posterior extent of pneumatization and the ease of accessibility of the sellar floor during endoscopic endonasal resection.

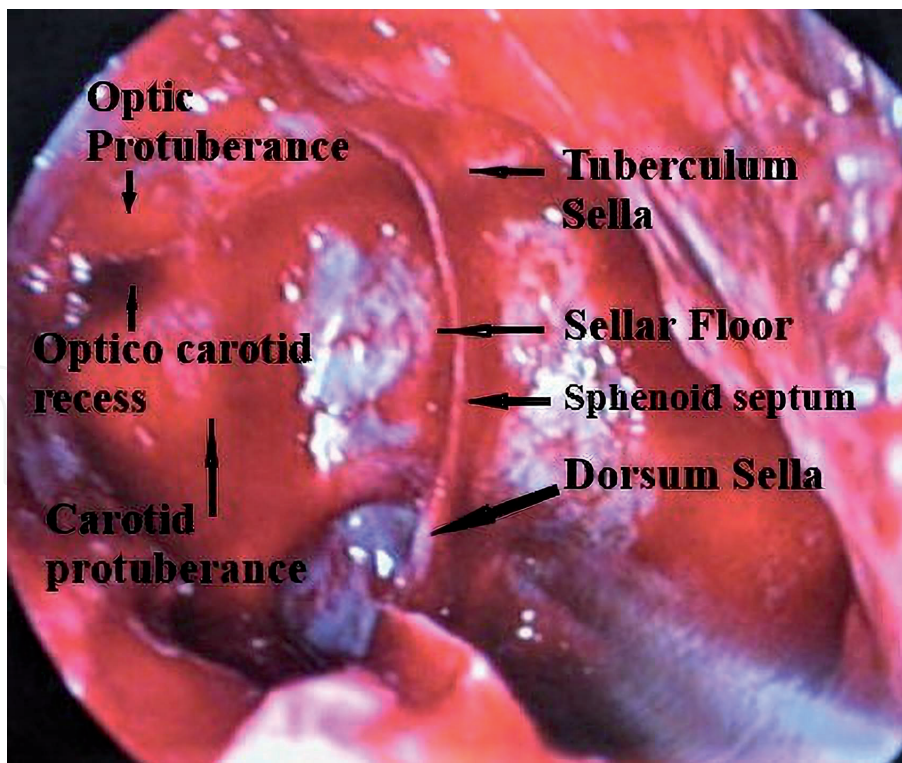


Figure 14.
End of sphenoidal phase of the pituitary surgery. The sellar floor is seen.

8.2.3 Sellar phase

From this phase of the procedure, the endoscope can be fixed to the holder, in order to free both of the surgeon's hands. Actually, it is our practice to continue using the endoscope free-hand, which is held dynamically by an assistant, while the surgeon can move the two instruments through one or both nostrils.

The sellar phase of the procedure (**Figure 15**) follows the same rules of the microsurgical transsphenoidal approach. Sellar floor opening is performed using a high-speed microdrill and a Kerrison rongeur usually extending the bone removal from one cavernous sinus to the other and from the tuberculum to the floor of the sella, although its shape and size could be tailored depending on lesion. Microdebrider can be another instrument which can be very helpful in removing the unwanted mucosal and bony debris. During such maneuvers a Doppler ultrasound probe will easily identify the carotid arteries, which will allow a safer opening of the dura that thereafter is incised in a midline position and in a rectangular, linear or cruciate fashion. In case of a macroadenoma, the inferior and lateral components of the lesion are removed before the superior aspect. This sequence will reduce the possibility of

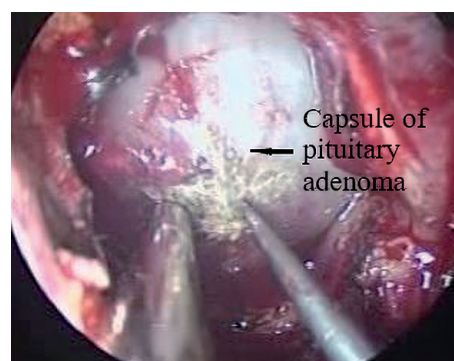


Figure 15.
Sellar stage of pituitary surgery. The capsule of pituitary tumor is exposed.

suprasellar cistern and the redundant diaphragma falling into the operative field and the lateral portions of the lesion will be less difficult to remove. Nevertheless, if the descent of the suprasellar portion of the lesion is not noted, a Valsalva maneuver is helpful to check the protrusion of the suprasellar cistern into the sellar cavity.

Besides, in case of microadenoma, dissecting tumor pseudocapsule from pituitary gland tissue is preferable for a complete 'en bloc' removal of the tumor, when possible, rather than performing an internal debulking [87]. This increases the chances of cure.

Finally, after removal of the lesion, an endoscopic exploration of the tumor cavity, by the means of a 0° and/or angled scope, is performed to assess for the presence of any tumor remnants. In case of hormone secreting tumors, the whole tumor needs to be removed to get a better outcome and angled scopes can contribute a great deal.

8.2.4 Sellar reconstruction

At the end of the procedure, especially in case of an intraoperative CSF leak, sellar repair is mandatory. Different methods of repair techniques are used (intra and/or extradural closure of the sella and packing of the sellar cavity with or without packing of the sphenoid sinus), based on the size of osteo-dural defect and of the space created following removal of the tumor inside the sella [88]. A number of dural substitute, tissue sealant and nasal packing are now available to secure the sellar reconstructions in place.

The aim of such a repair is to guarantee a watertight closure reducing the chance of CSF leak, reduce the dead space and prevent the descent of the chiasm into the sellar cavity. Nevertheless, overpacking has to be avoided to prevent compression of the optic system. Lumbar drainage is currently avoided, except in case of a minimal, unexpected post-operative CSF leak occurs. The endoscope is removed gradually, and the middle turbinate is gently put back in a medial direction. Packing of the nasal cavity is not used by most of the surgeons, though there are absorbable and non-absorbable packing are available.

8.3 Advantages

Transsphenoidal endoscopic resection of pituitary tumor brings a number of advantages to the patient like less nasal trauma, no nasal packing, less post-operative pain and usually quick recovery. The surgeon enjoys some advantages too, like wider and closer view of the surgical target area, recording of the operation for training and studying purposes for future improvement and more interdisciplinary cooperation etc. [89–91].

8.4 Complications

The study by Ciric et al. [92] which is regarded as the benchmark transsphenoidal surgery complication questionnaire pertaining to perioperative complications reported major morbidity in 1–2% of cases and postoperative CSF leaks in 3.9% of cases. The most experienced surgeons had better results with lower complication rates [93].

Lobatto et al. reported the postoperative incidence rates of CSF leaks between 1.4 and 16.9% in their systematic review where the higher body mass index (BMI) and younger age were risk factors for postoperative CSF leaks [94]. The reported incidence of DI ranges from 0.3–45% and is variable in part because of inconsistent definitions [95]. Two experienced pituitary groups who used accepted definitions for DI and whose surgical experience predominantly focused on endoscopic resection of pituitary adenomas have recently published their postoperative DI rates with fairly comparable results [96, 97]. In 178 and 271 patients respectively, both studies

reported a DI incidence rate of 26% and 16.6% with only 10% and 4% progressing to permanent DI [96, 97].

While hypernatremia can lead to severe morbidity in the perioperative phase, delayed hyponatremia is the most common cause of unplanned readmission following pituitary tumor surgery [98]. Most delayed hyponatremia is a secondary consequence of inappropriate release of antidiuretic hormone (SIADH) and usually occurs between post-operative day 4 and 7 with a reported incidence of 3.6% to 19.8% [99–101].

Dysfunction of the hypothalamic–pituitary axis (HPA) remains a recognized clinical problem. The most life threatening of these problems is adrenal insufficiency with contemporary cases series reporting rates between 3% and 21% [102].

Excessive removal of nasal septum can result in loss of nasal structural support, resulting in external nasal deformity. This risk can be increased when extended approaches requiring nasal septal flap reconstruction are employed [103, 104]. Removal of significant posterior-superior portions of the nasal septum, its mucosa, and the adjacent superior and middle turbinate mucosa (structures which make up the olfactory cleft) can result in hyposmia, or worse, anosmia. Therefore, an adequate surgical corridor needs to be carefully created towards the sellar region while trying to preserve the above structures specially when nasoseptal flap is harvested [105, 106].

Injury to the ICA during sellar exposure or removal of the tumor is rare with reported incidence between 0.2 to 0.4% and is associated with significant morbidity [107]. The iatrogenic injury can result in severe stroke, disability or death [108]. Significant epistaxis requiring additional intervention can occur in the range of 3% of cases [109, 110].

Ciric et al. reported from the self –reported questionnaire survey that the mean operative mortality for all three groups was 0.9% [92]. Agam et al. recently (2019)

Surgery related complications	Sellar: <ul style="list-style-type: none"> • CSF rhinorrhoea • Internal carotid artery injury <hr/> Orbital <ul style="list-style-type: none"> • Optic nerve injury • Diplopia • Blindness <hr/> Nasal <ul style="list-style-type: none"> • Epistaxis <hr/> Endocrinologic <ul style="list-style-type: none"> • Diabetes insipidus • Hypernatremia • Delayed Hyponatremia (SIADH) • Hypopituitarism
Medical complications (related to surgery)	<ul style="list-style-type: none"> • Bacterial Meningitis
Medical complications (indirectly related to surgery)	<ul style="list-style-type: none"> • Deep vein thrombosis • Pulmonary embolism

Table 3.
Complications of pituitary surgery.

reported only one case of mortality among 1153 cases, which is 0.1% perioperative death in their series [111].

Agam et al. reported patients with visual deficits and tumors which invades any surrounding structures are at higher risk of complication, is likely a caveat of more severe underlying disease [111]. Revision surgeries for prior transsphenoidal surgery, craniotomy and radiosurgery were also at higher risk for complications, likely because of fibrosis, adhesions and scarring that make the surgical environment more difficult (Table 3) [112].

9. Endoscopic application in aneurysm surgery

9.1 General roles of endoscope

The advantages of better illumination, clear views of regional anatomic features at close range and the extended viewing angles make the use of the endoscope a good adjunct or an independent alternative of microscope. Endoscope can be used in and around the operative field of aneurysms easier and safer. Furthermore, the endoscope facilitates confirmation of optimal clip positions [113].

In a cadaveric study by Chowdhury et al. the variations were identified and the authors concluded endonasal extended transsphenoidal approach can fully expose CW with brain in situ to observe the circle for variations and asymmetry (Figures 16 and 17) [114]. Taniguchi et al. reported in their series of 54 cases, the endoscope was used for further clarification of the detailed additional anatomy in 9 cases (16.7%). The surgeons reapplied the clip on the basis of endoscopic information which was gained after the initial clipping in 5 cases (9.3%) [115]. In a series of studies by Kalavakonda et al., the endoscope was used to observe anatomical features in 26 (33%) and clip position in 75 of 79 cases (95%). In 15 (19%) aneurysms, the important information like the neck and back wall of the aneurysm, parent artery, branches, perforators and the completeness of clipping of the neck and inclusion of the parent artery in the clip could be visualized via the endoscope. To complete the clipping of the residual neck or to avoid the inclusion of parent artery within the clip, the clip was repositioned in six cases, and to avoid compression of the optic nerve the clip position was reapplied in 1 case [116]. Fischer et al. reported, the endoscope was used to obtain additional topographic information before clipping in 150 of 180 cases (83%) [5, 117]. In 4 cases, clipping was achieved under endoscopic view. Following the clip application, endoscopic inspection was performed in 130 out of 180 procedures [113].

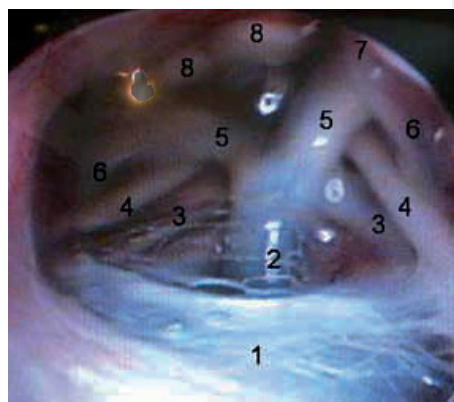


Figure 16.

Endoscopic view of posterior part of circle of Willis showing a number of anatomical variations. 1-Liliequist membrane, 2-basilar trunk, 3-SCA (left>right), 4-oculomotor nerve, 5-P1 (left>right), 6-P2 (left>right), 7-fetal type of Pcom & 8-mamillary bodies.

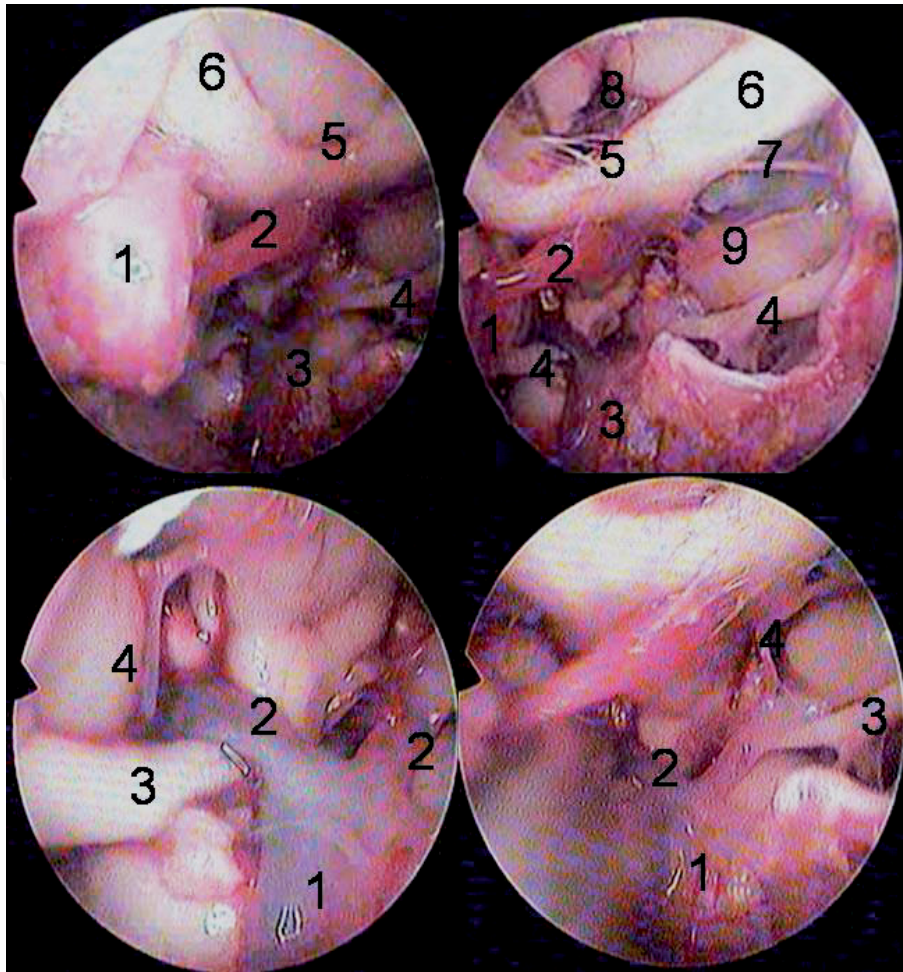


Figure 17.

Endoscopic view of interpeduncular fossa and posterior part of CW after mobilization of pituitary gland to right cavernous sinus area. A) 1-pituitary gland (mobilized), 2-pituitary stalk. 3-basilar artery, 4 - oculomotor nerve, 5- optic chiasma & 6-optic nerve. B) 1- pituitary gland (mobilized), 2- pituitary stalk. 3- basilar artery, 4 - oculomotor nerve, 5- optic chiasma, 6-optic nerve, 7-proximal A1 and internal carotid artery, 8-Acom complex, & 9-medial temporal lobe. C) 1-basilar artery, 2-P1, 3-oculomotor nerve, & 4- medial temporal lobe. D) 1-basilar artery, 2-P1, 3-oculomotor nerve & 4-posterior communicating artery (Pcom)).

In general, very large and giant aneurysms gain fewer benefits from the endoscope than smaller ones in the same location, because the mass of the lesion compromises insertion and fixation of the endoscope in the operative field [118]. The endoscope is especially useful in the treatment of deeply located cerebral aneurysm. Hence the location is another important factor. The effectiveness of the endoscope for these aneurysms is limited in case of superficially located aneurysms like middle cerebral artery aneurysms and distal aneurysms such as pericallosal aneurysms [113]. The detailed approach to the aneurysms are beyond the scope of this chapter.

Endoscopic application may be associated with some disadvantages. The endoscope can cause rupture of the aneurysm during initial inspection. Blood in the operative field may make the endoscope useless and clot must be removed before proceeding. There is still a lack of instrumentation specifically designed for endoscopic surgery [116]. Three dimensional views were not available before, which has now been circumvented by newer version of 3D endoscopes.

10. Microvascular decompression

The presence of offending vessels, which often compress the relevant nerve at the root entry/exit zone (REZ) generally cause the primary trigeminal neuralgia

(TN), hemifacial spasm (HFS), and glossopharyngeal neuralgia [119–121]. Microvascular decompression (MVD) is a well-established and effective treatment supported by many studies [122, 123].

Endoscopic techniques such as endoscopic or endoscope-assisted MVD (EMVD) have been used for MVD operations. Meanwhile, as the technique matures and the surgeons attain experience with endoscopic operation, some disadvantages of Microscopic MVD (MMVD) can be overcome. Though many neurosurgeons have not found EMVD superior to MMVD as the access for MMVD can be small and the offending vessels can be separated easily through that, several authors indicated the superior efficacy of endoscopic or endoscope-assisted surgery in locating the offending site of neurovascular conflict when compared with the microscopic surgery [124–126].

Regarding TN, the lateral pontomesencephalic segment of the SCA usually runs medial to the trigeminal nerve and the nerve can be compressed in a rostromedial direction [127, 128]. Through an endoscopic approach, the lateral pontomesencephalic segment of the SCA can be transposed rostromedially and fixed at the cerebellar tentorium. An approach with the thirty-degree endoscope through the lateral tentorial surface of the cerebellum via a keyhole provides excellent exposure of the trigeminal nerve from the REZ to the Meckel's cave. This can also show the course of the lateral pontomesencephalic segment of the SCA as the offending artery along the midbrain while requiring neither brain retraction nor ligation of the petrosal vein [129]. A clear endoscopic view also allows visualization of the perforators from the lateral pontomesencephalic segment of the SCA. Perforators from the lateral pontomesencephalic segment of the SCA are relatively long which helps transposition to fixation at the tentorium.

For HFS, the REZ of the facial nerve is located immediately medial to cranial nerve VIII in the supraolivary fossa, and the flocculus exits just lateral to cranial nerve VIII [127, 128]. The REZ of the facial nerve is often compressed by the lateral pontomedullary segment of the AICA from a caudal direction [127, 128]. The AICA can be transposed caudally and fixed at the petrosal dura mater by endoscopic approach. A 30° or 45° view of endoscopes through the petrosal surface of the cerebellum via a retrosigmoid keyhole clearly demonstrates the neurovascular structures and relationship around the supraolivary fossa behind the flocculus. The REZ of the facial nerve is readily identified after mobilization of the AICA as the offending artery. The endoscope also clearly demonstrates small perforators even behind obstacles [130], and secure recognition of perforators contributes to avoidance of injury during decompression procedures, especially for the transposition technique.

In the meta-analysis by Li et al., it is shown that, EMVD was superior considering the perioperative safety as with less perioperative complications [131]. Facial paralysis was significantly low in EMVD, and CSF leak and dysaudia (defective articulation stemming from auditory disability) also showed a similar trend with the previous discussions [132, 133]. Postoperative efficacy like recent remission rate, long-term remission rate, and offending vessel discovery rate was also superior to MMVD. The data from the series of Li et al. favored EMVD as the preferred method of surgery for MVD for the management of trigeminal or glossopharyngeal neuralgia and facial spasm [131].

11. Endoscopic operation for craniosynostosis

Jimenez and colleagues [134, 135] pioneered MIS treatment of craniosynostosis. Endoscopy-assisted craniosynostosis surgery (EACS) before the age of 6 months can

correct this condition while combined with postoperative helmet molding therapy. The optimal age for EACS is 3 months. The procedure is essentially strip craniectomy and can be carried out with a standard surgical instrument and a 0° endoscope with a working shaft used for endoscopic facial lift surgery without irrigation.

In scaphocephaly, the craniectomy is performed from the anterior fontanelle to the posterior one. The softer skull bone at this young age can be cut with strong scissors. The removed strip should be 4–5 cm wide and 11 cm long. Lateral barrel stave osteotomies or wedge-shaped osteotomies can be added behind the coronal suture and in front of the lambdoid sutures. Moreover the complication rate is reportedly low. Blood transfusion was required only in 9% of 139 patients. The children required to wear a helmet within 3 weeks postoperatively for 10 months. Special attention is given for possible pressure ulcerations or eczema, but skin complications are rare [2, 7, 135]. The reported studies showed that endoscopic approach has a good outcome with low reported complication rate and good success rate.

12. Evacuation of ICH: endoscopic and endoscope-assisted

Endoscope-Assisted Evacuation describes the creation of a small craniotomy or craniectomy with stereotactic introduction of a port or sheath to the hematoma followed by evacuation with the endoscope and a suction device or a combination device where the suction device is there side by side in the lumen of the sheath which is even less traumatic. Kim et al. performed a prospective study in 2009 evaluating endoscope-assisted evacuation in the treatment of patients with small ICH of less than 30 cm³ of volume and limited to the basal ganglia and thalamus [136]. Between the two groups, 204 patients in one group underwent stereotactic guided active evacuation and 103 patients in the other group were managed with conservative management. Patients that underwent endoscope assisted evacuation had mRS scores of 1.2 and medically managed group has an mRS scores of 3.0 at 180 days after initial presentation which obviously representing superiority of endoscopic assisted surgery [137].

Endoscopic evacuation is one of the earliest studies to investigate active MIS ICH evacuation using only endoscopes. Auer et al. published in 1989 demonstrating a significant benefit in favor of endoscopic evacuation, though in a single-center trial [138]. Investigators randomized 100 patients (within 48 hours from onset) with CT-proven supratentorial ICH greater than 10 cm³ and altered level of consciousness. Most patients had a 50 to 70% reduction of the volume of hematoma after endoscope-assisted surgery and experienced significantly lower mortality and morbidity rates when compared to the medically managed cohort (30 and 60% versus 70 and 75%). The cohort of patients, who were benefitted most from the procedure, had hemorrhages with a volume under 50 cm³ and age under 60 years [137].

13. Future perspectives

In this era of minimally invasive surgery, the future of neuroendoscopic surgery is likely to be bright as in other surgical superspecialities. The field will benefit from further miniaturization of cameras and optical technology with improvement of lenses with 3D technological improvement, innovations in surgical instrumentation design, the introduction of new navigation or robotics systems, new technological advances such as multiport endoscopic surgery, and an enhanced ability to perform endoscope-assisted microsurgery with bimanual microdissection. With ongoing development of endoscopic instruments and advanced surgical

techniques including multiport approaches, endoscopic surgery will be expanded beyond intraventricular and skull base lesions to intraparenchymal brain lesions. Other goals are telemanipulated neurosurgery with supervisory-controlled robotic systems, shared control systems, and even fully robotic telesurgery which can be operated by a panel of surgeons from different parts of the country or the world. Nanotechnology developments are needed to address future indications for minimally or even ultramicro-access neurosurgery.

In the future, neuroendoscopy is expected to become routine with further expansion in various aspects of modern neurosurgical practice. Institutions should develop training programs for young neurosurgeons [7].

14. Conclusion

From this chapter we learn how versatile the endoscopic approach can be in neurosurgery. As the scope of the chapter is limited, elaborate details could not be described. But the common approaches are mentioned and recent advancements are described. Some future directions are also described. This is how this chapter should benefit the trainees and the neurosurgeons.

Author details

Khandkar Ali Kawsar

Consultant Neurosurgeon, The Royal Infirmary of Edinburgh, UK

*Address all correspondence to: drkawsar@yahoo.com

IntechOpen

© 2021 The Author(s). Licensee IntechOpen. This chapter is distributed under the terms of the Creative Commons Attribution License (<http://creativecommons.org/licenses/by/3.0>), which permits unrestricted use, distribution, and reproduction in any medium, provided the original work is properly cited. 

References

- [1] Li KW, Nelson C, Suk I, Jallo GI. Neuroendoscopy: past, present, and future. *Neurosurg Focus*. 2005;19:E1.
- [2] Sgouros S. Neuroendoscopy: current status and future trends. ed 1. Heidelberg: Springer Science & Business Media; 2013.
- [3] Walker ML. History of ventriculostomy. *Neurosurg Clin N Am*. 2001;12:101-110. viii.
- [4] de Divitiis E, Cappabianca P, Cavallo LM. Endoscopic transsphenoidal approach: adaptability of the procedure to different sellar lesions. *Neurosurgery*. 2002;51:699-705. discussion 705-707.
- [5] Mixter WJ. Ventriculostomy and puncture of the floor of the third ventricle: preliminary report of a case. *Boston Med Surg J*. 1923;188:277-278.
- [6] Teo C & Mobbs R: Neuroendoscopy / Chapter 10 / Principals of Neurosurgery. Available from: https://www.researchgate.net/publication/306379195_Neuroendoscopy_Chapter_10_Principals_of_Neurosurgery
- [7] Shim KW, Park EK, Kim DS, Cho JU. Neuroendoscopy : Current and Future Perspectives. *J Korean Neurosurg Soc* 60 (3) : 322-326, 2017
- [8] Yokoh A, Sugita K, Kobayashi S. Intermittent versus continuous brain retraction: an experimental study. *J Neurosurg* 1983; 58: 918-23.
- [9] Perneczky A, Fries G. Endoscope-assisted brain surgery: Part I Evolution, basic concept, and current technique. *Neurosurgery* 1998; 42: 219-25.
- [10] Teo C. Endoscopic-assisted tumour and neurovascular procedures. *Clin Neurosurg* 2000; 46: 515-25.
- [11] Siomin V & Constantini S, Basic principles and equipment in neuroendoscopy. *Neurosurg Clin N Am* 15 (2004) 19-31.
- [12] Alberti O, Riegel T, Hellwig D, Bertalanffy H. Frameless navigation and endoscopy. *J Neurosurg* 2001; 95: 541-3.
- [13] André Grotenhuis Neuroendoscopic Instruments and Surgical Technique. S. Sgouros (ed.), Neuroendoscopy, 81 DOI 10.1007/978-3-642-39085-2_7, © Springer-Verlag Berlin Heidelberg 2014.
- [14] Nulsen FE, Spitz EB : Treatment of hydrocephalus by direct shunt from ventricle to jugular vein. *Surg Forum* 1951 : 399-403.
- [15] Vries JK : An endoscopic technique for third ventriculostomy. *Surg Neurol* 9 : 165-168, 1978.
- [16] Jones RF, Stening WA, Brydon M : Endoscopic third ventriculostomy. *Neurosurgery* 26 : 86-91; discussion 91-92, 1990.
- [17] Jones RF, Kwok BC, Stening WA, Vonau M : Neuroendoscopic third ventriculostomy. A practical alternative to extracranial shunts in non-communicating hydrocephalus. *Acta Neurochir Suppl* 61 : 79-83, 1994.
- [18] Mugamba J, Stagno V, Indication for Endoscopic Third Ventriculostomy, *World Neurosurgery*, Volume 79, Issue 2, Supplement, 2013, Pages S20.e19-S20.e23, ISSN 1878-8750, <https://doi.org/10.1016/j.wneu.2012.02.016>.
- [19] Sufianov A, Sufianova G, Iakimov I. Neuroendoscopic procedures in achievement of shunt independence: Outcome analysis of 28 patients with shunt malfunction. *Minimally Invasive Neurosurgery*. 2008;51:158-164.

- [20] Unal TC, Aydoseli A; Endoscopic Third Ventriculostomy. 2018, Intechopen.75394.
- [21] Saint-Rose C, Cinalli G, Roux FE, et al. Management of hydrocephalus in paediatric patients with posterior fossa tumours; the role of endoscopic third ventriculostomy. *J Neurosurg* 2001; 95: 791-7.
- [22] Barlow P, Ching HS. An economic argument in favour of endoscopic third ventriculostomy as a treatment for obstructive hydrocephalus. *Minim Invas Neurosurg* 1997; 40: 37-9.
- [23] Hader WJ, Drake J, Cochrane D, Sparrow O, Johnson ES, Kestle J. Death after late failure of third ventriculostomy in children. Report of three cases. *J Neurosurg* 2002; 97: 211-15.
- [24] Tisell M, Almstrom O, Stephenson H, Tullberg M, Wikkelson C. How effective is endoscopic third ventriculostomy in treating adult hydrocephalus caused by primary aqueductal stenosis? *Neurosurgery* 2000; 46: 104-9.
- [25] Brockmeyer D, Abtin K, Carey L, Walker ML. Endoscopic third ventriculostomy: an outcome analysis. *Paediatr Neurosurg* 1998; 28: 236-40.
- [26] Andresen M. and Juhler M.: Multiloculated hydrocephalus: A review of current problems in classification and treatment. *Childs. Nerv. Syst.*, Mar., 28 (3): 357-62, 2012.
- [27] Reinprecht A., Dietrich W. and Berger A.: Posthemorrhagic hydrocephalus in preterm infants: Long term follow-up and shunt related complications. *Child's Nerv. Syst.*, 17: 663-9, 2001.
- [28] Spennato P, Cinalli G, Carannante G., Ruggiero C. and Del ML: Multiloculated hydrocephalus. In: Cinalli G., Maixner WJ., Sainte-Rose C., editors. *Pediatric Hydrocephalus*. Milan: Springer, p. 219-44, 2004.
- [29] El-Tantawy MH, Endoscopic Fenestration of Multiloculated Post-Infectious Hydrocephalus, *Med. J. Cairo Univ.*, Vol. 86, No. 6, September: 2995-3002, 2018 www.medicaljournalofcairouniversity.net
- [30] Spennato P, Cinalli G, Ruggiero C, Aliberti F, Trischitta V, Cianciulli E. and Maggi G.: Neuroendoscopic treatment of multiloculated hydrocephalus in children. *J. Neurosurg.*, 106: 29-35, 2007.
- [31] El-Ghandour NM: Endoscopic cyst fenestration in the treatment of multiloculated hydrocephalus in children. *J. Neurosurg. Pediatr.*, Mar., 1 (3): 217-22, 2008.
- [32] Akbari SH, Holekamp TF, Murphy TM, Mercer D, Leonard JR, Smyth MD, Park TS and Limbrick DD. Jr.: Surgical management of complex multiloculated hydrocephalus in infants and children. *Childs. Nerv. Syst.*, Feb., 31 (2): 243-9, 2015.
- [33] Oi S, Abbott R : Loculated ventricles and isolated compartments in hydrocephalus: their pathophysiology and the efficacy of neuroendoscopic surgery. *Neurosurg Clin N Am* 15 : 77-87, 2004.
- [34] Robinson RG. Congenital cysts of the brain: arachnoid malformations. *Prog Neurol Surg.* 1971;4: 133-174 (doi:10.1159/000391818).
- [35] Hanieh A, Simpson DA, North JB. Arachnoid cysts: a critical review of 41 cases. *Childs Nerv Syst.* 1988;4(2):92-96.
- [36] Fernández Molina G. Neuroendoscopic management of middle fossa arachnoid cysts. *World Neurosurg.* 2013;79(2):S19.e19-23.

- [37] Oertel J, Linsler S, Wagner W, Gaab M, Schroeder H, Rediker J. Endoscopic Treatment of Intracranial Arachnoid Cysts: A Retrospective Analysis of a 25-Year Experience (Case Series), Operative Neurosurgery. October, 2020. Downloaded from <https://academic.oup.com/ons/advance-article/doi/10.1093/ons/opaa292/5918037>
- [38] Gangemi M, Seneca V, Colella G, Cioffi V, Imperato A, Maiuri F. Endoscopy versus microsurgical cyst excision and shunting for treating intracranial arachnoid cysts. *J Neurosurg Pediatr.* 2011;8(2):158-164.
- [39] Karabagli H, Etus V. Success of pure neuroendoscopic technique in the treatment of Sylvian arachnoid cysts in children. *Childs Nerv Syst.* 2012;28(3):445-452.
- [40] Wang C, Liu C, Xiong Y, Han G, et al. Surgical treatment of intracranial arachnoid cyst in adult patients. *Neurol India.* 2013;61(1):60-64.
- [41] Guiot G. Ventriculo-cisternostomy for stenosis of the aqueduct of Sylvius. *Acta Neurochir (Wien)* 1973; 28: 275-89.
- [42] Di Rocco F, Yoshino M, Oi S : Neuroendoscopic transventricular ventriculocystostomy in treatment for intracranial cysts. *J Neurosurg* 103(1 Suppl) : 54-60, 2005
- [43] Fukushima T, Ishijima B, Hirakawa K, Nakamura N, Sano K : Ventriculofiberscope: a new technique for endoscopic diagnosis and operation. Technical note. *J Neurosurg* 38 : 251-256, 1973.
- [44] Perneczky A, Muller-Forell W, van Lindert E, Fries G. Keyhole Concept in Neurosurgery. Stuttgart: Thieme; 1999: 120-48.
- [45] Wallner KR, Gonzales M, Sheline GE. Treatment of oligodendrogliomas with or without post-operative irradiation. *J Neurosurg* 1988; 68: 684-8.
- [46] Garcia DM, Fulling KH. Juvenile pilocytic astrocytomas of the cerebrum in adults. A distinctive neoplasm with favorable prognosis. *J Neurosurg* 1985; 63: 382-6.
- [47] Jacques S, Sheldon CH, McCann GD, Freshwater DB, Rand R: Computerized three-dimensional stereotaxic removal of small central nervous system lesions in patients. *J Neurosurg* 53:816-820, 1980.
- [48] Sheldon CH, McCann G, Jacques S, Lutes HR, Frazier RE, Katz R, et al: Development of a computerized microstereotaxic method for localization and removal of minute CNS lesions under direct 3-D vision: technical report. *J Neurosurg* 52:21-27, 1980.
- [49] Otsuki T, Jokura H, Yoshimoto T: Stereotactic guiding tube for open-system endoscopy: a new approach for the stereotactic endoscopic resection of intra-axial brain tumours. *Neurosurgery* 27:326-330, 1990
- [50] Kassam AB, Engh JA, Mintz AH, Prevedello DM. Completely endoscopic resection of intraparenchymal brain tumours. *J. Neurosurg.* / Vol 110 / January, 2009
- [51] Kelly PJ, Goerss SJ, Kall BA: The stereotaxic retractor in computer-assisted stereotaxic microsurgery. *J Neurosurg* 69:301- 306, 1988
- [52] Kelly PJ, Kall BA, Goerss S, Earnest F: Computer-assisted stereotaxic laser resection of intra-axial brain neoplasms. *J Neurosurg* 64:427-439, 1986
- [53] Russell SM, Kelly PJ: Volumetric stereotaxy and the supratentorial occipitotemporal approach in the resection of posterior hippocampus and

parahippocampal gyrus lesions. *Neurosurgery* 50:978-988, 2002

[54] Teo C, Nakaji P: Application of endoscopy to the resection of intra-axial tumours. *Op Tech Neursurg* 8: 179-185, 2005

[55] Kawsar KA, Haque MR, Chowdhury FH. Avoidance and management of perioperative complications of endoscopic third ventriculostomy: the Dhaka experience. *J Neurosurg.* 2015 Dec;123(6):1414-9.

[56] Yamini B, Refai D, Rubin CM, Frim DM : Initial endoscopic management of pineal region tumours and associated hydrocephalus: clinical series and literature review. *J Neurosurg* 100(5 Suppl Pediatrics) : 437-441, 2004.

[57] Delalande O, Fohlen M : Disconnecting surgical treatment of hypothalamic hamartoma in children and adults with refractory epilepsy and proposal of a new classification. *Neurol Med Chir (Tokyo)* 43: 61-68, 2003.

[58] Choi JU, Yang KH, Kim TG, Chang JH, Chang JW, Lee BI, et al. : Endoscopic disconnection for hypothalamic hamartoma with intractable seizure. Report of four cases. *J Neurosurg* 100(5 Suppl Pediatrics) : 506-511, 2004.

[59] ReKate HL, Feiz-Erfan I, Ng YT, Gonzalez LF, Kerrigan JF : Endoscopic surgery for hypothalamic hamartomas causing medically refractory gelastic epilepsy. *Childs Nerv Syst* 22 : 874-880, 2006.

[60] Lewis AI, Crone KR, Taha J, *et al.* Surgical resection of third ventricle colloid cyst. Preliminary results comparing transcalsallosal microsurgery with endoscopy. *J Neurosurg* 1994; 81: 174-8.

[61] Gamea A, Fathi M, el-Guindy A. The use of the rigid endoscope in

trans-sphenoidal pituitary surgery. *J Laryngol Otol* 1994; 108: 19-22.

[62] Carrau RL, Jho HD, Ko Y : Transnasal-transsphenoidal endoscopic surgery of the pituitary gland. *Laryngoscope* 106 : 914-918, 1996.

[63] Hadad G, Bassagasteguy L, Carrau RL et al (2006) A novel reconstructive technique after endoscopic expanded endonasal approaches: vascular pedicle nasoseptal flap. *Laryngoscope* 116(10):1882-1886.

[64] El-Sayed IH, Roediger FC, Goldberg AN, Parsa AT, McDermott MW (2008) Endoscopic reconstruction of skull base defects with the nasal septal flap. *Skull Base* 18(6):385-394.

[65] Roxbury CR, Ishii M, Gallia GL, Reh DD (2016) Endoscopic management of esthesioneuroblastoma. *Otolaryngol Clin N Am* 49(1):153-165.

[66] Sekhar LN, Sen C, Snyderman CH (1993) Anterior, anterolateral, and lateral approaches to extradural petroclival tumours. In: Sekhar LN, Janecka IP (eds) *Surgery of cranial base tumours*. Raven Press, New York.

[67] Zwagerman NT, Zenonos G, Lieber S, Wang WH, Wang EW, Fernandez-Miranda JC, Snyderman CH, Gardner PA. Endoscopic transnasal skull base surgery: pushing the boundaries, *J Neurooncol*, 2016.

[68] Wang X, Zhang X, Hu F et al (2016) Image-guided endoscopic endonasal transmaxillary transpterygoid approach to meckel's cave. *Turkish Neurosurg* 26(2):309-314.

[69] Raza SM, Donaldson AM, Mehta A, Tsiouris AJ, Anand VK, Schwartz TH (2014) Surgical management of trigeminal schwannomas: defining the role for endoscopic endonasal approaches. *Neurosurg Focus* 37(4):E17.

- [70] Jouanneau E, Simon E, Jacquesson T et al (2014) The endoscopic endonasal approach to the Meckel's cave tumours: surgical technique and indications. *World Neurosurg* 82(6 Suppl):S155–S161.
- [71] Chowdhury FH, Haque MR. Endoscopic assisted microsurgical removal of cerebello-pontine angle and prepontine epidermoid. *J Neurosci Rural Pract.* 2012 Sep;3(3):414-9. doi: 10.4103/0976-3147.102647. PMID: 23189019; PMCID: PMC3505358.
- [72] Fortes FS, Carrau RL, Snyderman CH, Kassam A, Prevedello D, Vescan A, Mintz A, Gardner P. Transpterygoid transposition of a temporoparietal fascia flap: a new method for skull base reconstruction after endoscopic expanded endonasal approaches. *Laryngoscope.* 2007 Jun;117(6):970-6. doi: 10.1097/MLG.0b013e3180471482. PMID: 17417106.
- [73] Kawsar KA, Land T, Tsermoulas G, Paluzzi A, Ahmed S. Novel Surgical Treatment of Recurrent CSF Leak by Temporoparietal Temporalis Myofascial Flap: A Series of 6 Cases. *World Neurosurg.* 2021 Mar;147:1-6. doi: 10.1016/j.wneu.2020.11.156. Epub 2020 Dec 5. PMID: 33290899.
- [74] Guiot G, Rougerie J, Fourestier M, et al: Explorations endoscopiques intracrâniennes. *Presse Med* 71: 1225-1228, 1963.
- [75] Liu JK, Das K, Weiss MH, et al: The history and evolution of transsphenoidal surgery. *J Neurosurg* 95:1083-1096, 2001.
- [76] Apuzzo MLJ, Heifetz M, Weiss MH, Kurze T: Neurosurgical endoscopy using the side-viewing telescope. Technical note. *J Neurosurg* 16:398-400, 1977.
- [77] Bushe KA, Halves E: Modifizierte Technik bei transnasaler Operation der Hypophysengeschwulste. *Acta Neurochir (Wien)* 41:163-175, 1978.
- [78] Halves E, Bushe KA: Transsphenoidal operation on craniopharyngiomas with extrasellar extensions. The advantage of the operating endoscope [proceedings]. *Acta Neurochir Suppl* 28: 362, 1979.
- [79] Hardy J: La chirurgie de l'hypophyse par voie transspénoïdale. *Union Med Can* 96:702-712, 1967.
- [80] Fries G, Perneczky A: Endoscope-assisted brain surgery: part 2— analysis of 380 procedures. *Neurosurgery* 42:226-232, 1998.
- [81] Jankowski R, Auque J, Simon C, et al: Endoscopic pituitary tumour surgery. *Laryngoscope* 102:198-202, 1992
- [82] Kaptain GJ, Vincent DA, Sheehan JP, et al: Transsphenoidal approaches for the extracapsular resection of midline suprasellar and anterior cranial base lesions. *Neurosurgery* 49:94-100, 2001.
- [83] Locatelli D, Castelnovo P, Santi L, et al: Endoscopic approaches to the cranial base: perspectives and realities. *Childs Nerv Syst* 16:686-691, 2000.
- [84] Hammer G, Radberg C. The sphenoidal sinus. An anatomical and roentgenologic study with reference to transsphenoid hypophysectomy. *Acta Radiol.* 1962;56:401-22.
- [85] Güldner C, Pistorius SM, Diogo I, Bien S, Sesterhenn A, Werner JA. Analysis of pneumatization and neurovascular structures of the sphenoid sinus using cone-beam tomography (CBT) *Acta Radiol.* 2012;53:214-9.
- [86] Hiremath SB, Gautam AA, Sheeja K, Benjamin G. Assessment of variations in sphenoid sinus pneumatization in Indian population: A multidetector computed tomography study. *Indian J*

Radiol Imaging. 2018 Jul-Sep; 28(3): 273-279.

[87] Oldfield EH, Vortmeyer AO (2006) Development of a histological pseudocapsule and its use as a surgical capsule in the excision of pituitary tumours. *J Neurosurg* 104:7-19 (Medline)

[88] Cappabianca P, Cavallo LM, Esposito F, Valente V, de Divitiis E (2002) Sellar repair in endoscopic endonasal transsphenoidal surgery: results of 170 cases. *Neurosurgery* 51:1365-1371 (discussion 1371-1362, Medline).

[89] Spencer WR, Das K, Nwagu C et al (1999) Approaches to the sellar and parasellar region: anatomic comparison of the microscope versus endoscope. *Laryngoscope* 109:791-794 (Medline).

[90] Snyderman C, Kassam A, Carrau R, Mintz A, Gardner P, Prevedello DM (2007) Acquisition of surgical skills for endonasal skull base surgery: a training program. *Laryngoscope* 117:699-705.

[91] Cappabianca P, Cavallo LM, Divitiis OD, Solari D, Esposito F, Colao A. Endoscopic pituitary surgery. *Pituitary* (2008) 11:385-390.

[92] Ciric I, Ragin A, Baumgartner C, Pierce D: Complications of transsphenoidal surgery: results of a national survey, review of the literature, and personal experience. *Neurosurgery* 40:225-237, 1997.

[93] Barker FG II, Klibanski A, Swearingen B: Transsphenoidal surgery for pituitary tumours in the United States, 1996-2000: mortality, morbidity, and the effects of hospital and surgeon volume. *J Clin Endocrinol Metab* 88:4709-4719, 2003.

[94] Lobatto, D.J., de Vries, F., Zamanipour Najafabadi, A.H. *et al.* Preoperative risk factors for

postoperative complications in endoscopic pituitary surgery: a systematic review. *Pituitary* 21, 84-97 (2018).

[95] Abhinav K, Tyler M, Dale OT, Mohyeldin A, Fernandez-Miranda JC & Katznelson L. (2020) Managing complications of endoscopic transsphenoidal surgery in pituitary adenomas, *Expert Review of Endocrinology & Metabolism*, 15:5, 311-319.

[96] Ajlan AM, Abdulqader SB, Achrol AS, et al. Diabetes Insipidus following Endoscopic Transsphenoidal Surgery for Pituitary Adenoma. *J Neurol Surg B Skull Base*. 2018 Apr;79(2):117-122. doi: 10.1055/s-0037-1604363.

[97] Nayak P, Montaser AS, Hu J, et al. Predictors of Postoperative Diabetes Insipidus Following Endoscopic Resection of Pituitary Adenomas. *J Endocr Soc*. 2018 Sep 1; 2(9):1010-1019.

[98] Bohl MA, Ahmad S, Jahnke H, et al. Delayed Hyponatremia Is the Most Common Cause of 30-Day Unplanned Readmission After Transsphenoidal Surgery for Pituitary Tumours. *Neurosurgery*. 2016 Jan;78(1):84-90.

[99] Barber SM, Liebelt BD, Baskin DS. Incidence, Etiology and Outcomes of Hyponatremia after Transsphenoidal Surgery: Experience with 344 Consecutive Patients at a Single Tertiary Center. *J Clin Med*. 2014 Oct 28;3(4):1199-219. doi: 10.3390/jcm3041199.

[100] Hussain NS, Piper M, Ludlam WG, et al. Delayed postoperative hyponatremia after transsphenoidal surgery: prevalence and associated factors. *JNeurosurg*. 2013 Dec;119(6):1453-60. doi: 10.3171/2013.8.JNS13411. PubMed PMID: 24053496.

- [101] Jahangiri A, Wagner J, Han SW, et al. Morbidity of repeat transsphenoidal surgery assessed in more than 1000 operations. *J Neurosurg.* 2014 Jul;121(1):67-74. doi: 10.3171/2014.3.JNS131532. PubMed PMID: 24834943.
- [102] Little AS, Kelly DF, White WL, et al. Results of a prospective multicenter controlled study comparing surgical outcomes of microscopic versus fully endoscopic transsphenoidal surgery for nonfunctioning pituitary adenomas: the Transsphenoidal Extent of Resection (TRANSSPHER) Study. *J Neurosurg.* 2019 Mar 22;1-11.
- [103] Rowan NR, Valappil B, Chen J, et al. Prospective characterization of postoperative nasal deformities in patients undergoing endoscopic endonasal skull-base surgery. *Int Forum Allergy Rhinol.* 2019 Oct 30. doi: 10.1002/alr.22466. PubMed PMID: 31665569.
- [104] Rowan NR, Wang EW, Gardner PA, et al. Nasal Deformities Following Nasoseptal Flap Reconstruction of Skull Base Defects. *J Neurol Surg B Skull Base.* 2016 Feb;77(1):14-8. doi: 10.1055/s-0035-1555136. PubMed PMID: 26949583; PubMed Central PMCID: PMC4777617.
- [105] Harvey RJ, Malek J, Winder M, et al. Sinonasal morbidity following tumour resection with and without nasoseptal flap reconstruction. *Rhinology.* 2015 Jun;53(2):122-8. doi: 10.4193/Rhin14.247. PubMed PMID: 26030034.
- [106] Harvey RJ, Winder M, Davidson A, et al. The Olfactory Strip and Its Preservation in Endoscopic Pituitary Surgery Maintains Smell and Sinonasal Function. *J Neurol Surg B Skull Base.* 2015 Dec;76(6):464-70.
- [107] Perry A, Graffeo CS, Meyer J, et al. Beyond the Learning Curve: Comparison of Microscopic and Endoscopic Incidences of Internal Carotid Injury in a Series of Highly Experienced Operators. *World Neurosurg.* 2019 Nov;131:e128-e135. doi: 10.1016/j.wneu.2019.07.074. PubMed PMID: 31319187.
- [108] Chin OY, Ghosh R, Fang CH, et al. Internal carotid artery injury in endoscopic endonasal surgery: A systematic review. *Laryngoscope.* 2016 Mar;126(3):582-90. doi: 10.1002/lary.25748. PubMed PMID: 26525334.
- [109] De Los Reyes KM, Gross BA, Frerichs KU, et al. Incidence, risk factors and management of severe post-transsphenoidal epistaxis. *J Clin Neurosci.* 2015 Jan;22(1):116-22. doi: 10.1016/j.jocn.2014.07.004. PubMed PMID: 25150759.
- [110] Alzhrani G, Sivakumar W, Park MS, et al. Delayed Complications After Transsphenoidal Surgery for Pituitary Adenomas. *World Neurosurg.* 2018 Jan;109:233-241.
- [111] Agam MS, Wedemeyer MA, Wrobel B, Weiss MH, Carmichael JD, Zada G. Complications associated with microscopic and endoscopic transsphenoidal pituitary surgery: experience of 1153 consecutive cases treated at a single tertiary care pituitary center. *J Neurosurg* 130:1576-1583, 2019
- [112] Esquenazi Y, Essayed WI, Singh H, Mauer E, Ahmed M, Christos PJ, et al: Endoscopic endonasal versus microscopic transsphenoidal surgery for recurrent and/or residual pituitary adenomas. *World Neurosurg* 101:186-195, 2017.
- [113] Yoshioka H, Kinouchi H. The Roles of Endoscope in Aneurysmal Surgery. *Neurol Med Chir (Tokyo).* 2015;55(6):469-478. doi:10.2176/nmc.ra.2014-0428.
- [114] Chowdhury FH, Haque MR, Kawsar KA, Ara S, Mohammad QD,

- Sarker MH, Goel AH. Endoscopic endonasal transsphenoidal exposure of circle of Willis (CW); can it be applied in vascular neurosurgery in the near future? A cadaveric study of 26 cases. *Turk Neurosurg.* 2012;22(1):68-76. doi: 10.5137/1019-5149.JTN.4887-11.2. PMID: 22274974.
- [115] Taniguchi M, Takimoto H, Yoshimine T, Shimada N, Miyao Y, Hirata M, Maruno M, Kato A, Kohmura E, Hayakawa T: Application of a rigid endoscope to the microsurgical management of 54 cerebral aneurysms: results in 48 patients. *J Neurosurg* 91: 231– 237, 1999.
- [116] Kalavakonda C, Sekhar LN, Ramachandran P, Hechl P: Endoscope-assisted microsurgery for intracranial aneurysms. *Neurosurgery* 51: 1119– 1126; discussion 1126-1127, 2002.
- [117] Fisher G, Oertel J, Perneczky A. Endoscopy in aneurysm surgery. *Neurosurgery* 70 (ONS Supple 2): ons184– ons191, 2012.
- [118] Galzio RJ, Di Cola F, Raysi Dehcordi S, Ricci A, De Paulis D: Endoscope-assisted microneurosurgery for intracranial aneurysms. *Front Neurol* 4: 201, 2013.
- [119] Haines SJ, Jannetta PJ, Zorub DS. Microvascular relations of the trigeminal nerve. An anatomical study with clinical correlation. *J Neurosurg.* 1980;52: 381-386.
- [120] Antonini G, Di Pasquale A, Cruccu G, et al. Magnetic resonance imaging contribution for diagnosing symptomatic neurovascular contact in classical trigeminal neuralgia: a blinded casecontrol study and meta-analysis. *Pain.* 2014;155: 1464-1471.
- [121] Campos-Benitez M, Kaufmann AM. Neurovascular compression findings in hemifacial spasm. *J Neurosurg.* 2008;109:416-420.
- [122] Pollock BE, Schoeberl KA. Prospective comparison of posterior fossa exploration and stereotactic radiosurgery dorsal root entry zone target as primary surgery for patients with idiopathic trigeminal neuralgia. *Neurosurgery.* 2010;67:633-638 [discussion: 8-9].
- [123] Apra C, Lefaucheur JP, Le Guerinel C. Microvascular decompression is an effective therapy for trigeminal neuralgia due to dolichoectatic basilar artery compression: case reports and literature review. *Neurosurg Rev.* 2017;40:577-582.
- [124] Duntze J, Litre CF, Eap C, et al. Adjunctive use of endoscopy during microvascular decompression in the cerebellopontine angle: 27 case reports. *Neurochirurgie.* 2011;57:68-72 [in French].
- [125] Chen MJ, Zhang WJ, Yang C, Wu YQ, Zhang ZY, Wang Y. Endoscopic neurovascular perspective in microvascular decompression of trigeminal neuralgia. *J Craniomaxillofac Surg.* 2008;36:456-461.
- [126] Burchiel KJ, Clarke H, Haglund M, Loeser JD. Long-term efficacy of microvascular decompression in trigeminal neuralgia. *J Neurosurg.* 1988;69: 35-38.
- [127] Hitotsumatsu T, Matsushima T, Inoue T. Microvascular decompression for treatment of trigeminal neuralgia, hemifacial spasm, and glossopharyngeal neuralgia: three surgical approach variations: technical note. *Neurosurgery* 2003;53(6):1436-1441; discussion 1442-1443.
- [128] Martin RG, Grant JL, Peace D, Theiss C, Rhoton AL Jr. Microsurgical relationships of the anterior inferior cerebellar artery and the facialvestibulocochlear nerve complex. *Neurosurgery* 1980;6(5):483-507.

- [129] Komatsu F, Komatsu M, Di Ieva A, Tschabitscher M. Endoscopic approaches to the trigeminal nerve and clinical consideration for trigeminal schwannomas: a cadaveric study. *J Neurosurg* 2012;117(4):690-696.
- [130] Ishikawa M, Tanaka Y, Watanabe E. Microvascular decompression under neuroendoscopic view in hemifacial spasm: rostral-type compression and perforator-type compression. *Acta Neurochir (Wien)* 2015;157(2):329-332; discussion 332.
- [131] Li Y, Mao F, Cheng F, Peng C, Guo D, Wang B. A meta-analysis of endoscopic microvascular decompression versus microscopic microvascular decompression for the treatment for cranial nerve syndrome caused by vascular compression. *World neurosurgery*. 2019 Jun 1;126:647-55.
- [132] Kabil MS, Eby JB, Shahinian HK. Endoscopic vascular decompression versus microvascular decompression of the trigeminal nerve. *Minim Invasive Neurosurg*. 2005;48:207-212.
- [133] Badr-El-Dine M, El-Garem HF, Talaat AM, Magnan J. Endoscopically assisted minimally invasive microvascular decompression of hemifacial spasm. *Otol Neurotol*. 2002;23:122-128.
- [134] Jimenez DF, Barone CM : Endoscopic craniectomy for early surgical correction of sagittal craniosynostosis. *J Neurosurg* 88 : 77-81, 1998.
- [135] Jimenez DF, Barone CM, McGee ME, Cartwright CC, Baker CL : Endoscopy-assisted wide-vertex craniectomy, barrel stave osteotomies, and postoperative helmet molding therapy in the management of sagittal suture craniosynostosis. *J Neurosurg* 100(5 Suppl Pediatrics) : 407- 417, 2004.
- [136] Kim YZ, Kim KH. Even in patients with a small hemorrhagic volume, stereotactic-guided evacuation of spontaneous intracerebral hemorrhage improves functional outcome. *J Korean Neurosurg Soc*. 2009;46:109-15.
- [137] Hersh EH, Gologorsky Y, Chartrain AG, Mocco J, Kellner CP. Minimally invasive surgery for intracerebral hemorrhage. *Current neurology and neuroscience reports*. 2018 Jun 1;18(6):34.
- [138] Auer LM, Deinsberger W, Niederkorn K, Gell G, Kleinert R, Schneider G, et al. Endoscopic surgery versus medical treatment for spontaneous intracerebral hematoma: a randomized study. *J Neurosurg*. 1989;70:530-5