

We are IntechOpen, the world's leading publisher of Open Access books Built by scientists, for scientists

5,600

Open access books available

137,000

International authors and editors

170M

Downloads

Our authors are among the

154

Countries delivered to

TOP 1%

most cited scientists

12.2%

Contributors from top 500 universities



WEB OF SCIENCE™

Selection of our books indexed in the Book Citation Index
in Web of Science™ Core Collection (BKCI)

Interested in publishing with us?
Contact book.department@intechopen.com

Numbers displayed above are based on latest data collected.
For more information visit www.intechopen.com



Applications of Helium Plasma in Rejuvenation of the Face and Neck

Deirdre Leake and Janet Lee

Abstract

Energy based devices have been developed for the purposes of tissue contraction and skin tightening. Its application in the face and neck have been explored using lasers, temperature controlled monopolar and bipolar radiofrequency, and ultrasound. The purpose of this chapter is to explore the various applications for the face and neck using Renuvion™, a unique energy driven device based on plasma generated from the combination of helium gas and radiofrequency energy. The advantage of this technology is its ability to offer precise delivery of heat to tissue with minimal thermal spread, in part due to the rapid cooling aided by the helium gas. We will explore the options in which this technology can be incorporated to rejuvenate the face and neck, the patient selection considerations in choosing method of approach, surgical technique, anticipated outcomes, potential concerns and or complications associated with this and expected perioperative care. Applications in the face and neck include: (1) Subdermally in the neck as a stand alone procedure with or without liposuction. (2) Subdermally in a limited incision, non-excisional technique with a concomitant platysmaplasty either with an open approach or percutaneous use of suture suspension for the platysmal muscle. (3) Subdermally in conjunction with an open traditional rhytidectomy involving skin excision. (4) Ablative resurfacing—fractional or pulsed and full continuous modalities (non-FDA cleared at the time of this writing). It is the authors' experience that with appropriate patient selection this can be a powerful tool that can deliver skin tightening and rhytid reduction not seen by other technologies available.

Keywords: skin tightening, facelift, necklift, helium plasma, renuvion, facial rejuvenation

1. Introduction

The aging population is on the rise in the United States, with greater than 30% of the US population being over the age of 50 based on 2019 demographic data [1]. Traditional facelifting has largely been the gold standard for facial rejuvenation to address skin laxity in the face and neck. Energy based devices have emerged in the past several years as a treatment alternative to manage skin laxity either as a stand-alone procedure or used concomitantly with open surgical techniques [2]. The aging and the youth are looking for alternatives to traditional surgeries to improve their appearance. These devices can help tighten the skin and diminish subcutaneous fat with presumed less downtime, smaller incisions or less visible stigmata of having had surgery.

The normal body temperature is 37°C, at 50°C cell death begins over a 6 minute period [3] and at 60°C cell death occurs instantly [4]. At temperatures between 60° and 100°C, protein denaturation and coagulation occurs in conjunction with cell death, it is these two processes that results in tissue contraction and cellular regeneration [3]. Collagen is the primary protein in the skin and subdermal fibroseptal network. Denaturation of collagen begins at 66.8°C [5] resulting in rapid contraction by up to 1/3 of the collagen fiber length [6]. Furthermore, thermal injury initiates a wound healing response that results in neocollagenesis which can occur over 6 months. The Renuvion™ handpiece is a novel technology that uses helium plasma to achieve temperatures of 60–80°C in 0.08 to 0.04 seconds for maximum tissue contraction with subsequent rapid cooling reaching temperatures below 65°C within 0.1–0.2 seconds to reduce risk for thermal spread or collateral injury. In its subdermal applications, maximum change in external skin temperature was less than 4°C [7]. These unique thermoplastic properties allow for maximum tissue contraction and skin tightening with reduced risk for collateral injury. In applications of the head and neck, this is highly operator dependent and an understanding of how tissue contraction occurs is important in achieving optimal results whether it is used for a subdermal treatment or a resurfacing treatment.

The Renuvion handpiece is particularly appealing because it can be used in multiple applications. The subdermal technique can be used as a standalone treatment or be paired with a traditional facelift, while the ablative resurfacing produces unparalleled wrinkle reduction and skin contraction. Choosing optimal candidates is key. A patient seeking wrinkle reduction as well as achieving lift may be an excellent candidate. However, particularly with the ablative resurfacing technique, if the patient is unwilling to accept the downtime of 10 days to a month, there may be alternate options with less recovery time. It is also important to consider a patient's Fitzpatrick skin type and avoid this treatment for skin types greater than 3. Patients with type 3 should be treated with caution considering the risk of hypopigmentation. In addition, thin skin should be treated on the pulse setting, and the results will not be as significant as with thick skin.

2. Our evolution

It is first inherently important to understand this single device has two completely unique and distinctly different applications. One being used as a tool for subdermal “minimally invasive” skin tightening. This can be used in conjunction with other technologies such as liposuction with or without energy driven assistance (i.e., Vaser™), an open platysmaplasty or a limited incision/percutaneous suture suspension platysmaplasty such as MyEllevate™ to achieve optimal results of tightening the neck and jawline. In this technique, the energy is being delivered to the subdermis and fibroseptal network to allow the skin, subdermis and underlying fibroseptal network to contract en bloc uniformly to tighten and improve the neck and jawline. This is very patient dependent and not all patients get the same tightening without removal of skin.

The second, non-FDA approved, usage of this machine is the most powerful. It was noticed by many that wrinkle reduction with ablative resurfacing using Renuvion™ is wildly successful. The results can be profoundly amazing, but it is far from “minimally invasive”. The authors found that not only did resurfacing result in dramatic wrinkle reduction, but a significant contraction of the skin along the jawline, eyelids, forehead and upper lip was noticed as well. The degree of skin contraction in many cases matched that of outcomes seen in surgical procedures involving skin removal—such as that of a blepharoplasty in the eyelids (**Figures 1 and 2**).

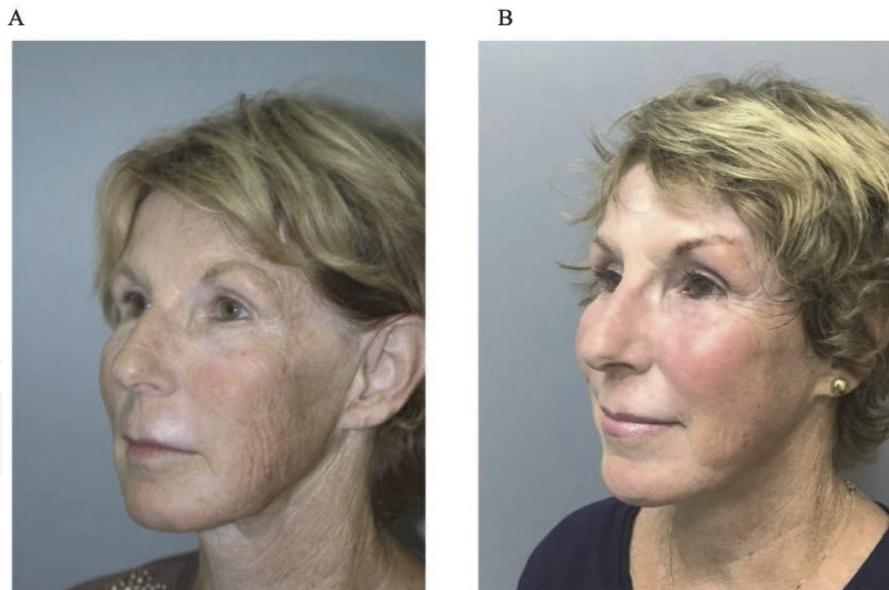


Figure 1.
One year after full face rejuvenation resurfacing, this patient's aged elongated upper lip was contracted that it almost restored the 1/3's proportions of the face.

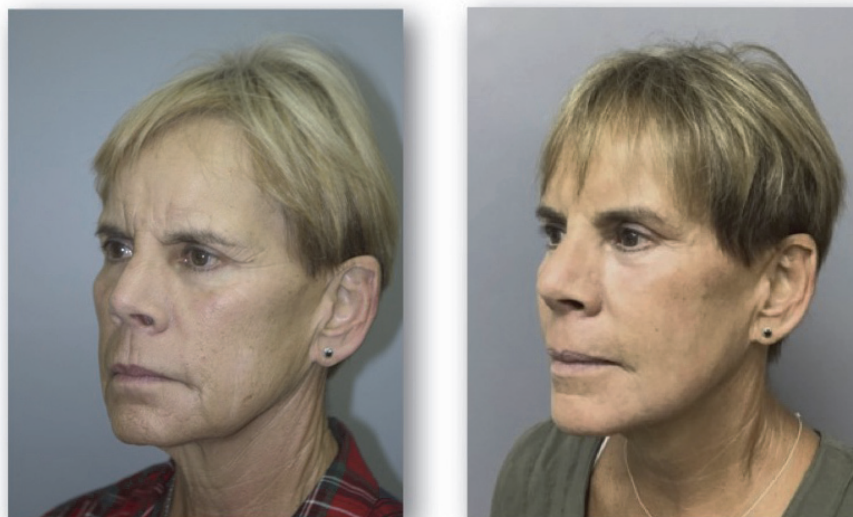

Figure 2.
This patient's mid face and upper lip had elongated with the aging process and sun, full face Renuvion™ resurfacing shortened the cutaneous upper lip significantly. The pink portion of her lip was rotated outward lifting her vermilion border while also decreasing her lip lines. This is a one year postoperative picture.

Again, this technique is highly operator dependent which will be discussed in detail later in the chapter.

Noticing the degree of skin contraction that can be achieved with ablative resurfacing and delivering energy directly to the epidermis, the authors questioned whether similar results could be achieved by delivering energy directly to the subdermis when it was separated from the fibroseptal network. In an open facelift technique, wherein the skin flap is fully elevated and released from the underlying fibroseptal network, energy is delivered directly to the lifted skin and subdermis. The Renuvion™ handpiece is now used in every open facelift that involves excision of redundant skin in conjunction with a platysmaplasty, deep plane or SMAS suspension. Previously, when performing a deep plane lift in the patient with excessively redundant skin, the vector of elevation results in significant skin removal and a significant shift of existing horizontal neck lines into the cheek and excess skin

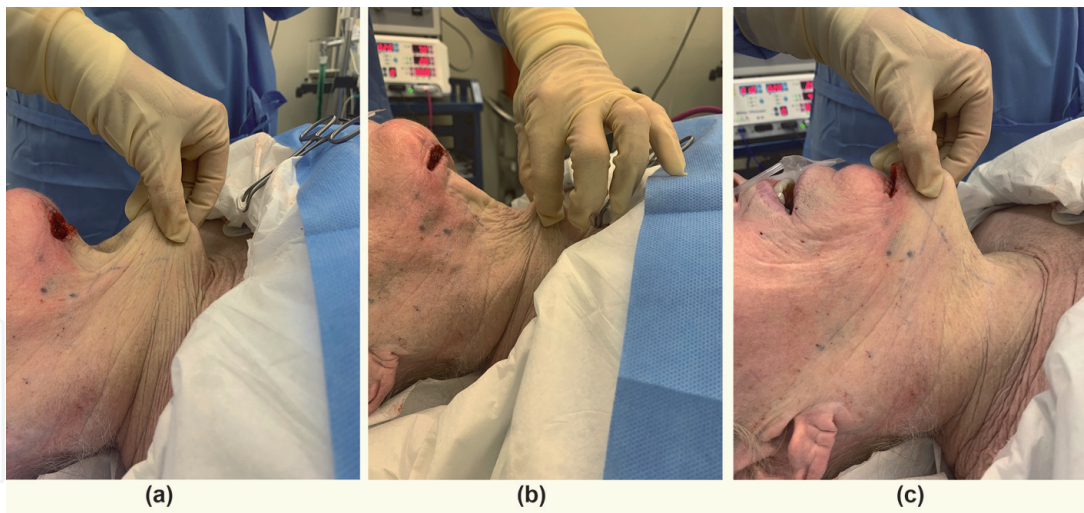


Figure 3.
(A-D) This intra-operative picture shows the excess skin with the neck flap is lifted inferiorly and superiorly. The Renuvion™ handpiece was used directly on the subcutaneous lifted flap and dermis. Approximately 6 passes were performed along the entire skin flap. Lifting the skin flap after the Renuvion™ had tightened the flap demonstrating the amount of skin contraction that can be achieved.

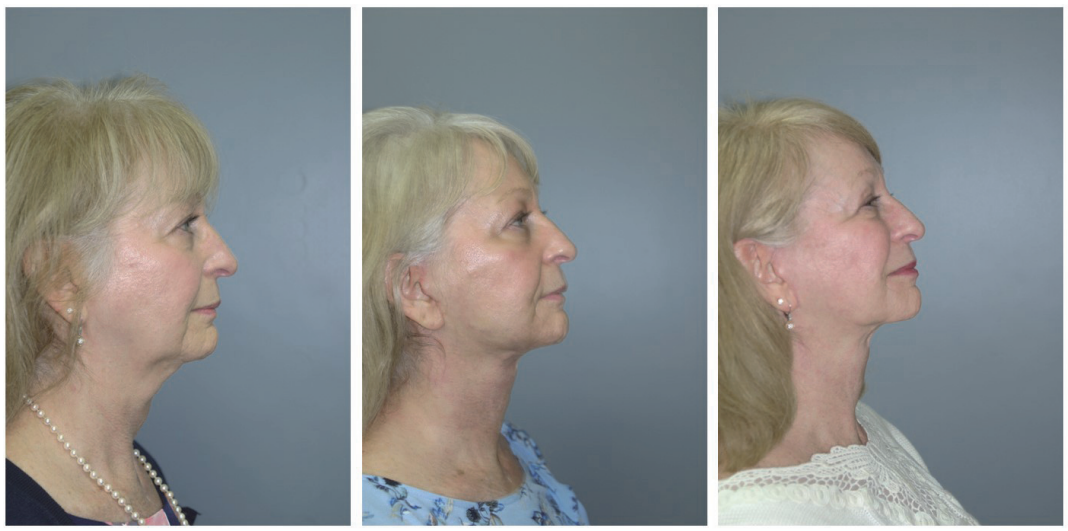

Figure 4.
This patient had an extended SMAS facelift on one side because she had a neck dissection 5 years earlier on the left side. The Renuvion™ was used subdermally to contract her skin in hopes to create a more symmetric look due to the previous dissected and irradiated neck skin on the left. The pictures shows preoperative, 6 months post op, and 2.5 year post op demonstrating the longevity of the skin contraction.

removal in the temporal area. With the use of Renuvion™ there is up to 1 to 1.5 cm of skin contraction seen directly on the table allowing less skin removal upon re-draping (**Figure 3**). An improved shrink wrap effect is seen along the jawline without abnormal shift of the lower horizontal neck lines. There is longevity to this skin tightening, patients seen at 3 years follow up have maintained results without further need of touch up, tuck ups at the submental area or jawline (**Figure 4**).

3. Patient considerations

Recognizing that there are several different applications and techniques in the approach to the head and neck with Renuvion™, it is important to discuss the

patient variables to consider who will achieve the best outcomes with which technique and not to mention considering the variabilities of the settings.

Using the device to tighten the subdermal neck only with or without liposuction, the ideal patient candidate is the younger patient, with minimal laxity, absence of redundant skin and inherently responsive skin elasticity. For the patient with inherent deep structure concerns such as platysmal banding, submandibular gland ptosis, and more significant skin laxity, but mild skin redundancy, a minimally invasive subdermal approach with Renuvion™ can be considered in conjunction with other minimally invasive techniques such as suture suspension platysmaplasty or with MyEllevate™. In the patient with significant facial aging, skin laxity with excess skin redundancy, the authors' experience is that an open traditional facelift approach combined with subdermal Renuvion™ yields best results. For the Fitzpatrick patient I-III with significant rhytidosis, solar elastosis, ablative resurfacing—both fractional and full resurfacing using Renuvion yields impressive results unsurpassed by other technologies currently on the market.

The Renuvion handpiece affords the physician to use one handpiece for the subdermal and resurfacing approaches. Other technologies cannot be used this way which makes the renuvion technology more attractive. With CO₂ laser and erbium Yag laser, wrinkle reduction is noted and has been studied in depth [8]. The authors have found that not only is wrinkle reduction improved, but the skin contraction with lifting of the lateral brow, medial brow and upper lip is seen much more with Renuvion. A split face study would need to be performed to truly delineate the superiority of renuvion for improving sagging skin. The authors decided to resurface with renuvion when the patient's skin is more loose and could benefit from lifting otherwise CO₂ is their other method of choice for wrinkle reduction and improvement of skin texture with less downtime. Also hypo pigmentation is seen 19% of patients getting fully ablative CO₂ laser [9]. While the authors noted some hypo pigmentation, it was not as high as 19%.

4. Technique

The Renuvion™ handpiece is very user dependent and technique cannot be discussed enough. It is different than most currently used laser devices that have a precise pulse width, spot size, duration with an exact depth of penetration. The Renuvion™ energy delivery is akin to using a laser in continuous mode. For this reason technique will directly impact time on tissue, energy delivered and depth of penetration. When used in pulsed mode the Renuvion™ helps regulate the depth and time on the skin for the first time users, but does not give the same degree of contraction or wrinkle reduction as seen in the non-pulsed mode. The most important determination of usage is to know that too much time on the subdermis or epidermis will cause increased depth of injury and result in permanent scarring. Furthermore, placing the handpiece too superficially in the subdermis will cause undulating acne like scars. It is recommended that a physician train users prior to the use on patients.

4.1 Subdermal neck only

When Renuvion™ is used in a minimally invasive manner as a stand-alone device for the subdermal neck, the ideal patient candidate is the younger patient in whom there is mild skin laxity in the absence of excessive skin redundancy. The subcutaneous neck is liberally infiltrated in a tumescent technique, this can be extended to varying degrees above the mandibular border to improve and impact

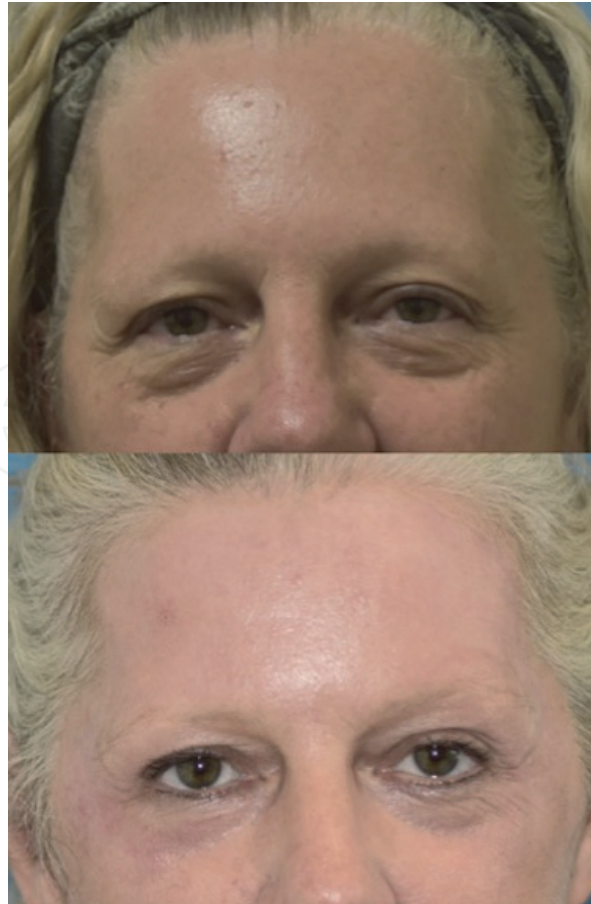

Figure 5.

This patient had Renuvion™ resurfacing performed with improvement of wrinkles and skin texture. The tightening of the lower lid skin has improved her fat pseudoherniation and her forehead contracted 1 cm.

energy along the jawline. Subdermal tunneling is then performed through stab incisions as seen in **Figure 6** create channels to pass the Renuvion handpiece without complete disruption of the underlying subdermal fibroseptal network. This can be performed using a liposuction cannula or other blunt tunneling instrument ideally measuring up to 3.5–4 mm in width. At this point, depending on the patient, the surgeon may elect to perform submental lipectomy or neck liposuction. It is important to point out that there needs to be open communication in your tunneling between the access points to facilitate Helium gas egress when the Renuvion™ handpiece is used. It is the authors' experience that taking the time to create sufficient tunneling broadly and widely involving the entire anterolateral neck yields best results. The handpiece is then passed subdermally 5 mm from the subdermis using the created subdermal tunnels. Energy is typically deployed in a retrograde fashion as the handpiece is removed and it is important to understand the handpiece should be in continuous motion when the energy is applied. The speed of the handpiece should be at approximately 1 cm/second maintaining a distance roughly 5 mm from the dermis to reduce risk of scarring. Energy delivered typically depends on the inherent thickness of the skin. In the thin-skinned patient energy of 60% up to 80% in the thicker-skinned patient can be considered at flow rates of 1.5–2 L. Typically, the neck and jawline are divided into subunits including the jawline, midline neck/submental area, the lateral neck, and posterior to the SCM. Four to six passes are performed 1 cm apart in each area, at a subdermal depth where the light from the wand can still be seen, but the skin is not tented under tension. As the energy is being delivered above the mandibular border, in the minimal incision technique, it is important to place firm hand pressure at the mid-cheek to prevent helium gas from extravasating into the cheek and orbit.

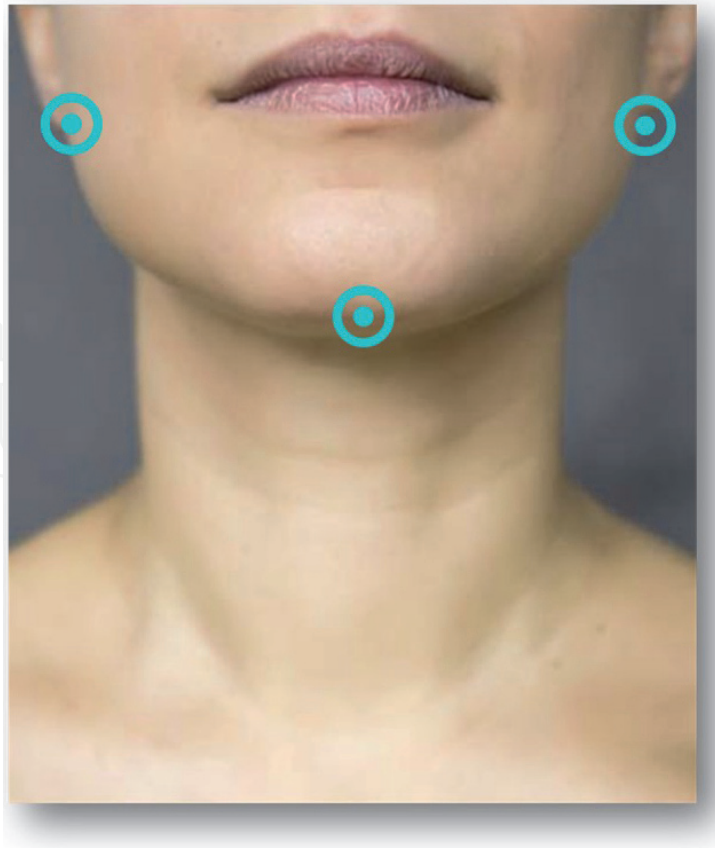


Figure 6.

Typically, 3 small entry point incisions (measuring 1 cm or less) are made—One is made under each earlobe at the facial junction as well as a small submental entry point incision.

Approximately a total of 4–6 KJ of energy is delivered to the neck and jawline in this technique. The exact energy delivered has not been studied to see what achieves optimal results.

4.2 Subdermal neck with platysmaplasty

In the patient for whom there is mild–moderate skin laxity in the presence of platysmal banding and or submandibular gland ptosis, addressing the underlying muscle in conjunction with subdermal Renuvion™ yields a better result than treatment of the subdermal neck alone. In this situation, the small entry point earlobe incisions remain the same, but the submental incision may be extended if an open platysmaplasty is to be performed. A novel limited incision technique is the combined use of platysmal band division and submental neck suture suspension using the LED light-guided device known as myEllevate™. In this case, the platysmal bands are percutaneously divided using the ICLED suture. The entry point incisions as described above remain the same. The neck is liberally infiltrated with tumescent solution. Subdermal tunnels are created in the midline and antero-lateral neck. At this point, the surgeon may proceed with submental and or neck liposuction if indicated. The Renuvion™ is then used at this stage, passing the wand through the created subdermal tunnels, delivering energy on withdrawal of the handpiece. Four to six passes are performed 1 cm apart as described above. Once more approximately 5–6 kJ of energy is delivered to the neck and jawline. Following completion of the Renuvion treatment of the fibroseptal network and subdermal neck, the MyEllevate™ suture is used to create a trampoline suture suspension from mastoid tip to mastoid tip to support the submental neck. The energy will not damage the previously placed sutures if the Renuvion™ needs to be passed again.

4.3 Open neck, facelift approach

In the patient for whom there is significant skin redundancy and laxity, an energy driven technology alone will be insufficient to achieve an optimal result. It has been the authors' experience, that best outcomes can be achieved when using the Renuvion™ handpiece in conjunction with a traditional open deep plane or SMAS face lift, neck lift approach. One may question why use the Renuvion™ handpiece at all if proceeding with a traditional facelift. Epidermal contraction was noticed by the authors when the Renuvion™ was used for ablative resurfacing. Consequently, the authors have speculated that similar tissue contraction can be achieved when the Renuvion is used in the subdermis. In the open facelift or neck lift, the skin has been fully released from the underlying platysma or SMAS, thereby completely releasing the fibroseptal network. In this situation, the energy is being targeted directly to the subdermis and not the fibroseptal attachments. When the Renuvion handpiece is being directly applied to the subdermis on an elevated skin flap, the authors have observed immediate contraction of the skin as seen in the figures above. The resulting shrink wrap effect permits less need for a vertical vector pull and less redundant skin to excise. Authors have found that the horizontal neck lines are less likely to be elevated into the lower cheek, and a smoother contour along the mandibular border is achieved. It was also noted that there is less skin to excise along the temporal anterior hairline creating well hidden incisions. For the open SMAS suspension face lifts, placing the handpiece along the jawline and medial jowl area creates a nice contraction and can obviate the need for a deep plane lift. It is not that a deep plane lift needs to be avoided, but this technique affords another option to the surgeon and patient.

4.4 Ablative resurfacing

The non-FDA approved application of the Renuvion™ for ablative resurfacing has been proven to be one of its most powerful applications. In the patient with significant rhytidosis and excess skin, wrinkle reduction and skin tightening can be accomplished with the Renuvion™ handpiece not seen with other technologies. Patients should expect significant downtime, which ranges from 10 days up to one month. As with most ablative resurfacing tools, this is not to be used in a Fitzpatrick skin type greater than 3 and even at times the Fitzpatrick 3 patient should be proceeded with caution. Thin skin should be treated on the pulse setting and results will not be as great. Diligent postop care is essential to the success of this treatment. Every patient experienced some milia and erythema, while some patients experienced hypertrophic scarring and hypopigmentation. The healing process may involve topical treatments such as tretinoin or adapalene, as well as laser treatments, kenalog injections and silicone sheeting to address minor complications.

The handpiece should be held no further than 5 mm from the skin in order to be effective. This is highly user dependent, requiring consistent, steady and constant movement across the skin surface maintaining uniformity in distance from the skin and speed of movement, moving at a speed of 1 cm/second [10]. Energy is being delivered directly to the epidermal surface, and therefore time on tissue is critical to achieve a good result and avoid complications. To accomplish wrinkle reduction and skin contraction, tissue coagulation and collagen remodeling needs to occur at the epidermis and epidermal/dermal junction just into the superficial papillary dermis. Delivery of energy into the deep papillary dermis or reticular dermis results in increased scar formation and hypertrophic scarring. For this reason, energy delivered, skin thickness, handpiece distance from the skin surface, and speed of movement are critical variables to outcome and reduced risk for complication.

The patient is prepped and draped in a meticulous sterile fashion. The skin is cleansed and degreased. Anesthesia is obtained, this can be accomplished using either systemic agents, sedation or with local anesthesia. If using local anesthesia, it is the authors' experience that a combination of local nerve blocks, mild tumescence and direct intradermal injections achieves best results. Selection of power setting depends on patient's skin type, skin thickness, and severity of wrinkles. The face is subdivided into zones of treatment. Number of passes and power settings vary based on zones of treatment (**Table 1**). Direction of movement of the handpiece, is optimally performed along the direction of the relaxed skin tension lines and it is the authors' opinion that this is less likely to result in hypertrophic scarring and potential webbing. While users have widely discussed ablative resurfacing using Renuvion™ with two passes at energies as high as 40%, the authors have found that satisfactory results can be achieved with one pass alone at 20% and less downtime. Early porcine studies performed by Bovie medical demonstrated the amount of tissue contraction using the BVX-044-BPS (now known as the Renuvion handpiece) is similar when comparing 40% power to 20% power, supporting the authors' opinion that optimal outcomes can be achieved at 20% [11]. The handpiece is held very close, within 5 mm of the skin and the endpoint looks similar to a toasted marshmallow (**Figure 7**). Continuous even movement is very important. Thin skin areas such as the upper and lower eyelid are treated at reduced energy

Zone	# Passes	Energy	LPM-Flow
Perioral	1–2	20–30	4
Periorbital	1	15–20	4
Forehead	1	20	4
Nose	1	20	4
Cheeks	1	20	4
Jawline	1	15	4
Neck	1	15 (pulsed/fractionated)	4

Table 1.
The different settings in different areas of the face.

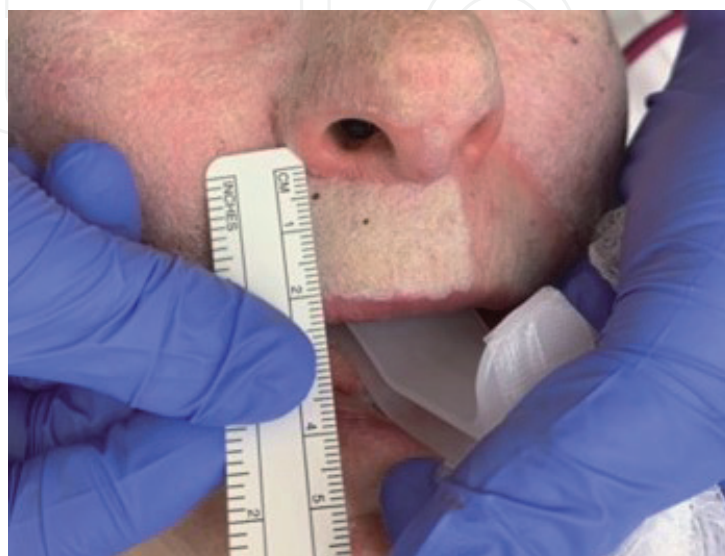

Figure 7.
The skin that is treated looks similar to a marshmallow that has just been exposed to the flame. Pre Renuvion measurement, Post Renuvion measurement.

15–20% and only pass. Areas of deep rhytids in thick skinned patients such as the glabella or upper lip have been addressed at times with 2 passes at 20–30% energy and 4 L flow rates. As one approaches along the mandibular border the energy is reduced to 15% and wand distance from the skin is increased to defocus the energy and to reduce risk for hypertrophic scarring and forming a demarcation line. The user can also place the handpiece in pulse mode along the jawline which helps decrease hypertrophic scars. Pulsed mode should be considered for the thin skin lateral to the chin and medial to the MLF line because this skin has been noted to develop hypertrophic scarring.

As with other resurfacing modalities, treatment of the neck should be exercised with caution. However, nice results can be achieved at lower and fractionated or pulsed settings. The energy can be made fractionated by placing a meshed wet gauze on the skin and then firing the handpiece over the gauze or placed in a pulsed mode. This can be done on the neck or face for less of a result, but with faster healing time and a decreased risk of complications. When placing a head wrap on the patient, non adherent gauze is placed on the neck. No scarring has been noted with this treatment. However, the resurfacing must be defocused and fractionated. This affords the patient tightening of crepe like skin of the neck.

The machine now has a KJ counter which is helpful for both subdermal applications and ablative resurfacing, but this is not available when used in pulsed mode. Again, the exact energy that is best for the patient's skin type has not been determined.

4.5 Post procedure care and normal sequelae

The best start to post operative care starts before the procedure. It is essential that the patient has understanding and is prepared for the after care. Prior to surgery, sharing pictures during the healing phase will be helpful. Having detailed written instructions for subdermal and resurfacing cases is a must (**Figure 8**).

Subdermal neck and face procedures should wear a head wrap compression dressing for a few days and a head wrap at night for a few weeks which will help the skin contract and seal down to the underlying platysmal muscle. The skin on the neck can look worse before it gets better similar to an elephant's foot. This typically settles down and can be improved with early treatment using IPL and non ablative lasers like Palomar 1540 XF. Delivery of energy to the subdermal neck is an intentional injury to the fibroseptal network, designed to stimulate collagen contraction. This resultant scar contracture can at times create tethering and bunching of the skin, particularly in the thin skinned patient. Dilute Kenalog 10 can help smooth out the skin during the healing process (**Figure 9**). The texture of the skin within a few weeks starts to improve. The thin crepe like skin will take longer and thick skin smooths out earlier. The platysmal muscle can create some bunching of the skin when it is overactive, so diluted neurotoxin can help smooth out the neck and hasten the healing process. Placing the handpiece too superficially or too long can cause a subdermal scar (**Figure 10**).

Resurfacing postoperative patients are very time consuming, require meticulous post operative care and must be seen frequently. During the first week, the regimen until re-epithelialization includes washing with distilled water and a capful of vinegar and/or mild soap (vanicream or cerave) twice a day. It is very important to tell the patients to not remove the eschar or dead skin while washing and to leave it as a biological dressing. The authors have found that constant picking and rubbing will cause prolonged redness and itching, and increases the risk for hypertrophic scarring or hypopigmentation (**Figure 11**). Keeping the treated area moist and protected with aquaphor/vaseline or an occlusive silicone patches can help the process of epithelialization. Informing the patient that they may need to frequently change

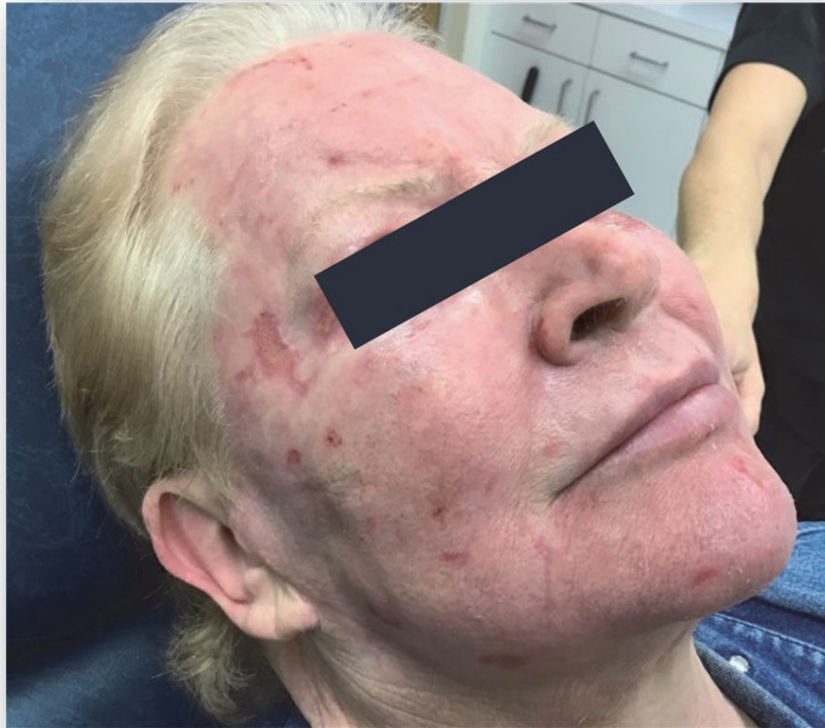

Figure 8.
This patient is two weeks postop. She did not have any sequelae or complications from the resurfacing procedure. This redness and splotchy circular healing the authors have found is completely normal and fades slowly.

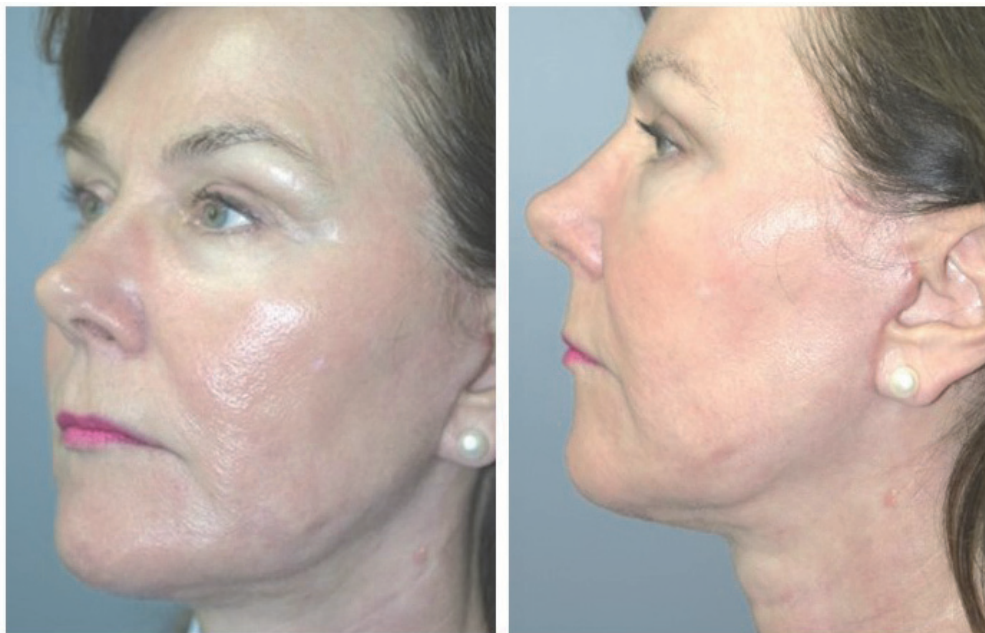

Figure 9.
This patient has some indentation and elephant looking edema along the jawline which dissipated with time and the use of IPL.

their skin care for resurfacing cases will be necessary. All patients are different and with the new skin they can have issues with dermatitis.

After epithelialization, several different sequelae can occur. Most have intense itching after two weeks and hydroxyzine works well to temper this. The hyperemia can be problematic and is worse after a shower or working out. This can improve with frequent IPL treatments and skin care. The redness seems to fade into circles

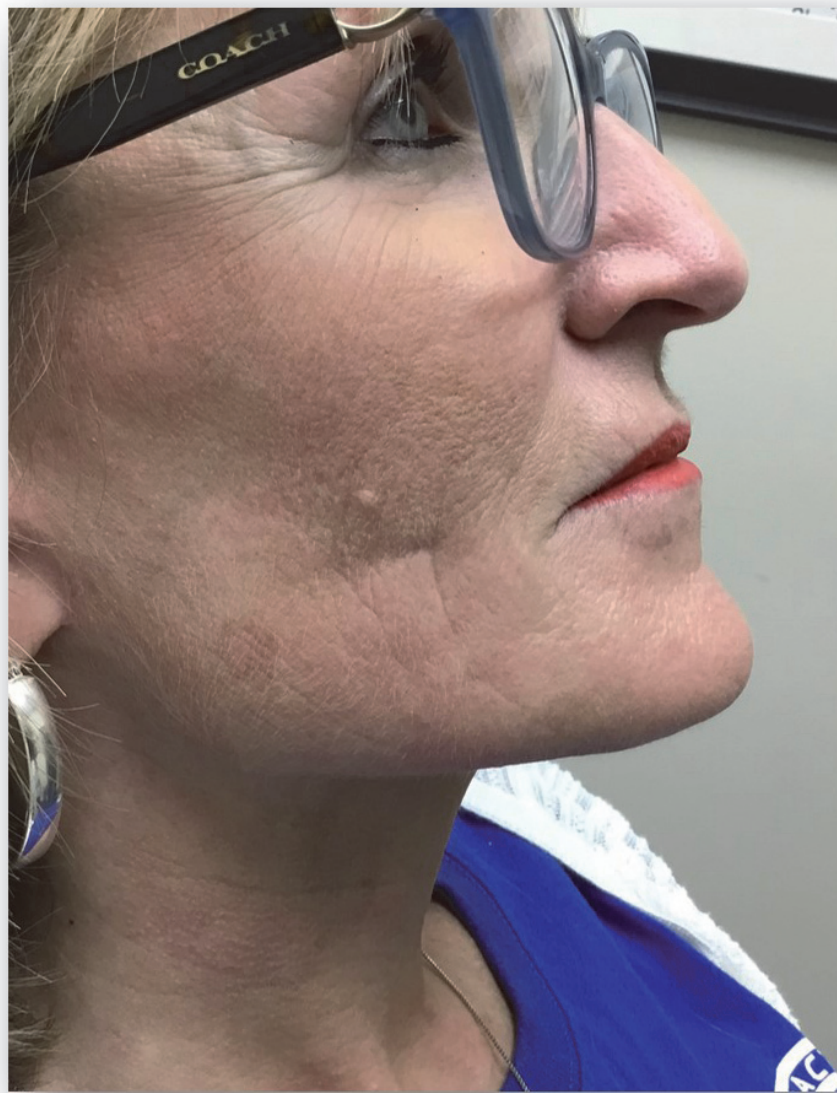

Figure 10. This thinned skin patient had a subdermal scar after placing the wand too close to her dermis. This required IPL, 1540 XF, PRP injections and filler injections to resolve this indented scar.

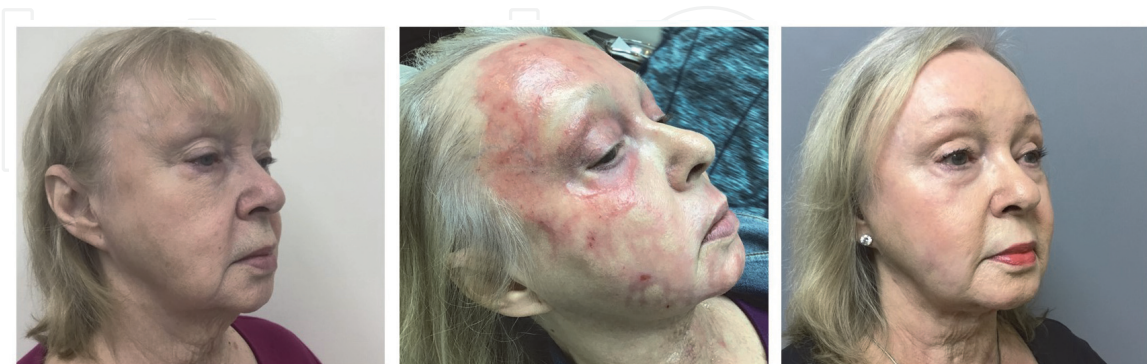

Figure 11. This patient suffered from redness and hypertrophic scars from too much mechanical irritation. Her scars developed 6 weeks post and were treated with IPL, 1540 XD, 1540 XF, injections of Kenalog 10, 5-FU, and PRP. The scarring has improved, but she has several permanent hypopigmented areas.

similar to a cheetah print. Most patients wake up after after 3 to 4 weeks and notice that the pattern has disappeared. Development of milia is common and frequent extractions may be necessary. Differen gel and Epi-duo can also help with the small white heads and milia that develop. This typically resolves after about 8–12 weeks.

5. Results

To achieve optimal results, appropriate patient selection for the various treatment applications is critical. If the patient has fat, it will need to be addressed. If the patient has significant redundant skin, a type of traditional lift will need to be performed with some skin excision. If rhytids are noted, the tool is diverse enough to perform fractional/pulsed or full ablative resurfacing causing a skin contraction and wrinkle reduction (**Figures 12–19**).

5.1 Subdermal with lipo

5.2 Subdermal renuvion with platysmaplasty

5.3 Facelift with subdermal renuvion and skin excision

5.4 Resurfacing results

The resulting contraction, lift and wrinkle reduction achieved with the Renuvion handpiece are evident in the before and after photos. In fact, the authors did not originally plan to pursue a study of this modality, but after noticing significant results when comparing before and after photos, they began measuring and compiling the data. Immediately following the procedure there is some swelling from the numbing and trauma that resolves during the healing process and over time continued contraction and neocollagenesis occurs.

Resurfacing results had a quantitative measurements as seen in **Figure 20**.

With aging, the cutaneous lip elongates and the pink portion of the lip deflates and starts to roll inward. Resurfacing the cutaneous upper lip causes the pink portion of the lip to become more oblique or more in a vertical direction on a planar view which decreases the appearance of a disappearing pink lip creating a plumper

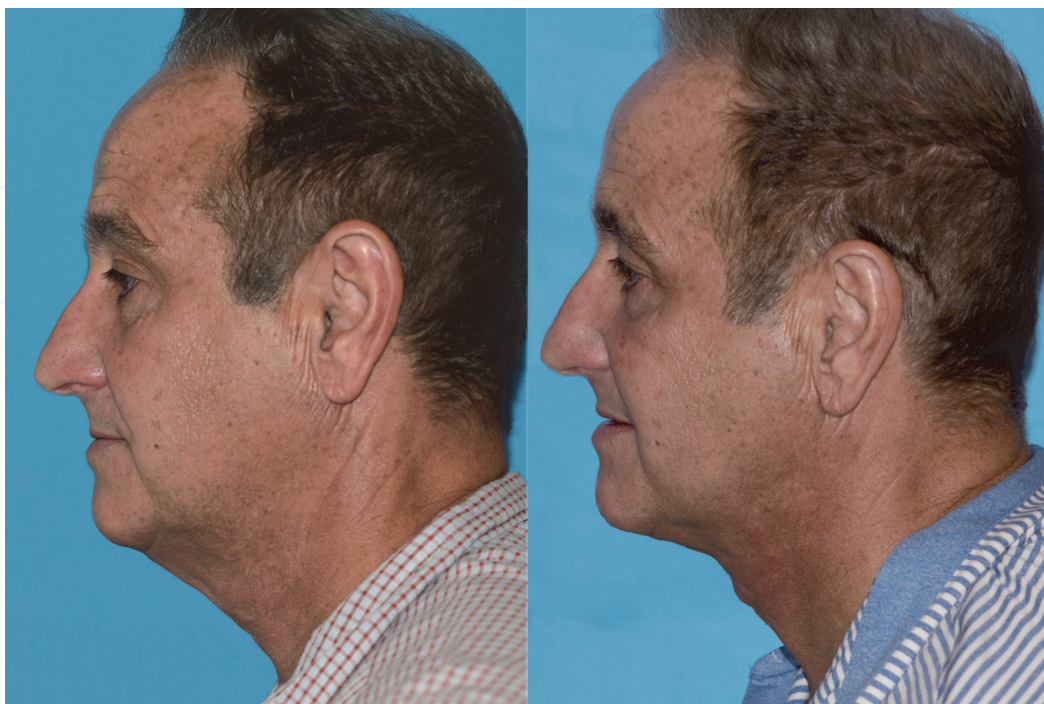

Figure 12.

This patient underwent an open platysmaplasty with subdermal renuvion, no skin removal, only infraauricular entry point incisions were made and communicated with a midline submittal incision through which the platysmaplasty was performed. - 1 year post op.

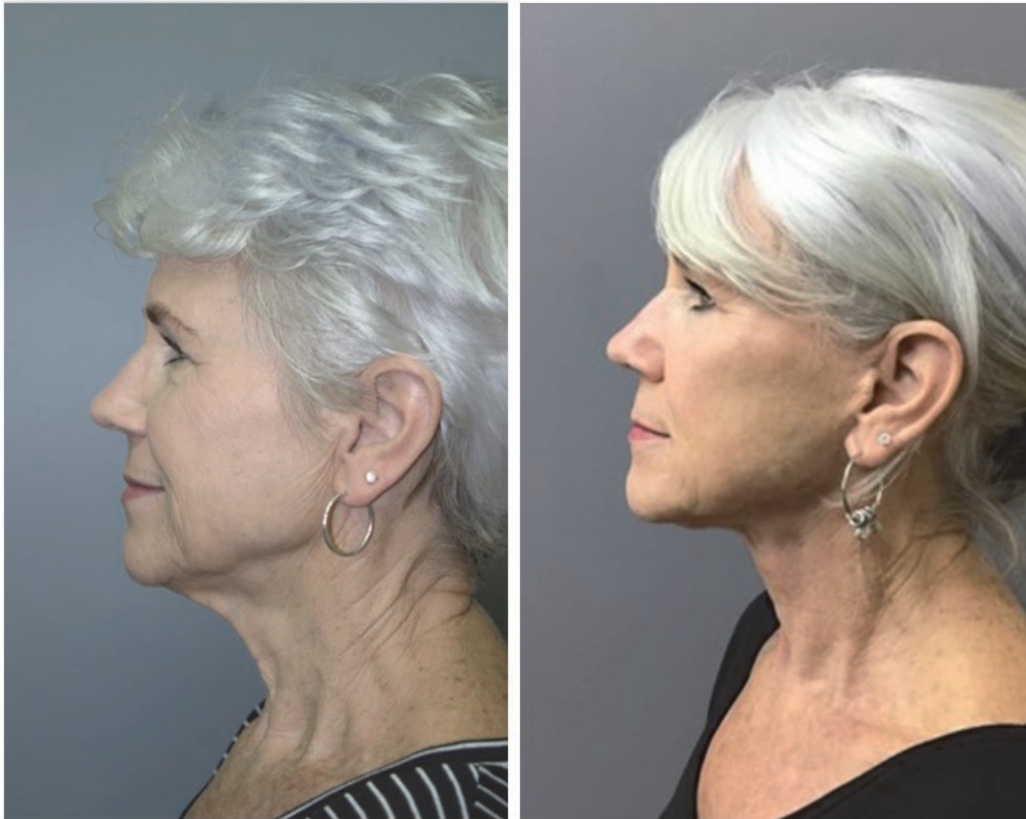

Figure 13.
This patient underwent a SubSMAS rhytidectomy with subdermal Renuvion - 2 year results.

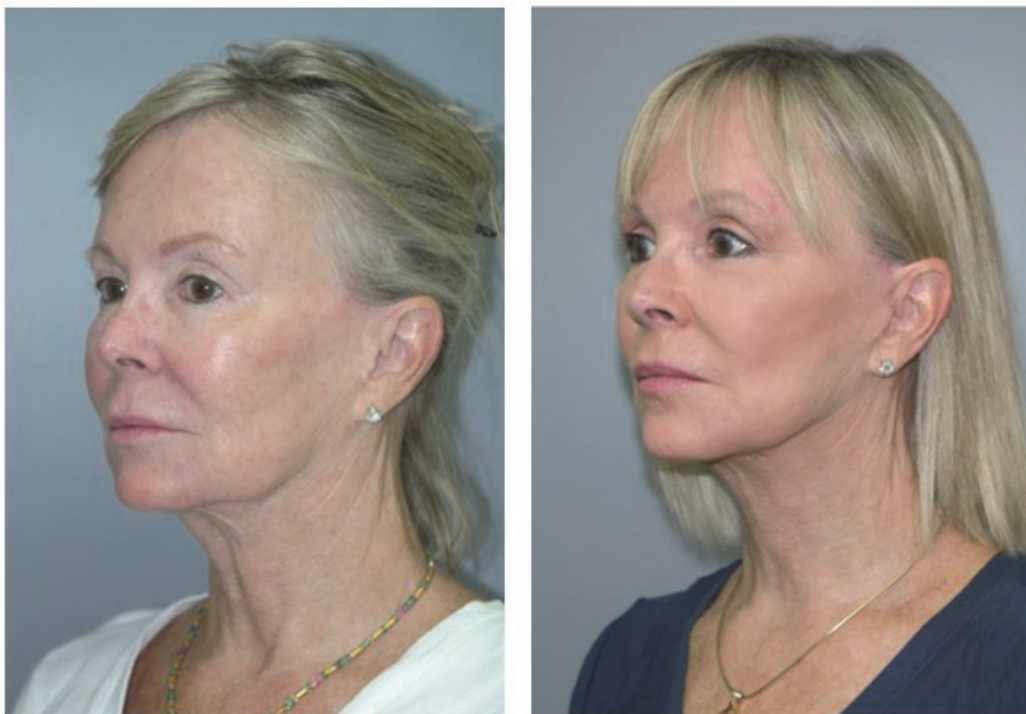

Figure 14.
This patient had a facelift 10 years prior and wanted a better neck and jawline. She had a subSMAS rhytidectomy with subdermal Renuvion on the neck and jawline and full face Renuvion resurfacing - 6 month results.

three dimensional upper lip. The same is noticed with the lower lip. The skin contraction that was noted has shortened the cutaneous portion of the lip which has proven to have longevity. The rhytids will almost disappear and the texture will improve. Some of the dynamic lines will return, but the lines at rest will resolve.

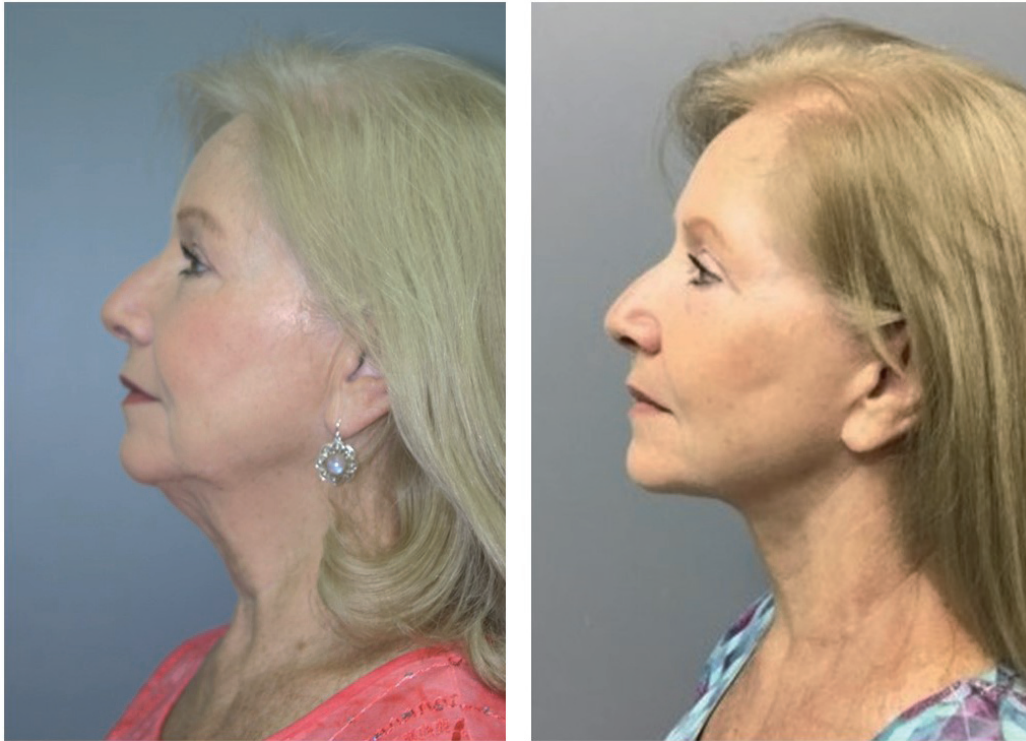

Figure 15.
This patient had Subsmas rhytidectomy with subdermal renuvion and lower blepharoplasty - 3 year results.

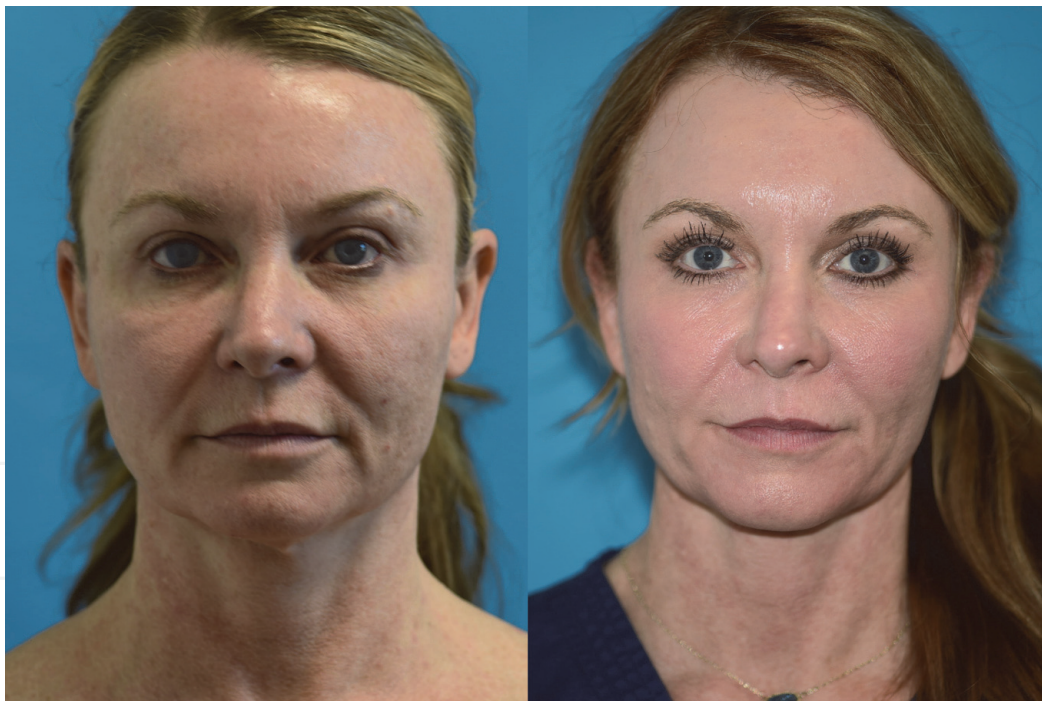

Figure 16.
This patient was treated with full face ablative resurfacing 1 pass 20% 4 L - 1 year result.

Table 2 demonstrates the improvement with lip lifting and the contraction has longevity over 1.5 years for 35 patients.

Particularly of note, the data shows that patients had an average lip contraction of 16.6% immediately following treatment, and one year later, the results remained essentially the same, with an average of 16.5%.

The forehead skin, upper and lower lids contract similarly to the upper cutaneous lip. The brow and the hairline actually move closer together especially at the

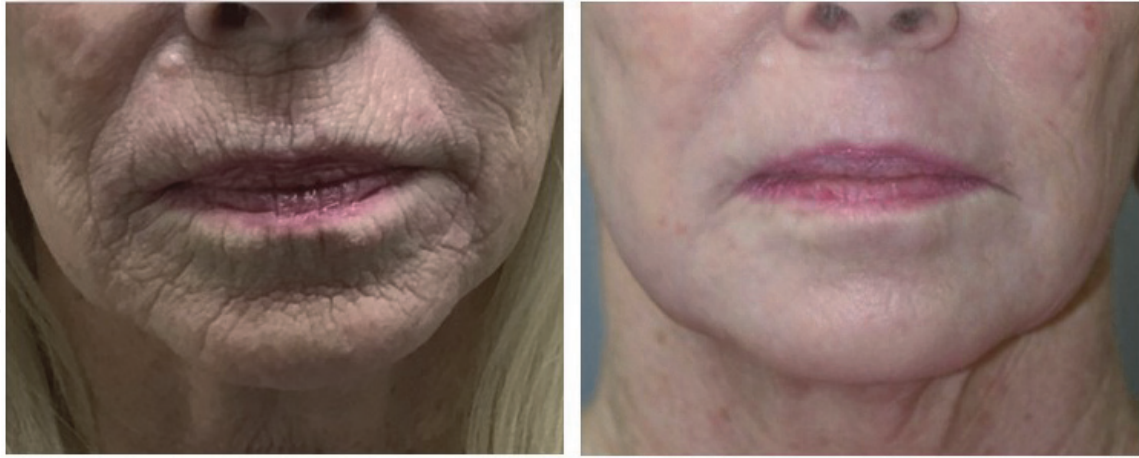

Figure 17.
This patient had deep wrinkles around her perioral and mid cheek area only. Two passes at 30% 2 liters were performed to the upper lip and one pass everywhere else. She has significant reduction of wrinkles and contraction of her upper lip. However, she does have mild hypo pigmentation. This is 2 year results.

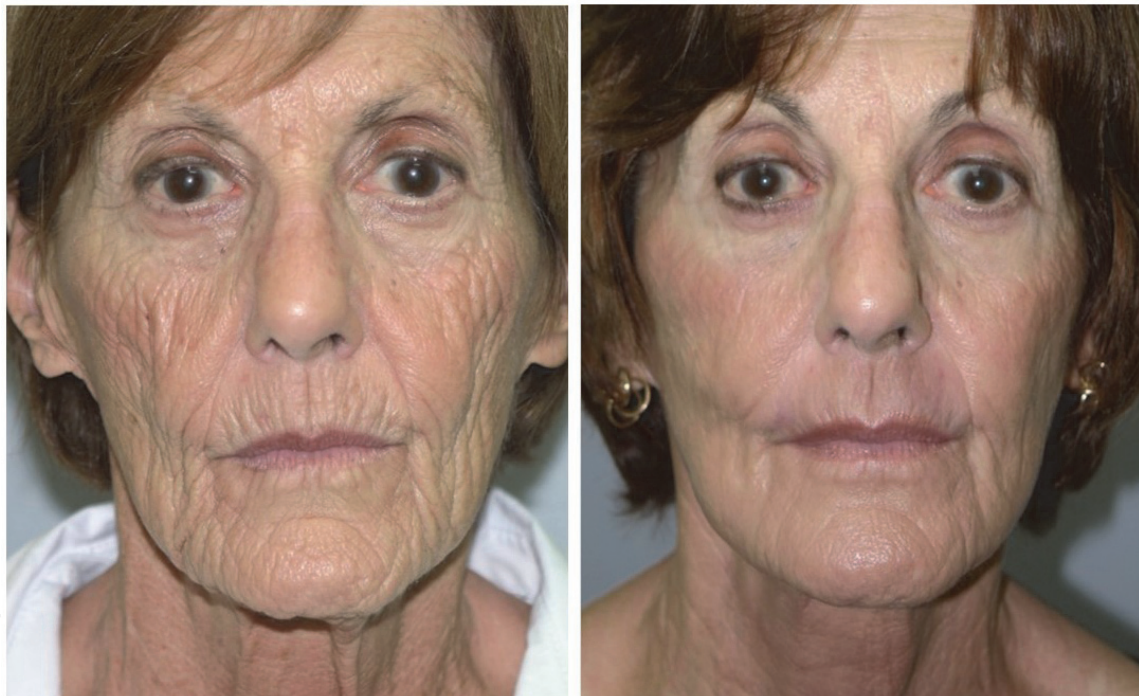

Figure 18.
This patient had minifacelift with fractional CO₂ laser to her cheeks and renuvion resurfacing to her upper lip only - 2 passes at 20% 4 liters. She is Fitzpatrick III and she did not have hypo pigmentation. These are 2 year results.

temple. The authors noticed a more natural brow lift than with endoscopic brow lifts. The deep, heavy glabella is lifted and the dynamic lines are reduced with longevity noticed without creating a widened midbrow. Minimal to moderate dermatochalasis of the upper and lower eyelids will resolve with this technique simulating a skin pinch. The horizontal lines of the forehead, oblique lines of the brow and crow's feet are significantly diminished (**Figure 5**).

Table 3 demonstrates the improvement of the lift in the brow and its longevity over 1.5 years for 35 patients.

Of note in this section is the continued improvement in contraction over time. Immediately following treatment the average contraction was 11.5%. However, a year later the average improvement was 35.4%, indicating continued contraction.

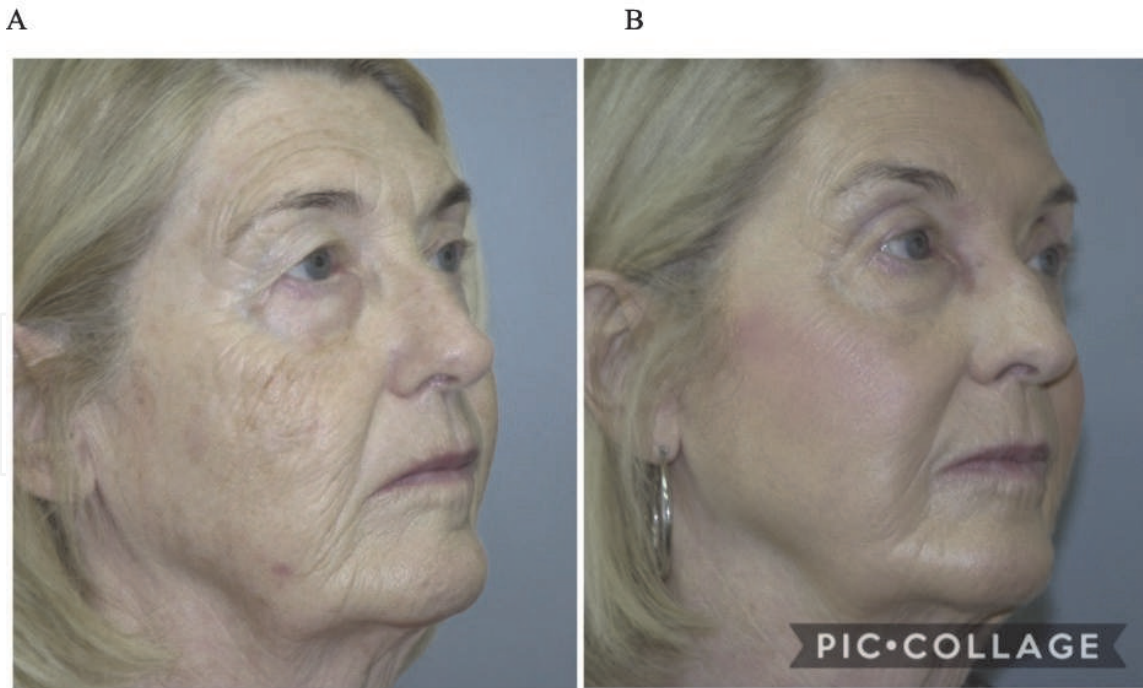

Figure 19.
This patient had cheeks, lateral brows, and upper lids only renuvion resurfacing - on pass 30% 4 liters which improved her jowls, deep wrinkles and skin texture.

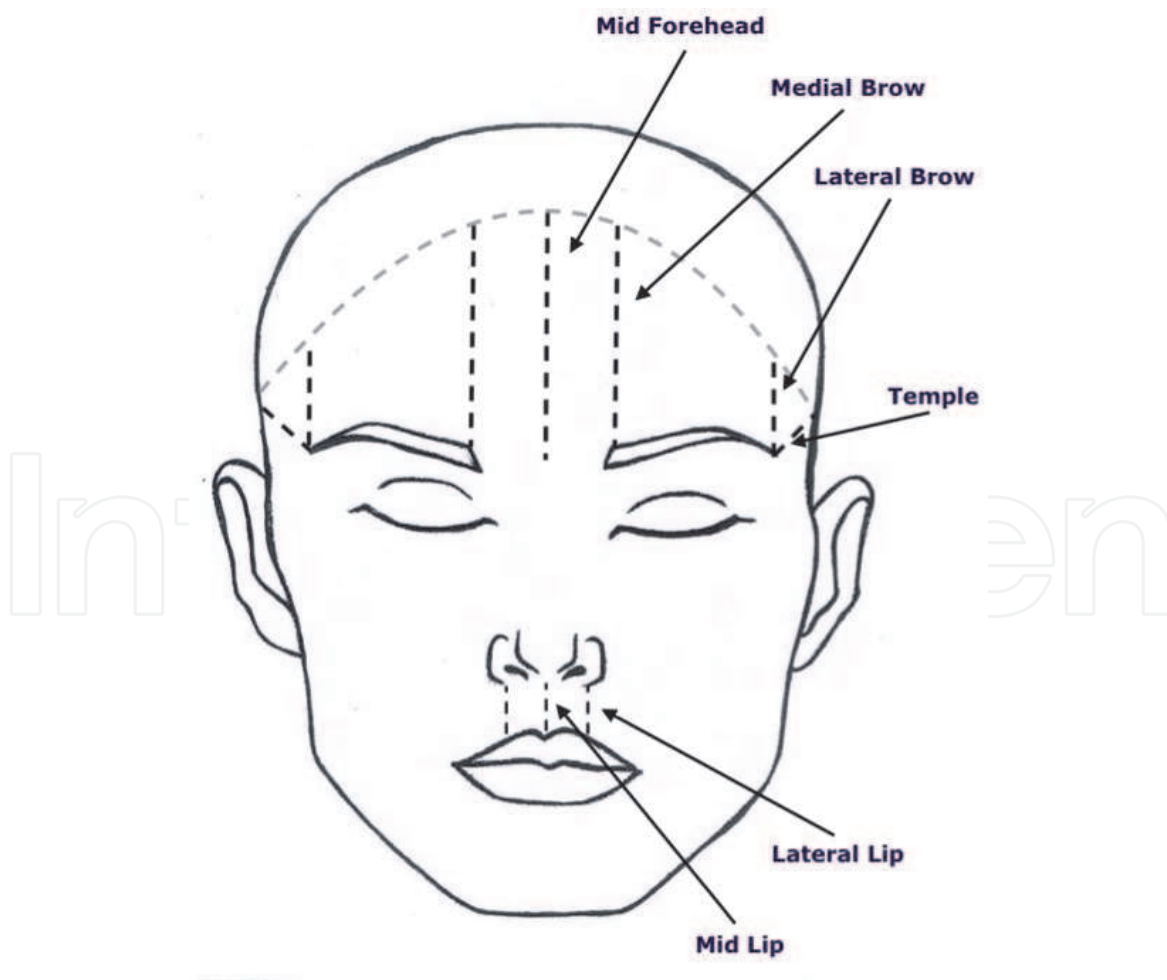


Figure 20.
Mid forehead - procerus line to the hairline at the mid forehead. Right and left medial brow - top of most medial brow hairs to hairline. Right and left lateral brow - top of most lateral brow hairs perpendicular to hairline. Right and left temporal brow - lateral brow obliquely to hairline. Mid upper lip - vermillion border to junction of columella and cutaneous lip. Right and left upper lip - vermillion border to junction of ala and cutaneous upper lip.

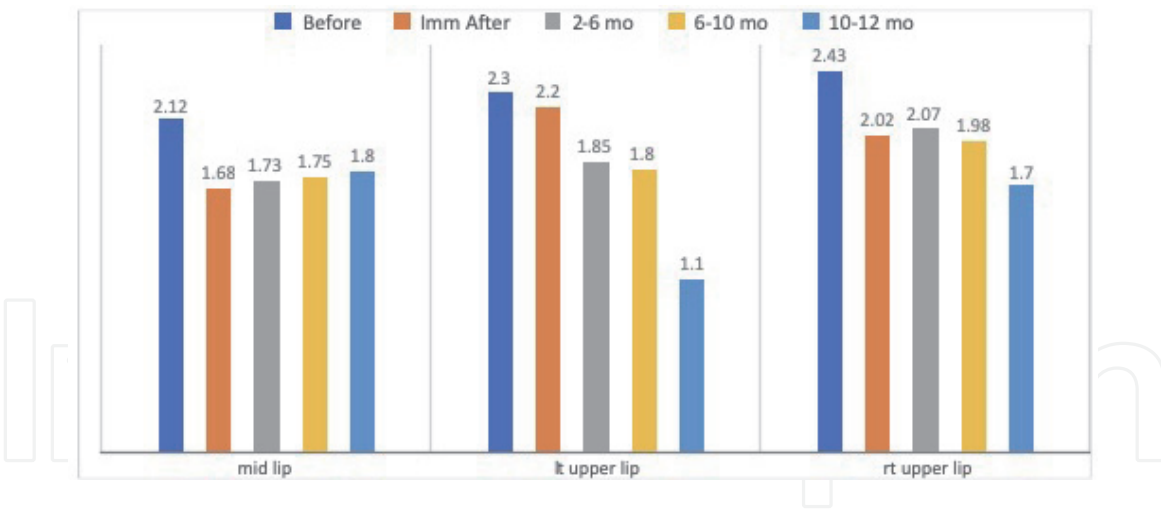


Table 2.
Lip data compiled by Abby Miller - medical student. The contraction of the upper lip has shown longevity.

FOREHEAD DATA POINTS

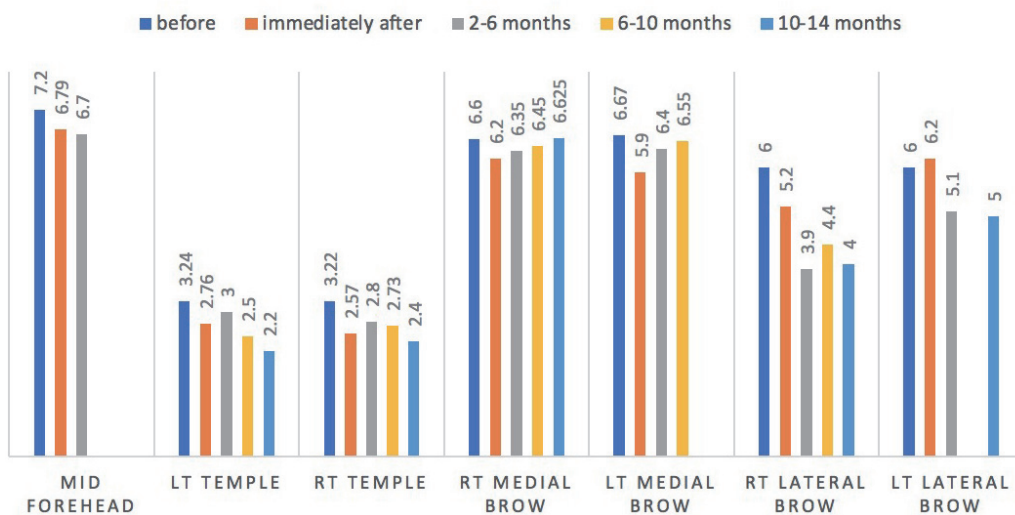


Table 3.
Forehead contraction has also shown longevity. Forehead data compiled by Abby Miller - medical student.

The overall texture and pore size is significantly improved after it has healed. The redness will take the longest to resolve and it fades in blotches. It seems to be worse for 3–4 months after a shower or after exercise. Lentigines have decreased in number and shade. There has been permanent hypopigmentation and demarcation noted which will be discussed later. Those patients are typically Fitzpatrick I and II and have thinner skin. Darker Fitz II and III have not had long term color changes in their skin.

6. Complications

The complication profile from the subdermal technique and resurfacing technique differ greatly and again is mainly operator dependent whether it be poor patient selection or poor user technique.

Fewer complications are seen with the subdermal techniques. Retained helium gas can cause crepitus, prolonged swelling, eye issues, and embolus. This is prevented by holding pressure at the cheek and at the clavicle to prevent extravasation. Massaging the gas out of the incision sites helps prevent swelling and crepitus. Placing enough small incisions sites to help the gas escape is key to decrease swelling or crepitus.

Placement of the handpiece too close to the dermis and or moving it too slow can cause an indented scar similar to an undulating acne scar as seen in **Figure 10**. This patient had a linear subdermal scar with volume loss similar to the undulating acne scars seen in patients. This was caused by using the device too close to the dermis. The scar resolved with repeated treatments of of intense pulsed light, 1540 deep Palomar treatment, plasma rich protein injections, and hyaluronic acid injection. The technique can cause such a contraction of the dermis or fibroseptal network that it can cause the skin to bunch especially when it is too loose. This can take a few weeks to resolve ultimately leading to continued excess skin.

One of the most frustrating complications is the dissatisfied patient from lack of results which is mainly seen in the subdermal technique. This was found more when no skin was excised or platysmal work was not done. Once again the key to optimal outcomes arises from choosing the appropriate technique for the appropriate patient and detailed preoperative counseling. Patients with thick skin that when pinched has a fast recoil and has thicker subcutaneous tissue seem to have a better result with skin tightening when used subdermally than those with loose crepey like skin.

When using this device as a resurfacing procedure, there are many more chances for complications. This cannot be stressed enough, this technology in both treatment modalities is operator dependent. Time on skin is of utmost importance. Going too slowly over the skin causes deeper thermal injury and will lead to scarring. Setting appropriate energy settings dependent on the different areas of the skin and the patient's skin type plays a role in determining if they are going to have sequelae from this procedure. If the patient has thin skin, they can have hypertrophic scarring and ultimately hypopigmentation. Thicker skin patients do better having less scarring. Hypertrophic scarring is seen frequently along the jawline, upper and lower lids in a linear fashion, temples, and the triangle at the melolabial area. This is noted more where time on skin has been too long or if a patient has scratched or rubbed the area as seen in **Figure 11**. Treatment of the scarring includes IPL, 5-FU injection, 1540 deep Palomar, Kenalog injection, saline injection, silicone sheeting. At least 50% of patients developed hypertrophic scarring somewhere on the face, but 95% of those patients had resolution of scar with treatment. Everyone recommends tumescence with lidocaine prior to treatment. However, the porcine studies by Apyx shows that the use of tumescence resulted in more depth of thermal effect. This raises concerns that the use of tumescence may increase depth of injury and may be a contributing variable for increased risk for hypertrophic scarring.

Hypopigmentation is more common with two passes and can occur if the energy is higher, which more deeply embedded wrinkles require. Sometimes PRP injections can help take the alabaster appearance away, but does not completely revert the depigmentation. Transient hyperpigmentation is noted typically in darker skin patients. This has not been permanent and resolves easily with topical vitamin C, sunscreen, and hydroquinone.

Milia and erythema is seen in every patient during the healing process. Some worse than others. Milia typically go away after a few months and with the help of extractions, low dose tretinoin, adapaline, and/or benzyl peroxide washes. Erythema can be intense for the first month. If it is prolonged, it typically leads to

hypopigmentation. Intense pulsed light, LED and infrared lights, and brief low dose topical steroids can help abate this. It seems to be worse after exercise or hot showers.

Itching is universal and very normal during the first and second week postoperatively and should abate. The more the patient rubs or uses ice, the itching worsens. Hydroxyzine works very well for this issue.

7. Conclusion

The Renuvion helium plasma facilitates rapid delivery of high intensity radio frequency energy with rapid cooling to tissue to achieve significant tissue contraction with diminished risk of thermal spread and collateral injury. This versatile tool has many powerful applications in rejuvenation of the head and neck and can be used both subdermally as well as for ablative resurfacing to accomplish significant skin contraction and wrinkle reduction. Deeply etched wrinkles will be erased and the skin contraction of the upper lip and forehead is worth noting. The subdermal application affords a lift of the jowls and neck without having to perform a deep plane lift which can cause skin bunching in temporal area when there is excess redundant skin. This technology requires a thorough understanding of how the energy delivery effects change to the tissue and is highly user and technique dependent. Once more research has been done regarding the settings - optimal energy, flow rates and number of passes based on patients' skin types, then a consensus of treatment methods can be decided.

Author details


Deirdre Leake^{1*} and Janet Lee²

¹ Facial Rejuvenation Centre, Saint Augustine, FL, United States

² Florida ENT and Allergy, Tampa, FL, United States

*Address all correspondence to: deirdreleake@hotmail.com

IntechOpen

© 2021 The Author(s). Licensee IntechOpen. This chapter is distributed under the terms of the Creative Commons Attribution License (<http://creativecommons.org/licenses/by/3.0>), which permits unrestricted use, distribution, and reproduction in any medium, provided the original work is properly cited. 

References

- [1] Population of the United States by sex and age as of July 1, 2019. Available from: <https://www.statista.com/statistics/241488/population-of-the-us-by-sex-and-age/> [Accessed: 9 February 2021]
- [2] Gentile RD. Laser-assisted facelifting and energy-based rejuvenation techniques during rhytidectomy. *Facial Plast Surg Clin N Am* 2020;28:379–396. DOI:10.1016/j.fsc.2020.03.006
- [3] Goldberg SN, Gazelle GS, Halpern EF, Rittman WJ, Mueller PR, et al. Radiofrequency tissue ablation: Importance of local temperature along the electrode tip exposure in determining lesion shape and size. *Acad Radiol* 1996;3(3):212–218.
- [4] Thomsen S. Pathologic analysis of photothermal and photomechanical effects of laser-tissue interactions. *Photochem Photo Biol* 1991;53(6):825–835.
- [5] Wright NT, Humphrey JD. Denaturation of collagen during heating: An irreversible rate process. *Annu Rev Biomed Eng* 2002;4:109–128.
- [6] Chen SS, Wright NT, Humphrey JD. Heat-induced changes in the mechanics of a collagenous tissue: Isothermal free shrinkage. *Journal of Biomechanical Engineering* 1997;119:372–378.
- [7] Duncan DI, Roman S. Helium plasma subdermal tissue contraction method of action. *Biomed Sci Tech Res* 2020;31(2).
- [8] Manuskiatti W, Fitzpatrick R, Goldman M. Long term effectiveness and side effects of carbon dioxide laser resurfacing for photo aged facial skin. *J Am Acad Dermatol* 1999;40(3):401–411.
- [9] Ward PD, Baker S. Long-term results of carbon dioxide laser resurfacing of the face. *Arch Facial Plast Surg* 2008;104:238–243.
- [10] Gentile RD, McCoy JD. Pulsed and fractionated techniques for helium plasma energy skin resurfacing. *Facial Plast Surg Clin N Am* 2020;28:75–85. DOI:10.1016/j.fsc.2019.09.007
- [11] Holcomb JD, Schucker A. Helium plasma skin regeneration: Evaluation of skin tissue effects in a porcine model and comparison to nitrogen plasma skin regeneration. *Lasers in Surgery and Medicine* 2019;10.