

# We are IntechOpen, the world's leading publisher of Open Access books Built by scientists, for scientists

5,600

Open access books available

137,000

International authors and editors

170M

Downloads

Our authors are among the

154

Countries delivered to

TOP 1%

most cited scientists

12.2%

Contributors from top 500 universities



WEB OF SCIENCE™

Selection of our books indexed in the Book Citation Index  
in Web of Science™ Core Collection (BKCI)

Interested in publishing with us?  
Contact [book.department@intechopen.com](mailto:book.department@intechopen.com)

Numbers displayed above are based on latest data collected.  
For more information visit [www.intechopen.com](http://www.intechopen.com)



## Chapter

# The Use of Cortical Bone Wedges from the Mandibular Ramus “Wedge Technique” for 3-Dimensional Bone Augmentation of the Atrophic Ridges

*Fares Kablan*

## Abstract

Autogenous bone is still considered the gold standard in bone augmentation for implant insertion in atrophic ridges. However, augmentation of multiple edentulous atrophic segments usually necessitates the use of extraoral donor sites. This chapter introduces the Wedge Technique, as a new bone augmentation method that can augment multiple edentulous ridges with intraoral cortical bone grafts. Patients with moderate to severe ridge atrophy in different regions of the jaws were treated with the wedge technique (WT). Patients received a panoramic radiograph immediately after the surgery, and they were examined clinically and radiographically (periapical radiograph) every 2 weeks. At four months, CBCT was performed to evaluate the bone gain. Reentry was performed after 4 to 5 months to evaluate the new bone volume and quality and to insert implants. The follow-up period ranged from 30 to 120 months. The healing process was uneventful, with minimal morbidity. The success rate was 95%, the bone gain average was 3–6 mm vertically and 3–9 mm horizontally. The wedge technique can augment multiple segments of atrophic ridges with a small amount of autogenous graft. The achieved bone volume was satisfying, especially that the majority of the augmented areas were at posterior mandibular defects.

**Keywords:** bone augmentation, autogenous bone grafts, allogeneic bone substitute, donor site, space maintenance

## 1. Introduction

Alveolar bone loss as a result of teeth extractions, periodontal disease, dentoalveolar trauma, pathologic conditions, failed implants, and failed bone grafting procedures may provide poor bone quality in height, width, and angulation which may result in impaired intermaxillary relationships. Ridge augmentation is considered in such cases to enhance the insertion of dental implants with good diameter and length at a proper prosthetic position. Several augmentation methods and materials have been successfully used during the last decades, but much controversy still exists [1–10].

Autogenous bone grafts are still considered as the gold standard not only because of their osteogenic, osteoinductive, and osteoconductive biological activities but also due to their safety and their excellent incorporation in the recipient bed. Common extra donor sites such as iliac crest, rib, tibia, and cranium are used and provide large quantities of cortical and cancellous bone. However, extraoral donor sites have several disadvantages that include the need for hospitalization and general anesthesia, prolonged healing time of donor site, concomitant morbidities, and visible scars [11–17].

Different intraoral donor sites are widely used as bone blocks or particulate bone. The most common intraoral sites are the symphysis and ramus/retromolar area [18–22], they have different degrees of morbidities and complications [23–27]. Non-autogenous bone grafts such as allografts, xenografts, and synthetic bone substitutes are widely used either alone or in combinations [28–34]. They eliminate the potential complications associated with autogenous donor sites and their availability is unlimited, however, they have osteoconductive characteristics and lack of osteoprogenitor cells.

The incorporation of the autogenous bone graft at the recipient site depends mainly on the amount of revascularization together with remodeling and substitution of the graft, which leads to the integration of the graft at the recipient bed [35]. There is a solid connection between osteogenesis and revascularization inside and around the graft [36]. Revascularization of the bone graft starts when blood vessels sprouts grow and go through the bone block. They originate from two sources; first, from the bone at the recipient bed, and second from the surrounding soft tissue. Hammack and Enneking in 1960 found that penetration of the blood vessels to the cortical graft was observed on the sixth day [37]. De Marco et al. in 2005 reported the timing and the penetration rate of the blood vessels into the autogenous bone block in rats. New capillaries had migrated from the surface of the recipient bed and penetrated the graft to different degrees [38].

Graft fixation plays a crucial role in cortico-cancellous bone grafts survival. Fixation screws are usually used to prevent micromovement of the augmented bone blocks at the recipient site, preventing and minimizing early graft volume loss and infections [4, 39, 40]. This chapter introduces a new bone augmentation method, Wedge Technique (WT) as a biological approach that utilizes the main advantage of autogenic bone which is transferring living cells, and the main advantage of the allogenic bone as well which is the availability and the unlimited quantities. The surgical procedures of WT, including bone block harvesting, wedge preparation, recipient site preparation, and the augmentation methods are presented in this chapter. The biological rationale, the healing process, and the advantages of the WT are explained and discussed.

## **2. Patients and methods**

Patients were referred by their surgeons due to different types and degrees of alveolar bone deficiencies, a lot of them result from failed implants or failed previous bone augmentation attempts. The majority of the cases had at least two sites at one or both jaws, and the majority of the sites were at the posterior mandible (**Table 1**). Inclusion criteria for the use of wedge-technique in the participants were: atrophic alveolar ridge with a bone deficit that needs vertical, horizontal or combined vertical and horizontal bone augmentation. The exclusion criteria were the severe atrophy of the mandibular retromolar area (the donor site); and patients with less than 3 mm bone over the inferior alveolar nerve at the posterior mandibular ridge.

Patient No.	Site's	Age	Sex	Augmented region	Available bone Height Width	Donor side		
1	1.1	48	F	44–47	4–5	1.2–2.4	RT	
	1.2			35–36	5–7			2.5–3
2	2.3	19	F	45–47	5.4–6.2	3.2–4.2	RT	
	2.4			35–37	7–9			3–4.5
3	3.5	28	F	13–23	10–12	1.5–2	RT	
4	4.6	63	M	43–47	8–18	1.5–2.5	RT	
	4.7			34–37	6–11			2–4
5	5.8	29	F	32–42	9–12	1.5–3	RT	
	5.9			44–47	6–10			2–6
6	6.10	54	F	44–47	4.5–9	2–3.2	LT	
	6.11			35–37	6–10			2.8–3.5
7	7.12	54	F	44–47	6–10	3–4	LT	
	7.13			35–37	6–8			4–6
8	8.14	49	F	33–43	16–18	1.8–2.4	LT	
	8.15			36–37	8–10			1–2
9	9.16	63	M	35–37	7–9	2.5–5	LT	
10	10.17	55	M	34–37	6–8	3–7	LT	
11	11.18	47	F	34–37	5–7	2.4–4	RT	
	11.19			45–47	5–8			2.8–4
12	12.20	56	F	13–17	6–11	1.5–2.5	RT and LT	
	12.21			23–27	7–12			1.5–3
	12.22			43–47	8–18			1–3
13	13.23	19	M	23–27	8–11	2.5–3.5	RT	
14	14.24	39	F	43–47	5–7	6–8	LT	
	14.25			34–37	5–7			6–8
15	15.26	62	M	15–25	10–13	1–2	RT	
16	16.27	67	M	34–36	5–7	2.4–4	LT	
	16.28			44–47	5–8			2.9–4
17	17.29	51	F	46–47	3–5	6	RT	
	17.30			36–37	3.5–7			6
18	18.31	30	F	12–15	8–11	2.5–3	RT	
	18.32			33–43	14–18			2–3
19	19.33	44	F	13–23	8–13	1.8–2.7	RT	
	19.34			46–47	4–5			2–3
	19.35			34–37	6–7			3–4.5
20	20.36	54	F	44–47	3.5–4.8	4–5	RT	
	20.37			35–37	4.6–5.2			3–6
21	20.38	57	F	26–27	4–6	2–4	LT	
22	22.39	53	M	35–37	8	2–4.5	LT	

**Table 1.**  
*Patients demographics, augmented sites, and the donor sites.*

Patients with informed consent underwent bone augmentation with the WT at least at one site in different arch regions. The retromolar/ramus area was the donor site of the bone cortical wedges of this technique. Post-operative instructions included a soft diet for six weeks, antibiotics for ten days, and meticulous oral hygiene. In addition, the use of removable appliances was not allowed.

Follow-up examinations were performed every 2 weeks. Four months after the surgery, the recipient site was evaluated clinically (to assess the contour and the volume of the augmented ridge), and radiographically (by computed tomography) to examine the bone gain and the new available bone for dental implant placement. Reentry was performed after 4 to 5 months to evaluate the new bone volume, to obtain biopsy specimens and to insert implants. The prosthetic rehabilitation was allowed 4 months after the placement of the dental implants. Follow-up of the bone augmentations and implants that were inserted at these sites, included periodic clinical evaluation and periapical radiographs. All the surgical procedures and postoperative evaluations were performed by the author.

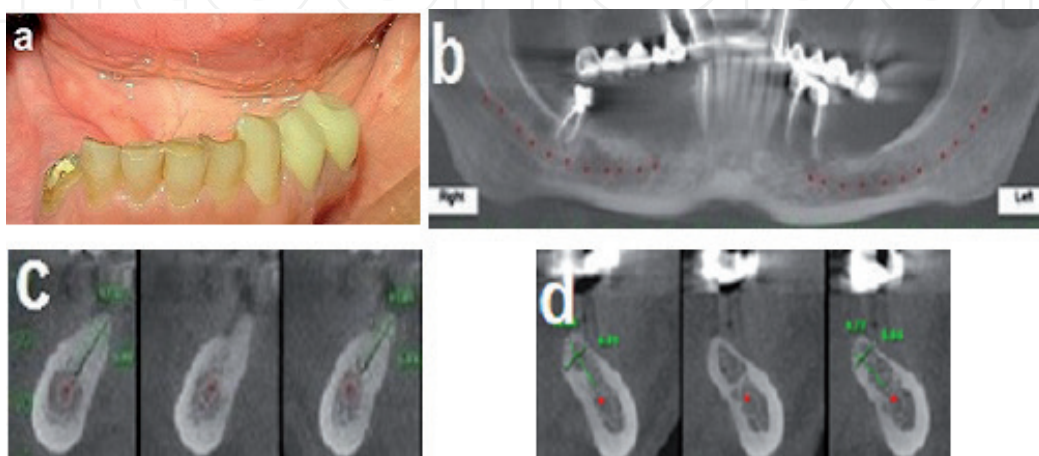
## 2.1 Technique

Illustration case; 55 years old female was referred to the pre-prosthetic unit at our department for bone augmentation of her posterior mandible bilaterally and placement of dental implants. On examination; a healthy patient presented with bilateral posterior mandibular edentulism (Kennedy class-1).

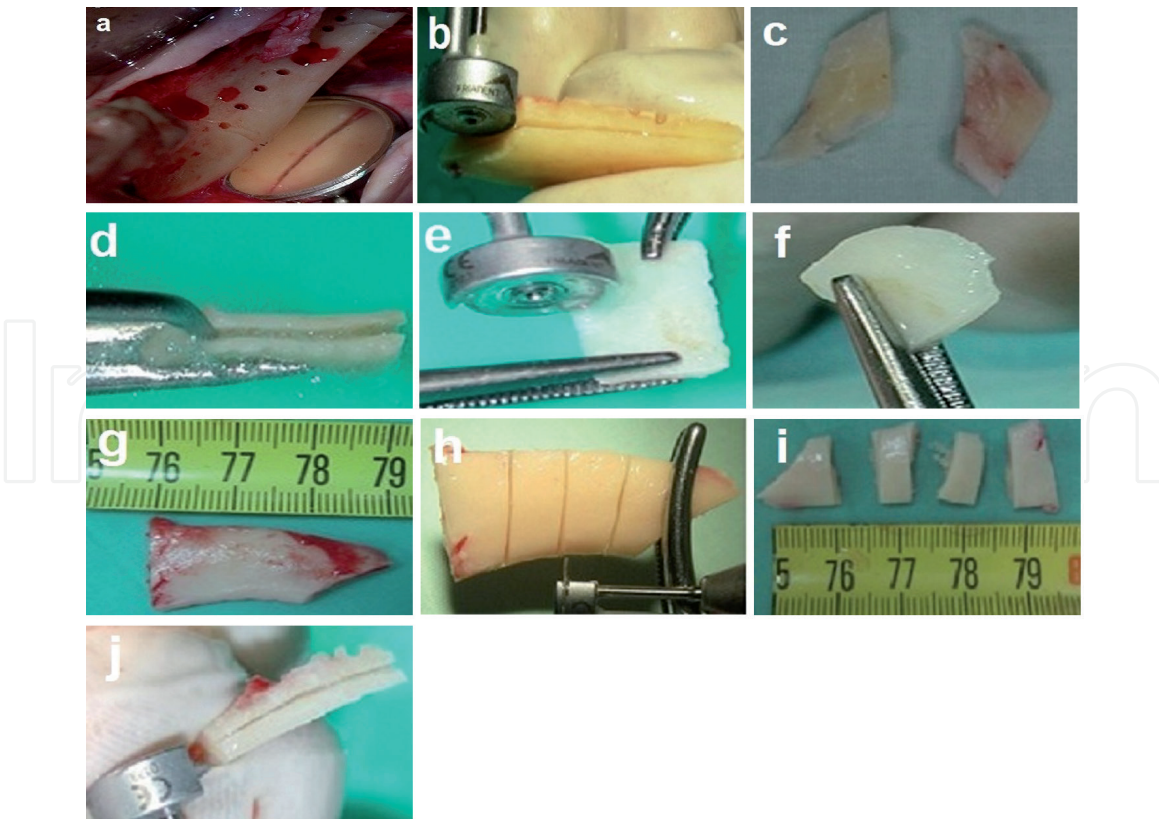
Both of the residual ridges had more than 20 degrees of bone angulation toward the lingual side (**Figure 1a**). CBCT showed moderate to severe atrophy of both posterior mandibular ridges (**Figure 1b–d**). Short implants were not an option due to the severe lingual angulation, and inadequate bone width of the residual ridges. Guided implant placement was not a treatment option as well due to the central location of the inferior alveolar nerve. This case necessitated bone augmentation and was treated with the WT.

## 2.2 The donor site

Retromolar/ramus region is the gold standard of this technique. It can provide cortical bone blocks of 3-4 mm thickness, 2–3 cm length, 8-12 mm width (height). In the present case, the left retromolar area was the donor site. Under general anesthesia, administration of IV Augmentin 1 gr, Iv Dexamethasone 20 mg, and



**Figure 1.** Bilateral edentulous posterior mandibular ridges. (a) Clinical view. (b–d) Computed tomography shows inadequate bone in height, width, and angulation.



**Figure 2.**  
*The donor site and the Wedge preparation. (a) The bone block harvesting from the left retromolar area. (b–f) Multiple splitting of the bone blocks results in multiple small bone wedges. (g–j) Transverse splitting of the harvested bone block, as an additional option to create the bone wedges.*

local anesthesia with a vasoconstrictor. A full-thickness mucoperiosteal flap was reflected with mid-crestal incision distal to the second premolar. The incision was extended through the retromolar region and the external oblique ridge to the ramus. An anterior release incision was performed at the first premolar and extended to the vestibular depth. This flap exposed the left augmented site (teeth 36 and 37 region), and the donor site of the bone block. In addition, it allowed visualization of the lateral and inferior border of the mandible, the buccal shelf, and the mental neurovascular bundle. The length (posterior–anterior) of the bone block, the width (superior–inferior) were determined and done by three complete osteotomies; posterior, anterior, and inferior (**Figure 2a**), using a micro-Saw (Dentsply Friudent, Mannheim, Germany). The superior (crestal) edge was perforated with small holes by small round bur in a straight hand-piece, those holes determined the thickness of the bone block. The block harvest was completed by a straight osteotome that was tapped along the superior holes. The block was carefully released and removed to avoid injury to inferior alveolar neurovascular bundles, and the donor site was left for spontaneous regeneration.

### 2.3 The wedge preparation

The wedge preparation was made by multiple splittings of the harvested bone block. In the present case, the bone block splitting was performed in the direction of the longitudinal axis, the first split yielded two thinner bone blocks, and further splitting at the same axis gave 4 thin bone blocks from the original bone block (**Figure 2b–d**). Further transverse splitting of the four thin bone blocks provided 8–10 thin bone blocks and each one is called “bone wedge” (**Figure 2e and f**). However, the splitting of the harvested block can be also made at the transverse axis

of the block to obtain four thick bone blocks. Further splitting of those blocks at their long axis can give 8–10 thin bone wedges (**Figure 2g–j**).

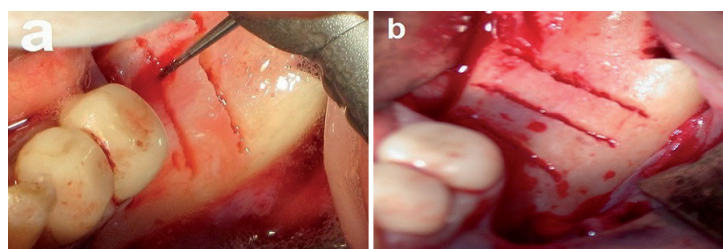
## 2.4 Recipient site

The left recipient site was already exposed for bone block harvesting. The augmented bed was prepared by making grooves (slots, fissures) with either high speed straight thin bur, low speed small straight bur, or by the saw-shaped piezo-surgery device, therefore, at the recipient site, three buccolingual grooves were made (**Figure 3a and b**). The number of the grooves is determined by the length of the augmented ridge, on the other hand, the depth of the grooves is limited by its distance from the inferior alveolar nerve which is measured on the dental CT scan. In general, the groove should be extended all the way from the buccal cortices to the lingual cortices, and as deep as possible in the recipient site residual bone. The main role of the groove in the WT is to give biological and mechanical retention of the bone wedge.

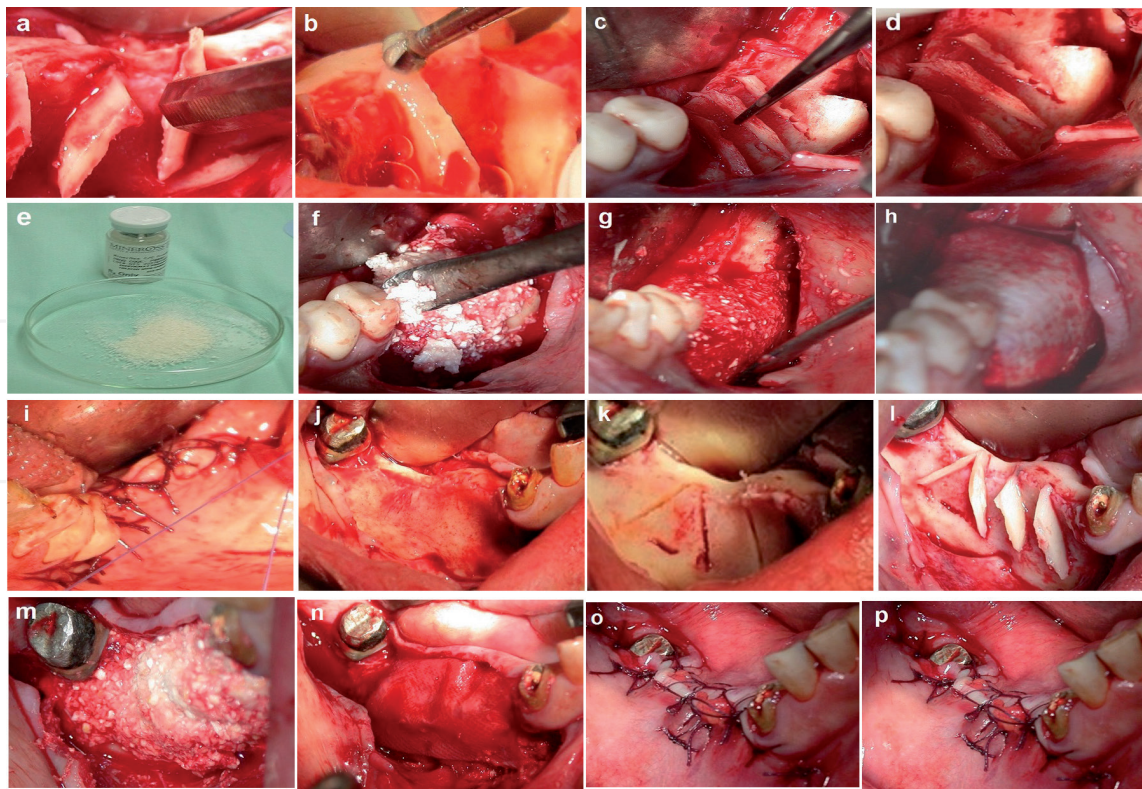
## 2.5 The augmentation procedure

Try-in of the bone wedges into the grooves at the recipient bed was performed in order to adapt one bone wedge to each groove. Thereafter, one wedge was inserted and taped into one groove using a flat edge cylindrical instrument and hummer (**Figure 4a**). It was extremely important to check the stability of each wedge by trying to extract it out from its groove; an unstable wedge should be removed and replaced by a stable one. This procedure is the fixation method of the bone wedge to the recipient site. The next step was the trimming and rounding of the sharp edges of each wedge in order to prevent trauma to the soft tissue overlying the augmentation (**Figure 4b and c**), consequently, multiple bone compartments were achieved (**Figure 4d**). The next step was packing those compartments with allograft particulate bone substitutes (**Figure 4e and f**), the desired bone volume was achieved (**Figure 4g**), subsequently the bone graft was covered with a resorbable membrane (**Figure 4h**). A tension-free closure of the flap was performed (**Figure 4i**), utilizing a free buccal fat pad graft was used to enhance flap closure. The right side of the mandible was augmented using 4 bone wedges, with the same sequence that was performed to augment the left side (**Figure 4j–o**).

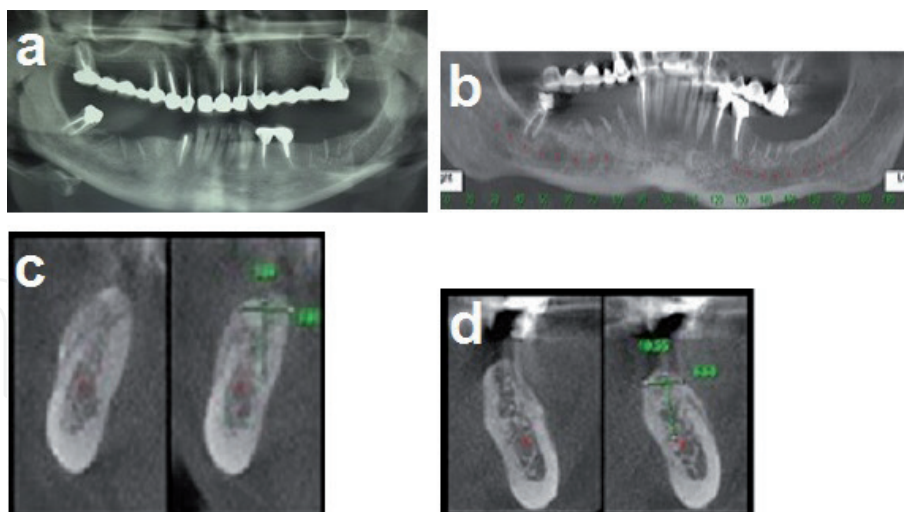
The follow-up was performed every two weeks for the first six weeks, and once a month later on (**Figure 5a**). After 4 months the patient underwent a dental CT scan (CBCT) to evaluate the amount of bone gain that was achieved from the augmentation procedure (**Figure 5b–d**), then dental implants were inserted under local anesthesia (**Figure 6**). Three to four months later the patient was referred for prosthetic rehabilitation (**Figure 7a and b**). This case has been followed up for 120 months (**Figure 7c–e**).



**Figure 3.** The recipient site. (a) Grooves are created by height speed, low speed or piezoelectric. (b) Three grooves were created at the recipient site.



**Figure 4.**  
 The bone augmentation procedure. (a) Insertion and tapping of the bone wedges inside the grooves. (b) Trimming of the sharp edges of bone wedge. (c) Stability checking of the bone wedge inside the groove. (d) Bone compartments at the recipient site. (e) The bone filler, allograft particulate bone. (f) The filling of the bone compartments with the allograft particles. (g) The obtained final bone volume. (h) The resorbable membrane covering the bone graft. (i) Tension free closure of the augmented site. (j–o) Bone grafting of the patient's right side with the WT.



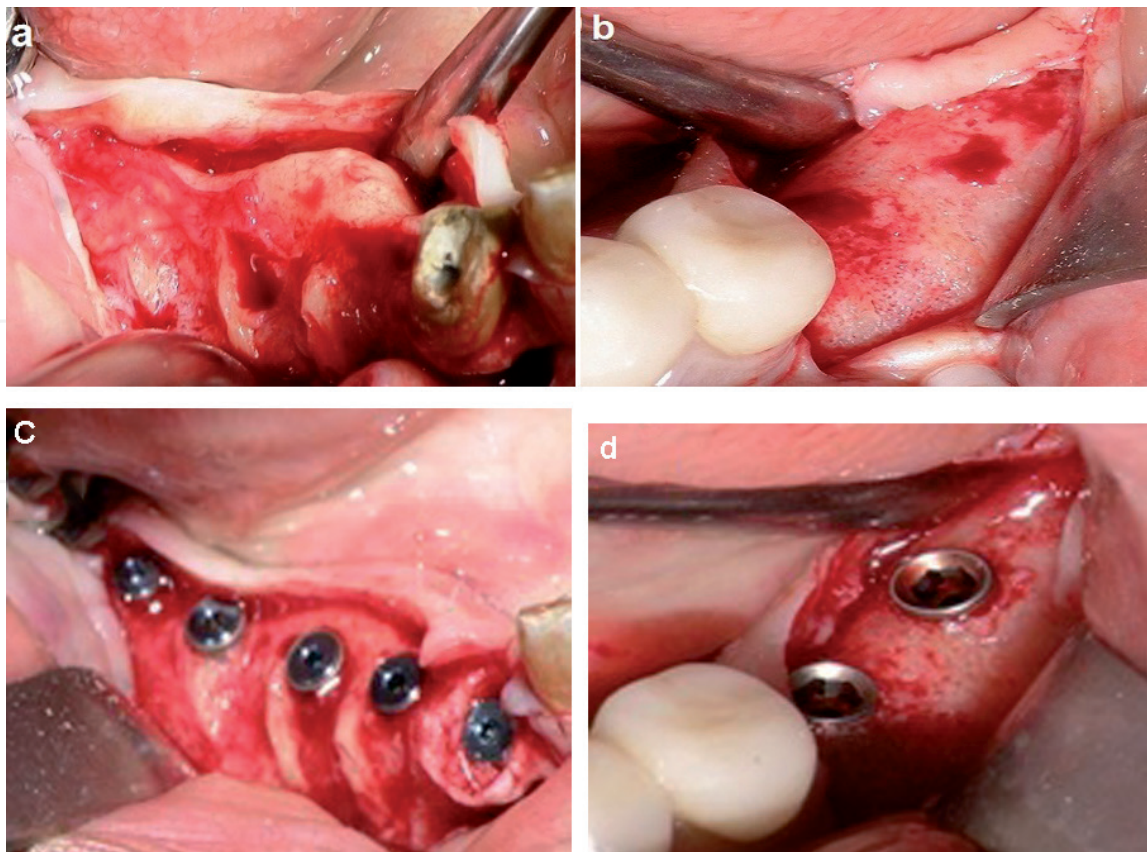
**Figure 5.**  
 Follow-up after two weeks. (a) The post-op panoramic view demonstrates one donor site and two recipient sites. (b–d) Computed tomographic views demonstrate the new bone that was obtained.

## 2.6 Case presentations

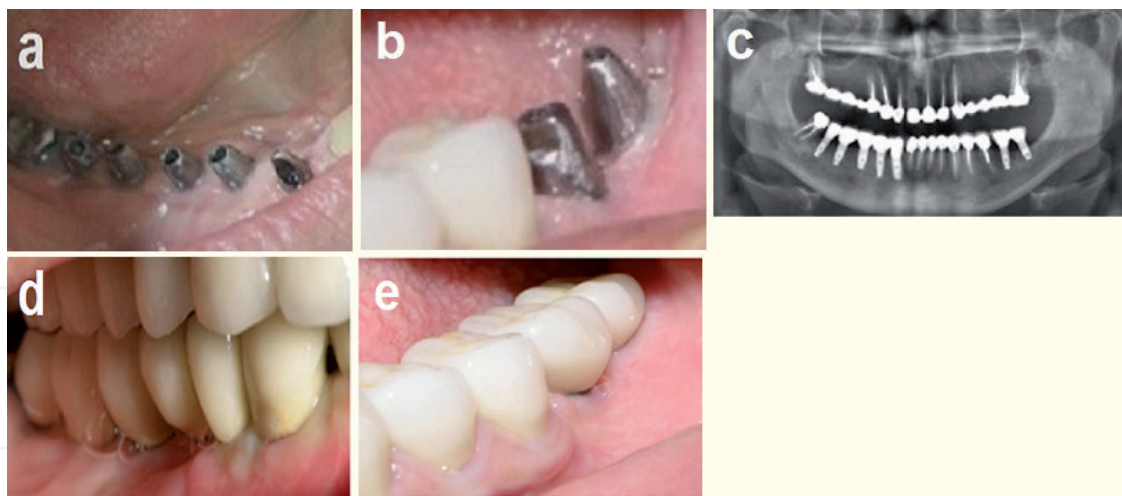
### 2.6.1 Case 1

A 45-year-old woman was referred to our department to augment atrophic ridges at the anterior and left posterior mandible. On examination, partial edentulism of the mandible with missing anterior and left posterior teeth



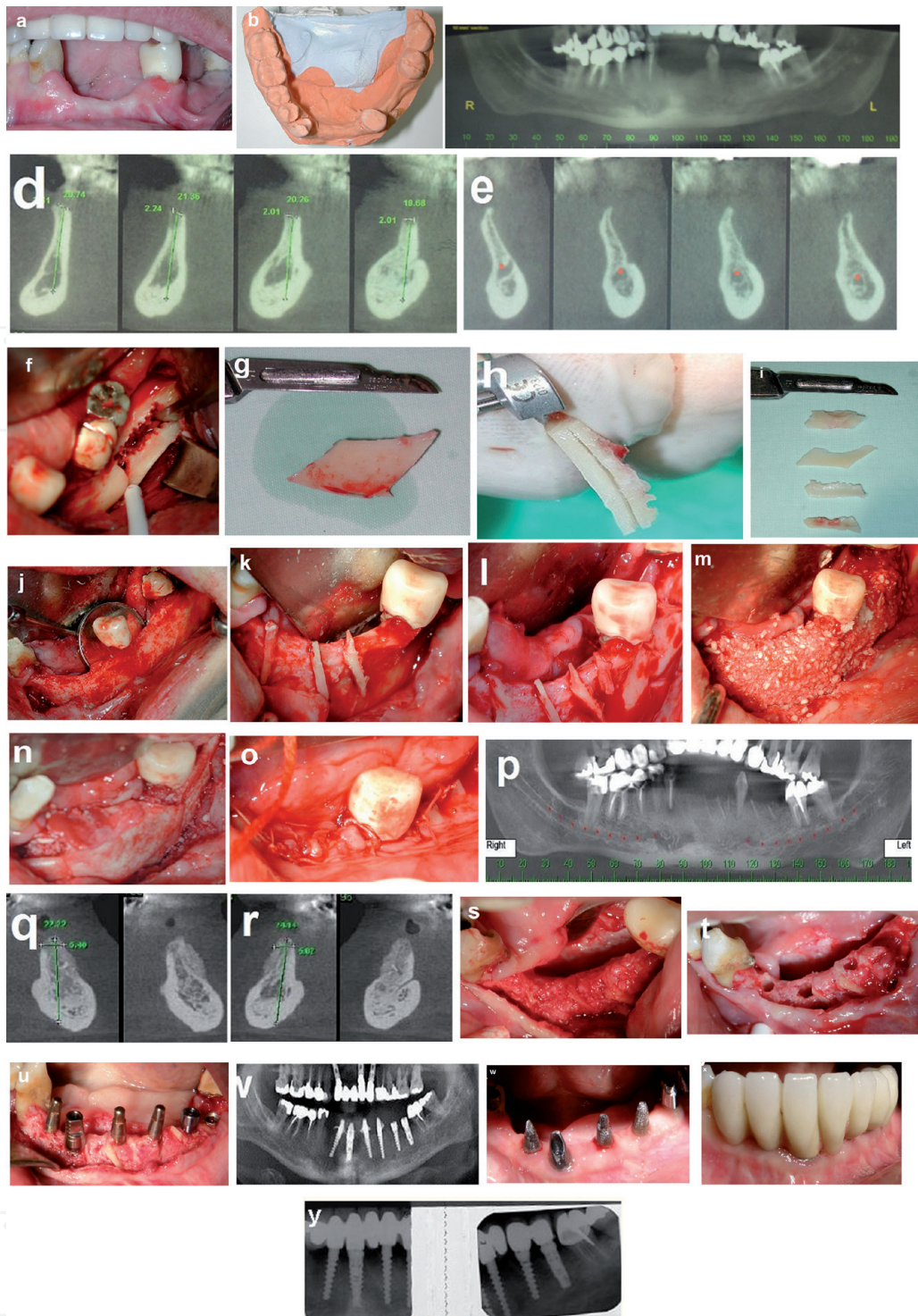


**Figure 6.**  
*Reentry after 4 months and implant placement. (a) Shows good bone regeneration after 4 months at the right side. (b) Shows good new bone volume at the left side. (c and d) Implants placement.*



**Figure 7.**  
*Rehabilitation and follow up. (a and b) Implant abutments. (c-e) Panoramic radiograph and clinical view 60 months after the surgery.*

(43–33 and 35, 36), moreover, the left and right first premolar were with poor prognosis (**Figure 8a–c**). Computed tomography was performed and demonstrated the bone deficit at the anterior and left mandible (**Figure 8d and e**). The patient had been treated in two stages; at the first stage, WT was performed to augment the anterior and left mandibular regions. Under general anesthesia the bone block was harvested from the left retromolar area (the same surgical site), then was split to obtain the bone wedges (**Figure 8f–i**). The recipient sites were prepared by creating grooves, consequently, 7 bone wedges were inserted into the grooves in a stable



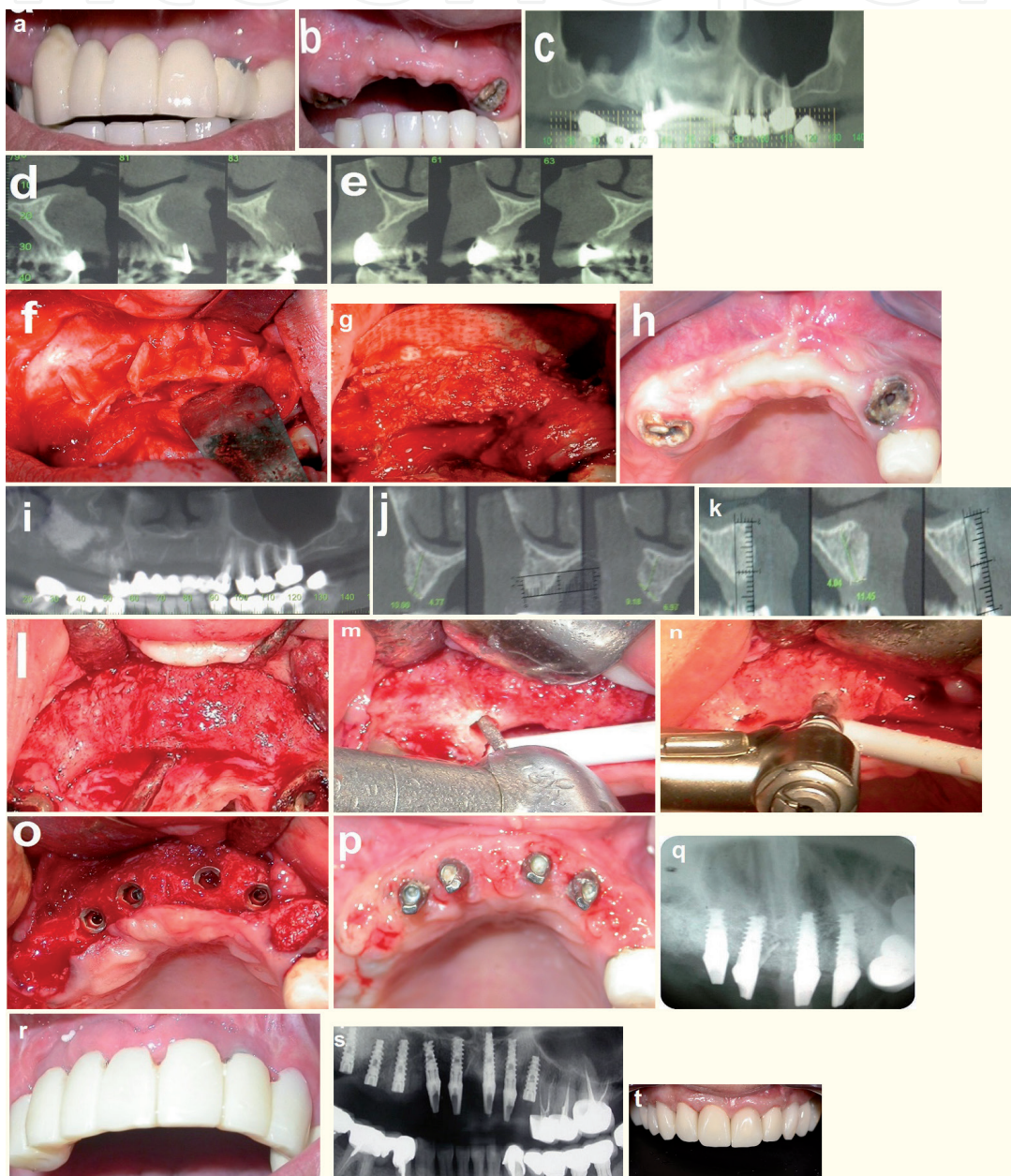
**Figure 8.**  
 Case 2. (a–e) Clinical and radiographic view of the mandible. (f–i) Bone block harvest and the preparation of the bone wedges. (j–o) WT bone augmentation at the anterior and the left mandibular ridges. (p–r) Computed tomography 4 months after bone grafting. (s–u) Reentry and implant insertions 4 months after the augmentation surgery. (v) Radiographic view-follow up of the implants. (w and x) Crowns rehabilitation. (y) 72 months follow-up.

position and several bone compartments were achieved (**Figure 8j–l**). Then, the compartments were filled with particulate allograft bone substitute, obtaining the desired bone volume (**Figure 8m**), which was covered with a resorbable membrane (**Figure 8n**), and tension free closure of the recipient site was performed (**Figure 8o**). A temporary bridge based on left and right first premolars was placed. The healing process was uneventful during the follow-up period, after 4 months a Computed dental tomography was performed and demonstrated the bone gain

which was 4–6 mm horizontally and vertically (**Figure 8p–r**). At the second stage, the reentry to the augmented sites revealed new bone volume, and integration of the bone wedges into the new bone mass (**Figure 8s**), thereafter, 6 implants were inserted with immediate loading (**Figure 8t–v**). All implants were successfully osseointegrated (**Figure 8w and x**) and the final rehabilitation was performed after 3 months (**Figure 8y**). This case is followed for 72 months (**Figure 8y**).

### 2.6.2 Case 2

A 28-year-old woman was referred complaining of severe atrophy of the anterior maxillary region; after a failed bone augmentation procedure which was done by her



**Figure 9.**  
 Case 2. (a and b) Clinical view-anterior maxilla. (c–e) Computed tomography of the anterior maxilla demonstrates the severe atrophy of the residual ridge. (f–g) The WT bone augmentation, intraoperative views. (h–k) Clinical and radiographic views at four months after the surgery. (l) Reentry 4 months after the surgery demonstrates nice bone regeneration. (m and n) Show the drilling for the implants that was performed through the bone wedges. (o) 4 implants were placed at the recipient site. (p and q) Clinical and radiographic view at 4 months after implant placement. (r and s) Temporary rehabilitation follow up 5 months after implants insertion. (t) 60 months follow-up after the surgery, fixed prosthesis supported by dental implants with excellent outcomes.

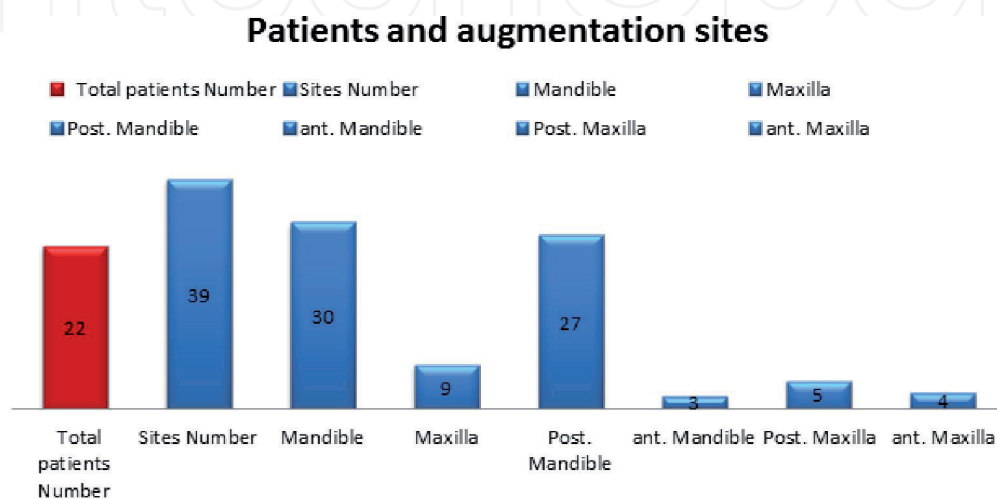
surgeon. Clinical and radiographic examinations revealed severe atrophy of the anterior maxillary ridge and pneumatization of the right maxillary sinus (**Figure 9a–e**). She was treated in three stages; bone augmentation of the anterior maxilla with the wedge technique, extraction and socket augmentation of the right second premolar, and right maxillary sinus augmentation. The right mandibular retromolar area was the donor site for the bone block, after splitting the bone block, 7 bone wedges were obtained. Four cortical bone wedges were inserted at the grooves that were prepared at the recipient site (**Figure 9f**). Then, particulate allograft bone substitute was used as the bone filler between the bone wedges (**Figure 9g**). The right maxillary first premolar, and the left maxillary canine were temporarily preserved to hold an acrylic bridge during the healing phase. Follow-up examinations at months showed excellent recovery (**Figure 9h**) and CBCT showed the new bone gain and the available bone (width; 6 to 10 mm) for implant insertion (**Figure 9i–k**). At the stage-two surgery, the intraoperative views showed a good regeneration, and the bone wedges had excellent integration in the new bone volume (**Figure 9l**). **Figure 9(m)** and **(n)** demonstrate the drilling through those wedges indicating their stability and viability.

At the same stage, the right maxillary first premolar, and the left maxillary canine were extracted with socket augmentation. In addition, 4 implants were placed at the anterior augmented region (**Figure 9o**) with immediate loading. **Figure 9(p)** and **(q)** show clinical and radiographic view one month after implant placement. At stage-three surgery, additional 4 implants were placed; 3 at the right maxilla and one implant at the left maxillary canine. Four months later the patient was referred to her dentist for a fixed prosthesis over the implants (**Figure 9r** and **s**). This patient had been followed for 60 months (**Figure 9t**).

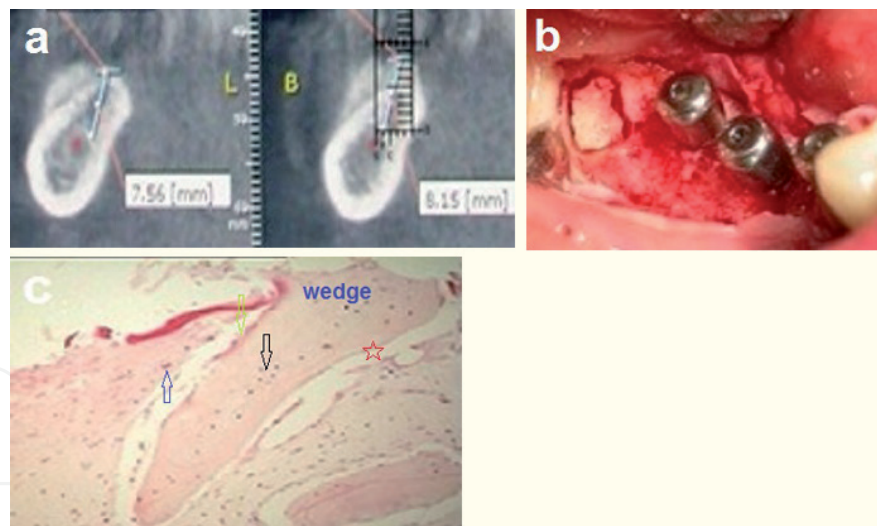
### 3. Results

#### 3.1 Clinical outcomes

Bone augmentation with cortical bone wedges was performed in adult patients, mean age 47 years; ranging from 19 to 67 years. Different sites at the maxilla and the mandible had been treated with the WT, and the majority of the augmented sites were at the posterior mandible (**Figure 10**). The majority of the treated patients had more than one site to augment. The healing process was uneventful. The donor site for the bone block (the retromolar area) healed very well without complications



**Figure 10.**  
*Patients and augmented sites.*



**Figure 11.** Histologic examination. (a and b) The site of the wedge biopsy. (c) The bone wedge is obvious at the center of the figure (hematoxylin–eosin). Black arrow, vital osteoclasts; blue arrow, osteoblasts; green arrow, osteoclasts. The red star, the artificial split of the specimens.

and spontaneous regeneration of the site was observed during the follow-up period, with full regeneration after twelve months. The recipient sites healed very well, and the bone augmentations were maintained without wound dehiscence among almost all the treated patients. However, one patient experienced a partial breakdown of the wound, and the majority of the augmented bone was lost; this patient had completed treatment with nerve transposition for implant placement. Four months after the augmentation surgery, clinical evaluation of the recipient sites revealed new hard tissue volume and good ridge contour. CBCT evaluation showed a good bone volume with 4 to 8 mm bone gain horizontally and 3–6 mm bone gain vertically. The second surgery that was performed for dental implant placement revealed a new and good bone volume, with excellent integration of the bone wedges at the recipient site. The excellent integration of the bone wedges was obvious with no dislodgement during the implant site preparation. Dental implants were inserted of adequate lengths (10–16 mm) and diameters (2.8–4.2 mm). Further follow-up of the augmentation sites and the implants in both the mandible and the maxilla revealed stable long-term outcomes after the implants rehabilitation.

### 3.2 Histologic findings

At the reentry stage for implant insertion, hard tissue specimens were obtained from the wedge area for histologic evaluation (**Figure 11a** and **b**). The obtained specimen of the bone wedge was stained with hematoxylin and eosin (H&E) after overnight decalcification using Rapid Decalcification Solution containing Hydrochloric Acid, revealed vital osteocytes within the entire bone wedge, osteoblasts, and osteoclast in its periphery (**Figure 11c**), with no evidence of necrotic areas inside the bone wedges. Those findings may indicate the vitality and remodeling activities of the graft. More specific histological examinations and stains should be performed to enhance the understanding of the healing process. This could be performed on an animal model.

## 4. Discussion

Autogenous bone grafts have been used for many years for the reconstruction of alveolar defects and are still considered the gold standard for bone augmentation.

The mandibular symphysis and ramus are widely used as intraoral donor sites. Extraoral donor sites are used as well, however, they have some major disadvantages including concomitant morbidities of the donor site, high treatment costs, and high resorption rates [11–17]. The donor site for the WT is the mandibular retromolar/ramus area, therefore, the majority of the bone block consists mainly of cortical bone. Pikos in 2005 stated that one ramus donor site can provide bone volume for a three-tooth segment, and can provide 3–4 mm as horizontal or vertical bone regeneration [41]. If an extensive bone graft is required for one or more sites in the same patient, it may necessitate simultaneous harvest of bone blocks bilaterally from the ramus area and from the symphysis area as well in order to obtain enough bone quantities. Moreover, these cases may necessitate multiple augmentation surgeries to achieve the desired reconstruction of the same site as the report of Schwarts using the Multitier techniques for such cases. In addition, some surgeons may use extraoral donor sites for multiple-site ridge augmentation [42]. Among the concerns of the recipient sites reconstruction with bone blocks, two of them are extremely significant for the final outcome; the First one is bone block dislodgement during the insertion of the implants [43], and the second one is the presence of a connective tissue layer between the block graft and the recipient bed [44]. In addition, micromovements of the bone block graft, loosening the fixation screws, and infection may compromise the desired augmentation outcomes.

The present chapter describes the wedge technique as a novel bone augmentation method that can be useful for multiple site augmentations as horizontal or vertical bone augmentation or both (3-dimensional). The multiple splitting of one harvested block could give 8 to 12 thin cortical bone wedges (0.5 to 1 mm thickness for each wedge), and 3 to 4 wedges that are used in the recipient site can augment at least a three-tooth segment. A simple calculation manifests that one harvested bone block can augment 3 to 4 sites of a three-tooth segment. The fundamental concept of this technique is the use of cortical bone wedges that are inserted into the grooves at the recipient site to create bone compartments that are filled with allograft bone particles.

The grooves at the recipient site have several functions including; mechanical retention of the cortical bone wedge so there is no need for fixation materials like screws, reducing the hazards of hardware infection and eliminating their expenses. Moreover, the grooves act as biological retention of the cortical bone wedge, and may be considered as decortication for the recipient site. The blood vessels injury during the groove preparation can enhance angiogenesis and revascularization of the thin bone wedge in one hand, and it can accelerate the regional acceleratory phenomenon on the other hand which has an important function in the healing of the operated organs. It is well documented in the relevant literature that the success of bone grafting procedures depends mainly on the amount of revascularization (quality and intensity). De Marco et al. in 2005 reported that several vascular sprouts from the recipient bed proliferated toward the graft by the third day, and were demonstrated at the graft periphery. Moreover, revascularization was more intense in the area near the perforation of the recipient bed [38].

According to the author's opinion, the previously mentioned findings regarding the revascularization of a bone graft at the recipient site may explain the integration of the thin bone wedges in the retention grooves. In addition, the use of particulate bone to fill the compartments in the WT plays a significant role in the fast incorporation of the bone graft at the recipient site [4]. The regeneration process can be approved by the histologic finding of specimens obtained from the bone wedges examinations 4 months after the augmentation. Vital Osteocytes were visible inside the bone wedge which indicates the wedge vitality. Moreover, the presence of osteoclasts and osteoblasts at the periphery of the wedge indicate bone graft remodeling.

The cortical bone wedge, in the WT, has several functions; the thin nature of the wedge (0,5-1 mm) may enhance the ingrowth of the vascular sprouts that emerge from the grooves at the recipient bed at two contact surface areas at each wedge, therefore, the revascularization of the wedge graft maybe earlier and faster than that of the standard thick block. Moreover, the bone wedge acts as a space maintainer for the augmented bone, which is achieved by the multiple bone compartments that are created between the bone wedges. In addition, while inserting the bone wedges in the grooves, they tent the membrane that covers the graft. As a result, the bone wedges support the particulate bone filler, and inhibit its deformation at the recipient site. According to the author's point of view, the insertion of several bone wedges at the recipient site creates a site with an increased number of autogenous bone walls that may accelerate the regeneration of the treated sites similar to the reconstruction concept of the periodontal defects. Moreover, the wedge-groove unit increases bone to bone contact surface areas that lead to a faster wedge to groove integration. Successful grafting depends mainly on the close contact between the graft and vascularization tissue, and on its fixation to the recipient bed [35, 39]. Those two principles are fundamental in the wedge-groove unit concept. Moreover, comparing the wedge-groove unit with the standard thick cortical bone graft, the latter has higher failure rates due to the risk of early exposure, slower rates of revascularization with areas of necrosis that may persist for a long time within the graf, and incomplete bone graft replacement [45, 46].

The cortical bone wedge technique has several advantages:

1. One harvested bone block from the ramus can augment two to three recipient sites.
2. Two harvested ramus bone blocks bilaterally can augment multisite in both jaws.
3. There is no need for fixation materials (Screws, mini-plates, or titanium mesh).
4. Decrease the need for extra-oral donor sites. Therefore, reducing the complications and expenses of the standard bone block graft.

An additional key factor for successful bone augmentation relies crucially on adequate volume, quality, and tension-free closure of the soft tissue at the recipient site. The buccal-free fat graft was simultaneously used along with the wedge technique as soft tissue grafting to enhance a double layer tension-free closure of the recipient site. The role of the buccal free fat graft during bone augmentation procedures was proved by Kablan and Laster at their publication [47].

The Resorption of different bone augmentation materials is well documented in the relevant literature in dentistry. Haggery et al. in 2015 stated that the resorption rates of cortical grafts are (0–50%), with the most resorption occurring at the periphery of the graft [4]. In addition, according to the dental implant literature, bone resorption around implants is expected during the first year of function to be approximately 1.2 mm in height, and 0.1 mm additional resorption for every subsequent year [48, 49]. The clinical and radiographic follow-up results among the patients that had been treated with the WT and followed for an average time of 56 months; ranging from 30 to 120 months showed excellent survival and success rates with minimal bone resorption around the implants. According to the author, the long-term stability of the outcomes utilizing the WT results from the use of thin cortical bone wedges that completely revascularized during the healing period, and from the combined use of particulate bone as well; that is readily incorporated at the recipient site.

## 5. Conclusions

The cortical bone wedge technique's biological rationale is to create multiple autogenic bone compartments that are filled with allogeneic bone particles. This combination can augment multiple sites with intraoral autogenous bone blocks and reduces the need for extraoral donor sites. The wedge-groove unit may enhance revascularization of the bone graft and improve its survival. The long-term follow-up results of the wedge technique indicate the predictability of this treatment modality.

## Acknowledgements

Thanks to Dr. Abir Abu Subeh for her technical support.

## Conflict of interest

The author declares no conflict of interest.

## Abbreviations

WT                      wedge technique

## Author details

Fares Kablan  
Department of Oral and Maxillofacial Surgery, The Galilee Medical Center,  
Nahariya, Israel

\*Address all correspondence to: [kablanp1@gmail.com](mailto:kablanp1@gmail.com)

## IntechOpen

© 2021 The Author(s). Licensee IntechOpen. This chapter is distributed under the terms of the Creative Commons Attribution License (<http://creativecommons.org/licenses/by/3.0>), which permits unrestricted use, distribution, and reproduction in any medium, provided the original work is properly cited. 



## References

- [1] Cross J. Bone augmentation procedures in implant dentistry. *Int J Oral Maxillofac Implants* [Internet]. 2009;24 Suppl:237-259. Available from: <https://pubmed.ncbi.nlm.nih.gov/19885448/>.
- [2] Esposito M. The efficacy of various bone augmentation procedures for dental implants: A Cochrane systematic review of randomized controlled clinical trials. *Int J Oral Maxillofac Implants* [Internet]. 2006 [cited 14 August 2021];21(5):696-710. Available from: <https://pubmed.ncbi.nlm.nih.gov/17066630/>.
- [3] Davi Rabelo G. Retrospective study of bone grafting procedures before implant placement. *Implant Dent* [Internet]. 2010 [cited 14 August 2021];19(4). Available from: <https://pubmed.ncbi.nlm.nih.gov/20683291/>.
- [4] CJ H. Simple bone augmentation for alveolar ridge defects. *Oral Maxillofac Surg Clin North Am* [Internet]. 2015 [cited 14 August 2021];27(2):203-226. Available from: <https://pubmed.ncbi.nlm.nih.gov/25951957/>
- [5] PJ B. An algorithm for reconstruction of alveolar defects before implant placement. *Oral Maxillofac Surg Clin North Am*. 2001;13:533-541.
- [6] Jensen S. Bone augmentation procedures in localized defects in the alveolar ridge: Clinical results with different bone grafts and bone-substitute materials. *Int J Oral Maxillofac Implants* [Internet]. 2009 [cited 14 August 2021];24:218-36. Available from: <https://pubmed.ncbi.nlm.nih.gov/19885447/>
- [7] PJW S. A: Interpositional bone graft augmentation of atrophic mandible. *J Oral Surg*. 1978;36:30-32.
- [8] Jensen OT. Anterior maxillary alveolar distraction osteogenesis: A prospective 5-year clinical study. *Int J Oral Maxillofac Implants*. 2002;17:52-68.
- [9] Jensen OT. Alveolar segmental “sandwich” osteotomies for posterior edentulous mandibular sites for dental implants. *J Oral Maxillofac Surg*. 2006;64:471-475.
- [10] Urbani G. Distraction osteogenesis to achieve mandibular vertical bone regeneration: A case report. *Int J Oral Maxillofac Implants*. 1996;11: 387-394.
- [11] Beirne OR. Comparison of complications after bone removal from lateral and medial plates of the anterior ilium for mandibular augmentation. *Int J Oral Maxillofac Surg*. 1986;15:269.
- [12] Cricchio G. Donor site morbidity in two different approaches to anterior iliac crest bone harvesting. *Clin Implant Dent Relat Res*. 2003;5(3):161-169.
- [13] Kline Jr RM. Complications associated with the harvesting of cranial bone grafts. *Plast Reconstr Surg*. 1995;95(1):5-13.
- [14] Frodel Jr JL. Calvarial bone graft harvest. Techniques, considerations, and morbidity. *Arch Otolaryngol Head Neck Surg*. 1993 Jan;119(1):17-23.
- [15] Restoy-Lozano A. Calvarial bone grafting for three-dimensional reconstruction of severe maxillary defects: A case series. *Int J Oral Maxillofac Implants*. 2015;30(4):880-890.
- [16] Chen YC. Donor site morbidity after harvesting of proximal tibia bone. *Head Neck*. 2006 Jun;28(6):496-500.
- [17] Nkenke E. Morbidity of harvesting of bone grafts from the iliac crest for preprosthetic augmentation procedures:

A prospective study. *Int J Oral Maxillofac Surg.* 2004 Mar;33(2):157-163.

[18] Khoury F. Augmentation of the sinus floor with mandibular bone blocks and simultaneous implantation. A 6-year clinical investigation. *Int J Oral Maxillofac Implants.* Jul-Aug 1999;14(4):557-564.

[19] Misch CM. Ridge augmentation using mandibular ramus bone grafts for the placement of dental implants: Presentation of a technique. *Pract Periodontics Aesthet Dent.* 1996 Mar;8(2):127-135; quiz 138.

[20] Misch CM. Comparison of intraoral donor sites for onlay grafting prior to implant placement. *Int J Oral Maxillofac Implants.* Nov-Dec 1997;12(6):767-776.

[21] Schwartz-Arad D. Surgical success of intraoral autogenous block onlay bone grafting for alveolar ridge augmentation. *Implant Dent.* 2005 Jun;14(2):131-138.

[22] Garg AK. Autogenous mandibular bone grafts in the treatment of the resorbed maxillary anterior alveolar ridge rationale and approach. *Implant Dent.* 1998;7(3):169-176.

[23] Silva FM. Complications of intraoral donor site for bone grafting prior to implant placement. *Implant Dent.* 2006 Dec;15(4):420-426.

[24] Joshi A. An investigation of post-operative morbidity following chin graft surgery. *Br Dent J.* 2004 Feb 28;196(4):215-218.

[25] Clavero J. Ramus or chin grafts for maxillary sinus inlay and local onlay augmentation: Comparison of donor site morbidity and complications. *Clin Implant Dent Relat Res.* 2003;5(3):154-160.

[26] Nkenke E. Morbidity of harvesting of retromolar bone grafts: A prospective study. *Clin Oral Implants Res.* 2002 Oct;13(5):514-521.

[27] Nkenke E. Morbidity of harvesting of chin grafts: A prospective study. *Clin Oral Implants Res.* 2001 Oct;12(5):495-502.

[28] Widmark G. Rehabilitation of patients with severely resorbed maxillae by means of implants with or without bone grafts. A one year follow up study. *Int J Oral Maxillofac Implants.* Jul-Aug 1998;13(4):474-482.

[29] Cammack GV 2nd. Histologic evaluation of mineralized and demineralized freeze-dried bone allograft for ridge and sinus augmentations. *Int J Periodontics Restorative Dent.* 2005 Jun;25(3):231-237.

[30] Simon M. Vertical ridge augmentation by expanded-polytetrafluoroethylene membrane and a combination of intraoral autogenous bone graft and deproteinized anorganic bovine bone (Bio Oss). *Clin Oral Implants Res.* 2007 Oct;18(5):620-629.

[31] Koll A. Current trends and future perspectives of bone substitute materials – From space holders to innovative biomaterials. *J Craniomaxillofac Surg.* 2012 Dec;40(8):706-718

[32] Gomes KU. Use of allogenic bone graft in maxillary reconstruction for installation of dental implants. *J Oral Maxillofac Surg.* 2008 Nov;66(11):2335-2338.

[33] Le B. Cortical tenting grafting technique in severely atrophic alveolar ridge for implant site preparation. *Implant Dent.* 2008 Mar;17(1):40-50.

[34] Khojasteh A. Localized bone augmentation with cortical bone blocks

tended over different particulate bone substitutes: A retrospective study. *Int J Oral Maxillofac Implants*. Nov-Dec 2012;27(6):1481-1493.

[35] Burchardt H. Transplantation of bone. *Surg Clin North Am*. 1978 Apr;58(2):403-427.

[36] Nathanson A. The early vascularization of an autogenous bone inlay into an artificial defect in the rabbit mandibular. *Acta Otolaryngol*. Jan-Feb 1978;85(1-2):135-148.

[37] Hammack BL. Comparative vascularization of autogenous and homogenous-bone transplants. *J Bone Joint Surg Am*. 1960 Jul;42-A:811-817.

[38] De Marco AC. Revascularization of autogenous block grafts with or without an e-PTFE membrane. *Int J Oral Maxillofac Implants*. Nov-Dec 2005;20(6):867-874.

[39] Scardina GA. Microcirculation in the healing of surgical wounds in the oral cavity. *Int J Oral Maxillofac Surg*. 2013 Jan;42(1):31-35.

[40] LaTenta GS. The role of rigid fixation in bone graft augmentation of the craniofacial skeleton. *Plast Reconstr Surg*. 1989 Oct;84(4):578-588.

[41] Pikos MA. Mandibular block autografts for alveolar ridge augmentation. *Atlas Oral Maxillofac Surg Clin North Am*. 2005 Sep;13(2):91-107.

[42] Schwarts AD. Multitier of harvesting technique for bone augmentation using intraoral autogenous bone blocks. *Implant Den*. 2007 Mar;16(1):5-12.

[43] Proussaefs P. The use of intraorally harvested autogenous block grafts for vertical alveolar ridge augmentation: A human study. *Int J Periodontics Restorative Dent*. 2005 Aug;25(4):351-363.

[44] De Carvalho PS. Influence of bed preparation on the incorporation of autogenous bone grafts: A study in dogs. *Int J Oral Maxillofac Implants*. Jul-Aug 2000;15(4):565-570

[45] Andrade MG. Pattern of osteogenesis during onlay bone graft healing. *Oral Surg Oral Med Oral Pathol Oral Radiol Endod*. 2010 Dec;110(6):713-719.

[46] Oppenheimer AJ. Craniofacial bone grafting: Wolff's law revisited. *Craniofacial Trauma Reconstr*. 2008 Nov;1(1):49-61.

[47] Kablan F. The use of free fat tissue transfer from the buccal fat pad to obtain and maintain primary closure and to improve soft tissue thickness at bone-augmented sites: Technique presentation and report of case series. *Int J Oral Maxillofac Implants*. Mar-Apr 2014;29(2):e220-e231.

[48] Adell R. A 15-year study of osseointegrated implants in the treatment of the edentulous jaw. *Int J Oral Surg*. 1981 Dec;10(6):387-416

[49] Albrektsson T. The long-term efficacy of currently used dental implants: A review and proposed criteria of success. *Int J Oral Maxillofac Implants*. Summer 1986;1(1):11-25.