

We are IntechOpen, the world's leading publisher of Open Access books Built by scientists, for scientists

5,500

Open access books available

136,000

International authors and editors

170M

Downloads

Our authors are among the

154

Countries delivered to

TOP 1%

most cited scientists

12.2%

Contributors from top 500 universities



WEB OF SCIENCE™

Selection of our books indexed in the Book Citation Index
in Web of Science™ Core Collection (BKCI)

Interested in publishing with us?
Contact book.department@intechopen.com

Numbers displayed above are based on latest data collected.
For more information visit www.intechopen.com



Chapter

VASER Liposuction. How to Get Natural Results with Ultrasound Assisted Liposuction?

*Dinko Bagatin, Tomica Bagatin, Judith Deutsch,
Katarina Sakic, Johann Nemrava, Eduardo Isomura
and Martina Sarec Ivelj*

Abstract

Ultrasound assisted liposuction technology is a selective technique to emulsify fatty tissue and improve the removal of fat. This technique can be used on many areas of the body such as: chin neck, back, buttocks, abdomen, legs, arms. Fatty areas, as well as, skin and cellulite can be molded in a process known as ultrasound cavitation. Results can produce significant skin contraction and smoothing of areas. Using this method reduces the need for surgical intervention and requires less energy to achieve similar results. This method is also good for treatment of fibrous scar tissue, producing less bruising and blood loss. The advantages of the VASER ultrasound prepared liposuction in comparison to the mechanical liposuction method are better with fat extraction, less blood loss, and smoother results. While the disadvantages of VASER ultrasound method are possible thermal injuries, the need for larger incisions for protective ports, increased incidence of seromas, slightly increased cost and longer preparation and operative times. However further presentation will show the benefits of this newer generation of liposuction method. Also, various probes for better fat extraction and specific treatment areas will be discussed.

Keywords: ultrasound liposuction, emulsification of fat, cavitation, skin retraction, natural result

1. Introduction

A brief historic introduction to liposuction and surgical body contouring, the method has been around since the 1970's. Developed and enhanced throughout the passing years, most notably in 1988 by Michele Zocchi. The ultrasound assisted liposuction (UAL) method was created and used in 1,057 patients (875 women and 182 men) from 1989 to 1996, by Zocchi [1]. He was able to remove larger quantities of fat than the manual liposuction method and suggested that this technique had great potential in treating specific patients. The results are excellent and with no major complications, opening the door to a more effective liposuction method. Of the minor complications encountered, there were mild burns at cannula sites and discoloration of skin (dyschromia).

Further technique development and increased popularity began in the 21st century, with Alfredo E. Hoyos. He introduced high-definition body sculpturing [2–4].

VASER liposuction means vibration amplification of sound energy at resonance (VASER).

VASER ultrasound technology enables the fragmenting of large fat into smaller fat pieces. The method uses an infiltration technique with tumescent fluid comprised of a combination of saline, adrenalin, lidocaine and sodium bicarbonate. The released fat molecules are then extracted from the body using liposuction cannulas. A more sparring and less aggressive manual extraction is needed with this method, than what is used with the classic liposuction technique [5, 6].

The use of tumescent fluid not only releases the fat molecules but also reduces bleeding and provides analgesia.

A presentation and discussion of the VASER modes used (continuous or intermittent), tumescent fluid (amounts and preparation), method of achieving natural results, differences between sexes and areas being treated will all be covered thoroughly.

My personal experience with liposuction began in 2008, as a plastic surgery resident. Attending several congresses, notably an annual Congress of the Turkish Society of plastic Surgery in Istanbul. There an American surgeon, Mark Jewell, described VASER as, “the best thing to ever happen to him in his life”. He stated, “this method gave significant better results compared to earlier methods” [7]. This was intriguing and Polyclinic Bagatin purchased the device and began implementing it, after several hands on courses. The results were immediate. The method of liposuction was easier and more efficient in fat extraction. At the start, several patients (5–10%) had to have additional corrections until the technique was perfected. However, results were good, and patients were very satisfied. There were a few cases where the results were not as anticipated. Even after attempted corrections, the results were not great. This suggests actual limitations of the VASER technique in some cases [8–10].

Overall, it is always important and crucial to listen to patients what they want and what can be realistically achieved [11]. It is better not to make promises that cannot be kept. An honest open approach is best as to what can be done. Results depend on patient age, skin quality, amount of fat deposits and their locations, as well as eating and drinking habits and patient motivation. An ideal patient is one who knows exactly what they want, realistic expectations, good skin tone and texture.

2. Materials and methods

Performing an ultrasound assisted liposuction method involves thorough preparation and planning.

Patient candidate consultation, discussion, planning, visual aids (VECTRA, drawings, examples of results) and clear achievement goals are needed prior to operating.

Once a goal and plan has been reached, the operating team is debriefed and steps to start the procedure can begin.

Klein’s original fluid combination uses saline, a local anesthetic (lidocaine), a vasoconstrictor (adrenaline), and sodium bicarbonate. Dr. Klein uses for each 1000 mLs of saline, 12.5 mL sodium bicarbonate (8.4%), 0.5–0.75 mg adrenaline, and lidocaine 500 mg (using up to a maximum of 55 mg/kg patient body weight) [12]. At Poliklinika Bagatin a significantly lower maximal dose is used,

	Klein	Hunstad (modified)	Poliklinika Bagatin	Pitman	Toledo	Zocchi
0.9% NaCl (saline) (mL)	1000		1000	1000		
0.45% NaCl (saline) (mL)						1000
Ringer Lactate (mL)		1000			1000	
1% Lidocaine (mL, mg)	50 mL, 500 mg	50 mL, 500 mg		50 mL, 500 mg	80 mL, 800 mL	50 mL, 500 mg
0.5% bupivacaine (mL, mg)			10 mL, 50 mg			
8.4% Sodium Bicarbonate (mL)	12.5		10	5	7	10
Adrenaline (mg)	0.5–0.75	1	1	1	2	1

Table 1.
Tumescent solution variations.

35–45 mg/kg. Interestingly, Hunstad created a modified solution using a 500 mg lidocaine within 1000 ml Ringer Lactate and 1 mg of adrenaline [12]. However, Dr. Hunstad opts not to use sodium bicarbonate in his modified solution. Various mixtures of tumescent fluids are used worldwide. Others such as Pitman, Toledo and Zocchi, as seen in the table provided, have their preferred combinations (**Table 1**).

3. Various combinations of tumescent solutions

Whatever the variations used, in general a mix of similar ingredients are combined.

The tumescent fluid is prepared using a specified amount of saline required for certain areas of the body. This depends on body surface area to be performed on. For example, the chest can require 3–4 liters, while the legs or arms may need 1–3 liters. The abdomen may require 6 liters. The surgeon decides on volume amounts, reducing this if multiple operative sites are to be performed, with or without surgical reduction.

At Poliklinika Bagatin, each liter of tumescent fluid used is a combination of standard intravenous saline, 1 mg adrenaline (epinephrine), 10 mL bupivacaine (5 mg/mL), and 10 mL sodium bicarbonate (8.4% w/v) [13]. More than 35–45 mg/kg bupivacaine in total, is never used [14, 15], reducing the risks of possible overdose. A larger amount of anesthetic can be used, since it will not be placed intravascularly, is combined with adrenaline and the majority will be removed during extraction liposuction. The half-life of lidocaine and bupivacaine is about 2–2.5 hours and both are metabolized 90% hepatically. The procedures are often lengthy, and can last more than 3 hours. This further reduces the possibility of local anesthetic toxicity.

The final tumescent solution looks similar in color to champagne.

Patient preparation is performed as usual, from preoperative anesthesia exam, induction, monitoring, surgical wash and sterile drape coverings.

Following the standard surgical time out, infiltration with 20mLs tumescent fluid (for easier application) is used to infiltrate areas where ports will be placed. Ports are protective portholes used for the various cannulas (VASER, liposuction VentX, infiltration probe), and protect the skin surface areas below from thermic burns that can occur without using them. The ports used are a standard diameter of 3.7 mm. Skin incisions for the ports are 3 to 5 mm wide. Care is taken to carefully choose positions, of these port incision areas, as well as how many ports will be placed. This is important for achieving natural and proper results.

When the ports are in place, tissue infiltration with the remaining tumescent fluid begins with the infiltration apparatus (**Figure 1**).

The infiltration device has various injection settings. Each are used specifically to apply the tumescent fluid into various layers and depths in the areas being treated. Surface layers are injected using the VASER variable flow (start-stop-start). While deeper layers are injected with a continuous flow. This is important to protect against burns and bleeding of more sensitive surface layers. The flow rate used is not faster than 100mLs per minute.

Following the successful tumescent fluid application, there is a waiting time (cooking time) of 10–15 minutes. During this time, fat cells are enabled to bloat and

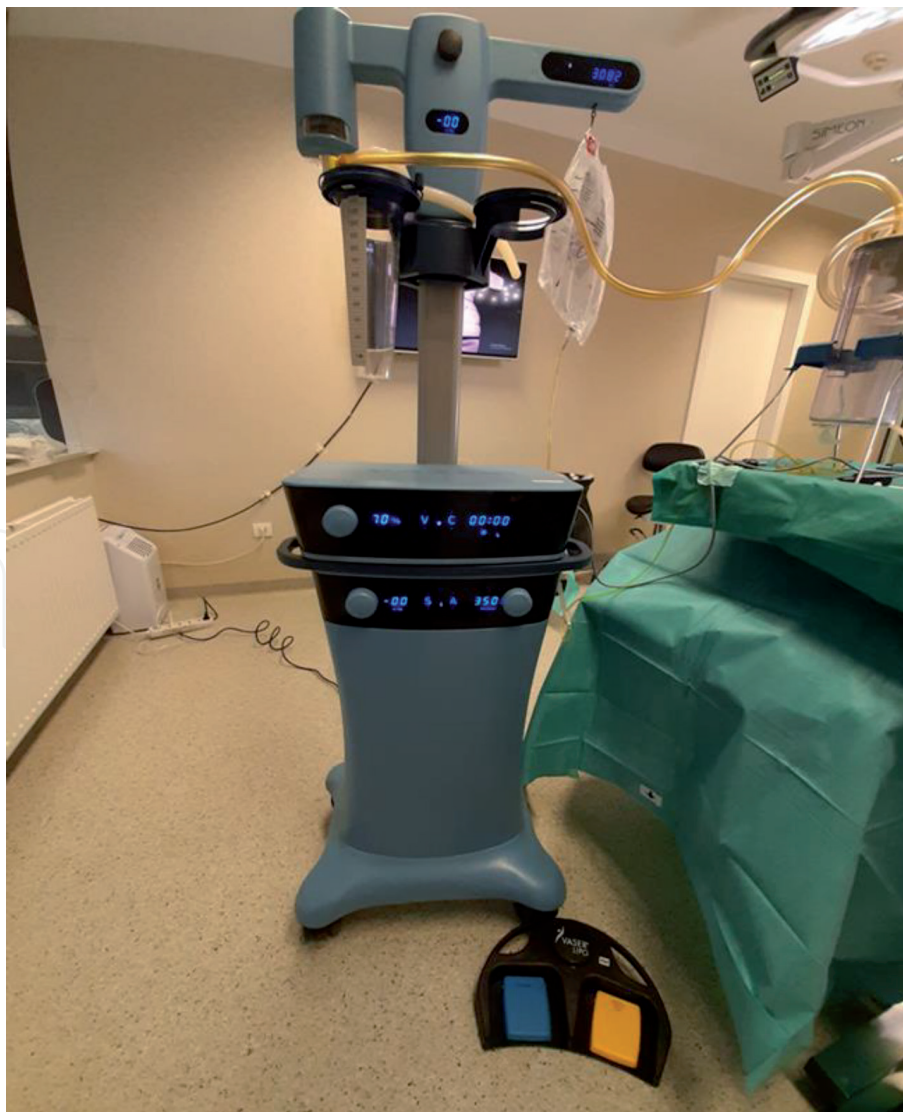

Figure 1.
VASER machine.

explode into smaller fatty fragments, which will then be more easily extracted by the various cannulas.

The tumescent fluid is prepared using a specified amount of saline required for certain areas of the body. This depends on body surface area to be performed on. For example, the chest can require 3–4 liters, while the legs or arms may need 1–3 liters. The abdomen may require 6 liters. The surgeon decides on this amount by determining operative site area, as well as procedure to be performed (possible surgical combination of area reduction).

Each liter of tumescent fluid used is a combination of standard intravenous saline, 1 mg adrenaline (epinephrine), 10 mL bupivacaine (5 mg/mL), and 10 mL sodium bicarbonate (8.4% w/v) [12]. More than 35–45 mg/kg bupivacaine, in total, is never used [13, 14], reducing the risks of possible overdose. A larger amount of anesthetic can be used, since it will not be placed intravascularly, and the majority will be removed during extraction liposuction.

When the ports are in place, tissue infiltration with the remaining tumescent fluid begins with the infiltration apparatus (**Figures 2–4**).

The infiltration device has various injection settings. Each are used specifically to apply the tumescent fluid into various layers and depths in the areas being treated. Surface layers are injected using the VASER variable flow (start-stop-start). While deeper layers are injected with a continuous flow. This is important to protect against burns and bleeding of more sensitive surface layers. The flow rate used is not faster than 100mLs per minute.

Following the successful tumescent fluid application, there is a waiting time (cooking time) of 10–15 minutes. During this time, fat cells are enabled to bloat and explode into smaller fatty fragments, which will then be more easily extracted by the various cannulas.

High-definition extraction can be achieved in various regions of the body. A gentle fanning, in-out motion of the cannulas is used. This process is continued until desired results are achieved. Following maximal extraction, it is mandatory to place overflow release drains. This helps reduce formation of seromas and faster normalization of the liposuction area, removing excess remaining trapped fluid and reducing build

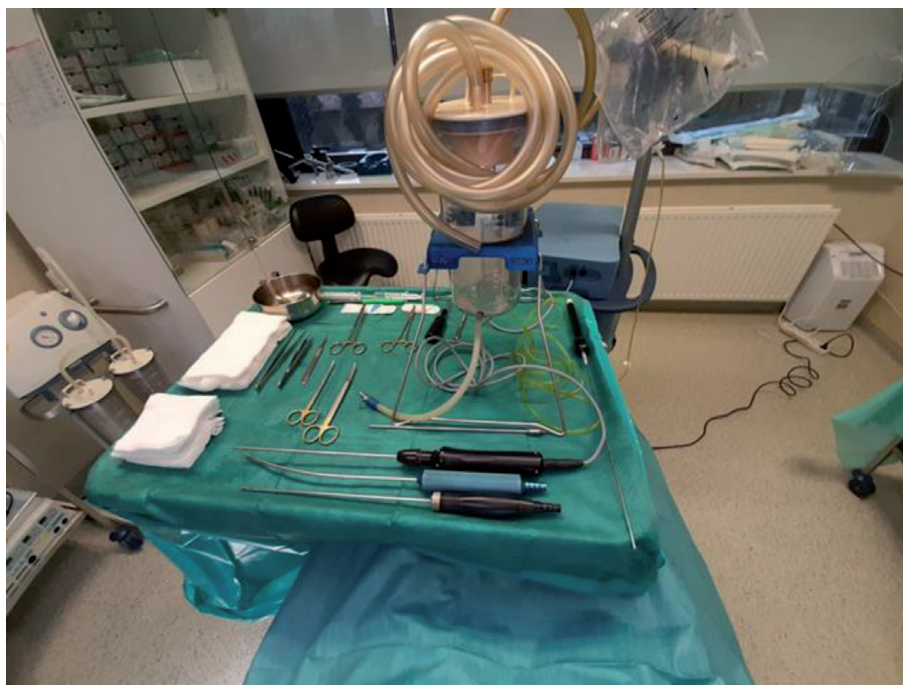


Figure 2.
All needed instruments for VASER liposuction.

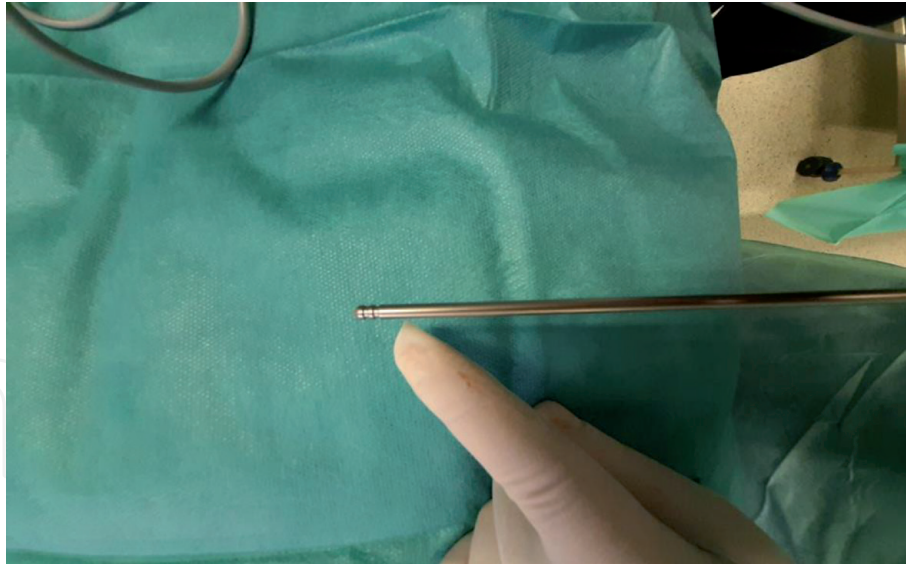


Figure 3.
Two rings VASER probe.

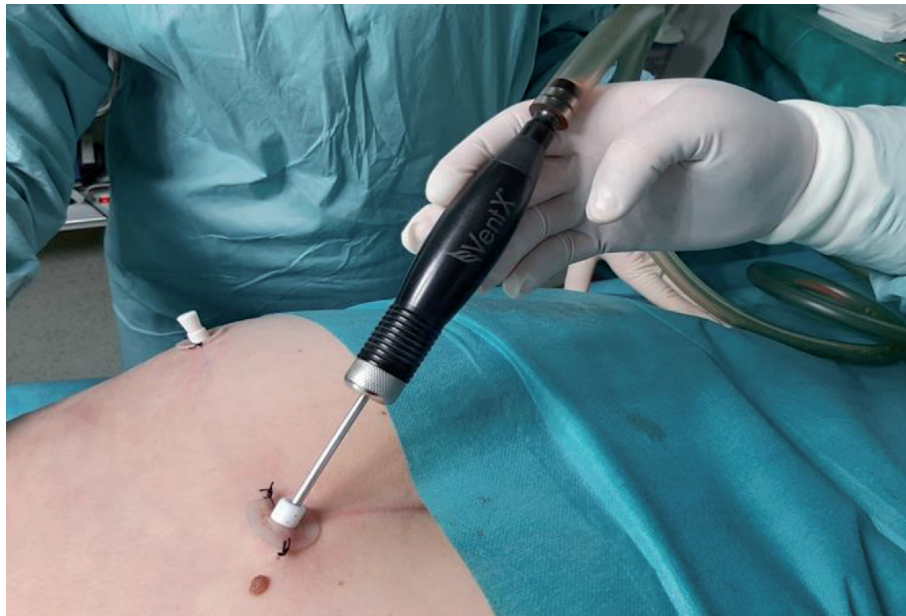

Figure 4.
Standard 3,7 mm VentX cannula.

up. Patient follow-ups need to be frequent, recommended daily for the first 7 days. During the early postoperative period, deformities are possible and can be then attended to, before becoming permanent. Later, if any lasting deformities present, they can be corrected a year after the initial operation. This is important to allow all tissues to heal, settle into a formed position and give a final view of procedure results.

4. Various featured techniques based on specific areas of the body

4.1 Double chin: men and women

Double chin sagging correction, regardless of sex, can be performed by placing ports of under 2.9 mm in locations under the chin and laterally on both sides under

the ears. Tumescence fluid infiltration should be with about 200–300 mL. The VASER device strength should be set between 20 and 40%, a stronger strength can cause the cannula probe to break. Following tumescence fluid insertion, a 5–6-minute waiting time is needed. For a more pronounced double chin and neck region, this can be increased to 9 minutes. Liposuction duration can be up to 10 minutes, until desired results. This region is very delicate and a baby VENTX cannula is used, to prevent injury and for ease of suctioning and movement. Flat cannulas up to 5 mm can also be useful to use. It is important not to feel any resistance while the VASER converts larger pieces of fat into smaller ones. A large quantity of fat is rarely present, in this area, as compared to other areas of the body. It is also important to postoperatively check neurological facial mimicry functions (smiling, whistling, frowning) to assess possible peripheral nerve injury, which can be common. However, with exercises and anti-inflammatory medications this will resolve in time.

4.2 The back area: men and women

The back can be defined as the upper, middle and lower areas. Each section can be combined with lateral side areas for liposuction. The upper and middle are often combined with the areas under the armpits and lateral sides of the rib cage – posterior part of chest girth. While the lower back is combined with love handles and buttocks. Differences among the sexes varies only in liposuction definition sections. Women often prefer the lower back with buttocks defined, while men prefer the love handles [16]. However, most opt for a thorough combination of a more complete coverage. Liposuction preparation is the same for both. Ports are regularly distributed, usually 3 to 5 of them, to adequately cover each area for various movement directions of the cannulas. Infiltration is performed with 2–3 liters of tumescence fluid, the amount used depends on coverage area. The VASER device strength should be set at 70–80%, with a waiting duration time of 10–15 minutes. The liposuction duration can last between 15 and 30 minutes, for each area, using VASER probe cannula and VENTX cannula with a diameter of 3.7 mm. The continuous mode is used depending on fibrous tissue (Figures 5–7).

4.3 Buttocks: men and women

Liposuction of the buttocks often includes the lower area and sides. This procedure is reserved for specific cases and deformities. If VASER is performed, it should be at 50% VASER device strength, with a waiting time of 10–15 minutes, and tumescence fluid of 1–2 liters. However, instead of liposuction of the buttocks, fat grafting is preferably used. In practice, it is a much better defining and contouring procedure, with more natural results, where the surrounding excess buttocks fatty tissue is removed. The process starts by first emptying the supragluteal region, followed by the infragluteal region. The upper thigh area, lower side areas, and lower buttock area, on both sides, are evaluated for appropriate reduction. Once these areas are defined and reduced, sculpturing of the buttocks can begin [17, 18]. Depending on the sex of the client, certain specific areas are chosen for enhancement. For women, higher side segments are applied, while in men the central and upper areas with concaving sides is defined. Women prefer more of a curvature effect, while men prefer a more athletic figure, with an emptying effect of the lateral sides. Performing the contouring and defining in this area with the cannulas, extreme caution of the tip is needed since it can be easily punctured through the surface, leaving scarring. Gentle in-out motions should be used, and a significant amount of quality fatty tissue should be used to instill when space is created, using

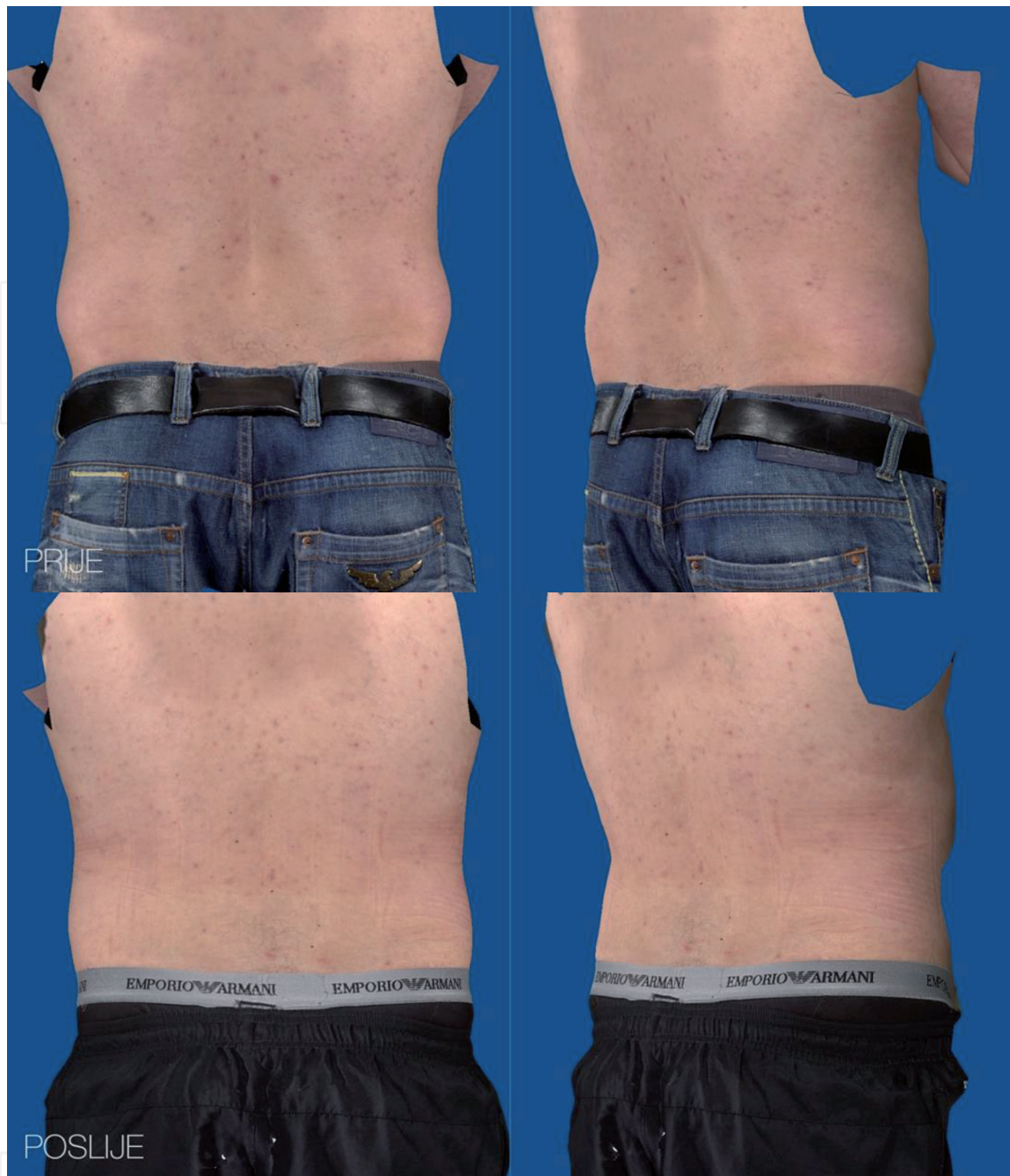

Figure 5.
Before and 3 months after VASER liposuction.

about 200–300 mL. In some cases, more can be used, such as in more obese clients, while more slender clients will need less volume to achieve adequate results.

4.4 Abdomen: men and women

The abdomen area is the most popular area treated by VASER liposuction [19]. A nicely balanced and well-defined abdominal wall is usually what defines a healthy body figure. This area is the focus of visible differences between males and females. As stated previously, men prefer a more athletic, six pack figure, while women prefer natural contours reducing the “tummy” area, not emphasizing abdominal musculature. Preparing clients for this procedure should be done in a standing position. Drawing directly on the surface and marking defined areas to correct, should be completely discussed, and planned with them. It is at this moment, a clear plan is developed and explained, as to what can be achieved and what is not possible. Planning for males, involves defining of flat abdominal wall muscles (six-pack),

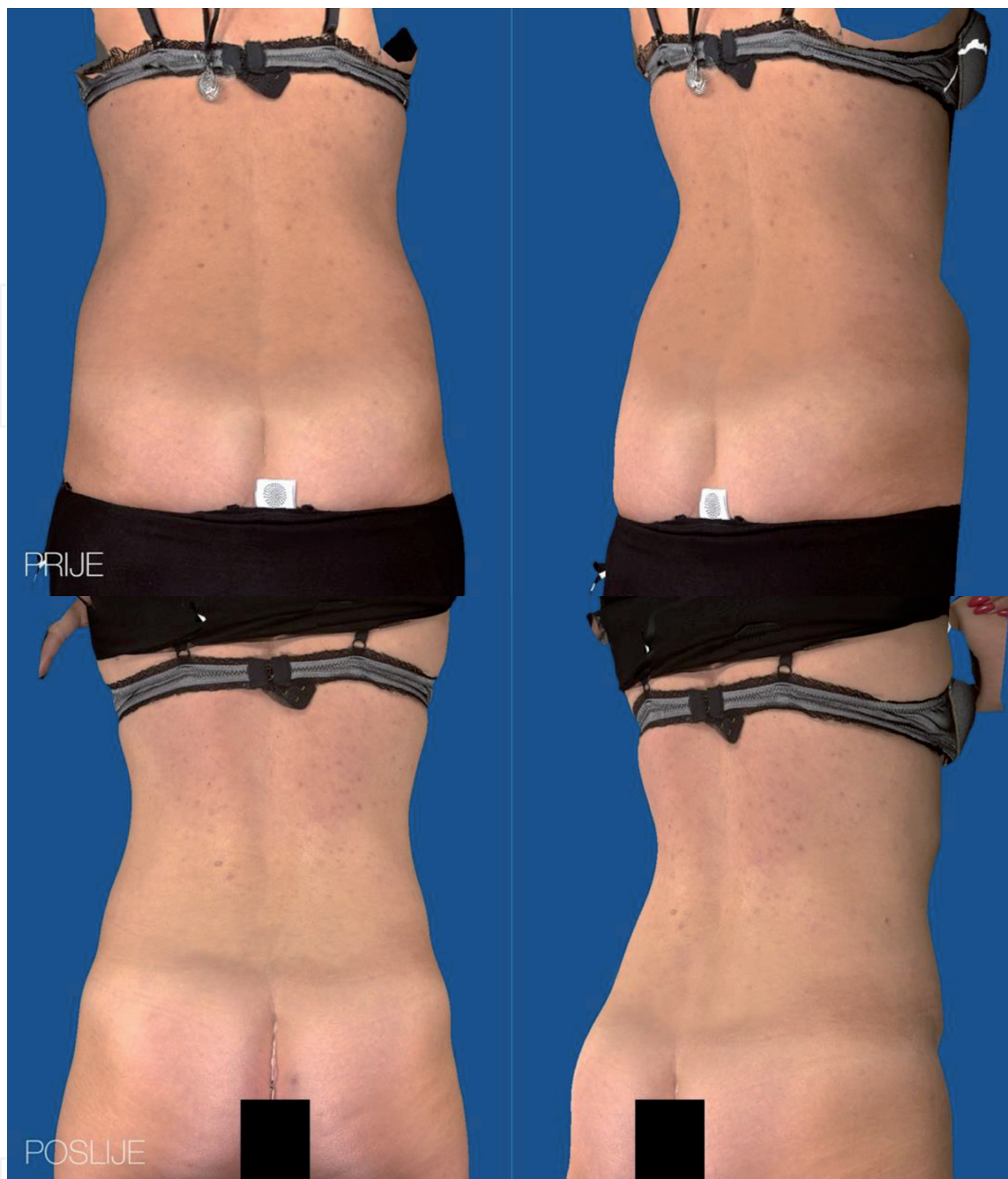

Figure 6.
Before and one year after VASER liposuction.

the linea alba and linea semilunaris regions. In women, a more subtle and gentler approach is used, creating more sensual contours defining linea semilunaris. In some instances, in women, linea alba can be defined as well, more often in slender clients. The procedure preparation is similar for both, using 3–4 liters of tumescent fluid, after application with VASER device at 70%, a waiting time of 10–15 minutes is needed. The ports used here are VENTX, with a diameter of 3.7 mm. The VASER probe cannula is set at a continuous mode, for deeper tissue reduction. However, if fibrous tissue is encountered, for example from previous operative scars, then an increased strength of the VASER device is needed, about 80–90%. A three grooved VASER probe cannula can be used. As this helps in producing maximal reduction of fatty tissue volume. At all times, the fatty tissue distribution and quality must remain symmetric. Leaving an abdominal wall subcutaneous fat layer of about 1–1.5 cm is important to retain a more natural abdominal wall contour. The liposuction process can last from 20 to 30 minutes as needed to achieve desired results (Figures 8–10).

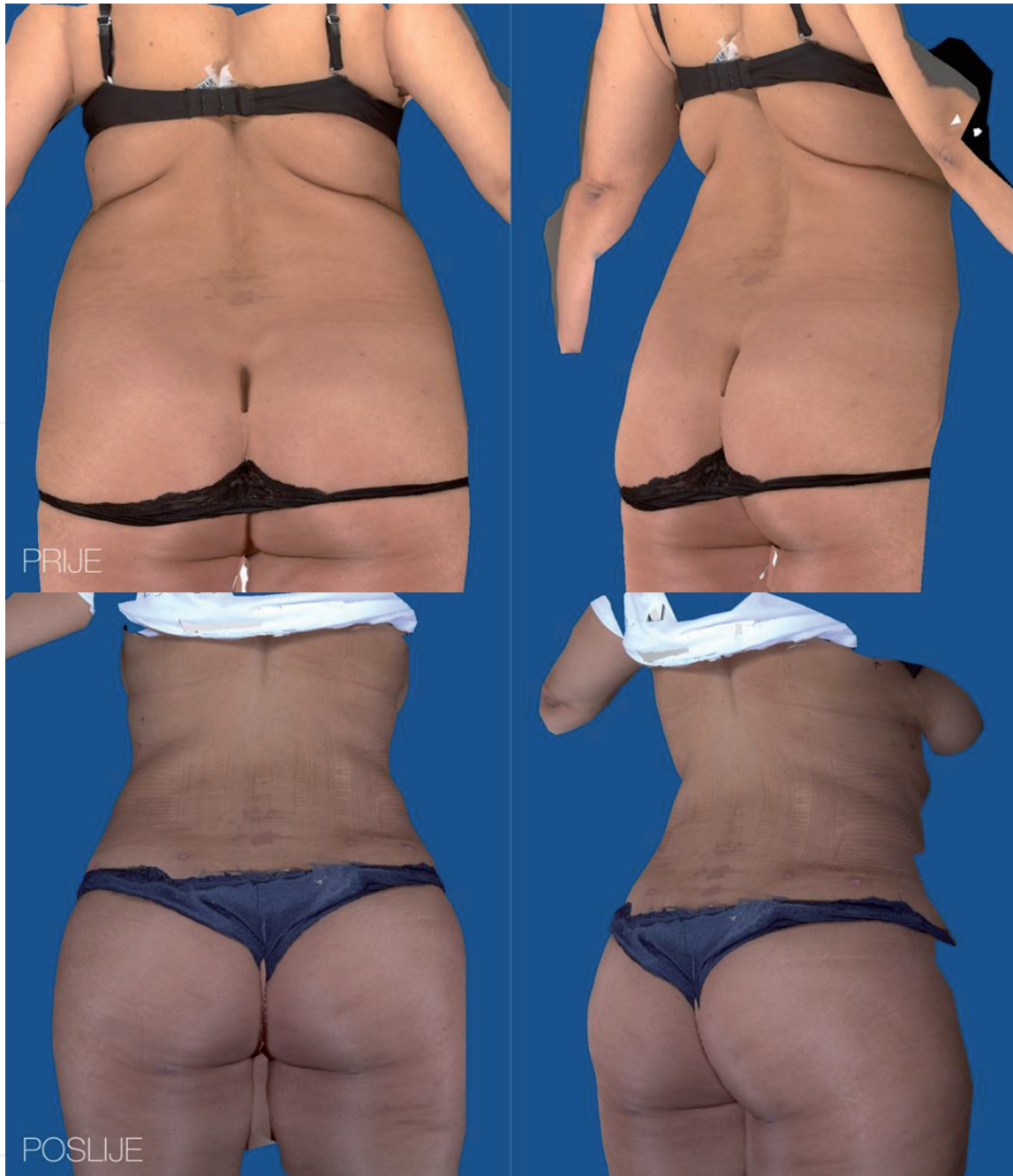

Figure 7.
Before and 3 months after operation – Back view.

4.5 Chest area: men and women

Shaping the chest area is obviously significantly different in males and females. In males, this tends to be the most performed liposuction procedure. Excess fatty tissue under the nipple-areolar complex is the most common problem seen. However, this can be spread out wider, covering more of the breast plane. Correcting excess just under the areolar areas is usually not sufficient. Full redefining of the chest region is often necessary to achieve satisfying results. In performing reduction in this area, the sides and lower chest areas, underneath the nipple areolar complex are reduced. Providing a wider reduction area covered. This provides more definition and enhancement of the large chest muscles. Fat grafting is usually not performed in males in this area, since they usually prefer a slender leaner look, with minimal scarring. Preparation for this area include, performing incisions for ports

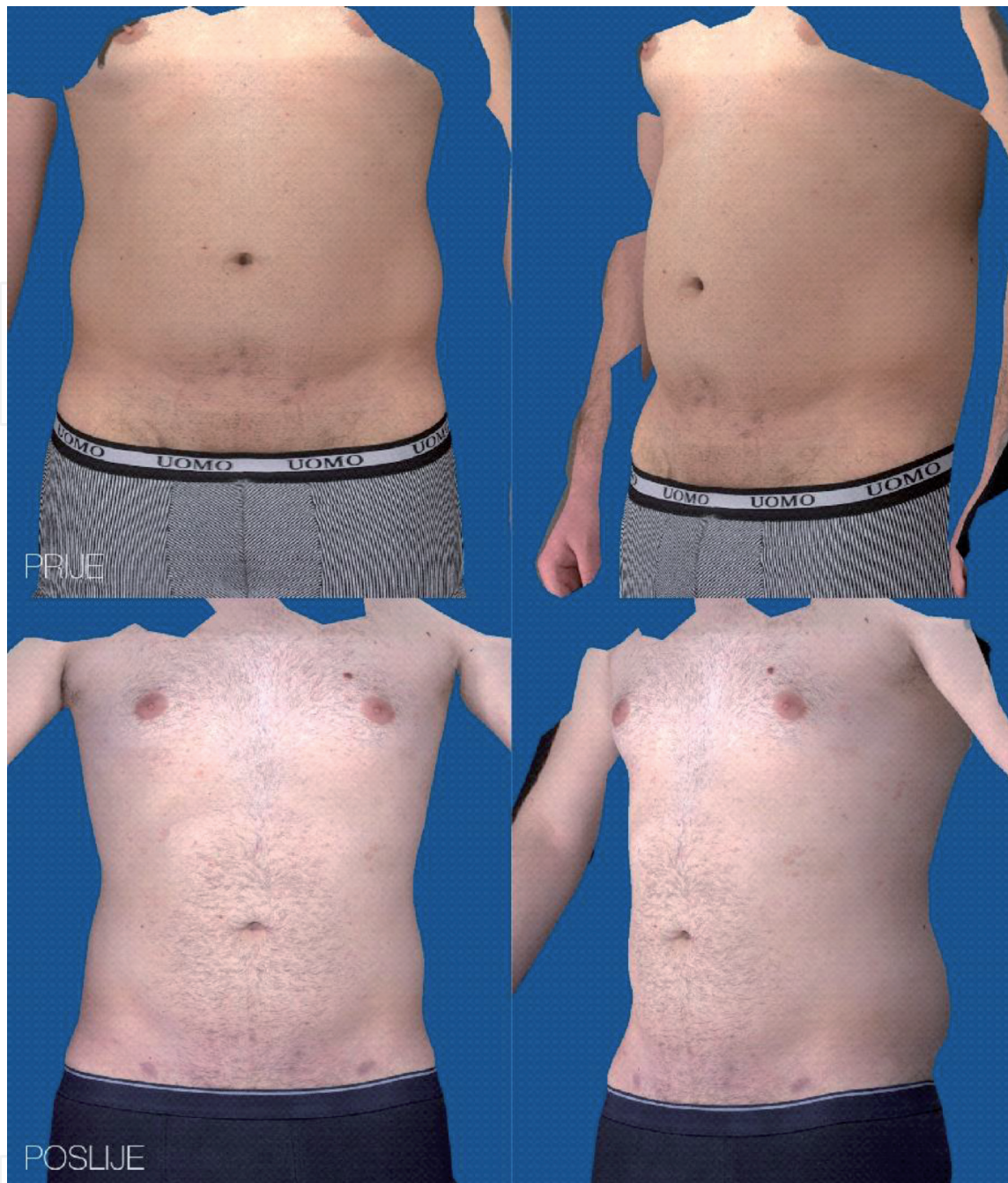

Figure 8.
Before and 6 months after VASER liposuction – Front view.

using the method Alfredo Hoyos uses [20], placing them directly under the nipple and in the peripheral armpit region, as to minimize visual scarring postoperatively. These incision areas also allow for easier access to all areas needed reduced. Again, VENTX ports are used from 2.9–3.7 mm diameter. Previously, larger diameter of 3–4 mm, when “Byrone” cannulas (wide diameter) for liposuction were used. However, now the more reduced diameters are preferred, especially in more sensitive delicate regions [21]. VASER device strength can be set from 70 to 90% depending on the presence of scar tissue, increasing strength if present. Tumescent fluid infiltration should be about 1–2 liters for each breast side. The waiting time is 10–15 minutes after application and liposuction should last 20–30 minutes, for each side performed. The combination of surgical tissue removal can be necessary, to achieve desired results. It is important to explain to patients that some loss of touch sensation can occur in the nipple region. Sometimes, this can be permanent.

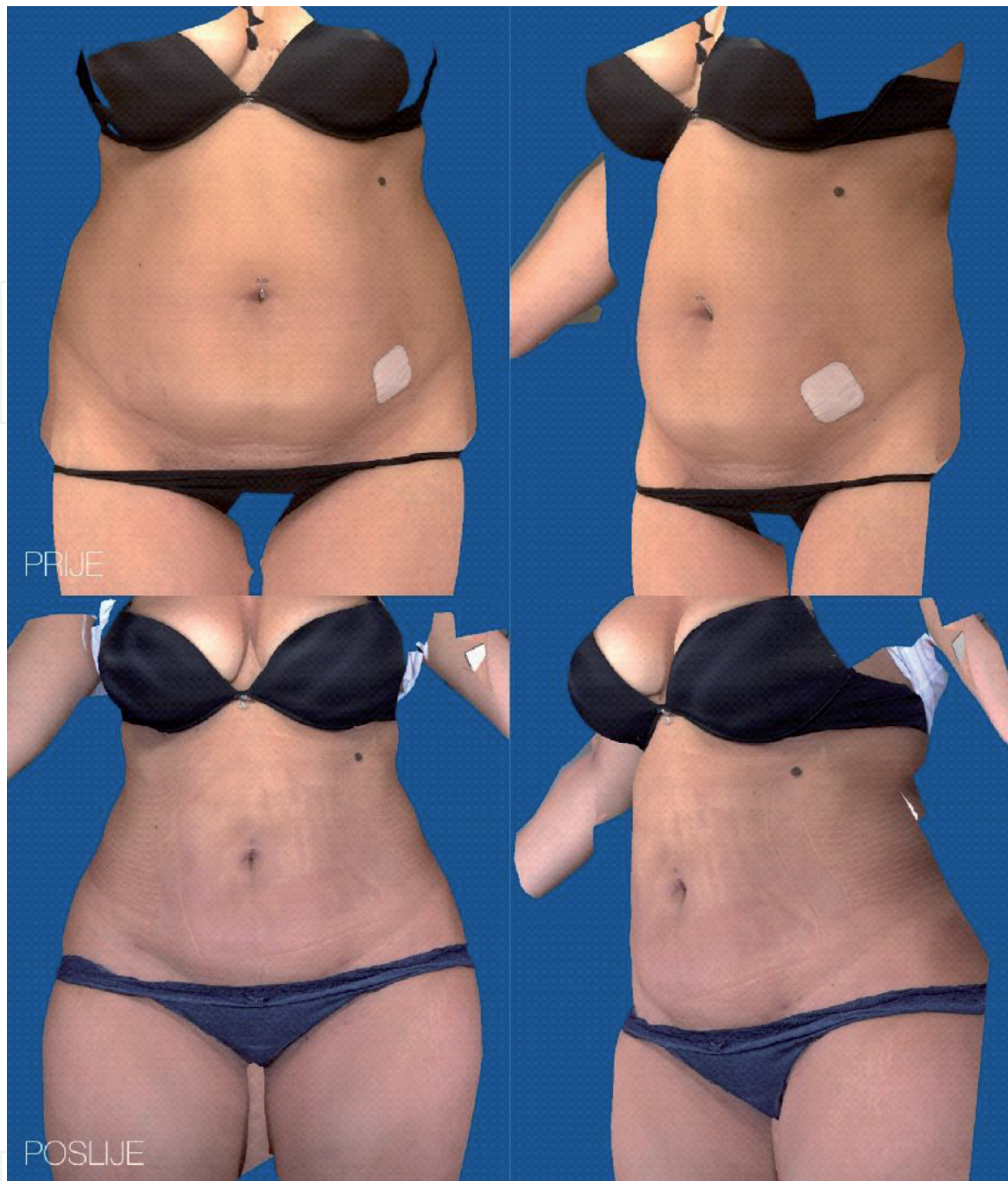


Figure 9.
Before and 3 months after VASER liposuction – Front view.

Drains are usually not placed, however at the side regions they can be placed to aid overflow in some selected cases.

For women, rarely isolated tissue reduction using VASER liposuction is performed. Instead, VASER is used for defining and contouring the lateral breast and chest areas. This method in combination with surgical reduction achieve very good results, in specific cases. If performed, 3.7 mm diameter VENTX ports are used. Tumescant fluid can be up to 1 liter per side, VASER device strength setting between 70 and 90%, waiting time of 10–15 minutes, and liposuction for 20–30 minutes. Mercedes cannulas with 3 openings can also be used. (For surgical breast reduction, incisions are made under the breast or through horizontal and vertical incisions (inverted T). More often fat grafting is a method used, providing supplement to the procedure on the breast [22]. Small incisions are made, only a few millimeters long in the areolar area, using cannulas of 2.1 mm in diameter for application. This reduces visible scarring postoperatively.

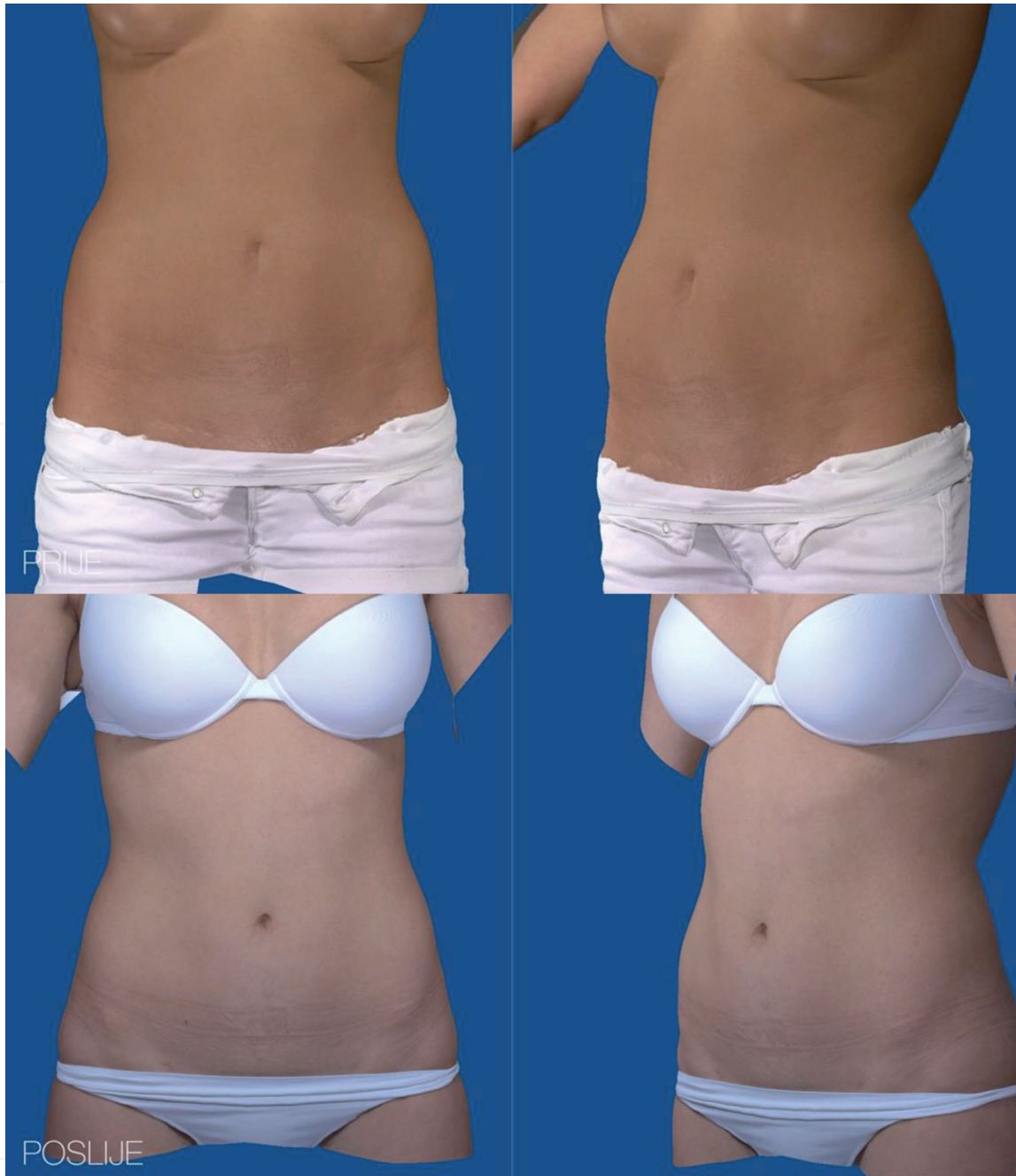


Figure 10.
Before and one year after VASER liposuction.

4.6 Thighs: men and women

Corrective thigh area procedures are rarely sought by men, this is a more problematic area for women. The upper thighs area is more pronounced, visually with clusters of fatty tissue, cellulite, forming distortions of the skin and contour. The procedure here is to reduce the volume in the front and side areas [4]. Tumescent fluid ordinarily used is 1–2 liters on each leg. VENTX Port diameter size is 3.7 mm, while the VASER device should be set at 50% at a continuous fluid injection stream. Port incisions are made at the groin and knees, medially in the inner thigh area. One placed at the groin, while two are placed lower halfway down towards the knee and at knee level. Liposuction time is again 20–30 minutes per side. Careful care should be taken, to avoid excessive liposuction in this area, because it can lead to the onset of “cutis marmorata” (marbled skin) [23]. Attention should be directed to sagging skin, and in selected cases surgical reduction may be required to tighten the

area. Ordinarily, the knees are concurrently defined when the thighs are performed (**Figures 11 and 12**).

4.7 Calves: men and women

The calf, as well as the thigh region, is rarely corrected in males. If performed, it would be similarly done as in women. Incisions are placed in both the knee areas, posterior centrally (poplitea fossa), and in the upper ankle area medially, and at times laterally. This depends on the degree of tissue accumulation and reduction needed to be performed [4]. VENTX ports should be of a narrower diameter, 2.9 mm, the VASER device should be set at 50%, tumescent fluid used should be maximally up to 1 liter, waiting time is 10–15 minutes, and liposuction duration can be 20–30 minutes per side. Performing in this area depends on the thigh volume. This region when done can be swollen for an extended period. Drainage from the

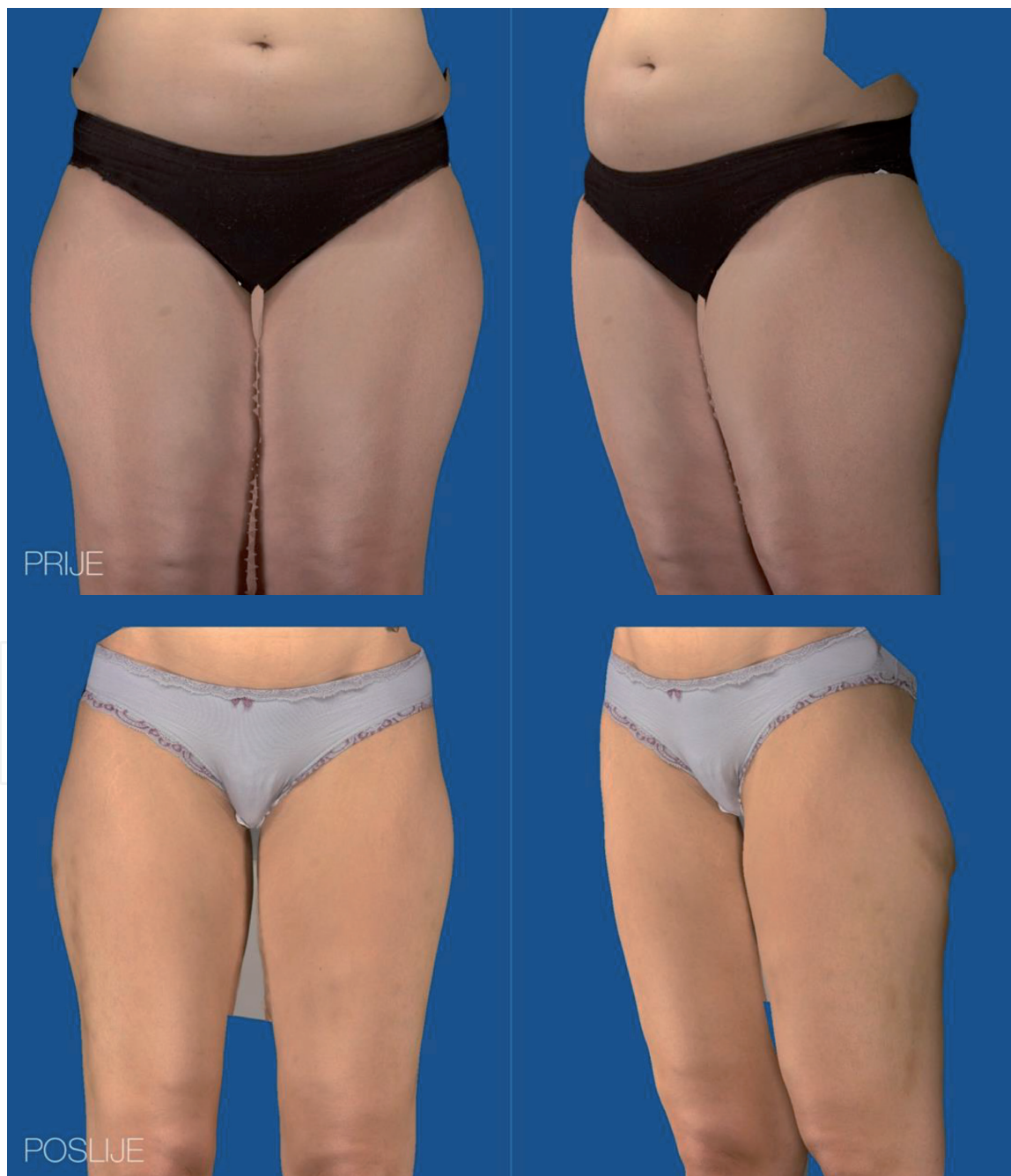

Figure 11.
Before and 6 months after VASER liposuction – Front view.

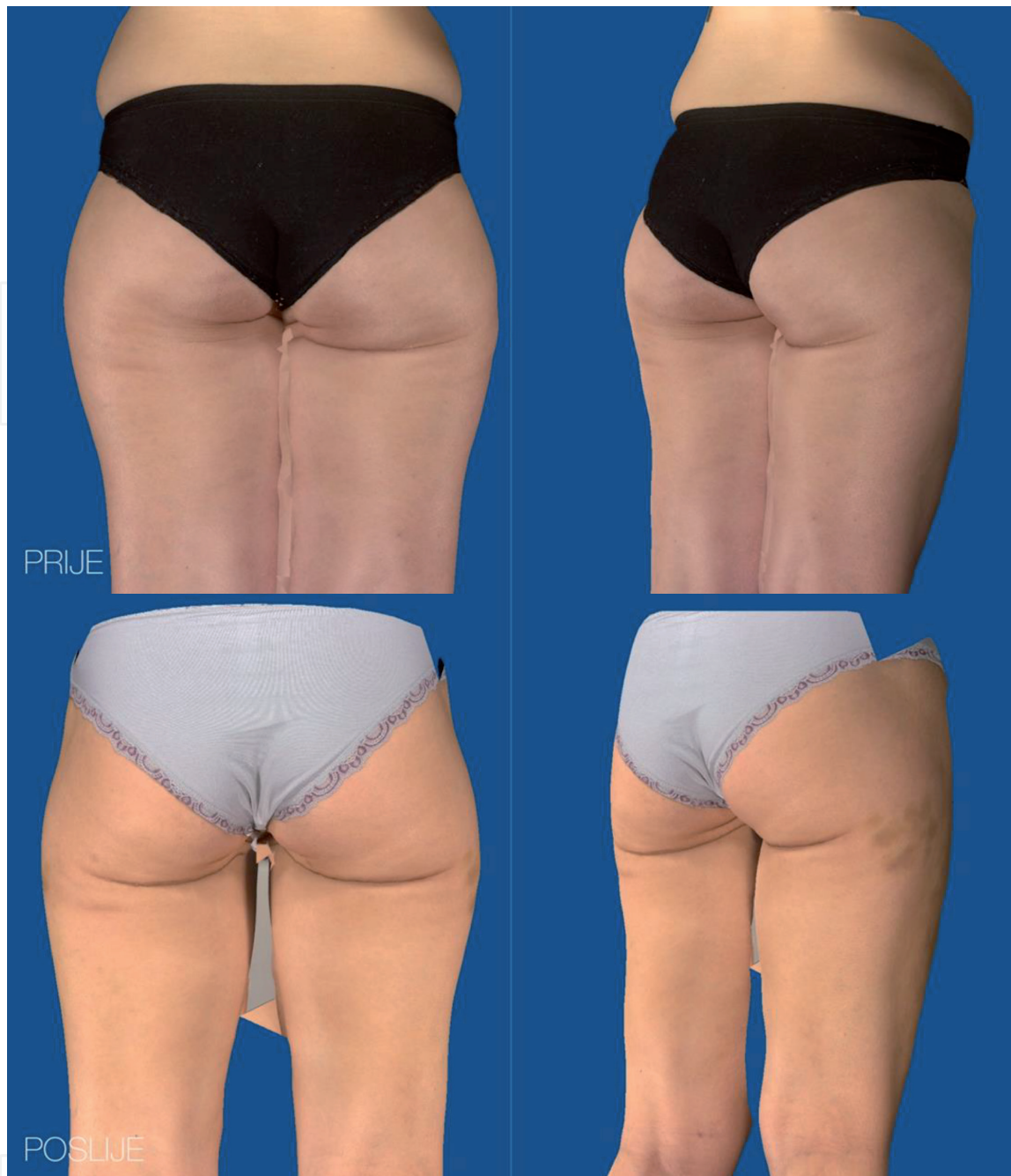

Figure 12.
Before and 6 months after VASER liposuction – Back view.

thighs adds to this accumulation. Peripherally performed sites need more healing time and lymphatic drainage is disturbed. Hence, this region is rarely performed.

4.8 Upper arms: men and women

The upper arm area can be combined with chest definition, in selected male cases. In women, the defining process area is the triceps region, often saggy and hanging. It is important in both sexes to define the muscles, for men more the upper section, while in women the lower upper arm portion. The process is similar in both sexes. VENTX ports are placed in the arm pits and elbow region. Taking care that postoperatively scars will be hidden in skin folds, and less visible. Port size should be 3.7 mm, using up to 1 liter of tumescent fluid on each side, with reduced power of VASER device at 50%, using VENTX cannulas for liposuction and if fibrous tissue is present, use the VASER 2–3 grooved cannulas for better extraction of fatty

tissue. Waiting times are similar as previous areas, 10–15 minutes with liposuction time of 20–30 minutes depending on visual achieved results.

4.9 Forearm: men and women

The forearm area is rarely requested as a corrective area from clients. As such, it is rarely performed. However, in the event this would be necessary to perform tumescent fluid of 200–500 mLs would be used. VENTX ports of a narrower diameter of 2.9 mm would be appropriate and placed in visually conspicuous areas. The VASER device should be at a reduced strength of 50%, using a 3 grooved cannula for liposuction. Waiting times again would be 10–15 minutes, with liposuction time of 20 minutes or more depending on desired results. Great care should be taken to stay away from the skin surface, to avoid breaking through and causing potential scarring.

5. Results

At Polyclinic Bagatin, there have been 409 VASER liposuctions performed in the last 9 years, including combination procedures with surgical resections. In about 15% of the cases, they involved male clients. The most frequent areas treated were the chest, abdominal wall, and lower back area. There were a few double chin procedures, as well. In women, most often VASER liposuction was performed on the abdominal wall, upper back area, hips and lower inside sections of the thighs. Patient postoperative monitoring lasted from 3 months to a year, or even more in certain cases. In both sexes, relatively few complications were encountered. The few seen were slight burns involving areas where ports were positioned, skin color changes, irregularities in the skin as depressions, dimpling or bulges, and some hardness, involving fat necrosis. In two cases, the thermal burns were caused at the ports and usage of over-heated tumescent fluid. Therefore, careful preparation and caution must be used throughout the VASER liposuction process. In 10% of the cases, additional corrections were necessary to achieve the desired results. Adjuncts used to enhance definition and contouring were the non-invasive Med2Contour, Zeron cold laser and the Venus Legacy radiofrequency methods. If liposuction was needed for addition touch up corrections, this was performed a year later. This would also include fat grafting to improve results. It was important to wait a year before redoing liposuction to give the body tissues time to heal and settle down into their new positions. This provided a more accurate visual of what needed to be corrected and exactly where to concentrate the liposuction correction. Patient satisfaction is the key. At Polyclinic Bagatin, patient satisfaction surveys show great percentage levels of satisfaction. Clients frequently recommend our clinic to others, as well as, continue their care and use many of our services offered.

6. Discussion

VASER liposuction itself can achieve great results. The combination of other liposuction methods and surgical methods, adds to the enhancement of desired results. Abdominoplasty is often combined with liposuction in correcting the abdominal area. Procedures to be performed depend on what clients prefer and want. It is the role of the plastic surgeon to explain what can and cannot be achieved, and what will yield the best results for individual cases. Patient satisfaction is a key part of what Polyclinic Bagatin strives for. The best commercial is a happy client.

In general, any liposuction technique used should be tapered to each client specifically. Of course, there are standard procedures and preparations to be followed.

Careful selection of port entries, tumescent fluid amounts, duration and extraction times should be used and again modulated for each case. The amount of tumescent fluid used can vary and is tapered to each case, especially if more than one region is being corrected. It is important to take the time to prepare well, and results will usually follow.

7. Conclusion

The method of VASER liposuction is an excellent technique to treat areas that previously were difficult to treat. Better depth control, VASER device strength and flow, and overall better tissue reduction are achieved by this technique. This is most certainly the case with difficult fibrous scar tissue, which has a level of skin retraction, thus needing increased device strength to be applied [24]. This method enables fatty tissue removal, in a far more efficient way, as well as, being less traumatic, than with just liposuction. This leads to fewer complications, like bleeding, distortion, breakthrough scarring, and a better recovery. The pain levels can be similar using either method, this can be alleviated by medications. Bruising can last 2–3 weeks. Drains are necessary to assist in carrying off collected excess fluids and secretions, and this can be up to 10 days. Recovery of patient with more extensive liposuction regions performed will need 7 or more days. The dosage of strength and action of flow (continuous or intermittent) using VASER technology has enabled more natural results. With every procedure performed, increased experience is gained. Combining various available methods and knowing specific tissue anatomy can help us create our goal of naturally defined body contours. VASER liposuction is a great and safe method, offering best results, at our disposal [25, 26].

Author details


Dinko Bagatin^{1,2*}, Tomica Bagatin^{1,2}, Judith Deutsch^{1,2}, Katarina Sakic^{1,2},
Johann Nemrava^{1,2}, Eduardo Isomura^{1,2} and Martina Sarec Ivelj^{1,2}

1 Poliklinika Bagatin, Zagreb, Croatia

2 Faculty of Dental Medicine and Health Osijek, University of Josip Juraj
Strossmayer, Osijek, Polyclinic Bagatin, Zagreb, Croatia

*Address all correspondence to: dinkobagatin@gmail.com

IntechOpen

© 2021 The Author(s). Licensee IntechOpen. This chapter is distributed under the terms of the Creative Commons Attribution License (<http://creativecommons.org/licenses/by/3.0>), which permits unrestricted use, distribution, and reproduction in any medium, provided the original work is properly cited. 

References

- [1] Zocchi ML. Ultrasonic assisted lipoplasty. Technical refinements and clinical evaluations. *Clin Plast Surg* 1996;23(4):575-598 (1)
- [2] Cimino WW. History of ultrasound-assisted lipoplasty. In: Shiffman MA, Di Giuseppe A, eds. *Body contouring: art, science, and clinical practice*. Berlin: Springer; 2010:399
- [3] Cimino WW. Ultrasonic surgery: power quantification and efficiency optimization. *Aesthet Surg J* 2001;21(3):233-241
- [4] Hoyos AE, Millard JA. VASER-assisted high-definition liposculpture. *Aesthet Surg J* 2007;27(6):594-604 (2)
- [5] Scuderi N, Devita R, D'Andrea F, Vonella M. Nuove prospettive nella liposuzione la lipoemulsicazione. *Giorn Chir Plast Ricostr ed Estetica* 1987;2(1):33-39
- [6] Schafer ME, Hicok KC, Mills DC, Cohen SR, Chao JJ. Acute adipocyte viability after third-generation ultrasound-assisted liposuction. *Aesthet Surg J* 2013;33(5):698-704
- [7] Jewell ML, Fodor PB, de Souza Pinto EB, Al Shammari MA. Clinical application of VASER-assisted lipoplasty: a pilot clinical study. *Aesthet Surg J* 2002;22(2):131-146 (3)
- [8] de Souza Pinto EB, Abdala PC, Maciel CM, dos Santos FdeP, de Souza RPM. Liposuction and VASER. *Clin Plast Surg* 2006;33(1):107-115, vii
- [9] Miller DL, Smith NB, Bailey MR, Czarnota GJ, Hynynen K, Makin IR; Bioeffects Committee of the American Institute of Ultrasound in Medicine. Overview of therapeutic ultrasound applications and safety considerations. *J Ultrasound Med* 2012;31(4):623-634
- [10] Panetta NJ, Gupta DM, Kwan MD, Wan DC, Commons GW, Longaker MT. Tissue harvest by means of suction-assisted or third-generation ultrasound-assisted lipoaspiration has no effect on osteogenic potential of human adipose-derived stromal cells. *Plast Reconstr Surg* 2009;124(1):65-73
- [11] Glaser DA, Kaminer MS (2005) Body dyismorphic disorder and the liposuction patient. *Dermatol Surg* 31(5):559-560.
- [12] Hunstad, JP, Repta, R. Liposuction in abdominal Contouring. In: Hunstad, JP, Repta, R, eds. *Atlas of Abdominoplasty*. Philadelphia, Pa: Saunders Elsevier; 2009:15-24.
- [13] Alfredo E. Hoyos et al. *High Definition Body Sculpting. Art and Advanced Lipoplasty Techniques*. Springer Verlag Berlin Heidelberg 2014.
- [14] Levin N (2007) Preanesthetic assessment of the cosmetic surgery patient. In: Friedberg BL (ed) *Anesthesia in cosmetic surgery*. Cambridge University Press, cCambrige, p 172.
- [15] Shapiro FE (2008) Anesthesia for outpatient cosmetic surgery. *Curr Opin Anesthesiol* 21(6):704-710.
- [16] Matarasso SI (1999) Liposuction of the chest and back. *Dermatol Clin* 17(4):799-804, vi
- [17] Mendieta CG (2011) Evaluation based on anatomic landmarks. In: *The art of gluteal sculpting*. Qualiti Medica Publishing, St. Louis, p 10.
- [18] Mendieta CG (2003) Gluteoplasty. *Aesthetic Surg J* 23(6): 441-455
- [19] Prendergast PM (2011) Liposculpture of the abdomen in a n office-based practice. In: *Body*

contouring. Art, science and clinical practice. Springer, Berlin.

[20] Hoyos A, Perez M (2012) Dynamic-definition male pectoral reshaping and enhancement in slim, athletic, obese, and gynecomastic patients patients through selective fat removal and grafting. *Aesthetic Plast Surg* 36(5): 1066-1077

[21] Hammond DC, Arnold JF, Simon AM, Capraro PA (2003) Combined use of liposuction with pull-through technique for the treatment of gynaecomastia. *Plast Reconstr Surg* 112(3):891-895

[22] Coleman SR, Saboeiro AP (2007) Fat grafting to the breast revisited: safety and efficacy. *Plast Reconstr Surg* 119(3):775-785; discussion 786-787.

[23] Rogerio Porto da Rocha, Elke Lusmoller Porto da Rocha, Ewaldo Bolivar de Souza Pinto, Angelo Sementilli, Carla Patricia Nakanishi
Cutis Marmorata Resemblance After Liposuction *Aesth. Plast. Surg.* 29:310-312, 2005

[24] Hoyos A, Perez M (2012) Arm dynamic definition by liposculpture and fat grafting. *Aesthet Surg J* 32(8):974-987

[25] De Souza Pinto Eb, Indaburo PE, Da Costa Muniz A, Martinez YP, Gerent KMM, Iwamoto H, Marao Miziara AC (1996) Superficial liposuction: body contouring. *Clin Plast Surg* 23(4): 529-548

[26] Gutowski KA, ASPS Fat Graft Task Force (2009) Current applications and safety of autologous fat grafts: a report of the ASPS fat graft task force. *Plast Reconstr Surg* 124:272-280