

We are IntechOpen, the world's leading publisher of Open Access books Built by scientists, for scientists

5,500

Open access books available

136,000

International authors and editors

170M

Downloads

Our authors are among the

154

Countries delivered to

TOP 1%

most cited scientists

12.2%

Contributors from top 500 universities



WEB OF SCIENCE™

Selection of our books indexed in the Book Citation Index
in Web of Science™ Core Collection (BKCI)

Interested in publishing with us?
Contact book.department@intechopen.com

Numbers displayed above are based on latest data collected.
For more information visit www.intechopen.com



Colonoscopy after Diverticulitis

Jeremy Meyer and Frédéric Ris

Abstract

Patients suffering from diverticulitis are at increased risk for colorectal cancer and should undergo colonoscopy to rule out colorectal cancer. The prevalence of colorectal cancer in this population was estimated to range between 1.9 and 2.3%. This prevalence is higher in patients with complicated diverticulitis (abscess, perforation) and ranges between 6.1% and 7.9%. Therefore, interval colonoscopy is strongly recommended after an episode of complicated diverticulitis. The prevalence of colorectal cancer is lower in patients with uncomplicated diverticulitis and approaches the prevalence from screened populations. In patients with uncomplicated diverticulitis, the indication for colonoscopy is still a matter of debate and should be done on a case-by-case basis.

Keywords: Colonoscopy, endoscopy, sigmoidoscopy, diverticulitis, diverticular disease, colorectal cancer

1. Introduction

Diverticulitis is defined as the inflammation of a diverticulum confirmed by imaging and associated with compatible clinical presentation and laboratory tests [1].

First imaging modalities for diverticulitis included plain film radiography of the abdomen, contrast enema and abdominal ultrasound. However, due to their low sensitivity and specificity for the diagnosis of diverticulitis, these imaging techniques became quickly supplanted by computed tomography (CT). CT features of acute diverticulitis consist in signs of local inflammation [2], such as thickening of the colonic wall close to the diverticulum, peri-diverticulum and/or peri-colonic fat stranding and, in case of perforation, peri-colonic or distant air bubbles, peri-colonic abscess, pelvic fluid or extra-colonic feces.

Several classifications systems have been developed based on CT findings [3, 4], such as the Neff classification [5], the Kaiser classification [6] and the Hansen-Stock [7] classification. However, the most commonly used classification system is the hybrid score (both radiological and clinical) of Hinchey modified by Wasvary [8]. Classification of diverticulitis tailors its therapeutic management. More commonly, diverticulitis is usually classified into uncomplicated diverticulitis and complicated diverticulitis [1]. Uncomplicated diverticulitis is defined as the local inflammation of a diverticulum (and its associated segment of bowel) without any sign of perforation and/or abscess (corresponding to modified Hinchey 1a [8]), whereas complicated diverticulitis is defined as an acute diverticulitis with a covered perforation [9–12] (Hansen-Stock I/IIa [7]), with a paracolic abscess (modified Hinchey

1b [8]), with a distant abscess (Hinchey II [8]), or with a purulent (Hinchey III [8]) or fecal peritonitis (Hinchey IV [8]).

According to the Global Burden of Disease Study, the number of incident cases of colorectal cancer (CRC) was of 1.8 million for year 2017, with a 9.5% increase in the age-standardized incidence rate within 30 years. Moreover, CRC accounted for 896,000 deaths and 19 million disability-adjusted life-years in 2017 [13]. As a consequence, several countries have implemented screening programs, either with fecal tests and/or with colonoscopy, which allowed reducing the incidence of CRC (by removing polyps) and the mortality related to CRC (by early detection of CRC) [14]. Despite these public health interventions, CRC is often still discovered by CT protocolled to investigate weight loss, iron-deficiency anemia, change in bowel habits and/or abdominal pain. If suspicion for CRC is raised on CT, flexible sigmoidoscopy or colonoscopy are requested to confirm the diagnosis with biopsies, tattoo the lesion for potential surgery and rule out any additional synchronous CRC.

However, in patients presenting with abdominal pain and/or sepsis in the acute setting, interpretation of the CT becomes more difficult, especially in the presence of diverticular disease, whose prevalence is increasing with aging. For the radiologist and for the surgeon, distinguishing with certitude between diverticulitis and CRC is not always possible, as both pathologies share similar imaging features of local and/or distant inflammation [15–17].

Considering the difficulty in ruling out CRC based solely on CT in patients initially diagnosed with diverticulitis, recommendations have emerged in favor of interval colonoscopy after diverticulitis.

2. Colonoscopy in patients with diverticular disease

The incidence of CRC was found to be increased by 5.8-fold in patients with diverticular disease when compared to reference patients without diverticular disease [18]. However, this risk was reported to be more important within the early period after diverticular disease-related hospitalization, before decreasing to the incidence of the reference population after 2 years [19, 20]. Therefore, it is likely that the increased risk of CRC observed in the short-term follow-up period reflects initial misdiagnosis of CRC as a diverticular disease-related complication (such as diverticulitis), rather than a true long-term risk for CRC. A systematic review and meta-analysis of cross-sectional studies (450,953 patients) found no association between diverticular disease and advanced colorectal neoplasia [21]. As a consequence, colonoscopy is currently not recommended in patients with uncomplicated diverticular disease, as this population is not at increased risk for CRC.

3. Colonoscopy after diverticulitis

The primary indication for performing colonoscopy after diverticulitis is to rule out CRC, with the rationale that patients with diverticulitis are at increased risk for CRC. Therefore, numerous observational studies have reported the prevalence and/or the incidence of CRC in patients diagnosed with diverticulitis, and were pooled into several systematic reviews with/without meta-analyses [22–27].

A recent and large systematic review and meta-analysis pooling both observational studies and population-based studies (50,445 patients) estimated the pooled

prevalence of CRC to be of 1.9% in patients initially diagnosed with diverticulitis. This prevalence was of 2.3% when performing subgroup analysis including only studies based on colonoscopy. Moreover, the pooled prevalences of polyps, advanced adenomas and adenomas were estimated to be of 22.7%, 4.4% and 14.2%, respectively [25]. Another meta-analysis pooling only diverticulitis patients who underwent colonoscopy estimated the prevalence of CRC to be of 2.1%, and the prevalence of advanced colorectal neoplasia to be of 6.9% [24].

The incidence of CRC in diverticulitis patients is therefore higher than the incidence encountered in colonoscopy screening programs (which is approximately of 0.8% [28]). A recent observational study with a good sample size reported that patients with diverticulitis were at significantly higher risk (prevalence of 2.9%) for CRC than patients from a local colonoscopy register (prevalence of 0.3%) [29]. Moreover, patients who undergo colonoscopy are already considered at higher risk for CRC, as they were entered into the program due to either positive fecal test and/or red flags for CRC. The prevalence of CRC in this population may therefore be overestimated and not reflect the prevalence in the general population.

To ensure that patients suffering from diverticulitis are effectively at increased risk for CRC and should be targeted by endoscopic screening, the incidence of CRC in this population was compared to the incidence of CRC in a reference population, and was found to be 20 to 44-fold more important than in reference matched patients [30, 31].

Therefore, the current recommendation is that patients with diverticulitis should undergo colonoscopy to rule out CRC at least 6 weeks after the episode if no colonoscopy was done within the last 3 years. However, this recommendation differs depending on the severity of the diverticulitis episode [1].

4. Colonoscopy after uncomplicated diverticulitis

Uncomplicated diverticulitis is defined as diverticulitis without any evidence for abscess and/or perforation.

In this population, the prevalence of CRC was estimated to be of 1.3% by one large meta-analysis [25] and of 0.5% by a meta-analysis selectively including patients who underwent colonoscopy [24]. The prevalence of CRC in patients with uncomplicated diverticulitis is therefore low and close to the prevalence reported by colonoscopy screening programs (0.8% [28]). Of note, one study reported that the prevalence of CRC was of 1.2% in patients with uncomplicated diverticulitis versus 0.6% in patients from a CRC colonoscopy screening program, this difference not reaching significance [32]. Therefore, several authors have recommended to dispense patients with uncomplicated diverticulitis from colonoscopy. However, the interpretation of these data may be limited by the overestimation of the prevalence of CRC in patients from screening programs, which may not reflect the prevalence in the general population, and by heterogeneity of studies in the field.

Looking more specifically at studies which compared the incidence of CRC in patients with uncomplicated diverticulitis to the incidence of CRC in the general population, patients with uncomplicated episode may still constitute a population at risk for CRC. For instance, one study reported the incidence of CRC to be 40-fold higher in patients with uncomplicated diverticulitis than in age- and gender-matched reference patients, but was limited by a low number of incidental cases [31]. Another study documented an incidence that was 20-fold

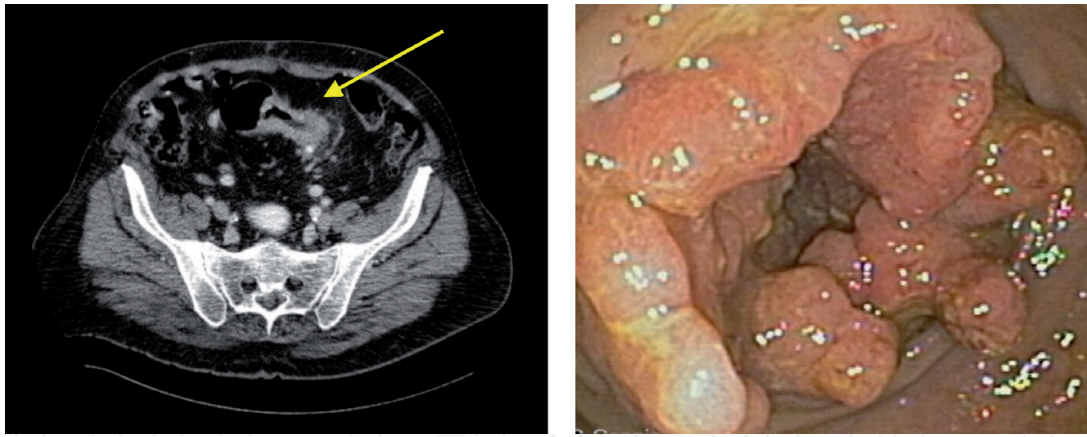


Figure 1.

Sixty-four year old female patient who presented with abdominal pain in the left iliac fossa and iron-deficiency anemia. Computed tomography reported an uncomplicated diverticulitis of the sigmoid colon (left, arrow). Flexible sigmoidoscopy found a suspect lesion at 23 cm from the anal verge (right), whose biopsies came back positive for an adenocarcinoma. The patient underwent a high anterior resection. Pathology of the operative specimen was pT3N2 (4/35).

higher in diverticulitis patients, but the study population was not limited to patients with uncomplicated diverticulitis and included all patients who had conservative management [30]. Finally, a population-based study cross-matched with data from the Cancer Registry of Norway estimated the standard morbidity ratio for CRC to be of 6.58 for patients with uncomplicated diverticulitis when compared to reference patients [33], therefore suggesting an increased risk in this population.

Moreover, colonoscopy carries a risk of complications [34]. For instance, the incidence of colonoscopy-related perforation was estimated to range between 0.09% [35] and 0.19% [36], and perforation was shown to significantly increase mortality when compared to patients without perforation [36]. Further, the cost per colonoscopy was recently evaluated to range between 188.6 USD and 501.2 USD (for purchase, maintenance and processing) [37, 38]. When considering that approximately 15 millions colonoscopies were performed in 2012 in the USA [39], targeting at risk populations is key to avoid increasing the costs for healthcare systems.

Considering the conflicting results regarding the prevalence of CRC in patients with uncomplicated diverticulitis, as well as the morbidity and cost of colonoscopy, the indication to perform colonoscopy after an episode of uncomplicated diverticulitis has remained controversial. Current guidelines recommend to do it on a case-by-case basis and to reserve it to symptomatic patients (**Figure 1**) [1, 40].

5. Colonoscopy after complicated diverticulitis

Complicated diverticulitis is by definition associated with abscess and/or perforation.

Radiological studies showed that abscess and perforation on CT are predictors for CRC [16, 22, 41–43]. Meta-analyses have estimated that the incidence of CRC in patients with complicated diverticulitis ranges between 6.1% [27] and 7.9% [25], and is 5–16.3 fold more important than in patients with uncomplicated diverticulitis [25, 27, 33].

Therefore, it is currently agreed that patients with complicated diverticulitis should undergo colonoscopy to rule out CRC (**Figure 2**) [1].

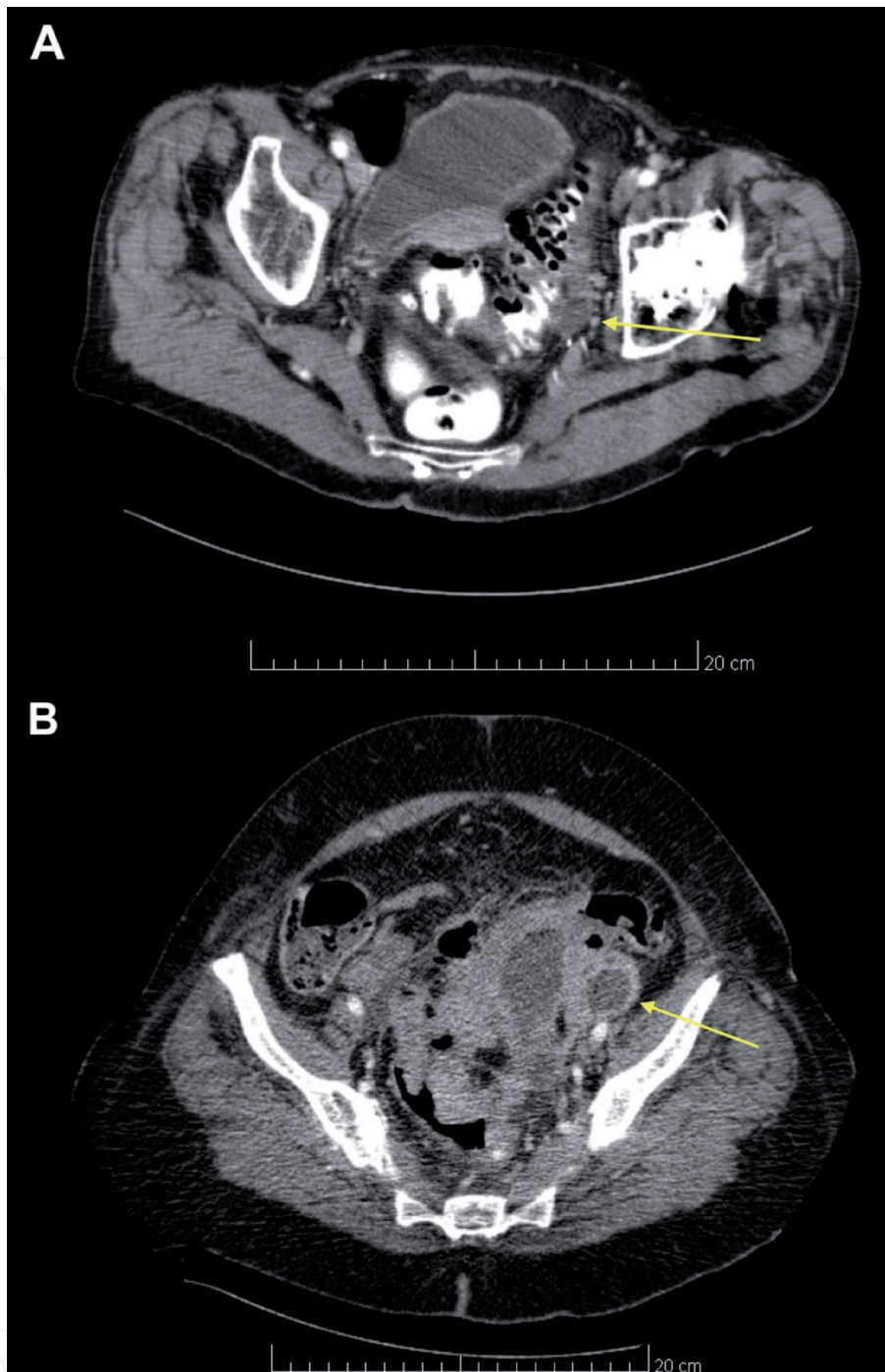


Figure 2. (A) Ninety year old female patient who presented with acute abdominal pain in the left iliac fossa and localized guarding. Computed tomography showed a 3 cm paracolic abscess (arrow), and the episode was classified as Hinchey 1b. Due to poor response to conservative management, the patient underwent Hartmann procedure. Examination of the operative specimen found a pT1 No adenocarcinoma arising from a polyp close to the perforated diverticulum. (B) Eighty-five female patient who presented with lower abdominal pain. Computed tomography found a large paracolic abscess (arrows), and the episode was classified as Hinchey 1b. The patient underwent percutaneous drainage, which allowed to completely drain the abscess. However, interval computed tomography described an apple core imaging of the sigmoid. Flexible sigmoidoscopy found a lesion of the sigmoid compatible with cancer, and biopsies came back positive for adenocarcinoma. The patient underwent oncologic Hartmann, and pathology of the operative specimen came back as pT4 N1 (2/20).

6. Conclusion

Due to increased risk for CRC, colonoscopy should be performed after acute diverticulitis in patients with complicated episode or who remain symptomatic after uncomplicated episode.

Conflict of interest

The authors declare no conflict of interest.

IntechOpen

IntechOpen

Author details

Jeremy Meyer* and Frédéric Ris
University Hospitals of Geneva, Geneva, Switzerland

*Address all correspondence to: jeremy.meyer@hcuge.ch

IntechOpen

© 2021 The Author(s). Licensee IntechOpen. This chapter is distributed under the terms of the Creative Commons Attribution License (<http://creativecommons.org/licenses/by/3.0>), which permits unrestricted use, distribution, and reproduction in any medium, provided the original work is properly cited. 

References

- [1] Schultz JK, Azhar N, Binda GA, et al. European Society of Coloproctology: guidelines for the management of diverticular disease of the colon. *Colorectal Dis* 2020;22 Suppl 2:5-28.
- [2] Kircher MF, Rhea JT, Kihiczak D, et al. Frequency, sensitivity, and specificity of individual signs of diverticulitis on thin-section helical CT with colonic contrast material: experience with 312 cases. *AJR Am J Roentgenol* 2002;178:1313-1318.
- [3] Klarenbeek BR, de Korte N, van der Peet DL, et al. Review of current classifications for diverticular disease and a translation into clinical practice. *Int J Colorectal Dis* 2012;27:207-214.
- [4] Feingold D, Steele SR, Lee S, et al. Practice parameters for the treatment of sigmoid diverticulitis. *Dis Colon Rectum* 2014;57:284-294.
- [5] Neff CC, vanSonnenberg E. CT of diverticulitis. Diagnosis and treatment. *Radiol Clin North Am* 1989;27:743-752.
- [6] Kaiser AM, Jiang JK, Lake JP, et al. The management of complicated diverticulitis and the role of computed tomography. *Am J Gastroenterol* 2005;100:910-917.
- [7] Hansen O, Graupe F, Stock W. [Prognostic factors in perforating diverticulitis of the large intestine]. *Chirurg* 1998;69:443-449.
- [8] Wasvary H, Turfah F, Kadro O, et al. Same hospitalization resection for acute diverticulitis. *Am Surg* 1999;65:632-635; discussion 636.
- [9] Garcia-Gomez MA, Belmonte-Montes C, Cosme-Reyes C, et al. [Prognostic value of the presence of pericolic air bubbles detected by computed tomography in acute diverticulitis]. *Cir Cir* 2017;85:471-477.
- [10] Bolkenstein HE, van Dijk ST, Consten ECJ, et al. Conservative Treatment in Diverticulitis Patients with Pericolic Extraluminal Air and the Role of Antibiotic Treatment. *J Gastrointest Surg* 2019.
- [11] Mora Lopez L, Serra Pla S, Serra-Aracil X, et al. Application of a modified Neff classification to patients with uncomplicated diverticulitis. *Colorectal Dis* 2013;15:1442-1447.
- [12] Meyer J, Caruso A, Roos E, et al. The clinical significance of extraluminal air in Hinchey 1a diverticulitis: results from a retrospective cohort study with 10-year follow-up. *Int J Colorectal Dis* 2019;34:2053-2058.
- [13] Collaborators GBDCC. The global, regional, and national burden of colorectal cancer and its attributable risk factors in 195 countries and territories, 1990-2017: a systematic analysis for the Global Burden of Disease Study 2017. *Lancet Gastroenterol Hepatol* 2019;4:913-933.
- [14] Cardoso R, Guo F, Heisser T, et al. Colorectal cancer incidence, mortality, and stage distribution in European countries in the colorectal cancer screening era: an international population-based study. *Lancet Oncol* 2021;22:1002-1013.
- [15] Chintapalli KN, Chopra S, Ghiatas AA, et al. Diverticulitis versus colon cancer: differentiation with helical CT findings. *Radiology* 1999;210:429-435.
- [16] Balthazar EJ, Megibow A, Schinella RA, et al. Limitations in the CT diagnosis of acute diverticulitis: comparison of CT, contrast enema, and pathologic findings in 16 patients. *AJR Am J Roentgenol* 1990;154:281-285.
- [17] Shen SH, Chen JD, Tiu CM, et al. Differentiating colonic diverticulitis

- from colon cancer: the value of computed tomography in the emergency setting. *J Chin Med Assoc* 2005;68:411-418.
- [18] Stefansson T, Ekblom A, Sparen P, et al. Increased risk of left sided colon cancer in patients with diverticular disease. *Gut* 1993;34:499-502.
- [19] Granlund J, Svensson T, Granath F, et al. Diverticular disease and the risk of colon cancer - a population-based case-control study. *Aliment Pharmacol Ther* 2011;34:675-681.
- [20] Huang WY, Lin CC, Jen YM, et al. Association between colonic diverticular disease and colorectal cancer: a nationwide population-based study. *Clin Gastroenterol Hepatol* 2014;12:1288-1294.
- [21] Lee HJ, Park SJ, Cheon JH, et al. The relationship between diverticulosis and colorectal neoplasia: A meta-analysis. *PLoS One* 2019;14:e0216380.
- [22] Sharma PV, Eglinton T, Hider P, et al. Systematic review and meta-analysis of the role of routine colonic evaluation after radiologically confirmed acute diverticulitis. *Ann Surg* 2014;259:263-272.
- [23] Sai VF, Velayos F, Neuhaus J, et al. Colonoscopy after CT diagnosis of diverticulitis to exclude colon cancer: a systematic literature review. *Radiology* 2012;263:383-390.
- [24] Rottier SJ, van Dijk ST, van Geloven AAW, et al. Meta-analysis of the role of colonoscopy after an episode of left-sided acute diverticulitis. *Br J Surg* 2019;106:988-997.
- [25] Meyer J, Orci LA, Combescure C, et al. Risk of Colorectal Cancer in Patients With Acute Diverticulitis: A Systematic Review and Meta-analysis of Observational Studies. *Clin Gastroenterol Hepatol* 2019;17:1448-1456 e17.
- [26] Daniels L, Unlu C, de Wijkerslooth TR, et al. Routine colonoscopy after left-sided acute uncomplicated diverticulitis: a systematic review. *Gastrointest Endosc* 2014;79:378-89; quiz 498-498 e5.
- [27] Koo CH, Chang JHE, Syn NL, et al. Systematic Review and Meta-analysis on Colorectal Cancer Findings on Colonic Evaluation After CT-Confirmed Acute Diverticulitis. *Dis Colon Rectum* 2020;63:701-709.
- [28] Niv Y, Hazazi R, Levi Z, et al. Screening colonoscopy for colorectal cancer in asymptomatic people: a meta-analysis. *Dig Dis Sci* 2008;53:3049-3054.
- [29] Tehranian S, Klinge M, Saul M, et al. Prevalence of colorectal cancer and advanced adenoma in patients with acute diverticulitis: implications for follow-up colonoscopy. *Gastrointest Endosc* 2020;91:634-640.
- [30] Grahnat CJ, Herard S, Ackzell A, et al. High Probability of an Underlying Colorectal Cancer Among Patients Treated for Acute Diverticulitis. A Population-Based Cohort Follow-Up Study. *World J Surg* 2016;40:2283-2288.
- [31] Meyer J, Thomopoulos T, Usel M, et al. The incidence of colon cancer among patients diagnosed with left colonic or sigmoid acute diverticulitis is higher than in the general population. *Surg Endosc* 2015;29:3331-3337.
- [32] Daniels L, Unlu C, de Wijkerslooth TR, et al. Yield of colonoscopy after recent CT-proven uncomplicated acute diverticulitis: a comparative cohort study. *Surg Endosc* 2015;29:2605-2613.
- [33] Azhar N, Buchwald P, Ansari HZ, et al. Risk of colorectal cancer following

CT-verified acute diverticulitis: a nationwide population-based cohort study. *Colorectal Dis* 2020;22:1406-1414.

[34] Kim SY, Kim HS, Park HJ. Adverse events related to colonoscopy: Global trends and future challenges. *World J Gastroenterol* 2019;25:190-204.

[35] Araghizadeh FY, Timmcke AE, Opelka FG, et al. Colonoscopic perforations. *Dis Colon Rectum* 2001;44:713-716.

[36] Gatto NM, Frucht H, Sundararajan V, et al. Risk of perforation after colonoscopy and sigmoidoscopy: a population-based study. *J Natl Cancer Inst* 2003;95:230-236.

[37] Larsen S, Kalloo A, Hutfless S. The hidden cost of colonoscopy including cost of reprocessing and infection rate: the implications for disposable colonoscopes. *Gut* 2020;69:197-200.

[38] Henry SG, Ness RM, Stiles RA, et al. A cost analysis of colonoscopy using microcosting and time-and-motion techniques. *J Gen Intern Med* 2007;22:1415-1421.

[39] Joseph DA, Meester RG, Zauber AG, et al. Colorectal cancer screening: Estimated future colonoscopy need and current volume and capacity. *Cancer* 2016;122:2479-2486.

[40] Rottier SJ, van Dijk ST, Boermeester MA. Author response to Comment on: Meta-analysis of the role of colonoscopy after an episode of left-sided acute diverticulitis. *Br J Surg* 2020;107:154.

[41] Sallinen V, Mentula P, Leppaniemi A. Risk of colon cancer after computed tomography-diagnosed acute diverticulitis: is routine colonoscopy necessary? *Surg Endosc* 2014;28:961-966.

[42] Brar MS, Roxin G, Yaffe PB, et al. Colonoscopy following nonoperative

management of uncomplicated diverticulitis may not be warranted. *Dis Colon Rectum* 2013;56:1259-1264.

[43] Lau KC, Spilsbury K, Farooque Y, et al. Is colonoscopy still mandatory after a CT diagnosis of left-sided diverticulitis: can colorectal cancer be confidently excluded? *Dis Colon Rectum* 2011;54:1265-1270.