

We are IntechOpen, the world's leading publisher of Open Access books Built by scientists, for scientists

5,500

Open access books available

136,000

International authors and editors

170M

Downloads

Our authors are among the

154

Countries delivered to

TOP 1%

most cited scientists

12.2%

Contributors from top 500 universities



WEB OF SCIENCE™

Selection of our books indexed in the Book Citation Index
in Web of Science™ Core Collection (BKCI)

Interested in publishing with us?
Contact book.department@intechopen.com

Numbers displayed above are based on latest data collected.
For more information visit www.intechopen.com



Radiotherapy in Oral Cancers: Current Perspective and Future Directions

A.S. Kirthi Koushik and Ram Charith Alva

Abstract

Oral cancers form one of the most common malignancies seen worldwide, with a steady increase in number over time. Surgery with the addition of adjuvant therapy forms the cornerstone of therapeutic management for these cancers. Despite excellent surgical management, loco-regional recurrences have always been of concern. This has expanded the role of radiotherapy, with concomitant therapies, allowing to establish an effective management protocol. Over the last two decades, there have been huge strides taken towards understanding these specific aspects and providing insight into the most fruitful application of radiotherapy in these patients. In this chapter, we have presented the oncologists perspective to dealing with the non-surgical aspects of oral cancer management. We have elaborated on the chronological order with which radiotherapy has evolved and provided the contemporary aspects of decision making, essential for current practice. The evidence-based approach will address all components of radiotherapy workflow from basic understanding of patient's anatomy, planning & evaluation during therapy to the outcomes & toxicity profiles to be expected in day-to-day clinics. Established guidelines have been incorporated into the graphical representations to ensure scenario-based understanding. Future perspectives, essential for identifying the possible direction of therapy & potential improvements in outcomes, have also been addressed.

Keywords: Oral cancers, Radiotherapy, Adjuvant, Definitive, Brachytherapy, Chemotherapy

1. Introduction

Oral cancers are one of the most well described & clearly detailed cancers in history, since the times of ancient Egyptian and Ayurveda (Sushruta) systems. Globally, as per the data released from International Agency for research on cancer (IARC), oral cancer occurs most commonly in middle- & low-income countries with worldwide incidence of 377,713 cases with 177,757 deaths seen in 2020. [1] The worldwide incidence rate is 4.1 cases per 100,000.

Since the evolution of modern contemporary management for oral cavity cancers, radiotherapy has played a pivotal role along with surgery and recently with chemotherapy in improving patient outcomes. After the milestone discovery of x-rays by Wilhem Roentgen in 1898, utility of radiation in various cancers was established. The role of radiotherapy in oral cancers specifically, developed between the two world wars, as the morbidity was less troublesome and was easier to deliver

in community hospitals. [2] However, as surgical processes got more flexible and easier to execute and the survival rates of patients receiving radiation alone were not very encouraging, radical surgery resurfaced as the primary modality for oral cancers mid-century. Also, concerns of long-term radiation morbidity affecting patient's quality of life, in those receiving conventional radiation as a sole modality came to the fore. Keeping this in mind, towards the end of the 20th century, development of newer technology was directed towards minimising these particular issues. Also, optimum and effective combinations between surgery & radiotherapy with or without the addition of chemotherapy, were slowly established as standards of care which have been thoroughly reviewed in this chapter.

In order to keep the options simple and to make the life of an oncologist simpler, one can divide oral cancers as early, locally advanced and metastatic disease. In this chapter, we will give an overview of the current understanding for the choice of treatment in these different categories with insight into the specific therapeutic aspects of both external & internal radiation therapy. We will also dwell upon the advances in recent research related to oral cancer management as well as the possible future directions from the prism of the new age radiation oncologist.

2. Basic aspects in oral cavity cancers

2.1 Anatomy from an oncologist perspective

In order to understand a disease, one needs to be well versed with the anatomy of the area and since we want to know the way this would influence a radiation oncologist's outlook, the following section will address anatomy from a radiation oncologists' perspective (**Figure 1**).

Oral cavity includes lips, buccal mucosa, gingivobuccal sulcus, superior and inferior alveolar ridges, teeth & mandible, oral tongue, floor of mouth (FOM),

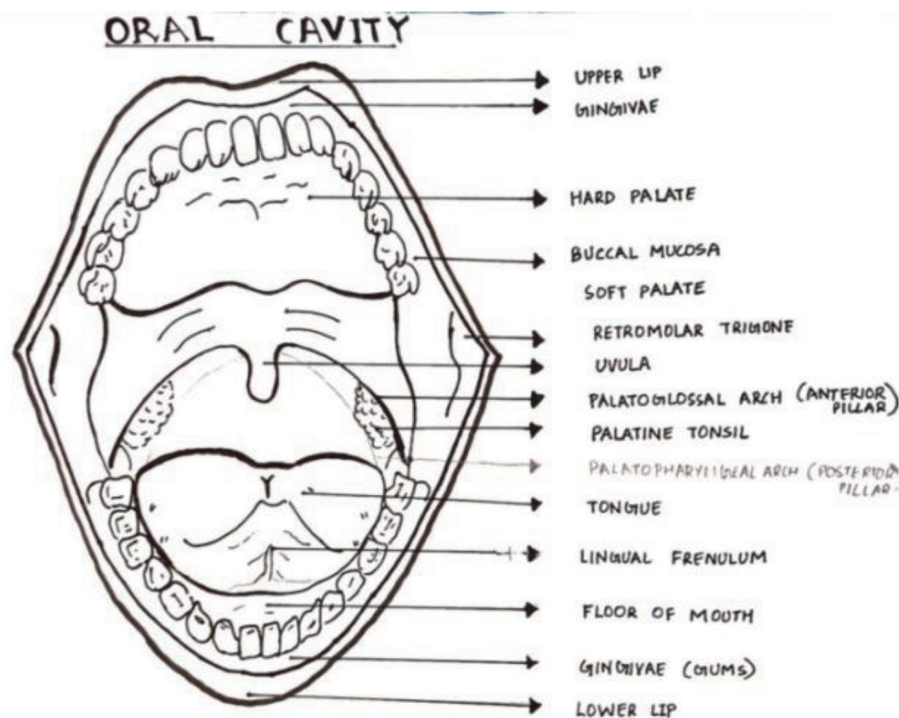


Figure 1.
Anatomical aspects of oral cavity.

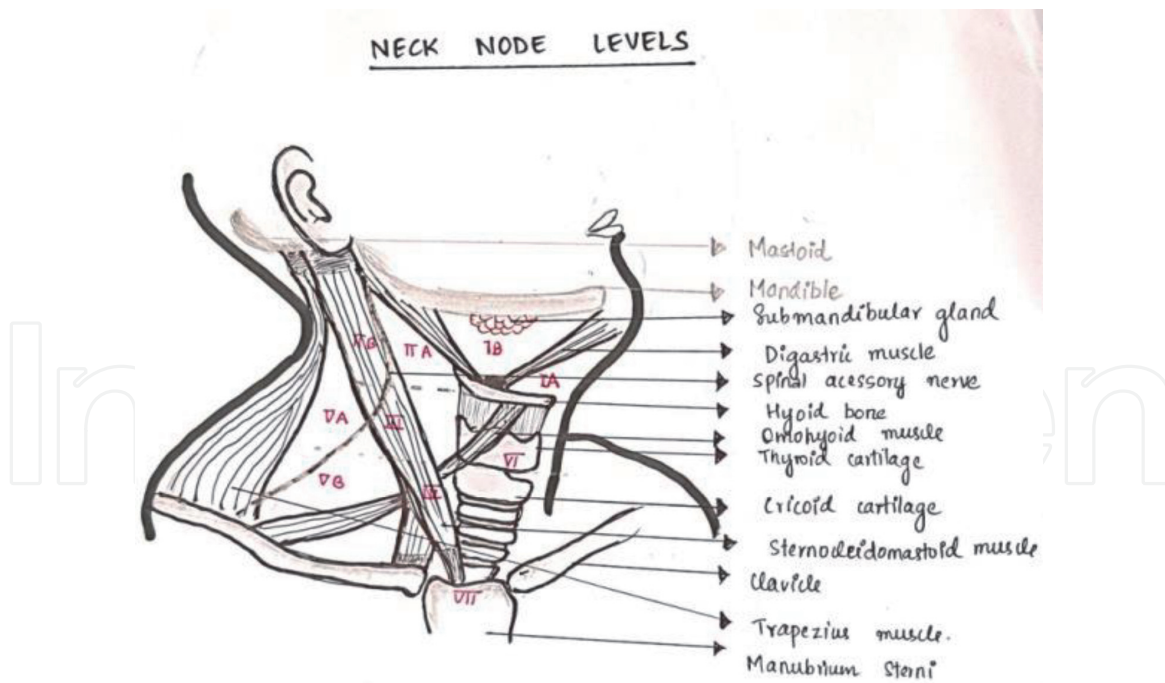


Figure 2.
Description of various nodal levels in the neck.

retromolar trigone (RMT) and hard palate. [3] One needs to know a few terminologies like buccal mucosa which means mucosal surface of lips and cheek, whereas gingival mucosa means mucosal lining of teeth, alveolar arches and gums. The area of maximum incidence of squamous cell carcinoma is at the gingivobuccal sulcus which is the junction of buccal mucosa to gingival mucosa. Floor of mouth is the U-shaped sling formed due to joining of two mylohyoid muscles to a fibrous median raphe. Oral tongue also known as Anterior 2/3rd of tongue includes the tip, lateral border and body which consists of intrinsic and extrinsic muscles. It is imperative to know the muscles as their involvement can upstage the disease, which will be discussed later in the chapter. Intrinsic muscles have no bony attachment and are divided into longitudinal, transverse and vertical groups. Extrinsic muscles do have a bony attachment and originate outside the tongue, and are made up of four paired bundles - genioglossus, hyoglossus, styloglossus and palatoglossus. These can be appreciated well on a CT scan and an MRI scans.

The most important feature of neoplasia is the potential for spread and the most common route of spread in oral cavity tumours is the lymphatic spread (**Figure 2**). Since radiotherapy is a branch which tackles locoregional disease it becomes imperative to have a thorough knowledge of the lymphatic drainage. In order to understand this better, we are dividing the lymphatic channels as functional pathways:

1. Main lymphatic pathway: submental → submandibular → anterior jugulodigastric → middle and lower deep cervical nodal groups → jugular collecting trunk
2. Posterior accessory pathway: posterior part of jugulodigastric group → middle and deep posterior cervical groups
3. Anterior lymphatic pathway: submental and jugulo-omohyoid → lower internal jugular nodes.
4. Superficial lateral pathway: occipital and mastoid group.

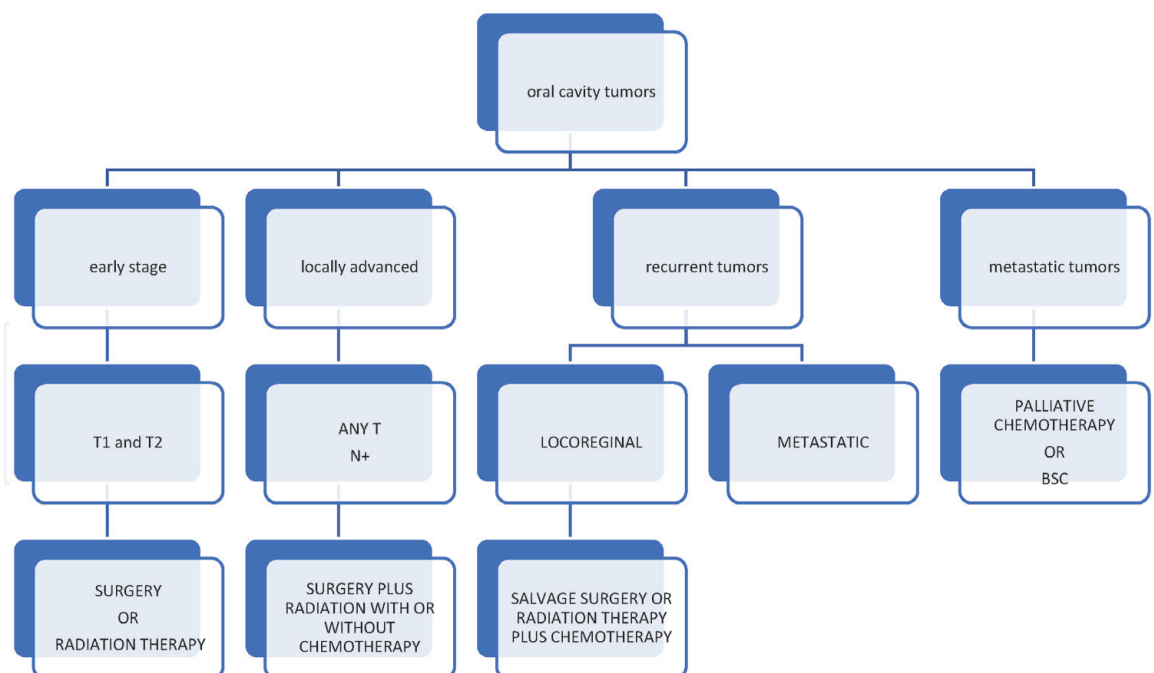


Figure 3.
Overview of management of Oral cancers.

2.2 Basic principles of treatment and broad guidelines

Radiotherapy is loco-regional form of treatment just like surgery. In oral cavity cancers one needs to keep in mind the functionality and cosmesis when deciding on the management, hence it requires a multidisciplinary team to take a call. For management and prognosis reasons, these tumours are divided in to early stage, locally advanced and metastatic tumours. The flow chart provides concise & definitive steps on how to manage oral cavity tumours. (Figure 3).

For any malignancy there are only three weapons and they are surgery, radiation therapy and systemic therapy. The sequencing and need of each therapy are a point of debate. However, in oral cavity tumours, mostly all modalities are required and sequencing is usually pre-determined and rationale is also established.

2.2.1 Early stage

As per TNM this group includes cT1 and cT2, which means localised tumours only. This group is usually tackled by surgery or radiation therapy and role of systemic therapy is limited (Table 1).

	Surgery	Radiation therapy	Rationale
Lip	Yes	Yes	Cosmetically better
Buccal mucosa	Yes	Yes	If localised and margins are clear
Tongue	Yes	No	Usually aggressive and depth can be better made out on hpe than mri
FOM	No	Yes	As organ preservation is better
RMT	No	Yes	As posterior margin will not be an issue

Table 1.
Rationale for application of radiotherapy in early oral cancers.

	Surgery +/- Radiation therapy	Rationale
LIP	Surgery followed by Radiation +/- Chemotherapy	As locally advanced one modality will not be able to achieve cure.
BUCCAL MUCOSA	Surgery followed by Radiation +/- Chemotherapy	Locally advanced diseases tend to recur locally
TONGUE	Surgery followed by Radiation +/- Chemotherapy	Usually aggressive and tend to recur locally as well as systemically
FOM	Radiation and chemotherapy	As organ preservation is better
RMT	Radiation and chemotherapy	As posterior margin will not be an issue

Table 2.
Rationale for combined modality therapy in advanced oral cancers.

2.2.2 Locally advanced disease

As per TNM this group will include cT1-4 and N+ disease. Basically, it means that the disease has spread to nodes and or direct extension to surrounding structures. This group has to be addressed by combined modality therapy and there will always be some amount of deliberation to be had about the sequencing of the three modalities (**Table 2**).

Recurrent tumours: a tumour can be suggested to have recurred if there is disease recurrence after a period of documented complete remission and usually it is taken as 2 follow-ups of 6 weeks apart with a period of 6 months post primary therapy. Based on this they can be:

1. Locally recurrent: the plan of treatment will depend on the primary therapy received and also the operability. Usually, it is important to reassess the disease to take a call on treatment. If the disease is operable, salvage surgery gives best results. If more than 2 years has elapsed post primary therapy, then radiation can also be advised based on site of recurrence.
2. Locoregionally recurrent: if the duration post primary therapy is more than 2 years and if operable then both salvage surgery with radiation can be offered or else based on the status the treatment can be tailored.
3. Metastatic: these are usually managed with palliative systemic therapy and role of radiation is limited to palliation to relieve the symptoms such as bleeding, pain or dysphagia.

In the following section we are going to address the basis of radiation, how it is delivered and what are the relevant toxicities encountered.

2.3 Basis for radiation

2.3.1 What is radiation?

One needs to remember that discovery of many great things happened by accident. Same thing holds good for practice of radiotherapy, as its use was established when Henry Becquerel left 200 mg of Radium in his vest pocket for 6 hours and later noted ulceration along the adjacent skin. This event opened the eyes of the

scientific community towards the clinical effects of radiation & radioactive sources. From then on, there were many experiments done to establish the role of radiation in treatment of malignancy.

Radiation is nothing but energy in the form of waves or stream of particles which can be explained by emission, propagation and absorption of energy. In the present day, most common form of radiation in use is X-rays though there are utilisation of gamma in brachytherapy and proton in particle therapy but in order to restrict ourselves to common terminologies we are not going in detail about them. This form of radiation is considered to have the ability to produce ions in the cells of tissues it passes through, by dislodging the electrons from atoms, and hence it is commonly called as ionising radiation.

If one needed to know the most basic principle about radiation, it would be that - "radiation is effective only on dividing cells". There are 5 phases that each cell goes through from $G_0 \rightarrow G_1 \rightarrow S \rightarrow G_2 \rightarrow M$. Among these G_2 & M phases are the most radiosensitive and S phase is the most radioresistant phase. The knowledge of these help in deciding on combination therapy and use of radiosensitisers. Radiation is usually delivered in a fractionated manner and it would be paramount to have the knowledge of the 4R's of radiation therapy to understand the basis for this fractionation:

- Repair: differential rate of repair between tumour & normal tissue cells, is what is utilised in fractionation
- Repopulation: this helps in normal tissues such that if one cell dies, then due to compensatory mechanisms other cells divide rapidly to replace this loss.
- Reoxygenation: oxygen is the most important component for both cell survival and also for effective action of radiation.
- Redistribution: as cell death happens there will be redistribution, making the cells in less radiosensitive phases to move to more radiosensitive phases, thus making radiation very effective and forms another basis for fractionation.

2.3.2 How is it delivered?

One can divide this based on technology, based on setting and based on type. The following flowchart will briefly describe about it. (Figure 4).

Description of these commonly employed terminology are as follows

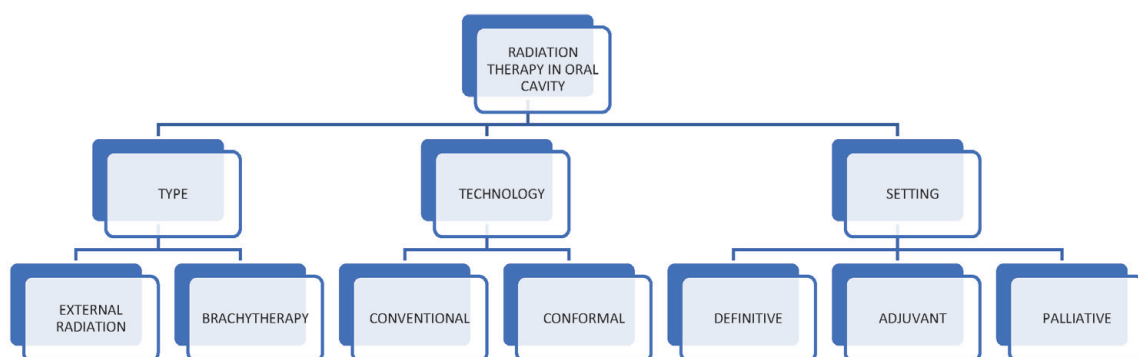


Figure 4.
Aspects of radiotherapy in Oral cancers.

1. External radiation: radiation delivered from a distance away from the body is called external radiation and the unit that's commonly employed for this are known as linear accelerators. There are different types of radiation that are used such as X-rays, gamma rays and particle therapy like protons.
2. Brachytherapy: delivery of radiation in close proximity to or within the target tissue is known as brachytherapy. The usual sources used are Iridium192 and Cobalt60.
3. Conventional: it is the traditional way of radiation delivery, where the dose is delivered without much conformity and is based mainly on bony landmarks.
4. Conformal: it is a contemporary form of radiation delivery where in the conformity is good and avoidance of normal structures can be achieved.
5. Definitive: it means radiation is the main modality of treatment and it is used with an intent to cure.
6. Adjuvant: it means radiation is delivered post-surgery in order to mop up the most probable microscopic disease that is present.
7. Palliative: as the name indicates is to only tackle the symptoms and give relief.

3. Evidence based review on current management concepts in oral cavity cancers

3.1 Risk factors for locoregional recurrence

3.1.1 Risk factors which have been utilised traditionally

Oral cavity cancers are commonly managed with single modality treatment in early stages and a combined modality approach in advanced stages. Radical, oncologically-sound surgical approaches form the backbone of early cancers with a meticulous assessment of the histopathological specimen. Even with appropriate excisions, local and regional recurrences are an extremely concerning aspect which can alter the eventual outcomes in these cancers.

Many retrospective studies and single institution prospective trials demonstrated the benefit of adding radiation adjuvantly for oral cancer patients who have undergone radical surgery. Cooper et al. collated data from RTOG #85-03 & #88-24 to retrospectively sort into 3 risk groups of presumed progressive risk to enable adjuvant treatment decisions. [4] Group I included fewer than 2 involved nodes, no ECE & negative surgical margins. Group II included at least 2 involved nodes or presence of ECE of tumour with uninvolved margins. Group III included microscopically involved surgical margins. Accordingly, comparing outcomes in groups I to III, the loco-regional recurrence rates at 5 years was 17%, 27% & 61% and median survival was 5.6 yrs., 2.6 yrs. and 1.5 yrs. respectively.

Langendijk et al. used the Classification and Regression Tree(CART) or the Recursive Partitioning Analysis(RPA) method to construct homogenous subgroups of well-known prognostication parameters to be able to identify locoregional recurrence risk. [5] Accordingly, 801 patients were divided into RPA 1 group(Intermediate risk) which included no ECE and free surgical margins; RPA 2(High Risk) which included T1,T2 and T4 tumours with close or positive surgical margins or one

positive node with ECE and RPA 3 (Very High Risk) which included T3 tumours with close or positive margin, N3 neck or multiple nodes with ECE. The 5-year LRC was 92%, 78% and 58% and OS rates were 67%, 50% and 36% for the three RPA classes respectively.

Salama JK et al. used pooled multivariate analysis to give a consensus statement on use of adjuvant therapy in head and neck cancers. [6] They divided patients into two groups to identify their risk for developing loco-regional recurrences based on pathological features. High risk group included those with involved surgical margins and extranodal spread. Low risk group included other adverse features such as T3/4 tumours, perineural invasion, lymphovascular space invasion, multiple nodal involvement and lower neck adenopathy. They advised for postop radiotherapy alone for patients with low-risk features and addition of concurrent chemotherapy for those with high-risk features. They also suggested postop radiotherapy dose of upto 63Gy for high-risk features and 57Gy for those with low-risk disease.

Perineural Invasion (PNI): There is no standardised definition of this entity, but the most accepted one is when tumour cells are present in any one of the three layers of the nerve sheath & when tumour cells are in close proximity to the nerve & involves more than one-third of circumference. Bur et al. identified an incidence of PNI in literature of between 3 and 52%. [7] Though many authors have not been able to assign prognostic significance to presence of PNI, some features such as multiple foci of PNI, involvement of large nerves(>1 mm) and higher maximum extent of PNI were associated with increased local failure and reduced disease specific survival.

In the systematic review collated data from 13 retrospective studies, they identified local recurrence rates of 4.4% - 22.9%, regional recurrence rates of 12.3% - 30.8% and 5-yr overall survival estimates of 48-89.6% in those patients with presence of PNI. [7] In two studies from this review, where neck dissection was conducted, regional failure rates were 12.3% and 17.6% which undermines the fact of ineffective salvage options after this. However, the authors suggest that in the absence of any prospective trial to assess the impact of PNI on loco-regional recurrence or survival, it would be imperative to discuss the options of treatment in detail in those patients where positive PNI is the only risk factor post radical surgery.

Depth of Invasion (DOI): Tumour thickness or depth of invasion has been consistently identified as a predictor for cervical lymph node metastasis in oral cavity cancers. Oral cavity cancers have occult nodal metastases of up to 40% in clinically negative neck, which is usually managed with elective nodal dissection as opposed to just observation. Huang et al. in their meta-analysis, have tried to address this aspect and have concluded that the optimal cut-off point for DOI is 4 mm, to consider for neck management. [8]

In another study, Liao et al. followed-up patients who underwent surgery of early-stage oral cavity cancers(pT1-2 N0) to identify poor prognostic features and suggest for adjuvant therapy. [9] They found that poorly differentiated tumours and DOI of 4 mm and above were both independent poor prognostic factors, and when present together accounts for 2-yr regional failure of 42%. Hence, they suggest for the use of PORT in this subset of early OC cancers.

Bulbul et al. conducted a meta-analysis of 8 studies (1427 patients), which used frozen section (FS) evaluation to define margin status in early(T1/2N0) oral cavity cancers. [10] They compared positive/close FS margins which was cleared by further resection (R1 – R0), positive margin not cleared (R1) to those with negative margins upfront (R0). They found that patient with R1-R0 had poorer local recurrence free survival (LRFS) when compared to R0, regardless of clearance which was statistically significant. Furthermore, R1-R0 patients showed almost equal LRFS to

that of R1, though the trend to worse result was with R1 patients. They concluded that upfront positive/close margin was a marker of a locally aggressive disease regardless of re-resection & correction. They also indicated that there should be standardisation of the FS sampling method too.

3.2 Surgery followed by radiotherapy

The value of postoperative radiotherapy (PORT) for advanced head & neck cancers, was established in 1970's with few well researched studies. [11] Marcus et al. suggested doses for OC cancers of 6500Rads to achieve high local control and up to 7000rads for those with positive surgical margins. [12]

Outcomes in locally advanced cancers are suboptimal with primary failure being loco-regional relapses. Hence combined modality treatments have been employed to counter this aspect as well as to ascertain if they added to overall survival patterns too. Lavaf et al. retrospectively analysed data from the Surveillance Epidemiology End Results (SEER) data base to collate results on 8795 lymph node positive cases of advanced head and neck cancers. [13] They found addition of adjuvant radiotherapy in these patients improved 5 yr. overall survival rates (43.2% vs. 33.4%; $p < 0.001$) and cause specific survival rates (50.9% vs. 42.1%).

Kao et al. did a similar SEER group analysis of advanced cancers of head and neck region and specifically tried to address benefit of RT with respect to various nodal stages and specific sites of disease. [14] Subset analysis found that all nodal stages, including N1 Disease, has improved survival with the addition of adjuvant RT. Also, in multivariate analysis, addition of RT in node positive oral cavity tumours improved overall survival [HR, 0.84; 95% CI, 0.73–0.98; $p = 0.025$], though it was not as significant as compared to the other head and neck sites.

Another population-based study done by Shrimet al, tried to specifically address the benefit of PORT in early-stage primary oral cavity cancers (pT1/T2N1) with single ipsilateral node without extracapsular spread and being <3 cm in size. [15] For all patients, adjuvant RT was associated with superior 5 yr. overall survival [52.4% vs. 41.4% ($p < .001$)]. Survival advantage was statistically significant in T2 cases, with a trend to significance in T1 cases. When individual sub-sites were analysed, PORT significantly improved survival in patients with cancers of oral tongue [52.3% vs. 37.9% ($p = .002$)] and floor of mouth [39.9% vs. 17.7% ($p = .003$)].

Addition of Chemotherapy to Radiation in post-op setting: Several retrospective and small prospective trials had showed improvement in outcomes of advanced head and neck cancers by adding chemotherapy (adjuvant or concurrent) to post-operative radiotherapy, especially in those with high-risk features such as inadequate margins, presence of extracapsular nodal spread and multiple involved nodes. Single institution trials by Bachaud and Smid, revealed improved loco-regional control rates and superior DFS/OS rates in combined modality group at a slightly higher rate of complications. [16, 17]

Lacas & Pignon et al. (MACH-NC) in their updated meta-analysis of chemotherapy in head and neck cancer have studied the effect of concurrent chemotherapy use along with radiotherapy (upfront & post-surgery). [18] Out of 107 studies (19,805 patients), 71 studies (10,680 patients) were on concomitant chemotherapy with a median follow up of 9.2 years. There was an absolute benefit in overall survival & event free survival of 6.5% & 5.8% at 5 years and 3.6% & 3.1% at 10 years with significant reduction in LRF rates [sub-HR = 0.71; $p < 0.0001$]. The study also showed that concurrent chemotherapy outcomes were better than induction chemotherapy and also that platin based chemotherapy gave maximum benefit, however there was no significant difference between weekly or three-weekly chemotherapy protocols in terms of outcomes or toxicity.

Bernier et al. (EORTC 22931) conducted a multi-institutional prospective study in 334 patients and found that addition of chemotherapy to adjuvant radiotherapy showed a benefit in 5 yr. PFS rates [47%(CMT) vs. 36%(RT)] and OS rates [53% (CMT) vs. 40%(RT)] & reduced the 5-year risk of death in combined modality from 43–27%. [19] Cooper et al.(RTOG 9501) did a similar study in 459 patients and showed significantly improved local/regional control as well as disease free survival (10% absolute benefit at 2 years) in the combined modality group after 45.9 months follow up. [20]

As both these studies had few differences in their definition of high-risk disease, a pooled analysis was done to get some clarity and this concluded that outcomes for patients with ECE and/or involved surgical margins was significantly better with CMT. [21] Also, there was a trend to improved outcomes in patients with clinically enlarged level IV/V nodes with oral cavity/oropharyngeal primaries and perineural infiltration.

Three weekly high dose cisplatin (100 mg/m²) is the standard systemic chemotherapy regimen given concurrently with radiation in high-risk oral cavity cancers. However, due to compliance issues low dose regimens have been applied in clinical practice without any prospective evidence to support the same. Szturz et al. conducted a meta-analysis to compare the standard three weekly regimen (100 mg/m²; 3 doses) with the low dose weekly regimen ≤ 50 mg/m²; ≥ 6 doses). [22] Though there were no prospective comparative studies till date, 52 studies with 4209 patients were included and it showed no difference in the efficacy indices such as overall survival or response rates. In the definitive treatment setting, weekly regimen was more compliant and significantly less toxic with respect to myelosuppression, severe nausea/vomiting and nephrotoxicity. In the post-op setting, the two approaches were similar with the weekly arm causing more grade 3/4 dysphagia and weight loss.

JCOG1008 was a multi-institutional phase II/III non-inferiority trial comparing 3 weekly cisplatin with weekly schedule (40 mg/m²) as a concurrent chemotherapy option in post-operative high-risk H&N cancers. [23] After enrolling 261 patients and a median follow up of 2.2 years, the trial was stopped as the non-inferiority criteria was reached. The 3-year OS (76.1% vs. 59.1%; HR of 0.69) & RFS (64.5% vs. 53%; HR of 0.71) was favouring the weekly arm as against the 3 weekly arm, confirming the non-inferiority of the lower dose weekly regimen.

3.3 Definitive radiotherapy (with or without chemotherapy)

There are no prospective trials which have directly compared primary surgery vs. primary radiotherapy in oral cavity cancers specifically. Two case series comparing these two modalities suggested a lower loco-regional control with primary radiotherapy compared to a surgical approach.

First was Studer et al., who assessed 58 consecutive oral cancer patients referred for either adjuvant or definitive radiotherapy. [24] They found local control rates were highest in the surgery followed by post-op IMRT group (92% LC at 2 yr), followed by patients treated with surgery alone or those receiving post-op 3DCRT (70–80% LC at 2 yr) and least in the definitive radiotherapy group treated with IMRT (40%LC at 2 yr) or 3DCRT (30% LC at 2 yr).

Murthy V. et al. studied 1180 oral cancer patients treated with PORT or definitive RT, by dividing them into 2 groups – Group 1 included gingiva-alveolar-buccal complex, lip and hard palate sites and group 2 included tongue and floor of mouth sites. [25] The 3 yr. LC, LRC and DFS for those treated with PORT was 74%, 65% & 60% respectively. And for those treated with definitive RT it was 34%, 31% & 30%

respectively. Also, they found Group 1 patients had significantly better LC, LRC and DFS than group 2 patients.

Cohen et al. did a retrospective review of 4 multi-institutional phase II trials dealing with primary chemo-radiotherapy for T4 oral cavity tumours. [26] In all 39 patients were assessed, 42% of them having bone involvement. Median dose of RT given was 74Gy. Five-year OS, PFS and LC were 56%, 51% & 75% respectively suggesting definitive chemoradiation to be a reasonable option in these tumours.

Hosni et al. retrospectively analysed all oral cancer patients (108 patients) treated with IMRT (with no surgical intervention). [27] The cases had 63% cT3/T4 disease, 35% cN2/3 and 35% received concurrent chemotherapy. After a median follow up of 52 months, the 5-year local, regional and distant control rate was 78%, 92% & 90% respectively. The 5-year DFS, OS and CSS were 42%, 50% & 76% respectively justifying definitive non-surgical chemoradiation as a meaningful alternative in appropriately chosen cases.

Updated MACH-NC results showed the benefit of concomitant chemotherapy was due to its effect on deaths related to head and neck cancer (absolute benefit of 9.8% in 5 years). [18] Addition of chemotherapy showed a significant reduction in loco-regional failure (sub-HR = 0.71; $p < 0.0001$) with a non-significant effect on distant failure.

The first Meta-Analysis of Radiotherapy in Head and neck cancer (MARCH) in 2005 and clearly showed an advantage of altered fractionation radiotherapy over conventional radiotherapy in terms of overall and progression free survival. The updated analysis of this study was conducted by Lacas et al. in 2017 by including 34 trials and 11,969 patients and extended the comparison to benefit of concomitant chemoradiotherapy over altered fractionation schemes. [28] They reiterated that altered fractionation was superior to conventional RT alone schemes in all disease indices and also that hyperfractionation schemes were better than accelerated RT plans especially when nodal disease was higher. The comparison between concomitant chemoradiation and altered fractionation revealed a clear benefit for CMT with an absolute benefit of 5.8% and 5.1% at 5 & 10 years respectively.

Combining altered fractionation RT schemes with chemotherapy in head and neck cancers have been studied in the following two trials. GORTEC 99-02 did a three-arm study comparing standard chemoradiation, accelerated radiotherapy-chemotherapy and very accelerated radiotherapy alone. [29] Progression free survival were 37.6%, 34.1% & 32.2% respectively with acute grade 3/4 toxicity of 76-84% in the altered fractionation arms. The RTOG 0129 trial did a direct head on comparison between standard fractionation chemoradiotherapy and accelerated chemotherapy-radiotherapy in 743 patients. [30] At a median follow up of 7.9 years, there were no differences in OS, PFS, LRF or DM rates between the two arms. Both these studies concluded that addition of chemotherapy to altered fractionation radiation schemes in locally advanced head and neck cancers provided no benefit in terms of outcomes.

3.4 Time factor in PORT

Two aspects of timing with regards to radiotherapy has been shown to be important for eventual outcomes in head and neck cancer management – overall treatment duration of radiotherapy as well as total time of both surgery and radiotherapy in CMT. Prolongation of both these indices seems to negatively impact the outcomes. Ang et al. conducted a multi-institutional study including 288 patients and found that in high-risk H&N cancers, there was a trend towards higher LRC and survival rates when PORT was delivered in 5 rather than 7 weeks. [31] Also, a

prolonged interval between surgery and PORT of >6 weeks or a total duration of surgery and PORT of >13 weeks significantly impacted outcomes negatively.

Huang et al. in their meta-analysis involving 46 studies dealing with this aspect found that in the combined analysis the rates of local recurrences were significantly higher among patients who received PORT more than 6 weeks after surgery (OR = 2.89; 95% CI). [32]

Fast tumour cell repopulation has been postulated as the reason behind why prolonging overall treatment time (OTT) can negatively impact local control and survival in cancers. González Ferreira et al. in their review of literature found prolongation of OTT resulted in an average loss of LRC ranging from 1 to 1.2% per day to 12–14% per day, requiring an average increase of 0.6–0.8Gy/day to compensate for it. [33] Also, they postulated that the lag period for the accelerated repopulation to be initiated was between 21 and 28 days.

Graboyes et al. conducted an institutional review to study this aspect and found that starting PORT > 6 weeks post-surgery resulted in decreased OS rates in both multivariate and propensity score-matched subsets. [34] They also found that increasing delay beyond 6 weeks resulted in small, progressive survival decrements [aHR 1.09, 1.10, 1.12 for 7–8 wks, 8–10 wks and >10wks respectively].

Zumer et al. did a retrospective analysis to identify the relationship between time before treatment intervention and tumour growth kinetics on treatment outcomes in those undergoing definitive radiotherapy with or without chemotherapy in 273 head and neck cancer patients. [35] There was no significant association between loco-regional control or survival indices and time to treatment intervention. They also found that the median tumour volume relative increase rate & tumour volume doubling time was 3.2%/day and 19 days respectively, but both had no impact on outcomes.

3.5 Dose & volumes considerations for radiation in oral cancers

As a principle in radiotherapy, at least for oral cavity squamous cell carcinomas, the dose needs to be delivered in the desired fractionated regimen without unnecessary interruptions and in the shortest time possible with no reduction in dose below that what is tolerated by late responding normal tissue.

This means that the total dose is important to prevent local recurrences and the factors that need to be kept in mind are [36].

- Dose
- Dose per fraction
- Overall treatment time
- Normal tissue toxicity

Radiotherapy in oral cavity tumours is associated with lot of acute as well as chronic toxicities which will be dealt separately. In order to minimise this, there are several steps taken and one of them is the use of highly conformal Intensity modulated radiotherapy (IMRT), and there is lot of data to support its use in head and neck cancers. Before starting radiation therapy all patients undergo a detailed examination by a dental surgeon and this is known as dental prophylaxis. The dental surgeon will assess the area of treatment and also estimate the dose that would probably be delivered to the surrounding bony structures as well as ascertain the status of the teeth and score it as per DMF (Decayed, Missing, Filled) index.

Based on this, treatment is advised and appropriately followed. By doing this exercise, the chances of osteoradionecrosis & soft tissue related long-term toxicities can be reduced or even eliminated. IMRT involves simulation and planning for which the most basic step is immobilisation by thermoplastic facemask attached to a base plate indexed to the treatment table. After the planning CT scan is done the volumes are outlined on them as per the guidelines. [37]

3.5.1 For definitive radiation therapy

GTV or gross tumour volume is defined as the visible tumour along with the nodes which are abnormal. HRCTV [High Risk Clinical Target Volume] includes the margin around the GTV and also the first echelon group of nodes which will be level IB to level II. For LRCTV [Low Risk Clinical Target Volume] one would include level III, IV, supraclavicular and IA. Usually bilateral neck is to be treated, based on institutional protocol. PTV [Planning Target Volume] would be 5 mm around the CTV trimmed from skin, but based on institutional protocol, it could range from 3 mm to 10 mm. (Figures 5 and 6).

3.5.2 For postop radiation therapy

HRCTV encompasses the area of the tumour bed [if features such as margin positivity, node positivity with extracapsular extension, peri-neural invasion and soft tissue extension is present]. IRCTV [Intermediate Risk Clinical Target Volume] would include the involved nodes without ECE & uninvolved adjacent nodal levels.

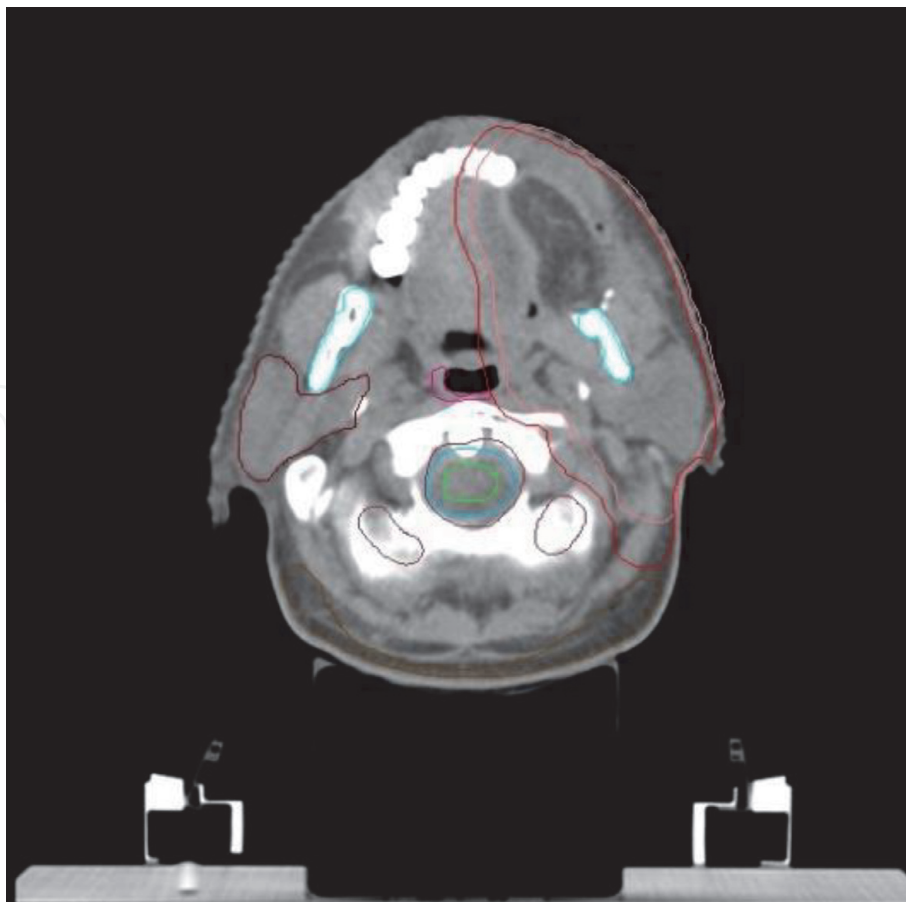


Figure 5.
Contouring of target volumes & organs at risk (OAR) for a case of carcinoma Oral tongue post surgery [pT₃N₁M₀]; Orange – clinical target volume; Red – planning target volume; Cyan – mandible; brown – right parotid; green – spinal cord; pink – constrictor.

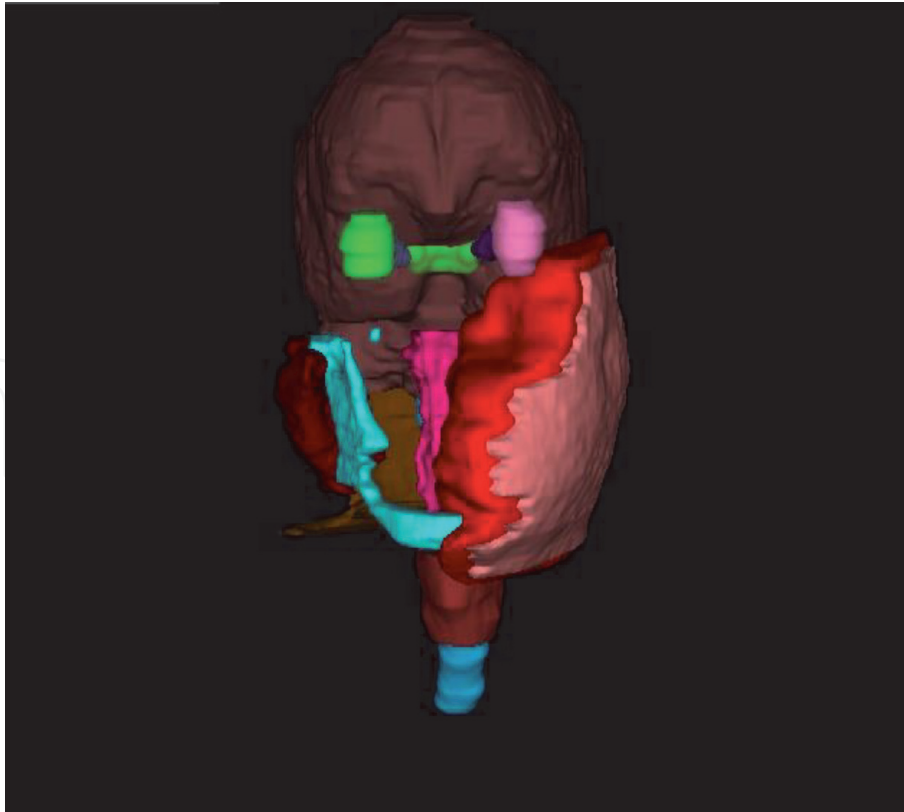


Figure 6.
3-dimensional projection of target & normal tissues contoured.

LRCTV would include rest of the nodal levels based on the risk stratification and bilateral neck is treated if risk is higher. PTV would be 5 mm around the CTV trimmed from skin, but based on institutional protocol, it could range from 3 mm to 10 mm. (**Figure 5**).




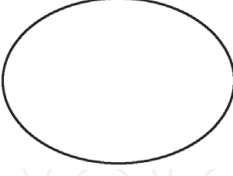

As far as dose and dose per fraction is concerned there are multiple regimens and multiple doses available with their pros and cons. The following table depicts the usual practice with some insight on hypothesis. (**Tables 3 and 4**).

3.6 Radiation related toxicity in oral cancer management

Radiotherapy is an essential part of multi-modality treatment for oral cancers. However, several uninvolved organs in the vicinity of these cancers like the skin, salivary glands, oral mucosa, masticatory apparatus, dentition and jaws receive significant doses of radiation during treatment. This could result in moderate to severe adverse effects during and after completion of treatment and also affect the patient's quality of life. The effects may be acute such as dermatitis, mucositis and hyposalivation or chronic and long-term such as xerostomia, radiation caries, trismus and osteoradionecrosis. [38]

As many of these effects are dose-limiting, introduction of newer radiation techniques and schedules have minimised late effects to a large extent. Nutting et al. were able to demonstrate 50% reduction in subjective xerostomia rates with IMRT by keeping mean dose to contralateral parotid gland at 26Gy. [39] Parotid sparing IMRT was achieved by avoiding the contralateral parotid, upper parapharyngeal space as well as giving a tight constraint for the anterior oral cavity. [36, 40]

A more problematic late effect is osteoradionecrosis, which is the process of bone and soft tissue necrosis, arising as a result of radiation induced hypocellularity, hypoxia and hypovascularity, resulting in a non-healing region. [41] As spontaneous ORN is dose dependent(>60Gy), IMRT is able to reduce the maximum


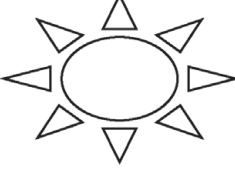
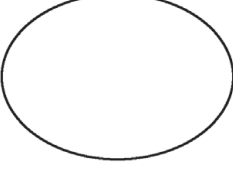

Post operative disease		
R1-Microscopic Disease 	R0 Resection 	R0 & N0 Disease
NODE +, ECE/PNI + 	NODE +, No ECE/PNI 	ELECTIVE ONLY 
RISK OF RELAPSE – >30%	RISK OF RELAPSE – 15–20%	RISK OF RELAPSE – 5–10%
VOLUME – CTV-HR (PRIMARY)	VOLUME - CTVIR (PRIMARY) CTV IR(NODES)	VOLUME -CTVLR (NODES)
DOSE – 66Gy–70Gy at 2Gy per fraction	DOSE – 60Gy at 2Gy per fraction	DOSE – 50Gy at 2Gy per fraction

Volumes are applicable for conformal therapy.

These volumes are subjective based on dose/fraction.

Surgery to radiation interval should be ≤ 6 weeks

Table 3.
 Dose & volume consideration for post-op adjuvant radiotherapy.

Definitive radiotherapy		
MACROSCOPIC DISEASE 	MARGIN AROUND THE GTV	NODE NEGATIVE, BUT DRAINAGE NODAL AREA
NODE + WITH ECE 	PRIMARY ECHELON 	ELECTIVE ONLY 
VOLUME – GTV or CTVHR	VOLUME- CTVIR (PRIMARY) CTV IR(NODES)	VOLUME- CTVLR(NODES)
DOSE – 66Gy–70Gy at 2Gy per fraction	DOSE – 60Gy at 2Gy per fraction	DOSE – 50Gy at 2Gy per fraction

Volumes are applicable for conformal therapy.

These volumes are subjective based on dose/fraction.

Table 4.
 Dose & volume consideration for definitive radiotherapy.

dose received by the mandible as well as volume of mandible covered by 50-55Gy isodoses. The reported ORN rates in IMRT series is 5–6%.

Chen et al. found that IMRT also helped reduce dysphagia related complications in oral cancer patients undergoing radiotherapy. [42] Those receiving IMRT had significantly lesser moderate (grade 2) and severe (grade 3) dysphagia when compared to those receiving conventional radiotherapy (21% vs. 59%; $p = 0.02$) [42]

3.7 Targeted therapy, current bio-markers and future perspectives for oral cancers

Epidermal growth factor receptor (EGFR) regulates many cellular functions crucial for tumorigenesis. Huang et al. studied 160 oral cancer patients using immunohistochemistry for EGFR protein over-expression and fluorescence in situ hybridization for copy number. [43] EGFR overexpression was noted in 46.88% and 31.25% had increased gene copy numbers. They also found 100% concordance rate between EGFR gene amplification and protein overexpression. EGFR over-expression was associated with poor prognosis, both in terms of DFS and OS.

Cetuximab, an EGFR antibody has shown good results in head and neck cancers, in combination with definitive radiation. [44] The RTOG 0920 trial (Ongoing) is trying to address outcomes with addition of cetuximab to PORT in intermediate-risk oral cancers.

The development of PD-1/PD-L1 inhibitors (pembrolizumab & nivolumab) & other immune checkpoint inhibitors (ICI) has changed the systemic management of HNSCC. [45, 46] PD-L1 expression in pre-treatment biopsies have been associated with good prognosis. Preclinical data suggests synergy between anti-PD1 inhibitors and radiation, making it a potential therapeutic option for high-risk oral cancers in the future. [47] Several phase II studies addressing these agents in combination with standard therapy or as a neoadjuvant/adjuvant option are in the works. [48]

Tumour mutational burden (TMB) as a biomarker of ICI response has shown mixed response in HNSCC, with KEYNOTE-012 trial showing a positive correlation while using a cut-off of ≥ 102 mutations per exome. [49]

Other aspects being studied are tumour immune microenvironment and oral/gut microbiome as regulating mechanisms having implications for response of HNSCC to immune therapies. Oral microbiome has also shown an effect on toxicity profile of patients undergoing concurrent chemoradiation. [50] Cell therapy-based options such as the use of activated cytotoxic T-Lymphocytes (CTL's) to result in tumour cell death has also been attempted in HNSCC. [51] Chimeric antigen Receptor T cells are one such example being used in advanced oral cancers.

4. Brachytherapy

Brachytherapy is the delivery of radiation therapy using sealed sources placed within or close to the site to be treated. Oral cavity cancers with their ease of accessibility and better visibility had provided the best sites for use of this therapy for improved local control and outcomes in the past. With its ability to give high doses to tumour and very minimal dose to the surrounding tissues, brachytherapy could be considered the most ideal conformal therapy. However, in recent times the technological advancements associated with external beam therapy, improved imaging and surgical techniques and lack of appropriate knowledge or expertise in invasive implants has relegated brachytherapy to be used in very specific and not so common indications of these cancers. Modern brachytherapy too has evolved to

allow for acceptable dose and fractionation schedules, image guidance, dose optimization and better radiation protection mechanisms.

Common cancer sites where brachytherapy can be used in oral cavity are mobile tongue, lip, buccal mucosa, floor of mouth and palate. [52, 53] Indications for use of brachytherapy presently is

- Small localised T1 squamous cell cancers as primary treatment
- In combination of external beam radiotherapy as a boost modality
- As a re-irradiation modality in previously treated sites or development of second primaries

Disadvantages for brachytherapy are primarily due to lack of expertise and need for an initial learning curve which is usually lacking other than in bigger institutes, ease of modern conformal external radiotherapy techniques, competition with modern surgical techniques and concerns of radiation protection. Some relative contraindications to this procedure in oral cavity tumours would be compromised mouth opening, difficult naso-tracheal intubation & those having large defects requiring flap reconstructions in post-op setting.

Usually, the procedure followed is a single implant with multiple treatment fractions over nearly a week. Procedure is done under general anaesthesia with the help of nasotracheal intubation and dental separators to allow for proper visualisation. An interstitial implant is done following the principles of the Paris technique. (**Figures 7 and 8**) A CT-scan based planning is done and the oncologist will delineate the tumour and organs at risk on the treatment planning system. Doses delivered are between 3-4Gy in 10-12 fractions delivered six hours apart over 5-6 days in

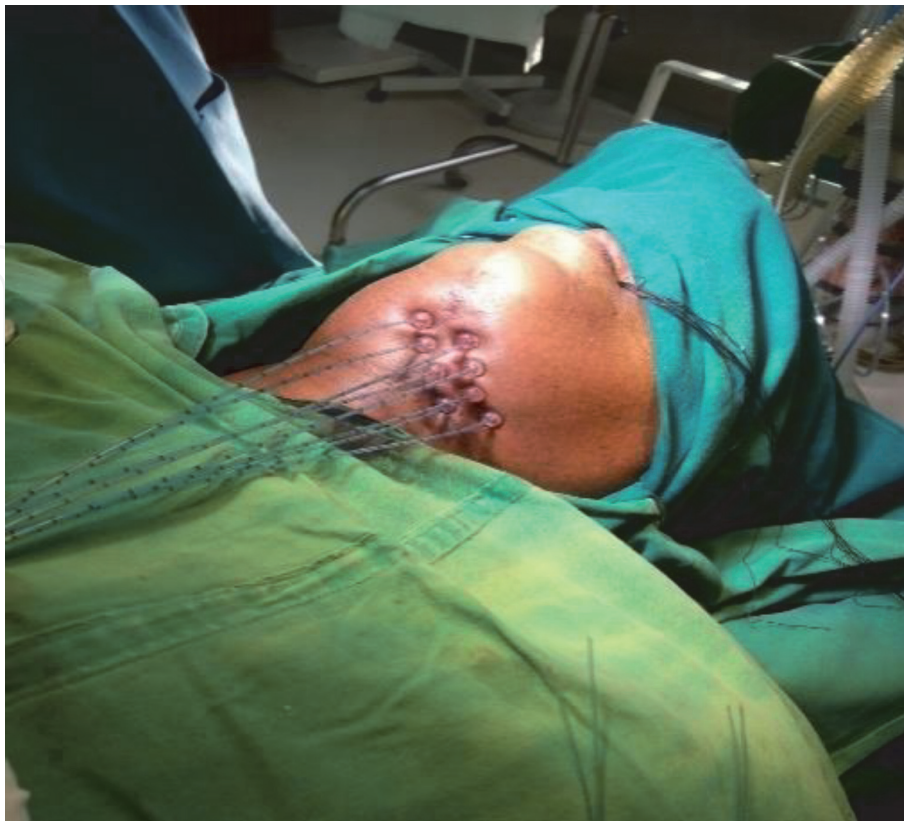

Figure 7.
Brachytherapy of tongue.

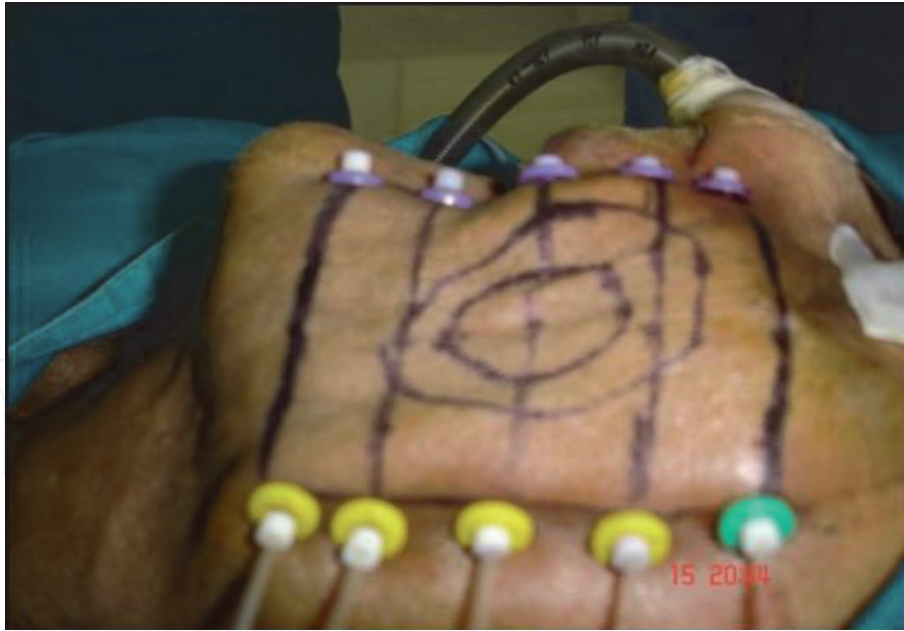

Figure 8.
Brachytherapy of buccal mucosa.

the primary treatment setting and 3-4Gy in 6-8 fractions over 3-4 days in the boost setting.

Acute complications of brachytherapy could be haemorrhage, infection, airway compromise & sialadenitis. Long term side effects could be soft tissue necrosis, telangiectasia and rarely osteoradionecrosis.

5. Conclusions

Oral cavity cancers are a diverse group of tumours which are known for its aggressive behaviour and higher chances of recurrences, which can lead to extremely difficult & cumbersome management decisions. This current review denotes the various available options for treatment for different categories of these tumours, to provide us a glimmer of hope to not only manage the disease well but also give good results in terms of locoregional control, long-term survival and at the same time ensuring cosmetically acceptable outcomes. As the primary focus of this chapter was on aspects of use of radiotherapy in oral cancers, the specific nuances on current evidence-based practice have been elaborated upon. Though most of the general details on use of external & internal radiation in oral cancers have been described, the detailed specific site-based & technique-based points have not been elaborated as they are beyond the scope of this chapter.

Available potential therapeutic options being currently investigated to ascertain possible benefit in oral cancers have also been described in this chapter. The future advances in use of radiation therapy should focus on recognising & refining the most appropriate indications for its application, strategic use of higher end technology like modulated arc therapy/stereotactic radiation & proton therapy, better amalgamation of radiation with newer concomitant systemic therapy agents as well as a well-rounded approach in inculcating genomic attributes of oral cancers in identifying the future standard of care for these tumours.

IntechOpen

IntechOpen

Author details

A.S. Kirthi Koushik* and Ram Charith Alva
Ramaiah Medical College and Hospital, Bengaluru, India

*Address all correspondence to: kirthi.koushik@gmail.com

IntechOpen

© 2021 The Author(s). Licensee IntechOpen. This chapter is distributed under the terms of the Creative Commons Attribution License (<http://creativecommons.org/licenses/by/3.0>), which permits unrestricted use, distribution, and reproduction in any medium, provided the original work is properly cited. 

References

- [1] World Health Organization. Oral Health. 2020. Available online. <https://gco.iarc.fr/today/data/factsheets/cancers/1-Lip-oral-cavity-fact-sheet.pdf>. (Accessed on 11th July, 2021)
- [2] Petrosyan V, Kane G, Ameerally P. Oral Cancer Treatment Through the Ages: Part 2. *J Oral Maxillofac Surg*. 2019 Jul;77(7):1484-1489. doi: 10.1016/j.joms.2019.01.024. Epub 2019 Jan 28. PMID: 30794811.
- [3] Fred J. Laine, Wendy R.K. Smoker. Oral cavity: Anatomy and pathology, *Seminars in Ultrasound, CT and MRI*, Volume 16, Issue 6, 1995, Pages 527-545, [https://doi.org/10.1016/S0887-2171\(06\)80024-7](https://doi.org/10.1016/S0887-2171(06)80024-7)
- [4] Cooper JS, Pajak TF, Forastiere A, Jacobs J, Fu KK, Ang KK, Laramore GE, Al-Sarraf M. Precisely defining high-risk operable head and neck tumors based on RTOG #83-03 and #88-24: Targets for postoperative radiochemotherapy? *Head Neck* 1998;20:588-94
- [5] Langendijk JA, Slotman BJ, van der Waal I, Doornaert P, Berkof J, Leemans CR. Risk group definition by recursive partitioning analysis of patients with squamous cell head and neck carcinoma treated with surgery and postoperative radiotherapy. *Cancer* 2005;104:1408-17
- [6] Expert Panel on Radiation Oncology-Head and Neck, Salama JK, Saba N, Quon H, Garg MK, Lawson J, McDonald MW, Ridge JA, Smith RV, Yeung AR, Yom SS, Beitler JJ. ACR appropriateness criteria® adjuvant therapy for resected squamous cell carcinoma of the head and neck. *Oral Oncol* 2011;47:554-9
- [7] Bur AM, Lin A, Weinstein GS. Adjuvant radiotherapy for early head and neck squamous cell carcinoma with perineural invasion: a systematic review. *Head Neck* 2016;38 Suppl1: E2350-7
- [8] Huang SH, Hwang D, Lockwood G, Goldstein DP, O'Sullivan B. Predictive value of tumor thickness for cervical lymph-node involvement in squamous cell carcinoma of the oral cavity: a meta-analysis of reported studies. *Cancer*. 2009;115:1489-1497.
- [9] Liao CT, Lin CY, Fan KH, Wang HM, Ng SH, Lee LY, et al. Identification of a high-risk group among patients with oral cavity squamous cell carcinoma and pT1-2N0 disease. *Int J Radiat Oncol Biol Phys*. 2012;82:284-90.
- [10] Bulbul MG, Tarabichi O, Sethi RK, Parikh AS, Varvares MA (2019) Does clearance of positive margins improve local control in oral cavity cancer? A meta-analysis. *Otolaryngol Head Neck Surg* 161:235–244.
- [11] Fletcher GH, Evers WT. Radiotherapeutic management of surgical recurrences and postoperative residuals tumors of the head and neck. *Radiology* 1970;95:185-8. 57.
- [12] Marcus RB Jr, Million RR, Cassissi NJ. Postoperative irradiation for squamous cell carcinomas of the head and neck: analysis of time-dose factors related to control above the clavicles. *Int J Radiat Oncol Biol Phys* 1979;5:1943-49
- [13] Lavaf A, Genden EM, Cesaretti JA, Packer S, Kao J. Adjuvant radiotherapy improves overall survival for patients with lymph node-positive head and neck squamous cell carcinoma. *Cancer* 2008;112:535-43. 60.
- [14] Kao J, Lavaf F, Teng MS, Huang D, Genden EM. Adjuvant radiotherapy and survival for patients with node-positive head and neck cancer: an analysis by primary site and nodal stage. *Int J Radiat Oncol Biol Phys* 2008;71:362-70

- [15] Shrime MG, Gullane PJ, Dawson L, Kim J, Gilbert RW, Irish JC, Brown DH, Goldstein DP. The impact of adjuvant radiotherapy on survival in T1-2N1 squamous cell carcinoma of the oral cavity. *Arch Otolaryngol Head Neck Surg* 2010;136:225-8
- [16] Bachaud JM, Cohen-Jonathan E, Alzieu C, David JM, Serrano E, Daly-Schveitzer N. Combined postoperative radiotherapy and weekly cisplatin infusion for locally advanced head and neck carcinoma: final report of a randomized trial. *Int J Radiat Oncol Biol Phys.* (1996) 36:999–1004. doi: 10.1016/S0360-3016(96)00430-0
- [17] Smid L, Budihna M, Zakotnik B, Soba E, Strojjan P, Fajdiga I, et al. Postoperative concomitant irradiation and chemotherapy with mitomycin C and bleomycin for advanced head-and-neck carcinoma. *Int J Radiat Oncol Biol Phys.* (2003) 56:1055–62. doi: 10.1016/S0360-3016(03)00207-4
- [18] Lacas B, Carmel A, Landais C et al. Meta-analysis of chemotherapy in head and neck cancer (MACH-NC): An update on 107 randomized trials and 19,805 patients, on behalf of MACH-NC Group. *Radiother Oncol.* 2021 Mar;156:281-293. doi: 10.1016/j.radonc.2021.01.013. Epub 2021 Jan 27. PMID: 33515668
- [19] Bernier J, Dommé C, Ozsahin M, Matuszewska K, Lefèbvre JL, Greiner RH, et al. Postoperative irradiation with or without concomitant chemotherapy for locally advanced head and neck cancer. *N Engl J Med.* 2004; 350:1945-52.
- [20] Cooper JS, Pajak TF, Forastiere AA, Jacobs J, Campbell BH, Saxman SB, et al. Postoperative concurrent radiotherapy and chemotherapy for high-risk squamous-cell carcinoma of the head and neck. *N Engl J Med.* 2004;350:1937-44
- [21] Bernier J, Cooper JS, Pajak T, Van Glabbeke M, Bourhis J, Forastiere A, et al. Defining risk levels in locally advanced head and neck cancers: a comparative analysis of concurrent postoperative radiation plus chemotherapy trials of the EORTC (# 22931) and RTOG (# 9501). *Head Neck* (2005) 27:843–50. doi: 10.1002/hed.20279
- [22] Szturcz P, Wouters K, Kiyota N, Tahara M, Prabhash K, Noronha V, Castro A, Licitra L, Adelstein D, Vermorken JB. Weekly Low-Dose Versus Three-Weekly High-Dose Cisplatin for Concurrent Chemoradiation in Locoregionally Advanced Non-Nasopharyngeal Head and Neck Cancer: A Systematic Review and Meta-Analysis of Aggregate Data. *Oncologist.* 2017 Sep;22(9):1056-1066. doi: 10.1634/theoncologist.2017-0015. Epub 2017 May 22. PMID: 28533474; PMCID: PMC5599190
- [23] Naomi Kiyota, Makoto Tahara, Hirofumi Fujii, Tomoko Yamazaki, Hiroki Mitani, Shigemichi Iwae, Yasushi Fujimoto, Yusuke Onozawa, Nobuhiro Hanai, Takenori Ogawa, Hiroki Hara, Nobuya Monden, Eiji Shimura, Shujiro Minami, Takashi Fujii, Kaoru Tanaka, Takeshi Kodaira, Junki Mizusawa, Kenichi Nakamura, Ryuichi Hayashi, and Head and Neck Cancer Study Group of Japan Clinical Oncology Group (JCOG-HNCSG). Phase II/III trial of post-operative chemoradiotherapy comparing 3-weekly cisplatin with weekly cisplatin in high-risk patients with squamous cell carcinoma of head and neck (JCOG1008). *Journal of Clinical Oncology* 2020 38:15_suppl, 6502-6502
- [24] Studer G, Zwahlen RA, Graetz KW, Davis BJ, Glanzmann C. IMRT in oral cavity cancer. *Radiat Oncol.* 2007;2:16.
- [25] Murthy V, Agarwal JP, Laskar SG, Gupta T, Budrukkar A, Pai P, et al. Analysis of prognostic factors in 1180

- patients with oral cavity primary cancer treated with definitive or adjuvant radiotherapy. *J Cancer Res Ther.* 2010;6: 282-9.
- [26] Cohen EE, Baru J, Huo D, Haraf DJ, Crowley M, Witt ME, Blair EA, Weichselbaum RR, Rosen F, Vokes EE, Stenson K. Efficacy and safety of treating T4 oral cavity tumors with primary chemoradiotherapy. *Head Neck.* 2009;31:1013-21
- [27] Hosni, Ali et al. "Non-operative management for oral cavity carcinoma: Definitive radiation therapy as a potential alternative treatment approach." *Radiotherapy and oncology : journal of the European Society for Therapeutic Radiology and Oncology* vol. 154 (2021): 70-75. doi:10.1016/j.radonc.2020.08.013
- [28] Lacas B, Bourhis J, Overgaard J, Zhang Q, Grégoire V, Nankivell M, Zackrisson B, Szutkowski Z, Suwiński R, Poulsen M, O'Sullivan B, Corvò R, Laskar SG, Fallai C, Yamazaki H, Dobrowsky W, Cho KH, Beadle B, Langendijk JA, Viegas CMP, Hay J, Lotayef M, Parmar MKB, Aupérin A, van Herpen C, Maingon P, Trotti AM, Grau C, Pignon JP, Blanchard P; MARCH Collaborative Group. Role of radiotherapy fractionation in head and neck cancers (MARCH): an updated meta-analysis. *Lancet Oncol.* 2017 Sep;18(9):1221-1237. doi: 10.1016/S1470-2045(17)30458-8. Epub 2017 Jul 27. Erratum in: *Lancet Oncol.* 2018 Apr;19(4):e184. PMID: 28757375; PMCID: PMC5737765.
- [29] Bourhis J, Sire C, Graff P, Grégoire V, Maingon P, Calais G, Gery B, Martin L, Alfonsi M, Desprez P, Pignon T, Bardet E, Rives M, Geoffrois L, Daly- Schweitzer N, Sen S, Tuchais C, Dupuis O, Guerif S, Lapeyre M, Favrel V, Hamoir M, Lusinchi A, Temam S, Pinna A, Tao YG, Blanchard P, Aupérin A. Concomitant chemoradiotherapy versus acceleration of radiotherapy with or without concomitant chemotherapy in locally advanced head and neck carcinoma (GORTEC 99-02): an open-label phase 3 randomised trial. *Lancet Oncol* 2012;13: 145-53
- [30] Nguyen-Tan PF, Zhang Q, Ang KK, Weber RS, Rosenthal DI, Soulieres D, Kim H, Silverman C, Raben A, Galloway TJ, Fortin A, Gore E, Westra WH, Chung CH, Jordan RC, Gillison ML, List M, Le QT. Randomized phase III trial to test accelerated versus standard fractionation in combination with concurrent cisplatin for head and neck carcinomas in the Radiation Therapy Oncology Group 0129 trial: long-term report of efficacy and toxicity. *J Clin Oncol* 2014;32:3858-66.
- [31] Ang KK, Trotti A, Brown BW, Garden AS, Foote RL, Morrison WH, Geara FB, Klotch DW, Goepfert H, Peters LJ. Randomized trial addressing risk features and time factors of surgery plus radiotherapy in advanced head-and-neck cancer. *Int J Radiat Oncol Biol Phys* 2001;51:571-8
- [32] Huang J, Barbera L, Brouwers M, Browman G, Mackillop WJ. Does delay instarting treatment affect the outcomes of radiotherapy? a systematic review. *J Clin Oncol* 2003;21:555-63
- [33] González Ferreira JA, JaénOlasolo J, Azinovic I, Jeremic B. Effect of radiotherapy delay in overall treatment time on local control and survival in head and neck cancer: review of the literature. *Rep Pract Oncol Radiother* 2015;20:328-39.
- [34] Graboyes, E.M., Garrett-Mayer, E., Ellis, M.A., Sharma, A.K., Wahlquist, A. E., Lentsch, E.J., Nussenbaum, B. and Day, T.A. (2017), Effect of time to initiation of postoperative radiation therapy on survival in surgically managed head and neck cancer. *Cancer*, 123: 4841-4850. <https://doi.org/10.1002/cncr.30939>

- [35] Žumer, B., PoharPerme, M., Jereb, S. et al. Impact of delays in radiotherapy of head and neck cancer on outcome. *Radiat Oncol* **15**, 202 (2020). <https://doi.org/10.1186/s13014-020-01645-w>
- [36] Daly ME, Le QT, Kozak MM, Maxim PG, Murphy JD, Hsu A, Loo BW Jr, Kaplan MJ, Fischbein NJ, Chang DT. Intensity-modulated radiotherapy for oral cavity squamous cell carcinoma: patterns of failure and predictors of local control. *Int J Radiat Oncol Biol Phys.* 2011 Aug 1;80(5):1412-22. doi: 10.1016/j.ijrobp.2010.04.031. Epub 2010 Aug 2. PMID: 20675073.
- [37] Merlotti A, Alterio D, Vigna-Taglianti R, Muraglia A, Lastrucci L, Manzo R, Gambaro G, Caspiani O, Miccichè F, Deodato F, Pergolizzi S, Franco P, Corvò R, Russi EG, Sanguineti G; Italian Association of Radiation Oncology. Technical guidelines for head and neck cancer IMRT on behalf of the Italian association of radiation oncology - head and neck working group. *Radiat Oncol.* 2014 Dec 29;9:264. doi: 10.1186/s13014-014-0264-9. PMID: 25544268; PMCID: PMC4316652
- [38] Basu T, Laskar SG, Gupta T, Budrukkar A, Murthy V, Agarwal JP. Toxicity with radiotherapy for oral cancers and its management: a practical approach. *J Cancer Res Ther.* 2012 Jan;8 Suppl1:S72-84. doi: 10.4103/0973-1482.92219. PMID: 22322736.
- [39] Nutting CM, Morden JP, Harrington KJ, Urbano TG, Bhide SA, Clark C, et al. Parotid-sparing intensity modulated versus conventional radiotherapy in head and neck cancer (PARSPORT): A phase 3 multicentre randomised controlled trial. *Lancet Oncol* 2011;12:127-36
- [40] Bhide SA, Ahmed M, Newbold K, Harrington KJ, Nutting CM. The role of intensity modulated radiotherapy in advanced oral cavity carcinoma. *J Cancer Res Ther.* 2012;8 Suppl1:S67-71.
- [41] Eisbruch AH, Garden A, et al. Phase II Multi-institutional Study of IMRT for Oropharyngeal Cancer (RTOG 00-22): *Int J Radiat Oncol Biol Phys* 2006;66 Supplement.
- [42] Chen WC, Hwang TZ, Wang WH, Lu CH, Chen CC, Chen CM, et al. Comparison between conventional and intensity-modulated post-operative radiotherapy for stage III and IV oral cavity cancer in terms of treatment results and toxicity. *Oral Oncol.* 2009; 45:505-10
- [43] Huang SF, Cheng SD, Chien HT, Liao CT, Chen IH, Wang HM, et al. Relationship between epidermal growth factor receptor gene copy number and protein expression in oral cavity squamous cell carcinoma. *Oral Oncol.* 2012;48:67-72
- [44] Bonner, J.A.; Harari, P.M.; Giralt, J.; Azarnia, N.; Shin, D.M.; Cohen, R.B.; Jones, C.U.; Sur, R.; Raben, D.; Jassem, J.; et al. Radiotherapy plus cetuximab for squamous-cell carcinoma of the head and neck. *N. Engl. J. Med.* 2006, 354, 567–578
- [45] Muzaffar J, Bari S, Kirtane K, Chung CH. Recent Advances and Future Directions in Clinical Management of Head and Neck Squamous Cell Carcinoma. *Cancers (Basel).* 2021 Jan 18;13(2):338. doi: 10.3390/cancers13020338. PMID: 33477635; PMCID: PMC7831487.
- [46] Herbst, R.S.; Soria, J.C.; Kowanetz, M.; Fine, G.D.; Hamid, O.; Gordon, M. S.; Sosman, J.A.; McDermott, D.F.; Powderly, J.D.; Gettinger, S.N.; et al. Predictive correlates of response to the anti-PD-L1 antibody MPDL3280A in cancer patients. *Nature* 2014, 515, 563
- [47] Twyman-Saint Victor C, Rech AJ, Maity A, Rengan R, Pauken KE, Stelekati E, et al. Radiation and dual checkpoint blockade activate nonredundant immune mechanisms in

cancer. *Nature* (2015) 520:373–7. doi: 10.1038/nature14292

brachytherapy for head-and-neck carcinoma. *Int J Radiat Oncol Biol Phys* 2001;50:1190-8

[48] Kirtane K, Rodriguez CP. Postoperative Combined Modality Treatment in High Risk Resected Locally Advanced Squamous Cell Carcinomas of the Head and Neck (HNSCC). *Front Oncol*. 2018 Dec 4;8:588. doi: 10.3389/fonc.2018.00588. PMID: 30564559; PMCID: PMC6288294.

[49] Seiwert, T.Y.; Burtness, B.; Mehra, R.; Weiss, J.; Berger, R.; Eder, J.P.; Heath, K.; McClanahan, T.; Lunceford, J.; Gause, C.; et al. Safety and clinical activity of pembrolizumab for treatment of recurrent or metastatic squamous cell carcinoma of the head and neck (KEYNOTE-012): An open-label, multicentre, phase 1b trial. *Lancet Oncol*. 2016, 17, 956–965

[50] Pierce, C.M.; Hogue, S.; Paul, S.; Hong, B.Y.; da Silva, W.V.; Gomez, M. F.; Giuliano, A.R.; Caudell, J.J.; Weinstock, G.M. Abstract 3326: Mucositis, candidiasis, and associations with the oral microbiome in treatment naive patients with oropharyngeal cancer. *Cancer Res*. 2019, 79

[51] Ohtani, T.; Yamada, Y.; Furuhashi, A.; Ohmura, Y.; Nakamura, S.; Kato, H.; Yoshikawa, K.; Kazaoka, Y. Activated cytotoxic T-lymphocyte immunotherapy is effective for advanced oral and maxillofacial cancers. *Int. J. Oncol*. 2014, 45, 2051–2057

[52] Mazon JJ, Ardiet JM, Haie-Méder C, Kovács G, Levendag P, Peiffert D, Polo A, Roviroso A, Strnad V. GEC-ESTRO recommendations for brachytherapy for head and neck squamous cell carcinomas. *Radiother Oncol* 2009;91:150-6

[53] Nag S, Cano ER, Demanes DJ, Puthawala AA, Vikram B; American Brachytherapy Society. The American Brachytherapy Society recommendations for high-dose-rate