

We are IntechOpen, the world's leading publisher of Open Access books Built by scientists, for scientists

5,600

Open access books available

137,000

International authors and editors

170M

Downloads

Our authors are among the

154

Countries delivered to

TOP 1%

most cited scientists

12.2%

Contributors from top 500 universities



WEB OF SCIENCE™

Selection of our books indexed in the Book Citation Index
in Web of Science™ Core Collection (BKCI)

Interested in publishing with us?
Contact book.department@intechopen.com

Numbers displayed above are based on latest data collected.
For more information visit www.intechopen.com



Chapter

A New Technique of Two Iliac Cortical Bone Blocks Sandwich Technique for Secondary Alveolar Bone Grafting in Cleft Lip and Palate Patients

*Nhan Van Vo, Nguyen Quan Pham, Chien Dac Ho,
Son Van Le and Ha Manh Nguyen*

Abstract

Alveolar cleft bone graft in the second stage of surgery was a crucial part of the cleft palate treatment protocol with many advantages: reconstructing bone for tooth eruption, supporting the periodontal structure for the teeth adjacent to the cleft, supporting and lifting the arch and preventing from collapsing of maxillary arch. Grafting technique and material are selected based on the treatment purpose that for orthodontic moving tooth into the arch or for dental implant rehabilitation. Cancellous material provides rapid vascularization and healing facilitating for tooth moving into the cleft site but easy to resorb that unsuitable for dental implant placement. While dense material is difficult to move teeth into the cleft but increase initial stability. Therefore, we offered a method that limit bone resorption, easily obtain the implant initial stability, quick osseointegration called two iliac cortical bone blocks sandwich technique for a purposes of dental implant rehabilitation. Treatment protocol started with orthodontic treatment prior alveolar bone grafting to create proper space for implant restoration. Our clinical experience with 32 cleft sites using two iliac cortical bone blocks sandwich had shown potential clinical application in follow-up time up to 96 months. Evaluation criteria of bone grafting for alveolar cleft included soft tissue condition of graft area, nasal fistula closure, bone grafting outcome, success in osseointegration and implant prosthesis. This chapter described in detail treatment procedure and outcomes of a new technique of two iliac cortical bone blocks sandwich for alveolar cleft in patients with unilateral cleft palate.

Keywords: secondary alveolar bone graft, cleft lip and palate, unilateral alveolar cleft, dental implant, iliac crest, bone graft

1. Introduction

Anatomical deformity in patients with cleft lip and palate was a complex abnormality including both soft tissues (nose, lips, soft palate) and hard tissues

(teeth, alveolar bone and hard palate). This defect affected the formation of tooth development, tooth eruption, malocclusion, masticatory function, deformities of the facial middle and lower third, pronunciation, esthetic and psychological problems [1]. Seventy-five percent of patients with cleft lip or cleft lip and palate was recognized with an anterior alveolar bone defect that can affect tooth development and contribute to the collapse of alveolar segments. Therefore, it is necessary to reconstruct the cleft, which facilitates the eruption of adjacent teeth, orthodontic or prosthodontic treatments of the edentulous area, and closure of symptomatic oronasal fistulas [2]. Two main obstacles for rehabilitation of alveolar cleft were the bone grafting and orthodontic treatment, because arch-width deficiency and dental crossbite was usually present due to maxillary hypoplasia. This chapter presented the new treatment technique for alveolar cleft in patients with unilateral cleft palate based on previous clinical researches [3–5].

2. Timing of bone graft

Cleft lip and palate (CLP) management is a long process that can begin prenatally and continue into adulthood [6]. The most broadcast treatment modalities in the management of unilateral cleft lip and palate were based on chronologic age [6] and dentofacial development [7]. Most clinicians concurred to perform alveolar cleft bone graft in the second stage. Second stage bone graft could be classified into 3 periods: early second stage (2 to 5 years old with primary teeth), intermediate second stage (6 to 12 years old with mixed teeth) and late second stage (after 12 years old with the permanent teeth) [8]. In late secondary stage, orthodontic treatment is recommended before bone grafting to create proper space for implant restoration. According to Dempf et al., the alveolar ridge height was reported to be lower after late second stage compared to the height after intermediate secondary stage [9]. Additional bone grafts were suggested to overcome insufficient bone height which affect the implant stability and the esthetic of restorations [9].

3. The need of alveolar cleft bone grafting

One viable option for prosthetic rehabilitation of patients with alveolar cleft was endosteal dental implants. They provide acceptable functional and esthetic outcomes and ease prosthodontic treatments. However, adequate bone volume and quality is required for implant survival. Alveolar bone grafting, introduced by Boyne and Sand, is a standard procedure for most patients [10].

Alveolar cleft bone graft aimed (1) allow spontaneous eruption or orthodontic movement of the canine or lateral incisor into the cleft area [9, 11, 12]; (2) maintain bony support of teeth adjacent to the cleft and prevent collapse of alveolar segments [3]; (3) enable oronasal fistula closure [3, 12]; (4) support the alar base and nose [3]; (5) improve speech, articulation, and nasality; and (6) facilitate dental implant placement [1].

4. Orthodontic treatment

In treating alveolar cleft, orthodontic is indicated to move tooth into the cleft without surgery. However, in the late secondary stage, with the presence of canine eruption, orthodontic is recommended prior bone grafting to create proper space for dental implant rehabilitation. Pre-surgical orthodontic treatment to

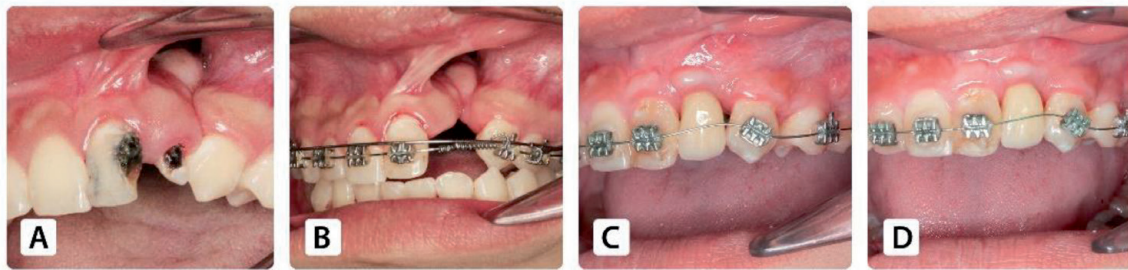


Figure 1. Postoperative treatment outcome. (A) Clinical alveolar cleft. (B) Presurgical orthodontic treatment. (C) Black triangles adjacent to the final restoration. (D) Orthodontic closure of black triangles.

realign the dental arch before bone grafting was necessary because teeth around the cleft are often severely rotated or deviated buccal/lingual/mesial/distal. The alignment to move these teeth out of the cleft and widen the jaw arch creating a suitable space for dental implants. It facilitates designing and determination of the graft volume as well as planning of the location and orientation of the dental implant [13].

The adjacent teeth usually tip into the alveolar cleft, creating black triangles after the final restoration in patients with CLP, which lead to both health and esthetic issues. Postoperative orthodontic treatment is essential to align the roots and shift the contact points apically for eliminating such gaps (**Figure 1**) and improving esthetics. Furthermore, it places traction on the graft and can stimulate bone formation [9].

5. Alveolar cleft bone grafting

5.1 The grafting tissue of choice

Previous literature has described the various donor sites, including the tibia [14], rib, and mandibular symphysis [15], the iliac crest is the most preferred [15–17]. In a survey of 240 American Cleft Palate-Craniofacial Association teams, tibia, rib, calvarium, iliac crest, and other bones were used as donor parts for alveolar bone grafting [16]. Iliac cancellous bone was proved to produce rapid vascularization of the graft but undergo greater resorption [18], compared to iliac cortical bone due to the presence of osteogenic cells. The main complaints of the patients were prolonged recovery, gait disturbance, and hospitalization [18] but these complications occurred for only a short time [19].

Additionally, several researches sought for materials to replace autogenous bone in bone grafting area, such as demineralized allogeneic bone matrix mixed with bone marrow [20], microstructured β -tricalcium phosphate [21, 22], and bone morphogenetic protein-2 [23].

Recently the technique for tissue engineering using bone marrow-derived mesenchymal stem cells is considered as a promising method in alveolar cleft bone grafting due to its ability to treat large defect [24]. Aida Mossaad 2019 concluded in his research that group C treated with tissue engineering method using bone marrow stem cells extract and PRF membrane showed superior results among all followed by group B treated with nano calcium hydroxyapatite with collagen membrane, while group A with autogenous iliac crest showed resorption in some cases [20].

Growth factors obtained from platelet rich plasma PRP was introduced with the advantages of promote tissue healing and accelerates recovery. PRP is proved

enhances bone formation in alveolar clefts when admixed with iliac autologous bone graft as it leads to early bone formation, increased bone density, decreases bone resorption, low infection rate and least post-operative complications [25–27]. In the year 2006, platelet-rich fibrin (PRF) is introduced by Chokroun as the second generation concentrate of PRP [28]. PRF-mixed particulate autogenous bone graft was used in the treatment of bone defects. Some studies demonstrated that PRF increase new bone formation and has a positive effect on early bone healing [20, 29, 30]. Based on PRP and PRF, Florian N. et al. developed a new material termed mineralized plasmatic matrix (MPM), which contains platelets and fibrin concentrate in a liquid state; these materials can become bound to bone particles. The filling material is easy to shape and a PRF-type membrane is also generated alveolar cleft defects [31, 32]. MPM preparation is simple and totally autologous and thus devoid of risks of infection or rejection. MPM was considered as a third-generation platelet concentrate with potential applications in bone grafting process.

5.2 Surgical techniques of bone grafting for alveolar defect

5.2.1 Autogenous cancellous bone grafting technique

In the autogenous cancellous bone grafting technique, most authors used iliac crest cancellous bones to place directly on the graft base, then added cancellous bones to fill the cleft site and suture the vestibular flap without using any synthetic materials [33]. This was a technique commonly used in decades for bone grafting. This technique is chosen frequently for the purpose of moving teeth into the cleft.

5.2.2 Iliac crest bone block grafting technique

Cho-Lee et al. used pyramidal iliac block grafted with the cortical surface contacting the nasal mucosa and interspaced with cancellous chips in 90 patients. The results showed that successful bone graft was recorded in 87 patients (96.6%) and failed bone graft was recorded in 3 patients (3.4%). Therefore, iliac crest bone block combined with cancellous bones was suggested to achieve continuity and stabilization of maxillary segments after orthodontic treatment; and removal of fistula and sufficient bone formation for implantation [3, 30, 34].

5.2.3 The technique of using resorbable membrane to cover bone graft material

Peled et al. [8, 35] used a resorbable membrane (Resolut XT) and a non-dissolvable membrane (Gore-Tex) to cover the iliac crest cancellous bone before flap suturing. Better results were recorded in the group using dissolvable membrane and iliac crest cancellous bone compared to the group using non-dissolvable membrane and the group using only the iliac crest cancellous bone without membranes [8, 35, 36].

5.2.4 Technique of palatal bone graft with cortical iliac crest bone

Ishii M. et al. performed iliac cortex bone plate grafted into the palatal deficiency and particulate marrow and cancellous bone (PMCB) packed between the cortical bone and the reconstructed nasal flap. Better results were obtained using this technique compared to the technique using only iliac crest cancellous bone in case small palatal cleft [4].

5.2.5 The grafting technique using Monocortical Mandibular Bone Grafting

Mikoya T. et al. firstly introduced the two-piece symphysis bone grafting technique: one piece was inserted into palatal side of the cleft and the other was inserted into labial side of the cleft. Finally, two pieces were covered by suturing flap without screw fixation and no cancellous bone was added between two pieces [5]. The disadvantage of this technique was limited volume of symphysis bone graft.

5.3 Methods of bone grafting assessment

To evaluate the results of bone grafting in the alveolar cleft, most studies combined two-dimensional film (periapical radiography, bite-wing radiography) and Cone Beam CT radiography [33, 37]. The formation of bone bridge in the graft area was evaluated two-dimensionally using Enermark scale [17], Bergland scale [38], Kindelan scale [39], Witherow scale [40], and Long scale [41]; while the size and volume of grafting bone was evaluated three-dimensionally in Cone Beam CT radiography [16, 37, 38]. Enermark scale was introduced in 1987 by classifying bone bridge height between adjacent teeth of the alveolar cleft into four-point scale.

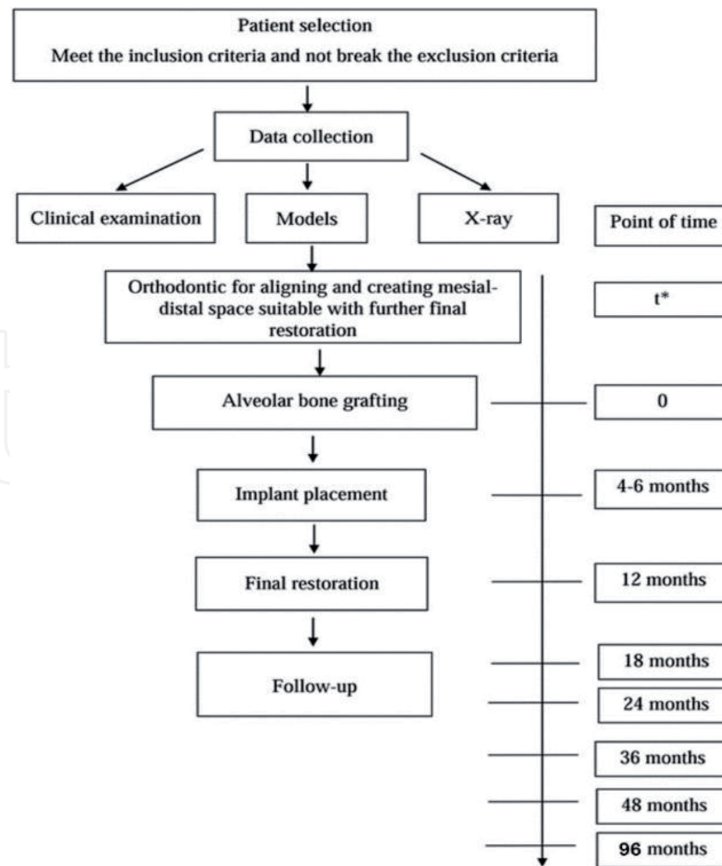
6. Proposal of new surgical technique

Based on previous techniques, our clinical experience with 32 cleft sites had confirmed the alveolar cleft bone graft outcomes and implant success with new technique of two iliac cortical bone blocks sandwich. Patient selection criteria was patients over 15 years old, patients in good health for endotracheal anesthesia, patients already had palatoplasty, patients with complete unilateral alveolar cleft, lack of permanent tooth germ in the cleft and did not receive any alveolar cleft bone graft. The patients underwent general dental treatment and pre-surgical orthodontic treatment. Any tooth extraction was performed 2 months before bone graft if necessary. All patients underwent late secondary bone grafting for alveolar cleft. The treatment protocol was suggested in **Figure 2**. This paragraph focused on introducing new technique and clinical results with follow-up time of 96 months after alveolar bone grafting.

6.1 Iliac bone block harvesting surgery

The main objective of first incision was to avoid damaging the lateral femoral cutaneous nerve. Under general anesthesia, the location of the anterosuperior iliac spine was marked. The incision was performed beginning 1 cm posterior to this marked point, with approximately 5 cm parallel to the iliac crest. The margin of the iliac crest was exposed by cutting the fascia and periosteum. Then, the monocortical bone was cut with a piezotome ultrasonic device and removed with a chisel by applying a medial approach. The cancellous bone was harvested with curettes. A hemostatic sponge was placed, and periosteal and intradermal sutures of coated Vicryl 4.0 (Polyglactin 910; Ethicon, Somerville, NJ) were performed to close the wound.

By combining the mean widths of the central incisor (about 8.5 mm), lateral incisor (about 8 mm), and canine (about 8.5 mm), the labial block size was required as 25 mm x 20 mm x 5 mm (**Figure 3A**). The palatal bone block size was 15 mm x 20 mm x 5 mm due to wider alveolar cleft at the nasal floor. Thus, the harvested iliac bone was required the total size of 40 mm x 20 mm x 5 mm (**Figure 3B**).



*t: time for orthodontic and general treatment depending on patient condition

Figure 2.
Treatment protocol for alveolar cleft bone graft.

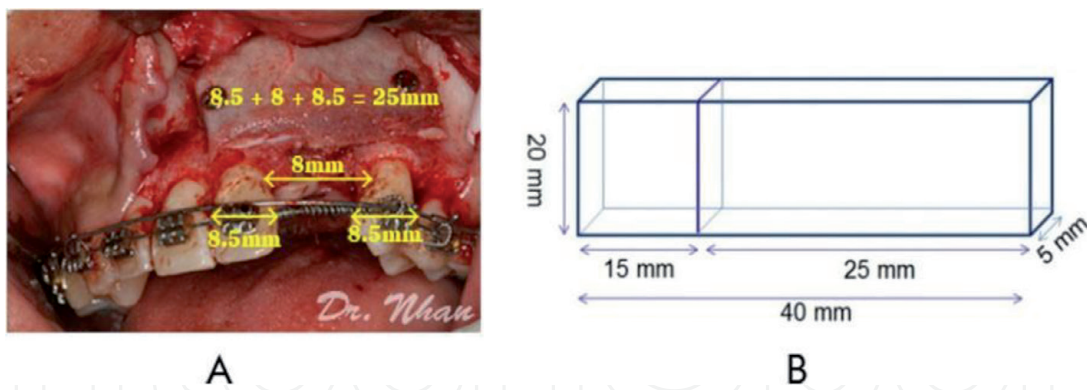


Figure 3.
Bone harvesting technique at the iliac crest. (A) the size of the labial bone block. (B) the total size of the bone block harvested from the iliac crest.

6.2 Alveolar cleft bone graft surgery

Alveolar cleft bone grafting was performed using the two iliac cortical bone blocks sandwich technique (**Figure 4**).

The incision was performed along the cleft margin under local anesthesia. In the labial, the incision was extended to about 2–3 adjacent teeth. Two vertical relieving incisions were made with 120° curved incisions at the ends. In the palate, the incision was continued from the cleft to the second premolar at each side, and a vertical relieving incision was applied from this area to 2/3 the distance from the gingiva margin toward the palatal midline, allowing anterior advancement of the palatal attached mucosa [42]. Full-thickness flaps were reflected labially and palatally.

The labial flaps had periosteal relieving incisions, which ensured sufficient sliding of the flaps (**Figure 5**).

After harvesting, the bone was divided into 2 corticocancellous blocks. The smaller block was shaped to fit the defect margin of palatal side and placed against the sutured nasal lining. The cortical bone layer was inserted toward the palatal side (**Figure 6A, B**). Harvested particulate cancellous bone was added to the cleft to reconstruct cancellous bone of the maxilla (**Figure 6C**).

The larger block (labial block) was shaped to fit the defect margin of labial side. The cortical bone layer was placed on the particulate cancellous bone and toward the labial side. It was fixed with screws (**Figure 6D**). After surgery, the radicular bone of the two teeth adjacent to the cleft and the area from the alveolar crest to the nasal floor were covered. During screw fixation, the palatal flap was closed precisely with interrupted sutures and protected by finger pressure. The palatal and labial mucoperiosteum were closed with horizontal mattress and interrupted sutures. Keratinized tissue overlaid the alveolar ridge and tension-free closure was achieved as all the flaps were advanced (**Figure 6E**).

All patients were indicated a preoperative antibiotic and oral antibiotics for 10 days postoperatively. The patients were hospitalized for 1 day for easy observation.

6.3 Implant placement and implant prosthodontics

After 4 to 6 months alveolar cleft bone grafting, an endosteal dental implant was placed in the grafted site with static guidance of an acrylic surgical stent (**Figure 7A**) [43]. The surgical procedure was performed under local anesthesia with undersized site preparation to achieve primary implant stability. Additional bone was placed simultaneously with implant insertion by the guided bone regeneration (GBR) or bone ring technique (large defects). A mixture of autogenous particulate bone and Osteon (30% hydroxyapatite and 70% β -tricalcium phosphate) was used with resorbable membrane (Genoss, Suwon, Korea) for GBR

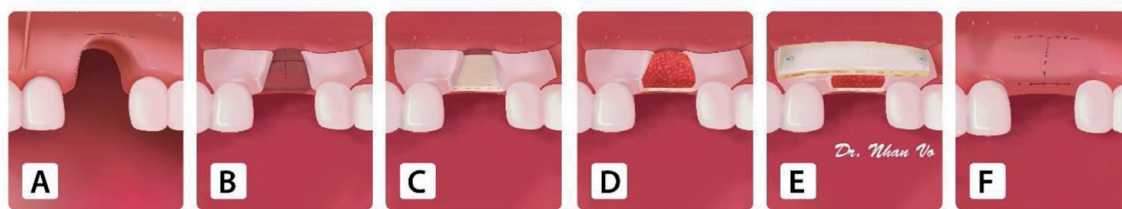


Figure 4. Illustration of the two iliac cortical bone blocks sandwich technique: (A) a flap design for alveolar cleft bone grafting. (B) the nasal flap closure. (C) the first bone block on the nasal lining. (D) Cancellous bone was packed on the first block. (E) the second bone block on the vestibular was secured by screws. (F) Wound closure.

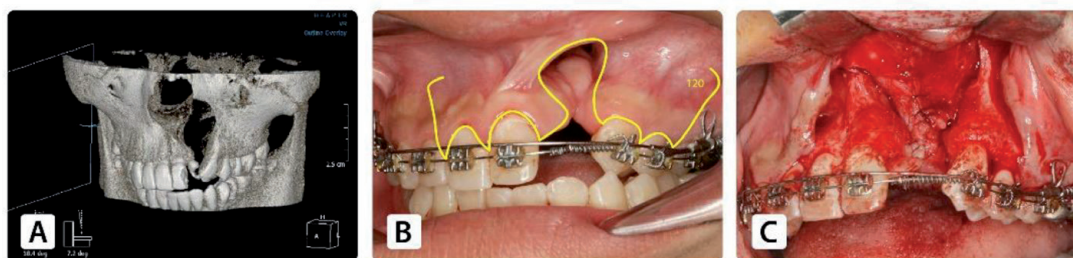


Figure 5. Bone grafting preparation. (A) the alveolar cleft on CT cone beam. (B) Pre-orthodontic and flap design for alveolar cleft bone graft surgery. (C) Nasal flap closure.

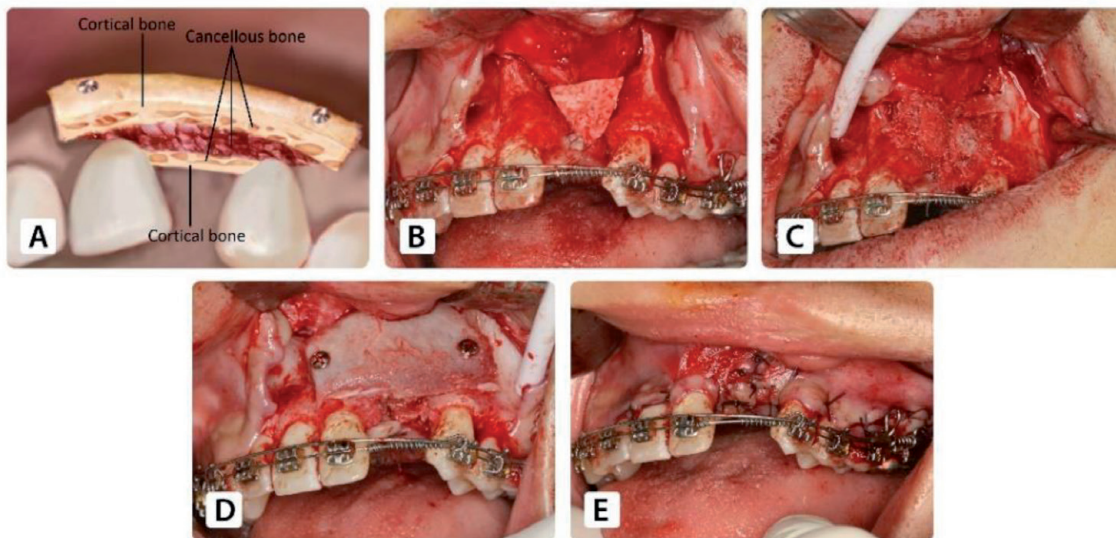


Figure 6. Alveolar bone grafting. (A) the technique of two iliac cortical bone blocks sandwich (B) the bone block on the nasal lining. (C) the cleft was nearly filled by cancellous bone. (D) the bone block on the vestibular was secured by screws. (E) Wound closure.

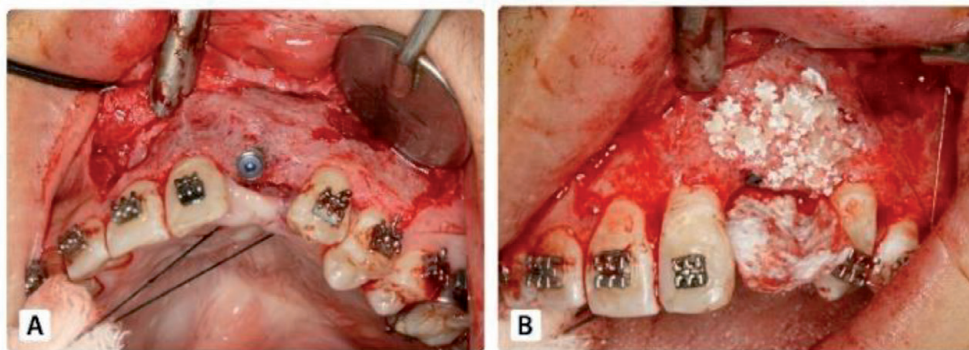


Figure 7. Dental implant placement after 4–6 months' bone grafting. (A) Dental implant placement. (B) Particulate additional bone grafting.

grafting technique (**Figure 7B**). Autogenous bone harvested at the position of the implant bed by a 3-mm-diameter trephine bur was used as particulate bone graft. Bone ring grafting is a technique of 3-dimensional crestal bone augmentation for vertical bone loss. The bone ring was harvested from symphysis or retromolar in a manner similar to that of Stevens et al. [44].

After 6-month follow-up, a healing screw was placed. Impressions were made for the final restoration after three weeks (**Figure 1**).

6.4 Assessment criteria for secondary alveolar cleft bone grafting

The following parameters were evaluated 7 days and 4 to 6, 12, 18, 24, 36, 48 and 96 months after alveolar bone grafting: (1) Soft tissue evaluation (dehiscence and infection), (2) fistula evaluation, (3) bone formation, and (4) implant health.

1. Soft tissue evaluation: was considered as good with pink mucosa, dry, tight flap, as average with the presence of dehiscence but no graft exposure and bad with the sign of infection, dehiscence or bone graft exposure.
2. Fistula evaluation: showed the closed or unclosed fistula

3. Bone formation was evaluated by periapical radiographs using Enermark scale and by Cone Beam CT. Periapical radiographs were obtained using the paralleling technique before alveolar bone grafting and at each follow-up visit. Enermark scale was used to evaluate bone bridge radiographically with the scores of 1 to 4, which represented the amount of bone fill in the grafted site (**Figure 8A**). Scores 1 and 2 were considered as successful, score 3 was suggested as partial failure, and score 4 was indicated as complete failure. Cone Beam CT were obtained with the surgical stent in which a gutta-percha was placed vertically along the potential axis of the final restoration. The images were imported into an imaging program (EasyDent V4 Viewer; Vatech, Suwon, Korea) to determine suitable graft dimensions for implant placement. The height which marked as *d* in **Figure 8B** was measured from the lowest point to the highest point of the graft. The width was calculated by averaging the buccolingual measurements of the apical, middle, and coronal one-thirds of the graft (marked as *a*, *b*, and *c*, respectively in **Figure 8B**). It's assumed that standard implants of 10 mm length would be biomechanically sound in the lateral incisor region, required grafted bone for implant placement was at least 7 mm height and 4 mm width.
4. Implant evaluation: included implant osseointegration and esthetic of implant prosthesis. Implant osseointegration was evaluated by Misch's criteria through 4 clinical groups. The successful group was determined as no pain or tenderness during function, no mobility, no history of exudate, and the crestal bone showed a loss of <2.0 mm on radiographs. The satisfactory group was determined as no pain or tenderness during function, no mobility, no history of exudate, and the crestal bone showed a loss of from 2 to 4 mm on radiographs. However, compromised group was determined as sensitivity and history of exudates, but no mobility, and bone loss >4 mm (less than half the length of the implant) on radiographs. Lastly, all of the following were observed in the failure group, including: pain during function, mobility, uncontrolled exudate, and radiographic bone loss more than half the length of the implant or loss of the implant. The esthetic of implant prosthesis was evaluated following pink esthetic score (PES) and white esthetic score (WES) based on Belser's standard (2009) [25]. The pink esthetic score assesses the soft tissue condition around the implant through 5 factors compared to the contralateral tooth: mesial papilla, distal papilla, curvature of the facial mucosa, height of the facial mucosa margin, soft tissue color and texture. White esthetic score presents the esthetic of the implant restoration with 5 parameters in comparison with the contralateral reference tooth: general tooth form, volume of the clinical crown; color, surface texture and other character-

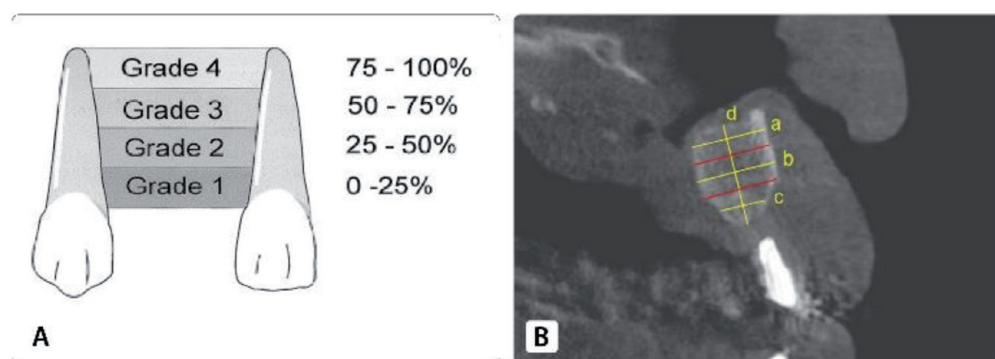


Figure 8. Evaluation bone formation. A. Using periapical radiograph with Enermark scale. B. Using cone beam computed tomography (CBCT).

ization. A maximum total score WES and PES of more than 12 was set for being esthetically successful, a score of 12 for clinical acceptance and a score of under 12 for esthetical failure. Degree of patient satisfaction was assessed by the score of 1 to 9 with a score of 1, 2, 3 for unsatisfactory, a score of 4, 5, 6 for satisfactory and a score of 7, 8, 9 for above satisfactory [45].

7. Outcome evaluation

The mean age before bone grafting was 21.28 years (range, 16–3 years). The mean follow-up period was 63.3 months (range from 18 to 96 months).

Evaluating criteria of bone grafting for alveolar cleft included flap status, fistula status, bone formation and implant health.

7.1 Soft tissue evaluation

After seven days' post-surgery, good healing was recorded in 29 cases (90.6%). Wound dehiscences occurred in three patients (9.4%), which resulted in a partial loss of bone. But the region healed uneventfully after exfoliation of small bone fragments. After 4 to 6 months, 100% of cases showed good mucosal healing.

7.2 Fistula evaluation

After seven days' post-surgery, complete closure of the oronasal fistula was achieved in all 32 patients.

7.3 Result of bone formation using Enermark scale

After 4 to 6 months' follow-up, the bone formation score I was 90.6% in 29 patients and score III was 9.4% in 3 patients. Score III were insufficient bone for dental implant so these 3 patients were indicated fixed bridge and removed from the follow-up. At 12 months' follow-up, there was no change in 29 patients scored I. After 18 months postoperatively, 1 patient appeared bone resorption which dropped from score I to score II. However, score I and score II were considered as successful by Enermark, so the total success rate of the graft was 90.6% (including 3 cases of score III) (Table 1). Bone bridge formation in the cleft at the point of 18 months

Time after grafting (months)	Patient	Implant	Enermark score (No of patient)			
			1	2	3	4
4–6	32		29 (90.6%)	0	3 (9.4%)	0
<12	29	32	29 (100%)	0	0	0
18	29	32	28 (96.6%)	1 (3.4%)	0	0
24	23	26	22 (95.6%)	1 (4.3%)	0	0
36	20	23	19 (95%)	1 (5%)	0	0
48	18	21	18 (100%)	0	0	0
96	15	18	15 (100%)	0	0	0

$p > 0.05$.

Table 1.
Results of bone formation according to Enermark scale.

compared with the point of 6 and 12 months showed no statistically significant differences ($p > 0,05$). Thus, implant placement can limit bone resorption. After 96 months, only 15 patients with total 18 implant were still remained follow-up presented Enermark score I (**Figure 9B, D**).

7.4 Result of bone formation using CT Cone Beam

On axial CT at 6 months postoperatively, the mean apical-coronal distance of $11.4.0 \pm 2.4$ mm and the mean buccal-lingual distance of 6.1 ± 1.0 mm was reported. According to Renouard's standard [46], 29 of 32 alveolar clefts (90.6%) displayed the bone bridge formation enable for implant placement. Three clefts (9.4%) showed insufficient bone for implant placement which indicated fixed bridge restorations.

7.5 Result of implant placement

Total of 32 implants were placed, of which 31 implants were of size 3.8 x 10 mm and 1 implant was 3.8 x 12 mm. 3/32 patients received 2 implants placement, 26/32 patients received 1 implant placement. Initial implant stability: over 35 N/cm² in 12.4% of implants, 20–35 N/cm² in 43.8% and 15-20 N/cm² in 43.8%. Additional bone graft during implant placement were performed in all 32 patients, in which 90.6% used GBR technique and 9.4% used ring bone technique.

7.6 Result of implant osseointegration

After 12 months' follow-up, 100% implants were successful (**Table 2**). However, after 18 months, 96.9% (31 implants) were successful, 3.1% (1 implant) appearing with 2 mm bone loss making it become satisfactory survival, no implant failure. The total survival of implants in good function were still 100%. The survival rate at the point of 12 had no significant difference compared to the point of 18 months ($p > 0.05$). After 90 months, all 18 implants were recorded success in 15 patients remained follow-up (**Figure 9E, F**).

7.7 Esthetic result of the prostheses on implant

Esthetic result followed pink esthetic score (PES) and white esthetic score (WES) based on Belser's standard (2009) [25]. In the follow up of 12 months after implant placement, 18 implant prostheses (56.3%) were esthetical success,

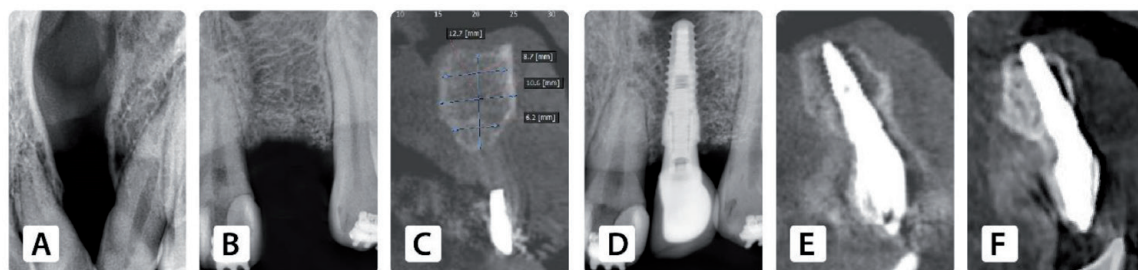


Figure 9. Postoperative treatment outcome on radiography (A) clinical alveolar cleft. (B) Bone formation after alveolar bone grafting. (C) Bone volume before implant placement. (D) Dental implant placement on periapical radiography. (E) Dental implant placement on CBCT. (F) Dental implant after 96 months' follow-up on CBCT.

Point of times (Months)		Patient	Implant	Results on implant osseointegration (No of implant)			
Post bone graft	Post implant Surgery			Success	Satisfactory survival	Compromised survival	Failure
12	6	29	32	32 (100%)	0	0	0
18	12	29	32	31 (96.9%)	1 (3.1%)	0	0
24	18	23	26	25 (96.1%)	1 (3.9%)	0	0
36	30	20	23	22 (95.7%)	1 (4.3%)	0	0
48	42	18	21	21 (100%)	0	0	0
96	90	15	18	18 (100%)	0	0	0

p > 0.05.

Table 2.
Results of implant osseointegration.

5 prostheses (15.6%) were clinical acceptable and 9 prostheses (28.1%) were esthetical failure. After 90 months implant postoperative, among 15 patients with 18 implants remained follow-up, 15 implant prostheses (83.4%) were esthetical success, 1 prosthesis (5.5%) were clinical acceptable and 2 prostheses (11.1%) were esthetical failure.

7.8 Result of degree of patient satisfaction of the prostheses on implant

In the follow up of 12 months after implant placement, 21 patients (72.4%) were above satisfied with their prostheses, 8 patients (27.6%) satisfied and no patients disappointed with their prostheses on implants. After 90 months implant postoperative, all 15 patients attended follow-up examination reported above satisfied with their prostheses.

8. Discussion

8.1 Result of alveolar bone graft

According to the radiographic findings, 90.6% (29/32) of the patients had sufficient bone volume for implant placement. This rate was similar to Abyholm's study (1981) with a success rate of 91% [47] or Bergland's study (1986) of 90% [38]. Besides, this result was higher than the success rate of Grant's (2009) of 76% [42], Nightingale's (2003) of 71% [48], Witherow's (2002) of 65% [40]. This result confirmed the optimal outcomes of the proposed grafting technique. Bone volume was also well-reconstructed in both apical-coronal direction (11.4 ± 2.4 mm) and buccal-lingual direction (6.1 ± 1.0 mm) based on criterion of successful implant by Franck Renouard [46]. This result was consistent with Takadashi's study [11]. The bone grafting result is still maintained success after 96 months' bone grafting in 18 patients attended for follow up.

Twenty-nine patients had sufficient bone volume for implant placement, evaluated as Enermark score 1, which was considered successful bone grafting. Therefore, the alveolar crest level of the cleft area was usually resorbed apically 1 to 2 mm after secondary alveolar graft [45]. To optimize the esthetics of the prosthesis on implant, additional bone graft was performed after implant insertion to cover all the exposed implant threads at the same time. It also supported the soft tissue and improved the esthetics of the prosthesis.

A mixture of autogenous particulate bone and Osteon (30% hydroxyapatite and 70% β -tricalcium phosphate) (Genoss, Suwon, Korea) was used for additional bone graft. Two different techniques were applied for additional grafting. Among 32 implant surgeries, GBR grafting technique was performed for 29 implants (90.6%) due to small defect size. Three implants with greater bone defect was reconstructed with a bone ring technique [44]. The GBR technique was applied more frequent than the bone ring technique in this study. It can be inferred that the bone defect after secondary bone grafting with the 2 iliac corticocancellous blocks was not remarkable.

8.2 Results of implant osseointegration

Implant surgery in the alveolar cleft was considered to achieve unsatisfactory results due to low stability. However, some studies showed the viability of this procedure [49]. Our technique recorded implant survival rate of 100% in 29 patients with 32 implants up to 8 years of follow-up. This result was similar to the findings of other studies, including: Yoshiro Matsui et al. (with implant survival rate 98.6%) [50], and Samuel's [51]. In contrast, the result was higher than Hartel's and Kramer's [52]. Moreover, it was demonstrated that implant placement maintained bone volume after secondary grafting [1]. Endosteal dental implants placed in the grafted area not only closed the gap but also stimulated the bone during mastication [9]. However, oral health status, esthetics, function, and patient desires should be considered and precise treatment plan should be established prior to implant surgery.

To ensure biomechanical stability, implants of 10 or 12 mm in length and 3.8 mm in diameter were used in this study. Despite successful alveolar bone grafting, the implant length measured from the alveolar height is frequently reduced in patients with cleft. According to Esper et al., irregularities of 1 to 2 mm is recorded in the soft tissue margin of the tooth adjacent to the cleft compared with the contralateral tooth [45]. Moreover, an additional bone graft was performed during implant surgery to improve the soft tissue profile and esthetics of the final restoration. Guided bone regeneration was applied in most cases, and only 3 cases indicated the bone ring technique. This result suggested the effectiveness of the two iliac cortical bone blocks sandwich technique.

Primary stability of implant was challenging to achieve in grafted bone. To enhance primary stability, several methods were applied such as undersizing site preparation, bone compression, rough tapered implants with more threads in the neck, as well as increasing the contact area between the bone and the implant during implant surgery. However, only 12.4% of the implants were placed achieving the insertion torque greater than 35 N/cm². Neugebauer et al. suggested that immediate loading in single-tooth should be indicated only if the implant can be placed with an insertion torque over 35 N/cm² [53]. Thus, to optimizing osseointegration, the implant restorations were carried out after a healing period of 6 months [53].

The interval between alveolar bone grafting and implant placement was considerably important, especially in patients with alveolar clefts. The longer the interval was, the greater the potential of alveolar bone resorption was [11, 49]. The interdental alveolar crest level (IACL) was recorded a significantly decrease after 24 months' bone grafting [11]. A maximum interval of 4 to 6 months was suggested after bone grafting in the permanent dentition [49]. In our study, in some

first cases, bone loss was found 6 months after bone grafting which coincided with the time of implant placement. Therefore, the waiting time was shortened and dental implants were inserted after 4 months. In fact, the indistinguishable border between the grafted bone and the native bone and good healing was confirmed. Better clinical results and greater osteogenic activity were achieved if secondary bone grafting was performed before canine eruption [1, 9]. Abyholm et al. recorded a higher failure rate when osteoplasty was performed late [54]. Yet, implant placement was generally not recommended before the growth spurt because implants were similar to ankylosed teeth. In other words, implants did not move along with other parts of the jaw during rapid growth in adolescence, resulting in a short prosthesis. Therefore, in our study, selected age of all the patients were older than 16 years.

8.3 Esthetic result of prostheses on implant

According to the esthetic standards by Belser, the results of our study showed that 18 implant prostheses (56.3%) were esthetically successful (score > 12), 5 prostheses were clinically acceptable (score = 12) and 9 prostheses were esthetical failures (score < 12). Based on the assessment of clinicians, 71.9% of the implant prostheses were clinically acceptable and 28.1% were esthetical failures. These unsatisfactory results were explained probably by two following reasons:

1. Complicated and unfavorable initial clinical condition such as horizontal or vertical bone defect caused by alveolar cleft existence. The insufficient bone height after bone graft still occurred especially in late secondary bone graft. Moreover, lack of soft tissues and the absence of the gum papilla also presented compared with the contralateral tooth [45].
2. There was no exclusive esthetic evaluation standard of prostheses on implant for cleft lip and palate patients.

Nevertheless, 100% patients expressed their satisfaction with their dental restorations, including the aesthetical failures of 28.1% assessed by clinicians. In cleft lip palate patients, the initial conditions were complex and unfavorable with the presence of cleft lip defect (no bones, no gums, no teeth), the presence of fistula, malposition of teeth around the cleft, malocclusion, arch deformity. After treatment, were obtained. The post-treatment results created significant changes for patients, such as closure of fistula, cleft, rehabilitation of bone, gums and teeth, especially completely change their appearance and self-confident. That explained why all patients were satisfied with their implant prostheses.

9. Conclusion

This chapter provides a new treatment method for patients with cleft lip and palate defect, not only to recover the function but also to meet the esthetic demand helping patients communicate confidently for community integration. The technique of two iliac cortical bone blocks sandwich has combined the advantages of cortical bone and cancellous bone that limit bone resorption, easily obtain the implant initial stability, rapidly vascularization and quick healing. Therefore, the new proposal technique seemed to be a practical and a feasible solution for the rehabilitation of alveolar cleft.

Acknowledgements

The authors wish to thank the staff of the Nhan Tam Dental Clinic, Ho Chi Minh City, Vietnam.

Conflict of interest

The authors have stated explicitly that there is no conflict of interest in connection with this article.

Author details

Nhan Van Vo^{1,2*}, Nguyen Quan Pham², Chien Dac Ho², Son Van Le³
and Ha Manh Nguyen⁴

1 Nhan Tam Dental Clinic, VietNam


2 Faculty of Odonto-Stomatology, Hong Bang International University, Viet Nam

3 Oral and Maxillofacial Surgery Department, Hanoi Medical University, Vietnam

4 Oral and Maxillofacial Surgery Department, National Hospital of Odonto-Stomatology, Ha Noi, Vietnam

*Address all correspondence to: drnhan1@gmail.com

IntechOpen

© 2021 The Author(s). Licensee IntechOpen. This chapter is distributed under the terms of the Creative Commons Attribution License (<http://creativecommons.org/licenses/by/3.0>), which permits unrestricted use, distribution, and reproduction in any medium, provided the original work is properly cited. 

References

- [1] Nakamura N. Surgical Strategy for Secondary Correction of Unilateral and Bilateral Cleft Lip-Nose Deformities. *Rhinoplasty*. 2011; 5:57-70.
- [2] Luque-Martín E, Tobella-Camps ML, Rivera-Baró A. Alveolar graft in the cleft lip and palate patient: Review of 104 cases. *Medicina oral, patología oral y cirugía bucal* 2014;19(5):e531-e5e7. <https://doi.org/10.4317/medoral.19413>
- [3] Cho-Lee GY, García-Díez EM, Nunes RA, Martí-Pagès C, Sieira-Gil R, Rivera-Baró A. Review of secondary alveolar cleft repair. *Annals of maxillofacial surgery* 2013;3(1):46-50. <https://doi.org/10.4103/2231-0746.110083>
- [4] Ishii M, Ishii Y, Moriyama T, Gunji A, Morita K, Imaizumi F, et al. Simultaneous cortex bone plate graft with particulate marrow and cancellous bone for reliable closure of palatal fistulae associated with cleft deformities. *Cleft Palate Craniofac J* 2002;39(3):364-369. https://doi.org/10.1597/1545-1569_2002_039_0364_scbpgw_2.0.co_2
- [5] Mikoya T, Inoue N, Matsuzawa Y, Totsuka Y, Kajii TS, Hirose T. Monocortical mandibular bone grafting for reconstruction of alveolar cleft. *The Cleft Palate-Craniofacial Journal* 2010;47(5):454-468. <https://doi.org/10.1597/09-172>
- [6] Posnick JC, Ruiz RL. Staging of cleft lip and palate reconstruction: infancy through adolescence. In: Wyszynski DF, editor. *Cleft Lip and Palate: From Origin to Treatment*. New York: Oxford University Press; 2002. p. 319-353.
- [7] Ladeira PRSD, Alonso N. Protocols in cleft lip and palate treatment: Systematic review. *Plastic Surgery International* 2012;2012. <https://doi.org/10.1155/2012/562892>
- [8] Peled M, Aizenbud D, Horwitz J, Machtei EE. Treatment of osseous cleft palate defects: A preliminary evaluation of novel treatment modalities. *Cleft Palate Craniofac J* 2005;42(4):344-348. <https://doi.org/10.1597/03-141.1>
- [9] Dempf R, Teltzrow T, Kramer F-J, Hausamen J-E. Alveolar bone grafting in patients with complete clefts: A comparative study between secondary and tertiary bone grafting. *The Cleft palate-craniofacial journal : official publication of the American Cleft Palate-Craniofacial Association* 2002;39:18-25. https://doi.org/10.1597/1545-1569_2002_039_0018:ABGIPW_2.0.CO_2
- [10] Boyne PJ, Sand NR. Secondary bone grafting of residual alveolar and palatal clefts. *Journal of oral surgery (American Dental Association : 1965)* 1972;30:87-92.
- [11] Takahashi T, Masayuki F, Tai Y. Placement of Endosseous implants into bone-grafted alveolar clefts: Assessment of bone bridge after autogenous particulate cancellous bone and marrow graft. *Int J Oral Maxillofacial Implants* 1999;14:86-93.
- [12] Fukuda M, Lino M, Takahashi T. Closure of large oronasal fistulas at the time of secondary bone grafting in patients with cleft lip and palate. *Scand J Plast Reconstr Surg Hand Surg* 2003;37(6):339-343. <https://doi.org/10.1080/02844310310004424>
- [13] Uzel A. Orthodontics in Relation with Alveolar Bone Grafting in CLP Patients. 2018.
- [14] Sindet-Pedersen S, Enemark H. Mandibular bone grafts for

reconstruction of alveolar clefts. *J Oral Maxillofac Surg* 1988;46(7):533-537. [https://doi.org/10.1016/0278-2391\(88\)90142-5](https://doi.org/10.1016/0278-2391(88)90142-5)

[15] Enemark H, Jensen J, Bosch C. Mandibular bone graft material for reconstruction of alveolar cleft defects: Long-term results. *The Cleft palate-craniofacial journal : official publication of the American Cleft Palate-Craniofacial Association* 2001;38:155-163. [https://doi.org/10.1597/1545-1569\(2001\)038<0155:MBGMFR>2.0.CO;2](https://doi.org/10.1597/1545-1569(2001)038<0155:MBGMFR>2.0.CO;2)

[16] Murthy AS, Lehman JA. Secondary alveolar bone grafting: An outcome analysis. *The Canadian journal of plastic surgery = Journal canadien de chirurgie plastique* 2006;14(3):172-174. <https://doi.org/10.1177/229255030601400307>

[17] Enemark H, Sindet-Pedersen S, Bundgaard M. Long-term results after secondary bone grafting of alveolar clefts. *J Oral Maxillofac Surg* 1987;45(11):913-919. [https://doi.org/10.1016/0278-2391\(87\)90439-3](https://doi.org/10.1016/0278-2391(87)90439-3)

[18] Swan MC, Goodacre TE. Morbidity at iliac crest donor site following bone grafting of the cleft alveolus. *Br J Oral Maxillofac Surg* 2006;44:129-133. <https://doi.org/10.1016/j.bjoms.2005.04.015>

[19] Canady JW, Zeitler DP, Thompson SA. Suitability of the iliac crest as a site for harvest of autogenous bone grafts. *Cleft Palate Craniofac J* 1993;30:579-581. https://doi.org/10.1597/1545-1569_1993_030_0579_sotica_2.3.co_2

[20] Mossaad A, Badry TE, Abdelrahman M, Abdelazim A, Ghanem W, Hassan S, et al. Alveolar cleft reconstruction using different grafting techniques. *Open access Macedonian journal of medical sciences*

2019;7(8):1369-1373. <https://doi.org/10.3889/oamjms.2019.236>

[21] de Ruiter A, Janssen N, van Es R, Frank M, Meijer G, Koole R, et al. Micro-structured P-tricalcium phosphate for repair of the alveolar cleft in cleft lip and palate patients: A pilot study. *Cleft Palate Craniofac J* 2015;52:336-340. <https://doi.org/10.1597/13-260>

[22] Janssen NG, Schreurs R, de Ruiter AP, Sylvester-Jensen HC, Blindheim G, Meijer GJ, et al. Microstructured beta-tricalcium phosphate for alveolar cleft repair: A two-Centre study. *Int J Oral Maxillofac Surg* 2019;48(6):708-711. <https://doi.org/10.1016/j.ijom.2018.11.009>

[23] Scalzone A, Flores-Mir C, Carozza D, d'Apuzzo F, Grassia V, Perillo L. Secondary alveolar bone grafting using autologous versus alloplastic material in the treatment of cleft lip and palate patients: Systematic review and meta-analysis. *Prog Orthod* 2019;20(1):6. <https://doi.org/10.1186/s40510-018-0252-y>

[24] Mona N B, Archana R. Stem cell therapy for reconstruction of alveolar cleft and trauma defects in adults: A randomized controlled, clinical trial. *Clin Implant Dent Relat Res* 2017 19(5):793-801. <https://doi.org/10.1111/cid.12506>

[25] Belser U, Grütter L, Vailati F, Bornstein M, Weber H-P, Buser D. Outcome evaluation of early placed maxillary anterior single-tooth implants using objective esthetic criteria: A cross-sectional, retrospective study in 45 patients with a 2- to 4-year follow-up using pink and white esthetic scores. *Journal of periodontology* 2009;80:140-151. <https://doi.org/10.1902/jop.2009.080435>

- [26] Osman O, Kamel IH, Elshereif A, Mohamed AM, Magdy A. Effect of platelet rich plasma (PRP) on bone graft in alveolar cleft repair. *The Egyptian Journal of Plastic and Reconstructive Surgery* 2020;43(3):417-424. <https://doi.org/10.21608/ejprs.2020.68177>
- [27] Bezerra BT, Pinho JNA, Figueiredo FED, Brandão J, Ayres LCG, da Silva LCF. Autogenous bone graft versus bovine bone graft in association with platelet-rich plasma for the reconstruction of alveolar clefts: A pilot study. *Cleft Palate Craniofac J* 2019;56(1):134-140. <https://doi.org/10.1177/1055665618770194>
- [28] Choukroun J, Diss A, Simonpieri A, Girard MO, Schoeffler C, Dohan SL, et al. Platelet-rich fibrin (PRF): A second-generation platelet concentrate. Part IV: Clinical effects on tissue healing. *Oral Surg Oral Med Oral Pathol Oral Radiol Endod* 2006;101(3):e56-e60. <https://doi.org/10.1016/j.tripleo.2005.07.011>
- [29] Al-Mahdi, Akmam HA, Mustafa S, Hadi Al-Jumaily, Hassanien A. Evaluation the Effectiveness of Using Platelet Rich Fibrin (PRF) With Bone Graft in the Reconstruction of Alveolar Cleft, A Prospective Study. *Journal of Craniofacial Surgery* 2021; Publish Ahead of Print.
- [30] Naguib, AS. Evaluation of use of platelet rich fibrin combined with autogenous iliac bone graft for closure of unilateral alveolar cleft. *Egyptian Dental Journal* 2018;64:3237-3244.
- [31] Nadon F, Chaput B, Périssé J, de Bérail A, Lauwers F, Lopez R. Interest of mineralized plasmatic matrix in secondary autogenous bone graft for the treatment of alveolar clefts. *J Craniofac Surg* 2015;26(7):2148-2151. <https://doi.org/10.1097/scs.0000000000001951>
- [32] Amine K, Gharibi A, Hsaine A, Kissa J. Effect of bone regeneration with mineralized plasmatic matrix for implant placement in aesthetic zone. *Case Reports in Dentistry* 2017;2017:2639564. <https://doi.org/10.1155/2017/2639564>
- [33] Chu YY, Chang FC, Lu TC, Lee CH, Chen PK. Surgical outcomes of secondary alveolar bone grafting and extensive Gingivoperiosteoplasty performed at mixed dentition stage in unilateral complete cleft lip and palate. *J Clin Med* 2020;9(2). <https://doi.org/10.3390/jcm9020576>
- [34] Du Y, Zhou W, Pan Y, Tang Y, Wan L, Jiang H. Block iliac bone grafting enhances osseous healing of alveolar reconstruction in older cleft patients: A radiological and histological evaluation. *Medicina oral, patologia oral y cirugía bucal* 2018;23(2):e216-ee24. <https://doi.org/10.4317/medoral.21991>
- [35] Larsen PE. Reconstruction of the Alveolar Cleft. *Peterson's Principles of Oral and Maxillofacial Surgery* 2012 p. 859 - 870.
- [36] Aly LAA, Hammouda N. Secondary closure of alveolar cleft with resorbable collagen membrane and a combination of intraoral autogenous bone graft and deproteinized anorganic bovine bone. *Annals of maxillofacial surgery* 2016;6(2):165-171. <https://doi.org/10.4103/2231-0746.200351>
- [37] Yu X, Guo R, Li W. Comparison of 2- and 3-dimensional radiologic evaluation of secondary alveolar bone grafting of clefts: A systematic review. *Oral Surgery, Oral Medicine, Oral Pathology and Oral Radiology* 2020;130(4):455-463. <https://doi.org/10.1016/j.o000.2020.04.815>
- [38] Bergland O, Semb G, Abyholm FE. Elimination of the residual alveolar cleft by secondary bone grafting and subsequent orthodontic treatment. *Cleft Palate J* 1986;23(3):175-205.

- [39] Kindelan JD, Nashed RR, Bromige MR. Radiographic assessment of secondary autogenous alveolar bone grafting in cleft lip and palate patients. *The Cleft Palate-Craniofacial Journal* 1997;34(3):195-198. https://doi.org/10.1597/1545-1569_1997_034_0195_raosaa_2.3.co_2
- [40] Witherow H, Cox S, Jones E, Carr R, Waterhouse N. A new scale to assess radiographic success of secondary alveolar bone grafts. *Cleft Palate Craniofac J* 2002;39(3):255-260. https://doi.org/10.1597/1545-1569_2002_039_0255_anstar_2.0.co_2
- [41] Long RE Jr, Spangler BE, Yow M. Cleft width and secondary alveolar bone graft success. *Cleft Palate Craniofac J* 1995;32(5):420-427. https://doi.org/10.1597/1545-1569_1995_032_0420_cwasab_2.3.co_2
- [42] McIntyre GT, Devlin MF. Secondary alveolar bone grafting (CLEFTSiS) 2000-2004. *Cleft Palate Craniofac J* 2010;47:66-72.
- [43] Belser UC, Buser D, Hämmerle C, Jung R, Martin WC, Morton D, et al. *ITI Treatment Guide: Implant Therapy in the Esthetic Zone – Single-Tooth Replacements*. 2007.
- [44] Stevens MR, Emam HA, Alaily ME, Sharawy M. Implant bone rings. One-stage three-dimensional bone transplant technique: A case report. *J Oral Implantol* 2010;36(1):69-74. <https://doi.org/10.1563/aaid-joi-d-09-00029>
- [45] Esper L, Sbrana M, Ribeiro I, Siqueira E, Almeida AL. Esthetic analysis of gingival components of smile and degree of satisfaction in individuals with cleft lip and palate. *The Cleft palate-craniofacial journal: official publication of the American Cleft Palate-Craniofacial Association* 2009;46:381-387. <https://doi.org/10.1597/07-189.1>
- [46] Franck R, Bo R. Treatment of the edentulous maxilla. Risk factors in implant dentistry, simplified clinical analysis for predictable treatment: Quintessence Publishing Co, Inc; 1999. p. 67-109.
- [47] Amanat N, Langdon JP. Secondary alveolar bone grafting of the lip and palate. *Journal of Cranio-Maxillofacial Surgery* 1991;19:7-14.
- [48] Nightingale C, Witherow H, Reid FD. Comparative reproducibility of three methods of radiographic assessment of alveolar bone grafting. *Eur J Orthod* 2003;25:35-41.
- [49] Kearns G, Perrott DH, Sharma A, Kaban LB, Vargervik K. Placement of endosseous implants in grafted alveolar clefts. *Cleft Palate Craniofac J* 1997;34(6):520-525. https://doi.org/10.1597/1545-1569_1997_034_0520_poeiig_2.3.co_2
- [50] Yoshiro Matsui KO, Akiko Nishimura. Long term study of dental implants places into alveolar clefts sites. *The Cleft Palate Craniofacial Journal* 2007;44(4):444-447. <https://doi.org/10.1597/06-095.1>
- [51] Samuel BF, Luis AE, Michyele CS. Survival of dental implants In the cleft area- a retrospective study. *Cleft Palate Craniofac J* 2010;47 (6):566-590.
- [52] Kramer FJ, Baethge C, Swennen G. Dental implants in patients with orofacial clefts: A long-term follow-up study. *Int J Oral Maxillofac Surg* 2005;34:715-721. <https://doi.org/10.1016/j.ijom.2005.04.014>
- [53] Neugebauer J, Traini T, Thams U, Piattelli A, Zöller JE. Peri-implant bone organization under immediate loading state. Circularly polarized light analyses:

A minipig study. *J Periodontol*
2006;77(2):152-160. <https://doi.org/10.1902/jop.2006.040360>

[54] Abyholm FE, Bergland O, Semb G.
Secondary bone grafting of alveolar
clefts. A surgical/orthodontic treatment
enabling a non-prosthetic
rehabilitation in cleft lip and palate
patients. *Scand J Plast Reconstr Surg*
1981;15(2):127-140. <https://doi.org/10.3109/02844318109103425>

IntechOpen