

We are IntechOpen, the world's leading publisher of Open Access books Built by scientists, for scientists

5,600

Open access books available

137,000

International authors and editors

170M

Downloads

Our authors are among the

154

Countries delivered to

TOP 1%

most cited scientists

12.2%

Contributors from top 500 universities



WEB OF SCIENCE™

Selection of our books indexed in the Book Citation Index
in Web of Science™ Core Collection (BKCI)

Interested in publishing with us?
Contact book.department@intechopen.com

Numbers displayed above are based on latest data collected.
For more information visit www.intechopen.com



Concepts and Clinical Applications of Intraoral 3D Scanning in the Management of Patients with Orofacial Clefts

Rahma ElNaghy, Sara Amin and Majd Hasanin

Abstract

Digital workflow in the dental is on the brink of completely replacing the traditional workflow. This opened the frontier for the introduction of intraoral scanners (IOS). In the craniofacial field, IOS has proven its applicability in various procedures with highly promising results. This includes comprehensive diagnosis of patients with orofacial clefts and custom-made treatment planning of challenging cases as well as its use in nasoalveolar molding (NAM) therapy. IOS also opened the horizon to the advanced digital workflow required for appliances design, manufacturing, and virtual surgical planning. IOS offer various advantages that decrease the time, effort for both the patients, their families and care providers. IOS adopt different optical technologies what aim for precise recording of a three-dimensional (3D) object. This chapter aims to provide a comprehensive review of the use of intraoral scanners in the craniofacial field.

Keywords: Intraoral scanning, Intraoral scanners, digital workflow, direct digital impression, digital 3D model

1. Introduction

The management of individuals with orofacial clefts extends from infancy till adulthood. Taking impressions of the dental arches is a frequently needed procedure, that can be utilized for recording, measuring and planning. However, conventional impression is considered a technique-sensitive procedure and prone to some complications and limitations, such as dimensional changes and patients' intolerability, especially in patients with orofacial clefts. Moreover, storage and maintenance of the poured models is a continuous challenge to clinicians. The last decade has witnessed a digital revolution that led to the introduction of digital intraoral scanners for dentistry. Since then, the number of IOS devices as well as their technology are tremendously growing to offer accurate and comfortable replacement for the traditional impression techniques. This chapter summarizes the different IOS technologies, advantages, clinical considerations, and applications in the craniofacial field.

2. Intraoral scanners technologies

The very first intraoral scanner was introduced in the 1980 [1] and incorporated into the CEREC® by Sirona Dental Systems LLC (Charlotte, NC) system for restorative dentistry. Later after that, many manufacturers introduced multipurpose IOS to the market including the orthodontic purposes. IOS adopt non-optical technologies to provide an intraoral three-dimensional map where data points are captured by either a scanning unit or handheld wand and fed back to a workstation and can be viewed on a monitor. These technologies include confocal imaging, triangulation, and 3D in motion video [2].

2.1 Confocal imaging

Acquisition is briefly based on capturing of in-focus (confocal) images and deflecting any defocused images which increases the scan accuracy [3]. Trios IOS AND iTero Element are examples of the majority of the IOS that adopt the confocal imaging. Both offer systems where the teeth are not necessarily powder coated before scanning, thus shorten the scanning time and enhance the color capture [4]. They have a wide use in implant and restorative dentistry, and the orthodontic field.

2.2 Triangulation

This technology allows for capturing high-speed data in recording undesirable or inaccessible areas. It uses either a lens or a light source, and a sensor that is sensitive to light for image formation. The is based upon Pythagoras theorem, where by knowing the position and angle of two points of a triangle, we can easily calculate the position of the third point (object). Single detector “prism shaped” or two detectors are used to detect the two different points in the exact time. Cerec (Dentsply Sirona, USA) adopts this technology. Bluecam Cerec requires a reflective powder coating for scanning while Omnicam Cerec can provide a powderless scan [2].

2.3 3D in motion video

This technology generates a true replica of the oral anatomy using a high-resolution video camera. It captures 3D data in a video sequence and models the data in real time. IOS that adopt this technology require a powder coating. However, it is lighter than that used with IOS with triangulation technology [2]. 3 M ESPE IOS adopt this technology.

3. Advantages of intraoral scanners

The capability of directly recording the patient’s dental arch and creating a digital 3D model alleviates the need for conventional impression techniques which may cause patient discomfort or inconvenience by either the material itself or the impression tray [5–7]. Neonates, Children, and patients with gag reflex cannot tolerate the conventional procedure, that’s why the intraoral scanning process is much appreciated [8–10]. It is reported by the literature that patients prefer intraoral scanning process over the traditional impression techniques [11].

Intraoral scanners are proven to save working time in comparison with the conventional techniques [12, 13]. Although IOS do not appear to significantly save time in full arch scans (take less than 3 minutes) when compared to the conventional techniques that take from 3 to 5 minutes. However, they save time afterwards where

the following steps of cast pouring, direct communication can be done with the laboratory by emailing the 3D digital model rather than courier delivery or using regular mail [12, 14–16]. Consequently, IOS can save throughout the working year a considerable amount of money and time [11, 14, 15, 17–20].

Communication between dentist and dental technician can be simplified, strengthened, and improved by being offered a real time assessment of the optical impression quality [15, 20, 21]. In addition to that, IOS can serve as an effective tool for patient education as well as communication which amplifies the psychological involvement that positively affect the overall treatment journey. Also, IOS can be considered as a powerful marketing tool as patients are becoming more interested in technology and digitally equipped dental offices and mention that to their circle of communication [22]. Intraoral scanning leads to digital models which can be saved as an STL file, the clinical and logistic merits of digital models include easy data archival, smart and effective storage, durability with maintaining model integrity and diagnostic versatility [23].

4. Applications of IOS in the craniofacial field

Orofacial cleft is considered as one of the most common congenital disorders. Cleft lip and/or cleft palate (CL/P) is the most common craniofacial condition. Orofacial clefts have a significant influence on the development and quality of life not only on of the affected patients but on their families as well. A systematic review and meta-analysis conducted by Kadir et al. reported that 1 child in every 730 births will be born with CL/P (whether associated with syndrome/condition or not) [24].

4.1 Preoperative evaluation and treatment planning in patients with orofacial clefts

Palatoplasty for patients with cleft palate is delayed till approximately from 9 to 10 months to avoid any maxillary growth limitation [25, 26]. At this age, the preoperative evaluation of the palate is very challenging because of its small size, not to mention that even in adults it is a very difficult structure to record [27]. Different attempts were conducted for the preoperative evaluation of the anatomy of the palate, yet it was very difficult because of limited accessibility and dynamic movements. Some surgeons depended on clinical examination by eyeballing (looking directly into patients' mouth while open) [27]. This method of assessment is very subjective and provide insufficient diagnostic information. That's why, alternative methods as diagnostic plaster models, CBCT scanning of the patient to provide a 3-dimensional anatomy of the palate, and Magnetic resonance scanning have been used to overcome the limitations of the physical examination method [28–30].

Plaster models have been considered as the gold standard in recording the dental arches [31]. Although plaster casts may record accurately the anatomy of the hard palate, yet it fails to provide a detailed recording of the soft palate [32]. Despite the presence of alternative radiographic methods as CBCT, high radiation exposure particularly in pediatric patients can be a limitation, in addition to possible images overlap and inaccurate recording of borders of soft tissue structures [33]. Also, studies reported that MRI may provide a gap between the radiographic and clinical case severity, so it cannot be used solely to evaluate patients with cleft palate and should be combined with clinical examination to provide an appropriate treatment plan [34].

The evolution of digital intraoral scanning is considered by most of the orthodontists especially the craniofacial ones as an absolute innovation, literature has reported many studies that validate their use in terms of accuracy in the

orthodontic field [35, 36]. Also, recent studies began to validate the use of IOS in recording the palatal tissue and reported intraoral scanning as a reliable method [37, 38]. Among the reported challenges of using IOS to record the soft palate or the palatal area in general is the accessibility as well as recording the posterior part of the soft palate as a smooth surface without any corrugations [32]. There are now intraoral scanners with smaller and thinner scanning tips - thanks to the developing scanning technologies - which significantly improved the accessibility and reduced any discomfort particularly in infant and neonate patients.

Three-dimensional analysis of the records captured by IOS (**Figure 1**) can offer a diagnostic opportunity that allows for accurate measurements between marked points on the palate. This facilitates the treatment planning part for the care providers where they can accurately record the various occlusal indices required to evaluate the inter-arch relationships [39].

4.2 Presurgical nasopalveolar molding (NAM)

Presurgical infant orthopedics, known as (PSIO) started its popularity in the 1950s and was validated later by Matuso in 1988 who noticed that the newborn's cartilage is soft and non-elastic thus, can be molded [40]. The PSIO is advisable to start as early as from birth up to 4 months due to the high estrogen and hyaluronic acid levels which inhibit the crosslinking of the cartilage matrix and allow for proper cartilage molding [40, 41]. In 1950, Grayson initiated the technique that is widely used till now and named it "presurgical naso-alveolar molding (NAM), this technique allows passive molding that aims mainly for repositioning the deformed alveolar process, nasal cartilage and lengthening of the columella. The Grayson technique itself then went through further modifications aiming for preferable outcomes and more comfort to the patients and their caregivers [42–44].

The concept of clear orthodontic appliances was first introduced in 1946 by Kesling to align the teeth in better positions [45]. Later after that, the clear aligner treatment (CAT) was introduced by Align Technology (Santa Clara, California). CAT was very acceptable for adult patients [46]. However, it was not that popular for pediatric patients in craniofacial orthopedics and orthodontics, this was related to the possible discomfort, allergy, and respiratory obstruction from impression material in newborns with cleft palate [47]. The introduction of a digital workflow that includes IOS instead of conventional impression techniques then designing and 3D printing of clear aligner for nasopalveolar molding has paved the way to a more friendly yet accurate method of reducing the cleft defect before surgery [48].

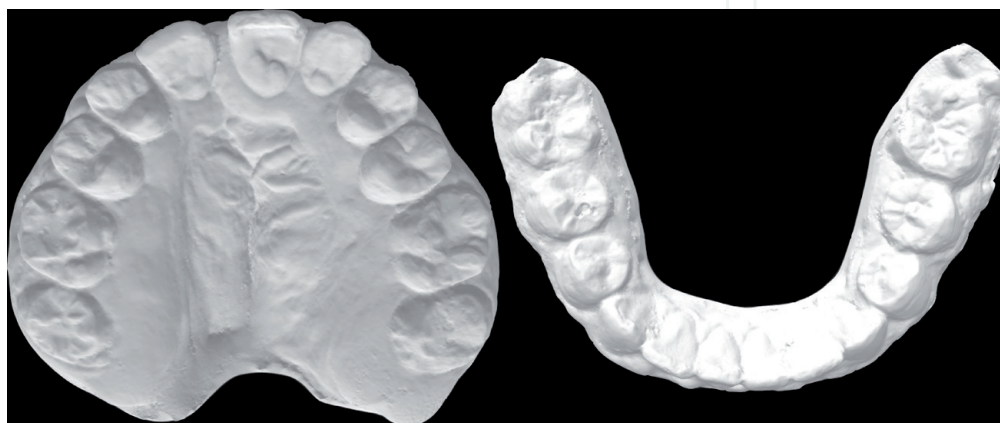


Figure 1. *Digital models of a patient with unilateral cleft lip and palate on the right side, which can be used for detailed diagnosis and tailored treatment planning.*

The scanning process is usually done using a small-sized scanning tip, the newborn/infant's head is advised to be stabilized gently with the parent's hand while keeping the infant seated in the parent's lap. The overall intraoral scanning process should take less than 3 minutes, an exact reported average of 1 minute 30 seconds up to 2 minutes has been reported in literature [48].

It is worth mentioning that the IOS software is accustomed to record continuous dental arches and interpret any discontinuous surface as a redundant or spurious surface that should be removed [47]. Hence, the most challenging part to be scanned was the cleft gap. However, the orthodontists' experience in the scanning process plays a significant role (**Figure 2**). On another hand, the scanning speed is recommended to support up to 3000 images per second with the rationale of reducing any errors that may result from any movement between the scanning tip and the surrounding oral structures [47].

4.3 IOS and 3D printing

Fully digital workflow can be implemented to successfully design and manufacture palatal plates for patients with cleft palate or any functional disorder. Applying this workflow in orthodontics requires the synchronization between different technologies to be able to finally create appliances, it is now possible to create palatal plates based on digital intraoral scanning [49].

Xepapadeas AB et al. [50], reported a detailed technique for scanning the patients with Trisomy 21 syndrome for the aim of manufacturing palatal plates. They advised that the orthodontist should make sure to record all the intraoral structures that can crucially affect the fit of the plate as the maxillary tuberosity, labial frenulum, and vestibule. Also, another important tip is to always define a reference point to mark the start of the scan - usually it is the incisive papilla - so that if the scanning position is lost, the papilla or the last scanned area can be taken as a starting point. The scanned data represents the digital working model. At first, adjusting the scan orientation is done then defining the outer borders of the scan to determine the final dimensions of the orthodontic model. The final step includes removing any undercuts or irregularities resulting from registration errors, this is usually done using the free form tool. In patients with cleft palate, it is advised to virtually block the cleft to ensure that all the anatomic structures are recorded rather than being removed and considered as redundant images. Thereby, the digital model is ready to be exported as Standard Tessellation Language (STL) file for the design of the palatal plate.

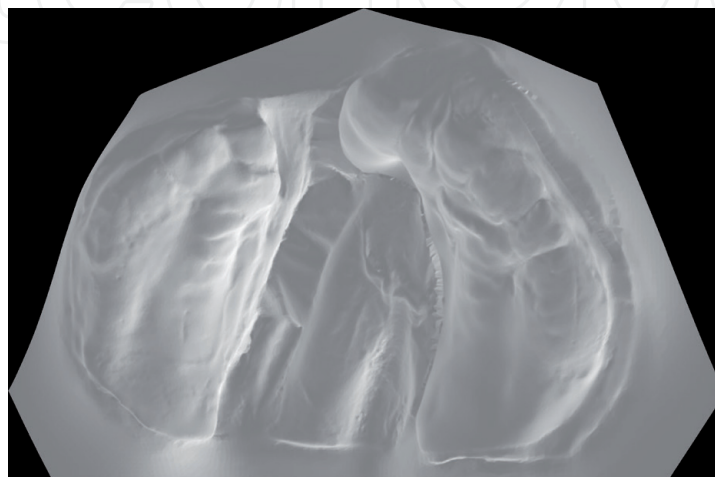


Figure 2. *Intraoral scan of an infant with unilateral cleft lip and palate. The digital impression can be used to assess the maxillary arch/segment dimensions and to fabricate a nasoalveolar molding (NAM) aligners.*

In the craniofacial field, accurate diagnostic information, precise understanding of the anatomy, and practice are the key for any successful surgery. Palatoplasty simulation on a 3D printed cleft palate model based on data from intraoral scanner is now a growing viable option. This simulation offers a training opportunity to the medical students and residents to increase their expertise [27].

4.4 IOS and 3D surgery

The 3D field is rapidly and favorably developing. This includes 3D imaging, scanning and printing. Following the promising development of the 3D field, it was about time for software creators to incorporate three-dimensional surgical modules into various software programs. Utilizing different 3D technologies together paved the road for virtual surgical planning (VSP) to accessible and widely spread.

Two fundamental elements are needed for VSP; 3D radiographic imaging (CT or CBCT) and intraoral digital impression. The intraoral scan of a patient's mouth is done in order to obtain a STL file, that will be accurately placed overlaying the dentition on the patient's CT or CBCT volume. This merging will provide an accurate representation of the patient's skeleton, dentition and facial soft tissues; i.e. creating a "virtual patient" [51]. Utilizing specific software programs, VSP can be performed with a step-by-step guidance. First, the boundaries of the maxilla, mandible and

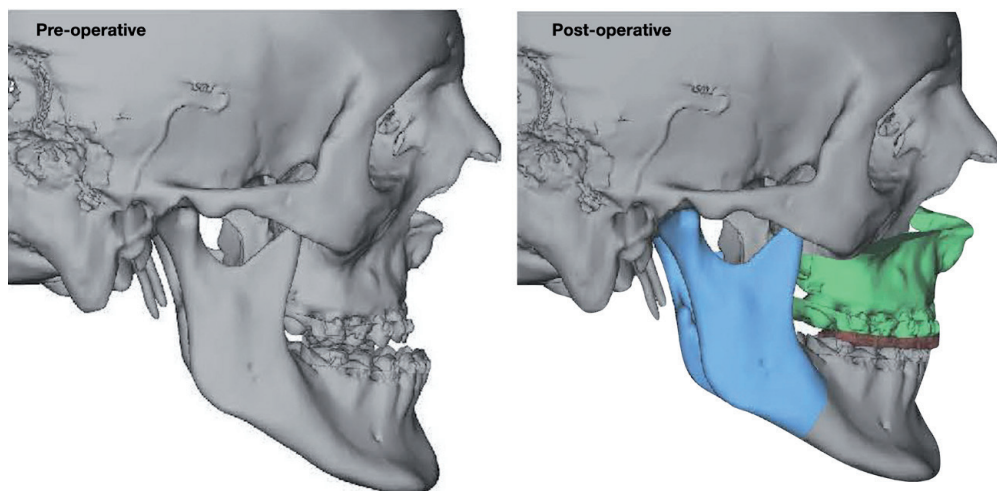


Figure 3. Virtual surgical planning (VSP) showing double-jaw surgery with final splint is in place.

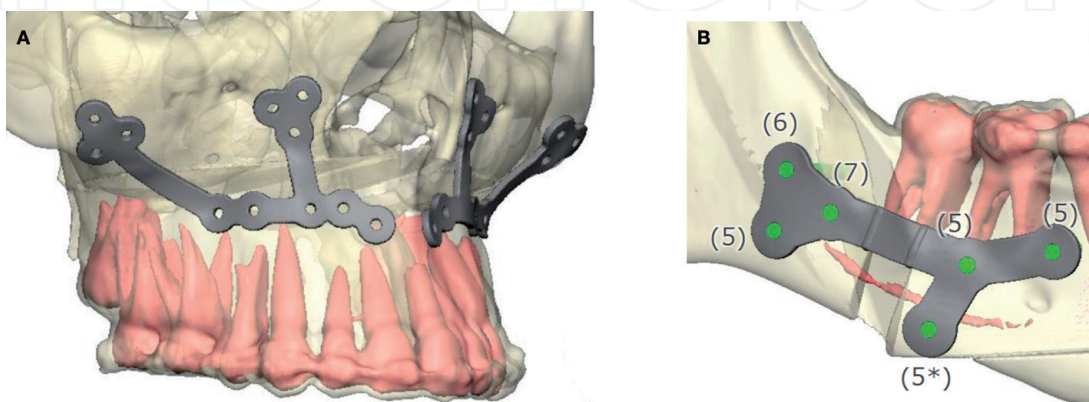


Figure 4. The surgical guides are virtually designed. Screw holes are accurately distributed to avoid any injury to the adjacent structures (such as teeth and nerves). Note that in figure (B), numbers represent the predetermined length of the screws, while screw (*) indicates the need to used angular screw.




Figure 5.
The surgical guides for the maxilla and mandible are virtually designed then 3D printed. A, right side of the maxilla; B, left side of the maxilla; C, right side of the mandible; D, left side of the mandible.

dentition are identified through landmark identification. Then, the surgical movements of one jaw or both are decided in all dimensions (anteroposterior, lateral, vertical, yaw, pitch and roll) depending on the surgical plan (**Figure 3**). 3D surgical guide(s) and Inter-mediate or/and final splint(s) can be created virtually and then 3D printed (**Figures 4 and 5**).

The VSP allows for accurate osteotomy cuts, better predictability of the outcomes and significant reduction in the amount of time spent in the operating room [52–54]. With the current and upcoming advanced in the 3D filed, it is only logical to consider VSP not only as a viable option, but as an upgraded alternative to traditional surgeries.

5. Conclusions

Digital intraoral scanners can be considered as an accurate novel diagnostic tool in the craniofacial field as well as a safe alternative to the traditional impression techniques especially for infants with craniofacial conditions. They allow for 3D evaluation of the scanned data; this can be very beneficial for infants/newborns with cleft palate by facilitating the treatment plan formulation based on accurate 3D measurements and analysis. Furthermore, IOS can enable the manufacture of craniofacial appliances when combined with a proper digital workflow. Finally, the with the marriage of IOS and 3D printing technology, surgical models can be easily fabricated for surgical training purposes.

Conflict of interest

The authors declared that there is no conflict of interest.

IntechOpen

Author details

Rahma ElNaghy^{1,2*}, Sara Amin³ and Majd Hasanin¹

1 Department of Graduate Orthodontics, School of Dentistry, University of Detroit Mercy, Detroit, Michigan, USA

2 Faculty of Dentistry, Nahda University in Beni-Suef, Egypt

3 iTX Pros, Delaware, USA

*Address all correspondence to: elnaghra@udmercy.edu

IntechOpen

© 2021 The Author(s). Licensee IntechOpen. This chapter is distributed under the terms of the Creative Commons Attribution License (<http://creativecommons.org/licenses/by/3.0>), which permits unrestricted use, distribution, and reproduction in any medium, provided the original work is properly cited. 

References

- [1] Moörmann WH. The evolution of the CEREC system. *The Journal of the American Dental Association*. 2006 Sep 1;137:7S-13S.
- [2] Kravitz ND, Groth CH, Jones PE, Graham JW, Redmond WR. Intraoral digital scanners. *J Clin Orthod*. 2014 Jun 1;48(6):337-47.
- [3] Logozzo S, Zanetti EM, Franceschini G, Kilpelä A, Mäkynen A. Recent advances in dental optics—Part I: 3D intraoral scanners for restorative dentistry. *Optics and Lasers in Engineering*. 2014 Mar 1;54:203-21.
- [4] Lee KM. Comparison of two intraoral scanners based on three-dimensional surface analysis. *Progress in orthodontics*. 2018 Dec;19(1):1-7.
- [5] Ting-shu S, Jian S. Intraoral digital impression technique: a review. *Journal of Prosthodontics*. 2015 Jun;24(4):313-21.
- [6] Imburgia M, Logozzo S, Hauschild U, Veronesi G, Mangano C, Mangano FG. Accuracy of four intraoral scanners in oral implantology: a comparative in vitro study. *BMC oral health*. 2017 Dec;17(1):1-3.
- [7] Ahlholm P, Sipilä K, Vallittu P, Jakonen M, Kotiranta U. Digital versus conventional impressions in fixed prosthodontics: a review. *Journal of Prosthodontics*. 2018 Jan;27(1):35-41.
- [8] Zimmermann M, Mehl A, Mörmann WH, Reich S. Intraoral scanning systems—a current overview. *International journal of computerized dentistry*. 2015 Jan 1;18(2):101-29.
- [9] Martin CB, Chalmers EV, McIntyre GT, Cochrane H, Mossey PA. Orthodontic scanners: what's available?. *Journal of orthodontics*. 2015 Jun;42(2):136-43.
- [10] Means CR, Flenniken IE. Gagging—a problem in prosthetic dentistry. *The Journal of prosthetic dentistry*. 1970 Jun 1;23(6):614-20.
- [11] Yuzbasioglu E, Kurt H, Turunc R, Bilir H. Comparison of digital and conventional impression techniques: evaluation of patients' perception, treatment comfort, effectiveness and clinical outcomes. *BMC oral health*. 2014 Dec;14(1):1-7.
- [12] Goracci C, Franchi L, Vichi A, Ferrari M. Accuracy, reliability, and efficiency of intraoral scanners for full-arch impressions: a systematic review of the clinical evidence. *European journal of orthodontics*. 2016 Aug 1;38(4):422-8.
- [13] Burhardt L, Livas C, Kerdijk W, van der Meer WJ, Ren Y. Treatment comfort, time perception, and preference for conventional and digital impression techniques: A comparative study in young patients. *American Journal of Orthodontics and Dentofacial Orthopedics*. 2016 Aug 1;150(2):261-7.
- [14] Grünheid T, McCarthy SD, Larson BE. Clinical use of a direct chairside oral scanner: an assessment of accuracy, time, and patient acceptance. *American Journal of Orthodontics and Dentofacial Orthopedics*. 2014 Nov 1;146(5):673-82.
- [15] Lee SJ, Gallucci GO. Digital vs. conventional implant impressions: efficiency outcomes. *Clinical oral implants research*. 2013 Jan;24(1):111-5.
- [16] Kugel G. Impression-taking: conventional methods remain steadfast as digital technology progresses. *Compendium of continuing education in dentistry (Jamesburg, NJ: 1995)*. 2014 Mar 1;35(3):202-3.
- [17] Chochlidakis KM, Papaspyridakos P, Geminiani A, Chen CJ, Feng IJ, Ercoli C.

Digital versus conventional impressions for fixed prosthodontics: A systematic review and meta-analysis. *The Journal of prosthetic dentistry*. 2016 Aug 1;116(2):184-90.

[18] Burzynski JA, Firestone AR, Beck FM, Fields Jr HW, Deguchi T. Comparison of digital intraoral scanners and alginate impressions: Time and patient satisfaction. *American Journal of Orthodontics and Dentofacial Orthopedics*. 2018 Apr 1;153(4):534-41.

[19] Joda T, Brägger U. Time-efficiency analysis comparing digital and conventional workflows for implant crowns: A prospective clinical crossover trial. *International journal of oral & maxillofacial implants*. 2015 Sep 1;30(5).

[20] Joda T, Brägger U. Digital vs. conventional implant prosthetic workflows: a cost/time analysis. *Clinical oral implants research*. 2015 Dec;26(12):1430-5.

[21] Lawson NC, Burgess JO. Clinicians reaping benefits of new concepts in impressioning. *Compendium of continuing education in dentistry (Jamesburg, NJ: 1995)*. 2015 Feb 1;36(2):152-3.

[22] Mangano F, Gandolfi A, Luongo G, Logozzo S. Intraoral scanners in dentistry: a review of the current literature. *BMC oral health*. 2017 Dec;17(1):1-1.

[23] Horton HM, Miller JR, Gaillard PR, Larson BE. Technique comparison for efficient orthodontic tooth measurements using digital models. *The Angle Orthodontist*. 2010 Mar;80(2):254-61.

[24] Kadir A, Mossey PA, Blencowe H, Moorthie S, Lawn JE, Mastroiacovo P, Modell B. Systematic Review and Meta-Analysis of the Birth Prevalence of Orofacial Clefts in Low- and

Middle-Income Countries. *Cleft Palate Craniofac J*. 2017 Sep;54(5):571-581. doi: 10.1597/15-221. Epub 2016 Jul 19. PMID: 27440051.

[25] Evans D, Renfrew C. The timing of primary cleft palate repair. *Scandinavian journal of Plastic and Reconstructive Surgery*. 1974 Jan 1;8(1-2): 153-5.

[26] Kaplan EN. Cleft palate repair at three months? *Annals of plastic surgery*. 1981 Sep 1;7(3):179-90.

[27] Choi YS, Shin HS. Preoperative planning and simulation in patients with cleft palate using intraoral three-dimensional scanning and printing. *Journal of Craniofacial Surgery*. 2019 Oct 1;30(7):2245-8.

[28] Lee D, Atti E, Blackburn J, et al. Volumetric assessment of cleft lip and palate defects using cone beam computed tomography. *Journal of the California Dental Association*. 2013 Nov;41(11):813-817.

[29] Scott AD, Boubertakh R, Birch MJ, Miquel ME. Adaptive averaging applied to dynamic imaging of the soft palate. *Magnetic resonance in medicine*. 2013 Sep;70(3):865-74.

[30] Wortche R, Hassfeld S, Lux CJ, Mussig E, Hensley FW, Krempien R, Hofele C. Clinical application of cone beam digital volume tomography in children with cleft lip and palate. *Dentomaxillofacial Radiology*. 2006 Mar;35(2):88-94.

[31] Kumar AA, Phillip A, Kumar S, Rawat A, Priya S, Kumaran V. Digital model as an alternative to plaster model in assessment of space analysis. *Journal of pharmacy & bioallied sciences*. 2015 Aug;7(Suppl 2):S465.

[32] Chaturvedi S, Khaled Addas M, Al Humaidi AS, Al Qahtani AM, Al Qahtani MD. A novel approach to determine the prevalence of type of soft

palate using digital intraoral impression. *International journal of dentistry*. 2017 Aug 29;2017.

[33] Chaturvedi S, Khaled Addas M, Al Humaidi AS, Al Qahtani AM, Al Qahtani MD. A novel approach to determine the prevalence of type of soft palate using digital intraoral impression. *International journal of dentistry*. 2017 Aug 29;2017.

[34] Argenta A, Petropoulou K, Cray J, Ford M, Jiang S, Losee J, Grunwaldt L. Magnetic resonance imaging as a predictor of submucous cleft palate severity and guide for surgical intervention. *Journal of Craniofacial Surgery*. 2013 May 1;24(3):964-9.

[35] Fleming PS, Marinho V, Johal A. Orthodontic measurements on digital study models compared with plaster models: a systematic review. *Orthodontics & craniofacial research*. 2011 Feb;14(1):1-6.

[36] Santoro M, Galkin S, Teredesai M, Nicolay OF, Cangialosi TJ. Comparison of measurements made on digital and plaster models. *American journal of orthodontics and dentofacial orthopedics*. 2003 Jul 1;124(1):101-5.

[37] Atia MA, El-Gheriani AA, Ferguson DJ. Validity of 3 shape scanner techniques: a comparison with the actual plaster study casts. *Biom Biostat Int J*. 2015;2(2):00026.

[38] Deferm JT, Schreurs R, Baan F, Bruggink R, Merckx MA, Xi T, Bergé SJ, Maal TJ. Validation of 3D documentation of palatal soft tissue shape, color, and irregularity with intraoral scanning. *Clinical oral investigations*. 2018 Apr;22(3):1303-9.

[39] Chalmers EV, McIntyre GT, Wang W, Gillgrass T, Martin CB, Mossey PA. Intraoral 3D scanning or dental impressions for the assessment of dental arch relationships in cleft care:

which is superior?. *The Cleft Palate-Craniofacial Journal*. 2016 Sep;53(5):568-77.

[40] Matsuo K, Hirose T, Otagiri T, Norose N. Repair of cleft lip with nonsurgical correction of nasal deformity in the early neonatal period. *Plastic and reconstructive surgery*. 1989 Jan 1;83(1):25-31.

[41] Matsuo K, Hirose T. Preoperative non-surgical over-correction of cleft lip nasal deformity. *British journal of plastic surgery*. 1991 Jan 1;44(1):5-11.

[42] Figueroa AA, Reisberg DJ, Polley JW, Cohen M. Intraoral-appliance modification to retract the premaxilla in patients with bilateral cleft lip. *The Cleft palate-craniofacial journal*. 1996 Nov;33(6):497-500.

[43] Monasterio L, Ford A, Gutiérrez C, Tastets ME, García J. Comparative study of nasoalveolar molding methods: nasal elevator plus DynaCleft® versus NAM-Grayson in patients with complete unilateral cleft lip and palate. *The Cleft Palate-Craniofacial Journal*. 2013 Sep;50(5):548-54.

[44] Vinson L. The effect of DynaCleft® on cleft width in unilateral cleft lip and palate patients. *Journal of Clinical Pediatric Dentistry*. 2017;41(6):442-5.

[45] Kesling HD. Coordinating the predetermined pattern and tooth positioner with conventional treatment. *American journal of orthodontics and oral surgery*. 1946 May 1;32(5):285-93.

[46] Krieger E, Seiferth J, Marinello I, Jung BA, Wriedt S, Jacobs C, Wehrbein H. Invisalign® treatment in the anterior region. *Journal of Orofacial Orthopedics/Fortschritte der Kieferorthopädie*. 2012 Sep 1;73(5):365-76.

[47] Patel J, Winters J, Walters M. Intraoral digital impression technique

for a neonate with bilateral cleft lip and palate. *The Cleft Palate-Craniofacial Journal*. 2019 Sep;56(8):1120-3.

[48] Batra P, Gribel BF, Abhinav BA, Arora A, Raghavan S. OrthoAligner “NAM”: a case series of Presurgical Infant Orthopedics (PSIO) using clear aligners. *The Cleft Palate-Craniofacial Journal*. 2020 May;57(5):646-55.

[49] Pillai S, Upadhyay A, Khayambashi P, Farooq I, Sabri H, Tarar M, Lee KT, Harb I, Zhou S, Wang Y, Tran SD. Dental 3D-Printing: Transferring Art from the Laboratories to the Clinics. *Polymers*. 2021 Jan;13(1):157.

[50] Xepapadeas AB, Weise C, Frank K, Spintzyk S, Poets CF, Wiechers C, Arand J, Koos B. Technical note on introducing a digital workflow for newborns with craniofacial anomalies based on intraoral scans-part I: 3D printed and milled palatal stimulation plate for trisomy 21. *BMC oral health*. 2020 Dec;20(1):1-8.

[51] Plooiij JM, Maal TJ, Haers P, Borstlap WA, Kuijpers-Jagtman AM, Berge SJ. Digital three-dimensional image fusion processes for planning and evaluating orthodontics and orthognathic surgery. A systematic review. *Int J Oral Maxillofac Surg*. 2011;40:341-52.

[52] Bengtsson M, Wall G, Miranda-Burgos P, Rasmusson L. Treatment outcome in orthognathic surgery – a prospective comparison of accuracy in computer assisted two and three-dimensional prediction techniques. *J Craniomaxillofac Surg*. 2017.

[53] Gelesko S, Markiewicz MR, Weimer K, Bell RB. Computer-aided orthognathic surgery. *Atlas Oral Maxillofac Surg Clin North Am*. 2012;20(1):107-18

[54] Yuan P, Mai H, Li J, et al. Design, development and clinical validation of computer-aided surgical simulation system for streamlined orthognathic surgical planning. *Int J Comput Assist Radiol Surg*. 2017