

# We are IntechOpen, the world's leading publisher of Open Access books Built by scientists, for scientists

5,500

Open access books available

136,000

International authors and editors

170M

Downloads

Our authors are among the

154

Countries delivered to

TOP 1%

most cited scientists

12.2%

Contributors from top 500 universities



WEB OF SCIENCE™

Selection of our books indexed in the Book Citation Index  
in Web of Science™ Core Collection (BKCI)

Interested in publishing with us?  
Contact [book.department@intechopen.com](mailto:book.department@intechopen.com)

Numbers displayed above are based on latest data collected.  
For more information visit [www.intechopen.com](http://www.intechopen.com)



# Seizures in Adult with Neurofibromatosis Type 1

*Demet İlhan Algin and Oğuz Osman Erdiñç*

## Abstract

Neurofibromatosis type 1 (NF1) is an autosomal dominantly inherited disorder, with an estimated prevalence of 1 in 3000–4000 people. Seizures occur 4–7% of individuals with NF1, mostly due to associated brain tumors or cortical malformations. Seizures in NF1 are often relatively easy to control with one or more conventional antiseizure drugs; surgical resection of offending lesions is sometimes pursued. Surgery has been most successful for temporal lobe gliomas. However, if you faced the drug-resistant epilepsy you may consider the cortical malformations, tumors and hippocampal sclerosis. In this chapter, it is aimed to explain the types of seizures, EEG features and the properties of drug therapy in NF1.

**Keywords:** NF1, epilepsy, electroencephalogram (EEG)

## 1. Introduction

Neurofibromatosis (NF-1) type 1, which is the most common neurocutaneous disease, is autosomal dominant inherited, and its incidence has been reported as 1/3000 [1].

The NF-1 gene is located in the 17q11.2 region of chromosome 17, and this gene encodes a tumor suppressor protein called Neurofibromin. Neurofibromas are the most common tumors in NF1, often seen in adolescence and increasing in number and size with age. Most of them are benign and rarely undergo malignant transformation [2].

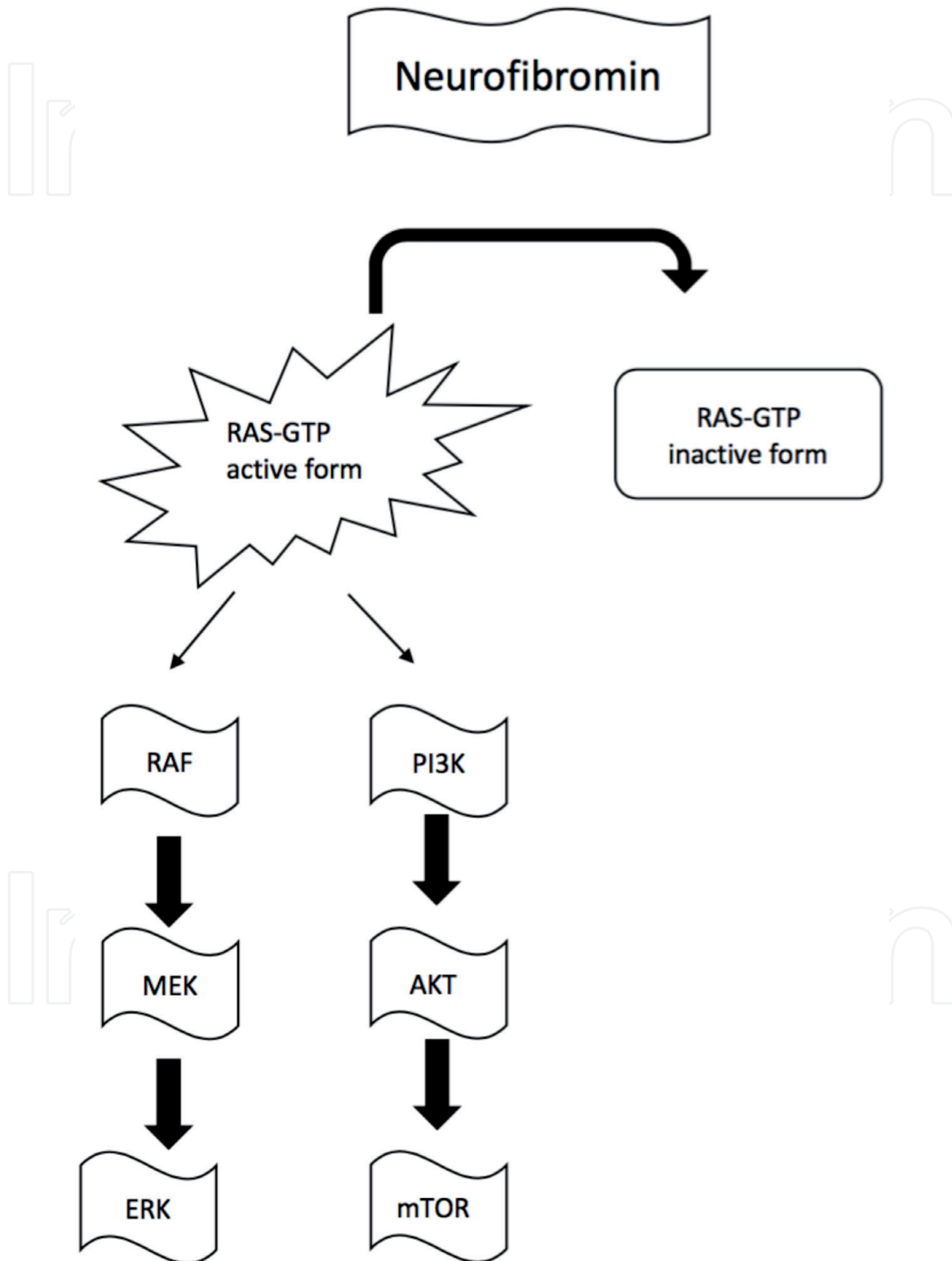
Diagnostic criteria for NF1 include cutaneous/subcutaneous or plexiform neurofibromas, “cafe au lait” spots, axillary or inguinal freckles, Lisch nodules, optic glioma, and skeletal dysplasia. Cranial magnetic resonance imaging (MRI) can show focus areas of high T2-weighted signals known as neurofibromatosis bright objects (NBOs).

Other findings that may accompany NF1 include vasculopathy, short stature, malignancy tendency, macrocephaly, learning disability, and epilepsy. Other symptoms include cognitive dysfunction, pain in specific nerve distribution (usually due to the presence of neurofibroma), seizures, visual changes that may be associated with optic gliomas, stenosis of the major intracranial arteries leading to the Moyamoya phenomenon, headaches. The prevalence of epilepsy in NF1 is 4–5 times the prevalence defined in the general population and is reported to be 4–7% [3, 4].

## 2. Epilepsy mechanism at NF1

The exact mechanism of epilepsy in NF1 is not clear. Identifying the features associated with epilepsy can provide clues about its pathogenesis [5].

Neurofibromin plays important roles in many aspects of cortical development, including synaptic plasticity, learning and memory, neurotransmitter phenotype, and synapse formation [6]. However, it is not clear why the brains of individuals with NF1 can be overstimulated and prone to seizures, and this issue is rarely discussed in the literature [7].



**Figure 1.** Potential mechanisms of increased epileptogenesis in NF1 [17]. Potential mechanisms of increased epileptogenesis in neurofibromatosis type 1. Protein neurofibromin is the NF1 gene product and functions as a negative regulator of Ras activity. In neurofibromatosis type 1, decreased neurofibromin levels lead to increased Ras activation and higher RAF/MEK/ERK and PI3K/AKT/mTOR signaling levels. Although the mechanism of increased seizures and epilepsy in patients with neurofibromatosis is unknown, changes in these signaling pathways may increase epileptogenesis, possibly through changes in GABAergic signaling, changes in ion channels, or altered synaptic plasticity.

The possibilities are undoubtedly speculative and include the pathophysiological spectrum that disrupts the excitation and inhibition balance [8]. Possibly related to seizure mechanisms, GABA release and levels were found to increase in NF1 +/- mice, resulting in unlimited Extracellular Signal Regulated Kinase (ERK) signal and increased synaptic GABA release as a result of neurofibromin loss [9]. This finding explains the impaired cognition, learning, and Long-term potentiation (LTP) of NF1 +/- mice. However, decreasing rather than increasing GABA levels will be more consistent with susceptibility to epilepsy. However, the increased GABA release strategically limited to local inhibitory circuits could theoretically increase excitability [10].

In NF1 +/- mice, calcium channel opening increases in hippocampal neurons and calcium currents increase, which increases excitability and neurotransmitter release [11]. Dysfunction of various ion channels (e.g. sodium, potassium, cyclic nucleotide-gated, activated by hyperpolarization) has been reported in different brain regions and NF models, but no consistent model emerged to suggest a unified hypothesis about cortical hyper-excitability or seizures. Several sodium channel isoforms (NaV1.1, NaV1.7, NaV1.8) have increased expression and activity in NF1 +/- mice, leading to hyper-excitability [12, 13].

These findings may be related to central neurons and circuits, a subject that needs to be investigated in terms of epilepsy mechanisms in NF. There is no published information on whether NF1 +/- mice alter the sensitivity to seizures induced by standard experimental methods (eg bicuculline, kindling) [14].

Stafstrom et al. stated that impaired excitation/inhibition balance and dysfunction of ion channels may be possible mechanisms of epilepsy in NF1 [15].

Neurofibromin deficiency leads to increased Ras activity, which is the mechanical target of rapamycin activation, and GABAergic signaling in the inhibitory circuit, which may contribute to neuronal hyperpolarization. Neurofibromin also plays a role in cortical development including synaptogenesis and synaptic plasticity; therefore, its deficiency may be associated with abnormal cortical development and seizure development (**Figure 1**) [15–17].

The high rate of learning disability in the epileptic group (without epilepsy; 8,2 with epilepsy; 64%) without any negative factors such as resistant epilepsy, multiple drugs or epileptic encephalopathy suggests that it is probably not caused by learning disability, but due to a GABA-mediated pathogenesis [17].

The mutation site in the NF1 locus may also be associated with epilepsy: replication of the NF1 locus has been shown to cause mental disability and epilepsy without any physical imprint of NF1. The duplication site also contains many genes that can cause epilepsy when the microdeletion site is deleted or mutated in some cases of NF1, explaining why only a small percentage of patients with NF1 experience seizures. Comparison of genotypes between NF1 patients with and without epilepsy may clarify this possibility [18].

### 3. Seizures in NF1

Neoplastic or non-neoplastic central nervous system symptoms occur in 15–20% of patients with NF-1. Brain lesions in NF1 have been reported as neoplastic, non-neoplastic structural changes, vasculopathy, cerebral and cerebellar cortical malformations [19].

Neoplastic lesions are classified as optic gliomas, brainstem gliomas, and other brain gliomas. Non-neoplastic structural lesions are NBOs, macrocephaly, corpus callosum pathologies, dural ectasia and encephalocele. In NF1, cortical malformations have been reported as transmantled cortical dysplasia, periventricular band

consisting of heterotopic gray matter with cerebral cortex pachygyria, and perisylvian polymicrogyria [20, 21].

Describing five adult patients with epilepsy associated with aqueductal stenosis, subdural hematoma, cerebral hamartoma, and meningioma, Hsieh HY. et al. reported several NF1 patients with seizures caused by various tumor types. Most of these patients continued their follow-up without seizures after lesionectomy [22, 23].

It has been reported that the seizures of patients with hemimegalencephaly and NF1 are well controlled [24]. MRI lesions of other cortical developmental malformations such as focal cortical dysplasia and polymicrogyria are often accompanied by drug-resistant epilepsy [22, 25].

However, about half of NF1 patients with epilepsy do not have a structural abnormality on MRI [4] and it has been reported that MRI lesions in NF1 are not always localized with epileptiform discharges on EEG [16]. In this case, they raised the question of whether the genetic condition itself contributes to overstimulation of the brain, susceptibility to seizures, and other chronic changes that lead to epilepsy. Seizures in NF1 are usually secondary to brain lesions such as tumors or cortical dysplasia [4, 26], but neurofibromatosis, a typical MRI lesion, has not been associated with bright nodes (NBOs) [4, 26].

NBOs (neurofibromatosis bright objects) were detected in 16 (69.6%) epilepsy patients and 108 (72.5%) patients without epilepsy in a study in which the MRI of 172 (23 with and 149 without epilepsy) NF1 patients were examined. The location or number of these intracranial lesions do not correlate significantly with the occurrence of epilepsy in our cohort. Among the 11 NF1 patients with intracranial tumors, 4 patients (36.36%) had seizures, whereas 19 (11.80%) of 161 NF1 patients without tumor were found to have seizures. In conclusion, in this article, epileptic seizure formation in NF1 patients was interpreted as associated with intracranial tumors, but not with NBOs [23].

Different seizure types and syndromes have been described in NF1. Most seizures in NF1 tend to be focal-onset seizures and are generally secondary generalized [22, 27, 28]. The seizures in NF1 are thought to be caused by numerous focal lesions that make up the disorder, namely, tumors and malformations of cortical development. The prevalence of West syndrome (infantile spasms) and febrile seizures is higher in NF1 patients compared to the general population.

EEGs are abnormal in about 25% of patients with NF1. EEG findings may include normal to focal or multifocal spike waves, spike and slow spike wave complexes at 2 Hz compatible with Lennox–Gastaut syndrome. The most common abnormality in EEG is focal disorders [27].

Therefore, seizure formation requires neuroimaging even if previous neuroimaging was normal. The relationship of NBOs to seizures is controversial, but most studies have concluded that NBOs are not associated with seizures [22, 28]. Seizures in NF1 are generally relatively easy to control with one or more conventional anti-epileptic drugs (AED); Sometimes, those ending lesions are surgically resected. Surgery is the most successful for temporal lobe gliomas [3].

#### **4. Epilepsy surgery in NF1**

In the review of 43 studies, structural causes were found in half of the patients with NF1. Low-grade gliomas were the most common, followed by mesial temporal sclerosis, cortical growth malformation, dysembryoplastic neuroepithelial tumor, and cerebrovascular lesions. Surgical method was the best approach for the treatment of epilepsy in patients with NF1 with structural lesions [29].

Eighteen patients with mesial temporal sclerosis (MTS) who were followed up with a diagnosis of NF1 and epilepsy have been reported in the literature. Ten of the 18 patients were women and 8 were men, 10 patients had right MTS, 6 patients had left MTS and 1 patient had bilateral MTS [30].

Vivarelli et al. [22] described 9 patients with NF1 and brain lesions. 5 patients had cerebral tumor, 3 patients had cortical malformation and 1 patient had MTS. Responded to medication in 1 case with MTS [16].

Carmen Barba et al. [31] reported 12 resistant epilepsy patients with cortical development or malformations of glioneuronal tumors on NF1 and MRI. Four of 12 patients had MTS. Four patients with MTS were women, and 3 had left MTS and 1 had right MTS. Three of the 4 patients were seizure-free after temporal lobectomy.

In the study by Ostendorf AP. et al. [3] 9.5% of individuals with NF1 had a history of at least one unprovoked seizure and 6.5% were diagnosed with epilepsy. Individuals who had seizures were more likely to have inherited NF1 from their mothers. Focal seizures were the most common seizure type occurring in 57% of individuals [21]. It has been reported in the literature that 60% of individuals with NF1 have good seizure control with only one AED or without AED treatment [5, 16]. Epilepsy in NF1 can be associated with more than one type of epilepsy and syndromes, and when relevant to localization, it is often drug resistant [31, 32].

## 5. Conclusion

As a result, epilepsy is more common in NF1 patients than in the general population. Although the clinical features of epilepsy in NF1 are heterogeneous, most patients have focal seizures and have a good response to treatment. In at least half of cases, epilepsy is mainly caused by central nervous system structural lesions represented by brain tumors. However, other brain changes such as MTS, DNETs, cortical abnormalities, cerebrovascular disease, and other complications cannot be ruled out. In addition, epilepsy in NF1 is associated with a history of epilepsy and learning disabilities in a family that contributes to a genetic mechanism that may be associated with cellular or synaptic changes in the brain and epileptogenesis in the NF1 pan.


Given the heterogeneity of structural causes in NF1-, correlation of relevant epilepsy, clinical-video EEG and neuroimaging should always be performed, especially before surgery.

### Author details

Demet İlhan Algin\* and Oğuz Osman Erdiñç  
Faculty of Medicine, Department of Neurology, Eskişehir Osmangazi University,  
Eskişehir, Turkey

\*Address all correspondence to: [ilhandemet@gmail.com](mailto:ilhandemet@gmail.com)

### IntechOpen

© 2021 The Author(s). Licensee IntechOpen. This chapter is distributed under the terms of the Creative Commons Attribution License (<http://creativecommons.org/licenses/by/3.0>), which permits unrestricted use, distribution, and reproduction in any medium, provided the original work is properly cited. 

## References

- [1] Kresak JL, Walsh M. Neurofibromatosis: A Review of NF1, NF2, and Schwannomatosis. *J Pediatr Genet* 2016;5:98-104.
- [2] Abramowicz A, Gos M. Neurofibromin in neurofibromatosis type 1 - mutations in NF1 gene as a cause of disease. *Dev Period Med* 2014;18:297-306.
- [3] Ostendorf AP, Gutmann DH, Weisenberg JL. Epilepsy in individuals with neurofibromatosis type 1. *Epilepsia* 2013;54:1810-4.
- [4] Santoro C, Bernardo P, Coppola A, Pugliese U, Cirillo M, Giugliano T, et al. Seizures in children with neurofibromatosis type 1: is neurofibromatosis type 1 enough? *Ital J Pediatr* 2018;44(41)
- [5] Nix JS, Blakeley J, Rodriguez FJ. An update on the central nervous system manifestations of neurofibromatosis type 1. *Acta Neuropathol* 2020;139:625-641.
- [6] Galanopoulou AS, Gorter JA, Cepeda C. Finding a better drug for epilepsy: the mTOR pathway as an antiepileptogenic target. *Epilepsia* 2012;53:1119-30.
- [7] Gutmann DH, Parada LF, Silva AJ, Ratner N. Neurofibromatosis type 1: modeling CNS dysfunction. *J Neurosci* 2012;32:14087-93.
- [8] Diggs-Andrews KA, Gutmann DH. Modeling cognitive dysfunction in neurofibromatosis-1. *Trends Neurosci* 2013;36:237-47.
- [9] Cui Y, Costa RM, Murphy GG, Elgersma Y, Zhu Y, Gutmann DH, et al. Neurofibromin regulation of ERK signaling modulates GABA release and learning. *Cell* 2008;135:549-60.
- [10] Moutal A, Dustrude ET, Khanna R. Sensitization of ion channels contributes to central and peripheral dysfunction in neurofibromatosis type 1. *Mol Neurobiol* 2016;54:3342-3349.
- [11] Wang Y, Brittain JM, Wilson SM, Hingtgen CM, Khanna R. Altered calcium currents and axonal growth in Nf1 haploinsufficient mice. *Transl Neurosci* 2010;1:106-14.
- [12] Omrani A, van der Vaart T, Mientjes E, van Woerden GM, Hojjati MR, Li KW, et al. HCN channels are a novel therapeutic target for cognitive dysfunction in neurofibromatosis type 1. *Mol Psychiatry* 2015;20:1311-21.
- [13] Gutmann DH, Ferner RE, Listernick RH, et al. Neurofibromatosis type 1. *Nat Rev Dis Primers* 2017;23:17004
- [14] Wang Y, Duan JH, Hingtgen CM, Nicol GD. Augmented sodium currents contribute to the enhanced excitability of small diameter capsaicin-sensitive sensory neurons isolated from Nf1<sup>+/-</sup> mice. *J Neurophysiol* 2010;2085-94.
- [15] Stafstrom CE, Staedtke V, Comi AM. Epilepsy mechanisms in neurocutaneous disorders: tuberous sclerosis complex, neurofibromatosis type 1, and Sturge-Weber syndrome. *Front Neurol* 2017;8:87.
- [16] Serdaroglu E, Konuskan B, Karli Oguz K, Gurler G, Yalnizoglu D, Anlar B. Epilepsy in neurofibromatosis type 1: Diffuse cerebral dysfunction?. *Epilepsy Behav* 2019;98:6-9.
- [17] Sabetghadam A, Wu C, Liu J, Zhang L, Reid AY. Increased epileptogenicity in a Mouse model of neurofibromatosis type 1. *Exp Neurol* 2020;331:113373.

- [18] Moles KJ, Gowans GC, Gedela S, Beversdorf D, Yu A, Seaver LH, et al. NF1 microduplications: identification of seven nonrelated individuals provides further characterization of the phenotype. *Genet Med* 2012;14:508-14.
- [19] Abdel A, Razek KA. MR imaging of neoplastic and non-neoplastic lesions of the brain and spine in neurofibromatosis type I. *Neurol Sci* 2018;39:821-8.
- [20] Abdel Razek AA, Kandell AY, Elsorogy LG, Elmongy A, Basett AA. Disorders of cortical formation: MR imaging features. *AJNR Am J Neuroradiol* 2009;30:4-11
- [21] Balestri P, Vivarelli R, Grosso S, Santori L, Farnetani MA, Galluzzi P, Vatti GP, Calabrese F, Morgese G. Malformations of cortical development in neurofibromatosis type 1. *Neurology* 2003; 61: 1799-1801
- [22] Vivarelli R, Grosso S, Calabrese F, Farnetani M, Di Bartolo R, Morgese G, et al. Epilepsy in neurofibromatosis 1. *J Child Neurol* 2003;18:338-42.
- [23] Hsieh HY, Fung HC, Wang CJ, Chin SC, Wu T. Epileptic seizures in neurofibromatosis type 1 are related to intracranial tumors but not to neurofibromatosis bright objects. *Seizure* 2011;20:606-11.
- [24] Flores-Sarnat L. Hemimegalencephaly: Part 1. Genetic, Clinical, and Imaging Aspects. *J Child Neurol* 2002;17:373-384.
- [25] Gales J, Prayson RA. Hippocampal sclerosis and associated focal cortical dysplasia-related epilepsy in neurofibromatosis type I. *J Clin Neurosci* 2017;37:15-19
- [26] Pecoraro A, Arehart E, Gallentine W, Radtke R, Smith E, Pizoli C, et al. Epilepsy in neurofibromatosis type 1. *Epilepsy Behav* 2017;73:137-41.
- [27] Korf BR, Carrazana E, Holmes GL. Patterns of seizures observed in association with neuro bromatosis 1. *Epilepsia* 1993; 34:616-20.
- [28] Caraballo RH, Portuondo E, Fortini PS. Neurofibromatosis and epilepsy. *J Pediatr Epilepsy* 2016;5: 59-63.
- [29] Pia Bernardo, Cinalli G, Santoro C. Epilepsy in NF1: a systematic review of the literature. *Childs Nerv Syst* 2020;36:2333-2350.
- [30] Algin Dİ, Tezer FI, Oguz KK, Bilginer B, Soylemezoglu F, Saygi S. Pharmacoresistant seizures in neurofibromatosis type 1 related to hippocampal sclerosis: three case presentation and review. *J Clin Neurosci* 2019; 64:14-17.
- [31] Barba C, Jacques T, Kahane P, Polster T, Isnard J, Leijten FS, et al. Epilepsy surgery in Neurofibromatosis Type 1. *Epilepsy Res* 2013; 105: 384-95.
- [32] Kullkantrakom K, Geller TJ. Seizures in neurofibromatosis 1. *Pediatr Neurol* 1998; 19: 347-50.