

We are IntechOpen, the world's leading publisher of Open Access books Built by scientists, for scientists

5,500

Open access books available

136,000

International authors and editors

170M

Downloads

Our authors are among the

154

Countries delivered to

TOP 1%

most cited scientists

12.2%

Contributors from top 500 universities



WEB OF SCIENCE™

Selection of our books indexed in the Book Citation Index
in Web of Science™ Core Collection (BKCI)

Interested in publishing with us?
Contact book.department@intechopen.com

Numbers displayed above are based on latest data collected.
For more information visit www.intechopen.com



Overview of the Global Prevalence and Diagnostic Criteria of Takotsubo Syndrome

Shogade Taiwo and Akpabio Akpabio

Abstract

Takotsubo syndrome (TTS) is an acute and reversible abnormal condition of the heart also known as stress cardiomyopathy, apical ballooning syndrome, or broken heart syndrome. It is an uncommon disease that mostly occurs among Asians though studies have shown its occurrence in other parts of the world. The typical takotsubo syndrome patient has a unique circumferential left ventricular contraction abnormality that extends beyond a coronary artery supply territory and appears to follow the anatomical cardiac sympathetic innervation.

The syndrome predominantly affects postmenopausal women and is often preceded by severe emotional or physical stress. The high risk of misdiagnosis on account of the similar clinical presentation between acute coronary syndrome (ACS) and TTS patients makes it imperative to do a detailed diagnostic work up of suspected patients.

Diagnosis of TTS is made by elevation of cardiac enzymes, abnormal electrocardiogram (ECG), visualization of abnormal myocardial wall motion, and demonstration of normal coronary arteries. Often, cardiac wall motion abnormalities resolve in weeks, and therapy is only necessary in hemodynamic unstable patients and if severe complications, such as arrhythmias, heart failure, thromboembolism, cardiac arrest, and cardiac wall rupture, occur. A universally acceptable guideline on TTS is necessary for its early diagnosis and optimal management.

Keywords: prevalence, diagnostic criteria, takotsubo syndrome, acute coronary syndrome

1. Introduction

Takotsubo syndrome (TTS) also known as left ventricular apical ballooning syndrome (LVBS), transient apical ballooning, broken heart syndrome or stress cardiomyopathy is an acute and reversible wall motion abnormality classically of the left ventricular myocardium, commonly but not exclusively seen among the Asian population. Takotsubo syndrome was first diagnosed in Hiroshima City Hospital Japan, in 1983 [1]. Sato and Dote in 1990 and 1991 introduced the term takotsubo (tako = octopus, tsubo = a pot) to describe the left ventricular silhouette during systole in five patients presenting with clinical features of myocardial infarction but without obstructive coronary artery disease [2].

(The syndrome is characterized by regional left ventricular wall motion abnormality (LVWMA) with a peculiar circumferential pattern resulting in a conspicuous ballooning of the left ventricle during systole as seen in **Figure 1a** and **b**. The LVWMA extends beyond a single coronary artery supply region and is reversible with almost complete resolution of ventricular dysfunction in hours to weeks depicted in **Figure 1c** and **d**). The LVWMA may be localized to the apical, midapical, midventricular, midbasal, or basal segments of the left ventricle [4].

However TTS gained international attention in the early 2000s, when the first diagnostic criteria: including apical dyskinesia/akinesia with basal hyperkinesia, absence of obstructive coronary artery disease (CAD) on coronary angiography, new electrocardiographic abnormalities, modest elevation in serum cardiac troponin in the absence of pheochromocytoma, and myocarditis, were published [5].

Recently, the Heart Failure Association of the European Society of Cardiology in a position statement from the task force on TTS introduced the terms primary and secondary TTS. They reported that “Acute cardiac symptoms are the primary reason for seeking medical care in primary TTS while in secondary TTS, the syndrome occurs in patients already hospitalized for a medical or surgical condition” [6].

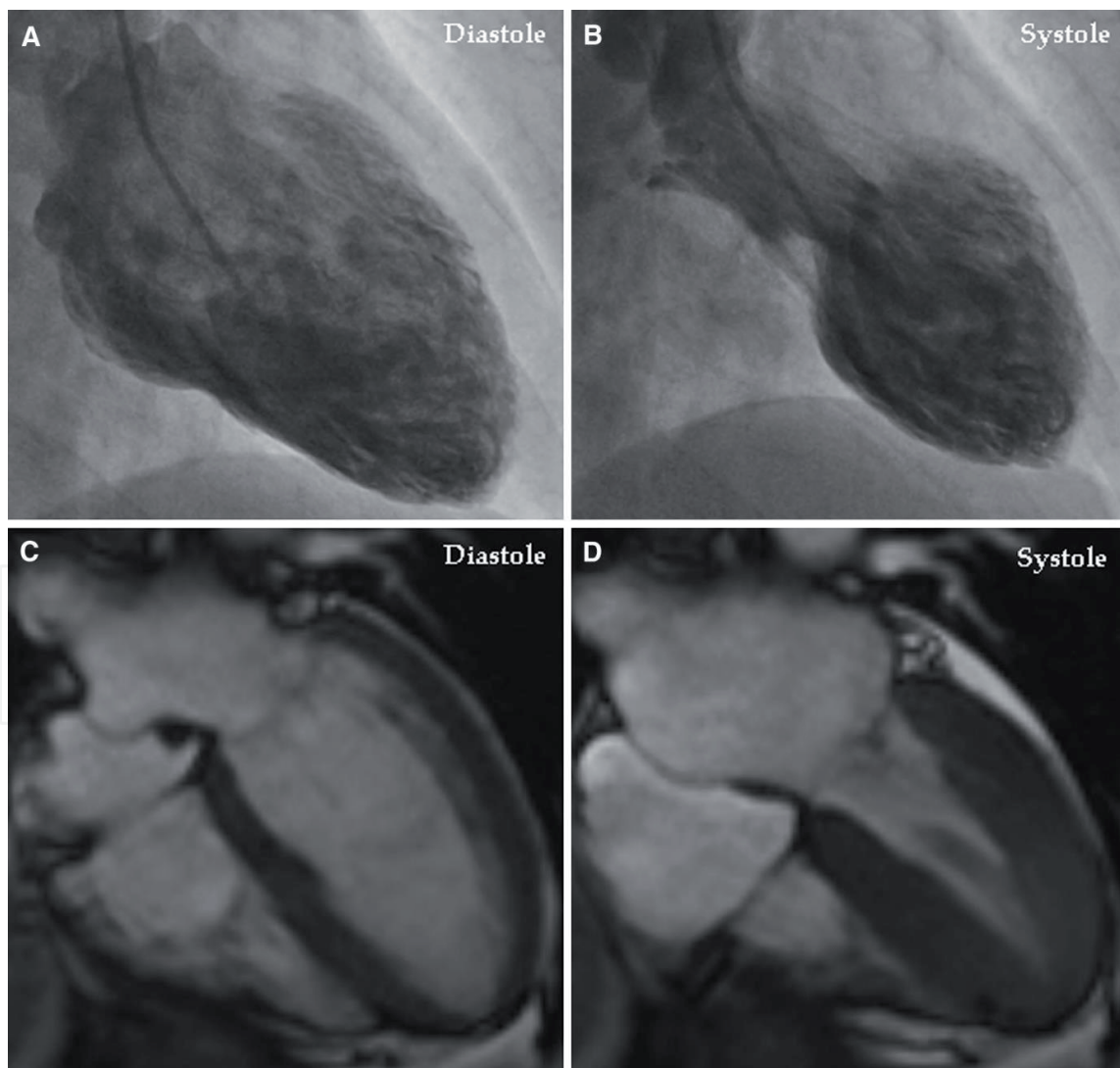


Figure 1. Left ventriculography during the acute stage of takotsubo syndrome shows typical midapical ballooning during systole (a) diastole, (b) systole. Cardiac magnetic resonance imaging 4 days after left ventriculography shows complete normalization of the left ventricular function (c) diastole, (d) systole. The figure is reproduced with permission from Y-Hassan et al. [3].

2. Global prevalence

The prevalence of TTS has been reported to be approximately 2% of all patients presenting with clinical manifestation of ACS and up to 10% if only women are considered [7]. More than 85% of the patients with TS are said to be postmenopausal women (aged 65–70 years) thus suggesting a possible hormonal response [6]. In Western countries, there is a female-to-male ratio of 9:1 [8], in contrast, men are more affected than women, for unknown reasons in Japan [9]. The syndrome has also been reported in all age groups and even in children [6].

Since the introduction of the term takotsubo in 1990 [4], TTS has increasingly gained more recognition in almost all countries of the world. The syndrome has been reported in a variety of races, the incidence and prevalence are rising in the Western countries due to greater awareness and widespread access to early invasive coronary angiography, but the syndrome is infrequently seen among African and Hispanics descents which maybe be due to poor awareness of the disease [10].

Minhas et al. reported from study done among North American population almost 20 times increase in the incidence of TTS from 2006 to 2012 (**Figure 2**) [11]. Similarly, a study by Murugiah et al. showed that hospitalization rates for TTS are increasing, in that study the incidence of primary TTS increased from 2.3 to 7.1 hospitalizations per 100,000 person-years in 2007 to 2012. The corresponding incidence for secondary TTS increased from 3.4 hospitalizations per 100,000 person-years in 2007 to 10.3 in 2012 [12].

2.1 Pathogenesis/pathophysiology

The proposed mechanism for the pathogenesis and pathophysiology of TS are complex and multifactorial which include acute reversible myocardial ischemia resulting from multivessel coronary artery spasm, microvascular dysfunction, left ventricular outflow tract obstruction (LVOTO), blood-borne catecholamine induced myocardial toxicity, epinephrine-induced switch in the intracellular signal

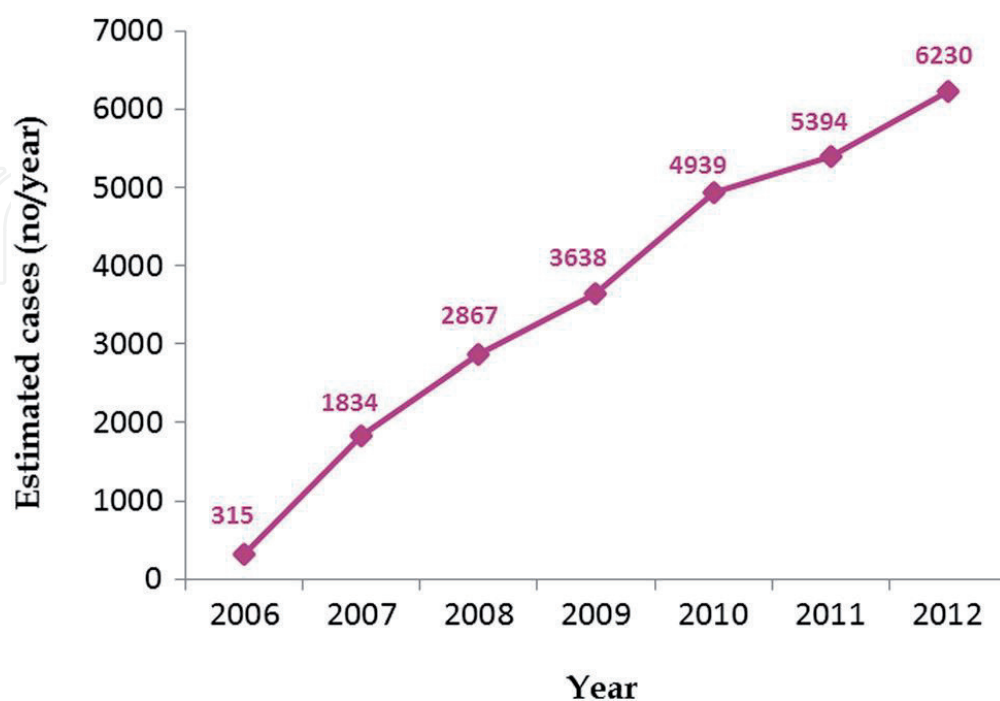


Figure 2. Trends in reported incidence of takotsubo syndrome from 2006 to 2012. Modified with permission from a table by Minhas et al. [11].

trafficking from Gs (stimulatory) to Gi (inhibitory) protein signaling through the B2 adrenoreceptor (B2AR) and sympathetic nervous system hyperactivation including local cardiac sympathetic disruption and norepinephrine excess and spillover [6].

2.2 Clinical presentation

Patients with TTS can present with acute chest pain, dyspnea, and syncope. They may also be completely asymptomatic and diagnosis made based on incidental abnormal electrocardiographic (ECG) or imaging features [13]. Furthermore, a minority of TTS patients may present with symptoms due to complications such as heart failure, pulmonary edema, cardiogenic shock, cardiac arrest, or stroke [14]. Takotsubo syndrome is often known to be preceded by a stressor; usually emotional in females or physical in males though no stressor may be identified in up to 30% of cases [14].

A strong association of subarachnoid hemorrhage and status epilepticus with TTS as well as a less strong association with seizures, transient global amnesia, meningoencephalitis, migraine headache, intracerebral hemorrhage and ischemic stroke was reported by Morris et al. [15]. In order to detect triggers in some cases, it is mandatory to scrutinize the individual's history for such events, often time relatives or close friends may need to be consulted in instances that patients are reluctant to talk about stressful events.

With the present Covid-19 pandemic it will not be unusual if there is a surge in the global incidence of TTS which could be as a result of, physical stressors: the direct impacts of the covid-19 infection on the heart and other organs of the body or emotional stressors: in form of emotional distress arising from direct or indirect effects of the covid 19 infection. Covid 19 infection have been associated with stress cardiomyopathy especially among postmenopausal females, Minhas et al. reported the case of a 58 year old female Caucasian who presented with symptoms of corona virus infection and subsequently developed mixed shock with echocardiography findings classic for TTS [16].

Morner and colleagues suggested that the presence of a preexisting subclinical cardiomyopathy may be a co-pathophysiological factor; they reported a patient with background hypertrophic cardiomyopathy (HCM) who developed heart failure with echocardiographic confirmed large left ventricular aneurysm after gastrointestinal surgery. Therefore, such background condition ought to be identified and monitored closely because it may impact negatively on the outcome of the syndrome. Thyroid dysregulation and pheochromocytoma are also known stressor in the pathogenesis of TTS [17, 18].

2.3 Imaging modalities

Transthoracic echocardiography (TTE): provides a quick method of demonstrating the left ventricular wall-motion abnormalities which usually extend beyond the distribution of a single coronary artery. Typically seen in TTS is hypokinesis or akinesis of the apical- and mid-segment of the left ventricle (LV) with characteristic hyperkinetic basal segment. Other variants include basal segment akinesia with midventricular and apical sparing, as well as the focal variant, characterized by focal wall motion abnormalities. Transthoracic echocardiography also helps in following up patients and assessing progress by estimating the LV ejection fraction (LVEF). Mean LVEF of affected patients are in the range of 20–49% [19].

Left ventricular ejection fraction though commonly assessed by echocardiography, can also be estimated by means of cardiac magnetic resonance imaging

(CMRI), or left ventriculography. Cardiac MRI offers unique advantage of safety, detailed anatomical visualization, and tissue characterization data, CMRI is essential for the exclusion of other entities particularly myocarditis and myocardial infarction with nonobstructive coronary arteries (MINOCA) [20].

Cardiac MRI is increasingly being preferred as a diagnostic technique uniquely suited for diagnosing TTS by accurately identifying reversible injury to the myocardium by the presence of inflammation/edema and the absence of necrosis/fibrosis, quantifying ventricular function as well as visualizing regional wall-motion abnormalities. Importantly cardiac MRI helps differentiate TTS which is characterized by absence of delayed gadolinium hyper-enhancement from myocardial infarction and myocarditis in which delayed enhancement occurs.

In 2011, CMR diagnostic criteria for TTS were established which includes:

1. The presence of wall motion abnormalities
2. Edema of dysfunctional segments on T2 weighted sequences
3. Absence of late gadolinium enhancement (LGE)

The absence of LGE suggests that there is no fibrosis or increased extracellular space. However, in some cases up to 9%, some spots of fibrosis are found, and these have been associated with worst prognosis [21].

Studies based on positron emission tomography (PET) and myocardial SPECT have shown a discrepancy between normal perfusion and reduced glucose utilization in TTS, commonly known as “inverse flow metabolism mismatch”. In the acute phase, TTS may be clinically indistinguishable from acute MI but, by means of PET, it has been successfully distinguished from acute MI [22]. Undoubtedly, coronary angiography is essential for the diagnosis of TTS by demonstrating a completely normal coronary arteries or rarely noncritical stenosis. It's important to note that left ventriculography is perhaps the best imaging modality for demonstrating the pathognomonic wall motion abnormalities and evaluating LV ejection fraction.

Data obtained from several registries including the international Takotsubo (InterTAK) Registry, a multicenter, prospective, retrospective, and observational study, which was conducted in more than 35 cardiovascular centers in 15 European countries, has enabled a diagnostic algorithm to be formulated. The diagnosis of TTS, which must be based on the absence of culprit coronary disease or presence of mild forms of coronary atherosclerosis. Therefore, TTS is gradually being better investigated and understood, and the number of diagnoses is increasing, as evidenced in the disease being included in the recent 4th universal definition of myocardial infarction by the European Society of Cardiology (ESC) [23].

2.4 Electrocardiogram

Electrocardiogram (ECG) is important in making a diagnosis of TTS, ECG is very useful in differentiating TTS from its closest differential, acute myocardial infarction. **Table 1** depicts the differences between the two conditions. ST-segment elevation and T-wave inversion are the commonest abnormalities seen on the initial ECG, which have been found to commonly involve the precordial leads and to be maximal in leads V2-V3. Unlike patients with ST-elevation myocardial infarction (STEMI) from left anterior descending (LAD) coronary artery occlusion, patients with TTS had significantly lower amplitude of ST-segment elevations. Similarly, T-wave inversions tend to occur in the days and weeks following presentation as the ST segments normalize, thus ECG cannot reliably differentiate TTS from other

Takotsubo syndrome	Acute anterior myocardial infarction
1. ST-segment elevation is detectable on precordial leads V1–V4 and limb leads I and aVL.	1. ST-segment elevation is mainly localized in V2–V5 leads and in limb leads II and aVR
2. Absence of reciprocal changes in inferior leads	2. There is presence of reciprocal changes in lateral and inferior leads
3. ST-segment elevation occurs more frequently in aVR	3. ST-segment elevation occurs more frequently in V1
4. There is absence of Q-wave	4. There is presence of Q-wave
5. ST-segment depressions occur in 10% of cases	5. ST-segment depression occurs in 30% of cases
6. Significantly lower amplitude of ST-segment elevation	6. Higher amplitude of ST-segment elevation

Table 1.
Electrocardiographic differences between takotsubo syndrome and acute myocardial infarction [24].

conditions with ST segments elevation. Chest radiograph, which is readily available and affordable, though often normal may demonstrate pulmonary edema in patients with the syndrome.

2.5 Biochemical profiles of takotsubo syndrome

Serum troponin is usually positive in the acute phase, but its values tend to be low when compares with the extent of myocardial dysfunction. The troponin level in TTS is commonly believed to be lower than in acute myocardial infarction (MI), though the InterTAK Registry has shown no difference between the two conditions. On the contrary, the hs-TnT/CKMB ratio has been found to be significantly higher in TTS when compares with STEMI and NSTEMI [25].

Increased levels of serum NT-proBNP can be demonstrated during the course of TTS. Nef and colleagues found that serum levels of NT-proBNP on admission were correlated to the severity of post-TTS complications during hospitalization, the higher the serum levels of NT-proBNP were on admission, the more clinical complications such as pulmonary edema and malignant ventricular arrhythmia present [26].

Recently, a two-part International expert consensus document on Takotsubo syndrome was published, providing a detailed characterization of TTC that allows clinicians to understand this cardiac dysfunction with a multidisciplinary view. There have been several attempts to create effective diagnostic criteria for TTS. The most widely used since 2018 has been the European Society of Cardiology (ESC) International Takotsubo Diagnostic Criteria (InterTAK Diagnostic Criteria) [27], which implements a diagnostic algorithm and assigns a score to TTS. InterTAK Diagnostic Score considers the following variables and gives each one a specific score: female sex; emotional and physical stress; absent ST depression; psychiatric disorders; neurologic disorders; and QTc prolongation. If the score is ≤ 70 points, the probability of having TTS is intermediate or low, whereas a score ≥ 70 indicates a high probability (**Table 2**).

Coronary angiography and left ventriculography are indicated in patients with a low probability of TTS and suspicion of ACS, while in patients with a high score, transthoracic echocardiography (TTE) should be performed. Wall motion abnormalities on TTE helps to decide the next step; if the typical presentation with circumferential ballooning pattern is absent, coronary angiography with left ventriculography is the next choice. In normal coronaries and typical ballooning, myocarditis must be excluded. The algorithm includes some red flags of

InterTak diagnostic score
Female sex 25 points
Emotional stress 24 points
Physical stress 13 points
No ST depression 12 points
Psychiatric disorders 11 points
Neurologic disorders 9 points
QTc prolongation 6 points
Score >70 points: high probability of TTS
Score ≤70 points: low/intermediate probability of TTS

Table 2.
 Diagnostic criteria used to distinguish takotsubo syndrome (TTS) from acute coronary syndrome (ACS).

myocarditis (signs and symptoms of viral infection, elevated ESR and/or PCR, and pericardial effusion); in the presence of the above, myocarditis should be excluded by Cardiac MRI.

2.6 Treatment

Supportive treatment is mainly indicated in the acute phase while promptly diagnosing and treating complications appropriately. In mild cases, in addition to supportive treatment bisoprolol and aspirin may be considered. However, for patients with complications standard treatment for the complications should be commenced such as antiarrhythmic drugs for arrhythmias, anticoagulation for those with documented thrombus in the left ventricle or embolic phenomena or until resolution of LVWMA.

The suggested treatment in cardiogenic shock due to left ventricular outflow tract obstruction (LVOTO) is intravenous fluid and parenteral beta-blocker which increases cardiac filling and suppresses the basal hypercontractility thereby reducing LVOTO or phenylephrine if patient is intolerant to intravenous fluid and betablocker. In primary failure, venoarterial extracorporeal membrane oxygenation, left ventricular assist device or levosimendan should be considered as bridge to recovery [28].

2.7 Complications

Though initially believed to be a benign condition, outcomes in patients with TTS can be influenced negatively owing to the various in-hospital complications that may arise as a result of electrical and hemodynamic instability, such as cardiac arrhythmias, cardiogenic shock, ventricular thrombus, pulmonary edema, ventricular septal defect, free-wall rupture and arterial thromboembolism. Male patients have been shown to have three times higher mortality rate due to major adverse cardiac and cerebrovascular events [27].

2.8 Prognosis of takotsubo syndrome

Takotsubo syndrome has been known to recur, recurrence rate varies widely between 1.5% and 6.1% during 6 years follow up period. Notably female patients showed higher recurrence rate of TTS compared to male [29, 30]. A significantly higher recurrence rate of 17.7% have been reported in patients with

pheochromocytoma-triggered TTS [18]. While some studies reported more male mortality compared to female [31]. Patel et al. found in their analysis no significant sex difference in respect to overall mortality rates of TTS patients aged ≥ 50 years [32].

Battrawy et al. reported from the multicenter GEIST (German Italian Stress Cardiomyopathy) Registry a recurrence rate of 4% at a median follow-up of 830 days among 749 patients. A variable TTS pattern at recurrence is common in up to 20% of recurrence cases. In this study it was observed that many patients that presented initially with involvement of only the left ventricle (LV), some years later developed right ventricular or biventricular involvement [30].

3. Conclusion

In conclusion, TTC is an acute and reversible cardiac disease, which commonly affects females of post-menopausal age and is often triggered by emotional or physical factors. Initially thought to be limited to the Asian population, it is also found in other parts of the world. This syndrome is associated with acute dysfunction of the central and autonomic nervous systems.

In order to better understand TTC, research on better diagnostic tools and therapeutic options need to be done. The recently published consensus document on TTS enhances clinical characterization of the syndrome and is hereby recommended.

Conflict of interest

Dr. Shogade Tolulope and Dr. Akpabio Akpabio declare no conflicts of interest.

Author details

Shogade Taiwo* and Akpabio Akpabio
University of Uyo Teaching Hospital, Uyo, Nigeria

*Address all correspondence to: docttaiwo@yahoo.com

IntechOpen

© 2020 The Author(s). Licensee IntechOpen. This chapter is distributed under the terms of the Creative Commons Attribution License (<http://creativecommons.org/licenses/by/3.0>), which permits unrestricted use, distribution, and reproduction in any medium, provided the original work is properly cited. 

References

- [1] Sato H. Tako-tsubo-like left ventricular dysfunction due to multivessel coronary spasm. In: Kodama K, Haze K, Hori M, editors. *Clinical Aspect of Myocardial Injury: From Ischemia to Heart Failure*. Tokyo, Japan: Kagakuhyoronsha Publishing Co; 1990. p. 56-64
- [2] YH S, Yamasaki K. History of takotsubo syndrome: Is the syndrome really described as a disease entity first in 1990? Some inaccuracies. *International Journal of Cardiology*. 2013;**166**:736-737
- [3] Y-Hassan S, Tornvall P. Epidemiology, pathogenesis, and management of takotsubo syndrome. *Clinical Autonomic Research*. 2018;**28**:53-65. DOI: 10.1007/s10286-017-0465-z
- [4] YH S, De Palma R. Contemporary review on the pathogenesis of takotsubo syndrome: The heart shedding tears: Norepinephrine churn and foam at the cardiac sympathetic nerve terminals. *International Journal of Cardiology*. 2016;**228**:528-536
- [5] Prasad A, Lerman A, Rihal C. Apical ballooning syndrome (tako-tsubo or stress cardiomyopathy): A mimic of acute myocardial infarction. *American Heart Journal*. 2008;**155**(3):408-417
- [6] Lyon AR, Bossone E, Schneider B, Sechtem U, Citro R, Underwood S, et al. Current state of knowledge on takotsubo syndrome: A position statement from the taskforce on takotsubo syndrome of the heart failure Association of the European Society of cardiology. *European Journal of Heart Failure*. 2016;**18**:8-27. DOI: 10.1093/eurheartj/ehy885
- [7] Akashi YJ, Nef HM, Lyon A. Epidemiology and pathophysiology of takotsubo syndrome. *Nature Reviews. Cardiology*. 2015;**12**:387-397
- [8] Schneider B, Athanasiadis A, Stöllberger C, et al. Gender differences in the manifestation of tako-tsubo cardiomyopathy. *International Journal of Cardiology*. 2013;**166**(3):584-588
- [9] Aizawa K, Suzuki T. Takotsubo cardiomyopathy. *Heart Failure Clinics*. 2013;**9**(2):243-247. DOI: 10.1093/eurheartj/ehy686
- [10] Nascimento FO, Larrauri-Reyes MC, Santana OP-C, M; Lamas G. Comparison of stress cardiomyopathy in Hispanic and non-Hispanic patients. *Revista Espanola de Cardiologia (Engl Ed)*. 2013;**66**:67-68
- [11] Minhas AS, Hughey AB, Koliass T. Nationwide trends in reported incidence of takotsubo cardiomyopathy from 2006 to 2012. *The American Journal of Cardiology*. 2015;**116**:1128-1131
- [12] Murugiah K, Wang Y, Desai NR, Spatz ES, Nuti SV, Dreyer R, et al. Trends in short- and long-term outcomes for takotsubo cardiomyopathy among medicare fee-for-service beneficiaries, 2007 to 2012. *JACC: Heart Failure*. 2016;**4**:197-205
- [13] Ghadri JR, Wittstein IS, Prasad A, et al. International expert consensus document on Takotsubo syndrome (part II): Diagnostic workup, outcome, and management. *European Heart Journal*. 2018;**39**(22):2047-2062
- [14] Templin C, Ghadri JRD, et al. Clinical features and outcomes of takotsubo (stress) cardiomyopathy. *The New England Journal of Medicine*. 2015;**373**(10):929-938
- [15] Morris NA, Chatterjee A, Adejumo OL, Chen M, Merkler AE, Murthy S, et al. The risk of takotsubo cardiomyopathy in acute neurological disease. *Neurocritical Care*.

2018;**30**:171-176. DOI: 10.1007/s12028-018-0591-z

[16] Minhas A, Scheel P, Garibaldi B, Liu G, Horton M, Jennings M, et al. Takotsubo syndrome in the setting of COVID-19. *Journal of the American College of Cardiology: Case Rep.* 2020;**2**:1321-1325. DOI: 10.1016/j.jaccas.2020.04.023

[17] Rueda D, Aguirre R, Contardo D, Finocchietto P, Hernandez S, di Fonzo H. Takotsubo myocardopathy and hyperthyroidism: A case report and literature review. *American Journal of Case Reports.* 2017;**18**:865-870

[18] YH S. Clinical features and outcome of pheochromocytoma- induced takotsubo syndrome: Analysis of 80 published cases. *The American Journal of Cardiology.* 2016;**117**:1836-1844

[19] Citro R, Rigo CC, D'Andrea A, et al. Echocardiographic correlates of acute heart failure, cardiogenic shock, and inhospital mortality in tako-tsubo cardiomyopathy. *JACC: Cardiovascular Imaging.* 2014;**7**(2):119-129

[20] Placido ER, Cunha Lopes B, Almeida AG, Rochitte C. The role of cardiovascular magnetic resonance in takotsubo syndrome. *Journal of Cardiovascular Magnetic Resonance.* 2016;**18**(1):68

[21] Wu KC, Weiss RTD, et al. Late gadolinium enhancement by cardiovascular magnetic resonance heralds an adverse prognosis in nonischemic cardiomyopathy. *Journal of the American College of Cardiology.* 2008;**51**(25):2414-2421

[22] Testa M, Feola M. Usefulness of myocardial positron emission tomography/nuclear imaging in takotsubo cardiomyopathy. *World Journal of Radiology.* 2014;**6**(7):502-506

[23] Thygesen K, Alpert JJA, et al. Fourth universal definition of myocardial infarction (2018). *European Heart Journal.* 2019;**40**:237-269

[24] Frangieh AH, Obeid SGJ, et al. ECG criteria to differentiate between Takotsubo (stress) cardiomyopathy and myocardial infarction. *Journal of the American Heart Association.* 2016;**5**(6):e003418

[25] Pirlet C, Pierard L, Legrand V, Gach O. Ratio of highsensitivity takotsubo, troponin to creatine kinase-MB in syndrome. *International Journal of Cardiology.* 2017;**243**:300-305

[26] Nef, HM; Mollmann, M; Troidl, C; Weber, M; Hamm C and EA. "Takotsubo cardiomyopathy: NT-proBNP as a reliable parameter of a favourable prognosis?" *International Journal of Cardiology* 2008;**124**(2):237-238

[27] Ghadri JR, Wittstein IA, Prasad A, et al. International expert consensus document on Takotsubo syndrome (part I): Clinical characteristics, diagnostic criteria, and pathophysiology. *European Heart Journal.* 2018;**39**(22):2032-2046

[28] Santoro F, Ieva R, Ferraretti A, Ienco V, Carpagnano G, Lodispoto M, et al. Safety and feasibility of levosimendan administration in takotsubo cardiomyopathy: A case series. *Cardiovascular Therapeutics.* 2013;**31**:e133-e137

[29] El-Battrawy I, Ansari U, Behnes M, Hillenbrand D, Schramm KHD, et al. Clinical and echocardiographic analysis of patients suffering from recurrent Takotsubo cardiomyopathy. *Journal of Geriatric Cardiology.* 2016;**13**:888-893. DOI: 10.11909/j.issn.1671-5411.2016.11.002

[30] El-Battrawy I, Santoro F, Stiermaier T, Möller C, Guastafierro F,

Novo Guasta G, et al. Incidence and clinical impact of recurrent Takotsubo syndrome. *Journal of American Heart Association*. 2019;**ke010753**:1-7. DOI: 10.1161/JAHA.118.010753

[31] Konstantinos G, El-Battrawy I, Schramm K, Uzair A, Hoffmann U, Martin B, et al. Comparison and outcome analysis of patients with Takotsubo cardiomyopathy triggered by emotional stress or physical stress. *Frontiers in Psychology*. 2017;**8**:527-531. DOI: 10.3389/fpsyg.2017.00527

[32] Patel SM, Chokka RG, Prasad KPA. Distinctive clinical characteristics according to age and gender in apical ballooning syndrome (Takotsubo/stress cardiomyopathy): An analysis focusing on men and young women. *Journal of Cardiac Failure*. 2013;**19**:306-310. DOI: 10.1016/j.cardfail.2013.03.007