

Transforaminal epidural steroid injection for recurrent lumbar disc herniation

İsmail Yuce¹, Okan Kahyaoglu², Muzeyyen Ataseven³, Halit Cavusoglu¹, Yunus Aydin²

¹Vocational School of Health Services, Acibadem Mehmet Ali Aydinlar University, Istanbul, Turkey

²Acibadem Healthcare Group, Fulya Hospital, Istanbul, Turkey

³Vocational School of Health Services, Istanbul Medipol University, Istanbul, Turkey

Copyright © 2020 by authors and Annals of Medical Research Publishing Inc.

Abstract

Aim: Transforaminal epidural steroid injection reduces the low back-leg pain which caused by lumbar disc herniation (LDH). The aim of our study is to evaluate the treatment of transforaminal epidural steroid injection for recurrent LDH.

Materials and Methods: 19 patients were included in our study who were treated by transforaminal epidural steroid injection for recurrent LDH in our clinic between 2014 and 2018. We evaluated the patients pre-procedure and at 2 weeks, 3 and 6 months after treatment by Visual Analogue Scale / Oswestry Disability Index (ODI) and followed up for surgical treatment after 6 months.

Results: The mean low back and leg pain VAS was 4.2±0.6 before TFESI procedure and it was 1.9±0.3 after two weeks. It was 2.1±0.3, 3.6±0.8 at 3 and 6 months after procedure respectively. The reduction of low back and leg pain mean VAS is statistically significant between before treatment and at 2 weeks and at 3 months after TFESI procedure respectively (p<0.05). The mean ODI was 21.4±0.3 before TFESI procedure and it was 12.4±0.7 after two weeks. It was 15.3±0.5 and 18.2±0.1 at 3 and 6 months after procedure respectively. The four of all patients were treated by microdiscectomy for recurrent LDH.

Conclusion: The transforaminal epidural steroid injection is safely treatment for non-surgical treatment of recurrent LDH. Our study recommends that transforaminal epidural steroid injection should be considered before surgical intervention and this procedure may support to surgical indication of recurrent LDH.

Keywords: Non-surgical treatment; recurrent lumbar disc herniation; transforaminal epidural steroid injection

INTRODUCTION

TFESI is most commonly used for the pain which is caused by LDH (1-3). This procedure is effective for short term treatment of lumbar radicular pain due to intervertebral disc herniation and is favored because fewer drugs is needed for the method (4-8). The symptoms such as lumbar radicular pain may relapses after lumbar microdiscectomy and reoperation for recurrent LDH causes difficulties to surgeons because of epidural fibrosis or adhesions (9). Due to these reason, TFESI procedure is preferred for recurrent LDH before re-surgery or conservative treatment.

MATERIALS and METHODS

This retrospective study was approved by the Ethical Committee of Medipol University Approval No: 190/19022020. 19 patients were evaluated retrospectively in our study who were treated for one level ipsilateral side recurrent LDH by TFESI in our clinic between 2014

and 2018. Inclusion criteria: History of one level lumbar microdiscectomy in our clinic, no history of conservative treatment at least 3 months, low back or radicular pain which demonstrate lumbar magnetic resonance images (MRI), one level and ipsilateral side recurrent LDH images at lumbar MRI (Figure 1 A,B), no preferred surgical treatment for recurrent LDH. The patients who have neurological deficits were excluded. We evaluated the patients 2 weeks, 3 and 6 months after treatment by Visual Analogue Scale (VAS) and Oswestry Disability Index (ODI). All patients were admitted to the neurosurgery department with VAS and ODI conducted by the medical secretary. Patients were asked questions via face-to-face assessment, or questions were addressed to family members if the patients had communication problems owing to regional dialect. The patients who have the same-high VAS or ODI score at 6 months after treatment were examined with lumbar MRI and were evaluated to re-surgery for recurrent LDH.

Received: 05.03.2020 **Accepted:** 30.10.2020 **Available online:** 19.11.2020

Corresponding Author: İsmail Yuce, Vocational School of Health Services, Acibadem Mehmet Ali Aydinlar University, Istanbul, Turkey

E-mail: dr.ismailyuce@gmail.com

Surgical procedures

TFESI is performed in the operation theatre equipped with C army scopy while the patients were prone position. The 21-gauge spinal needle is advanced towards the involved neural foramen under scopy after sterile preparation and local anesthesia. The one milliliter of contrast material (iohexol, 300 mg iodine per milliliter) was injected to confirm epidural area to avoid intradural or intravascular infiltration by anteroposterior and lateral X-ray imaging (Figure 1 C,D). The 0,5 milliliter bupivacaine HCl and 1 milliliter methylprednisolone acetate are injected to intervertebral foramen. The procedure is finished after exam of the patient.

Statistical analysis

The data obtained from the cases were recorded using Microsoft Excel-2010. SPSS 19 (Statistical Package for Social Sciences) for Windows Software was used for the evaluation of the findings (mean and standard deviation). Distribution of the data was analyzed using one way ANOVA tests. Statistical significance was set at a probability value of <0.05 (CI: Confidence Interval 95%).

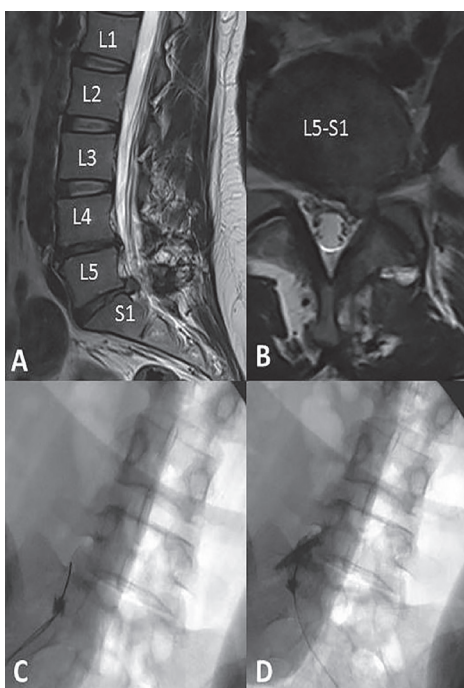


Figure 1. A, B Lumbar Magnetic Resonance Images of L5-S1 left recurrent lumbar disc herniation and C, D Anterior-posterior X-ray graphy images of L5-S1 transforaminal injection

RESULTS

Twenty patients were treated by TFESI for recurrent LDH and one patient refused to follow-up. The nineteen patients (11 were men, 8 were women) who underwent TFESI procedure for recurrent LDH were evaluated in our study. The mean age was 39.7±6 years. 12 of 19 patients were treated for L4-5 level and 7 patients were treated for L5-S1 level recurrent LDH by TFESI. The mean recurrent time was 11.2 months for L4-5 level and it was 14.7 months for L5-S1 level. 13 of all patients were left side recurrent and other 6 were right side.

The mean low back and leg pain VAS was 4.2±0.6 before TFESI procedure and it was 1.9±0.4 after two weeks. It was 2.1±0.3, 3.6±0.8 at 3 and 6 months after procedure respectively. The diversity of before procedure VAS between L4-5 and L5-S1 was not statistically significant ($p>0.05$). The reduction of low back and leg pain mean VAS is statistically significant between before treatment and at 2 weeks and at 3 months after TFESI procedure respectively ($p<0.05$) (Table 1). 5 of 19 (26.3%) patient's VAS were increase at 6 months. The worsening of VAS between two weeks and 6 months after treatment is statistically significant ($p<0.05$). 4 of 5 patients were treated by microdiscectomy for recurrent LDH.

Table 1. Demographics of patients

Parameters	n	%	P value
Mean age	39.7±6		
Gender			
Male	11	57.9	
Female	8	42.1	
Level			
L4-5	12	63.2	
L5-S1	7	36.8	
VAS			
Pre- procedure	4.2±0.6		
After 2 weeks	1.9±0.4		
After 3 months	2.1±0.3		
After 6 months	3.6±0.8		
Differences of 2 weeks / 6 months	0.6±0.2		P<0.05
ODI			
Pre- procedure	21.4±0.3		
After 2 weeks	12.4±0.7		
After 3 months	15.3±0.5		
After 6 months	18.2±0.1		
Differences of 2 weeks / 6 months	2.2±0.4		P<0.05

The mean ODI was 21.4±0.3 before TFESI procedure and it was 12.4±0.7 after two weeks. It was 15.3±0.5 and 18.2±0.1 at 3 and 6 months after procedure respectively. The diversity of pre-procedure ODI between L4-5 and L5-S1 was not statistically significant ($p>0.05$). The improvement of mean ODI is statistically significant at 2 weeks and 3 months after TFESI procedure respectively ($p<0.05$). 4 of 19 (21,1 %) patient's ODI were worse at 6 months. The worsening of ODI-between two weeks and 6 months after treatment is statistically significant ($p<0.05$). 4 patients were treated by microdiscectomy for recurrent LDH.

We did not observe any dural puncture or any spread of contrast medium in subarachnoid space, subdural space, and intradiscal space. No patient developed skin lesions or paresthesia.

We evaluated complication for TFESI at one patient in our study. It was weakness (left leg) after early period of TFESI procedure. After 2 days with rest, the weakness was not determined. There was no other complaint in this patient. The other complications were not determined in our study.

DISCUSSION

The intervertebral disc herniation at lumbar level of spine is a common cause of low back pain (LBP) or radicular leg pain (10-12). In patients with LDH, radicular pain of sciatic nerve is the major complaint and the reason of a need for surgical treatment. If the pain can be reduced, patients may feel that they have sufficient control over any residual discomfort, thus avoiding an operation.

TFESI procedure is widely performed for the treatment of radiculopathy or low back pain commonly caused by LDH. The coverage guidelines suppose that the surgical treatment for LDH unnecessary unless conservative treatment or TFESI (13).

The safely methods which commonly preferred for TFESI procedure have been described in literature. The subpedicular extraepidural approach is used for TFESI in our clinic which is described safely method in literature for the neural structures (14). This method has been found to have better clinical improvement with less pain during the procedure than intraepidural injection (15). The aim of TFESI is provide clinical improvement by suppressing the inflammation with steroid efficacy around the dorsal root that reason of the complaint (16-20). The anti-inflammatory effect of steroids is the presumed mechanism of action in this procedure and has been described in literature and it is commonly accepted that the TFESI has better results because of better distribution of the drug to the anterior part of the sac (17,20-24).

The low back pain or radiculopathy due to fibrosis in the epidural area with or without recurrent LDH were determined several studies in literature (16,25). The post-lumbar laminectomy nerve root adherence and fibrosis to the underlying disc and pedicle has been demonstrated in literature (26). Buenaventura et al. reported poor outcomes after TFESI for recurrent LDH, which may have been due to epidural fibrosis (27). However, the innervation to the annulus and its peripheral ligaments is multi-segmental, and in some studies it has even been stated that pain transferring via sympathetic routes will not be relieved by nerve block below the level of L2 (28). This mechanism makes that the TFESI method vulnerable to fibrosis-adhesion or recurrent LDH before re-surgery.

ODI and VAS, which are widely used in the literature, were used to evaluate the neurological status and pain complaints of our patients (29,30). The TFESI procedure is more effective treatment to LDH for patient whose age is <50 years than other patients and it was 39,7±6 years in our study (31).

TFESI provides clinical improvement for LDH in 6 months after the procedure (32). We evaluate and follow-up our patients in 6 months for determined improvement of pain and clinical status in our study. The patients who have been worse ODI or VAS score at 6 months after TFESI were examined and diagnosed by lumbar MRI for surgical treatment. The four patients who determined at 6 months after TFESI procedure and who have worse ODI classification or high VAS were treated surgically by microdiscectomy for recurrent LDH.

Generally the patients who have recurrent LDH consult the neurosurgeon who was operated them. The recurrent LDHs are rare pathologies for our clinic because of our small recurrent rate. The limitation of our present study which is related recurrent LDH is small case number.

CONCLUSION

The transforaminal epidural steroid injection is safely treatment for non-surgical treatment of recurrent LDH. It is effective method and has low-risk alternative to surgical treatment in selected cases. Our study recommends that TFESI should be considered before surgical intervention and this procedure may support to surgical indication of recurrent LDH.

Conflict of interest: The authors declare that they have no competing interest.

Financial Disclosure: There are no financial supports.

Ethical approval: The Ethics Committee of Medipol University; Approval No:190/19022020.

REFERENCES

1. Friedly J, Nishio I, Bishop MJ, et al. The relationship between repeated epidural steroid injections and subsequent opioid use and lumbar surgery. Arch Phys Med Rehabil 2008;89:1011-5.
2. Krych AJ, Richman D, Drakos M, et al. Epidural steroid injection for lumbar disc herniation in NFL athletes. Med Sci Sports Exerc 2012;44:193-8.
3. Abdi S, Datta S, Trescot AM, et al. Epidural steroids in the management of chronic spinal pain: a systematic review. Pain Physician 2007;10:185-212.
4. Atcheson SG, Dymeck T. Rapid resolution of chronic sciatica with intravenous infliximab after failed epidural steroid injections. Spine (Phila Pa 1976) 2004;29:248-50.
5. MacVicar, J, King, W, Landers, M. H, et al. The effectiveness of lumbar transforaminal injection of steroids: a comprehensive review with systematic analysis of the published data. Pain Med Malden Mass 2013;14:14-28.
6. Kennedy DJ, Plastaras C, Casey E, et al. Comparative effectiveness of lumbar transforaminal epidural steroid injections with particulate versus nonparticulate corticosteroids for lumbar radicular pain due to intervertebral disc herniation: a prospective, randomized, double-blind trial. Pain Med. Malden Mass 2014;15:548-55.

7. Ghahreman, A., Ferch, R. & Bogduk, N. The efficacy of transforaminal injection of steroids for the treatment of lumbar radicular pain. *Pain Med.* Malden Mass 2010;11:1149-68.
8. Chou R, Hashimoto R, Friedly J, et al. Epidural Corticosteroid Injections for Radiculopathy and Spinal Stenosis: A Systematic Review and Meta-analysis. *Ann Intern Med* 2015;163:373.
9. Chen Z, Zhao J, Liu A, et al. Surgical treatment of recurrent lumbar disc herniation by transforaminal lumbar interbody fusion. *Int Orthop* 2009;33:197-201.
10. Manchikanti L. Transforaminal lumbar epidural steroid injection. *Pain Physician* 2000;3:374-98.
11. Murphy RW. Nerve roots and spinal nerves in degenerative disc disease. *Clin Ortho* 1977;129:46-60.
12. McCarron RF, Wimpee MW, Hudkins PG, et al. The inflammatory effect of nucleus pulposus. A possible element in pathogenesis of low back pain. *Spine* 1987;12:760-4.
13. Epidural Steroid and Facet Injections for Spinal Pain. United Healthcare Commercial Medical Policy 2018 #2018T0004DD. Effective 02/01/2018
14. Atluri S, Glaser SE, Shah RV, et al. Needle position analysis in cases of paralysis from transforaminal epidurals: Consider alternative approaches to traditional techniques. *Pain Physician* 2013;16:321-34.
15. Lee J.W, Kim S.H, Lee I.S, et al. Therapeutic effect and outcome predictors of sciatica treated using transforaminal epidural steroid injection. *AJR Am J Roentgenol* 2006;187, 1427-31.
16. Olmarker, K.; Holm, S.; Rosenqvist, A.-L, et al. Experimental nerve root compression. A model of acute, graded compression of the porcine cauda equina and an analysis of neural and vascular anatomy. *Spine* 1991;16:61-9.
17. Jeong HS, Lee JW, Kim SH, et al. Effectiveness of Transforaminal Epidural Steroid Injection by Using a Preganglionic Approach: A Prospective Randomized Controlled Study. *Radiology* 2007;245:584-90.
18. Lee JW, Kim SH, Choi JY, et al. Transforaminal epidural steroid injection for lumbosacral radiculopathy: Preganglionic versus conventional approach. *Korean J Radiol* 2006;7:139-44.
19. Onda A, Yabuki S, Kikuchi S, et al. Effects of lidocaine on blood flow and endoneurial fluid pressure in a rat model of herniated nucleus pulposus. *Spine* 2001;26:2186-91.
20. Vad VB, Bhat AL, Lutz GE, et al. Transforaminal epidural steroid injections in lumbosacral radiculopathy: a prospective randomized study. *Spine* 2002;27:11-6.
21. Roberts ST, Willick SE, Rho ME, et al. Efficacy of lumbosacral transforaminal epidural steroid injections: a systematic review. *PM R* 2009;657-68
22. Khan MU, Hussain SZ. Role of psoas compartment and caudal epidural steroid injection in spinal stenosis patients associated with low back pain and lower limb radiculopathy. *J Pak Med Assoc* 2008;58:490-3.
23. Rinehart JJ, Sagone AL, Balcerzak SP, et al. Effects of corticosteroid therapy on human monocyte function. *N Engl J Med* 1975;292:236-41.
24. Weinstein SM, Herring SA, Derby R. Contemporary concepts in spine care: Epidural steroid injections. *Spine* 1995;20:1842-6.
25. Delamarter RB, Bohlman H, Dodge LEA, et al. Experimental lumbar spinal stenosis. Analysis of the cortical evoked potentials, microvasculature, and histopathology. *J Bone Jt Surg Am* 1990;72:110-20.
26. Lee JG, Lee SC, Kim YC, et al. Effects of low and high molecular weight hyaluronic acids on peridural fibrosis and inflammation in lumbar laminectomized rats. *Korean J Pain* 2011;24:191-8
27. Buenaventura RM, Datta S, Abdi S, et al. Systematic review of therapeutic lumbar transforaminal epidural steroid injections. *Pain Physician* 2009;12:233-51.
28. Sluijter ME. The role of radiofrequency in failed back surgery patients. *Curr Rev Pain* 2000;4:49-53.
29. Park Y, Lee WY, Ahn JK, et al. Percutaneous Adhesiolysis Versus Transforaminal Epidural Steroid Injection for the Treatment of Chronic Radicular Pain Caused by Lumbar Foraminal Spinal Stenosis: A Retrospective Comparative Study *Ann Rehabil Med* 2015;39:941-9.
30. Kim HJ, Yeom JS, Lee JW, et al. The influence of pain sensitivity on the treatment outcome of transforaminal epidural steroid injection in patients with lumbar spinal stenosis. *Pain Pract* 2014;14:405-12.
31. Viton JM, Peretti-Viton P, Rubino T, et al. Short-term assessment of periradicular corticosteroid injections in lumbar radiculopathy associated with disc pathology. *Neuroradiology* 1998;40:59-62.
32. Evidence-Based Clinical Guidelines for Multidisciplinary Spine Care: Diagnosis and Treatment of Lumbar Disc Herniation with Radiculopathy. (2012) North American Spine Society.