

# Clinical Evaluation of Decompressive Craniectomy in Malignant Middle Cerebral Artery Infarction using 3D Area and Volume Calculations

Serkan Kitiş<sup>1</sup>, Serdar Çevik<sup>2,3</sup>, Kevser B. Köse<sup>4</sup>, Arzu Baygöl<sup>5</sup>, Serhat Cömert<sup>6</sup>, Ülkün Ü. Ünsal<sup>7</sup>, Meliha G. Papaker<sup>1</sup>

<sup>1</sup>Department of Neurosurgery, Bezmialem Vakıf University, Istanbul, <sup>2</sup>Department of Neurosurgery, Memorial Şişli Hospital, Istanbul, <sup>3</sup>Department of Physical Therapy and Rehabilitation, School of Health Sciences, Gelişim University, Istanbul, <sup>4</sup>Department of Biomedical Engineering Department, Istanbul Medipol University, Istanbul, <sup>5</sup>Department of Biostatistics and Medical Informatics, Koç University, Istanbul, <sup>6</sup>Department of Neurosurgery, Yenimahalle Training and Research Hospital, Ankara, <sup>7</sup>Department of Neurosurgery, Manisa State Hospital, Manisa, Turkey

## Abstract

**Objective:** We aimed to measure the craniectomy area using three-dimensional (3D) anatomic area and volume calculations to demonstrate that it can be an effective criterion for evaluating survival and functional outcomes of patients with malignant middle cerebral artery (MCA) infarction. **Material and Methods:** The patients diagnosed with malignant ischemic stroke between 2013 and 2018, for which they underwent surgery due to deterioration in their neurological function, were retrospectively reviewed. Radiological images of all patients were evaluated; total brain tissue volume, ischemic brain tissue volume, total calvarial bone area, and decompression bone area were measured using 3D anatomical area and volume calculations. **Results:** In total, 45 patients (27 males and 18 females) had been treated with decompressive craniectomy (DC). The removed bone area was found to be significantly related to the outcome in patients with MCA infarction. The average decompression bone area and mean bone removal rate for patients who died after DC were  $112 \pm 27 \text{ cm}^2$  and 20%, whereas these values for surviving patients were  $149 \pm 29 \text{ cm}^2$  and 26% ( $P = 0.001$ ), respectively. At the 6-month follow-up, the average decompression bone area and mean bone removal rate for patients with severe disability were  $126 \pm 30 \text{ cm}^2$  and 22.2%, whereas these values for patients without severe disability were  $159 \text{ cm}^2 \pm 26$  and 28.4% ( $P = 0.001$ ), respectively. **Conclusion:** In patients with malignant MCA infarction, the decompression area is associated with favorable functional outcomes, first, survival and second, 6-month modified Rankin scale score distribution after craniectomy.

**Keywords:** Craniectomy area, decompressive craniectomy, middle cerebral artery infarction, modified Rankin scale, outcome

## INTRODUCTION

Stroke, a neurological emergency, is one of the leading causes of mortality and morbidity in almost all countries. According to the World Health Organization data, it is the third most common cause of death after cardiovascular diseases and cancer in developed countries. Supratentorial localized cerebrovascular diseases, especially those caused by an increase in intracranial pressure (ICP) owing to diffuse edema after malignant middle cerebral artery (MCA) infarction, result in a clinical syndrome responsible for the increase in mortality.<sup>[1-4]</sup> For this reason, aggressive treatment should be performed for common ischemic events such as malignant infarction. Therefore, in patients at high risk for developing malignant edema radiologically and clinically, if the mass effect continues to increase despite adequate and sufficient medical treatment, decompressive craniectomy (DC) should be performed without waiting for herniation development.<sup>[5-9]</sup>

The aim of DC is to reduce intracranial hypertension and ensure normal nutrition to the brain tissue. At present, the method of choice among the available surgical treatments is DC. However, there is no standard procedure for performing DC as many factors, such as the amount of tissue affected, the compliance of brain tissue, and other

systemic diseases, affect the extent and severity of the developing brain edema.

The area to be involved in DC is determined by the patient's physician after the evaluation of his or her computed tomography (CT) and magnetic resonance imaging (MRI) findings. However, it is thought that small craniectomies may increase the severity of herniation by causing the brain parenchyma to get stuck in the decompression bone margin, thereby increasing the ischemia area by occlusion of the cerebral cortical veins.<sup>[10-13]</sup> For this reason, at least a 12-cm craniectomy is recommended in the anteroposterior (AP)

**Address for correspondence:** Dr. Serdar Çevik,  
Memorial Şişli Hospital, Piyalepaşa Bulvarı No: 4, Şişli - 34385,  
Istanbul, Turkey.  
E-mail: [dr.serdarcevik@gmail.com](mailto:dr.serdarcevik@gmail.com)

**Submitted:** 25-May-2020 **Revised:** 09-Jun-2020 **Accepted:** 21-Aug-2020  
**Published:** 01-Dec-2020

This is an open access journal, and articles are distributed under the terms of the Creative Commons Attribution-NonCommercial-ShareAlike 4.0 License, which allows others to remix, tweak, and build upon the work non-commercially, as long as appropriate credit is given and the new creations are licensed under the identical terms.

**For reprints contact:** [WKHLRPMedknow\\_reprints@wolterskluwer.com](mailto:WKHLRPMedknow_reprints@wolterskluwer.com)

**DOI:** 10.4103/aian.AIAN\_518\_20

direction, including the frontoparietotemporal bone and sometimes the occipital bone.<sup>[14]</sup> Although the size of the craniectomy is known to be related to many secondary complications in patients with malignant MCA infarction, there are limited studies in the literature to determine the ideal craniectomy area. In this study, we hypothesized that the craniectomy area is an effective criterion to evaluate the survival and functional outcomes of patients with MCA infarction.

## MATERIALS AND METHODS

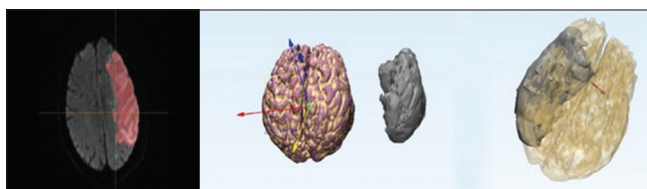
The data analyzed in this study were obtained from a university hospital where more than 500 patients with ischemic stroke are treated annually. The hospital data system was analyzed retrospectively to determine patients who underwent DC for ischemic MCA infarction. Among patients diagnosed with malignant ischemic stroke between 2013 and 2018, those who underwent surgery due to deterioration in their neurological conditions were identified. The inclusion criteria of the study were as follows: Patients with CT performed before and after surgery, those with preoperative MRI, those who had not undergone interventional thrombectomy, those with no signs of intracerebral bleeding before surgery, and those who were followed up for at least 6 months after surgery.

The duration from the onset of patients' symptoms to DC, the Glasgow coma scale (GCS) score before surgery, and modified Rankin scale (mRS) score at 6 months after surgery were documented. Radiological images of all patients were evaluated; total brain tissue, ischemic brain tissue, total calvarial bone area, and decompression bone area were measured.

### Volumetric and field measurements

Imaging data for each patient were obtained from the hospital PACS system. Pre- and postcranial models were obtained from the DICOM data using Toshiba Helical CT Scanner (Asteion; Toshiba Medical Systems, Tokyo, Japan). MRI data for brain and damaged tissue were obtained using Siemens MRI machine (1.5 Tesla Magnetom Avanto, Siemens Healthcare Sector, Erlangen).

Three-dimensional (3D) models for regions of interest were obtained from multi-sliced DICOM images using image processing tools by Mimics Innovation Suite 19.0 (Materialise, Leuven, Belgium). Cranial, brain tissue, and damaged brain tissue models were created for each patient [Figure 1].



**Figure 1:** Reconstruction of 3D cranial models from preoperative computed tomography images

Ischemic brain tissue was determined by manually marking hyperintense ischemic brain areas on MRI scans. The models were optimized using computer-aided design tools (Geomagic Studio; Geomagic Software, 3D Systems, Rockhill, SC, USA) for refining and measuring volume and grid generation tools (Ansys Design Modeler; ANSYS Inc, Somerset, PA, USA) to calculate the area of the upper hemisphere surface of the skull [Figure 2a]. The same guide plane-cut, which is between the occipital and nasal bones including the frontal, parietal, and temporal bones' upper surfaces, was used for each model [Figure 2b and c].

## RESULTS

In total, 45 patients [27 males, 18 females; mean age,  $62.7 \pm 11.1$  (range, 34–83) years], were included in the study. The demographic data of the patients are presented in Table 1. The mean GCS score of the patients at admission was  $7.9 \pm 1.45$  (range, 5–12). Of all the patients, 14 (31.1%) had left MCA and 31 (68.9%) had right MCA infarction. The mean duration from the onset of symptoms to DC was  $34.4 \pm 27.59$  h for all the patients. Furthermore, 24 patients underwent surgery within the first 24 h of the onset of symptoms (early surgery) and 21 underwent surgery 24 h after the onset of symptoms.

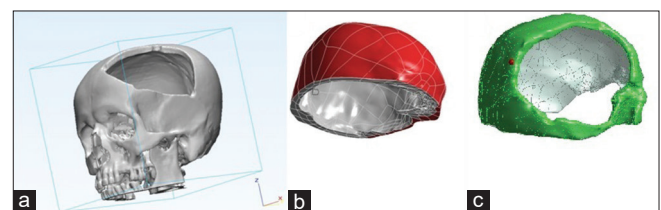
### Volumetric analysis

The mean calculated total brain tissue volume was  $1225 \pm 176$  (range, 835–1630)  $\text{cm}^3$ , ischemic brain tissue volume was  $212 \pm 71$  (range, 109–409)  $\text{cm}^3$ , and ischemic brain tissue/total brain tissue ratio was 17% (range, 10%–33%). The mean total calvarial area was  $566 \pm 55$  (range, 482–629)  $\text{cm}^2$ , decompression bone area was  $139 \pm 32$  (range, 70–205)  $\text{cm}^2$ , and decompression bone area/total calvarial area was 24% (range, 13%–36%).

### Clinical outcome

At the 6-month follow-up of the patients, the mRS score was  $<4$  in 19 (41%) patients and  $\geq 4$  in 26 (59%) patients. Twelve (27%) patients died before the 6-month follow-up after surgery (mRS score = 6). The duration from the onset of the patients' symptoms to DC and the GCS score of the patients before surgery did not have a significant effect on survival and functional outcomes.

The mean ischemic brain tissue volume and mean damaged brain tissue rate of patients who died after DC were  $248 \pm 94$   $\text{cm}^3$  and 19.8%, whereas these values for surviving



**Figure 2:** (a) The cut-plane standard for the cranial models. (b) Surface selection for pre (left)- and (c) post (right)-cranial models on ANSYS Design Modeler

patients were  $199 \pm 57 \text{ cm}^3$  and 16.6%, respectively. There were no significant between-group differences in the mean ischemic brain tissue volume and mean damaged brain tissue ratio in terms of mortality ( $P = 0.104$  and  $P = 0.095$ , respectively).

The mean decompression bone area and mean bone removal rate for the patients who died after DC were  $112 \pm 27 \text{ cm}^2$  and 20%, whereas these values for the surviving patients were  $149 \pm 29 \text{ cm}^2$  and 26%, respectively. Significant between-group differences were observed in the mean decompression bone area and mean bone removal rate in terms of mortality ( $P = 0.001$  and  $P = 0.001$ , respectively) [Table 2].

The mean ischemic brain tissue volume and mean damaged brain tissue ratio for the patients with severe disability (mRS score  $\geq 4$ ) after 6-month follow-up were  $220 \pm 73 \text{ cm}^3$  and 18.6%, whereas these values for the patients without severe disability (mRS score  $< 4$ ) were  $200 \pm 68 \text{ cm}^3$  and 15.6%, respectively. There were no significant between-group differences in mean ischemic brain tissue volume and mean damaged brain tissue ratio in terms of disability ( $P = 0.292$  and  $P = 0.052$ , respectively). After 6-month follow-up, the mean decompression bone area and mean bone removal rate for patients with severe disability were  $126 \pm 30 \text{ cm}^2$  and 22.2%, whereas these values for patients without severe disability were  $159 \pm 26 \text{ cm}^2$  and 28.4%, respectively. Significant between-group differences were observed in the mean decompression bone area and mean bone removal rate in terms of disability ( $P = 0.001$  and  $P = 0.001$ , respectively) [Table 3].

### Cutoff values for removed bone area as outcome markers for malignant MCA infarct

Cutoff values were determined to evaluate the efficacy of the removed bone area as a criterion for determining both morbidity and mortality. Removed bone area was significantly associated with outcomes in patients with malignant MCA infarction.

The ROC analysis of the removed bone area showed that the amount of removed bone area was strictly distinctive between patients who died and those who survived after DC. For removed bone area  $> 116 \text{ mm}^2$ , sensitivity was 75% and specificity was 88% (area under the ROC curve;  $\text{AUC} = 0.828$ ;  $P = 0.001$ ) [Figure 3a]. In addition, AUC demonstrated that the amount of removed bone area was able to discriminate between patients with mRS score  $\geq 4$  and mRS score  $< 4$ . For removed bone area  $> 124 \text{ mm}^2$ , sensitivity was 59% and specificity was 94% ( $\text{AUC} = 0.798$ ;  $P = 0.001$ ) [Figure 3b].

## DISCUSSION

Our results show that the decompression area created during craniectomy in patients with malignant MCA infarction is associated with better functional outcomes: First, survival and second, 6-month mRS score distribution after craniectomy. In addition to parenchymal damage after MCA infarction, herniation and secondary neuronal injury development due to increased ICP worsens the prognosis in these patients.

**Table 1: Baseline characteristics in 45 patients who underwent surgical decompression to treat malignant MCA infarction**

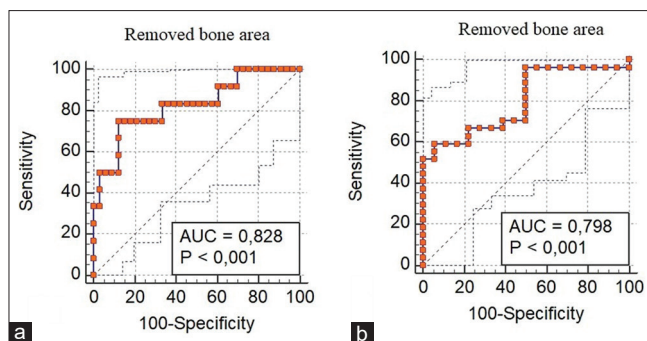
Characteristic or variable	Value
Mean age (years)	$62.6 \pm 11.1$
Mean GCS	$7.9 \pm 1.61$
Sex (n, %)	
female	18 (40%)
male	27 (60%)
Affected side (n, %)	
right	31 (68.9%)
left	14 (31.1%)
Mean time to operation (h)	$34.4 \pm 27.6$
$\leq 24$ h	24 (53.3%)
$> 24$ h	21 (46.7%)
Involvement of vascular territories (n, %)	
MCA	38 (84.5%)
MCA and ACA (ICA)	7 (15.5%)

**Table 2: Comparison of volumetric and field measurements of patients alive and dead after craniectomy**

	Dead (n = 12)	Alive (n = 33)	p
Age	$64.9 \pm 7.59$	$61.8 \pm 5.03$	0.552
GCS	$7.3 \pm 1.83$	$8.1 \pm 1.26$	0.051
Operation time	$28.3 \pm 24.7$	$36.6 \pm 28.6$	0.247
Total brain volume ( $\text{cm}^3$ )	$1245 \pm 208$	$1218 \pm 166$	0.771
Injured brain volume ( $\text{cm}^3$ )	$248 \pm 94$	$199 \pm 57$	0.104
Injured brain volume rate (%)	19.8%	16.6%	0.095
Total calvarium area ( $\text{mm}^2$ )	$567 \pm 42$	$566 \pm 59$	0.929
Removed bone area ( $\text{mm}^2$ )	$112 \pm 27$	$149 \pm 29$	0.001
Removed bone ratio (%)	19.8%	26.4%	0.001

**Table 3: Comparison of volumetric and field measurements of patients with favorable (mRS Score 0-3) and poor (mRS Score 4-6) functional outcomes at 6 months**

	mRS $\geq 4$ (n = 27)	mRS $< 4$ (n = 18)	p
Age	$63.6 \pm 12.37$	$61.3 \pm 9.04$	0.372
GCS	$7.7 \pm 1.64$	$8.3 \pm 1.07$	0.081
Operation time	$30.2 \pm 21.52$	$40.7 \pm 34.53$	0.310
Total brain volume ( $\text{cm}^3$ )	$1190 \pm 193$	$1278 \pm 135$	0.091
Injured brain volume ( $\text{cm}^3$ )	$220 \pm 73$	$200 \pm 68$	0.292
Injured brain volume rate (%)	18.6%	15.6%	0.052
Total calvarium area ( $\text{mm}^2$ )	$570 \pm 50$	$561 \pm 63$	0.331
Removed bone area ( $\text{mm}^2$ )	$126 \pm 30$	$159 \pm 26$	0.001
Removed bone ratio (%)	22.2%	28.4%	0.001



**Figure 3:** (a) The receiver operating characteristics (ROC) curve analysis of the removed bone area; for the removed bone area > 116 mm<sup>2</sup>, sensitivity was 75% and specificity was 88% (AUC = 0.828;  $P = 0.001$ ). (b) ROC curve analysis of the removed bone area; for the removed bone area > 124 mm<sup>2</sup>, sensitivity was 59% and specificity was 94% (AUC = 0.798;  $P = 0.001$ )

Therefore, evaluation of the effectiveness of surgical interventions to reduce ICP has garnered attention in recent years. Hence, the dimensions of craniectomy area should be well planned to sufficiently decrease ICP in patients with malignant MCA infarction. Moreover, small craniectomies may exacerbate the herniation by resulting in conditions such as kinking/occlusion of the cerebral veins and swelling and laceration of the cerebral cortex.<sup>[10-13]</sup> It is known that suboptimal DC causes additional cortical lesions, leading to a decrease in survival rate.<sup>[14]</sup> Therefore, it is recognized that for effective decompression, the minimum diameter should be at least 12 cm in the AP direction.<sup>[14]</sup> However, there is still uncertainty in determining the dimensions of the craniectomy area.

In our retrospective analysis, we evaluated total brain volume, infarct volume, calvarial surface area, and craniectomy surface area measurements from preoperative and postoperative imaging findings. Infarct volume and infarct volume/brain volume ratio had no significant effect on survival. However, the removed bone area and removed bone area/calvarial surface area ratio showed significant effects on patients' survival. When a cutoff value of >116 cm<sup>2</sup> was determined for the removed bone area according to the ROC curve analysis, a significant improvement was observed in the survival rate of the patients (sensitivity, 75%; specificity, 88%; AUC 0.828;  $P = 0.001$ ).

Our results showed that DC has an impressive lifesaving effect on patients with malignant MCA infarction, corroborating the results of previous randomized controlled trials (DESTINY,<sup>[6]</sup> DECIMAL<sup>[7]</sup>). However, the role of surgical decompression in the treatment of malignant cerebral infarction remains controversial. DC is an emergency neurosurgical intervention performed only for a life-threatening condition that cannot be evaluated in terms of survival.<sup>[15,16]</sup> Therefore, the main purpose of our study was to evaluate the effect of the amount of craniectomy area on functional outcome. As reported previously, we considered mRS score <4 as a good

functional outcome.<sup>[8]</sup> Accordingly, it was observed that the infarct volume and infarct volume/brain volume ratio had no effect on the functional outcome of the patients at 6-month follow-up [Table 3]. However, the removed bone area and removed bone area/calvarial surface area ratio showed a significant effect on patients' functional outcome. Walz *et al.* found severe disability in only 8.3% of patients and slight to moderate disability in most patients in long-term follow-up of patients who underwent craniectomy larger than 14 cm.<sup>[17]</sup> In addition, in a recent study, Chung *et al.* showed that DC at the maximum size increased the positive result rate 3 months after stroke compared with that at a large size (>12 cm) (mRS score <4).<sup>[18]</sup> In our study, when a cutoff value of >124 cm<sup>2</sup> was determined for the removed bone area according to the ROC analysis, a significant improvement was observed in the survival rate of the patients (sensitivity, 59%; specificity, 94%; AUC, 0.798;  $P = 0.001$ ).

This study has some limitations. As this is a retrospective study, it is potentially exposed to sources of bias. Selection bias was avoided as all consecutive patients of 5 years (2013–2018) were included in the study. In addition, patients who had undergone endovascular thrombectomy were not included in the study, thereby eliminating the possible bias for surgical decompression.

## CONCLUSION

In patients with surgically treated MCA infarctions, the decompression bone area is associated with favorable functional outcomes for survival and at 6-month follow-up. For patients with malignant MCA infarction, prospective randomized studies focusing on the relationship between the removed bone area and favorable functional outcomes are required.

## Financial support and sponsorship

Nil.

## Conflicts of interest

There are no conflicts of interest.

## REFERENCES

- Hacke W, Schwab S, Horn M, Spranger M, De Georgia M, von Kummer R. Malignant middle cerebral artery infarction: Clinical course and prognostic signs. *Arch Neurol* 1996;53:309-15.
- Heinsius T, Bogousslavsky J, Van Melle G. Large infarcts in the middle cerebral artery territory. Etiology and outcome patterns. *Neurology* 1998;50:341-50.
- Sakai K, Iwahashi K, Terada K, Gohda Y, Sakurai M, Matsumoto Y. Outcome after external decompression for massive cerebral infarction. *Neurol Med Chir* 1998;38:131-5.
- Shaw CM, Alvord EC Jr, Berry RG. Swelling of the brain following ischemic infarction with arterial occlusion. *Arch Neurol* 1959;1:161-77.
- Hofmeijer J, Kappelle LJ, Algra A, Amelink GJ, van Gijn J, van der Worp HB, *et al.* Surgical decompression for space-occupying cerebral infarction (the Hemicraniectomy after middle cerebral artery infarction with lifethreatening edema trial HAMLET): A multicenter, open, randomised trial. *Lancet Neurol* 2009;8:326-33.
- Jüttler E, Schwab S, Schmiedek P, Unterberg A, Hennerici M, Woitzik J, *et al.* Decompressive surgery for the treatment of malignant infarction of

- the middle cerebral artery (DESTINY): A randomized, controlled trial. *Stroke* 2007;38:2518-25.
7. Vahedi K, Vicaut E, Mateo J, Kurtz A, Orabi M, Guichard JP, *et al.* Sequential design, multicenter, randomized, controlled trial of early decompressive craniectomy in malignant middle cerebral artery infarction (DECIMAL Trial). *Stroke* 2007;38:2506-17.
  8. Vahedi K, Hofmeijer J, Juettler E, Vicaut E, George B, Algra A, *et al.* Early decompressive surgery in malignant infarction of the middle cerebral artery: A pooled analysis of three randomised controlled trials. *Lancet Neurol* 2007;6:215-22.
  9. Frank JI, Schumm LP, Wroblewski K, Chyatte D, Rosengart AJ, Kordeck C, *et al.* Hemicraniectomy and durotomy upon deterioration from infarction-related swelling trial: Randomized pilot clinical trial. *Stroke* 2014;45:781-7.
  10. Fung C, Murek M, Z'Graggen WJ, Krähenbühl AK, Gautschi OP, Schucht P, *et al.* Decompressive hemicraniectomy in patients with supratentorial intracerebralhemorrhage. *Stroke* 2012;43:3207-11.
  11. Neugebauer H, Heuschmann PU, Jüttler E. DEcompressive surgery for the treatment of malignant INfarction of the middle cerebral artery-Registry (DESTINY-R): Design and protocols. *BMC Neurol* 2012;12:115.
  12. Takeuchi S, Wada K, Nagatani K, Nagata I. Decompressive hemicraniectomy for spontaneous intracerebral hemorrhage. *Neurosurg Focus* 2013;34:E5.
  13. Yang XF, Wen L, Shen F, Li G, Lou R, Liu WG, *et al.* Surgical complications secondary to decompressive craniectomy in patients with a head injury: A series of 108 consecutive cases. *Acta Neurochir (Wien)* 2008;150:1241-7.
  14. Wagner S, Schnippering H, Aschoff A, Koziol JA, Schwab S, Steiner T. Suboptimum hemicraniectomy as a cause of additional cerebral lesions in patients with malignant infarction of the middle cerebral artery. *J Neurosurg* 2001;94:693-6.
  15. Treadwell SD, Thanvi B. Malignant middle cerebral artery (MCA) infarction: Pathophysiology, diagnosis and management. *Postgrad Med J* 2010;86:235-42.
  16. Subramaniam S, Hill MD. Decompressive hemicraniectomy for malignant middle cerebral artery infarction: An update. *Neurologist* 2009;15:178-84.
  17. Walz B, Zimmermann C, Böttger S, Haberl RL. Prognosis of patients after hemicraniectomy in malignant middle cerebral artery infarction. *J Neurol* 2002;249:1183-90.
  18. Chung J, Bang OY, Lim YC, Park SK, Shin YS. Newly suggested surgical method of decompressive craniectomy for patients with middle cerebral artery infarction. *Neurologist* 2011;17:11-5.

Copyright of Annals of Indian Academy of Neurology is the property of Wolters Kluwer India Pvt Ltd and its content may not be copied or emailed to multiple sites or posted to a listserv without the copyright holder's express written permission. However, users may print, download, or email articles for individual use.