

APOSTEL 2.0 Recommendations for Reporting Quantitative Optical Coherence Tomography Studies

Aykut Aytulun, MD,* Andrés Cruz-Herranz, MD, PhD,* Orhan Aktas, MD, Laura J. Balcer, MD, Lisanne Balk, PhD, Piero Barboni, MD, Augusto Azuara Blanco, MD, Peter A. Calabresi, MD, Fiona Costello, MD, Bernardo Sanchez-Dalmau, MD, PhD, Delia Cabrera DeBuc, PhD, Nicolas Feltgen, MD, Robert P. Finger, MD, PhD, Jette Lautrup Frederiksen, MD, DMSci, Elliot Frohman, MD, Teresa Frohman, MD, David Garway-Heath, MD, Iñigo Gabilondo, MD, PhD, Jennifer S. Graves, MD, PHD, MAS, Ari J. Green, MD, Hans-Peter Hartung, MD, FRCP, Joachim Havla, MD, Frank G. Holz, MD, Jaime Imitola, MD, Rachel Kenney, MPhil, Alexander Klistorner, PhD, Benjamin Knier, MD, Thomas Korn, MD, Scott Kolbe, MD, Julia Krämer, MD, Wolf A. Lagrèze, MD, Letizia Leocani, MD, PhD, Oliver Maier, MD, Elena H. Martínez-Lapiscina, MD, Sven Meuth, MD, Olivier Outteryck, MD, Friedemann Paul, MD, Axel Petzold, MD, PhD, FRCP, Gorm Pihl-Jensen, MD, Jana Lizrova Preiningerova, MD, PhD, Gema Rebolleda, MD, PhD, Marius Ringelstein, MD, Shiv Saidha, MD, Sven Schippling, MD, Joel S. Schuman, MD, Robert C. Sergott, MD, Ahmed Toosy, MD, Pablo Villoslada, MD, Sebastian Wolf, MD, E. Ann Yeh, MD, Patrick Yu-Wai-Man, PhD, FRCOphth, FRCPath, Hanna G. Zimmermann, PhD, Alexander U. Brandt, MD,† and Philipp Albrecht, MD†

Correspondence

Dr. Albrecht
phil.albrecht@gmail.com

Neurology® 2021;97:68-79. doi:10.1212/WNL.00000000000012125

Abstract

Objective

To update the consensus recommendations for reporting of quantitative optical coherence tomography (OCT) study results, thus revising the previously published Advised Protocol for OCT Study Terminology and Elements (APOSTEL) recommendations.

Methods

To identify studies reporting quantitative OCT results, we performed a PubMed search for the terms “quantitative” and “optical coherence tomography” from 2015 to 2017. Corresponding

*These authors contributed equally as first authors.

†These authors contributed equally as senior authors.

From the Department of Neurology, Medical Faculty (A.A., O.A., H.-P.H., O.M., S.M., M.R., P.A.), Heinrich-Heine University Düsseldorf, Germany; Department of Neurology (A.C.-H., A.J.G.), University of California San Francisco; Departments of Neurology, Population Health, and Ophthalmology (L.J.B., R.K.), NYU Grossman School of Medicine, New York, NY; Muller Institute (L.B.), Centre for Research on Sports in Society, Utrecht, the Netherlands; Scientific Institute San Raffaele (P.B.), Milan, Italy; Centre for Public Health (A.A.B.), Queen's University Belfast, Northern Ireland, UK; Division of Neuroimmunology (P.A.C., S. Saidha), Johns Hopkins University, Baltimore, MD; Departments of Clinical Neurosciences and Surgery (F.C.), University of Calgary, Alberta, Canada; Institut d'Investigacions Biomediques August Pi i Sunyer (IDIBAPS) and Hospital Clinic (B.S.-D., E.H.M.-L., P.V.), University of Barcelona, Spain; Bascom Palmer Eye Institute (D.C.D.), University of Miami Miller School of Medicine, FL; Department of Ophthalmology (N.F.), University Medical Center, Göttingen; Department of Ophthalmology (R.P.F., F.G.H.), University of Bonn, Germany; Department of Neurology (J.L.F., G.P.-J.), Rigshospitalet Glostrup and University of Copenhagen, Denmark; Laboratory of Neuroimmunology (E.F., T.F.), Stanford University School of Medicine, CA; Institute of Ophthalmology (D.G.-H.), National Institute for Health Research (NIHR) Biomedical Research Centre at Moorfields Eye Hospital NHS Foundation Trust and UCL Institute of Ophthalmology (D.G.-H.), London, UK; Biocruces Bizkaia Health Research Institute (I.G.), Barakaldo, Spain; Department of Neurosciences (J.S.G.), University of California, San Diego; Brain and Mind Centre (H.-P.H.), University of Sydney, Australia; Department of Neurology (H.-P.H.), Medical University of Vienna, Austria; Institute of Clinical Neuroimmunology (J.H.), LMU Hospital, Ludwig-Maximilians Universität München, Germany; UConn Health Comprehensive MS Center, Division of Multiple Sclerosis and Neuroimmunology, Department of Neurology (J.I.), University of Connecticut School of Medicine, Farmington; Faculty of Medicine and Health Sciences (A.K.), Macquarie University, Sydney, Australia; Department of Neurology (B.K., T.K.), Klinikum rechts der Isar, School of Medicine, Technical University of Munich, Germany; Department of Medicine and Radiology (S.K.), University of Melbourne, Australia; Department of Neurology with Institute of Translational Neurology (J.K.), University of Münster; Eye Center, Medical Center, Faculty of Medicine (W.A.L.), University of Freiburg, Germany; Experimental Neurophysiology Unit (L.L.), Institute of Experimental Neurology (INSPE), IRCCS San Raffaele, University Vita-Salute San Raffaele, Milan, Italy; Lille Neurosciences & Cognition (O.O.), Univ Lille, Inserm, CHU Lille, U1172-LiNCog (IPARC), France; Experimental and Clinical Research Center (F.P., H.G.Z., A.U.B.), Max Delbrück Center for Molecular Medicine and Charité-Universitätsmedizin Berlin, corporate member of Freie Universität Berlin, Humboldt-Universität zu Berlin, and Berlin Institute of Health, Germany; Moorfields Eye Hospital (A.P.), The National Hospital for Neurology and Neurosurgery, Queen Square, UCL Institute of Neurology, London, UK; Neuro-ophthalmology Expert Center (A.P.), Amsterdam UMC, the Netherlands; Department of Neurology, First Faculty of Medicine (J.L.P.), Charles University and General University Hospital in Prague, Czech Republic; Department of Ophthalmology (G.R.), Ramon y Cajal Hospital, Medicine University of Alcalá, Madrid, Spain; Department of Neurology (M.R.), Center for Neurology and Neuropsychiatry, LVR-Klinikum, Heinrich-Heine-University Düsseldorf, Germany; Department of Neurology (S. Schippling), University Hospital Zurich, Switzerland; Departments of Ophthalmology, Neuroscience, and Physiology (J.S.S.), NYU Langone Health, NYU Grossman School of Medicine, New York; Departments of Biomedical Engineering, Electrical and Computer Engineering (J.S.S.), NYU Tandon School of Engineering, Brooklyn, NY; Thomas Jefferson University Medical College (R.C.S.), Philadelphia, PA; Queen Square MS Centre, Department of Neuroinflammation (A.T.), UCL Institute of Neurology, University College London, UK; Departments of Ophthalmology and Clinical Research (S.W.), Bern University Hospital, University of Bern, Switzerland; Division of Neurology, Department of Pediatrics (E.A.Y.), Hospital for Sick Children, Division of Neurosciences and Mental Health SickKids Research Institute, University of Toronto, Canada; Department of Clinical Neurosciences (P.Y.-W.-M.), University of Cambridge; Moorfields Eye Hospital (P.Y.-W.-M.), London, UK; University of California (A.U.B.), Irvine; and IMSVISUAL (A.A., A.C.-H., O.A., L.J.B., L.B., P.A.C., F.C., J.L.F., E.F., T.F., I.G., J.S.G., A.J.G., H.-P.H., J.H., J.I., R.K., A.K., B.K., T.K., J.K., L.L., E.H.M.-L., S.M., O.O., F.P., A.P., G.P.-J., J.L.P., M.R., S. Saidha, S. Schippling, R.C.S., P.V., E.A.Y., H.G.Z., A.U.B., P.A.), International Multiple Sclerosis Visual System Consortium, Middleton, WI.

Go to [Neurology.org/N](https://www.neurology.org/N) for full disclosures. Funding information and disclosures deemed relevant by the authors, if any, are provided at the end of the article.

The Article Processing Charge is funded by the authors.

This is an open access article distributed under the terms of the Creative Commons Attribution License 4.0 (CC BY), which permits unrestricted use, distribution, and reproduction in any medium, provided the original work is properly cited.

Glossary

APOSTEL = Advised Protocol for OCT Study Terminology and Elements; **GRADE** = Grading of Recommendations Assessment, Development and Evaluation; **OCT** = optical coherence tomography; **OCT-A** = optical coherence tomography angiography.

authors of the identified publications were invited to provide feedback on the initial APOSTEL recommendations via online surveys following the principle of a modified Delphi method. The results were evaluated and discussed by a panel of experts and changes to the initial recommendations were proposed. A final survey was recirculated among the corresponding authors to obtain a majority vote on the proposed changes.

Results

A total of 116 authors participated in the surveys, resulting in 15 suggestions, of which 12 were finally accepted and incorporated into an updated 9-point checklist. We harmonized the nomenclature of the outer retinal layers, added the exact area of measurement to the description of volume scans, and suggested reporting device-specific features. We advised to address potential bias in manual segmentation or manual correction of segmentation errors. References to specific reporting guidelines and room light conditions were removed. The participants' consensus with the recommendations increased from 80% for the previous APOSTEL version to greater than 90%.

Conclusions

The modified Delphi method resulted in an expert-led guideline (evidence Class III; Grading of Recommendations, Assessment, Development and Evaluations [GRADE] criteria) concerning study protocol, acquisition device, acquisition settings, scanning protocol, funduscopy imaging, postacquisition data selection, postacquisition analysis, nomenclature and abbreviations, and statistical approach. It will be essential to update these recommendations to new research and practices regularly.

Increases in the numbers of quantitative optical coherence tomography (OCT) studies have raised the need for consistent and coherent standardized reporting recommendations. In 2016, the Advised Protocol for OCT Study Terminology and Elements (APOSTEL) recommendations were published to provide a 9-point checklist of relevant aspects for reporting quantitative retinal OCT studies.¹ The original APOSTEL recommendations were conceived as expert opinion (level D evidence according to the Grading of Recommendations Assessment, Development and Evaluation [GRADE] working group criteria; gradeworkinggroup.org) from discussions among the authors, the IMSVISUAL consortium (imsvisual.org), and consideration of the literature.² Without a formal consensus-building approach, and without involving a broader audience, further validation was warranted. We aimed to revise and achieve consensus on these recommendations by using a modified Delphi method, including a larger group of OCT scientists and clinicians, in a formal procedure to review the consensus and develop level C evidence-based guidelines (GRADE criteria).³ The long-term goal was to improve the reproducibility and interoperability of OCT studies for retinal and neuro-ophthalmology diseases.

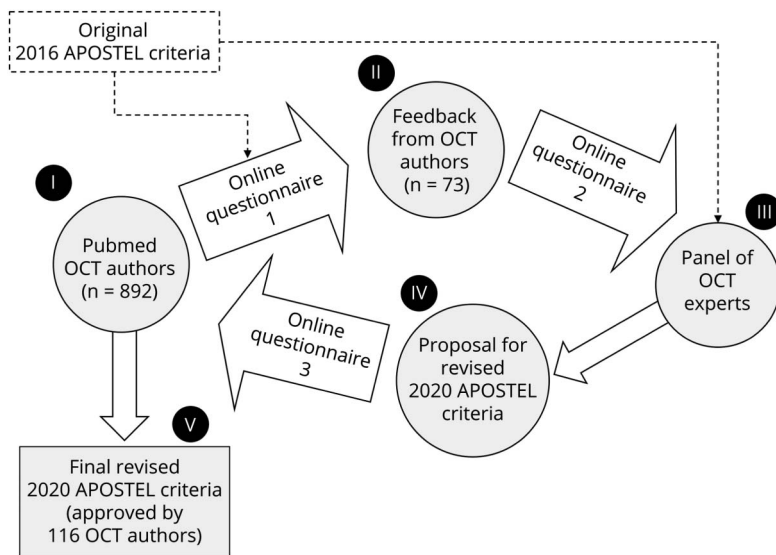
Methods

In order to identify experts in the field while minimizing the risk of selection bias, we chose to contact corresponding authors of studies reporting quantitative retinal OCT results published within 24 months prior to our initial survey by email. A total of 892 authors of 1,189 publications were identified by a PubMed search (performed

3 July 2017) using the search terms “quantitative” and “optical coherence tomography” for 2015 to 2017. The Delphi method is a systematic, multistage survey to obtain consensus on a specified question. The process involves multiple rounds of questionnaires presented to participants. The responses are analyzed by a panel of experts and fed back to participants and assessed for consensus.⁴ Most of the members of the panel of experts were also corresponding authors of quantitative retinal OCT studies and were therefore also invited to participate in the survey. Following the consensus-building procedure of a modified Delphi method (figure 1), we conducted the following steps:

1. We contacted all corresponding authors of the identified publications and asked them to evaluate and give feedback on the initial APOSTEL recommendations. The participants were asked about their agreement on each item of the recommendations, rating from 1 (full disagreement) to 4 (full approval). Participants were given the opportunity to provide comments. In a blinded fashion, we collected feedback and suggestions using a free online survey via Google Forms (initial questionnaire; raw data of survey results can be obtained from the corresponding author upon qualified request).
2. We then formed a panel of 54 international experts who gathered at congress meetings and during 4 rounds of telephone conferences. The aggregated results of the initial questionnaire were reviewed online through a second questionnaire by the panel, who also revised the original APOSTEL recommendations and proposed a list of changes.

Figure 1 Modified Delphi Method



The modified Delphi method is described as a consensus-building process. We contacted 892 authors of quantitative (optical coherence tomography [OCT]) studies identified by PubMed (I) using an online survey, in which feedback on the original Advised Protocol for OCT Study Terminology and Elements (APOSTEL) 2016 criteria was requested. The feedback of the 73 responding OCT authors was analyzed by a panel of experts (II) and changes to the APOSTEL recommendations were proposed (III). A revised version (IV) was proposed to the OCT authors (n = 116), who approved the revisions by majority vote, which led to the final revised 2020 APOSTEL criteria (V).

3. This list was then reviewed in a second Delphi round by the original group of corresponding authors through a third online questionnaire (Google Forms). In this last Delphi round, the participants were given the opportunity to approve or reject the final list of suggestions of the panel of experts by majority vote.

Results

Initial Questionnaire: Survey About the Initial APOSTEL Recommendations Among Corresponding Authors

Seventy-three (8%) of the 892 contacted corresponding authors of quantitative OCT studies completed the first online questionnaire and provided feedback, the majority of these being ophthalmologists (71%), followed by neurologists (10%) and neuro-ophthalmologists (10%). Eighty percent of participants agreed with the recommendations as they were published and 95% planned to adhere to the recommendations in future publications. At the same time, 64% stated having reported their previous research with less detail than suggested.

Second Questionnaire: Consensus Building With the Panel of Experts

Based on the feedback obtained during the first survey, the panel of 54 experts drafted a list of 15 suggested changes to the original APOSTEL recommendations. Twelve (80%) of these suggestions (see below) were accepted through the second questionnaire, while proposals already covered in the original recommendations or to include OCT angiography (OCT-A) were rejected. With this feedback, we generated a revised version of the APOSTEL recommendations with an updated 9-point checklist.

Third Questionnaire: Second Delphi Round With Corresponding Authors

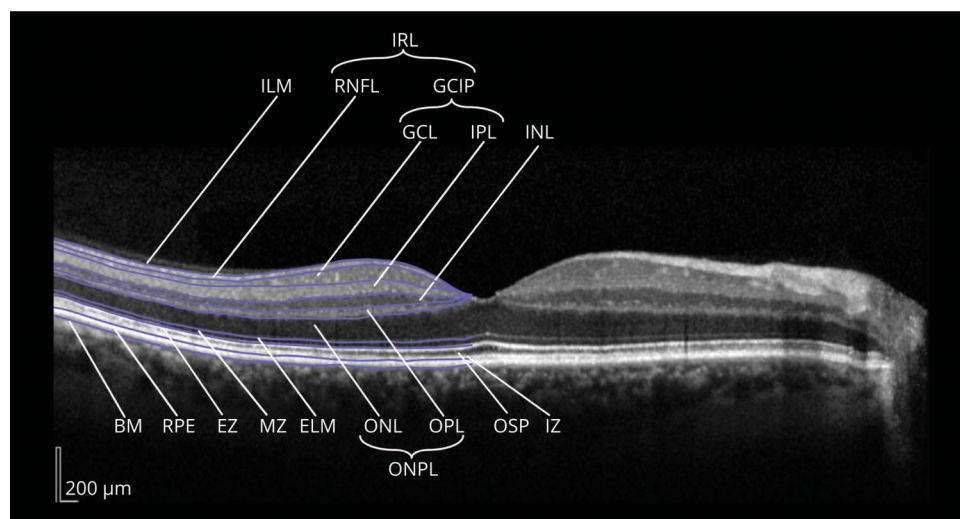
A total of 116 (13%) of the 892 corresponding authors responded to the third survey. Among them, 53% were ophthalmologists, 35% neurologists, and 12% non-MD researchers. The overall acceptance of the proposed changes was over 95%, with the only exception of the recommendation to report the pixel to millimeter ratio and the image format if the images are exported from the device for analysis, which was accepted by 84% of the authors.

Summary of Revisions

After the modified Delphi process for consensus building, we decided to maintain the initial recommendations of stating the acquisition protocol and imaging modalities and addressing concomitant eye pathologies with the exact scanning protocol. The changes made to the original APOSTEL recommendations checklist are highlighted in the table and summarized below:

1. As already addressed in correspondence to the initial recommendations,⁵ we harmonized the nomenclature of the outer retinal layers to match the 2014 consensus article by Staurenghi et al.⁶ (figure 2).
2. We removed references to specific reporting guidelines to avoid favoring any guidelines or omitting relevant recommendations.
3. When utilized, we suggest reporting device-specific features (e.g., enhanced depth imaging, swept-source OCT, adaptive optics).
4. We added the exact area of measurement (e.g., analysis grids) to the description of volume scans.
5. We added a commentary regarding the importance of addressing potential bias in manual segmentation or manual correction of segmentation errors (masking). In several comments, concerns were raised regarding the

Figure 2 Consensus Nomenclature for Retinal Structures



The different layers (and their boundaries) are illustrated in a central horizontal spectral-domain optical coherence tomography scan through the middle of the fovea. Retinal structures and layers: BM = Bruch membrane; ELM = external limiting membrane; EZ = ellipsoid zone (inner and outer segment junction); GCL = ganglion cell layer; ILM = inner limiting membrane; INL = inner nuclear layer; IPL = inner plexiform layer; IZ = interdigitation zone; MZ = myoid zone; ONL = outer nuclear layer; OPL = outer plexiform layer; OSP = outer segment of the photoreceptors; RNFL = retinal nerve fiber layer; RPE = retinal pigment epithelium. Compound layers: GCLIP = ganglion cell and inner plexiform layer (composite of macular GCL and IPL); IRL = inner retinal layers (composite of macular RNFL, GCL, and IPL); ONPL = outer nuclear and plexiform layer (composite of ONL and OPL). Copyright by IMSVISUAL and licensed under CC-BY-4.0 for this publication (imsvisual.org/resources/media).

length of the methodology section of articles that fully adhered to the APOSTEL recommendations. In case of limited word count availability, we now advise submitting the exact OCT methodology as supplementary material, if permitted.

- Another issue raised by several comments was concerning the relevance of some of the details to be reported regarding the acquisition setting, namely the room lighting conditions and whether pupils were dilated. The panel of experts agreed that reporting the ambient lighting condition is likely to be of low clinical importance, although shaded room lighting is suggested. However, off-axis beam placement could affect the results of OCT imaging studies, and the risk for this phenomenon increases with pupil dilation and is greater for the outer retinal layers (outer plexiform layer/outer nuclear layer) compared to the inner retinal layers (peripapillary retinal nerve fiber layer to inner nuclear layer).⁷ Oberwahrenbrock and colleagues⁸ showed that the greatest error is for the outer retinal layers. Therefore, pupil dilation is relevant because it can directly affect quantitative OCT measures. We thus omitted room light conditions but retained pupil dilation.

Discussion

The formal consensus-building approach of a modified Delphi method was used to revise the APOSTEL recommendations for the reporting of quantitative OCT studies.

We observed a high consensus of the participants already with the initial APOSTEL recommendations in the first survey. The majority of the participants acknowledged the need for guidance.

Whereas the original APOSTEL recommendations were conceived by a panel dominated by neurologists, a more heterogeneous mix of specialties, with broader expertise, contributed to this new version, the majority being ophthalmologists. Ninety-seven percent of all participants agreed that the APOSTEL 2.0 guidelines should apply to all studies reporting on quantitative retinal OCT research and not be restrained to certain disorders or disciplines. Furthermore, choosing to identify the experts to be addressed by the survey as the corresponding authors of relevant research articles based on a PubMed search assured a broad consensus-building approach, eliminating the selection bias typically immanent to expert consortia. However, there was a low response rate⁹: 8% of the contacted corresponding authors responded to the first round of the survey and 13% to the second round. Possible explanations for this limitation may include the fact that corresponding authors are senior supervisors or principal investigators and are not necessarily as involved in the technical details and specifications addressed by the APOSTEL recommendations. Likewise, there are time constraints to consider. This can be viewed as a limitation of the study but we have to assume that those who participated in the survey were knowledgeable about the matter and contact details for the first authors or technicians involved in these studies were not available.

The modified Delphi method tends to eliminate extreme (but possibly relevant) positions and steers a middle-course consensus. However, all survey participants were given the opportunity to provide feedback in free text and all comments were critically discussed among the panel of experts. The achieved consensus is based on the opinion of the participants and the panel of experts and therefore it should be regularly counterchecked and revised along with evolving scientific evidence.

Table Nine-Point Advised Protocol for OCT Study Terminology and Elements (APOSTEL) Checklist (Adapted From Cruz-Herranz et al.¹)

Item	Category	Recommendation
1	Study protocol	(1) Describe how many OCT operating sites and graders were included (2) Report the timing of OCT compared to other measurements (same day, delayed) (3) Describe the inclusion and exclusion criteria (4) In case of limited word count, consider submitting the exact methodology as supplementary material ^a
2	Acquisition device	For all OCT devices used, report data on: (1) Manufacturer (2) Model (3) Version (4) Software version (5) Device type (time/spectral domain, swept-source, adaptive optics) ^a
3	Acquisition settings	Clearly describe the settings in which OCT scans were obtained: (1) Pupils dilated before examination (y/n) (2) Number of operators and devices ^b
4	Scanning protocol	Clearly describe the scanning protocol, including: (1) Type of scan (circular, volume, star, line, other) (2) Location (area of interest, macula, optic nerve head, papillomacular bundle, other) (3) Scan parameters (with or without eye tracking) Volume scan: size of scan, area and location of measurement (degrees or millimeters), number of B-scans, alignment of B-scans, number of A-scans per B-scan ^a Radial scan: size of scan area (degrees or millimeters), number of B-scans, alignment of B-scans, number of A-scans per B-scan Ring scan: diameter, A-scans/B-scan, manual or automatic placement of ring or method of centering, depth resolution Line scan: angle, location, number of A-scans, depth resolution
5	Funduscopy imaging	(1) Report other imaging modalities used in addition to OCT (funduscopy, confocal scanning laser ophthalmoscope, retinal angiography, autofluorescence imaging, etc.) (2) Describe acquisition protocol, including: Excitation wavelength Filter sets Number of frames averaged (if applicable) Report device specific features when utilized (e.g., enhanced depth imaging, swept-source OCT, adaptive optics) ^a
6	Postacquisition data selection	Describe image selection process, including: (1) Quality control criteria (2) Postacquisition discard (number and criteria) (3) Eye selection strategy (if applicable)
7	Postacquisition analysis	Describe all postacquisition steps: (1) Software used for processing scans and segmentation (may be different from acquisition software) (2) Which individual retinal layers were segmented/included (3) Method of segmentation (automated, semi-automated, or manual) (4) How potential bias was addressed in the case of manual segmentation or manual correction of automated segmentation errors (masking) ^a (5) Grid used for data extraction (size, shape, selected sections) (6) Pixel to millimeter ratio if images are exported (caliper need) ^a
8	Nomenclature and abbreviations	Define: (1) Anatomical structures analyzed (2) Units of provided measurements (e.g., volume or thickness) (3) Report the number of eyes presenting additional retinal pathology; describe qualitative retinal changes and report exact methodology of quantification ^a
9	Statistical approach	Describe: (1) Statistical models used for the analyses of OCT data (2) Whether data were analyzed by eye or by patient

Abbreviation: OCT = optical coherence tomography.

The modified APOSTEL checklist containing 9 important items when reporting quantitative OCT studies.

^a Changes made to the original APOSTEL recommendations checklist.

^b Room light conditions were removed.

These recommendations do not cover all aspects and techniques possibly amenable to OCT research and are based on expert opinion and a single consensus finding investigation rather than on a systematic review of a large body of literature. Therefore, they are not intended as an indispensable premise for all experimental OCT research. The APOSTEL recommendations are intended for clinical OCT studies using

established techniques and help to provide the necessary comparability between studies.

Some additions suggested during the revision process were not included in the final version as consensus was not reached. One of these suggestions was to incorporate a section on OCT-A. However, the inclusion of details pertaining to OCT-

A in the APOSTEL 2.0 recommendations would be premature. The field of OCT-A, both clinically and academically, is in a phase of rapid evolution and essentially in its infancy. Its use is not well established in routine clinical care in either the fields of ophthalmology or neurology. Interpretation of OCT-A scans across devices is challenging and standardized quantitative OCT-A metrics are lacking or vary across OCT platforms. Moreover, there is a lack of consensus regarding quality control criteria for image acquisition and the implementation of such standards as they pertain to OCT-A. These limitations are likely to change in the future. For these reasons, the evidence and corresponding investigative and clinical recommendations for OCT and OCT-A should remain on separate tracks.

A future revision of the APOSTEL criteria likely will also need to consider the role of artificial intelligence–based data from image analyses.¹⁰

We present revised APOSTEL recommendations based on this investigation using a modified Delphi process that involves a broad group of experts. Therefore, the resulting APOSTEL 2.0 can be considered an expert-led guideline (evidence class C, GRADE criteria) covering all relevant aspects of quantitative retinal OCT research. It will be necessary to update these recommendations to new research and practices regularly.

Acknowledgment

The authors thank the contributors for taking part in the surveys: Solmaz Abdolrahimzadeh (University of Rome Sapienza, Italy); Fahmy Aboulenein-Djamshidian (Department of Neurology, Sozialmedizinisches Zentrum Ost, Donauspital, Vienna, Austria); Kaveh Abri Aghdam (Eye Research Center, The Five Senses Institute, Rassoul Akram Hospital, Iran University of Medical Sciences, Tehran); Asaf Achiron (Wolfson Medical Center Tel Aviv University, Israel); Lillian Aly (Department of Neurology, TU Munich, Germany); Sofia Androudi (Department of Ophthalmology, University of Thessaly, Larissa, Greece); J. Fernando Arevalo (Wilmer Eye Institute at Johns Hopkins University, Baltimore, MD); Jennifer Arnold (Marsden Eye Specialists, Parramatta, Australia); Nicole Balducci (Policlinico Sant'Orsola-Malpighi Bologna, Italy); Francesco Bandello (San Raffaele Scientific Institute, Milan, Italy); Rajani Battu (Centre for Eye Genetics and Research, Bangalore, India); Raed Behbehani (Al-Bahar Ophthalmology Center, Kuwait); Ivan Bodis-Wollner (SUNY Downstate Medical Center, New York, NY); Enrico Borrelli (San Raffaele Scientific Institute, Milan, Italy); Livia Brandao (University of Basel, Switzerland); Josefine Britze (Department of Neurology, Rigshospitalet Glostrup, Copenhagen, Denmark); Troels Brynskov (Department of Ophthalmology, Glostrup Hospital, Copenhagen, Denmark); Pilar Calvo (IIS-Aragon, Miguel Servet University Hospital, Zaragoza, Spain); Adriana Carrá (MS Center Hospital Británico, Buenos Aires, Argentina); Alfonso Casado (Hospital Universitario Marqués de Valdecilla, Santander, Spain); Irini Chatziralli (2nd Department of Ophthalmology, University of Athens, Greece); Fred K. Chen (Centre for Ophthalmology and Visual Science,

The University of Western Australia, Perth); Gemmy Cheung (Singapore National Eye Center, Malaysia); Salomon Cohen (Centre d'Imagerie et de Laser Paris, France); Sara Collorone (NMR Research Unit, Department of Neuroinflammation, Institute of Neurology, Faculty of Brain Sciences, University College London, United Kingdom); Christian Cordano (University of California, San Francisco); Christine A. Curcio (University of Alabama at Birmingham); Floriana De Angelis (Queen Square MS Centre, UCL, London, United Kingdom); Roberto Dell'Omo (University of Molise, Campobasso, Italy); Mauricio Della Paolera (Hospital de Olhos City, São Paulo, Brazil); Nabil El Ayoubi (American University of Beirut and Medical Center/Department of Neurology/Multiple Sclerosis Center, Lebanon); Brian Fernández (Heidelberg Engineering, Franklin, MA); Antonio Ferreras (Miguel Servet University Hospital, University of Zaragoza, Spain); Ignacio Flores-Moreno (Puerta de Hierro University Hospital, Madrid, Spain); K. Bailey Freund (Vitreous Retina Macula Consultants of New York, NY); Simona Frontoni (Department of Systems Medicine, University of Rome "Tor Vergata," Italy); Steven Galetta (New York University Lagone Medical Center, New York); Ignacio García Basterra (Hospital Costa del Sol, Marbella, Spain); Stuart Gardiner (Devers Eye Institute, Portland, OR); Barbara Giambene (Al Emadi Hospital, Doha, Qatar); Steffen Hamann (Department of Ophthalmology, Rigshospitalet, University of Copenhagen, Denmark); Poya Hård af Segerstad (Lund University, Scania, Sweden); Pascal Hasler (Eye Department, University Hospital Basel, Switzerland); Xiangui He (Shanghai Eye Disease Prevention and Treatment Center, Shanghai Eye Hospital, China); Carsten Heinz (Eye Center at St. Franziskus Hospital Muenster, Germany); Yoshio Hirano (Nagoya City University Graduate School of Medical Sciences, Japan); Jyh Yung Hor (Department of Neurology, Penang General Hospital, Malaysia); Ragnhild Wivestad Jansson (University of Bergen, Norway); Jost B. Jonas (Department of Ophthalmology, Medical Faculty Mannheim, Heidelberg University, Germany); Motohiro Kamei (Aichi Medical University, Nagakute, Japan); Niro Kasahara (Santa Casa de São Paulo School of Medical Sciences, Brazil); Amir Kashani (University of Southern California, Los Angeles); Rajiv Khandekar (King Khaled Eye Specialist Hospital, Riyadh, Saudi Arabia); Albert Khouri (Rutgers New Jersey Medical School, Newark); Sidsel Ehlers Klug (Department of Ophthalmology at Aarhus University Hospital, Denmark); Chiara La Morgia (IRCCS Institute of Neurological Sciences of Bologna, University of Bologna, Italy); Timothy Y.Y. Lai (The Chinese University of Hong Kong); Marco Lana-Peixoto (Federal University of Minas Gerais Medical School, Belo Horizonte, Brazil); Paolo Lanzetta (Department of Medicine, University of Udine, Italy); Michael Larsen (Rigshospitalet and University of Copenhagen, Denmark); Eun Ji Lee (Seoul National University Bundang Hospital, South Korea); Shu Yen Lee (Singapore National Eye Centre, Singapore); Theodore Leng (Byers Eye Institute at Stanford, Stanford University School of Medicine, Palo Alto, CA); Nicolas Leveziel (Department of Ophthalmology, CHU Poitiers, France); Kenneth Li (United Christian Hospital,

Hong Kong); Marco Lombardo (Vision Engineering, Rome, Italy); Iuliano Lorenzo (Vita-Salute University, Ospedale San Raffaele Scientific Institute, Milan, Italy); Brandon Lujan (OHSU Casey Eye Institute, Portland, OR); Amir-Hadi Maghzi (Brigham and Women's Hospital, Harvard Medical School, Boston, MA); Maureen Maguire (University of Pennsylvania, Philadelphia); Idit Maharshak (Wolfson Medical Center Holon Israel); Christian Mardin (Department of Ophthalmology, University Erlangen, Germany); Joao Pedro Marques (Department of Ophthalmology, Centro Hospitalar e Universitário de Coimbra [CHUC], Coimbra, Portugal); Battaglia Parodi Maurizio (Vita-Salute San Raffaele University, Milan, Italy); Martin McKibbin (Leeds Teaching Hospitals NHS Trust, West Yorkshire, United Kingdom); Carlos Moreira-Neto (Hospital de Ohos do Paraná, Brazil); Adriana Morgan (Santa Casa de São Paulo School of Medical Sciences, Brazil); Inger Christine Munch (Zealand University Hospital, Roskilde, Denmark); Marion Munk (Department of Ophthalmology, University Hospital Bern, Switzerland); Maria Nilsson (Karolinska Institutet, Solna, Sweden); Susana Noval (La Paz Children Hospital, Madrid, Spain); Frederike Cosima Oertel (Department of Neurology, University of California San Francisco and NCRC & ECRC Charité-Universitätsmedizin Berlin, Germany); Akio Oishi (Kyoto University, Japan); Abdullah Ozkaya (Beyoglu Eye Training and Research Hospital, Istanbul, Turkey); Lekha Pandit (Nitte University, Mangalore, India); Athina Papadopoulou (University Hospital Basel, Switzerland); Isabel Pinilla (Hospital Clinico Universitario Zaragoza, Spain); Giuseppe Querques (San Raffaele Scientific Institute, Milan, Italy); Richard Rosen (New York Eye and Ear Infirmary of Mount Sinai, New York); Richard Roxburgh (Auckland City Hospital, New Zealand); Ana Rita Santos (AIBILI-Association for Innovation and Biomedical Research on Light and Image, Coimbra, Portugal); Kaur Savleen (Department of Ophthalmology, Post Graduate Institute of Medical Education and Research, Chandigarh, India); Reinier O. Schlingemann (Academic Medical Center, University of Amsterdam, the Netherlands); Steffen Schmitz-Valckenberg (Department of Ophthalmology, University of Bonn, Germany); Carlos Schönfeldt-Lecuona (Department of Psychiatry and Psychotherapy III, University Clinic Ulm, Germany); Ori Segal (Sackler School of Medicine, Tel Aviv University, Israel); Oudy Semoun (Centre Hospitalier Intercommunal Creteil, France); Aleksandra Shelankova (Research Institute of Eye Diseases, Moscow, Russia); Elizabeth Silbermann (Oregon Health & Science University, Portland); Travis Smith (Oregon Health & Science University, Portland); Gabor Mark Somfai (Department of Ophthalmology, Semmelweis University, Budapest, Hungary); Elias Sotirchos (Johns Hopkins University, Baltimore, MD); Richard Spaide (Vitreous, Retina, Macula Consultants of New York, New York); Rosa Tang (Eye Wellness Center, Houston, TX); Angelo Tanna (Northwestern University Feinberg School of Medicine, Chicago, IL); Lisa Toto (Ophthalmology Clinic, University "G. d'Annunzio" of Chieti-Pescara, Italy); Umut Duygu Uzunel (Izmir Bozyaka Training and Research Hospital, Turkey); Anneke Van der Walt (Alfred Health, Monash

University, Melbourne, Australia); Clemens Vass (Medical University Vienna, Austria); Gianni Virgili (University of Florence, Italy); Stela Vujosevic (University Hospital Maggiore della Carita', Novara, Italy); Nadia Waheed (Tufts University Medical School, Boston, MA); Maria Waizel (University Hospital Basel, Switzerland); Lihteh Wu (Asociados de Macula Vitreo y Retina de Costa Rica); Yih Chian Yew (Bukit Mertajam Hospital, Malaysia); Glenn Yiu (UC Davis); Hyeong Gon Yu (Seoul National University Hospital, South Korea); Shen Yuan (Tenth Hospital of Tongji University, Shanghai, China); Lucia Ziccardi (IRCCS Fondazione Bietti, Rome, Italy); and Martin Zinkernagel (Department of Ophthalmology, University Hospital Bern, Switzerland).

Study Funding

None.

Disclosure

The authors declare no financial disclosures relevant to the manuscript. Financial disclosures outside of the work submitted include the following: Aykut Aytulun reports no conflicts of interest. Andrés Cruz-Herranz reports grants from the National Multiple Sclerosis Society (FG 20102-A-1) and the UCSF Program for Breakthrough Biomedical Research (PBBR). Orhan Aktas reports grants from the German Research Foundation (DFG, GRK 2578) and the German Ministry of Education and Research (BMBF, FKZ01GI1602B), grants and personal fees from Bayer HealthCare, Biogen, Genzyme, Novartis, and Teva, and personal fees from Alexion, Almirall, MedImmune, Merck Serono, and Roche. Laura Balcer received research funding from Biogen and is Editor-in-Chief of *Journal of Neuro-Ophthalmology*. Lisanne Balk, Piero Barboni, Augusto Azuara Blanco, Peter A. Calabresi, and Fiona Costello report no conflicts of interest. Bernardo Sanchez Dalmau received consulting services or speaking activities from Chiesi, Esteve, and Thea. Delia Cabrera DeBu reports grants from the NIH (P30-EY014801 to the University of Miami), Research to Prevent Blindness Inc. (unrestricted grant to the University of Miami), the NIA, and the Alzheimer's Association. Nicolas Feltgen is consultant to Bayer, Novartis, Roche, Allergan, Alimera, and Heidelberg Engineering. Robert Finger is consultant to Bayer Novartis, Roche, Allergan, Alimera, Santhera, Ellex, Novelon, Inositec, Opthea, and ProQR and reports research funding from Novartis, Heidelberg Engineering, Zeiss, and CentreVue. Jette Lautrup Frederiksen has served on scientific advisory boards for and received funding for travel related to these activities as well as honoraria from Biogen Idec, Merck Serono, Sanofi-Aventis, Teva, Novartis, and Almirall; has received speaker honoraria from Biogen Idec, Teva, and Novartis; has served as advisor on preclinical development for Takeda; and participated in advisory board meetings with Alexion and Chiesi. Elliot Frohman received speaker fees from Novartis, Biogen, Genzyme, and Alexion. Teresa Frohman received advisory board fees from Alexion. avid Garway Heath is supported by the National Institute for Health Research (NIHR) Biomedical Research Centre based

at Moorfields Eye Hospital NHS Foundation Trust and UCL Institute of Ophthalmology, is part of the steering committee of the ANGI network, which is sponsored by Zeiss, and has equipment loans from Topcon. Íñigo Gabilondo reports grants from “Ikerbasque: The Basque Foundation for Science” and Carlos III Health Institute (Ministry of Science and Innovation of Spain) and personal fees and nonfinancial support from Zambon Group and Alter Medica. Jennifer S. Graves, Ari J. Green, and Hans-Peter Hartung report no conflicts of interest. Joachim Havla reports grants for OCT research from Friedrich-Baur-Stiftung and Merck, personal fees and nonfinancial support from Celgene, Merck, Alexion, Novartis, Roche, Santhera, Biogen, Heidelberg Engineering, and Sanofi Genzyme, and nonfinancial support from the Guthy-Jackson Charitable Foundation, all outside the submitted work; and is partially funded by the German Federal Ministry of Education and Research (grant numbers 01ZZ1603 [A–D] and 01ZZ1804 [A–H] [DIFUTURE]). Frank G. Holz reports the following: research grant support: Acucela, Allergan, Apellis, Bayer, Bioeq/Formycon, CenterVue, Ellex, Roche/Genentech, Geuder, Kanghong, NightStarx, Novartis, Optos, and Zeiss; and consultant: Acucela, Allergan, Apellis, Bayer, Boehringer-Ingelheim, Roche/Genentech, Geuder, Grayburg Vision, Lin-Bioscience, Kanghong, Novartis, Pixium Vision, Oxurion, Stealth BioTherapeutics, and Zeiss. Jaime Imitola, Rachel Kenney, and Alexander Klistorner report no conflicts of interest. Benjamin Knier reports a research grant from the Else Kröner-Fresenius-Stiftung and a research grant (Oppenheim grant) and travel support from Novartis outside the submitted work. Thomas Korn reports no conflicts of interest. Scott Kolbe receives project support from Biogen and has received honoraria from Biogen, Merck, and Novartis for work unrelated to this manuscript. Julia Krämer received honoraria for lecturing from Biogen, Novartis, Genzyme, Merck, Mylan, Roche, and Teva, and financial research support from Sanofi Genzyme and Novartis. Wolf A. Lagrèze reports no conflicts of interest. Letizia Leocani reports consulting services or speaking activities from Novartis, Merck, Biogen, Roche, and Almirall. Oliver Maier reports no conflicts of interest. Sven Meuth received honoraria for lecturing and travel expenses for attending meetings from Almirall, Amicus Therapeutics Germany, Bayer Health Care, Biogen, Celgene, Diamed, Genzyme, MedDay Pharmaceuticals, Merck Serono, Novartis, Novo Nordisk, ONO Pharma, Roche, Sanofi-Aventis, Chugai Pharma, QuintilesIMS, and Teva; and his research is funded by the German Ministry for Education and Research (BMBF), Deutsche Forschungsgemeinschaft (DFG), Else Kröner Fresenius Foundation, German Academic Exchange Service, Hertie Foundation, Interdisciplinary Center for Clinical Studies (IZKF) Muenster, German Foundation Neurology, and Almirall, Amicus Therapeutics Germany, Biogen, Diamed, Fresenius Medical Care, Genzyme, Merck Serono, Novartis, ONO Pharma, Roche, and Teva. Elena H. Martínez-Lapiscina is, since 16 April 2019, an employee of the European Medicines Agency (Human Medicines). This article is related to her activity at the Hospital Clinic of Barcelona/IDIBAPS affiliation and, as external activity, it does not represent the views of the

Agency, its committees, or working parties. Before joining the EMA, Dr. Martínez-Lapiscina was granted funds from IDIBAPS and the Clinic of the University of Barcelona Foundation for research and educational purposes, and from the Instituto de Salud Carlos III (Spain) and Fondo Europeo de Desarrollo Regional (JR16/00006; MV17/00021; PI17/01228; RD16/0015/0003, a grant for MS Innovation GMSI, 2016), the Fundació Privada Cellex, the Marató TV3 Charitable Foundation (20142030), Sanofi-Genzyme, and Novartis. Before joining the EMA, Dr. Martínez-Lapiscina received travel support for international and national meetings from Roche and Sanofi-Genzyme and received honoraria for consultancies from Novartis, Roche, and Sanofi. She is a member of the International Multiple Sclerosis Visual System (IMSVISUAL) Consortium. Olivier Outteryck reports grants for research from Novartis and Bayer; a grant for research and personal fees from Biogen-Idec; and funding for travel from Biogen, Genzyme-Sanofi, Merck-Serono, Novartis, and Teva Pharmaceutical Industries, outside the submitted work. Friedemann Paul has served on the scientific advisory boards of Novartis and MedImmune; received speaker honoraria and travel funding from Bayer, Novartis, Biogen, Teva, Sanofi-Aventis/Genzyme, Merck Serono, Alexion, Chugai, MedImmune, and Shire; serves as academic editor of *PLoS ONE* and associate editor of *Neurology*[®]: *Neuroimmunology & Neuroinflammation*; consulted for Sanofi-Genzyme, Biogen, MedImmune, Shire, and Alexion; and received research support from Bayer, Novartis, Biogen, Teva, Sanofi-Aventis/Genzyme, Alexion, Merck Serono, German Research Council, Werth Stiftung of the City of Cologne, German Ministry of Education and Research, Arthur Arnstein Stiftung Berlin, EU FP7 Framework Program, Guthy Jackson Charitable Foundation, and NMSS. Axel Petzold is supported by the National Institute for Health Research (NIHR) Biomedical Research Centre based at Moorfields Eye Hospital NHS Foundation Trust and UCL Institute of Ophthalmology and is part of the steering committee of the ANGI network, which is sponsored by Zeiss; steering committee of the OCTiMS study, which is sponsored by Novartis; and reports speaker fees from Heidelberg-Engineering. Gorm Pihl-Jensen, Jana Lizrova Preiningerova, and Gema Rebolleda report no conflicts of interest. Marius Ringelstein received speaker honoraria from Novartis, Bayer, Roche, Alexion, and Ipsen and travel reimbursement from Bayer Schering, Biogen Idec, Merz, Genzyme, Teva, Grifols, Roche, and Merck, none related to this study. Shiv Saidha has received consulting fees from Medical Logix for the development of CME programs in neurology and has served on scientific advisory boards for Biogen, Genzyme, Genentech Corporation, EMD Serono, and Celgene; is the PI of investigator-initiated studies funded by Genentech Corporation and Biogen Idec; received support from the Race to Erase MS foundation; was the site investigator of a trial sponsored by MedDay Pharmaceuticals; and has received equity compensation for consulting from JuneBrain LLC, a retinal imaging device developer. Sven Schippling reports no conflicts of interest. Joel S. Schuman reports the following: Aerie Pharmaceuticals, Inc., Ocular Therapeutix, Inc., Opticent: consultant/advisor, equity owner; Bright Focus

Foundation, National Eye Institute: grant support; Boehringer Ingelheim, Perfuse, Inc., Regeneron, Inc., SLACK Incorporated: consultant/advisor; Carl Zeiss Meditec: patents/royalty/consultant/advisor; Massachusetts Eye and Ear Infirmary, Massachusetts Institute of Technology, New York University, Tufts University, University of Pittsburgh: intellectual property; Ocugenix: equity owner, patents/royalty; funding from the NIH (Bethesda, MD) R01-EY013178; and an unrestricted grant from Research to Prevent Blindness (New York, NY) to the Department of Ophthalmology, NYU Langone Health, NYU Grossman School of Medicine, New York, NY. Robert C. Sergott reports no conflicts of interest. Ahmed Toosy has received speaker honoraria from Biomedica, Sereno Symposia International Foundation, and Bayer, and meeting expenses from Biogen Idec and Novartis; and was the UK PI for two clinical trials sponsored by MedDay pharmaceutical company (MD1003 in optic neuropathy [MS-ON] and progressive MS [MS-SPI2]). Pablo Villoslada has stocks and has received consultancy fees from Accure Therapeutics SL, Health Engineering SL, QMENTA Inc., Attune Neurosciences Inc., Spiral therapeutics Inc., CLight Inc., and NeuroPrex Inc. Sebastian Wolf has served as a consultant for Allergan, Bayer, Chengdu Kanghong Biotech, Heidelberg Engineering, Novartis, Zeiss, and Roche; and has received grant support from Heidelberg Engineering and Zeiss. E. Ann Yeh reports grants from CMSC, NMSS, MS Society of Canada/MS Scientific Research Foundation, Biogen, CIHR, OIRM, SCN, SickKids Foundation, and CBMH; meeting support from the Guthy Jackson Foundation; and honoraria from MS at the Limits, Excemed, Alexion, and Biogen, all outside the submitted work. Patrick Yu-Wai-Man reports no conflicts of interest. Hanna G. Zimmermann received research grants from Novartis and speaking fees from Bayer Healthcare. Alexander U. Brandt reports no conflicts of interest. Philipp Albrecht reports grants, personal fees, and nonfinancial support from Allergan, Biogen, Celgene, Ipsen, Merz Pharmaceuticals, Merck, Novartis, and Roche; personal fees and nonfinancial support from Bayer Healthcare and Teva; and nonfinancial support from Sanofi-Aventis/Genzyme outside the submitted work. Go to Neurology.org/N for full disclosures.

Publication History

Received by *Neurology* September 25, 2020. Accepted in final form March 15, 2021.

Appendix Authors

Name	Location	Contribution
Aykut Aytulun, MD	Department of Neurology, Medical Faculty, Heinrich-Heine University Düsseldorf, Germany	Study concept and design, acquisition of data, analysis and interpretation, drafting and critical revision of the manuscript for important intellectual content, took part in the panel discussions

Appendix (continued)

Name	Location	Contribution
Andrés Cruz-Herranz, MD, PhD	Department of Neurology, University of California San Francisco	Study concept and design, acquisition of data, analysis and interpretation, drafting and critical revision of the manuscript for important intellectual content, took part in the panel discussions
Orhan Aktas, MD	Department of Neurology, Medical Faculty, Heinrich-Heine University Düsseldorf, Germany	Analysis and interpretation, critical revision of the manuscript for important intellectual content, took part in the panel discussions
Laura J. Balcer, MD	Departments of Neurology, Population Health, and Ophthalmology, NYU Grossman School of Medicine, New York, NY	Analysis and interpretation, critical revision of the manuscript for important intellectual content, took part in the panel discussions
Lisanne J. Balk, PhD	Mulier Institute, Centre for Research on Sports in Society, Utrecht, the Netherlands	Analysis and interpretation, critical revision of the manuscript for important intellectual content, took part in the panel discussions
Piero Barboni, MD	Scientific Institute San Raffaele, Milan, Italy	Analysis and interpretation, critical revision of the manuscript for important intellectual content, took part in the panel discussions
Augusto Azuara Blanco, MD	Centre for Public Health, Queen's University Belfast, Northern Ireland, UK	Analysis and interpretation, critical revision of the manuscript for important intellectual content, took part in the panel discussions
Peter A. Calabresi, MD	Division of Neuroimmunology, Johns Hopkins University, Baltimore, MD	Analysis and interpretation, critical revision of the manuscript for important intellectual content, took part in the panel discussions
Fiona Costello, MD	Departments of Clinical Neurosciences and Surgery, University of Calgary, Alberta, Canada	Analysis and interpretation, critical revision of the manuscript for important intellectual content, took part in the panel discussions
Bernardo Sanchez-Dalmau, MD, PhD	Institut d'Investigacions Biomèdiques August Pi i Sunyer (IDIBAPS) and Hospital Clinic, University of Barcelona, Spain	Analysis and interpretation, critical revision of the manuscript for important intellectual content, took part in the panel discussions
Delia Cabrera DeBuc, PhD	Bascom Palmer Eye Institute, University of Miami Miller School of Medicine, FL	Analysis and interpretation, critical revision of the manuscript for important intellectual content, took part in the panel discussions
Nicolas Feltgen, MD	Department of Ophthalmology, University Medical Center, Göttingen, Germany	Analysis and interpretation, critical revision of the manuscript for important intellectual content, took part in the panel discussions

Appendix (continued)

Name	Location	Contribution
Robert P. Finger, MD, PhD	Department of Ophthalmology, University of Bonn, Germany	Analysis and interpretation, critical revision of the manuscript for important intellectual content, took part in the panel discussions
Jette Laurrup Frederiksen, MD, DMSci	Department of Neurology, Rigshospitalet Glostrup and University of Copenhagen, Denmark	Analysis and interpretation, critical revision of the manuscript for important intellectual content, took part in the panel discussions
Elliot Frohman, MD	Laboratory of Neuroimmunology, Stanford University School of Medicine, CA	Analysis and interpretation, critical revision of the manuscript for important intellectual content, took part in the panel discussions
Teresa Frohman, MD	Laboratory of Neuroimmunology, Stanford University School of Medicine, CA	Analysis and interpretation, critical revision of the manuscript for important intellectual content, took part in the panel discussions
David Garway-Heath, MD	Institute of Ophthalmology, University College London; Moorfields Eye Hospital NHS Foundation Trust, UK	Analysis and interpretation, critical revision of the manuscript for important intellectual content, took part in the panel discussions
Iñigo Gabilondo, MD, PhD	Biocruces Bizkaia Health Research Institute, Barakaldo, Spain	Analysis and interpretation, critical revision of the manuscript for important intellectual content, took part in the panel discussions
Jennifer S. Graves, MD, PHD, MAS	Department of Neurosciences, University of California, San Diego	Analysis and interpretation, critical revision of the manuscript for important intellectual content, took part in the panel discussions
Ari J. Green, MD	Department of Neurology, University of California San Francisco, CA	Analysis and interpretation, critical revision of the manuscript for important intellectual content, took part in the panel discussions
Hans-Peter Hartung, MD, FRCP	Department of Neurology, Medical Faculty, Heinrich-Heine University Düsseldorf, Germany; Brain and Mind Centre, University of Sydney, Australia; Department of Neurology, Medical University of Vienna, Austria	Analysis and interpretation, critical revision of the manuscript for important intellectual content, took part in the panel discussions
Joachim Havla, MD	Institute of Clinical Neuroimmunology, LMU Hospital, Ludwig-Maximilians Universität München, Munich, Germany	Analysis and interpretation, critical revision of the manuscript for important intellectual content, took part in the panel discussions
Frank G. Holz, MD	Department of Ophthalmology, University of Bonn, Germany	Analysis and interpretation, critical revision of the manuscript for important intellectual content, took part in the panel discussions

Appendix (continued)

Name	Location	Contribution
Jaime Imitola, MD	UConn Health Comprehensive MS Center, Division of Multiple Sclerosis and Neuroimmunology, Department of Neurology, University of Connecticut School of Medicine, Farmington	Analysis and interpretation, critical revision of the manuscript for important intellectual content, took part in the panel discussions
Rachel Kenney, MPhil	Departments of Neurology, Population Health and Ophthalmology, NYU Grossman School of Medicine, New York, NY	Analysis and interpretation, critical revision of the manuscript for important intellectual content, took part in the panel discussions
Alexander Klistorner, PhD	Faculty of Medicine and Health Sciences, Macquarie University, Sydney, Australia	Analysis and interpretation, critical revision of the manuscript for important intellectual content, took part in the panel discussions
Benjamin Knier, MD	Department of Neurology, Klinikum rechts der Isar, School of Medicine, Technical University of Munich, Germany	Analysis and interpretation, critical revision of the manuscript for important intellectual content, took part in the panel discussions
Thomas Korn, MD	Department of Neurology, Klinikum rechts der Isar, School of Medicine, Technical University of Munich, Germany	Analysis and interpretation, critical revision of the manuscript for important intellectual content, took part in the panel discussions
Scott Kolbe, MD	Department of Medicine and Radiology, University of Melbourne, Australia	Analysis and interpretation, critical revision of the manuscript for important intellectual content, took part in the panel discussions
Julia Krämer, MD	Department of Neurology with Institute of Translational Neurology, University of Münster, Germany	Analysis and interpretation, critical revision of the manuscript for important intellectual content, took part in the panel discussions
Wolf A. Lagrèze, MD	Eye Center, Medical Center, Faculty of Medicine, University of Freiburg, Germany	Analysis and interpretation, critical revision of the manuscript for important intellectual content, took part in the panel discussions
Letizia Leocani, MD, PhD	Experimental Neurophysiology Unit, Institute of Experimental Neurology (INSPE), IRCCS San Raffaele, University Vita-Salute San Raffaele, Milan, Italy	Analysis and interpretation, critical revision of the manuscript for important intellectual content, took part in the panel discussions
Oliver Maier, MD	Department of Neurology, Medical Faculty, Heinrich-Heine University Düsseldorf, Germany	Analysis and interpretation, critical revision of the manuscript for important intellectual content, took part in the panel discussions

Continued

Appendix (continued)

Name	Location	Contribution
Elena H. Martínez-Lapiscina, MD	Institut d'Investigacions Biomediques August Pi i Sunyer (IDIBAPS) and Hospital Clinic, University of Barcelona, Spain	Analysis and interpretation, critical revision of the manuscript for important intellectual content, took part in the panel discussions
Sven Meuth, MD	Department of Neurology, Medical Faculty, Heinrich-Heine University Düsseldorf, Germany	Analysis and interpretation, critical revision of the manuscript for important intellectual content, took part in the panel discussions
Olivier Outteryck, MD	Univ. Lille, Inserm, CHU Lille, U1172-LiNCog (JPARC)-Lille Neurosciences & Cognition, France	Analysis and interpretation, critical revision of the manuscript for important intellectual content, took part in the panel discussions
Friedemann Paul, MD	Experimental and Clinical Research Center, Max Delbrück Center for Molecular Medicine and Charité-Universitätsmedizin Berlin, corporate member of Freie Universität Berlin, Humboldt-Universität zu Berlin, and Berlin Institute of Health, Germany	Analysis and interpretation, critical revision of the manuscript for important intellectual content, took part in the panel discussions
Axel Petzold, MD, PhD, FRCP	Moorfields Eye Hospital, The National Hospital for Neurology and Neurosurgery, Queen Square, UCL Institute of Neurology, London, UK; Neuro-ophthalmology Expert Center, Amsterdam UMC, the Netherlands	Analysis and interpretation, critical revision of the manuscript for important intellectual content, took part in the panel discussions
Gorm Pihl-Jensen, MD	Department of Neurology, Rigshospitalet Glostrup and University of Copenhagen, Denmark	Analysis and interpretation, critical revision of the manuscript for important intellectual content, took part in the panel discussions
Jana Lizrova Preiningerova, MD, PhD	Department of Neurology, First Faculty of Medicine, Charles University and General University Hospital in Prague, Czech Republic	Analysis and interpretation, critical revision of the manuscript for important intellectual content, took part in the panel discussions
Gema Rebollada, MD, PhD	Department of Ophthalmology, Ramon y Cajal Hospital, Medicine University of Alcalá, Madrid, Spain	Analysis and interpretation, critical revision of the manuscript for important intellectual content, took part in the panel discussions
Marius Ringelstein, MD	Department of Neurology, Center for Neurology and Neuropsychiatry, LVR-Klinikum, Heinrich-Heine-University Düsseldorf, Germany	Analysis and interpretation, critical revision of the manuscript for important intellectual content, took part in the panel discussions
Shiv Saidha, MD	Division of Neuroimmunology, Johns Hopkins University, Baltimore, MD	Analysis and interpretation, critical revision of the manuscript for important intellectual content, took part in the panel discussions

Appendix (continued)

Name	Location	Contribution
Sven Schippling, MD	Department of Neurology, University Hospital Zurich, Switzerland	Analysis and interpretation, critical revision of the manuscript for important intellectual content, took part in the panel discussions
Joel S. Schuman, MD	Departments of Neurology, Population Health and Ophthalmology, NYU Grossman School of Medicine, New York, NY	Analysis and interpretation, critical revision of the manuscript for important intellectual content, took part in the panel discussions
Robert C. Sergott, MD	Thomas Jefferson University Medical College, Philadelphia, PA	Analysis and interpretation, critical revision of the manuscript for important intellectual content, took part in the panel discussions
Ahmed Toosy, MD	Queen Square MS Centre, Department of Neuroinflammation, UCL Institute of Neurology, University College London, UK	Analysis and interpretation, critical revision of the manuscript for important intellectual content, took part in the panel discussions
Pablo Villoslada, MD	Institut d'Investigacions Biomediques August Pi i Sunyer (IDIBAPS) and Hospital Clinic, University of Barcelona, Barcelona, Spain	Analysis and interpretation, critical revision of the manuscript for important intellectual content, took part in the panel discussions
Sebastian Wolf, MD	Department of Ophthalmology and Department of Clinical Research, Bern University Hospital, University of Bern, Switzerland	Analysis and interpretation, critical revision of the manuscript for important intellectual content, took part in the panel discussions
E. Ann Yeh, MD	Division of Neurology, Department of Pediatrics, Hospital for Sick Children, Division of Neurosciences and Mental Health SickKids Research Institute, University of Toronto, Canada	Analysis and interpretation, critical revision of the manuscript for important intellectual content, took part in the panel discussions
Patrick Yu-Wai-Man, PhD, FRCOphth, FRCPath	Department of Clinical Neurosciences, University of Cambridge; Moorfields Eye Hospital, London, UK	Analysis and interpretation, critical revision of the manuscript for important intellectual content, took part in the panel discussions
Hanna G. Zimmermann, PhD	Experimental and Clinical Research Center, Max Delbrück Center for Molecular Medicine and Charité-Universitätsmedizin Berlin, corporate member of Freie Universität Berlin, Humboldt-Universität zu Berlin, and Berlin Institute of Health, Germany	Analysis and interpretation, critical revision of the manuscript for important intellectual content, took part in the panel discussions
Alexander U. Brandt, MD	Experimental and Clinical Research Center, Max Delbrück Center for Molecular Medicine and Charité-Universitätsmedizin Berlin, corporate member of Freie Universität Berlin, Humboldt-Universität zu Berlin, and Berlin Institute of Health, Germany; University of California, Irvine	Analysis and interpretation, study concept and design, acquisition of data, drafting and critical revision of the manuscript for important intellectual content, study supervision, took part in the panel discussions

Appendix (continued)

Name	Location	Contribution
Philipp Albrecht, MD	Department of Neurology, Medical Faculty, Heinrich-Heine University Düsseldorf, Germany	Analysis and interpretation, study concept and design, acquisition of data, drafting and critical revision of the manuscript for important intellectual content, study supervision, took part in the panel discussions

References

1. Cruz-Herranz A, Balk LJ, Oberwahrenbrock T, et al. The APOSTEL recommendations for reporting quantitative optical coherence tomography studies. *Neurology*. 2016;86(24):2303-2309.
2. Balcer LJ, Balk LJ, Brandt AU, et al. The International Multiple Sclerosis Visual System consortium: advancing visual system research in multiple sclerosis. *J Neuroophthalmol*. 2018;38(4):494-501.
3. Guyatt GH, Oxman AD, Schünemann HJ, Tugwell P, Knottnerus A. GRADE guidelines: a new series of articles in the *Journal of Clinical Epidemiology*. *J Clin Epidemiol*. 2011;64(4):380-382.
4. de Villiers MR, de Villiers PJ, Kent AP. The Delphi technique in health sciences education research. *Med Teach*. 2005;27(7):639-643.
5. Cameron JR, Albrecht P, Cruz-Herranz A, Petzold A, Lagreze WA, Brandt AU. The APOSTEL recommendations for reporting quantitative optical coherence tomography studies. *Neurology*. 2016;87(24):1960.
6. Staurengi G, Sadda S, Chakravarthy U, Spaide RF. Proposed lexicon for anatomic landmarks in normal posterior segment spectral-domain optical coherence tomography: the IN•OCT consensus. *Ophthalmology*. 2014;121(8):1572-1578.
7. Balk LJ, de Vries-Knoppert WA, Petzold A. A simple sign for recognizing off-axis OCT measurement beam placement in the context of multicentre studies. *PLoS One*. 2012;7(11):e48222.
8. Oberwahrenbrock T, Weinhold M, Mikolajczak J, et al. Reliability of intra-retinal layer thickness estimates. *PLoS One*. 2015;10(9):e0137316.
9. Cunningham CT, Quan H, Hemmelgarn B, et al. Exploring physician specialist response rates to web-based surveys. *BMC Med Res Methodol*. 2015;15:32.
10. Petzold A, Albrecht P, Balcer L, et al. Artificial intelligence extension of the OSCAR-IB criteria. *Ann Clin Translational Neurol*. Forthcoming.

Subspecialty Alerts by E-mail!


Customize your online journal experience by signing up for e-mail alerts related to your subspecialty or area of interest. Access this free service by clicking on the “My Alerts” link on the home page. An extensive list of subspecialties, methods, and study design choices will be available for you to choose from—allowing you priority alerts to cutting-edge research in your field!

Visit the *Neurology*® Resident & Fellow Website

Click on Residents & Fellows tab at Neurology.org.

Now offering:

- *Neurology*® Resident & Fellow Editorial team information
- “Search by subcategory” option
- E-pearl of the Week
- RSS Feeds
- Direct links to Continuum®, Career Planning, and AAN Resident & Fellow pages
- Recently published Resident & Fellow articles
- Podcast descriptions
- Blogs by Editors and Resident & Fellow team members

 Find *Neurology*® Residents & Fellows Section on Facebook: facebook.com/AANResidentsAndFellows

 Follow *Neurology*® on Twitter: @GreenJournal #NeurologyRF

 Find *Neurology*® Residents & Fellows Section on Instagram: @aanbrain #NeurologyRF

Neurology®

APOSTEL 2.0 Recommendations for Reporting Quantitative Optical Coherence Tomography Studies

Aykut Aytulun, Andrés Cruz-Herranz, Orhan Aktas, et al.
Neurology 2021;97:68-79 Published Online before print April 28, 2021
DOI 10.1212/WNL.0000000000012125

This information is current as of April 28, 2021

Updated Information & Services	including high resolution figures, can be found at: http://n.neurology.org/content/97/2/68.full
References	This article cites 9 articles, 2 of which you can access for free at: http://n.neurology.org/content/97/2/68.full#ref-list-1
Subspecialty Collections	This article, along with others on similar topics, appears in the following collection(s): All Imaging http://n.neurology.org/cgi/collection/all_imaging All Neuro-ophthalmology http://n.neurology.org/cgi/collection/all_neuroophthalmology Retina http://n.neurology.org/cgi/collection/retina
Permissions & Licensing	Information about reproducing this article in parts (figures, tables) or in its entirety can be found online at: http://www.neurology.org/about/about_the_journal#permissions
Reprints	Information about ordering reprints can be found online: http://n.neurology.org/subscribers/advertise

Neurology® is the official journal of the American Academy of Neurology. Published continuously since 1951, it is now a weekly with 48 issues per year. Copyright © 2021 The Author(s). Published by Wolters Kluwer Health, Inc. on behalf of the American Academy of Neurology. All rights reserved. Print ISSN: 0028-3878. Online ISSN: 1526-632X.

