

Posttraumatic Vascular Anomalies in Hand Surgery—A Case-based Approach

Helene Sophie Scheer, MD*
Yara Banz, MD, PhD†
Adriaan O. Grobbelaar, MD*
Esther Vögelin, MD*

Summary: The field of vascular anomalies (VA) has been subject to changes during the last few decades. The current classification of the International Society for the Study of Vascular Anomalies (ISSVA) offers a simple diagnostic structure. Hand surgeons commonly appear to have limited exposure to VA. Already recognized for more than 120 years, pyogenic granuloma (PG) is by far the most commonly described VA by different disciplines with accordingly diverse treatment strategies and theories behind it. Arteriovenous fistula (AVF), venous aneurysms (VAN), and venous malformations (VM) are, however, rare in hand surgery. With a compilation of four illustrative cases of posttraumatic entities such as AVF, VAN, VM, and PG, we would like to highlight possible daily exposure to VA in the general hand surgery practice. We discuss diagnostic and therapeutic options as well as the current literature with focus on posttraumatic VA. (*Plast Reconstr Surg Glob Open* 2021;9:e3802; doi: 10.1097/GOX.0000000000003802; Published online 14 September 2021.)

INTRODUCTION

Vascular anomalies (VA) are a complex topic dating back to the first descriptions by Rudolf Virchow in 1863.¹ The first systematic approach to VA anomalies was presented by Mulliken and Glowacki in 1982.² They differentiated between hemangiomas and vascular malformations. In 1988, the Hamburg Classification offered further differentiation according to the anatomic region involved.³ The latest update in 2018 by the International Society for the Study of Vascular Anomalies (ISSVA) includes a combination of the previous two systems. The classification is simple to understand without previous knowledge of the topic³ (Table 1). However, only nontraumatic VA is considered.

The differentiation between vascular neoplasms and malformations or the umbrella term for “VA” still gives rise to confusion.^{3,4} Usually, this topic is limited to the very last pages in hand surgery text books,⁵ and is given little attention. Furthermore, if the topic is considered at all, it usually focuses on the rare cases treated in the world’s largest centers⁶ without sharing the experience of the more general scientific community. These cases mostly reflect congenital anomalies and, to a

lesser degree, posttraumatic lesions of the hand or the extremities.

Pediatric dermatologists and pediatric surgeons point out that vascular tumors are more common in boys and usually sporadic.⁷ The reports by nonpediatric dermatologists and surgeons report the opposite and focus on adults with a posttraumatic onset of vascular tumors such as the pyogenic granuloma (PG).⁸

In this review, we would like to highlight the often-neglected topic of posttraumatic VA presenting as tumors in the adult population, to improve the knowledge of these entities in the daily practice. Using four illustrative cases, this interesting entity is reappraised to provide more clarity on this generally underdiagnosed but rare problem in hand surgery patients.

CASE 1

The first patient (34 y) suffered from a painful tumor (2 × 2 mm) on the dorsum of the PIP joint of the left index finger (Fig. 1). The tumor appeared after a blunt trauma several months prior and slowly increased in size, with intermittent persistent bleeding. The ultrasonography presented a central intralesional vessel resembling a fountain (Fig. 2). (See Video [online], which displays how the ultrasonography of the granuloma pyogenicum highlights a central intralesional vessel resembling a fountain.) A direct excision was performed as is advised in the current literature.⁹ Histopathology confirmed a

From the *Clinic of Plastic and Hand Surgery, University Hospital, Bern, Switzerland; and †Institute of Pathology, University of Bern, Bern, Switzerland. Bern, Switzerland

Received for publication February 7, 2021; accepted July 12, 2021.

Copyright © 2021 The Authors. Published by Wolters Kluwer Health, Inc. on behalf of The American Society of Plastic Surgeons. This is an open-access article distributed under the terms of the Creative Commons Attribution-Non Commercial-No Derivatives License 4.0 (CCBY-NC-ND), where it is permissible to download and share the work provided it is properly cited. The work cannot be changed in any way or used commercially without permission from the journal.

DOI: 10.1097/GOX.0000000000003802

Disclosure: The authors have no financial interest to declare in relation to the content of this article.

Related Digital Media are available in the full-text version of the article on www.PRSGlobalOpen.com.

Table 1. ISSVA 2018

Vascular Tumors	Vascular Anomalies			
	Simple	Combined†	Of major named vessels	Associated with other anomalies
Benign	Arteriovenous fistula*	CVM, CLM	‡	‡
Locally aggressive or borderline	Arteriovenous malformations*	LVM, CLVM	For example, venous aneurysm	
	Venous malformations	CAVM		
	Capillary malformations	CLAVM		
Malignant	Lymphatic malformations	Others		

The table shows the latest classification of VA given by the ISSVA in the year 2018. The described anomalies in this review are indicated in bold. Due to the focus of the case series the table is presented in this shortened version.

*High-flow lesions.

†Defined as two or more vascular malformations found in one lesion.

‡See details at ISSVA.org.

CAVM, capillary-arteriovenous malformation; CLAVM, capillary-lymphatic-arteriovenous malformation; CLM, capillary-lymphatic malformation; CLVM, capillary-lymphatic-venous malformation; CLVAVM, capillary-lymphatic-venous-arteriovenous malformation; CVAVM, capillary-venous-arteriovenous malformation; CVM, capillary-venous malformation; LVM, lymphatic-venous malformation.

PG (Fig. 3). Due to the lesion’s size and localization on the dorsum of the PIP joint, the wound was closed with a hemi-hatched flap and the further clinical course was uneventful.

CASE 2

The second patient (55 y) sustained a cut from a sushi knife on the proximal radial phalanx of the index finger accompanied by initial profuse bleeding. He treated the injury by local compression without any further exploration of the wound. Scar development was uneventful.

Within 8 months after the trauma, the patient presented progressive swelling proximal to the scar, which was tender on pressure. Due to a palpable whirring and compressible swelling, the patient was referred to an angiologist, who diagnosed an AVF. Sclerotherapy was performed, unfortunately resulting in progressive growth and persistent pain. The patient was subsequently seen for evaluation of surgical excision.

After the clinical examination, which confirmed the swelling and the whirl (Fig. 4), sonography demonstrated the typical bands of an AVF (Fig. 5), proximal to the scar and distal to the swelling. A direct excision of a small AVF was performed under the scar followed by excision of an

ectatic venous vessel (Fig. 6). Histopathological evaluation confirmed an ectatic vessel with the presence of an intravascular PG (Fig. 7). Wound healing was uneventful, and the pain resolved completely.

CASE 3

After carrying six 1.5L water bottles using just the middle finger, a 36-year-old male patient developed a hematoma and small-lacerated wound on the proximal phalanx. During the following 6 months, he developed a progressive swelling with minimal tenderness on the radial side of his proximal interphalangeal joint and the base of the middle phalanx. Because of physical restrictions, the patient sought medical attention (Fig. 8). Sonography suggested an aneurysm of the radial digital artery. The Allen test revealed adequate perfusion from the ulnar and radial side. Because of worsening pain and a probable increase in size, surgical excision of the aneurysm was performed.

Intraoperatively, a vascular tumor was found, which was nourished by a little vascular stalk originating from the digital vein (Fig. 9). The stalk was ligated and the tumor removed without injuring the vein or artery. The tumor was analyzed histopathologically and in addition to the ectatic vein, an intravenous PG was confirmed (Fig. 10). The patient recovered completely without any residual effects.

CASE 4

After increased exertion of the left arm for the duration of 3 months due to immobilization of the right arm following shoulder surgery, a 45-year-old patient developed a swelling of the soft tissue of the intermetacarpal space III/IV, which varied in size depending on the position of the hand and finger. He presented because the swelling prohibited him from wearing his wedding ring and he feared intractable bleeding. A 8mm large swelling was found in the intermetacarpal web space (Fig. 11). Sonography revealed an enlargement of the vein from 4mm to its triple size and a variation in blood flow velocity.

Intraoperative, venous ectasia of the digital vein was found, which was resected (Fig. 12). End-to-end anastomosis was performed to restore venous network (Fig. 12C).

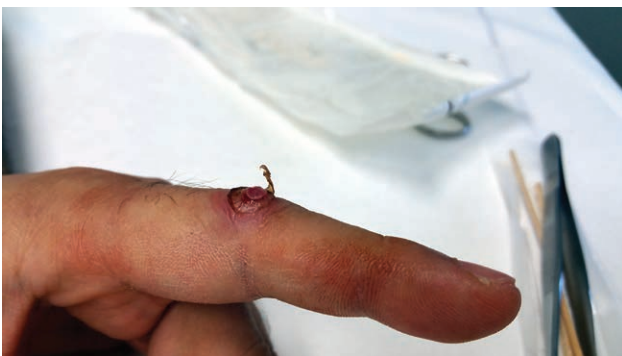

Fig 1. Case 1: A painful tumor presented on the dorsum of the PIP joint of the left index finger. The clinical diagnosis of a granuloma pyogenicum was established.

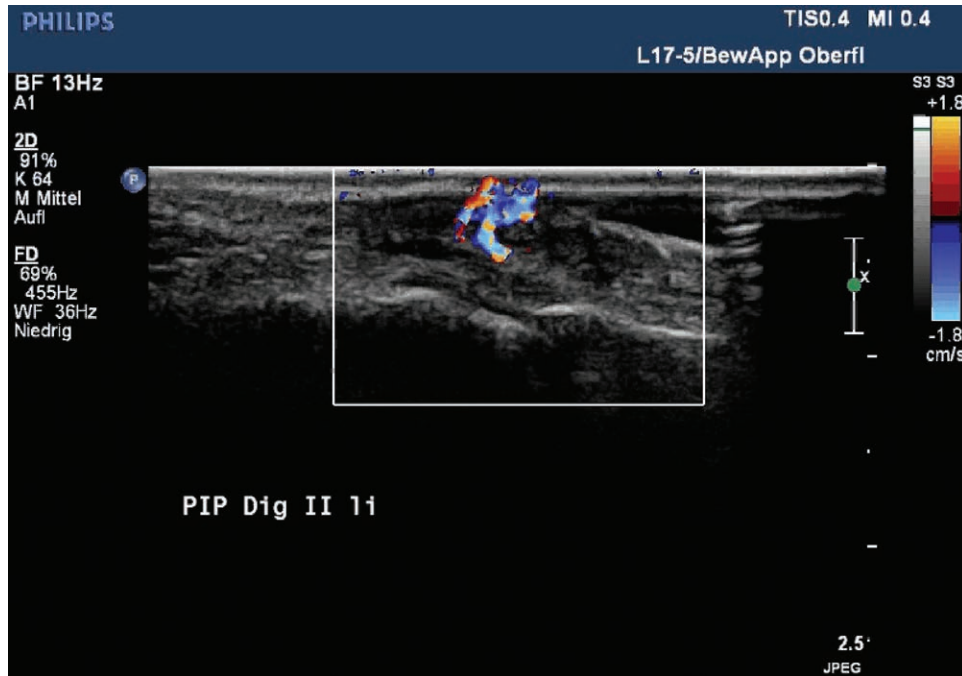


Fig. 2. Case 1: The ultrasonography of the granuloma pyogenicum presented a central intralesional vessel resembling a fountain.

The patient recovered completely without any residual effects. Histopathological work-up showed aneurysmal changes compatible with a venous malformation (Fig. 13).

DISCUSSION

The current literature seems to focus on extraordinary VA cases in the world's biggest centers.⁶ Indeed, clinicians are confronted with VA, without realizing that the most

common VA, the PG, has been known for more than a century in general surgical practice.¹⁰ In contrast to congenital VA, posttraumatic VA is much more common. Despite this fact, the topic is often only touched upon briefly, usually on the very last pages of textbooks, offering little diagnostic or therapeutic help.⁵

Table 1 presents an overview of VA according to the ISSVA to orientate the treating physician. The differentiation between a true neoplasm and a malformation as well as the attribution to the involved vessels facilitates deciding upon the correct treatment algorithm. Posttraumatic onset is not a variable in the ISSVA table. Using these presented illustrative cases, we would like to discuss four

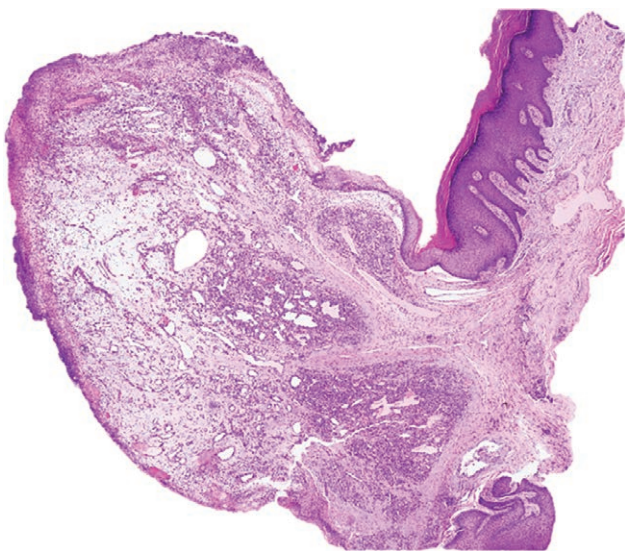


Fig. 3. Hematoxylin and Eosin (H&E) stain, 20x. At the surface of the skin lies a superficially ulcerated protruding proliferation of capillary-like blood vessels within a hyalinized fibrous matrix, presenting a vaguely lobular architecture.

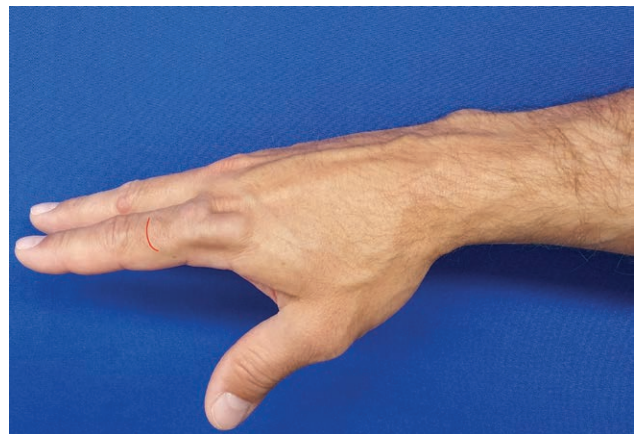


Fig. 4. Case 2: Proximal to the scar, clinical examination confirmed the swelling and the whirl, which the patient recognized after a cut with the sushi knife (marked red).

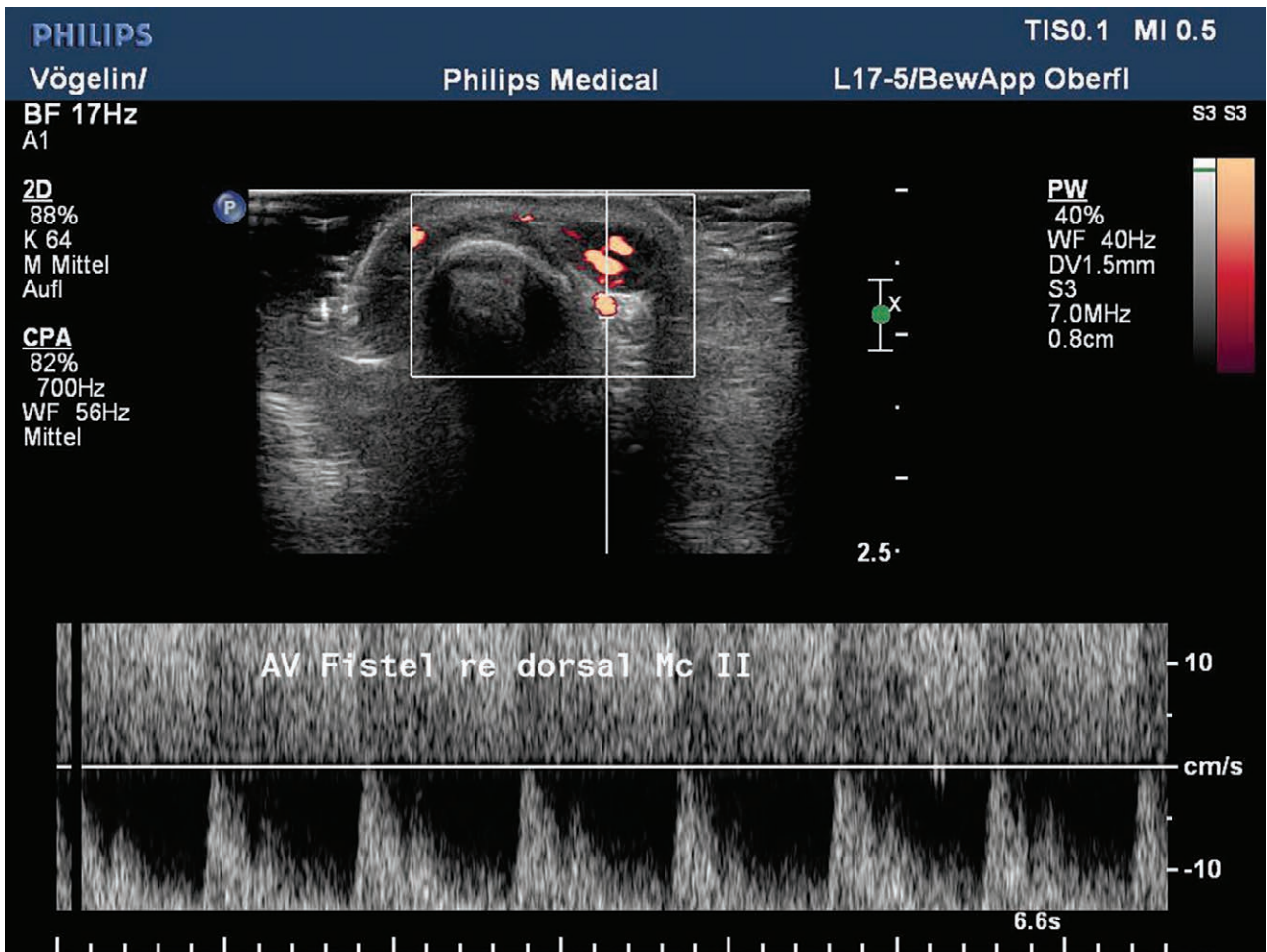


Fig. 5. Case 2: Sonography demonstrates the typical bands of an AVF, proximal to the scar and distal to the swelling.

clinical pictures in more detail: the PG, the AVF, venous ectasia (venous aneurysm), and venous malformation (Fig. 14).

A tumor/swelling originating from an existing vessel which was initially traumatized was the clinical symptom which prompted medical attention in all cases (PG, AVF, ectatic vein with PG, and VAN). This was accompanied by a proliferation of capillary-like blood vessels in three cases [one extravascular (case 1), two intravascular (cases 2 and 3), and one intervascular (case 2)] appearing like active reactions to the prior trauma. Case 4 showed no such

additional feature. In contrast, it developed an ectasia with a dysplastic wall in histology which can be interpreted as a passive reaction.

PYOGENIC GRANULOMA

The PG (cases 1, 2, and 3) is a good example of how the understanding and treatment of VA have changed in the last century. The first description of PG is dated back to 1897 by Poncet and Dor,¹⁰ who initially named it “Botryomycose humaine,” because they suspected a

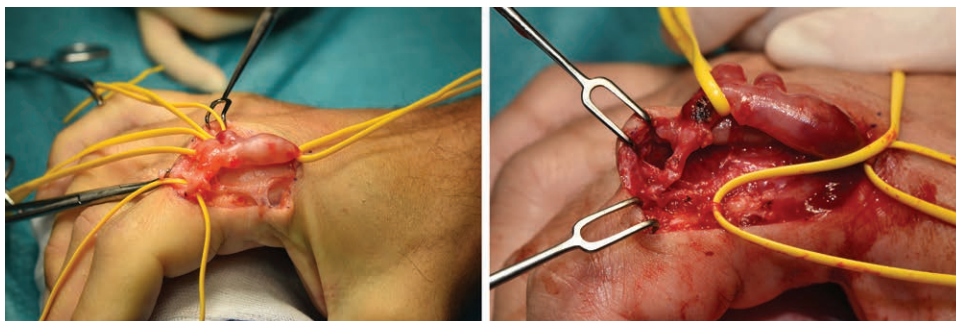


Fig. 6. Case 2: Intraoperative presentation of the AVF and the venous ectasia proximal of the pathologic connection.

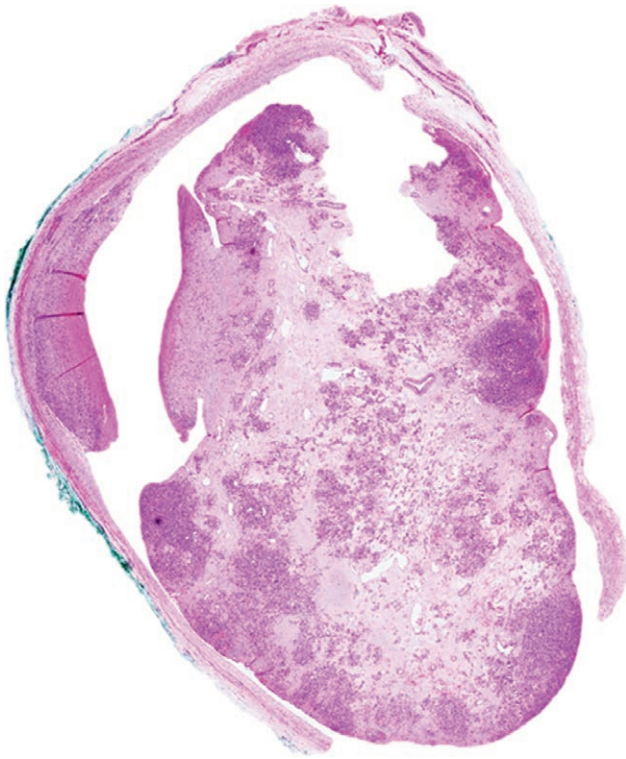


Fig. 7. Hematoxylin and Eosin (H&E) stain, 10x. Within the lumen of a dilated venous blood vessel lies a conglomerate of capillary-like blood vessels within a hyalinized fibrous matrix, presenting a vaguely lobular architecture. The intraluminal surface is very focally ulcerated with adherent thrombotic material.

correlation to the botryomycosis in animals. “Lobular capillary hemangioma”^{11,12} and “granuloma teleangiectaticum” were prominent names for years besides many others.^{13,14} Even though PG is often described as a hemangioma, a distinct histopathological difference between a classical hemangioma and PG exists.¹¹ In 1904, the term granuloma pyogenicum followed,¹⁰ currently termed PG.

PG supposedly constitutes 0.5% of all childhood skin nodules. The data in adults are not as clear. An increased occurrence has been described in pregnancy.¹⁴ Giblin et al⁸ analyzed 408 cases within 10 years. The median age was 40.5 years and 9.5% of the women (46%) were pregnant. Thirty-three percent of the cases

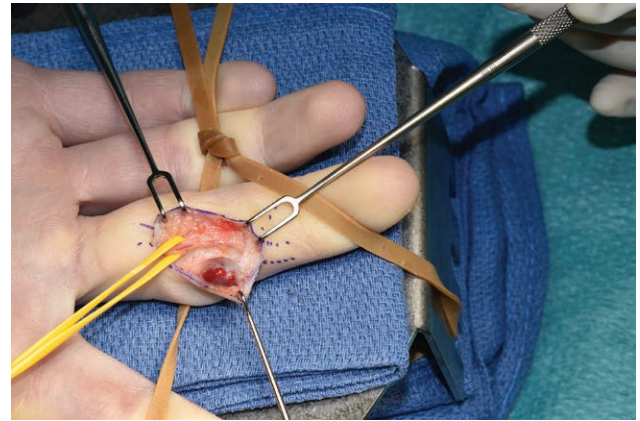


Fig. 9. Case 3: Intraoperatively, a vascular tumor was found, which was nourished by a little vascular stalk originating from the digital vein.

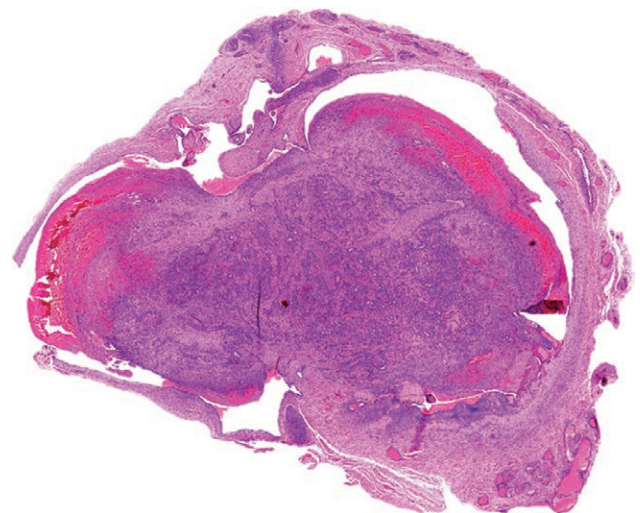


Fig. 10. Hematoxylin and Eosin (H&E) stain, 10x. Within the lumen of a dilated and slightly irregular venous blood vessel lies a conglomerate of capillary-like blood vessels within a fibrous matrix, presenting a vaguely lobular architecture. The intraluminal surface is focally ulcerated with adherent thrombotic material.

were located in the upper limb, mainly on the hand/fingers after trauma of any kind as previous studies also suggested.^{8,13} Studies in children showed a clear

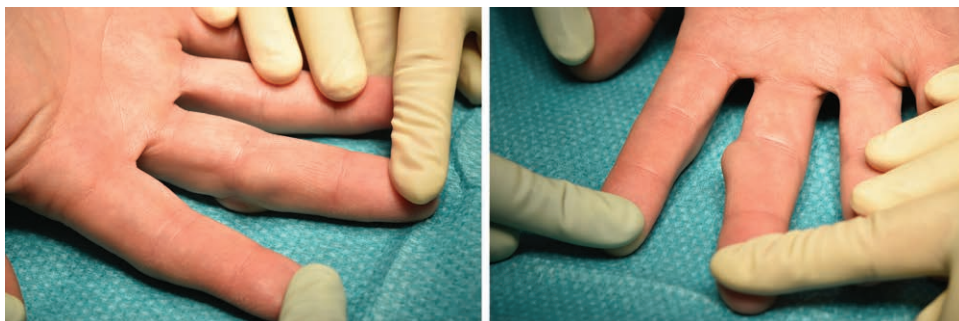


Fig. 8. Case 3: A progressive tumor with minimal tenderness developed on the radial side after minimal trauma 6 months ago.

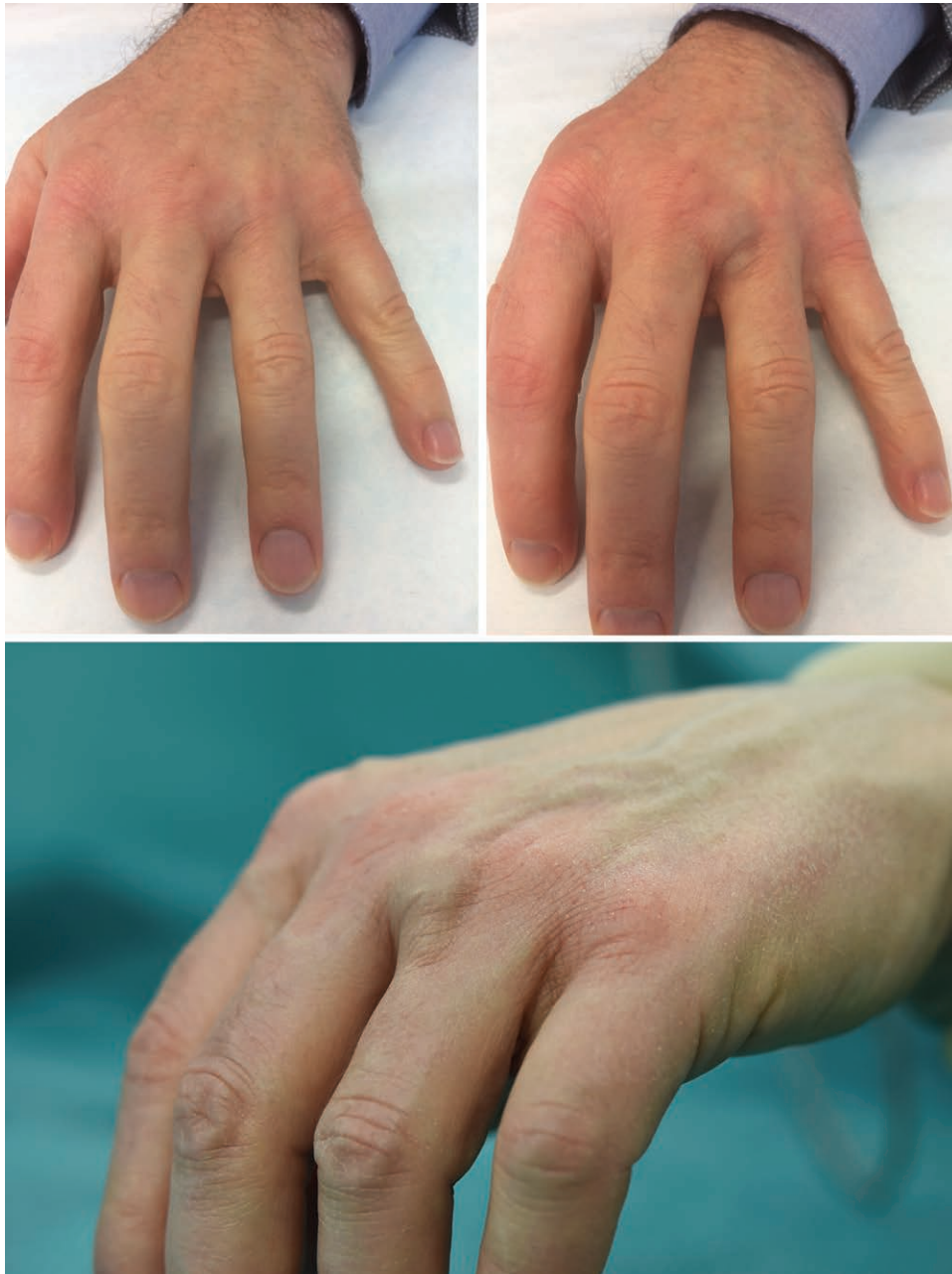

Fig. 11. Case 4: Depending on the position of his hand the patient recognized a swelling in the intermetacarpal space III/IV which disappeared with elevation of the hand.

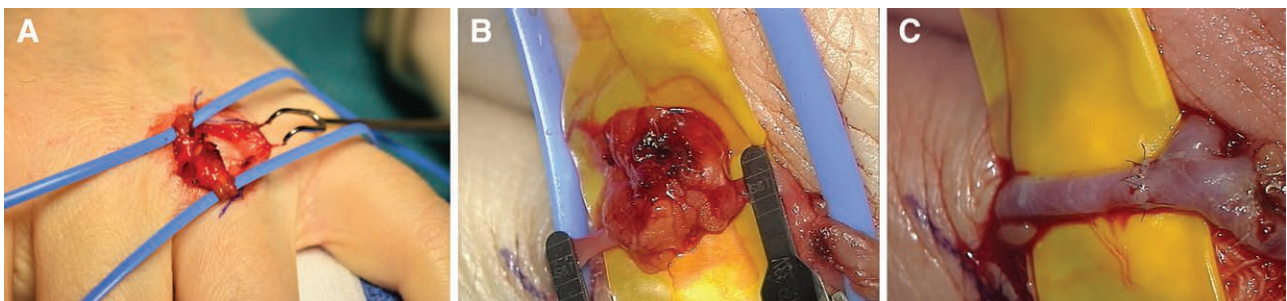

Fig. 12. Case 4: Venous ectasia - Macroscopic versus microscopic evaluation. A and B, Intraoperative, venous ectasia of the digital vein was found. C, End-to-end anastomosis was performed to restore venous network.

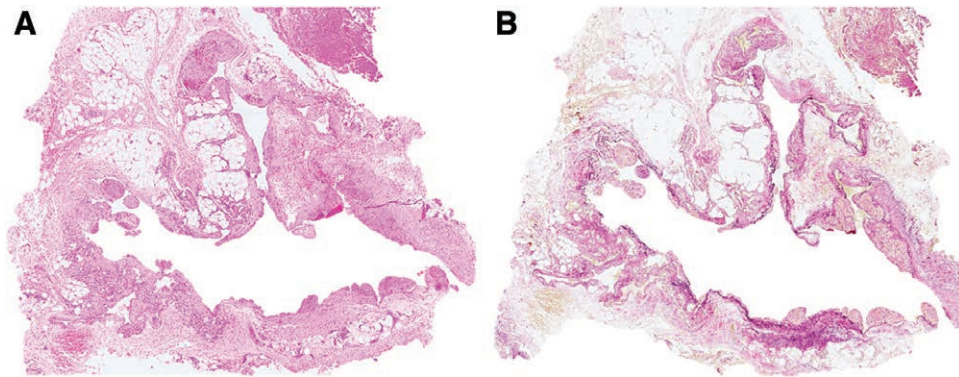


Fig. 13. Hematoxylin and Eosin (H&E) stain (A) and Elastica van Gieson stain (EVG; B), 10x. Within the fatty tissue lies a dilated venous blood vessel presenting with very irregular, focally highly thinned-out, focally fibrosed vascular wall consisting of irregularly spaced and oriented smooth muscle bundles and elastic fibers.

predominance in the head and neck area,¹⁵ which are known to be predisposed to trauma in this age group. Besides trauma and hormonal changes in pregnancy, certain genetic alterations have been found to promote the development of PG.

The FLT4 (Fms-Like Tyrosine Kinase 4) gene may be attributed to impaired wound healing following trauma, which is associated with PG.¹¹ BRAF (isoform B of the gene for rapidly accelerated fibrosarcoma protein) mutations, which play an important role in tumor genesis, may also be found in cases of PG.^{7,14,16}

Additionally, a macroscopic similarity to amelanotic melanoma has been described by Moshe et al.¹⁷ For that reason the authors suggest certain criteria which should prompt surgical excision instead of conservative PG treatment: patient age older than 50 years and size of more than 8mm² size “even if the clinical diagnosis seems ‘obvious.’”¹⁷

A “malignant” potential per se has been described in one single report in which satellite lesions of a PG are taken as proof of malignancy.⁷ According to the current scientific consensus¹⁸ no signs of malignancy were detected in any of our cases.

Treatment aims at local control and often applies locally destructive methods such as the application of silver nitrate or laser treatment.¹⁹ Based on current studies, however, simple excision shows the lowest recurrence rates^{8,9} and provides tissue for histopathological examination.^{17,20}

Intravascular PG (case 2) is a rare but well-described entity,^{12,21–23} commonly regarded as a posttraumatic hyperplastic lesion.²⁴ Although the diagnosis is usually possible following routine histopathological work-up, immunohistochemistry may be used to better visualize and confirm the entity.²³ Changes in the vascular flow are thought to promote the genesis of intravascular PGs.²³ These changes may also occur after blunt trauma.²⁵ Some authors assume a connection between PG and intravascular papillary endothelial hyperplasia or Masson’s tumor, which is a painful tumor also arising in veins after blunt trauma, which could grow to an occluding size.^{25,26} Histopathologically, these two entities may show some overlap and be tricky to diagnose and even occur concomitantly.²⁷ Commonly, however, intravascular PG presents as a proliferation of capillary-like blood vessels with some form of lobular architecture, much like the much more common extravascular kind.


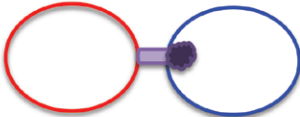


	Case 1	Case 2	Case 3	Case 4
Intraoperative findings	Granulomatous tumor	Arterio-venous fistula (AVF)	Venous ectasia	Venous aneurysm
Configuration				
Histological findings	Pyogenic Granuloma (PG)	AVF and intravascular PG in a vein	Intravenous PG	Venous malformation

Fig 14. Posttraumatic VA. Histopathological examination revealed one common aspect in three of the four cases, namely vascular ectasia—the leading clinical symptom prompting medical attention. Although this was accompanied by a proliferation of capillary-like blood vessels in the first three cases—two of which were intravascular—case 4 showed no such additional feature. Case 4 revealed a dysplastic-appearing venous blood vessel, morphologically resembling a venous malformation (Figs. 11–13).

Typically, intravascular papillary endothelial hyperplasia presents with papillary, hyalinized proliferations lined by plump endothelial cells admixed with fibrin, giving the appearance of more slit-like vascular spaces. This appearance is much more akin to an exaggerated intravascular thrombus in organization.²⁸

TRAUMATIC AVF

An AVF (case 2) is an abnormal “communication between an artery and a vein without an intervening vascular nidus.”²⁹ These communications are not restricted to a certain vessel size or location.

The first report by Hunter in 1757 refers to a post-traumatic origin. An artery and a vein could become fused after transfixion by a cutting instrument.^{30,31} Other authors reported this after war injuries.^{21,32} The mechanism is thought to be inadequate treatment of an arterial injury by local compression and simple wound suture.³²

AVF for dialysis patients represents the most common form of nontraumatic AVF. Cases of posttraumatic AVFs in the hand are rare and are usually described after blunt trauma²¹ in contrast to AVF in large vessels. During the last two decades, there was just one report on posttraumatic AVF of the fingers or hand.³³ However, there are increasing numbers of reports of AVFs at the radial wrist following coronary angiography since 2013.^{34–36} The incidence of AVF following femoral catheterization is less than 1%;³⁷ radial catheterizations are supposedly thought to cause less complications.³⁷ Radial AVFs are mostly managed by hand surgeons in contrast to femoral AVFs that are managed by vascular surgeons.

Our case of posttraumatic AVF (case 3) developed much like dialysis AVFs. “Maturation” in this case leads to significant increase in size over time. Its resection with the dilated vein was unproblematic and cured the patient completely. From the intraoperative point of view, the vein was too dilated to be sclerosed completely without any harm to the more distal vessels so that retrospectively the initial sclerosing therapy was doomed to fail in this setting.

VENOUS ANEURYSM

VAN (cases 3 and 4) could be part of the spectrum of congenital VMs, but posttraumatic onset may be more common.^{38,39} Trauma as well as an enhanced wall shear stress and wall shear stress gradient are thought to cause sacular aneurysms.⁴⁰

In case 4, the patient was forced to increase the use of his left nondominant hand but continued to wear his wedding ring on the left hand, which became too tight due to the overuse of his hand. This compression may have caused trauma to the vessels, curbing blood flow while the fingers are clenched. The persistent use of the nondominant left hand may also increase the risk of accidents. The metacarpal web space area is a vulnerable zone, in particular for digital nerve compressions—the simple habit of wearing a ring may suffice to cause damage to this area.⁴¹

The repetitive venous stasis in the left hand during manual activities below the heart enhances the backflow in the metacarpal web space area and could have aggravated

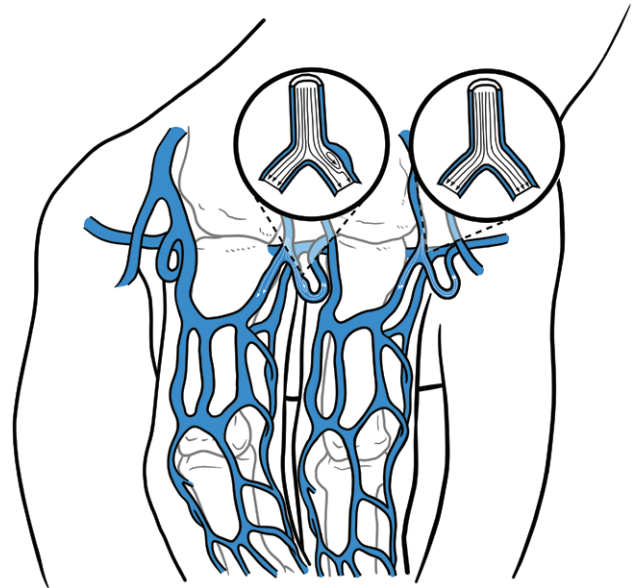


Fig. 15. Case 4: Possible etiopathology—the repetitive venous stasis in the left hand during manual activities below the heart enhances the backflow in the metacarpal web space area and could have aggravated an initial posttraumatic bulging of the vein to a venous aneurysm.

an initial posttraumatic bulging of the vein to a venous aneurysm (Fig. 15).

VENOUS MALFORMATION

Venous malformation (VM; case 4) is present at birth and has a genetic predisposition. It may become evident as individuals grow, mainly due to the VM’s thin walls and an abnormal smooth muscle structure. VMs typically become apparent during adolescence or following trauma.⁴² They are also termed “dependent lesions,” because they expand and contract depending on the patient’s position.⁴³

With its “dependent” behavior and plausible posttraumatic onset of the fourth digit, case 4 shared the criteria of VM and posttraumatic VAN. Due to the localization and its short length, we decided to perform a simple excision and repair under general anesthesia, which is regarded as the gold standard treatment option.^{44,45} It leads to a reconstruction without any residual restrictions or recurrences.

Histopathological examination was compatible with a VM as well as with VAN. A differentiation between these two diagnoses is not always possible by histopathology alone as they share similar characteristics.³⁸ In both cases, the leading histological picture is that of an often ectatic venous blood vessel with an irregular, “dysplastic” wall. The differentiation between the two entities often relies on the clinical presentation and imaging studies. Genetic analysis may reveal a mutation of the endothelial receptor TIE2, which binds and is activated by angiopoietin—a mechanism for the formation of blood vessels. A mutation of TIE2 is typical for VM, however, only in around half of all cases. TIE2 mutations cause an uncoupling of

endothelial cells and pericytes, altering the venous development.^{46,47} In theory, posttraumatic VAN would not harbor such mutations; to the best of our knowledge, no studies investigating TIE2 mutations and predisposition to develop posttraumatic VAN exist. As VAN can appear in VM,³⁸ a smooth transition from VAN single lesions to complex lesions inside VMs is conceivable.

For the patient, differentiation between the two entities is relevant, as it determines the recurrence rate and risk for further symptoms or a systemic disease. Posttraumatic VAN is healed with the complete resection. No further symptoms would have to be expected. VMs are usually sporadic and solitary (90% of cases),⁴⁶ which means that also in this case the surgical resection would have been sufficient. In addition, we could not find a cobblestone pattern which is typical for the glomovenous type of VM and found in up to 40% of these small lesions.⁴² This diagnosis would have the risk of 17% to develop new lesions over time.⁴⁸

An interventional angiological approach with sclerotherapy would have been possible in this case. However, as the lesion was small, easily accessible, and an exploration under clear view allowed for retrieval of histopathological specimens, a surgical approach was chosen. Sclerotherapy would have had the risk of sclerosing beyond the area of interest. Sclerotherapy may be more suitable for complex vascular networks, which may be treated solely by interventional means or as a primary step before surgical resection.⁴²

CONCLUSIONS

VA has been simplified by the latest ISSVA classification that allows for better management of these lesions by providing clear diagnostic and therapeutic groups. This basis facilitates clinical decision-making and helps to determine therapeutic strategies, even for those not working in a highly specialized vascular center.

Posttraumatic VA is not yet included as a subgroup in the current classification but could be considered as one in future. The reactive and passive changes due to trauma may offer a contribution to the understanding of the development and efficient treatment of VA.

To clinicians who suspect a lesion to be a VA, we propose the following algorithm: evaluation with an ultrasound which provides valuable information. An additional MRI is rarely needed in posttraumatic VA. In general, an operation versus a sclerosing treatment by interventional angiologists or radiologists versus a conservative approach should be weighed. In the presented cases, the operation turned out to be the most efficient solution because of the small size and localization of the lesions. But the analysis of more cases would be needed to prove whether posttraumatic VA shows a better outcome after (micro-)surgical treatment.

Helene Sophie Scheer, MD

Freiburgstrasse 4

Bern, Switzerland

E-mail: helenesophie.scheer@insel.ch

REFERENCES

1. Virchow V. *Angioma in die Krankhaften Geschwülste*. Berlin: Hirshwald; 1863.
2. Mulliken JB, Glowacki J. Hemangiomas and vascular malformations in infants and children: a classification based on endothelial characteristics. *Plast Reconstr Surg*. 1982;69:412–422.
3. Wassef M, Blei F, Adams D, et al; ISSVA Board and Scientific Committee. Vascular anomalies classification: recommendations from the International Society for the Study of Vascular Anomalies. *Pediatrics*. 2015;136:e203–e214.
4. Hand JL, Frieden IJ. Vascular birthmarks of infancy: resolving nosologic confusion. *Am J Med Genet*. 2002;108:257–264.
5. Koman LA, Paterson Smith B, Smith T, et al. Vascular disorders. In: Kozin SWWPSH, ed. *Green's Operative Hand Surgery*. 6th ed. Philadelphia, Pa.: Churchill Livingstone. 2010;6:2197–2240.
6. Mende K, Vargesson N, Sivakumar B. Vascular anomalies of the upper limb. *J Hand Surg Eur Vol*. 2019;44:233–241.
7. Groesser L, Peterhof E, Evert M, et al. BRAF and RAS mutations in sporadic and secondary pyogenic granuloma. *J Invest Dermatol*. 2016;136:481–486.
8. Giblin AV, Clover AJ, Athanassopoulos A, et al. Pyogenic granuloma - the quest for optimum treatment: audit of treatment of 408 cases. *J Plast Reconstr Aesthet Surg*. 2007;60:1030–1035.
9. Witthaut J, Steffens K, Koob E. Reliable treatment of pyogenic granuloma of the hand. *J Hand Surg Br*. 1994;19:791–793.
10. Hartzell HE. Granuloma pyogenicum. *J Cutaneous Dis Including Syphilis*. 1904;22:520–525.
11. Godfraind C, Calicchio ML, Kozakewich H. Pyogenic granuloma, an impaired wound healing process, linked to vascular growth driven by FLT4 and the nitric oxide pathway. *Mod Pathol*. 2013;26:247–255.
12. Matsuzaki K, Imamura Y, Ozawa M, et al. Intravenous lobular capillary hemangioma in the subclavian vein. *Ann Thorac Surg*. 2016;102:e427–e429.
13. Hoffmann H. Granuloma teleangiectatum. In: Jadassohn J. SO, ed. *Handbuch der Haut- und Geschlechtskrankheiten*. Berlin: Springer; 1929;9:401–432.
14. Altmeyer PDmP. Altmeyers Enzyklopädie. 2017. Available at <https://www.altmeyers.org/de/home>. Accessed December 2018.
15. Patrice SJ, Wiss K, Mulliken JB. Pyogenic granuloma (lobular capillary hemangioma): a clinicopathologic study of 178 cases. *Pediatr Dermatol*. 1991;8:267–276.
16. Bloethner S, Snellman E, Bermejo JL, et al. Differential gene expression in melanocytic nevi with the V600E BRAF mutation. *Genes Chromosomes Cancer*. 2007;46:1019–1027.
17. Moshe M, Levi A, Ad-El D, et al. Malignant melanoma clinically mimicking pyogenic granuloma: comparison of clinical evaluation and histopathology. *Melanoma Res*. 2018;28:363–367.
18. Pagliai KA, Cohen BA. Pyogenic granuloma in children. *Pediatr Dermatol*. 2004;21:10–13.
19. Sommer NZ, Brown RE. The perionychium. In: Wolfe S, ed. *Green's Operative Hand Surgery*. Philadelphia, Pa.: Churchill Livingstone. 2010;6:348.
20. Warner J, Jones EW. Pyogenic granuloma recurring with multiple satellites. A report of 11 cases. *Br J Dermatol*. 1968;80:218–227.
21. May JW Jr, Atkinson R, Rosen H. Traumatic arteriovenous fistula of the thumb after blunt trauma: a case report. *J Hand Surg Am*. 1984;9:253–255.
22. Kamishima T, Hasegawa A, Kubota KC, et al. Intravenous pyogenic granuloma of the finger. *Jpn J Radiol*. 2009;27:328–332.
23. Gameiro A, Cardoso JC, Calonje E, et al. Intravascular lobular capillary hemangioma in the corpus spongiosum. *Am J Dermatopathol*. 2016;38:e15–e17.

24. Sanguenza OP, Requena L. *Pathology of Vascular Skin Lesions*. New York, N.Y.: Humana Press; 2003.
25. Pantanowitz L, Duke WH. Intravascular lesions of the hand. *Diagn Pathol*. 2008;3:24.
26. Boukoulas S, Dillard R, Qiu S, et al. Intravascular papillary endothelial hyperplasia (Masson's tumor): diagnosis the plastic surgeon should be aware of. *Plast Reconstr Surg Glob Open*. 2017;5:e1122.
27. Inalöz HS, Patel G, Knight AG. Recurrent intravascular papillary endothelial hyperplasia developing from a pyogenic granuloma. *J Eur Acad Dermatol Venereol*. 2001;15:156–158.
28. Kuo T, Sayers CP, Rosai J. Masson's "vegetant intravascular hemangioendothelioma:" a lesion often mistaken for angiosarcoma: study of seventeen cases located in the skin and soft tissues. *Cancer*. 1976;38:1227–1236.
29. Cura M, Elmerhi F, Suri R, et al. Vascular malformations and arteriovenous fistulas of the kidney. *Acta Radiol*. 2010;51:144–149.
30. Hunter W. The history of an aneurysm of the aorta, with some remarks on aneurysm in general. *Med Observations Inquiries*. 1757;1:323.
31. Rienhoff WF. Congenital arteriovenous fistula - An embryological study, with the report of a case. *B Johns Hopkins Hosp*. 1924;35:271.
32. Rostad H, Engedal H, Hall KV. Traumatic arteriovenous fistulas. A follow-up study. *Angiology*. 1976;27:157–164.
33. Gormus N, Karabacakoglu A, Solak H, et al. Post-traumatic arteriovenous fistula presented with hypertrophic palmaris digitalis II. *Ann Vasc Surg*. 2003;17:690–692.
34. Nagata T, John H. Radial arteriovenous fistula following coronary angiography. *J Card Surg*. 2017;32:805–806.
35. Pascual I, Lorca R, Avanzas P, et al. Arteriovenous radial fistula: a rare and delayed complication of coronary angiography. *JACC Cardiovasc Interv*. 2017;10:1370–1371.
36. Goldberg A, Tsipis A, Rosenfeld I. Arteriovenous fistula after cardiac catheterization from a radial approach. *Isr Med Assoc J*. 2013;15:313–314.
37. Perings SM, Kelm M, Jax T, et al. A prospective study on incidence and risk factors of arteriovenous fistulae following transfemoral cardiac catheterization. *Int J Cardiol*. 2003;88:223–228.
38. Behraves S, Yakes W, Gupta N, et al. Venous malformations: clinical diagnosis and treatment. *Cardiovasc Diagn Ther*. 2016;6:557–569.
39. Gillespie DL, Villavicencio JL, Gallagher C, et al. Presentation and management of venous aneurysms. *J Vasc Surg*. 1997;26:845–852.
40. Dolan JM, Kolega J, Meng H. High wall shear stress and spatial gradients in vascular pathology: a review. *Ann Biomed Eng*. 2013;41:1411–1427.
41. Dobyms JH. Digital nerve compression. *Hand Clin*. 1992;8:359–367.
42. Greene AK, Alomari AI. Management of venous malformations. *Clin Plast Surg*. 2011;38:83–93.
43. Cox JA, Bartlett E, Lee EI. Vascular malformations: a review. *Semin Plast Surg*. 2014;28:58–63.
44. Malem D, Bangash HK, Mwipatayi BP. Primary axillary venous aneurysm associated with local neurological complications. *Ann Vasc Surg*. 2017;41:282.e15–282.e17.
45. Teter KA, Maldonado TM, Adelman MA. A systematic review of venous aneurysms by anatomic location. *J Vasc Surg Venous Lymphat Disord*. 2018;6:408–413.
46. Boon LM, Mulliken JB, Enjolras O, et al. Glomuvenous malformation (glomangioma) and venous malformation: distinct clinicopathologic and genetic entities. *Arch Dermatol*. 2004;140:971–976.
47. Limaye N, Wouters V, Uebelhoer M, et al. Somatic mutations in angiopoietin receptor gene TEK cause solitary and multiple sporadic venous malformations. *Nat Genet*. 2009;41:118–124.
48. Brouillard P, Ghassibé M, Penington A, et al. Four common glomulin mutations cause two thirds of glomuvenous malformations ("familial glomangiomas"): evidence for a founder effect. *J Med Genet*. 2005;42:e13.