



# Complications of hip preserving surgery

Markus S. Hanke<sup>1</sup>  
Till D. Lerch<sup>2</sup>  
Florian Schmaranzer<sup>2</sup>  
Malin K. Meier<sup>1</sup>  
Simon D. Steppacher<sup>1</sup>  
Klaus A. Siebenrock<sup>1</sup>

- Preoperative evaluation of the pathomorphology is crucial for surgical planning, including radiographs as the basic modality and magnetic resonance imaging (MRI) and case-based additional imaging (e.g. 3D-CT, abduction views).
- Hip arthroscopy (HAS) has undergone tremendous technical advances, an immense increase in use and the indications are getting wider. The most common indications for revision arthroscopy are labral tears and residual femoroacetabular impingement (FAI).
- Treatment of borderline developmental dysplastic hip is currently a subject of controversy. It is paramount to understand the underlining problem of the individual hip and distinguish instability (dysplasia) from FAI, as the appropriate treatment for unstable hips is periacetabular osteotomy (PAO) and for FAI arthroscopic impingement surgery.
- PAO with a concomitant cam resection is associated with a higher survival rate compared to PAO alone for the treatment of hip dysplasia. Further, the challenge for the surgeon is the balance between over- and undercorrection.
- Femoral torsion abnormalities should be evaluated and evaluation of femoral rotational osteotomy for these patients should be incorporated to the treatment plan.

**Keywords:** femoroacetabular impingement; hip arthroscopy; hip dysplasia; periacetabular osteotomy; SCFE; surgical hip dislocation

Cite this article: *EFORT Open Rev* 2021;6:472-486.  
DOI: 10.1302/2058-5241.6.210019

Over the past two decades, substantial increase in the knowledge of pre-arthritic conditions of the hip joint including femoroacetabular impingement, development dysplasia of the hip, slipped capital femoral epiphysis, residual deformities after Perthes disease, torsional abnormalities together with the development of new surgical approaches and procedures, have revolutionized the field

of joint preserving surgery. The utilization of joint preservation operations including hip arthroscopy, surgical hip dislocation, and periacetabular osteotomy (PAO) has increased over time.<sup>1</sup>

The purpose of this article is to review current knowledge about complications of joint preservation procedures of the hip.

## Preoperative workup

A workup of the patient's symptoms, clinical findings and standardized radiographic workup is mandatory in patients eligible for joint preserving surgery. Detailed understanding of the location and extension of the deformity is essential for the correct choice of surgical technique and success of the surgical treatment. Patients may present typical symptoms (e.g. groin pain with hip rotation, while sitting or during sport activities; trochanteric pain). A detailed clinical examination of the hip may further present typical findings (e.g. restricted range of motion, positive anterior impingement sign).<sup>2-4</sup> Conventional radiographs remain the basis of the radiographic workup. These should include supine anteroposterior (AP) pelvic views to assess radiographic joint degeneration, acetabular coverage, acetabular version and gross anatomy of the pelvis.<sup>5</sup> To detect accompanying cam deformities, which are typically located anterosuperiorly, an axial view is needed. In the absence of severe joint space narrowing, magnetic resonance imaging (MRI) of the hip should be performed in all patients evaluated for joint preserving surgery. At first, fluid-sensitive images with a large field of view should be obtained to screen for associated inflammatory or neoplastic conditions surrounding the hip joint.<sup>6</sup> Fast axial images of the pelvis and the distal femoral condyles should be acquired to assess femoral torsion.<sup>7</sup> Then dedicated high-resolution images of the hip at field strengths of 1.5 T or 3 T in the coronal, axial-oblique/axial and sagittal orientations should be performed to assess

intraarticular lesions.<sup>8</sup> Acquisition of radial images is essential to provide a circumferential assessment of the femoral head neck junction.<sup>9,10</sup> Although promising results have been demonstrated for non-contrast MRI of the hip at 3 T, direct MR arthrography is still the current diagnostic gold standard in the detection of chondrolabral lesions.<sup>11–13</sup> MR arthrograms provide crucial prognostic information as extensive cartilage defects, acetabular cysts and osteophyte formations indicate a higher risk for failure of femoroacetabular impingement (FAI) surgery in the long term.<sup>14</sup> Injection of intraarticular contrast agent further enables application of leg traction to achieve joint distraction and has shown promising early results to improve the visualization of intraarticular lesions.<sup>15–18</sup>

Further on, selective additional imaging may be added. To assess for joint congruency, functional views are performed. Especially in dysplastic hips there is typically an apparent joint space narrowing due to subluxation and for differentiation the abduction view is used.<sup>19</sup> New biochemical cartilage MRI techniques such as delayed gadolinium-enhanced MRI of cartilage (dGEMRIC) or T2\* imaging offer the ability to evaluate chondral defects more accurately before surgical therapy.<sup>20,21</sup> Three-dimensional computerized tomography (3D CT) scans enable exact visualization of the bony deformities, and specific software for dynamic range of motion simulation can be very effective to identify the dominant osseous deformity and plan surgical correction.<sup>22</sup> This is especially true for surgical planning in cases with suspected extraarticular FAI.<sup>23</sup> 3D MRI has great potential to replace 3D CT for rendering of 3D models of the hip joint and further analysis for a non-invasive improved surgical decision-making in these mostly young patients.<sup>24–26</sup>

### Hip arthroscopy (HAS)

Historically the treatment of hip pathologies including FAI and labral tears has required open surgical hip dislocation.<sup>27</sup> Over the past years HAS has undergone tremendous technical advances, an immense increase in use and the indications are getting wider.<sup>28–30</sup> Thus, a wide range of complications is more frequently seen and reported (Table 1; Fig. 1). Generally complications are rare (1.3–4.2%),<sup>28,31–33</sup> but may be underreported.<sup>33,34</sup>

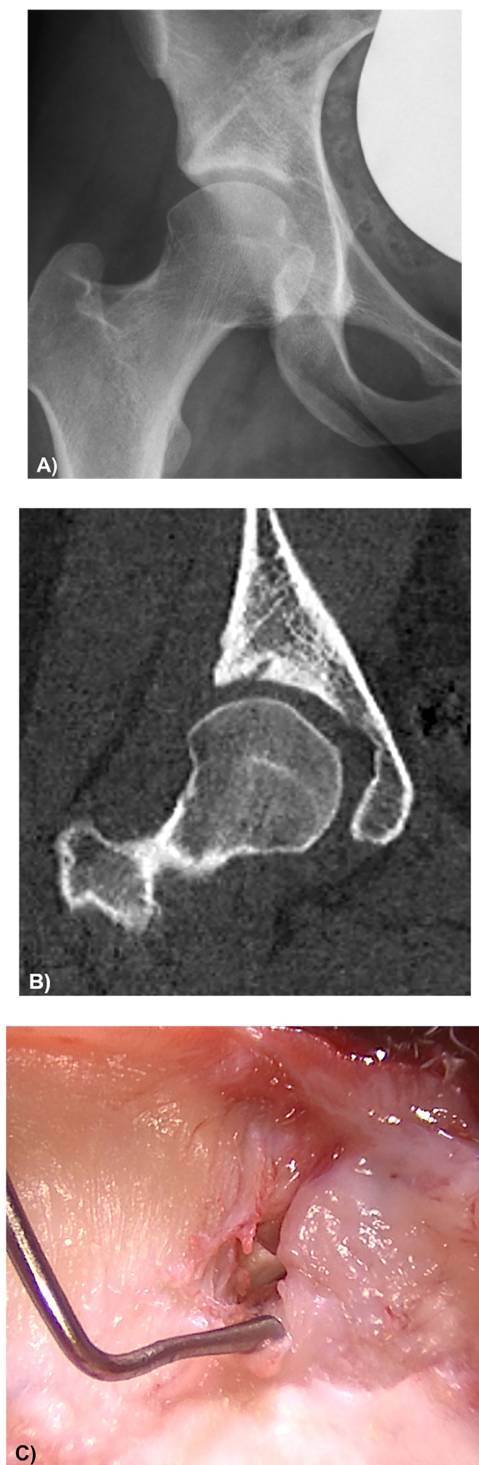
The early arthroscopic treatment method of labral tears was debridement.<sup>35</sup> Based on increasing understanding and research on labral function and its relation to joint stability, management has progressed to favour repair when sufficient tissue is available or even reconstruction in cases in which the labrum was not amenable to repair.<sup>36–40</sup> Reestablishment of suction seal and normal biomechanics of the hip joint is allowed by labral repair.<sup>41</sup> This has further been substantiated in several case-control

**Table 1. Complications of hip arthroscopy (HAS) are listed below with grading according to Sink et al.<sup>118</sup>**

Grade	Complication	Prevalence	Reference
1 <i>Complication without clinical relevance</i>	Superficial wound infection	< 1%	119
	Heterotopic ossification Grade 1–2 (Brooker)	< 1–6%	119–122
	Instrument breakage	< 1%	119,122,123
	Iatrogenic chondral injury	3%	119,124
	Iatrogenic labral injury	< 1–20%	119,125
	Hypothermia	2.7%	126
2 <i>Complication with outpatient or medication treatment</i>	Temporary nerve injury	2–7%	119,122,123,127
	Permanent nerve injury	< 1%	122
	Perineal skin damage	< 1%	119,122,123,128
	Deep wound infection	< 1%	119,129
3 <i>Complication with surgical therapy or unplanned hospitalization</i>	Deep vein thrombosis	< 1–3.7%	119,130
	Femoral neck fracture	< 1%	119,123
	Scrotal skin necrosis	< 1%	131
	Avascular necrosis	< 1%	119,123
	Heterotopic ossifications Grade 3–4 (Brooker)	< 1%	120
	Extraarticular fluid extravasation	< 1–1%	119,122,123

studies comparing patient-reported outcomes (PROs) of labral repair to debridement reporting significantly better outcomes for patients undergoing repair.<sup>42–44</sup> Further on, reconstruction has become a more widely used treatment option in cases where the labrum is not amenable to repair.<sup>27</sup> Several studies have demonstrated that reconstruction can closely approximate the native labrum and lead to favourable outcomes in the short term despite variable techniques, graft type and indications.<sup>39,40</sup>

The most common indications for revision arthroscopy are labral tears and residual FAI.<sup>45</sup> In a systematic review labral tears were commonly treated with labral reconstruction at the time of revision.<sup>45</sup> The corresponding improvement in outcomes may suggest that labral degeneration is one of the leading sources of pain in the failed hip arthroscopy.<sup>45</sup> In systematic reviews of revision hip arthroscopy, residual cam or pincer lesions not properly addressed in the index procedure were found to be the most common indication for revision arthroscopic surgery and the most common intraoperative finding.<sup>46,47</sup> Under-resection of cam lesions may leave residual impingement<sup>48</sup> and consequently further chondrolabral damage that may result in cartilage degeneration.<sup>49</sup> Residual cam deformities were addressed in up to 37% of the patients undergoing revision HAS.<sup>47</sup> On the other hand over-resection may cause fractures of the femoral neck, disruption of the labral seal, or mechanical symptoms.<sup>50,51</sup> Femoral neck fractures may occur due to weakening of the bone and thus most



**Fig. 1** A 34-year-old patient presented with postoperative hip pain following arthroscopic rim trimming and labrum refixation in an external institution. (A) Anteroposterior pelvis view shows a preserved joint space and no obvious deformity. (B) Computerized tomography of the hip showed a drill hole and suspected intraarticular position of the anchor. (C) Patient underwent subsequent surgical hip dislocation which confirmed the intraarticular anchor position and resulting co-located acetabular cartilage damage.

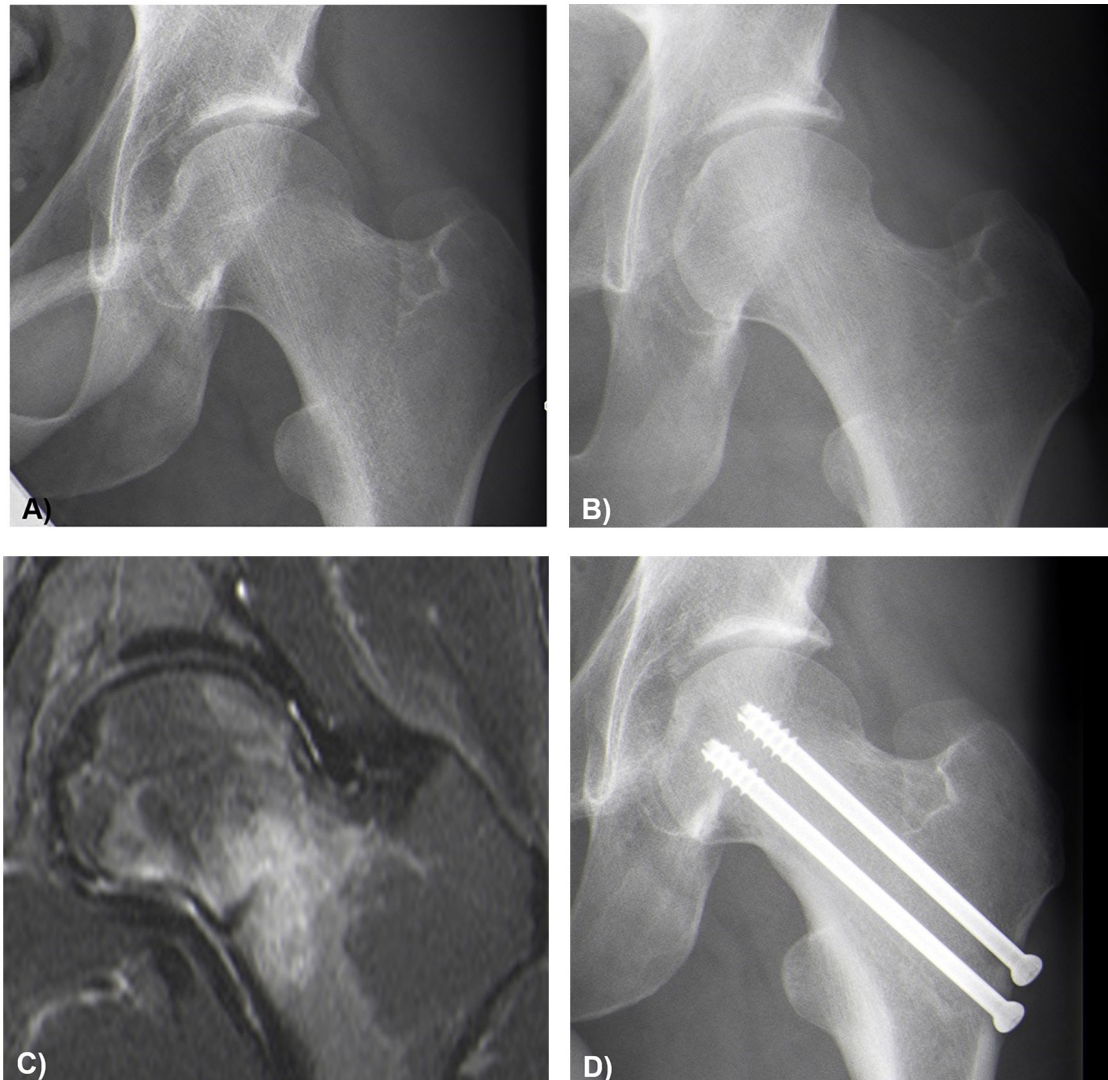
postoperative protocols limit weight bearing (Fig. 2).<sup>50</sup> A cadaveric study found that the load-bearing ability of the bone was not affected if resection of up to 30% of the anterolateral head–neck junction was performed. The sealing effect is dependent on the fit of the labrum against the femoral head and thus over-resection may disrupted this seal of the labrum against the over-resected area.<sup>50,52</sup> This leads to impaired joint lubrication and quicker cartilage consolidation.<sup>52</sup>

For arthroscopic treatment of FAI less favourable outcomes have been reported for patients of older age groups (> 45 years), female sex, those with elevated body mass index (BMI), osteoarthritic changes, decreased joint space (< 2 mm), chondral defects, increased lateral centre edge (LCE) angle and labral debridement compared with labral repair.<sup>53</sup>

The ideal treatment of borderline developmental dysplastic hip (BDDH) is currently a subject of controversy. It is paramount to understand the underlining problem of the individual hip and distinguish instability (dysplasia) from FAI as the appropriate treatment for unstable hips is PAO and for FAI arthroscopic impingement surgery. The consequences of hip arthroscopy in unstable hips can be devastating (Fig. 3).<sup>54–57</sup> Mostly, BDDH is defined as LCEA of 18–25°<sup>58</sup> and to further evaluate stability the Femoro-Epiphyseal Acetabular Roof (FEAR) Index was introduced,<sup>59</sup> which helps to separate the indications of PAO or hip arthroscopy. Among patients with an LCEA of  $\leq 25^\circ$ , a FEAR Index of  $< 5^\circ$  is a moderate indication for hip arthroscopy.<sup>59</sup> Instability due to deficient coverage further leads to increased loads to the labrum, resulting in labral hypertrophy<sup>60–62</sup> and an increased iliocapsularis-to-rectus-femoris ratio is suggestive for instability in BDDH.<sup>63</sup> Surgically, capsular closure or capsular plication is paramount. Failure to completely close the capsulotomy site may lead to iatrogenic instability and patients may be more likely to have residual symptoms from capsular laxity or capsular defects (Fig. 4).<sup>64</sup>

### Surgical hip dislocation (SHD)

Open surgical hip dislocation (SHD) offers the possibility of circumferential corrections and can be combined with additional procedures to relieve intra- and extraarticular impingement and associated collateral damages. The technique was first described by Ganz et al<sup>4</sup> in 2001 as a technique for safe surgical dislocation of the hip after detailed analysis of the blood supply of the femoral head.<sup>65</sup> The approach can be used for surgical correction of pre-arthritis conditions such as FAI,<sup>2</sup> residual Perthes deformity (Legg-Calvé-Perthes disease),<sup>66</sup> slipped capital femoral epiphysis (SCFE),<sup>67</sup> avascular necrosis of the femoral head (AVN), synovial disease with formation of loose bodies and for open reduction and internal fixation (ORIF) of acetabular fractures.<sup>68</sup>

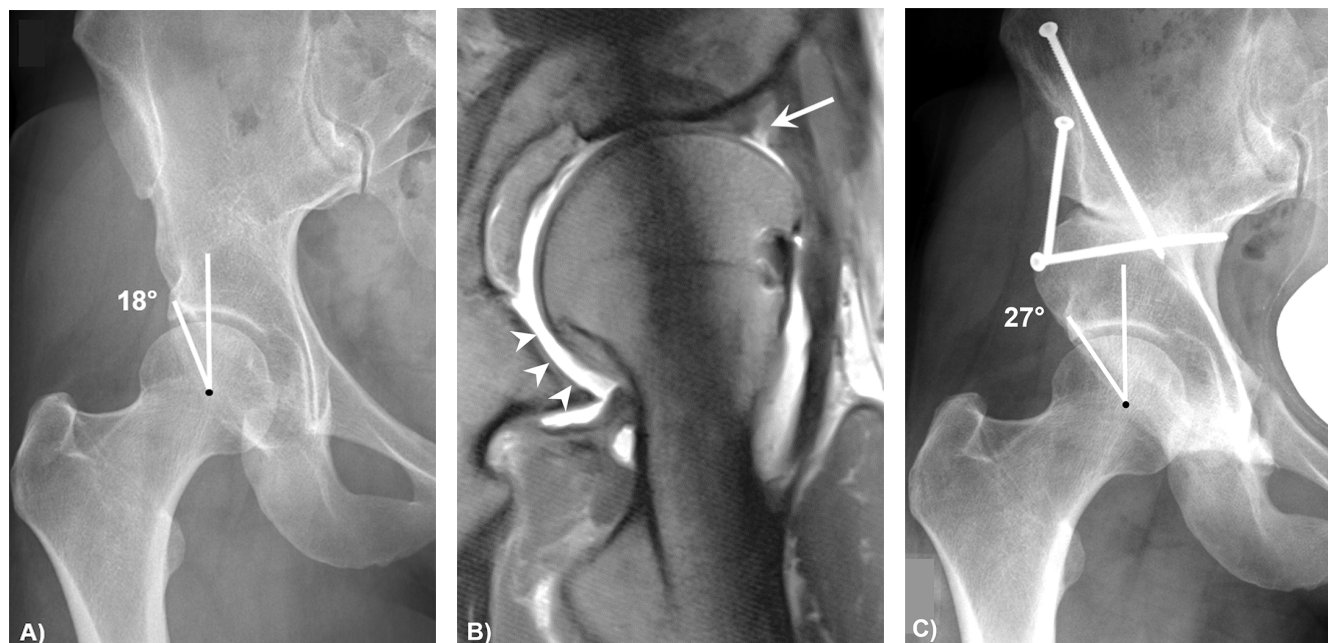


**Fig. 2** (A) Preoperative anteroposterior pelvis view of a 27-year old professional football player with cam femoroacetabular impingement who underwent arthroscopic cam resection. (B) Ten months following return to play, the patient presents with recurrent hip pain. The corresponding radiograph shows no obvious pathology. (C) The coronal fluid sensitive magnetic resonance image of the hip shows bright bone marrow oedema with sclerotic line corresponding to a stress fracture. (D) Stabilization of the stress fracture was performed using cannulated screws.

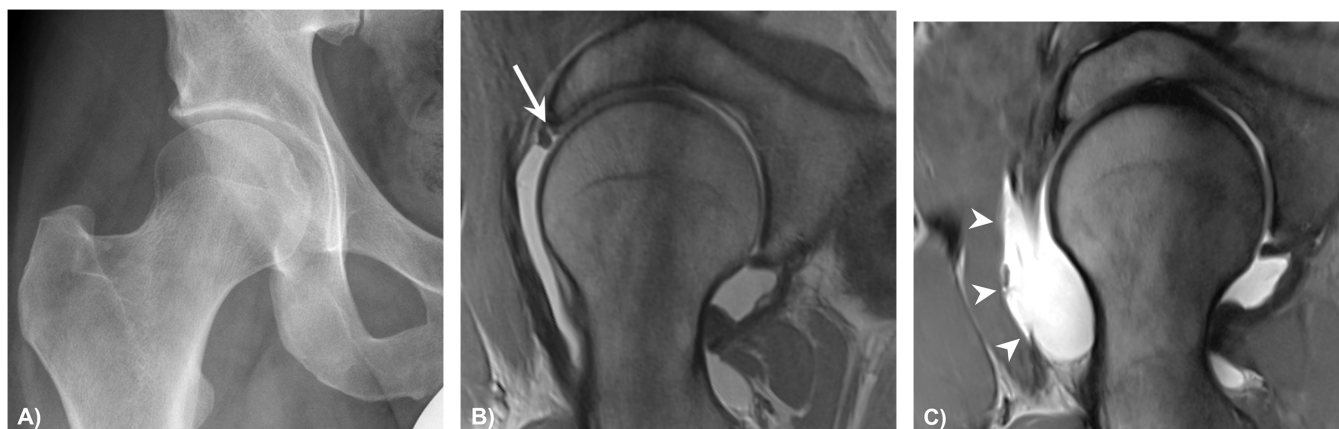The rate of severe complications after SHD for FAI is generally low (Table 2). Persisting groin pain can be present in approximately 10% to 15% of patients after open FAI surgery.<sup>69</sup> Insufficient correction of the femoral and acetabular deformity, advanced osteoarthritis and intra-articular adhesions<sup>70</sup> are causes of persistent groin pain after FAI surgery.<sup>71</sup> Patients often report no or only a short pain-free interval after surgery when a persistent FAI morphology is present. Residual deformity is the most common cause of persistent hip pain and persistent FAI after previous FAI surgery.<sup>72</sup> Adhesions may be present in up

to 62% of patients undergoing revision surgery.<sup>73</sup> Typical locations for adhesions are between the joint capsule and the former resection area of the femoral neck (Fig. 5), and between the labrum and the joint capsule.<sup>69</sup> Diagnostics are performed with MR arthrography,<sup>74</sup> and treatment of painful adhesions is generally by HAS.<sup>69</sup> Inadequate post-operative mobilization and patients aged under 30 years are at increased risk.<sup>75</sup>

Eighty per cent of patients undergoing SHD for correction of anterior intraarticular FAI have a good clinical result without osteoarthritis progression and no total hip



**Fig. 3** (A) A 26-year-old female patient with borderline developmental dysplastic hip and persistent hip pain following two external hip arthroscopies with offset correction and labrum debridement. Anteroposterior (AP) pelvis view shows insufficient acetabular coverage with an lateral centre edge angle (LCE) of 18°. (B) Magnetic resonance arthrography was performed for evaluation of intraarticular lesions. Radial images show hypoplastic labrum with intrasubstance tearing (arrow). Contrast interposition (arrowheads) at the posterior inferior acetabulum, corresponding anterior translation of the femoral head indicative for hip instability. (C) AP pelvis view six months after periacetabular osteotomy shows improved lateral acetabular coverage with an LCE of 27°.



**Fig. 4** (A, B) A 33-year-old patient with normal acetabular coverage and mild cam deformity and partial labrum tear (arrow) anterosuperiorly who underwent arthroscopic cam resection and labrum refixation. (C) Patient presented with prolonged pain postoperatively and repeated magnetic resonance arthrography showed extensive defect of the anterior capsule (arrowheads). The patient was scheduled to capsule reconstruction subsequently.

arthroplasty at 10-year follow-up.<sup>76</sup> One could count failure of the procedure and disease progression as complications, and several predictive factors for an unfavourable outcome after SDH have been reported (Table 3). In a retrospective study, a 10-year survivorship of 82% was reported after SHD for acetabular fractures involving the posterior wall or transverse and posterior wall or others.<sup>77</sup>

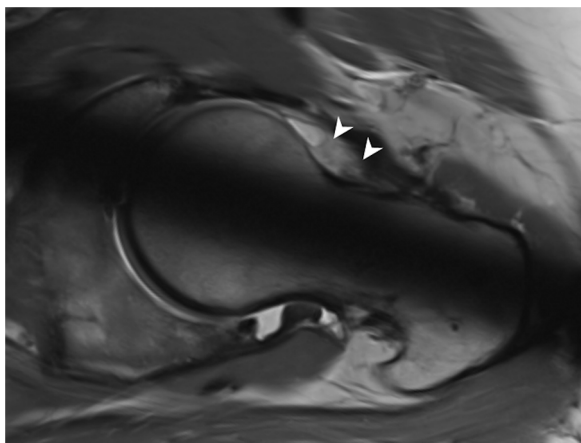
Predictors for failure were femoral chondral lesions, marginal impaction, duration of surgery, and age of patient.<sup>77</sup>

### Bernese periacetabular osteotomy (PAO)

The PAO is an accepted surgical technique for treatment of both hip dysplasia<sup>78</sup> and pincer-type FAI due to

**Table 2.** Complications of surgical hip dislocation (SHD) are listed below with grading according to Sink et al.<sup>18</sup>

Grade	Complication/ Consecutive Surgery	Prevalence	Reference
1 <i>Complication without clinical relevance</i>	Superficial wound infection	0.6–1 %	132,133
	Bursitis trochanterica	12.5%	134
	Heterotopic ossifications Grade 1–2 (Brooker)	5.4%	132
	Partial neurapraxia	0.3–1.5%	4,132
2 <i>Complication with outpatient or medication treatment</i>			
3 <i>Complication with surgical therapy or unplanned hospitalization</i>	Heterotopic ossification Grade 4 (Brooker)	1.4%	134
	Trochanteric fixation failure	1–1.8%	132–135,135
	Evacuation of wound haematoma	2%	133
	Removal of trochanteric screws	25–64.4%	133,135
	Arthroscopic adhesiolysis	6%	133
	Revision of iliotibial band dehiscence	1%	133


**Fig. 5** A 24-year-old patient with persistent pain after surgical hip dislocation for mixed femoroacetabular impingement. Magnetic resonance arthrography presents adhesions between the joint capsule and the femoral neck (arrowheads). The patient underwent hip arthroscopy for adhesiolysis.

acetabular retroversion.<sup>79</sup> The aim of PAO surgery is to prevent or delay secondary osteoarthritis while improving hip biomechanics. In contrast to different pelvic osteotomies, the posterior column remains intact during PAO. This improves the stability of the reoriented acetabular fragment and facilitates postoperative rehabilitation at the same time. The birth canal remains intact and allows normal birth. The overall complication rate is relatively low considering the complexity of the surgery. The key point for a successful long-term outcome is an optimal reorientation of the acetabulum avoiding under- or over-correction

**Table 3.** Predicted factors for failure of surgical hip dislocation (SHD) for femoroacetabular impingement (FAI) at 10-year follow-up according to Steppacher et al.<sup>76</sup>

Category	Predictive factors
Demographic factors	Age > 40 years BMI > 30 kg/m <sup>2</sup>
Preoperative radiographic factors	Anterior femoral coverage < 15% Osteoarthritis ≥ Tönnis Grade 1
Postoperative factors related to surgical accuracy	LCE < 22° or > 32° AI < 3° or > 13° Extrusion Index < 18% or > 28% Total femoral coverage < 72% or > 83% Anterior femoral coverage < 15% Posterior femoral coverage < 34%

Note. BMI, body mass index; LCE, lateral centre edge; AI, acetabular index.

for both hip dysplasia<sup>80</sup> and acetabular retroversion.<sup>81</sup> For the treatment of acetabular retroversion with anteverting PAO, a 10-year total hip arthroplasty (THA)-free survival of 100% has been described.<sup>81</sup> In addition, when comparing PAO and acetabular rim trimming for the treatment of acetabular retroversion, the first exhibited a higher long-term survival rate.<sup>82</sup> With optimal reorientation and a spherical femoral head, the cumulative survivorship of the hip after 10 years is 90.5%<sup>80</sup> for treatment of hip dysplasia. For the very first 75 patients, the cumulative THA-free survivorship at 20-year follow-up was 60%<sup>83</sup> and at 30-year follow-up was 43%.<sup>84</sup> The PAO has become the gold standard for the surgical therapy of hip dysplasia in adolescents and adult patients.

Although PAO is a rather complex operation, only few severe complications have been described so far (Table 4). In a recent review, analysing 4070 hips that underwent PAO, a complication rate of 7% was described.<sup>85</sup> Reduced complication rates were described for minimally invasive approaches.<sup>85</sup> Comparison between the studies remains difficult because of the heterogeneity of the studies and inconsistent training of the surgeons. A higher complication rate was described for patients with a BMI > 30.<sup>86</sup> The most common complications were transient or permanent damage of the lateral femoral cutaneous nerve with a prevalence of up to 30%,<sup>87</sup> asymptomatic heterotopic ossification being the most common Grade I/II complication with a prevalence of 20%<sup>88</sup> and protracted union with a prevalence of up to 15% (Fig. 6).<sup>78,89</sup> The most common complication requiring revision surgery was intraarticular osteotomy, with a prevalence of 1–15.5%.<sup>90,91</sup> Complications could be reduced with growing experience and the learning curve.<sup>92</sup> The reported prevalence of over-/under-correction is 22% while the LCE angle was more often under-corrected than over-corrected (20% versus 2%).<sup>93</sup> Hips with more severe dysplasia preoperatively were at higher risk for under-correction assessed with the LCE angle.<sup>93</sup> The prevalence of over-/under-correction was probably underestimated before the description of FAI.

**Table 4.** Complications of periacetabular osteotomy (PAO) are listed below, with grading according to Sink et al.<sup>118</sup>

Grade	Complication	Prevalence	Reference	
1 <i>Complication without clinical relevance</i>	Urinary tract infection	1.5–13%	87,89	
	Superficial wound infection	5%	136	
	Heterotopic ossifications Grade 1–2 (Brooker)	1.8–15%	87,137	
	Postoperative fever	18%	87	
2 <i>Complication with outpatient or medication treatment</i>	Paresthesia N. cutaneus femoris lateralis	30%	87	
	Paresis N. femoralis	1.6–5.6%	90,138	
	Paresis N. ischiadicus	1.5–7%	89,90	
	Blood loss (> 5 blood conserves administered)	3–8%	87,89	
	Avulsion of spina iliaca anterior superior	23%	139	
	Deep wound infection	3–15%	87,89	
	Discontinuity of the posterior column	1.5–8.5%	87,89	
	Fracture of the os ischium	4.3%	90	
	Stress fracture ramus inferior os pubis	5%	136	
	Protracted union of osteotomies	2.6–15%	78,89	
	Nonunion ramus superior os pubis, without revision surgery	6–16%	89,136	
	Deep vein thrombosis, pulmonary embolism	3%	89	
	3 <i>Complication with surgical therapy or unplanned hospitalization</i>	Migration of the acetabular fragment	1.3–5.6%	78,90
		Heterotopic ossifications Grade 3–4 (Brooker) with surgery	1–8.5%	90,91
Revision surgery for nonunion of the ramus superior os pubis		1%	136	
Revision surgery for haematoma evacuation		5%	87	
Intraarticular osteotomy or fracture		1–15.5%	90,91	
Necrosis of the acetabular fragment		4.2%	90	
4 <i>Total hip arthroplasty or life-threatening complication</i>				

Theoretically, through over-correction during PAO, secondary hip impingement can be induced (Fig. 7). This can lead to iatrogenic acetabular retroversion<sup>94</sup> or pincer-type deformity, thereby reducing range of motion and requiring revision osteotomy.

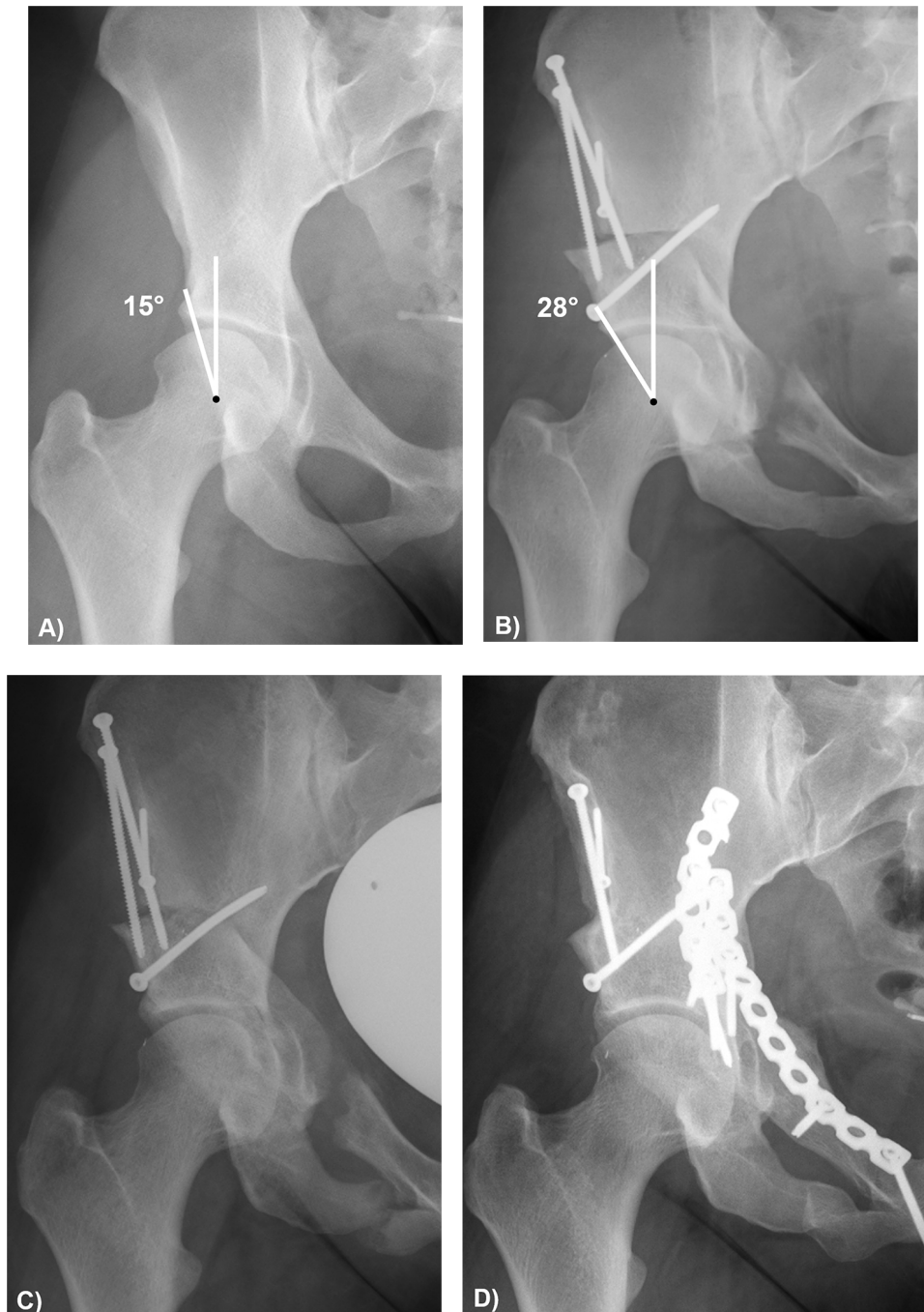
Failure to correct associated cam deformity probably had a higher prevalence before the description of FAI in 2003.<sup>2</sup> Currently this complication can be easily avoided with concomitant cam resection,<sup>80</sup> either with open capsulotomy or with concomitant hip arthroscopy. This is important because a non-spherical femoral head is associated with lower long-term survival. In the presence of a deformity of the proximal femur (valgus hip or increased femoral antetorsion), a concomitant proximal femoral osteotomy should be evaluated.<sup>95,96</sup> Up to 23% of patients with hip dysplasia had concomitant high femoral antetorsion (> 35°), in a recent prevalence study.<sup>97</sup>

### Femoral torsion correction

Abnormal femoral torsion has been described as an additional possible reason for FAI. Increased or decreased femoral torsion can cause extraarticular hip impingement.<sup>98</sup> Increased femoral torsion can cause posterior extraarticular ischiofemoral impingement.<sup>23</sup> On the other hand, decreased femoral torsion can cause anterior extraarticular subspine hip impingement; this is even worse if combined with mixed-type FAI.<sup>99</sup> Surgical treatment consists of hip arthroscopy or surgical hip dislocation combined with proximal femoral osteotomies. Derotational femoral

osteotomy is performed for hips with increased femoral torsion and vice versa. Few outcome studies have evaluated this treatment after the description of FAI in 2003.<sup>2</sup> Therefore, it is questionable whether the outcome and complications of studies before 2003 should be compared with today's treatment. Outcomes of recently published case series analysing patients who underwent femoral derotation osteotomy showed good clinical outcome.<sup>95,96,100</sup> Most of the patients reported that they would undergo surgery again.<sup>96</sup> However, for the treatment of decreased femoral torsion, usually hip arthroscopy with cam resection was performed. Some authors reported inferior outcomes of patients with decreased femoral torsion compared to patients with normal femoral torsion.<sup>101</sup> Therefore, some authors reported that decreased femoral torsion or femoral retrotorsion should be regarded as a contraindication for hip arthroscopy. Others recommended evaluation of femoral rotational osteotomy for these patients.<sup>102</sup>

Complications associated with the treatment of patients with torsional deformities of the femur depend on the treatment. The most common revision surgery after closed treatment with an intramedullary nail, is hardware removal.<sup>95</sup> Hardware removal was performed in the majority of patients in a recent case series of 55 femoral derotational osteotomies.<sup>95</sup> A nonunion rate of 2% and an infection rate of 2% were reported, while 4% underwent THA.<sup>95</sup> After open surgical treatment, the most common complication requiring revision surgery was also implant removal. Nonunion of the proximal femoral osteotomy

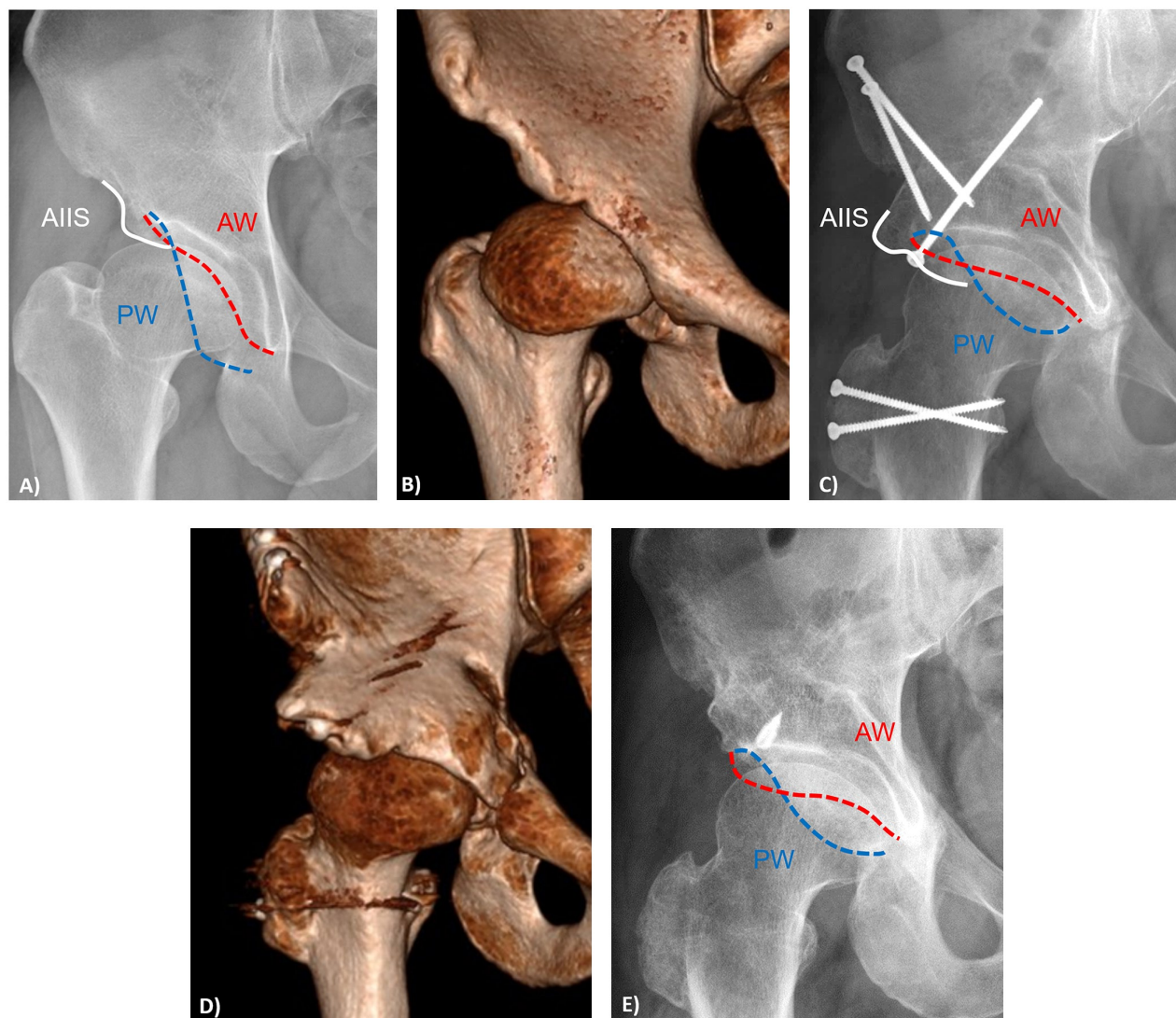


**Fig. 6** (A) A 39-year-old patient with developmental dysplastic hip (lateral centre edge angle (LCE) of 15°) and preserved joint space. (B) Six weeks postoperatively following periacetabular osteotomy, LCE was 28°. (C) Anteroposterior pelvis view shows nonunion of the osteotomy and stress fracture of the inferior pubic ramus six months postoperatively. (D) A decortication and re-osteosynthesis was performed via ilioinguinal approach.

ranged from 0% to 7%.<sup>96,100</sup> Previous studies reported nonunion rates of up to 15%, mostly for children.<sup>103</sup> Complications after open femoral derotation osteotomy are listed in Table 5. Next to hardware removal, subsequent surgeries included hip arthroscopy for adhesiolysis<sup>96</sup> or implant exchange due to implant failure.<sup>100</sup>

No predictive factors associated with failures are described in the orthopaedic literature. Tönnis and Heinecke described in 1999, that various types of femoral osteotomies result in improved clinical outcome,<sup>102</sup> unfortunately they did not report on complications associated with these procedures. For femoral rotational osteotomies





**Fig. 7** (A, B) A 41-year-old patient with history of Legg-Calvé-Perthes disease presenting with hip pain. Anteroposterior (AP) pelvis view and three-dimensional computerized tomography (3D CT) reconstruction show acetabular dysplasia with a prominent downsloping anterior inferior iliac spine (AIIS, white solid line) and coxa breva and magna. The anterior acetabular wall (AW) is shown in red, the posterior acetabular wall (PW) in blue. (C, D) The patient underwent subsequent periacetabular osteotomy and surgical hip dislocation with relative femoral head lengthening and offset correction. Six months postoperative, the patient presents with persistent hip pain and limited range of motion. The postoperative X-ray (C) and 3D reconstructed CT (D) show increased acetabular retroversion (positive crossover sign) and pronounced projection of the AIIS (white solid line) leading to intra- and extraarticular impingement. (E) Postoperative image after decompression of the too prominent AIIS and rim trimming via ilioinguinal approach.

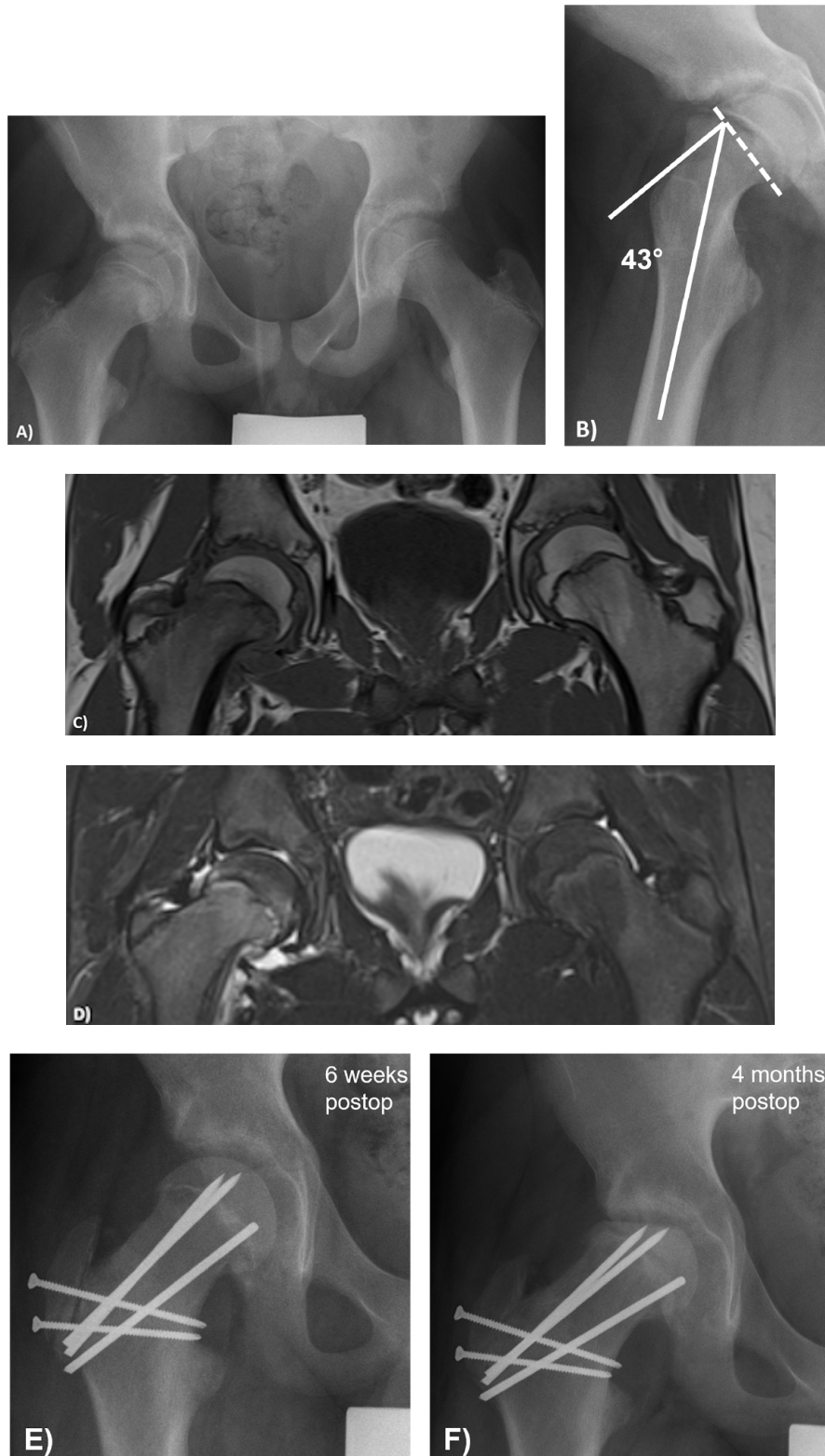to correct decreased femoral torsion, Tönnis and Heinecke reported less hip pain and balanced range of motion postoperative.<sup>102</sup>

### SCFE – modified Dunn, pinning

Slipped capital femoral epiphysis (SCFE) is a long-known hip deformity of adolescent patients. Several classifications have been described previously, among them the classification of

**Table 5.** Complications of femoral derotational osteotomy, with grading according to Sink et al.<sup>118</sup>

Complication	Grade	Prevalence	Reference
Nonunion of the femoral osteotomy	III	0–7%	100
Deep wound infection	III	2%	95
Total hip arthroplasty	IV	0–4%	95,96
Intraarticular adhesions requiring adhesiolysis	II	12%	96
Hardware removal	–	64–71%	95,96



**Fig. 8** (A, B) A 14-year-old boy presenting with hip pain and unstable moderate slipped capital femoral epiphysis (Southwick angle  $43^\circ$  shown in B). (C, D) Magnetic resonance imaging was performed showing joint effusion and bone marrow oedema at the femoral neck but no signs of femoral head necrosis. (E) Postoperative anteroposterior pelvis view six weeks after modified Dunn procedure. (F) Four months postoperative, patient presents with increased pain and radiographic signs of flattening femoral head indicative for avascular necrosis of the femoral head.

**Table 6.** Complications of different treatments for stable slipped capital femoral epiphysis (SCFE) according to the review by Naseem et al,<sup>108</sup> with grading according to Sink et al.<sup>118</sup>

Complication	Grade	Treatment	Prevalence
AVN	III	Epiphysiodesis	3%
		in situ pinning using single screw	1.4%
		in situ pinning using multiple pins	2.2%
		Physeal osteotomy	11.1%
		Surgical dislocation	3.1%
FAI	III	Epiphysiodesis	NR
		in situ pinning using single screw	29.8%
		in situ pinning using multiple pins	NR
		Physeal osteotomy	1.5%
OA	III/IV	Surgical dislocation	6%
		Epiphysiodesis	23.3%
		in situ pinning using single screw	3.1%
		in situ pinning using multiple pins	15%
		Physeal osteotomy	12.2%
		Surgical dislocation	0%

Note. AVN, avascular necrosis of the femoral head; FAI, femoroacetabular impingement; OA, osteoarthritis; NR, not reported.

**Table 7.** Complications of different treatments for unstable slipped capital femoral epiphysis (SCFE) according to the review by Alshryda et al,<sup>109</sup> with grading according to Sink et al.<sup>118</sup>

Complication	Grade	Treatment	Prevalence		
AVN	III	in situ pinning	33%		
		Epiphysiodesis	9%		
		Closed reduction and pinning	26%		
		Open reduction and internal fixation	5%		
		Open reduction and physeal osteotomy	17%		
				Surgical dislocation	18%

Note. AVN, avascular necrosis of the femoral head.

severity described Wilson (mild/moderate/severe)<sup>104</sup> while Loder<sup>105</sup> classified them based on stability (stable/unstable) of SCFE. Untreated SCFE can result in early osteoarthritis, hip pain and THA at young age.<sup>106,107</sup> Therefore, different surgical treatments have been performed. In situ pinning is probably the most common treatment for SCFE. Open surgery includes proximal femoral osteotomies and the modified Dunn procedure. This procedure allows anatomical restoration and normalization of hip function but is a difficult surgery. Long-term studies after the modified Dunn procedure showed no or only minimal signs of osteoarthritis.<sup>67</sup> Based on various studies on the vascular blood supply to the femoral head, the original technique according to Dunn had been modified. The modification included the development of a retinacular soft tissue flap containing the vascular blood supply to the femoral epiphysis.

According to a recent systematic review<sup>108</sup> analysing 58 studies with 2262 hips, the treatment of stable SCFE, in situ pinning using single screw had the lowest AVN rate of 1.4%. Overall, physeal osteotomy had the highest AVN rate of 11.1%. Physeal osteotomy exhibited the highest rate of chondrolysis of 9.8%. The highest rate of

secondary hip impingement (FAI) was noted in patients with stable SCFE who underwent in situ pinning using single screw (30%). Regarding the development of OA, the highest rate was described for epiphysiodesis (23%) and for in situ pinning using multiple pins (15%).

Analysing the outcome of patients with unstable SCFE, a recent systematic review<sup>109</sup> included 25 studies with 679 hips and found an overall AVN rate of 21%. The AVN rate varied between the interventions, varying from 33% from in situ pinning to 5% for open reduction and internal fixation. Further subgroup analysis showed different AVN rates for moderate and severe slips. Timing of surgery (intervention performed within 24 hours or later) remains an important prognostic factor in predicting AVN in these subgroups of SCFE.

Complications associated with treatment of SCFE depend on the treatment approach. Although the modified Dunn procedure is a complex surgery, low rates of AVN were described in Europe. On the other hand, some authors in the US reported a high AVN rate, ranging up to 29% for unstable SCFE (Fig. 8).<sup>110</sup> An overall complication rate needing revision surgery was described between 7% and 15% but remains difficult because of the heterogeneity of the included patients.<sup>111–114</sup> Some authors performed the modified Dunn procedure exclusively for severe or unstable SCFE. While others performed this procedure for moderate and severe SCFE or for both stable and unstable SCFE. Subsequent surgery for improvement of secondary deformities and impingement ranged from 0% to 16%.<sup>111,112,114–117</sup> In Tables 6 and 7 the complications described in the literature are listed in the order of severity according to the classification of Sink.<sup>118</sup> In situ pinning, proximal femoral osteotomies and the modified Dunn procedure are associated with long-term survival. The challenge for the surgeon is the patient selection for open surgery and its treatment.

## Conclusion

Preoperative evaluation and surgical planning are essential steps in joint preserving surgery. The choice of treatment method is crucial to approach the patient-specific pathomorphology and prevent surgical-related secondary problems such as instability and surgically induced FAI.

### AUTHOR INFORMATION

<sup>1</sup>Department of Orthopaedic and Trauma Surgery, Inselspital, University of Bern, Bern, Switzerland.

<sup>2</sup>Department of Diagnostic, Interventional and Pediatric Radiology University Hospital of Bern, Inselspital, University of Bern, Bern, Switzerland.

Correspondence should be sent to: Markus S. Hanke, Department of Orthopaedic and Trauma Surgery, Inselspital, University of Bern, Freiburgstrasse, 3010 Bern, Switzerland.

Email: markus.hanke@insel.ch.

**ICMJE CONFLICT OF INTEREST STATEMENT**

The authors declare no conflict of interest relevant to this work.

**FUNDING STATEMENT**

No benefits in any form have been received or will be received from a commercial party related directly or indirectly to the subject of this article.

**OPEN ACCESS**

© 2021 The author(s)

This article is distributed under the terms of the Creative Commons Attribution-Non Commercial 4.0 International (CC BY-NC 4.0) licence (<https://creativecommons.org/licenses/by-nc/4.0/>) which permits non-commercial use, reproduction and distribution of the work without further permission provided the original work is attributed.

**REFERENCES**

- Hale RF, Melugin HP, Zhou J, et al.** Incidence of femoroacetabular impingement and surgical management trends over time. *Am J Sports Med* 2021;49:35–41.
- Ganz R, Parvizi J, Beck M, Leunig M, Nötzli H, Siebenrock KA.** Femoroacetabular impingement: a cause for osteoarthritis of the hip. *Clin Orthop Relat Res* 2003;417:112–120.
- Ito K, Leunig M, Ganz R.** Histopathologic features of the acetabular labrum in femoroacetabular impingement. *Clin Orthop Relat Res* 2004;429:262–271.
- Ganz R, Gill TJ, Gautier E, Ganz K, Krügel N, Berlemann U.** Surgical dislocation of the adult hip a technique with full access to the femoral head and acetabulum without the risk of avascular necrosis. *J Bone Joint Surg Br* 2001;83:1119–1124.
- Tannast M, Siebenrock KA, Anderson SE.** Femoroacetabular impingement: radiographic diagnosis—what the radiologist should know. *AJR Am J Roentgenol* 2007;188:1540–1552.
- Schmaranzer F, Cerezal L, Llopis E.** Conventional and arthrographic magnetic resonance techniques for hip evaluation: what the radiologist should know. *Semin Musculoskelet Radiol* 2019;23:227–251.
- Sutter R, Dietrich TJ, Zingg PO, Pfirrmann CWA.** Femoral antetorsion: comparing asymptomatic volunteers and patients with femoroacetabular impingement. *Radiology* 2012;263:475–483.
- Schmaranzer F, Todorski IAS, Lerch TD, Schwab J, Cullmann-Bastian J, Tannast M.** Intra-articular lesions: imaging and surgical correlation. *Semin Musculoskelet Radiol* 2017;21:487–506.
- Dudda M, Albers C, Mamisch TC, Werlen S, Beck M.** Do normal radiographs exclude asphericity of the femoral head-neck junction? *Clin Orthop Relat Res* 2009;467:651–659.
- Klenke FM, Hoffmann DB, Cross BJ, Siebenrock KA.** Validation of a standardized mapping system of the hip joint for radial MRA sequencing. *Skeletal Radiol* 2015;44:339–343.
- Sutter R, Zubler V, Hoffmann A, et al.** Hip MRI: how useful is intraarticular contrast material for evaluating surgically proven lesions of the labrum and articular cartilage? *AJR Am J Roentgenol* 2014;202:160–169.
- Tian C-Y, Wang J-Q, Zheng Z-Z, Ren A-H.** 3.0 T conventional hip MR and hip MR arthrography for the acetabular labral tears confirmed by arthroscopy. *Eur J Radiol* 2014;83:1822–1827.
- Chopra A, Grainger AJ, Dube B, et al.** Comparative reliability and diagnostic performance of conventional 3T magnetic resonance imaging and 1.5T magnetic resonance arthrography for the evaluation of internal derangement of the hip. *Eur Radiol* 2018;28:963–971.
- Hanke MS, Steppacher SD, Anwander H, Werlen S, Siebenrock KA, Tannast M.** What MRI findings predict failure 10 years after surgery for femoroacetabular impingement? *Clin Orthop Relat Res* 2017;475:1192–1207.
- Schmaranzer F, Klauser A, Kogler M, et al.** Improving visualization of the central compartment of the hip with direct MR arthrography under axial leg traction: a feasibility study. *Acad Radiol* 2014;21:1240–1247.
- Schmaranzer F, Klauser A, Kogler M, et al.** Diagnostic performance of direct traction MR arthrography of the hip: detection of chondral and labral lesions with arthroscopic comparison. *Eur Radiol* 2015;25:1721–1730.
- Schmaranzer F, Klauser A, Kogler M, et al.** MR arthrography of the hip with and without leg traction: assessing the diagnostic performance in detection of ligamentum teres lesions with arthroscopic correlation. *Eur J Radiol* 2016;85:489–497.
- Schmaranzer F, Lerch TD, Strasser U, Vavron P, Schmaranzer E, Tannast M.** Usefulness of MR arthrography of the hip with and without leg traction in detection of intra-articular bodies. *Acad Radiol* 2019;26:e252–e259.
- Garbus DS, Masri BA, Haddad F, Duncan CP.** Clinical and radiographic assessment of the young adult with symptomatic hip dysplasia. *Clin Orthop Relat Res* 2004;418:18–22.
- Perets I, Chaharbakhshi EO, Hartigan DE, Ortiz-Declet V, Mu B, Domb BG.** The correlation between arthroscopically defined acetabular cartilage defects and a proposed preoperative delayed gadolinium-enhanced magnetic resonance imaging of cartilage index in hips of patients with femoroacetabular impingement syndrome. *Arthroscopy* 2018;34:1202–1212.
- Ben-Eliezer N, Raya JG, Babb JS, Youm T, Sodickson DK, Lattanzi R.** A new method for cartilage evaluation in femoroacetabular impingement using quantitative T2 magnetic resonance imaging: preliminary validation against arthroscopic findings. *Cartilage* 2019; <https://doi.org/10.1177/1947603519870852>. [Epub ahead of print]
- Tannast M, Kubiak-Langer M, Langlotz F, Puls M, Murphy SB, Siebenrock KA.** Noninvasive three-dimensional assessment of femoroacetabular impingement. *J Orthop Res* 2007;25:122–131.
- Siebenrock KA, Steppacher SD, Haefeli PC, Schwab JM, Tannast M.** Valgus hip with high antetorsion causes pain through posterior extraarticular FAI. *Clin Orthop Relat Res* 2013;471:3774–3780.
- Lerch TD, Degonda C, Schmaranzer F, et al.** Patient-specific 3-D magnetic resonance imaging-based dynamic simulation of hip impingement and range of motion can replace 3-D computed tomography-based simulation for patients with femoroacetabular impingement: implications for planning open hip preservation surgery and hip arthroscopy. *Am J Sports Med* 2019;47:2966–2977.
- Schmaranzer F, Helfenstein R, Zeng G, et al.** Automatic MRI-based three-dimensional models of hip cartilage provide improved morphologic and biochemical analysis. *Clin Orthop Relat Res* 2019;477:1036–1052.
- Hesper T, Neugroda C, Schleich C, et al.** T2\*-mapping of acetabular cartilage in patients with femoroacetabular impingement at 3 Tesla: comparative analysis with arthroscopic findings. *Cartilage* 2018;9:118–126.
- Kyin C, Maldonado DR, Go CC, Shapira J, Lall AC, Domb BG.** Mid- to long-term outcomes of hip arthroscopy: a systematic review. *Arthroscopy* 2020;50:749–8063(20)30828–8.

- 28. Cvetanovich GL, Chalmers PN, Levy DM, et al.** Hip arthroscopy surgical volume trends and 30-day postoperative complications. *Arthroscopy* 2016;32:1286–1292.
- 29. Carulli C, Schiavo A, Rigon A, De Marchi W, Innocenti M, Meccariello L, et al.** Rare and uncommon diseases of the hip: arthroscopic treatment. *Med Glas (Zenica)* 2021;18.
- 30. Disegni E, Martinot P, Dartus J, et al.** Hip arthroscopy in France: an epidemiological study of postoperative care and outcomes involving 3699 patients. *Orthop Traumatol Surg Res* 2021;107:102767.
- 31. Niroopan G, de Sa D, MacDonald A, Burrow S, Larson CM, Ayeni OR.** Hip arthroscopy in trauma: a systematic review of indications, efficacy, and complications. *Arthroscopy* 2016;32:692–703.e1.
- 32. de Sa D, Stephens K, Parmar D, et al.** A comparison of supine and lateral decubitus positions for hip arthroscopy: a systematic review of outcomes and complications. *Arthroscopy* 2016;32:716–725.e8.
- 33. Truntzer JN, Hoppe DJ, Shapiro LM, Abrams GD, Safran M.** Complication rates for hip arthroscopy are underestimated: a population-based study. *Arthroscopy* 2017;33:1194–1201.
- 34. Bedi A.** Editorial commentary: with new technology comes new responsibility: do the complications of hip arthroscopy see us more often than we see them? *Arthroscopy* 2017;33:1202–1203.
- 35. Chen AW, Yuen LC, Ortiz-Declet V, Litrenta J, Maldonado DR, Domb BG.** Selective debridement with labral preservation using narrow indications in the hip: minimum 5-year outcomes with a matched-pair labral repair control group. *Am J Sports Med* 2018;46:297–304.
- 36. Harris JD.** Hip labral repair: options and outcomes. *Curr Rev Musculoskelet Med* 2016;9:361–367.
- 37. Wu Z-X, Ren W-X, Ren Y-M, Tian M-Q.** Arthroscopic labral debridement versus labral repair for patients with femoroacetabular impingement: a meta-analysis. *Medicine (Baltimore)* 2020;99:e20141.
- 38. Duplantier NL, McCulloch PC, Nho SJ, Mather RC III, Lewis BD, Harris JD.** Hip dislocation or subluxation after hip arthroscopy: a systematic review. *Arthroscopy* 2016;32:1428–1434.
- 39. Chandrasekaran S, Darwish N, Close MR, Lodhia P, Suarez-Ahedo C, Domb BG.** Arthroscopic reconstruction of segmental defects of the hip labrum: results in 22 patients with mean 2-year follow-up. *Arthroscopy* 2017;33:1685–1693.
- 40. Domb BG, Kyin C, Rosinsky PJ, et al.** Circumferential labral reconstruction for irreparable labral tears in the primary setting: minimum 2-year outcomes with a nested matched-pair labral repair control group. *Arthroscopy* 2020;36:2583–2597.
- 41. Suarez-Ahedo C, Martin TJ, Walsh JP, Chandrasekaran S, Lodhia P, Domb BG.** Anatomic labral repair in the hip using a knotless tensionable suture anchor. *Arthrosc Tech* 2016;5:e1089–e1094.
- 42. Haddad B, Konan S, Haddad FS.** Debridement versus re-attachment of acetabular labral tears: a review of the literature and quantitative analysis. *Bone Joint J* 2014;96-B:24–30.
- 43. Krych AJ, Thompson M, Knutson Z, Scoon J, Coleman SH.** Arthroscopic labral repair versus selective labral debridement in female patients with femoroacetabular impingement: a prospective randomized study. *Arthroscopy* 2013;29:46–53.
- 44. Larson CM, Giveans MR.** Arthroscopic debridement versus refixation of the acetabular labrum associated with femoroacetabular impingement. *Arthroscopy* 2009;25:369–376.
- 45. Shapira J, Kyin C, Go C, et al.** Indications and outcomes of secondary hip procedures after failed hip arthroscopy: a systematic review. *Arthroscopy* 2020;36:1992–2007.
- 46. Cvetanovich GL, Harris JD, Erickson BJ, Bach BR Jr, Bush-Joseph CA, Nho SJ.** Revision hip arthroscopy: a systematic review of diagnoses, operative findings, and outcomes. *Arthroscopy* 2015;31:1382–1390.
- 47. Sardana V, Philippon MJ, de Sa D, et al.** Revision hip arthroscopy indications and outcomes: a systematic review. *Arthroscopy* 2015;31:2047–2055.
- 48. Ilizaliturri VM Jr.** Complications of arthroscopic femoroacetabular impingement treatment: a review. *Clin Orthop Relat Res* 2009;467:760–768.
- 49. McCarthy JC, Noble PC, Schuck MR, Wright J, Lee J.** The watershed labral lesion: its relationship to early arthritis of the hip. *J Arthroplasty* 2001;16:81–87.
- 50. Mansor Y, Perets I, Close MR, Mu BH, Domb BG.** In search of the spherical femoroplasty: cam overresection leads to inferior functional scores before and after revision hip arthroscopic surgery. *Am J Sports Med* 2018;46:2061–2071.
- 51. Ejnisman L, Philippon MJ, Lertwanich P.** Femoroacetabular impingement: the femoral side. *Clin Sports Med* 2011;30:369–377.
- 52. Ferguson SJ, Bryant JT, Ganz R, Ito K.** An in vitro investigation of the acetabular labral seal in hip joint mechanics. *J Biomech* 2003;36:171–178.
- 53. Sogbein OA, Shah A, Kay J, et al.** Predictors of outcomes after hip arthroscopic surgery for femoroacetabular impingement: a systematic review. *Orthop J Sports Med* 2019;7:2325967119848982.
- 54. Matsuda DK, Khatod M.** Rapidly progressive osteoarthritis after arthroscopic labral repair in patients with hip dysplasia. *Arthroscopy* 2012;28:1738–1743.
- 55. Mei-Dan O, McConkey MO, Brick M.** Catastrophic failure of hip arthroscopy due to iatrogenic instability: can partial division of the ligamentum teres and iliofemoral ligament cause subluxation? *Arthroscopy* 2012;28:440–445.
- 56. Nawabi DH, Degen RM, Fields KG, et al.** Outcomes after arthroscopic treatment of femoroacetabular impingement for patients with borderline hip dysplasia. *Am J Sports Med* 2016;44:1017–1023.
- 57. Parvizi J, Bican O, Bender B, et al.** Arthroscopy for labral tears in patients with developmental dysplasia of the hip: a cautionary note. *J Arthroplasty* 2009;24:110–113.
- 58. Kuroda Y, Saito M, Sunil Kumar KH, Malviya A, Khanduja V.** Hip arthroscopy and borderline developmental dysplasia of the hip: a systematic review. *Arthroscopy* 2020;36:2550–2567.e1.
- 59. Wyatt M, Weidner J, Pfluger D, Beck M.** The Femoro-Epiphyseal Acetabular Roof (FEAR) Index: a new measurement associated with instability in borderline hip dysplasia? *Clin Orthop Relat Res* 2017;475:861–869.
- 60. Sankar WN, Beaulé PE, Clohisy JC, et al.** Labral morphologic characteristics in patients with symptomatic acetabular dysplasia. *Am J Sports Med* 2015;43:2152–2156.
- 61. Henak CR, Abraham CL, Anderson AE, et al.** Patient-specific analysis of cartilage and labrum mechanics in human hips with acetabular dysplasia. *Osteoarthritis Cartilage* 2014;22:210–217.
- 62. Toft F, Anliker E, Beck M.** Is labral hypotrophy correlated with increased acetabular depth? *J Hip Preserv Surg* 2015;2:175–183.
- 63. Haefeli PC, Steppacher SD, Babst D, Siebenrock KA, Tannast M.** An increased iliocapsularis-to-rectus-femoris ratio is suggestive for instability in borderline hips. *Clin Orthop Relat Res* 2015;473:3725–3734.
- 64. Cvetanovich GL, Levy DM, Weber AE, et al.** Do patients with borderline dysplasia have inferior outcomes after hip arthroscopic surgery for femoroacetabular

- impingement compared with patients with normal acetabular coverage? *Am J Sports Med* 2017;45:2116–2124.
- 65. Gautier E, Ganz K, Krügel N, Gill T, Ganz R.** Anatomy of the medial femoral circumflex artery and its surgical implications. *J Bone Joint Surg Br* 2000;82:679–683.
- 66. Tannast M, Macintyre N, Steppacher SD, Hosalkar HS, Ganz R, Siebenrock KA.** A systematic approach to analyse the sequelae of LCPD. *Hip Int* 2013;23:S61–S70.
- 67. Ziebarth K, Milosevic M, Lerch TD, Steppacher SD, Slongo T, Siebenrock KA.** High survivorship and little osteoarthritis at 10-year followup in SCFE patients treated with a modified Dunn procedure. *Clin Orthop Relat Res* 2017;475:1212–1228.
- 68. Tannast M, Krüger A, Mack PW, Powell JN, Hosalkar HS, Siebenrock KA.** Surgical dislocation of the hip for the fixation of acetabular fractures. *J Bone Joint Surg Br* 2010;92:842–852.
- 69. Beck M.** Groin pain after open FAI surgery: the role of intraarticular adhesions. *Clin Orthop Relat Res* 2009;467:769–774.
- 70. Beck M, Leunig M, Parvizi J, Boutier V, Wyss D, Ganz R.** Anterior femoroacetabular impingement: part II. Midterm results of surgical treatment. *Clin Orthop Relat Res* 2004;418:67–73.
- 71. Philippon MJ, Schenker ML, Briggs KK, Kuppersmith DA, Maxwell RB, Stubbs AJ.** Revision hip arthroscopy. *Am J Sports Med* 2007;35:1918–1921.
- 72. Ross JR, Larson CM, Adeoye O, Kelly BT, Bedi A.** Residual deformity is the most common reason for revision hip arthroscopy: a three-dimensional CT study. *Clin Orthop Relat Res* 2015;473:1388–1395.
- 73. Philippon MJ, Schroder E, Souza BG, Briggs KK.** Hip arthroscopy for femoroacetabular impingement in patients aged 50 years or older. *Arthroscopy* 2012;28:59–65.
- 74. Kim CO, Dietrich TJ, Zingg PO, Dora C, Pfirrmann CWA, Sutter R.** Arthroscopic hip surgery: frequency of postoperative MR arthrographic findings in asymptomatic and symptomatic patients. *Radiology* 2017;283:779–788.
- 75. Willimon SC, Briggs KK, Philippon MJ.** Intra-articular adhesions following hip arthroscopy: a risk factor analysis. *Knee Surg Sports Traumatol Arthrosc* 2014;22:822–825.
- 76. Steppacher SD, Anwander H, Zurmühle CA, Tannast M, Siebenrock KA.** Eighty percent of patients with surgical hip dislocation for femoroacetabular impingement have a good clinical result without osteoarthritis progression at 10 years. *Clin Orthop Relat Res* 2015;473:1333–1341.
- 77. Haefeli PC, Marecek GS, Keel MJB, Siebenrock KA, Tannast M.** Patients undergoing surgical hip dislocation for the treatment of acetabular fractures show favourable long-term outcome. *Bone Joint J* 2017;99-B:508–515.
- 78. Ganz R, Klaue K, Vinh TS, Mast JW.** A new periacetabular osteotomy for the treatment of hip dysplasias: technique and preliminary results. *Clin Orthop Relat Res* 1988;232:26–36.
- 79. Siebenrock KA, Schoeniger R, Ganz R.** Anterior femoro-acetabular impingement due to acetabular retroversion: treatment with periacetabular osteotomy. *J Bone Joint Surg Am* 2003;85:278–286.
- 80. Albers CE, Steppacher SD, Ganz R, Tannast M, Siebenrock KA.** Impingement adversely affects 10-year survivorship after periacetabular osteotomy for DDH. *Clin Orthop Relat Res* 2013;471:1602–1614.
- 81. Siebenrock KA, Schaller C, Tannast M, Keel M, Büchler L.** Anteverting periacetabular osteotomy for symptomatic acetabular retroversion: results at ten years. *J Bone Joint Surg Am* 2014;96:1785–1792.
- 82. Zurmühle CA, Anwander H, Albers CE, et al.** Periacetabular osteotomy provides higher survivorship than rim trimming for acetabular retroversion. *Clin Orthop Relat Res* 2017;475:1138–1150.
- 83. Steppacher SD, Tannast M, Ganz R, Siebenrock KA.** Mean 20-year followup of Bernese periacetabular osteotomy. *Clin Orthop Relat Res* 2008;466:1633–1644.
- 84. Lerch TD, Steppacher SD, Liechti EF, Tannast M, Siebenrock KA.** One-third of hips after periacetabular osteotomy survive 30 years with good clinical results, no progression of arthritis, or conversion to THA. *Clin Orthop Relat Res* 2017;475:1154–1168.
- 85. Ali M, Malviya A.** Complications and outcome after periacetabular osteotomy: influence of surgical approach. *Hip Int* 2020;30:4–15.
- 86. Mayer SW, Zelenski NA, Karas V, Xie Z, Olson SA.** High body mass index is related to increased perioperative complications after periacetabular osteotomy. *Am J Orthop* 2018;47.
- 87. Biedermann R, Donnan L, Gabriel A, Wachter R, Krismer M, Behensky H.** Complications and patient satisfaction after periacetabular pelvic osteotomy. *Int Orthop* 2008;32:611–617.
- 88. Zaltz I, Baca G, Kim Y-J, et al.** Complications associated with the periacetabular osteotomy: a prospective multicenter study. *J Bone Joint Surg Am* 2014;96:1967–1974.
- 89. Matta JM, Stover MD, Siebenrock K.** Periacetabular osteotomy through the Smith-Petersen approach. *Clin Orthop Relat Res* 1999;363:21–29.
- 90. Siebenrock KA, Schöll E, Lottenbach M, Ganz R.** Bernese periacetabular osteotomy. *Clin Orthop Relat Res* 1999;363:9–20.
- 91. Murphy S, Deshmukh R.** Periacetabular osteotomy: preoperative radiographic predictors of outcome. *Clin Orthop Relat Res* 2002;405:168–174.
- 92. Peters CL, Erickson JA, Hines JL.** Early results of the Bernese periacetabular osteotomy: the learning curve at an academic medical center. *J Bone Joint Surg Am* 2006;88:1920–1926.
- 93. Novais EN, Duncan S, Nepple J, Pashos G, Schoenecker PL, Clohisy JC.** Do radiographic parameters of dysplasia improve to normal ranges after Bernese periacetabular osteotomy? *Clin Orthop Relat Res* 2017;475:1120–1127.
- 94. Tannast M, Pfander G, Steppacher SD, Mast JW, Ganz R.** Total acetabular retroversion following pelvic osteotomy: presentation, management, and outcome. *Hip Int* 2013;23:S14–S26.
- 95. Buly RL, Sosa BR, Poultsides LA, Caldwell E, Rozbruch SR.** Femoral derotation osteotomy in adults for version abnormalities. *J Am Acad Orthop Surg* 2018;26:e416–e425.
- 96. Lerch TD, Schmaranzer F, Steppacher SD, Ziebarth K, Tannast M, Siebenrock KA.** Most of patients with femoral derotation osteotomy for posterior extraarticular hip impingement and high femoral version would do surgery again. *Hip Int* 2020; <https://doi.org/10.1177/1120700020953100> [Epub ahead of print].
- 97. Lerch TD, Todorski IAS, Steppacher SD, et al.** Prevalence of femoral and acetabular version abnormalities in patients with symptomatic hip disease: a controlled study of 538 hips. *Am J Sports Med* 2018;46:122–134.
- 98. Lerch TD, Schmaranzer F, Hanke MS, et al.** Torsional deformities of the femur in patients with femoroacetabular impingement: dynamic 3D impingement simulation can be helpful for the planning of surgical hip dislocation and hip arthroscopy. *Orthopade* 2020;49:471–481.
- 99. Lerch TD, Boschung A, Todorski IAS, et al.** Femoroacetabular impingement patients with decreased femoral version have different impingement locations and intra- and extraarticular anterior subspine FAI on 3D-CT-based impingement simulation: implications for hip arthroscopy. *Am J Sports Med* 2019;47:3120–3132.

- 100. Kamath AF, Ganz R, Zhang H, Grappiolo G, Leunig M.** Subtrochanteric osteotomy for femoral mal-torsion through a surgical dislocation approach. *J Hip Preserv Surg* 2015;2:65–79.
- 101. Fabricant PD, Fields KG, Taylor SA, Magennis E, Bedi A, Kelly BT.** The effect of femoral and acetabular version on clinical outcomes after arthroscopic femoroacetabular impingement surgery. *J Bone Joint Surg Am* 2015;97:537–543.
- 102. Tönnis D, Heinecke A.** Acetabular and femoral anteversion: relationship with osteoarthritis of the hip. *J Bone Joint Surg Am* 1999;81:1747–1770.
- 103. Svenningsen S, Apalset K, Terjesen T, Anda S.** Osteotomy for femoral anteversion: complications in 95 children. *Acta Orthop Scand* 1989;60:401–405.
- 104. Wilson PD, Jacobs B, Schecter L.** Slipped capital femoral epiphysis: an end-result study. *J Bone Joint Surg Am* 1965;47:1128–1145.
- 105. Loder RT.** Unstable slipped capital femoral epiphysis. *J Pediatr Orthop* 2001;21:694–699.
- 106. Carney BT, Weinstein SL, Noble J.** Long-term follow-up of slipped capital femoral epiphysis. *J Bone Joint Surg Am* 1991;73:667–674.
- 107. Castañeda P, Ponce C, Villareal G, Vidal C.** The natural history of osteoarthritis after a slipped capital femoral epiphysis/the pistol grip deformity. *J Pediatr Orthop* 2013;33:576–582.
- 108. Naseem H, Chatterji S, Tsang K, Hakimi M, Chytas A, Alshryda S.** Treatment of stable slipped capital femoral epiphysis: systematic review and exploratory patient level analysis. *J Orthop Traumatol* 2017;18:379–394.
- 109. Alshryda S, Tsang K, Chytas A, et al.** Evidence based treatment for unstable slipped upper femoral epiphysis: systematic review and exploratory patient level analysis. *Surgeon* 2018;16:46–54.
- 110. Souder CD, Bomar JD, Wenger DR.** The role of capital realignment versus in situ stabilization for the treatment of slipped capital femoral epiphysis. *J Pediatr Orthop* 2014;34:791–798.
- 111. Huber H, Dora C, Ramseier LE, Buck F, Dierauer S.** Adolescent slipped capital femoral epiphysis treated by a modified Dunn osteotomy with surgical hip dislocation. *J Bone Joint Surg Br* 2011;93:833–838.
- 112. Novais EN, Hill MK, Carry PM, Heare TC, Sink EL.** Modified Dunn procedure is superior to in situ pinning for short-term clinical and radiographic improvement in severe stable SCFE. *Clin Orthop Relat Res* 2015;473:2108–2117.
- 113. Sankar WN, Vanderhave KL, Matheney T, Herrera-Soto JA, Karlen JW.** The modified Dunn procedure for unstable slipped capital femoral epiphysis: a multicenter perspective. *J Bone Joint Surg Am* 2013;95:585–591.
- 114. Ziebarth K, Zilkens C, Spencer S, Leunig M, Ganz R, Kim Y-J.** Capital realignment for moderate and severe SCFE using a modified Dunn procedure. *Clin Orthop Relat Res* 2009;467:704–716.
- 115. Madan SS, Cooper AP, Davies AG, Fernandes JA.** The treatment of severe slipped capital femoral epiphysis via the Ganz surgical dislocation and anatomical reduction: a prospective study. *Bone Joint J* 2013;95-B:424–429.
- 116. Slongo T, Kakaty D, Krause F, Ziebarth K.** Treatment of slipped capital femoral epiphysis with a modified Dunn procedure. *J Bone Joint Surg Am* 2010;92:2898–2908.
- 117. Upasani VV, Matheney TH, Spencer SA, Kim Y-J, Millis MB, Kasser JR.** Complications after modified Dunn osteotomy for the treatment of adolescent slipped capital femoral epiphysis. *J Pediatr Orthop* 2014;34:661–667.
- 118. Sink EL, Leunig M, Zalt I, Gilbert JC, Clohisy J; Academic Network for Conservational Hip Outcomes Research Group.** Reliability of a complication classification system for orthopaedic surgery. *Clin Orthop Relat Res* 2012;470:2220–2226.
- 119. Weber AE, Harris JD, Nho SJ.** Complications in hip arthroscopy: a systematic review and strategies for prevention. *Sports Med Arthrosc Rev* 2015;23:187–193.
- 120. Randelli F, Pierannunzi L, Banci L, Ragone V, Aliprandi A, Buly R.** Heterotopic ossifications after arthroscopic management of femoroacetabular impingement: the role of NSAID prophylaxis. *J Orthop Traumatol* 2010;11:245–250.
- 121. Larson CM, Giveans MR.** Arthroscopic management of femoroacetabular impingement: early outcomes measures. *Arthroscopy* 2008;24:540–546.
- 122. Thomas Byrd JW.** Complications associated with hip arthroscopy. In: Thomas Byrd JW, ed. *Operative Hip Arthroscopy*. New York, NY: Springer, 2005:229–235. [https://link.springer.com/chapter/10.1007/0-387-27047-7\\_16](https://link.springer.com/chapter/10.1007/0-387-27047-7_16)
- 123. Sampson TG.** Complications of hip arthroscopy. *Clin Sports Med* 2001;20:831–835.
- 124. McCarthy JC, Lee JA.** Hip arthroscopy: indications, outcomes, and complications. *Instr Course Lect* 2006;55:301–308.
- 125. Badylak JS, Keene JS.** Do iatrogenic punctures of the labrum affect the clinical results of hip arthroscopy? *Arthroscopy* 2011;27:761–767.
- 126. Parodi D, Tobar C, Valderrama J, et al.** Hip arthroscopy and hypothermia. *Arthroscopy* 2012;28:924–928.
- 127. Lo Y-P, Chan Y-S, Lien L-C, Lee MSS, Hsu K-Y, Shih C-H.** Complications of hip arthroscopy: analysis of seventy three cases. *Chang Gung Med J* 2006;29:86–92.
- 128. Gedouin J-E, May O, Bonin N, et al; French Arthroscopy Society.** Assessment of arthroscopic management of femoroacetabular impingement: a prospective multicenter study. *Orthop Traumatol Surg Res* 2010;96:S59–S67.
- 129. Clarke MT, Arora A, Villar RN.** Hip arthroscopy: complications in 1054 cases. *Clin Orthop Relat Res* 2003;406:84–88.
- 130. Salvo JP, Troxell CR, Duggan DP.** Incidence of venous thromboembolic disease following hip arthroscopy. *Orthopedics* 2010;33:664.
- 131. Souza BGS, Dani WS, Honda EK, et al.** Do complications in hip arthroscopy change with experience? *Arthroscopy* 2010;26:1053–1057.
- 132. Sink EL, Beaulé PE, Sucato D, et al.** Multicenter study of complications following surgical dislocation of the hip. *J Bone Joint Surg Am* 2011;93:1132–1136.
- 133. Steppacher SD, Huemmer C, Schwab JM, Tannast M, Siebenrock KA.** Surgical hip dislocation for treatment of femoroacetabular impingement: factors predicting 5-year survivorship. *Clin Orthop Relat Res* 2014;472:337–348.
- 134. Beaulé PE, Le Duff MJ, Zaragoza E.** Quality of life following femoral head-neck osteochondroplasty for femoroacetabular impingement. *J Bone Joint Surg Am* 2007;89:773–779.
- 135. Naal FD, Miozzari HH, Schär M, Hesper T, Nötzli HP.** Midterm results of surgical hip dislocation for the treatment of femoroacetabular impingement. *Am J Sports Med* 2012;40:1501–1510.
- 136. Thawrani D, Sucato DJ, Podeszwa DA, DeLaRocha A.** Complications associated with the Bernese periacetabular osteotomy for hip dysplasia in adolescents. *J Bone Joint Surg Am* 2010;92:1707–1714.
- 137. Hussell JG, Rodriguez JA, Ganz R.** Technical complications of the Bernese periacetabular osteotomy. *Clin Orthop Relat Res* 1999;363:81–92.
- 138. Trumble SJ, Mayo KA, Mast JW.** The periacetabular osteotomy: Minimum 2 year followup in more than 100 hips. *Clin Orthop Relat Res* 1999;363:54–63.
- 139. Crockarell J Jr, Trousdale RT, Cabanela ME, Berry DJ.** Early experience and results with the periacetabular osteotomy: the Mayo Clinic experience. *Clin Orthop Relat Res* 1999;363:45–53.