

Posterior Extra-articular Ischiofemoral Impingement Can Be Caused by the Lesser and Greater Trochanter in Patients With Increased Femoral Version



Dynamic 3D CT-Based Hip Impingement Simulation of a Modified FABER Test

Till D. Lerch,^{*†‡} MD, PhD, Sébastien Zwingelstein,^{†‡} MD, Florian Schmaranzer,^{†‡} MD, PhD, Adam Boschung,[†] MD, Markus S. Hanke,[†] MD, Inga A.S. Todorski,[‡] MD, Simon D. Steppacher,[†] MD, Nicolas Gerber,[§] PhD, Guodong Zeng,[§] PhD, Klaus A. Siebenrock,[†] MD, and Moritz Tannast,^{†||} MD

Investigation performed at Inselspital Bern, Bern University Hospital, University of Bern, Switzerland

Background: Posterior extra-articular hip impingement has been described for valgus hips with increased femoral version (FV). These patients can present clinically with lack of external rotation (ER) and extension and with a positive posterior impingement test. But we do not know the effect of the combination of deformities, and the impingement location in early flexion is unknown.

Purpose: To evaluate patient-specific 3-dimensional computed tomography (3D CT) scans of hips with increased FV and control hips for differences in range of motion, location and prevalence of osseous posterior intra- and extra-articular hip impingement.

Study Design: Case series; Level of evidence, 4.

Methods: Osseous 3D models based on segmentation of 3D CT scans were analyzed for 52 hips (38 symptomatic patients) with positive posterior impingement test and increased FV (>35°). There were 26 hips with an increased McKibbin instability index >70 (unstable hips). Patients were mainly female (96%), with an age range of 18 to 45 years. Of them, 21 hips had isolated increased FV (>35°); 22 hips had increased FV and increased acetabular version (AV; >25°); and 9 valgus hips (caput-collum-diaphyseal angle >139°) had increased FV and increased AV. The control group consisted of 20 hips with normal FV, normal AV, and no valgus (caput-collum-diaphyseal angle <139°). Validated 3D CT-based collision detection software for impingement simulation was used to calculate impingement-free range of motion and location of hip impingement. Surgical treatment was performed after the 3D CT-based impingement simulation in 27 hips (52%).

Results: Hips with increased FV had significantly ($P < .001$) decreased extension and ER at 90° of flexion as compared with the control group. Posterior impingement was extra-articular (92%) in hips with increased FV. Valgus hips with increased FV and AV had combined intra- and extra-articular impingement. Posterior hip impingement occurred between the ischium and the lesser trochanter at 20° of extension and 20° of ER. Impingement was located between the ischium and the greater trochanter or intertrochanteric area at 20° of flexion and 40° of ER, with a modification of the flexion-abduction-ER (FABER) test.

Conclusion: Posterior extra-articular ischiofemoral hip impingement can be caused by the lesser and greater trochanter or the intertrochanteric region. We recommend performing the modified FABER test during clinical examination in addition to the posterior impingement test for female patients with high FV. In addition, 3D CT can help for surgical planning, such as femoral derotation osteotomy and/or hip arthroscopy or resection of the lesser trochanter.

Keywords: extra-articular hip impingement; femoroacetabular impingement (FAI); femoral version; femoral torsion; hip arthroscopy; hip instability; ischiofemoral hip impingement

Anterior femoroacetabular impingement (FAI) is an osseous conflict that is increasingly recognized as causing hip pain, limited hip motion, and premature osteoarthritis in

young and active patients.^{17,18} In 2003,¹⁷ only cam, pincer, and mixed-type FAI were described as causes for anterior hip impingement, without investigation of abnormal femoral version (FV) such as increased or decreased FV. However, it has been shown that both increased and decreased FV can significantly impair patient-related outcomes after hip arthroscopy for FAI.^{15,16} For valgus hips with increased

The Orthopaedic Journal of Sports Medicine, 9(5), 2325967121990629
DOI: 10.1177/2325967121990629
© The Author(s) 2021

This open-access article is published and distributed under the Creative Commons Attribution - NonCommercial - No Derivatives License (<https://creativecommons.org/licenses/by-nc-nd/4.0/>), which permits the noncommercial use, distribution, and reproduction of the article in any medium, provided the original author and source are credited. You may not alter, transform, or build upon this article without the permission of the Author(s). For article reuse guidelines, please visit SAGE's website at <http://www.sagepub.com/journals-permissions>.

FV, posterior extra-articular hip impingement⁵⁸ has been described. These hips are lacking external rotation (ER) and extension and exhibit a positive posterior impingement test⁵⁸ during clinical examination. FV and acetabular version (AV) have a significant influence on hip range of motion (ROM), especially internal rotation (IR) and ER,^{9,11,24} muscular lever arms,⁵² and foot position.^{2,7} Analyzing FV and AV together results in the McKibbin instability index³⁶ (also called the COTAV index¹¹), in which a high McKibbin index is associated with hip instability.³⁶ In a 2018 study, hips with increased FV and AV abnormalities were highly prevalent in symptomatic hips with FAI or hip dysplasia.³³

Physical impairment and sports activity limitations are common in patients with anterior FAI¹⁴ because ROM is typically decreased in these patients.¹⁸ Posterior hip impingement decreases extension, which can impair walking with long strides. Diagnosis of FAI is challenging, and an objective assessment for ROM and location of impingement is missing. In a 2015 systematic review investigating clinical tests for the diagnosis of FAI, the authors concluded that more specific diagnostic tests are needed for FAI.⁴⁴ Objective analysis of the osseous limitations of hip motion is possible with 3-dimensional computed tomography (3D CT)-based virtual impingement simulations.^{6,48,65} To simulate ROM for complex or combined deformities (eg, hip dysplasia or valgus hips with increased FV), Puls et al⁴³ described the *equidistant method*, which they reported has a higher accuracy than other presented motion algorithms. Increased FV has been detected as a cause for posterior extra-articular hip impingement.⁵⁸ The impingement conflict occurred between the tip of the lesser trochanter and the os ischium (ischiofemoral impingement) using this method. Theoretically, valgus or increased AV could aggravate posterior extra-articular ischiofemoral impingement in the presence of increased FV²⁴ (Figure 1). In addition, the exact impingement location in early flexion is unknown. The combination of increased FV with increased AV and the effect of increased McKibbin index are poorly understood.⁵⁸ We evaluated patient-specific 3D CT with this combination because the exact location of impingement cannot be studied using standard 2-dimensional imaging.

The purpose of the current study was to use patient-specific 3D CT to examine whether differences exist among hips with isolated increased FV, hips with increased FV and AV, and valgus hips with increased FV and AV with regard to (study question 1) ROM, (study question 2) the

location of the osseous posterior intra- and extra-articular impingement, and (study question 3) the prevalence of posterior extra-articular impingement.

METHODS

This retrospective comparative analysis was approved by a local institutional review board and included 52 hips in 38 patients.

Group Allocation

All symptomatic patients with increased FV presented with hip pain at the time of image acquisition and had a positive posterior impingement test⁶⁷ and decreased ER during clinical examination. We retrospectively reviewed the case files of all patients with posterior hip impingement seen in our outpatient clinic between January 2014 and December 2016. Inclusion criteria for all hips in the study group were FV >35° (Figure 1) in the presence of a nondysplastic acetabulum and a CT scan of the pelvis.⁶⁹ Exclusion criteria were a lateral center-edge angle (LCEA) <18° or >39° with an acetabular index >14°, protrusio acetabuli, severe acetabular overcoverage, and osteoarthritis of Tönnis grade ≥1.^{35,64,68,69}

This resulted in 52 hips with elevated FV, of which 26 had a McKibbin index >70. The patient-specific 3D models of these 2 groups were compared with those of a control group of 20 hips (Table 1). In addition, we divided the 52 hips into 3 subgroups (Appendix Table A1): (1) 21 hips with isolated increased FV (>35°) and normal AV (10°-25° according to Tönnis⁶⁹) and the remaining 31 hips with increased FV (>35°) and elevated AV (>25°) (Figure 1), subdivided into (2) 22 hips with increased FV and AV and (3) 9 hips with valgus morphology (neck-shaft angle >139°)⁶⁹ with increased FV and AV.

The 52 hips with elevated FV were mainly from female patients (96%) with an age range of 18 to 45 years. The 3 groups differed significantly in terms of age, sex, FV, AV, and McKibbin index ($P \leq .001$ for all) (Table 1). Regarding the 3 subgroups, for hips with isolated FV, the mean FV was 50° ± 8° and mean AV was 20° ± 3°. For hips with increased FV and AV, the mean FV was 42° ± 9°, and the mean AV was 29° ± 3°. For valgus hips with increased FV and AV, the mean FV was 53° ± 11°, and the mean AV was 28° ± 3° ($P \leq .001$ for all) (Appendix Table A1).

The control group included hips without cam- or pincer-type deformity with normal FV (10°-25°). The 20 hips of the control group were available from a previous study,²⁷ selected from the contralateral hips of 146 patients

*Address correspondence to *Till D. Lerch, MD, PhD, Department of Diagnostic, Interventional and Paediatric Radiology, Inselspital, Freiburgstrasse, 3010 Bern, Switzerland (email: till.lerch@insel.ch).

[†]Department of Orthopaedic Surgery, Inselspital, Bern University Hospital, University of Bern, Bern, Switzerland.

[‡]Department of Diagnostic, Interventional and Paediatric Radiology, Inselspital, Bern University Hospital, University of Bern, Bern, Switzerland.

[§]Sitem Center for Translational Medicine and Biomedical Entrepreneurship, University of Bern, Bern, Switzerland.

^{||}Department of Orthopaedic Surgery and Traumatology, Fribourg Cantonal Hospital, University of Fribourg, Fribourg, Switzerland.

Final revision submitted September 3, 2020; accepted October 2, 2020.

One or more of the authors has declared the following potential conflict of interest or source of funding: M.T. and T.D.L. have received funding from the Swiss National Science Foundation. AOSSM checks author disclosures against the Open Payments Database (OPD). AOSSM has not conducted an independent investigation on the OPD and disclaims any liability or responsibility relating thereto.

Ethical approval for this study was obtained from the ethics commission of the Canton of Bern.

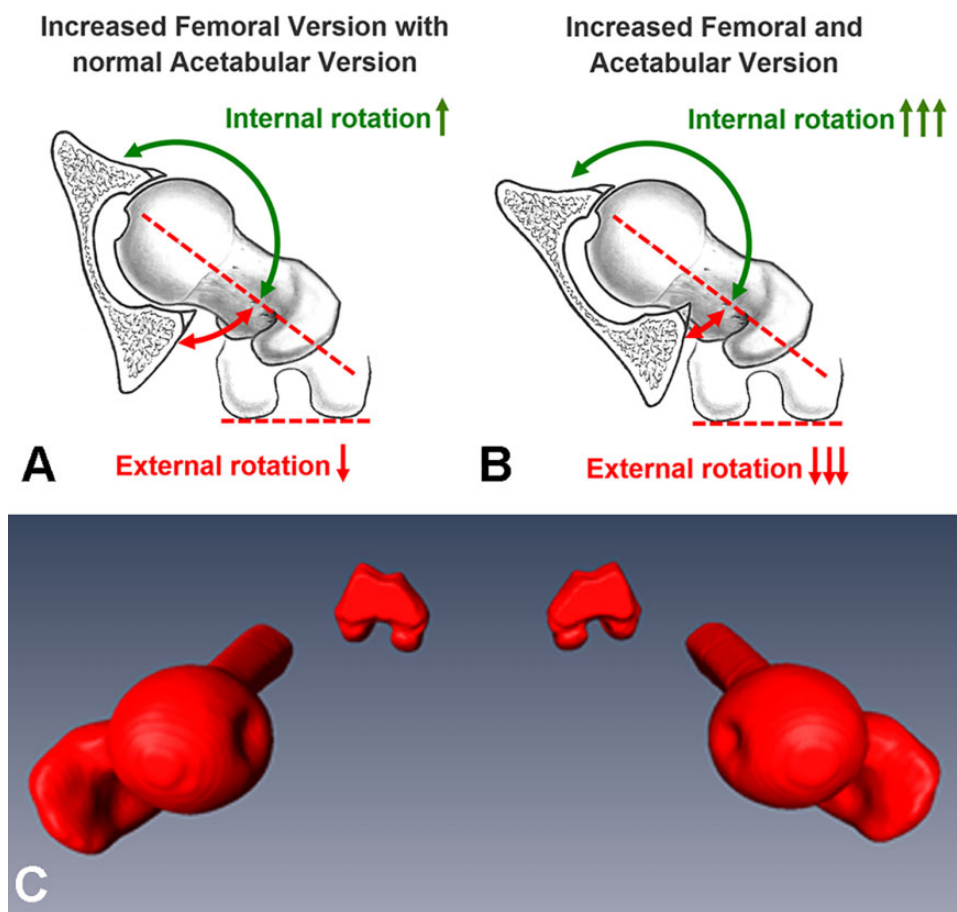


Figure 1. Schematic views of the difference between (A) hips with isolated increased femoral version and (B) hips with increased femoral version and acetabular version. (C) The 3-dimensional models of a patient with bilateral femoral version of 49°. Figure 1C reprinted with permission from Lerch et al. Torsional deformities of the femur in patients with femoroacetabular impingement: dynamic 3D impingement simulation can be helpful for the planning of surgical hip dislocation and hip arthroscopy [in German]. *Orthopade.* 2020;49(6):471-481.

TABLE 1
Demographic and Radiographic Data of All Hips, Hips With McKibbin Index >70, and Controls^a

	All Hips With Increased FV	Hips With McKibbin Index >70	Control	Overall P Value
Hips:patients, No.	52:38	26:18	20:20	
Age, y	30 ± 11 (18-45) ^b	29 ± 13 (18-45) ^b	56 ± 11 (31-74)	<.001
Sex: female, %	96 ^b	92 ^b	48	<.001
Side: right, %	55	50	71	.642
Height, cm	170 ± 7 (161-183)	170 ± 7 (161-180)	167 ± 10 (158-195)	.568
Weight, kg	66 ± 11 (50-100)	63 ± 8 (50-76)	75 ± 14 (49-104)	.146
Body mass index, kg/m ²	23 ± 3 (18-35)	22 ± 2 (18-26)	27 ± 4 (20-36)	.386
Angle, deg				
Lateral center edge	28 ± 6 (19-39)	28 ± 7 (19-39)	31 ± 5 (25-39)	.428
Neck-shaft	136 ± 8 (126-159)	138 ± 8 (126-155)	131 ± 5 (122-139)	.076
Alpha	52 ± 9 (35-70)	50 ± 9 (35-70)	42 ± 5 (36-50)	.095
FV, deg	47 ± 10 (35-68) ^b	55 ± 7 (43-68) ^b	19 ± 4 (11-24)	<.001
AV, deg	25 ± 5 (15-36) ^b	25 ± 4 (18-33) ^b	21 ± 5 (11-25)	.001
McKibbin index	72 ± 10 (53-98) ^b	80 ± 7 (71-98) ^b	40 ± 7 (23-49)	<.001

^aValues are displayed as mean ± SD (range) unless noted otherwise. Level of significance was adjusted for 3 groups (.05/3 = .016) with the Bonferroni correction. McKibbin index: sum of the femoral and acetabular version. AV, acetabular version; FV, femoral version.

^bStatistically significant difference vs control group (P < .016).

undergoing CT-based computer-assisted total hip arthroplasty at another institution, and considered normal. The mean age of patients in the control group was 56 years. Patients with the following features were excluded: osteoarthritis grade ≥ 1 according to Tönnis ($n = 40$), LCEA $< 25^\circ$ or $> 39^\circ$ ($n = 25$), total hip arthroplasty or total knee arthroplasty ($n = 10$), pain ($n = 4$), previous hip surgery ($n = 3$), pistol grip deformity ($n = 13$), coxa profunda ($n = 13$), coxa vara or valga ($n = 1$), acetabular retroversion ($n = 4$), protrusio acetabuli ($n = 2$), alpha angle $> 50^\circ$ ($n = 4$), FV $> 25^\circ$ ($n = 5$), and femoral retroversion FV $< 10^\circ$ ($n = 2$).

Clinical Evaluation

For all hips, the diagnosis of hip impingement was based on the current recommendations of a positive correlation among symptoms, findings during physical examination, and radiographic findings,^{53,67} as recommended by the Warwick Agreement.¹⁸ Routine examination included ROM in the supine and prone positions (Appendix Table A2), assessment of abductor strength, and general joint laxity using the self-reported Beighton score.³⁹ Routine clinical examination included the anterior impingement test (pain in forced flexion, IR, and adduction, also called FADIR¹⁰ [flexion-adduction-IR] test), posterior impingement test⁶⁷ (pain in forced extension and ER), and the FABER⁴ (flexion-abduction-ER) test and modification of the FABER test (only flexion and ER). The posterior impingement test was positive in all 52 hips with increased FV and was performed in the supine position in hyperextension as described previously.⁶⁷ These patients had a positive anterior apprehension sign in the posterior impingement position. A minority of patients had a positive FABER test. A positive posterior impingement test and/or positive FABER test was used as an indicator for hip instability. Clinical ROM before the CT scan showed IR of 61° and decreased ER of 17° , as examined in the prone position. Three patients reported anterior hip instability during sport (skiing, wind surfing, and karate kick), and 2 patients had osteochondral lesion of the femoral head. One patient had a documented anterior dislocation of the hip during karate kicking, which was treated with closed reduction.³⁰ Previous hip arthroscopy was performed at other institutions in 5 patients (10%) before the CT scan. One patient had undergone 2 previous hip arthroscopies. In 1 patient, labrum resection had been performed during previous hip arthroscopy.

Surgical Treatment After 3D CT

Surgical treatment was performed in our institution in 27 hips (52%) after the 3D CT-based impingement simulation. This included surgical hip dislocation with a femoral derotation osteotomy in 22 hips (42%; mean derotation correction of 19°). Before femoral derotation osteotomy, intraoperative ROM and impingement testing was performed to test for posterior extra-articular hip impingement in ER and extension. If anterior hip instability in ER and extension could be observed intraoperatively, a femoral derotation osteotomy was performed (see

Supplemental Video 1, available online). Additional concomitant cam resection was performed for 15 hips. Three hips underwent varus correction with femoral derotation. For 3 patients, concomitant cartilage treatment was performed: 1 with autologous matrix-induced chondrogenesis on the femoral head and 2 with acetabular subchondral drilling. In 1 hip, an arthroscopy was performed. In 1 hip, a surgical hip dislocation with a femoral neck osteotomy was performed. The remaining 25 hips were treated non-surgically with physical therapy.

Imaging

Increased FV was defined as $> 35^\circ$.⁶⁹ The measurement of FV (Figure 2A) was performed on preoperative CT scans using the method by Murphy et al.³⁸ The Murphy method has shown smaller variability and higher accuracy⁵⁵ than biplane radiographs for the measurement of FV.²⁶ Calculation of AV was performed on axial CT scans on the level of the center of the femoral head⁶⁹ (Figure 2B), and for the calculation of the McKibbin index, FV and AV were added. The neck-shaft angle was measured as described by others.⁶⁹ A cam-type deformity²⁹ was defined as an alpha angle⁴¹ $> 50^\circ$ on lateral radiographs. Pincer-type deformity was defined as an LCEA $> 34^\circ$ with an alpha angle $< 50^\circ$.⁶⁴ A mixed-type deformity was defined as the combination of an alpha angle $> 50^\circ$ and an LCEA $> 34^\circ$. In total, 9 hips exhibited a pincer-type deformity. For the group with isolated increased FV, 48% had a cam morphology. This was present in 59% of the patients with increased FV and AV and in 33% of valgus hips with increased FV and AV.

All patients underwent standardized anteroposterior and lateral radiographs. A preoperative CT scan of the entire pelvis and the knee joint^{42,43} was performed according to a previously described protocol.⁶¹ Some of the patients underwent magnetic resonance arthrography with or without axial leg traction.⁵⁶ The magnetic resonance imaging (MRI) of these patients included axial turbo inversion recovery magnitude of the pelvis; unilateral axial T1-weighted turbo spin echo of the hip; and unilateral coronal, sagittal, and radial proton density-weighted turbo spin echo of the hip.²⁸ The mean ischiofemoral distance of the patients with increased FV was 14 mm. A minority of the patients had edema of the muscle quadratus femoris. None of the patients with a positive FABER test exhibited edema of the sacroiliac joint (no sacroiliitis).

3D Models of the Hip Joint

We then reconstructed an osseous 3D model of the CT of the pelvis and the femur with the help of the Amira Visualization Toolkit (Visage Imaging Inc). Using the patient-specific 3D models of 52 hips of the CT scans, we compared the virtual ROM and the location of hip impingement of all patients among the 3 groups.

Collision Detection Software

CT-based patient-specific 3D models of 52 hips were evaluated using a validated 3D collision detection software

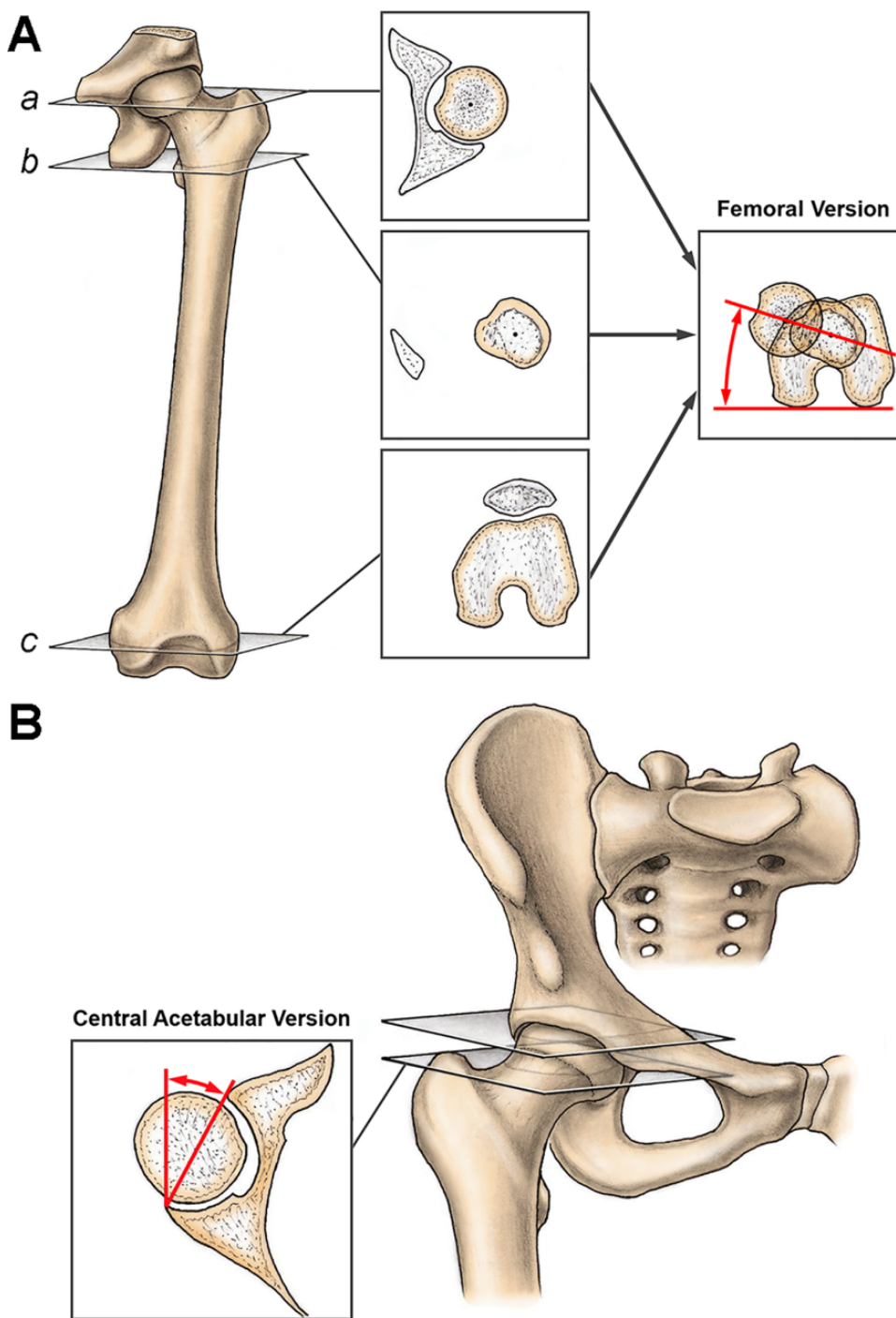


Figure 2. Measurement of (A) femoral and (B) acetabular version. Femoral version was measured on 3 axial computed tomography slices according to the method described by Murphy et al³⁸ (a-c). Acetabular version was calculated on axial computed tomography scans on the level of the center of the femoral head.⁶⁹ Figure reprinted with permission from Lerch et al. Prevalence of femoral and acetabular version abnormalities in patients with symptomatic hip disease: a controlled study of 538 hips. *Am J Sports Med.* 2018;46(1):122-134.

program (HipMotion; University of Bern) to quantify the hip ROM and the acetabular and femoral location of impingement.^{43,65} Each hip joint was then virtually simulated with the help of previously validated software⁶⁵; details of the

software program are described in Table 2. This method was designed for virtual analysis of FAI.⁴³ Based on a validation study including soft tissue, an impingement conflict can be detected with a mean accuracy of <math><3^\circ</math>.⁴³

Using this virtual analysis, we calculated the ROM for the following motions for all 3 groups: flexion and extension, IR and ER (at 0° and 90° of flexion), and abduction and adduction. ER in extension was calculated (Table 3). For calculation of location of impingement, ER at 20° of extension was calculated. In a validation study of this software, intra- and interobserver agreement was excellent (>0.9) for all hip motions except ER at 90° of flexion, while moderate agreement³⁷ was found for the interobserver intraclass correlation coefficient.⁶⁵ Furthermore,

we evaluated combinations of hip ROM that corresponded to the widely used posterior impingement test, in which ER was calculated in 1° steps between 5° of flexion and 20° of extension (Appendix Figure A1). The impingement zones for the posterior impingement test were calculated with 10° and 20° of adduction for the 3 aforementioned subgroups (Appendix Figure A2). In addition, ER was calculated at 20° of flexion for simulation of the modified FABER test. The impingement location was determined by the distribution of all impingement points for 3 specific combinations of motion for an individual patient: 20° of extension with 20° of ER (Figure 3A), 20° of flexion with 30° of ER (Figure 3B), and 20° of flexion with 40° of ER (Figure 3C). In addition, the impingement location was specified as extra- or intra-articular (Table 2). The software uses automatic acetabular rim detection⁴² and best-fit sphere algorithms to identify the femoral head center.³⁴

TABLE 2
Details of the Collision Detection Software Using
3-Dimensional Models of the Hip Joint

Software Tool	Description/Definition
Anterior pelvic plane was used as acetabular reference coordinate system	Defined by landmarks of the anterosuperior iliac spines and pubic tubercles ^{61,65,66}
Femoral reference coordinate system	Defined by landmarks of the femoral head center, knee center, and both femoral condyles ³⁸
Automatic rim detection ⁴²	For automatic detection of the osseous acetabular rim
Best-fitting sphere algorithm	For identification of the femoral head center
Equidistant method	For virtual impingement-free hip motion analysis ⁴³
Location of the impingement zones	Calculated using a previously described clock face system ^{61,63}
Clock face coordinate system	3 o'clock was defined anteriorly for right and left hips; 6 o'clock represents the acetabular notch
Intra-articular impingement	Intra-articular locations included the acetabular rim on the acetabular side and the femoral head and neck on the femoral side

Statistical Analysis

We tested the data for normal distribution with the Kolmogorov-Smirnov test. If the parameters were normally distributed, we used parametric tests; if there was no normal distribution, nonparametric tests for comparison were used. For continuous variables such as ROM, analysis of variance was used to compare 3 groups. To compare demographic and radiographic data or location of impingement among the 3 groups, we used a Kruskal-Wallis test; if significant, we used the Mann-Whitney *U* test to compare each of the 3 combinations of 2 groups. To compare binominal demographic data and the prevalence of extra-articular impingement among the 3 groups, we used a chi-square test; if significant, we used the Fisher exact test to compare each of the 3 combinations of 2 groups.

RESULTS

Study Question 1

ROM differed significantly among the 3 groups (Table 3). Extension and ER in extension were significantly ($P < .001$)

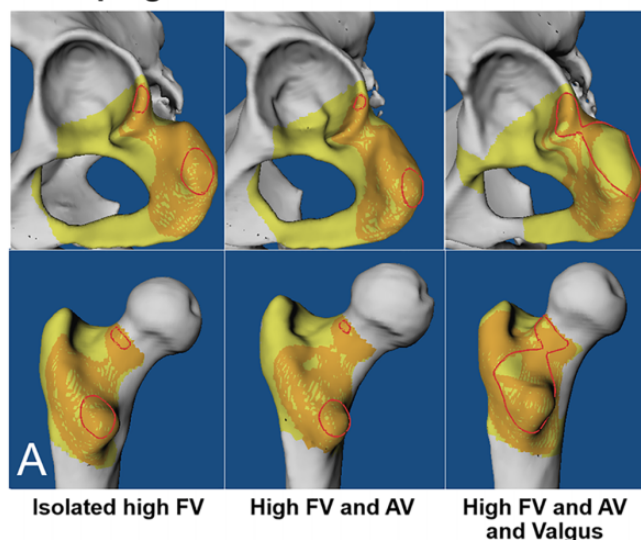
TABLE 3
Range of Motion Based on Patient-Specific Software for 3-Dimensional Simulation of Hip Impingement
for the 3 Groups With Posterior Hip Impingement^a

	All Hips With Increased Femoral Version	Hips With McKibbin Index >70	Control	Overall <i>P</i> Value
Flexion	130 ± 10 (107 to 149)	126 ± 10 (107 to 149)	124 ± 13 (103 to 146)	.237
Extension	15 ± 14 (-12 to 49) ^b	11 ± 13 (-12 to 41) ^b	60 ± 16 (32 to 95)	<.001
90° of flexion				
IR	65 ± 11 (44 to 92) ^b	69 ± 9 (53 to 86) ^b	30 ± 10 (13 to 40)	<.001
ER	86 ± 13 (50 to 107) ^b	81 ± 14 (50 to 102) ^b	104 ± 11 (89 to 125)	.003
Abduction	73 ± 9 (51 to 96) ^b	74 ± 9 (51 to 96) ^b	65 ± 11 (40 to 80)	.002
Adduction	13 ± 11 (-9 to 36) ^b	10 ± 11 (-9 to 36) ^b	40 ± 7 (25 to 52)	<.001
Extension				
ER	15 ± 12 (-21 to 35) ^b	10 ± 13 (-21 to 35) ^b	50 ± 9 (38 to 69)	<.001
IR	153 ± 16 (123 to 180) ^b	162 ± 12 (140 to 180) ^b	111 ± 16 (84 to 146)	<.001

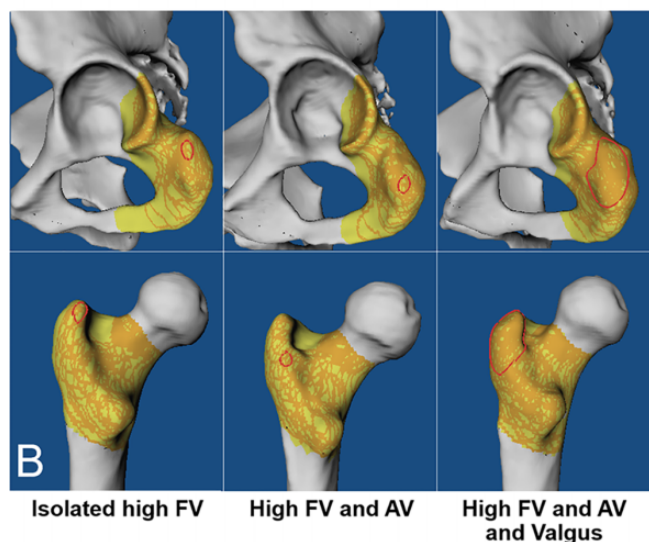
^aValues (in degrees) are displayed as mean ± SD (range). Level of significance was adjusted for 3 groups (.05/3 = .016) with the Bonferroni correction. ER, external rotation; IR, internal rotation.

^bStatistically significant difference vs control group ($P < .016$).

Posterior Impingement Test in 20° Extension and 20° ER



FABER Test in 20° Flexion and 30° ER



FABER Test in 20° Flexion and 40° ER

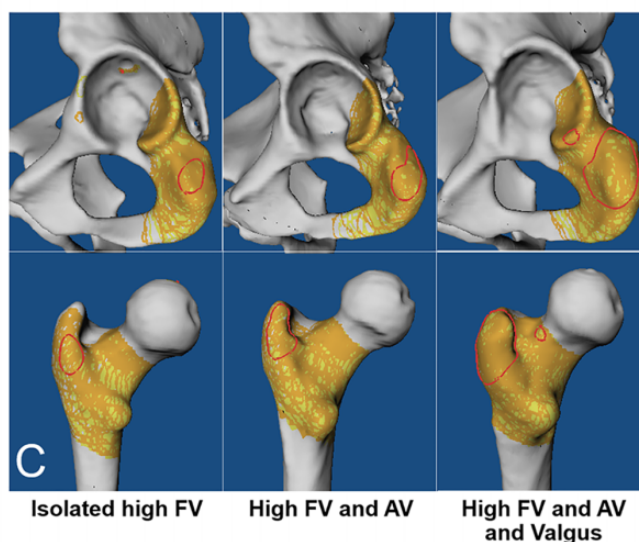


Figure 3. Posterior acetabular and femoral impingement zones as compared with the control group using 3D CT-based dynamic simulation for the (A) posterior impingement test (at 20° of ER and 20° of extension) and the modified FABER test (B) at 30° of ER and 20° of flexion and (C) at 40° of ER and 20° of flexion. The red zones signify osseous impingement conflict. See Supplemental Videos 2 to 4 for dynamic impingement simulations. 3D, 3-dimensional; AV, acetabular version; CT, computed tomography; ER, external rotation; FABER, flexion-abduction-ER; FV, femoral version.

decreased in hips with increased FV as compared with the control group. Extension and ER in extension were even lower in hips with a McKibbin index >70. Regarding the 3 subgroups, in hips with increased FV and AV as compared with valgus hips with increased FV and AV, we found that ER at 90° of flexion ($94^\circ \pm 10^\circ$ vs $81^\circ \pm 13^\circ$) was significantly ($P = .011$) increased, whereas IR in extension ($146^\circ \pm 16^\circ$ vs $167^\circ \pm 16^\circ$) was significantly ($P = .003$) decreased (Appendix Table A3). ER at 0° of flexion was significantly ($P < .001$) decreased in valgus hips with increased FV and AV compared with hips with increased FV and AV (Appendix Figure A2). Valgus hips with increased FV and AV showed

significantly ($P < .001$) decreased flexion versus hips with increased FV and AV ($118^\circ \pm 9^\circ$ vs $133^\circ \pm 8^\circ$).

Study Question 2

During the posterior impingement test (Figure 3A), 92% of the impingement was located posterior extra-articular ischiofemoral in hips with increased FV (Table 4 and Supplemental Videos 2-4). Posterior intra-articular hip impingement was present in 54% during the posterior impingement test (Figure 4A) and was located on the femoral neck between 7 and 10 o'clock (Figure 3). During the

TABLE 4
Prevalence of Posterior Extra-articular Hip Impingement
for the 3 Study Groups^a

	All Hips With Increased Femoral Version	Hips With McKibbin Index >70	Control	Overall P Value
Posterior impingement test (see Figures 3A and 4A)	92 ^b	88 ^b	0	<.001
20° of ER and 0° of extension FABER test	35 ^b	54 ^b	0	<.001
20° of ER and 20° of flexion	17	35	0	.526
30° of ER and 20° of flexion (see Figures 3B and 4B)	48 ^b	69 ^b	0	<.001
40° of ER and 20° of flexion (see Figures 3C and 4C)	96 ^b	100 ^b	10	<.001
0° of ER and 20° of extension	54 ^b	65 ^b	0	<.001

^aValues are presented as percentages. Posterior impingement test signifies 20° of extension with 20° of ER. ER, external rotation; FABER, flexion, abduction, and external rotation.

^bStatistically significant difference vs controls ($P < .016$).

modified FABER test at 40° of ER and 20° of flexion, 13% of the hips with increased FV (Figure 4C) had intra-articular impingement, while 96% showed posterior extra-articular impingement.

Study Question 3

Posterior extra-articular ischiofemoral impingement occurred between the ischium and the lesser trochanter (Supplemental Videos 2-4) in 83% of the hips with increased FV (Figure 4A) during the posterior impingement test at 20° of ER and 20° of extension (Figure 3A). During the modified FABER test, performed at 30° of ER and 20° of flexion, impingement zones were located posterior extra-articular in 67% of the hips with isolated increased FV and in 67% in valgus hips with increased FV and AV (Appendix Table A4). This was a significantly ($P < .001$) higher prevalence when compared with hips (22%) with increased FV and AV tested at 30° of ER and 20° of flexion.

During the modified FABER test at 40° of ER and 20° of flexion, the hips with increased FV had a significantly ($P < .001$) higher prevalence of posterior extra-articular hip impingement (96%) than the control group (10%) (Table 4).

In addition, during the modified FABER test at 40° of ER and 20° of flexion (Figure 3C), the impingement conflict was located ischiofemoral between the ischium and the greater trochanter (62%) or intertrochanteric region (67%) in all 3 subgroups (Figure 4C). During the modified FABER

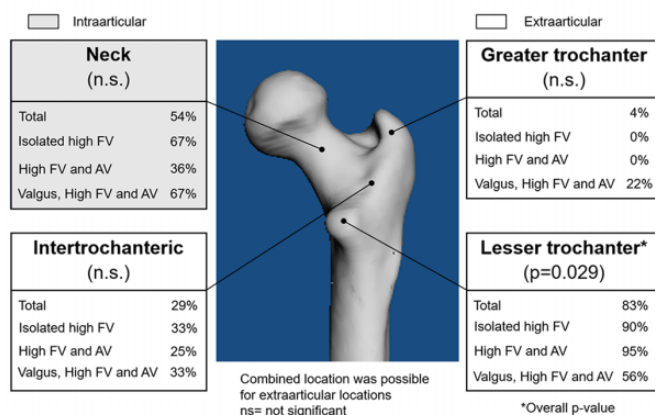
test at 40° of ER and 20° of flexion, 95% of hips with isolated increased FV had a posterior extra-articular impingement (Appendix Table A4), while the prevalence was 100% of the valgus hips with increased FV and AV.

DISCUSSION

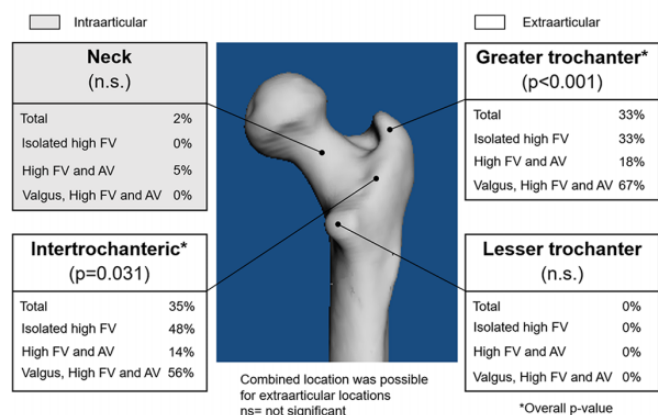
The aim of this study was to investigate the osseous impingement-free ROM and impingement location in hips with isolated increased FV, hips with increased FV and AV, and valgus hips with increased FV and AV. Osseous patient-specific CT-based 3D models of 52 hip joints with increased FV ($>35^\circ$) were compared with a control group using previously validated collision detection software⁴³ for impingement simulation. Most importantly, we found that posterior impingement can occur in early flexion and was located on the greater trochanter (Figures 3 and 4). This is new because previous investigations⁵⁸ investigated posterior impingement in extension that was located on the lesser trochanter. In all hips with increased FV, 83% of the impingement zones were located posterior extra-articular between the ischium and the lesser trochanter (Figure 4A) during the posterior impingement test. During the posterior impingement test, 67% of hips with increased FV and 67% of valgus hips with increased FV and AV exhibited intra- and extra-articular hip impingement (Appendix Table A5). Impingement was located between the ischium and the lesser trochanter in 90% in hips with isolated high FV. During the modified FABER test, at 30° of ER and 20° of flexion, impingement zones were located posterior and extra-articular in 67% of hips with isolated increased FV and in 67% of valgus hips with increased FV and AV (Appendix Table A4). Interestingly, during the modified FABER test at 40° of ER and 20° of flexion, the impingement conflict was located between the ischium and the greater trochanter (62%) (Figure 4C) or intertrochanteric region (67%) in all hips with increased FV. ROM in terms of flexion, ER at 90° of flexion, and IR at 0° of flexion differed significantly between the hips with increased FV and the control group. This is one of the first studies to analyze the location of impingement in hips with isolated increased FV and hips with increased FV and AV (high McKibbin index).

Our results for the impingement-free hip ROM values are in line with the orthopaedic literature for osseous impingement detection and confirm the validity of our data.^{5,6,48} For valgus hips with increased FV, a decreased hip extension of 26° and ER in extension of 22° have been reported.⁵⁸ This corresponds to our results with slightly more decreased mean hip extension and ER in extension: $15^\circ \pm 14^\circ$ and $15^\circ \pm 12^\circ$, respectively (Table 3). Based on a different software program for collision detection, a slightly lower mean flexion of $110^\circ \pm 7^\circ$ and a lower IR of $19^\circ \pm 6^\circ$ were reported for hips with anterior FAI.³ Comparing our results of IR at 90° flexion of $65^\circ \pm 11^\circ$ with the literature, we found increased values. We expected higher values for IR because of the increased FV. Another study cited a lower flexion of $107^\circ \pm 12^\circ$ and a lower IR of $19^\circ \pm 13^\circ$.⁵ For hockey players with symptomatic FAI, a flexion of 116° and an IR

A Posterior Impingement Test in 20° ER and 20° Extension



B FABER Test in 30° ER and 20° Flexion



C FABER Test in 40° ER and 20° Flexion

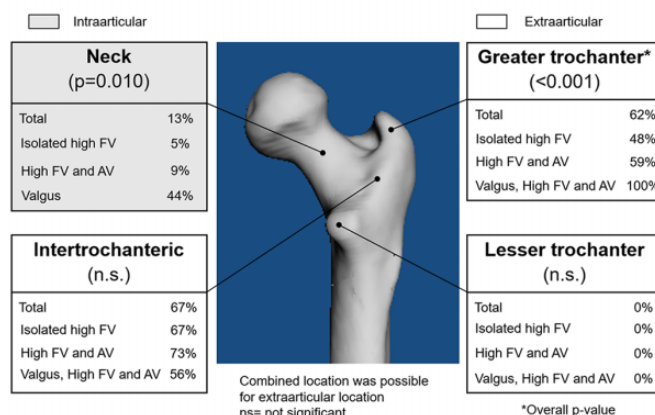


Figure 4. Location of posterior femoral impingement for the 3 study groups during (A) the posterior impingement test at 20° of extension and 20° of ER and (B, C) the modified FABER test at 30° of ER and 20° of flexion and at 40° of ER and 20° of flexion. The femoral impingement location was calculated using 3D CT-based dynamic impingement simulation software (see Supplemental Videos 2-4). 3D, 3-dimensional; CT, computed tomography; ER, external rotation; FABER, flexion-abduction-ER; FV, femoral version.

of 29° were noted.⁴⁸ A pronounced decreased flexion (93° ± 20°) and IR (8° ± 9°) have been described for hips with subspine impingement.²¹ The impingement simulation used in this study has been used previously to detect impingement-free ROM in hips with more complex deformities, including FAI,²⁵ hip dysplasia,⁶¹ valgus hips with increased FV,⁵⁸ and Perthes disease⁶³ (post-Perthes deformity). This allows direct comparison of our results with these studies.

In addition, our results for the location of impingement (Figures 3 and 4) compare well with the results indicated for hips with increased FV and valgus morphology.⁵⁸ A high prevalence of posterior extra-articular impingement has been reported in these hips.⁵⁸ We found that the acetabular and femoral location of posterior impingement was mostly extra-articular (Figure 4A) in all hips with increased FV (Table 4). The subgroup of valgus hips with increased FV and AV exhibited intra-articular (67%) and extra-articular (89%) posterior impingement (Appendix Tables A4 and A5) during the posterior impingement test. So far, there are no other results available in the literature for impingement

location using collision detection software for hips with isolated increased FV or for hips with increased FV and AV. The hips with isolated increased FV and the hips with increased FV and AV exhibited a comparable location of posterior extra-articular hip impingement. We did not expect this result. The similar McKibbin index of 70° (Table 1) seems to be only a partial explanation. We expected a higher prevalence of posterior intra-articular impingement with the combination of increased FV and AV.

We also found a high prevalence (83%) (Figure 4A) of posterior extra-articular impingement between the ischium and the lesser trochanter in all hips with increased FV during the simulation of the posterior impingement test at 20° of ER and 20° of extension. Interestingly, there was no difference in the prevalence of intra- and extra-articular hip impingement (Appendix Tables A4 and A5) among the 3 groups during the posterior impingement test. Simulation of the modified FABER test at 30° of ER and 20° of flexion revealed that valgus hips with increased FV and AV had the same prevalence (67%) of posterior extra-articular

impingement as hips with isolated increased FV. In addition, during the modified FABER test at 40° of ER and 20° of flexion, the impingement conflict was located between the ischium and the greater trochanter (62%) (Figure 4C) or intertrochanteric region (67%) in all hips with increased FV. This is important because the posterior impingement in early flexion in these hips is new and has clinical implications. Impingement in early flexion has not been described in the orthopaedic literature yet. Therefore, we recommend performing the FABER test during clinical examination to test for hip instability in addition to the posterior impingement test for female patients with increased FV for diagnosis of posterior extra-articular hip impingement.

This study has several important clinical implications. A high prevalence of posterior extra-articular impingement was detected during the posterior impingement test. This underlines the validity of this clinical test to detect posterior impingement. Also, during the modified FABER test at 40° of ER and 20° of flexion, the prevalence of posterior extra-articular impingement was high. So far, the FABER test has been described for patients with sacroiliac joint disorders but not for posterior hip impingement. Given the results of this study, we recommend use of the FABER test to search for hip instability for female patients with increased FV in combination with the posterior impingement test. Another name for the modified FABER test could be FLER test (flexion and ER).

According to our data, isolated increased FV without valgus deformity seems to be an additional cause for posterior extra-articular hip impingement. This is possible even in the absence of a cam-type or valgus morphology. This is in accordance with a recent prevalence study³³ reporting that increased FV is most often combined with a normal AV. In previous studies using collision detection software, hips with increased FV and a valgus morphology^{58,61} were investigated. As compared with the clinically determined ROM from previous studies^{19,32,60} of patients with FAI or hip dysplasia,³¹ the software for impingement detection in the current study was advantageous for the following reasons: (1) analysis of osseous impingement-free ROM had a higher accuracy because clinical examination is prone to error¹²; (2) the simulation included combined movements (posterior impingement test and FABER test) instead of isolated hip motion; and (3) the software detected the exact extra-articular impingement location (Figure 4).

Treatment of hips with increased FV is controversial: some authors utilized open therapy with proximal femoral osteotomies^{58,61} to decrease FV, while others relied on arthroscopic or endoscopic therapy, including resection of the lesser trochanter.^{20,50,59} However, it remains unclear if arthroscopic femoral cam resection or lesser trochanter resection can provide pain relief and improved ROM in hips with increased FV. Further studies are needed to evaluate the effect of these treatments. Theoretically, these hips are at risk for persistent pain after femoral cam resection because posterior hip impingement and FV are not altered. Treatment for extra-articular hip impingement is controversial as well and includes open and arthroscopic surgery.⁴⁷ According to a previous study, patients with extra-articular hip impingement are often female (see

Table 1), have a higher FV than patients with anterior FAI,⁴⁵ and are at risk for revision hip surgery.^{45,46} This is consistent with our patients, who were predominantly female, but our series included 1 symptomatic patient who presented in our outpatient clinic with an age of 45 years. We were surprised by this finding and cannot explain it. According to a recent systematic review,⁵¹ persisting deformity and insufficient correction are previously described risk factors for decreased subjective patient-centered clinical outcomes after hip arthroscopy. In addition, these risk factors are the most common causes for revision hip arthroscopy for FAI treatment.^{49,51}

Therefore, we believe that isolated labral treatment or femoral offset correction in hips with increased FV with or without a cam-type morphology should be performed with caution, and treatment should include consideration of a derotation femoral osteotomy.^{8,23} Derotation femoral osteotomies for increased FV⁶² and the treatment of hip dysplasia^{32,61} have been performed for decades for children with spastic hemiplegic cerebral palsy,¹ resulting in a normalization of ROM. These studies noted a decrease in IR and an increase in ER of the hip and satisfactory radiographic results.⁶⁹ But these reports were before the availability of 3D collision detection software. On the basis of the current study, we propose routine evaluation of FV using CT or MRI^{55,57} to identify increased FV³³ in all young, active patients presenting with hip pain. Additionally, we recommend considering a derotation femoral osteotomy as an additional treatment option in hips with posterior hip impingement and increased FV. A derotation femoral osteotomy should be performed only when extension and ER in extension cannot be sufficiently corrected by other nonsurgical means, such as injections of corticosteroids or physical therapy. Valgus deformity with increased FV can result in posterior extra-articular impingement with limited ER in extension, which can be improved with a varus derotation osteotomy of the femur.⁶¹

This study has limitations. First, the software for collision detection calculates the osseous ROM without considering the acetabular labrum or cartilage or other soft tissue. This is a previously known limitation for computer simulation of hip ROM.^{22,40,65} Because the FABER test and the posterior impingement test are motion patterns that are mainly limited by osseous conflicts,^{58,63,65} this should not affect our findings. Therefore, the clinical ROM (Appendix Table A2) was even lower, probably because of the soft tissue impingement (eg, quadratus femoris muscle in ischiofemoral impingement). However, this was also described for previously published ROM results using different collision detection software.^{5,6} This software has been used previously for hips with severe hip deformities, including dysplastic hips,⁶¹ hips with valgus deformity, and hips with Legg-Calve-Perthes disease or post-Perthes deformities.⁶³ Since the software has been applied to various hip conditions, the equidistant method seems to be a robust method for detection of extra-articular impingement location. MRI could be used in future studies to overcome this limitation.²⁸

Second, the patients in this study were recruited from a university center for hip-preserving surgery, possibly with

limited generalizability. A potential selection bias could be present because of the inclusion of more complex patients. Third, we did not report on clinical follow-up. However, this was not the aim of this study, and all patients were symptomatic at the time of image acquisition. Fourth, we used a cutoff value of $>35^\circ$ for hips with increased FV. Different definitions for increased FV exist in the literature,⁵⁵ and using another cutoff value could lead to different results. Additionally, in the current study dysplastic hip joints were excluded. A dysplastic hip joint could be combined with increased FV or increased FV and AV. Future studies could analyze the effect of increased FV with periacetabular osteotomy^{31,32} for the treatment of hip dysplasia. There was also a significant difference in the mean age among the 3 groups (see Table 1). This should not have influenced our results. The majority of patients were female. Therefore, the conclusions are applicable to female patients only. This is attributable to the prevalence of the disease; that is, increased FV is more common in females.³³ In addition, reconstruction of 3D models was performed with manual steps. This was necessary to ensure the accuracy of the patient-specific 3D models. Automatic 3D reconstruction^{13,54} could ideally overcome this limitation. Finally, we did not evaluate pelvic tilt or pelvic incidence, which could also affect hip motion.

CONCLUSION

Hips with increased FV had a high prevalence of posterior extra-articular hip impingement, which was mostly located between the ischium and the lesser trochanter in extension. Hips with increased FV had a similar frequency of posterior extra-articular hip impingement during the posterior impingement test and the modified FABER test performed at 40° of ER and 20° of flexion.

Posterior impingement can also be located between the ischium and the greater trochanter or the intertrochanteric region during the modified FABER test. Therefore, we recommend measuring FV in all female patients with hip pain to detect abnormal FV. In addition, we recommend performing the FABER test during clinical examination in female patients with increased FV. This could help to optimize surgical outcomes for patients evaluated for hip-preserving surgery, including femoral derotation osteotomy and/or hip arthroscopy or resection of the lesser trochanter.

Video Supplements for this article are available at <http://journals.sagepub.com/doi/suppl/10.1177/2325967121990629>.

REFERENCES

1. Aminian A, Vankoski SJ, Dias L, Novak RA. Spastic hemiplegic cerebral palsy and the femoral derotation osteotomy: effect at the pelvis and hip in the transverse plane during gait. *J Pediatr Orthop*. 2003; 23(3):314-320.
2. Arnold AS, Komattu AV, Delp SL. Internal rotation gait: a compensatory mechanism to restore abduction capacity decreased by bone deformity. *Dev Med Child Neurol*. 1997;39(1):40-44.
3. Audenaert EA, Peeters I, Vigneron L, Baelde N, Pattyn C. Hip morphological characteristics and range of internal rotation in femoroacetabular impingement. *Am J Sports Med*. 2012;40(6):1329-1336.
4. Bagwell JJ, Bauer L, Gradoz M, Grindstaff TL. The reliability of FABER test hip range of motion measurements. *Int J Sports Phys Ther*. 2016; 11(7):1101-1105.
5. Bedi A, Dolan M, Hetsroni I, et al. Surgical treatment of femoroacetabular impingement improves hip kinematics: a computer-assisted model. *Am J Sports Med*. 2011;39(suppl):43S-49S.
6. Bouma H, Hogervorst T, Audenaert E, van Kampen P. Combining femoral and acetabular parameters in femoroacetabular impingement: the omega surface. *Med Biol Eng Comput*. 2015;53(11): 1239-1246.
7. Bruderer-Hofstetter M, Fenner V, Payne E, Zdenek K, Klima H, Wegener R. Gait deviations and compensations in pediatric patients with increased femoral torsion. *J Orthop Res*. 2015;33(2):155-162.
8. Buly RL, Sosa BR, Poultides LA, Caldwell E, Rozbruch SR. Femoral derotation osteotomy in adults for version abnormalities. *J Am Acad Orthop Surg*. 2018;26(19):e416-e425.
9. Bunn A, Colwell CW, D'Lima DD. Bony impingement limits design-related increases in hip range of motion. *Clin Orthop Relat Res*. 2012; 470(2):418-427.
10. Casartelli NC, Brunner R, Maffiuletti NA, et al. The FADIR test accuracy for screening cam and pincer morphology in youth ice hockey players. *J Sci Med Sport*. 2018;21(2):134-138.
11. Chadayammuri V, Garabekyan T, Bedi A, et al. Passive hip range of motion predicts femoral torsion and acetabular version. *J Bone Joint Surg Am*. 2016;98(2):127-134.
12. Charbonnier C, Chagué S, Schmid J, Kolo FC, Bernardoni M, Christofilopoulos P. Analysis of hip range of motion in everyday life: a pilot study. *Hip Int*. 2015;25(1):82-90.
13. Damopoulos D, Lerch TD, Schmaranzer F, et al. Segmentation of the proximal femur in radial MR scans using a random forest classifier and deformable model registration. *Int J Comput Assist Radiol Surg*. 2019; 14(3):545-561.
14. Diamond LE, Dobson FL, Bennell KL, Wrigley TV, Hodges PW, Hinman RS. Physical impairments and activity limitations in people with femoroacetabular impingement: a systematic review. *Br J Sports Med*. 2015;49(4):230-242.
15. Fabricant PD, Bedi A, De La Torre K, Kelly BT. Clinical outcomes after arthroscopic psoas lengthening: the effect of femoral version. *Arthroscopy*. 2012;28(7):965-971.
16. Fabricant PD, Fields KG, Taylor SA, Magennis E, Bedi A, Kelly BT. The effect of femoral and acetabular version on clinical outcomes after arthroscopic femoroacetabular impingement surgery. *J Bone Joint Surg Am*. 2015;97(7):537-543.
17. Ganz R, Parvizi J, Beck M, Leunig M, Nötzli H, Siebenrock KA. Femoroacetabular impingement: a cause for osteoarthritis of the hip. *Clin Orthop Relat Res*. 2003;417:112-120.
18. Griffin DR, Dickenson EJ, O'Donnell J, et al. The Warwick Agreement on femoroacetabular impingement syndrome (FAI syndrome): an international consensus statement. *Br J Sports Med*. 2016;50(19): 1169-1176.
19. Haefeli PC, Albers CE, Steppacher SD, Tannast M, Büchler L. What are the risk factors for revision surgery after hip arthroscopy for femoroacetabular impingement at 7-year followup? *Clin Orthop Relat Res*. 2017;475(4):1169-1177.
20. Hatem MA, Palmer IJ, Martin HD. Diagnosis and 2-year outcomes of endoscopic treatment for ischiofemoral impingement. *Arthroscopy*. 2015;31(2):239-246.
21. Hetsroni I, Poultides L, Bedi A, Larson CM, Kelly BT. Anterior inferior iliac spine morphology correlates with hip range of motion: a classification system and dynamic model. *Clin Orthop Relat Res*. 2013; 471(8):2497-2503.

22. Iwai S, Kabata T, Maeda T, et al. Three-dimensional kinetic simulation before and after rotational acetabular osteotomy. *J Orthop Sci.* 2014;19(3):443-450.
23. Kamath AF, Ganz R, Zhang H, Grappiolo G, Leunig M. Subtrochanteric osteotomy for femoral mal-torsion through a surgical dislocation approach. *J Hip Preserv Surg.* 2015;2(1):65-79.
24. Kessler O, Patil S, Wirth S, et al. Bony impingement affects range of motion after total hip arthroplasty: a subject-specific approach. *J Orthop Res.* 2008;26(4):443-452.
25. Kubiak-Langer M, Tannast M, Murphy SB, Siebenrock KA, Langlotz F. Range of motion in anterior femoroacetabular impingement. *Clin Orthop Relat Res.* 2007;458:117-124.
26. Kuo TY, Skedros JG, Bloebaum RD. Measurement of femoral anteversion by biplane radiography and computed tomography imaging: comparison with an anatomic reference. *Invest Radiol.* 2003;38(4):221-229.
27. Lerch TD, Boschung A, Todorski IAS, et al. Femoroacetabular impingement patients with decreased femoral version have different impingement locations and intra- and extraarticular anterior subspine FAI on 3D-CT-based impingement simulation: implications for hip arthroscopy. *Am J Sports Med.* 2019;47(13):3120-3132.
28. Lerch TD, Degonda C, Schmaranzer F, et al. Patient-specific 3-D magnetic resonance imaging-based dynamic simulation of hip impingement and range of motion can replace 3-D computed tomography-based simulation for patients with femoroacetabular impingement: implications for planning open hip preservation surgery and hip arthroscopy. *Am J Sports Med.* 2019;47(12):2966-2977.
29. Lerch TD, Novais EN, Schmaranzer F, et al. What is the prevalence of cam deformity after prophylactic pinning of the contralateral asymptomatic hip in unilateral slipped capital femoral epiphysis? A 10-year minimum followup study. *Clin Orthop Relat Res.* 2019;477(5):1111-1122.
30. Lerch TD, Schmaranzer F, Steppacher SD, Ziebarth K, Tannast M, Siebenrock KA. Most of patients with femoral derotation osteotomy for posterior extraarticular hip impingement and high femoral version would do surgery again. *Hip Int.* Published online August 31, 2020. doi:10.1177/1120700020953100
31. Lerch TD, Steppacher SD, Liechti EF, Siebenrock KA, Tannast M. Bernese periacetabular osteotomy: indications, technique and results 30 years after the first description [in German]. *Orthopade.* 2016;45(8):687-694.
32. Lerch TD, Steppacher SD, Liechti EF, Tannast M, Siebenrock KA. One-third of hips after periacetabular osteotomy survive 30 years with good clinical results, no progression of arthritis, or conversion to THA. *Clin Orthop Relat Res.* 2017;475(4):1154-1168.
33. Lerch TD, Todorski IAS, Steppacher SD, et al. Prevalence of femoral and acetabular version abnormalities in patients with symptomatic hip disease: a controlled study of 538 hips. *Am J Sports Med.* 2018;46(1):122-134.
34. Mahaisavariya B, Sitthiseripratip K, Tongdee T, Bohez ELJ, Vander Sloten J, Oris P. Morphological study of the proximal femur: a new method of geometrical assessment using 3-dimensional reverse engineering. *Med Eng Phys.* 2002;24(9):617-622.
35. McClincy MP, Wylie JD, Yen Y-M, Novais EN. Mild or borderline hip dysplasia: are we characterizing hips with a lateral center-edge angle between 18° and 25° appropriately? *Am J Sports Med.* 2019;47(1):112-122.
36. McKibbin B. Anatomical factors in the stability of the hip joint in the newborn. *J Bone Joint Surg Br.* 1970;52(1):148-159.
37. Montgomery AA, Graham A, Evans PH, Fahey T. Inter-rater agreement in the scoring of abstracts submitted to a primary care research conference. *BMC Health Serv Res.* 2002;2(1):8.
38. Murphy SB, Simon SR, Kijewski PK, Wilkinson RH, Griscom NT. Femoral anteversion. *J Bone Joint Surg Am.* 1987;69(8):1169-1176.
39. Naal FD, Hatzung G, Müller A, Impellizzeri F, Leunig M. Validation of a self-reported Beighton score to assess hypermobility in patients with femoroacetabular impingement. *Int Orthop.* 2014;38(11):2245-2250.
40. Nakahara I, Takao M, Sakai T, Nishii T, Yoshikawa H, Sugano N. Gender differences in 3D morphology and bony impingement of human hips. *J Orthop Res.* 2011;29(3):333-339.
41. Nötzli HP, Wyss TF, Stoecklin CH, Schmid MR, Treiber K, Hodler J. The contour of the femoral head-neck junction as a predictor for the risk of anterior impingement. *J Bone Joint Surg Br.* 2002;84(4):556-560.
42. Puls M, Ecker TM, Steppacher SD, Tannast M, Siebenrock KA, Kowal JH. Automated detection of the osseous acetabular rim using three-dimensional models of the pelvis. *Comput Biol Med.* 2011;41(5):285-291.
43. Puls M, Ecker TM, Tannast M, Steppacher SD, Siebenrock KA, Kowal JH. The equidistant method—a novel hip joint simulation algorithm for detection of femoroacetabular impingement. *Comput Aided Surg.* 2010;15(4-6):75-82.
44. Reiman MP, Goode AP, Cook CE, Hölmich P, Thorborg K. Diagnostic accuracy of clinical tests for the diagnosis of hip femoroacetabular impingement/labral tear: a systematic review with meta-analysis. *Br J Sports Med.* 2015;49(12):811.
45. Ricciardi BF, Fabricant PD, Fields KG, Poultides L, Zaltz I, Sink EL. What are the demographic and radiographic characteristics of patients with symptomatic extraarticular femoroacetabular impingement? *Clin Orthop Relat Res.* 2015;473(4):1299-1308.
46. Ricciardi BF, Fields K, Kelly BT, Ranawat AS, Coleman SH, Sink EL. Causes and risk factors for revision hip preservation surgery. *Am J Sports Med.* 2014;42(11):2627-2633.
47. Ricciardi BF, Fields KG, Wentzel C, Kelly BT, Sink EL. Short-term outcomes of open hip preservation surgery for symptomatic extraarticular femoroacetabular impingement. *Hip Int.* 2017;27(6):599-607.
48. Ross JR, Bedi A, Stone RM, Sibilsky Enselman E, Kelly BT, Larson CM. Characterization of symptomatic hip impingement in butterfly ice hockey goalies. *Arthroscopy.* 2015;31(4):635-642.
49. Ross JR, Larson CM, Adeoyo O, Kelly BT, Bedi A. Residual deformity is the most common reason for revision hip arthroscopy: a three-dimensional CT study. *Clin Orthop Relat Res.* 2015;473(4):1388-1395.
50. de Sa D, Alradwan H, Carnelli S, et al. Extra-articular hip impingement: a systematic review examining operative treatment of psoas, subspine, ischiofemoral, and greater trochanteric/pelvic impingement. *Arthroscopy.* 2014;30(8):1026-1041.
51. Sardana V, Philippon MJ, de Sa D, et al. Revision hip arthroscopy indications and outcomes: a systematic review. *Arthroscopy.* 2015;31(10):2047-2055.
52. Scheys L, Van Campenhout A, Spaepen A, Suetens P, Jonkers I. Personalized MR-based musculoskeletal models compared to rescaled generic models in the presence of increased femoral anteversion: effect on hip moment arm lengths. *Gait Posture.* 2008;28(3):358-365.
53. Schmaranzer F, Hanke M, Lerch T, Steppacher S, Siebenrock K, Tannast M. Impingement of the hip [in German]. *Radiologe.* 2016;56(9):825-838.
54. Schmaranzer F, Helfenstein R, Zeng G, et al. Automatic MRI-based three-dimensional models of hip cartilage provide improved morphologic and biochemical analysis. *Clin Orthop Relat Res.* 2019;477(5):1036-1052.
55. Schmaranzer F, Lerch TD, Siebenrock KA, Tannast M, Steppacher SD. Differences in femoral torsion among various measurement methods increase in hips with excessive femoral torsion. *Clin Orthop Relat Res.* 2019;477(5):1073-1083.
56. Schmaranzer F, Lerch TD, Strasser U, Vavron P, Schmaranzer E, Tannast M. Usefulness of MR arthrography of the hip with and without leg traction in detection of intra-articular bodies. *Acad Radiol.* 2019;26(9):e252-e259.
57. Schmaranzer F, Todorski IAS, Lerch TD, Schwab J, Cullmann-Bastian J, Tannast M. Intra-articular lesions: imaging and surgical correlation. *Semin Musculoskelet Radiol.* 2017;21(5):487-506.
58. Siebenrock KA, Steppacher SD, Haefeli PC, Schwab JM, Tannast M. Valgus hip with high antetorsion causes pain through posterior extra-articular FAI. *Clin Orthop Relat Res.* 2013;471(12):3774-3780.

59. Singer AD, Subhawong TK, Jose J, Tresley J, Clifford PD. Ischiofemoral impingement syndrome: a meta-analysis. *Skeletal Radiol.* 2015; 44(6):831-837.

60. Steppacher SD, Anwander H, Zurmühle CA, Tannast M, Siebenrock KA. Eighty percent of patients with surgical hip dislocation for femoroacetabular impingement have a good clinical result without osteoarthritis progression at 10 years. *Clin Orthop Relat Res.* 2015;473(4): 1333-1341.

61. Steppacher SD, Zurmühle CA, Puls M, et al. Periacetabular osteotomy restores the typically excessive range of motion in dysplastic hips with a spherical head. *Clin Orthop Relat Res.* 2015;473(4): 1404-1416.

62. Svenningsen S, Terjesen T, Apalset K, Anda S. Osteotomy for femoral anteversion: a prospective 9-year study of 52 children. *Acta Orthop Scand.* 1990;61(4):360-363.

63. Tannast M, Hanke M, Ecker TM, Murphy SB, Albers CE, Puls M. LCPD: reduced range of motion resulting from extra- and intraarticular impingement. *Clin Orthop Relat Res.* 2012;470(9):2431-2440.

64. Tannast M, Hanke MS, Zheng G, Steppacher SD, Siebenrock KA. What are the radiographic reference values for acetabular under- and overcoverage? *Clin Orthop Relat Res.* 2015;473(4):1234-1246.

65. Tannast M, Kubiak-Langer M, Langlotz F, Puls M, Murphy SB, Siebenrock KA. Noninvasive three-dimensional assessment of femoroacetabular impingement. *J Orthop Res.* 2007;25(1):122-131.

66. Tannast M, Langlotz U, Siebenrock K-A, Wiese M, Bernsmann K, Langlotz F. Anatomic referencing of cup orientation in total hip arthroplasty. *Clin Orthop Relat Res.* 2005;436:144-150.

67. Tannast M, Siebenrock KA, Anderson SE. Femoroacetabular impingement: radiographic diagnosis—what the radiologist should know. *AJR Am J Roentgenol.* 2007;188(6):1540-1552.

68. Tönnis D. General radiography of the hip joint. In: Tönnis D, ed. *Congenital Dysplasia, Dislocation of the Hip.* Springer; 1987: 100-142.

69. Tönnis D, Heinecke A. Acetabular and femoral anteversion: relationship with osteoarthritis of the hip. *J Bone Joint Surg Am.* 1999;81(12): 1747-1770.

APPENDIX

TABLE A1
Demographic and Radiographic Description of the 3 Subgroups With Posterior Hip Impingement^a

	Isolated Increased FV	Increased FV and AV	Increased FV and AV With Valgus	Overall P Value
Hips:patients, No.	21:14	22:18	9:6	
Age, y	23 ± 7 (18-45)	33 ± 11 (18-55)	38 ± 13 (23-59) ^b	<.001
Sex: female, %	90	100	100	.458
Side: right, %	52	59	44	.157
Height, cm	170 ± 7 (161-180)	172 ± 7 (163-183)	167 ± 5 (161-174)	.213
Weight, kg	63 ± 9 (50-76)	70 ± 10 (58-85)	70 ± 14 (60-100)	.328
Body mass index, kg/m ²	22 ± 2 (18-26)	24 ± 3 (18-27)	25 ± 5 (21-35)	.032
Angle, deg				
Lateral center edge	28 ± 5 (19-36)	27 ± 6 (19-39)	30 ± 8 (19-39)	.710
Neck-shaft	134 ± 4 (126-139)	133 ± 6 (122-139)	149 ± 6 (140-159) ^{b,c}	<.001
Alpha	52 ± 8 (40-70)	54 ± 9 (37-69)	47 ± 9 (35-60)	.074
FV, deg	50 ± 8 (35-63)	42 ± 9 (35-65)	53 ± 11 (36-68)	.001
AV, deg	20 ± 3 (15-24)	29 ± 3 (25-36)	28 ± 3 (25-34) ^b	<.001
McKibbin index	70 ± 8 (53-82)	70 ± 9 (59-98)	83 ± 10 (70-95) ^{b,c}	.005

^aValues are displayed as mean ± SD (range) unless noted otherwise. Level of significance was adjusted for 3 groups (.05/3 = .016) with the Bonferroni correction. McKibbin index: sum of FV and AV. AV, acetabular version; FV, femoral version.

^bStatistically significant difference vs hips with isolated increased FV (P < .016).

^cStatistically significant difference vs hips with increased FV and AV (P < .016).

TABLE A2
Clinical Range of Motion of the Hips With Increased Femoral Version^a

	All Hips With Increased Femoral Version (52 Hips)	Hips With Increased McKibbin Index >70 (26 Hips)
Flexion	106 ± 8 (95-120)	107 ± 9 (95-120)
Extension	4 ± 4 (0-10)	4 ± 4 (0-10)
90° of flexion		
IR	53 ± 11 (30-80)	56 ± 13 (30-80)
ER	42 ± 19 (15-70)	44 ± 18 (20-70)
Extension		
ER	17 ± 8 (10-30)	14 ± 7 (10-30)
IR	61 ± 15 (30-85)	63 ± 15 (30-85)

^aValues (in degrees) are displayed as mean ± SD (range). Data not reported for the control group (n = 20 hips). ER, external rotation; IR, internal rotation.

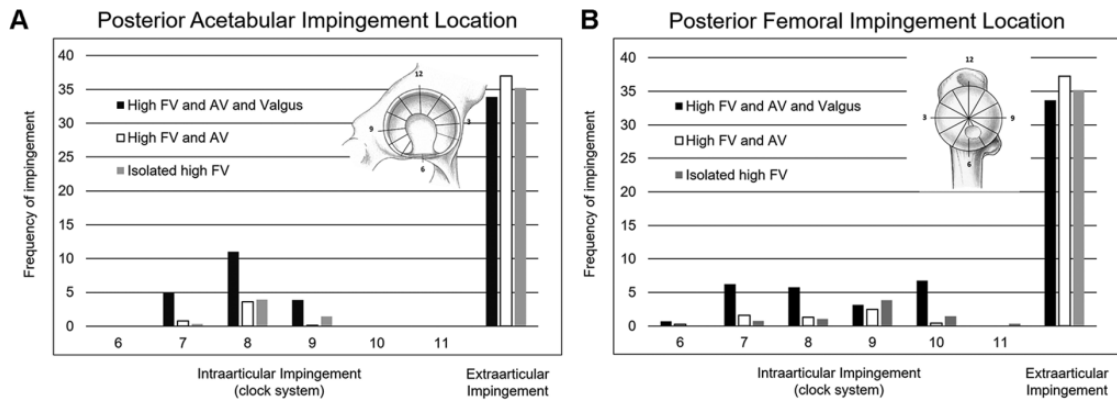


Figure A1. Posterior intra- and extra-articular impingement for (A) acetabular and (B) femoral zones for the 3 study subgroups. AV, acetabular version; FV, femoral version.

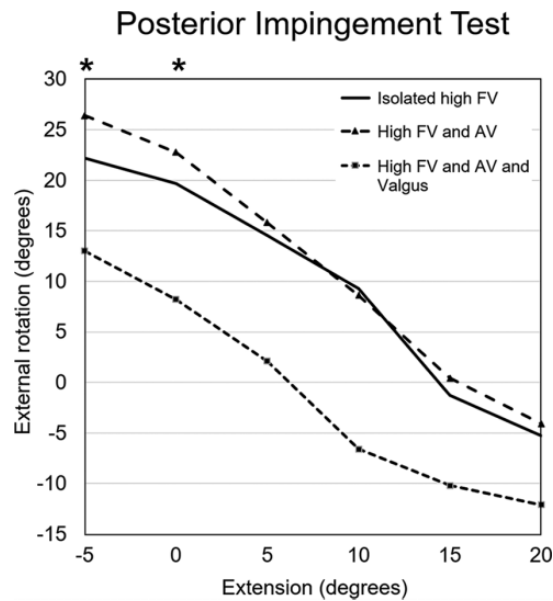


Figure A2. Posterior impingement test (or apprehension test) with external rotation in various degrees of extension (-5° to 20°) for hips with increased FV, hips with increased FV and AV, and valgus hips with increased FV and AV. *Statistically significant difference between hips with increased FV and AV and valgus hips with increased FV and AV. AV, acetabular version; FV, femoral version.

TABLE A3
Range of Motion Based on Patient-Specific Software for 3-Dimensional Simulation of Hip Impingement for the 3 Subgroups With Posterior Hip Impingement^a

Parameter	Isolated Increased Femoral Version (21 Hips)	Increased FV and AV (22 Hips)	Valgus Hips With Increased FV and AV (9 Hips)	Overall P Value
Flexion	130 ± 9 (113 to 149)	133 ± 8 (117 to 147)	118 ± 9 (107 to 129) ^{b,c}	<.001
Extension	16 ± 13 (2 to 44)	17 ± 15 (1 to 49)	7 ± 15 (-12 to 29)	.151
90° of flexion				
IR	70 ± 13 (49 to 92)	67 ± 10 (50 to 88)	72 ± 6 (62 to 81)	.274
ER	81 ± 14 (50 to 98)	94 ± 10 (73 to 107) ^b	81 ± 13 (54 to 97) ^c	.003
Abduction	75 ± 7 (63 to 88)	71 ± 10 (51 to 96)	77 ± 9 (62 to 90)	.148
Adduction	12 ± 8 (2 to 29)	15 ± 10 (-3 to 35)	11 ± 17 (-9 to 36)	.539
ER in extension	20 ± 8 (6 to 38)	23 ± 11 (-6 to 34)	8 ± 18 (-21 to 31)	.053

(continued)

Table A3 (continued)

Parameter	Isolated Increased Femoral Version (21 Hips)	Increased FV and AV (22 Hips)	Valgus Hips With Increased FV and AV (9 Hips)	Overall P Value
+ 10° of adduction	5 ± 11 (-28 to 14)	8 ± 13 (-29 to 19)	-3 ± 22 (-27 to 30)	.291
+ 20° of adduction	-12 ± 14 (-17 to 30)	-6 ± 15 (-18 to 30)	-14 ± 21 (-19 to 30)	.263
IR in extension	155 ± 12 (123 to 172)	146 ± 16 (124 to 180)	167 ± 16 (140 to 180) ^c	.002

^aValues (in degrees) are displayed as mean ± SD (range). Level of significance was adjusted for 3 groups (.05/3 = .016) with the Bonferroni correction. AV, acetabular version; ER, external rotation; FV, femoral version; IR, internal rotation.

^bStatistically significant difference vs hips with isolated increased FV ($P < .016$).

^cStatistically significant difference vs hips with increased FV and AV ($P < .016$).

TABLE A4
Prevalence of Posterior Extra-articular Hip Impingement for the 3 Subgroups With Posterior Hip Impingement During Different Motion Patterns^a

	Isolated Increased FV (21 Hips)	Increased FV and AV (22 Hips)	Valgus and Increased FV and AV (9 Hips)	Overall P Value
Posterior impingement test (see Figure 3A)	90	95	89	.758
20° of external rotation at 0° of extension	33	27	67	.109
FABER test at 20° of flexion				
20° of external rotation	10	5	67 ^{b,c}	<.001
30° of external rotation (see Figure 3B)	67	22 ^b	67 ^c	<.001
40° of external rotation (see Figure 3C)	95	95	100	NS
0° of external rotation at 20° of extension	62	45	67	.427

^aValues are presented as percentages. Level of significance was adjusted for 3 groups (.05/3 = .016) with the Bonferroni correction. Posterior impingement test signifies 20° of extension with 20° of external rotation. AV, acetabular version; FABER, flexion, abduction, and external rotation; FV, femoral version; NS, not significant.

^bStatistically significant difference vs hips with isolated increased FV ($P < .016$).

^cStatistically significant difference vs hips with increased FV and AV ($P < .016$).

TABLE A5
Prevalence of Posterior Intra-articular Hip Impingement for the 3 Subgroups With Posterior Hip Impingement During Different Motion Patterns^a

	Isolated Increased FV (21 Hips)	Increased FV and AV (22 Hips)	Valgus and Increased FV and AV (9 Hips)	Overall P Value
Posterior impingement test (see Figure 3A)	67	36	67	.096
20° of external rotation at 0° of extension	24	9	56 ^c	.021
FABER test at 20° of flexion				
20° of external rotation	0	5	0	.793
30° of external rotation (see Figure 3B)	10	5	22	NS
40° of external rotation (see Figure 3C)	5	9	44 ^{b,c}	<.001
0° of external rotation in 20° of extension	5	5	33	.029

^aValues are presented as percentages. Posterior impingement test signifies 20° of extension combined with 20° of ER. AV, acetabular version; FABER, flexion, abduction, and external rotation; FV, femoral version; NS, not significant.

^bStatistically significant difference vs hips with isolated increased FV ($P < .016$).

^cStatistically significant difference vs hips with increased FV and AV ($P < .016$).