

## RESEARCH ARTICLE

# Ethanol binge drinking exposure affects alveolar bone quality and aggravates bone loss in experimentally-induced periodontitis

Deborah Ribeiro Frazão<sup>1</sup>\*, Cristiane do Socorro Ferraz Maia<sup>2</sup>\*, Victória dos Santos Chemelo<sup>1</sup>, Deiweson Monteiro<sup>1</sup>, Railson de Oliveira Ferreira<sup>1</sup>, Leonardo Oliveira Bittencourt<sup>1</sup>, Gabriela de Souza Balbinot<sup>3</sup>, Fabrício Mezzomo Collares<sup>3</sup>, Cassiano Kuchenbecker Rösing<sup>4</sup>, Manoela Domingues Martins<sup>5</sup>, Rafael Rodrigues Lima<sup>1</sup>\*

**1** Laboratory of Functional and Structural Biology, Institute of Biological Sciences, Federal University of Pará (UFPA), Belém, Pará, Brazil, **2** Laboratory of Inflammation and Behavior Pharmacology, Pharmacy Faculty, Institute of Health Science, Federal University of Pará (UFPA), Belém, Pará, Brazil, **3** Dental Materials Laboratory, School of Dentistry, Federal University of Rio Grande do Sul (UFRGS), Porto Alegre, Brazil, **4** Department of Periodontology, School of Dentistry, Federal University of Rio Grande do Sul (UFRGS), Porto Alegre, Brazil, **5** Department of Oral Pathology, School of Dentistry, Federal University of Rio Grande do Sul (UFRGS), Porto Alegre, Brazil

\* These authors contributed equally to this work.

\* rafalima@ufpa.br, rafaelrodrigueslima@hotmail.com



## OPEN ACCESS

**Citation:** Frazão DR, Maia CdSF, Chemelo VdS, Monteiro D, Ferreira RdO, Bittencourt LO, et al. (2020) Ethanol binge drinking exposure affects alveolar bone quality and aggravates bone loss in experimentally-induced periodontitis. PLoS ONE 15 (7): e0236161. <https://doi.org/10.1371/journal.pone.0236161>

**Editor:** Timothy Damron, SUNY Upstate Medical University, UNITED STATES

**Received:** January 28, 2020

**Accepted:** June 30, 2020

**Published:** July 30, 2020

**Peer Review History:** PLOS recognizes the benefits of transparency in the peer review process; therefore, we enable the publication of all of the content of peer review and author responses alongside final, published articles. The editorial history of this article is available here: <https://doi.org/10.1371/journal.pone.0236161>

**Copyright:** © 2020 Frazão et al. This is an open access article distributed under the terms of the [Creative Commons Attribution License](https://creativecommons.org/licenses/by/4.0/), which permits unrestricted use, distribution, and reproduction in any medium, provided the original author and source are credited.

**Data Availability Statement:** All relevant data are within the manuscript and its Supporting Information files.

## Abstract

### Background

Periodontitis is a multifactorial inflammatory disease of tooth supporting tissues caused by oral biofilms, influenced by environmental and genetic factors, among others. Ethanol consumption has been considered a factor that enhances alveolar bone loss, especially in high doses. The present study aims to investigate the changes promoted by ethanol binge drinking *per se* or associated with ligature-induced periodontal breakdown on alveolar bone loss.

### Materials and methods

Thirty-two Wistar rats were randomly allocated into four groups: control (C), ethanol (3g/kg/day; 3 days On-4 days Off protocol by gavage for 28 days, EtOH), experimental periodontitis (EP) and experimental periodontitis plus ethanol administration (EP+EtOH). On day 14<sup>th</sup>, periodontitis was induced by ligatures that were placed around the lower first molars. On day 28<sup>th</sup>, the animals were euthanized and mandibles were submitted to stereomicroscopy for exposed root area analysis and micro-computed tomography (micro-CT) for the evaluation of alveolar bone loss and microstructural parameters.

### Results

The results revealed that ligature-induced alveolar bone loss is aggravated by ethanol binge drinking compared to controls ( $1.06 \pm 0.10$  vs  $0.77 \pm 0.04$ ;  $p < 0.0001$ ). In addition, binge drinking *per se* altered the alveolar bone quality and density demonstrating a reduction in trabecular thickness, trabecular number parameter and bone density percentual.

**Funding:** This study was partially supported by a grant provided by CNPq - Brazilian National Council for Scientific and Technological Development - 435093/2018-5 (DF, VC, RO, DF, LB, RL), CAPES/PROCAD - Higher Education Improvement Coordination - 23038.005350/2018-78 (CM, GB, FC, CR, MD, RL) and (CAPES) – Finance Code 001. The funders had no role in study design, data collection and analysis, decision to publish, or preparation of the manuscript. The APC was funded by Pró-Reitoria de Pesquisa e Pós-graduação from Federal University of Pará (PROPESP-UFPa). The funders had no role in study design, data collection and analysis, decision to publish, or preparation of the manuscript.

**Competing interests:** The authors have declared that no competing interests exist.

Periodontal disorder plus ethanol binge drinking group also demonstrated reduction of the quality of bone measured by trabecular thickness.

## Conclusions

In conclusion, intense and episodic ethanol intake decreased alveolar bone quality in all microstructural parameters analyzed which may be considered a modifying factor of periodontitis, intensifying the already installed disease.

## Introduction

Periodontitis is a multifactorial inflammatory disease, which affects the tooth supporting tissues (i.e., periodontal ligament, cementum, and alveolar bone). Periodontal destruction has been observed among 60–70% of the global population. As a multifactorial disease, 20% of the clinical findings of periodontitis are related to oral biofilms, however, the other 80% are linked to behavioral, environmental and genetic factors, which can modify periodontitis progression. In addition, immunological host response plays a pivotal role in prognosis of periodontally diseased individuals [1, 2].

Some medical conditions, smoking, and social history are described as disease modifiers. They seem to act altering the expression of periodontal disease. However, the exact role of systemic diseases and exposure to different risk indicators in initiating or modifying the progress of the periodontal disease is complex and not fully understood. Diabetes and smoking are the known true risk factors for periodontal disease. Diabetes is characterized as a progressive factor if the glycemic levels are above ideal [3].

Another factor, classified as behavioral, is smoking, which is associated with increased alveolar bone loss. As smoking is often related to alcohol consumption, the toxicological effects caused by ethanol have been related as possible alveolar bone loss intensified by its consumption [4]. Limited studies have linked alcohol consumption and periodontitis [5–7], however, evidence suggests that the relationship exists with several gaps on the exact interaction between alcohol and periodontitis [5, 8]. In the relationship between alcohol exposure and occurrence and progression of periodontitis, a J-curve has been proposed, in which low doses tend to be associated with lower progression and high doses with a more aggressive pattern of progression. Our group has been working on the association between alcohol intake and oral health consequences in animal models both on a heavy alcohol exposure paradigm [9, 10] and with binge drinking-type protocol [11].

Ethanol harmful effects in the oral cavity seem to be proportional to the alcohol-exposure pattern [7, 12, 13]. Enzymatic induction, immune modifier, as well as cementum formation and osteoblast activity reduction have been suggested to alcohol-related oral cavity health disorders [8, 10].

In addition, binge drinking pattern has been reported as the principal type of ethanol exposure among adolescents and adults [14]. Such “social behavior”, characterized by large amounts of alcohol in a short period of time, provokes overspread damages in several organs and tissues, and is not restricted to the central nervous system or liver [15]. The exact pathogenic mechanism that underlies ethanol harmful effects has been extensively investigated, however, it has been postulated that inflammatory and oxidative damage are two important pathways on the alcohol-related tissue damage [16]. Both ethanol pathological via that was described above are shared by periodontitis [17]. The aim of the present study was to assess

the effect of binge drinking on alveolar bone loss in Wistar rats. We hypothesize that prolonged binge drinking exposure is associated with the development of spontaneous periodontitis. Our second hypothesis relies on ethanol exposure increasing the impairment caused by ligature-induced periodontitis.

## Material and methods

### Animals

Wistar rats (90 days-old;  $n = 32$ ), obtained from animal facility (Federal University of Pará), were randomly allocated to cages ( $n = 4$ ), with controlled food (NUVITAL<sup>®</sup>, 3 pellets/animal) and water *ad libitum*. A 12 h light/dark cycle (lights on 7 AM) and temperature control ( $25 \pm 1^\circ\text{C}$ ) was used. All procedures were approved by the Ethics Committee on Experimental Animals of the UFPA (under number 6896071217), according to *NIH Guide for the Care and Use of Laboratory Animals* recommendations.

### Experimental procedures

[Fig 1](#) describes the study protocol. Animals were divided into 4 groups. In the control group (C, G1), animals received distilled water. Ethanol group (EtOH, G2) received ethanol binge drinking protocol characterized by 30% w/v ingestion in 4 sections of 3 consecutive days On-4 days Off protocol by gavage [18]. On the 14<sup>th</sup> day of experiment, the animals from experimental periodontitis group (EP, G3) and experimental periodontitis + ethanol group (EP + EtOH, G4) were submitted to intraperitoneal anesthesia [xylazine 2% (2mg/ml) plus ketamine 10% (10mg/ml)] and the ligature-induced periodontitis was installed by insertion of cotton ligatures (Coats Corrente, São Paulo, SP, Brazil) around the cervical regions of the first inferior molars, which was maintained until euthanasia, as previously described [19]. Ligatures were maintained for 14 days [19, 20]. Following the ethanol binge drinking protocol, animals were euthanized by intraperitoneal anesthesia [xylazine 2% (2mg/ml) plus ketamine 10% (10mg/ml)] followed by cervical dislocation, and jaws were collected. The right hemimandibles were maintained in physiologic serum (NaCl 0.9%) under the refrigerator for stereomicroscopic analyses. The left hemimandibles were maintained in formol solution 4% for micro-computed tomography (micro-CT) evaluation.

**Stereomicroscopic analyses.** The right hemimandibles from each animal ( $n = 8$ , each group) were examined by a stereomicroscope (Discovery V8 Zeiss, Germany). The samples were immersed in 10% sodium hypochlorite (NaOCl) for three hours and then they were washed in an ultrasonic bath with distilled water for 2 minutes. To make a better differentiation of the cementum-enamel junction (CEJ), the hemimandibles were immersed in 1% methylene blue for 60 seconds. After they dry at room temperature, the samples were fixed with wax n° 9 (Lysanda, Vila Prudente, São Paulo, Brazil) on individual glass slides with the lingual face of the teeth perpendicular to the axis of observation. The pictures were obtained with a 6.1-megapixel camera (Cannon, Powershot A640) coupled with the stereomicroscope (30.0X). Then, the measurement of the exposed root area (ERA) was made through these images, captured with an adequate scale, from the lingual face of the first molar.

**Bodyweight evaluation.** For bodyweight measurement, all animals were weighted weekly.

**Micro-computed tomography (micro-CT) analysis.** Animals left hemimandibles were submitted to micro-CT (MicroCT.SMX-90 CT; Shimadzu Corp., Kyoto, Japan). Images were captured under a rotation of  $360^\circ$ , with an intensity of 70kV and 100 mA. After this, images were reconstituted by inspeXio SMX-90CT software (Shimadzu Corp., Kyoto, Japan), with a voxel size of  $10 \mu\text{m}$  and resolution of  $1024 \times 1024$  which resulted in 541 images per sample. Bone loss was evaluated in height by RadiAnt DICOM Viewer 5.0.1 (Medixant, Poznan,

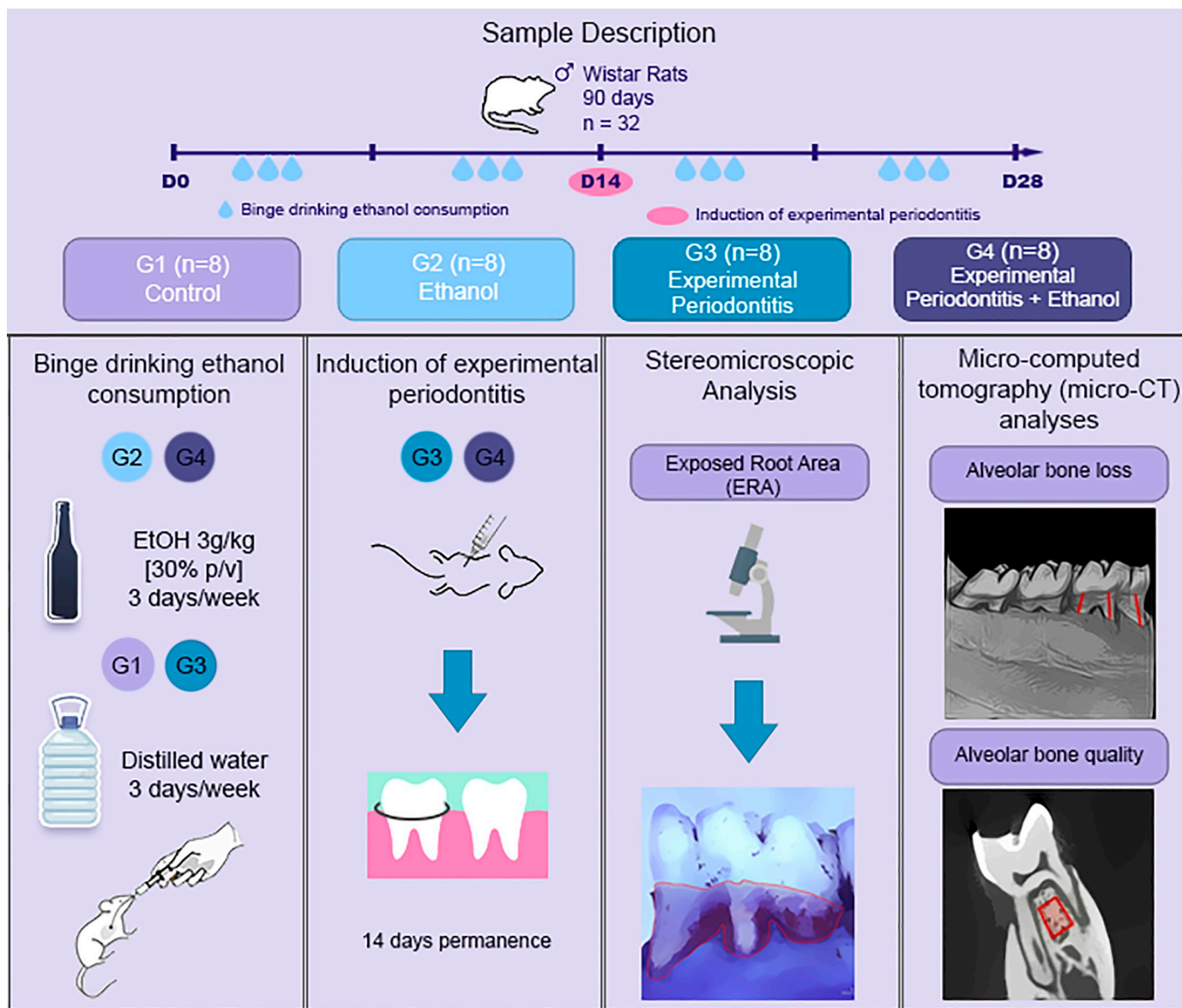


Fig 1. Sample description and experimental steps.

<https://doi.org/10.1371/journal.pone.0236161.g001>

Poland) where the 3D reconstruction of the hemimandibulas was performed. The tridimensional models were placed on a standard position (Fig 1), where the vestibular and lingual tooth face could be observed. Thus, the vertical bone loss was detected through the measurement of the distance between the cementum-enamel junction and the alveolar bone crest at six points of the first inferior molar, (i.e., mesio-buccal, buccal, distobuccal, disto-lingual, lingual and mesio-lingual) [21], performing the average of these regions.

To verify the alveolar bone tissue quality, the ImageJ® (National Institutes of Health, Bethesda, MD, USA) software was used on a set of 70 images from the inferior first molar alveolar bone region. The interradicular region, close to the furcation area, from the inferior first molar, including the cervical third until the middle third of the root (average area of 0.160mm<sup>2</sup>), was chosen as the standardized region of interest (Fig 1).

The threshold (0–70) was applied to the segmentation of the different scores of gray color present in the image. The plug-in BoneJ (National Institutes of Health, Bethesda, MD, USA) was used to evaluate the trabecular number (Tb.N), trabecular thickness (Tb.Th), trabecular separation (Tb.Sp), and the percentual of bone density (%BV/TV).

## Statistical analyses

Animals number samples per group were obtained by G\*Power software (Statistical Power Analyses 3.1.9.2). Data distribution normality was analyzed by Shapiro-Wilk test. Statistical analyses were performed by one-way ANOVA followed by Tukey test. Bodyweight data was evaluated by repeated measure two-way ANOVA. Student t test was performed to compare two specific groups. All results were expressed as mean  $\pm$  standard deviation (SD). Statistical differences were adopted when  $p < 0.05$ . GraphPad Prism 6.0. software (GraphPad, San Diego, CA, USA) was employed for statistical analyses.

## Results

### Bodyweight evaluation

Mean body weight did not reveal statistically significant differences among groups. (control:  $246.1 \pm 6.29$ ; ethanol:  $230.6 \pm 3.45$ ; ligature-induced periodontitis:  $238 \pm 1.98$ ; ligature-induced periodontitis + ethanol:  $254.8 \pm 3.87$ ;  $p = 0.97$ ).

### Stereomicroscopic analysis

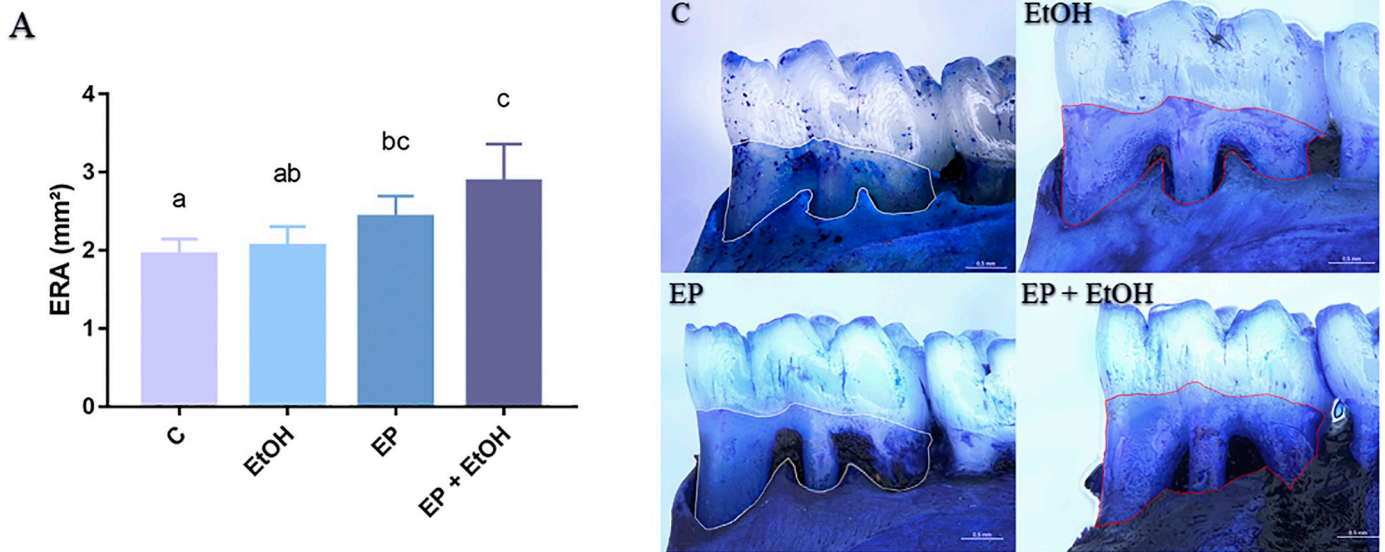
**Exposed root area (ERA).** The stereomicroscopic analyses showed that ethanol binge drinking exposure did not increase the ERA compared to animals that were not exposed to ethanol ( $2.05 \pm 0.08$  vs  $1.94 \pm 0.08$ ;  $p = 0.90$ ). However, the animals from the EP + EtOH group presented a higher area of exposed root in comparison to ethanol *per se* protocol ( $2.88 \pm 0.21$  vs  $2.05 \pm 0.08$ ;  $p = 0.0005$ ) and controls ( $2.88 \pm 0.21$  vs  $1.94 \pm 0.08$ ;  $p = 0.0002$ ). The graphic representation of the stereomicroscopic analysis is shown on [Fig 2](#).

### Micro-computed tomography (micro-CT) analysis

**Alveolar bone loss.** 3D hemimandible analyses show that four ethanol binge drinking exposure did not display additional alveolar bone loss as compared to animals that were not exposed to ethanol protocol ( $0.82 \pm 0.08\text{mm}$  vs  $0.77 \pm 0.04\text{mm}$ ;  $p = 0.49$ ). However, animals submitted to binge drinking protocol plus experimental periodontitis presented an increase in alveolar bone loss compared to ethanol *per se* protocol ( $0.82 \pm 0.08\text{mm}$  vs  $1.06 \pm 0.10\text{mm}$ ;  $p = 0.0001$ ), as well as experimental periodontitis ( $1.06 \pm 0.10\text{mm}$  vs  $0.92 \pm 0.03\text{mm}$ ;  $p = 0.003$ ) and control ( $1.06 \pm 0.10\text{mm}$  vs  $0.77 \pm 0.04\text{mm}$ ;  $p < 0.0001$ ) ([Fig 3](#)).

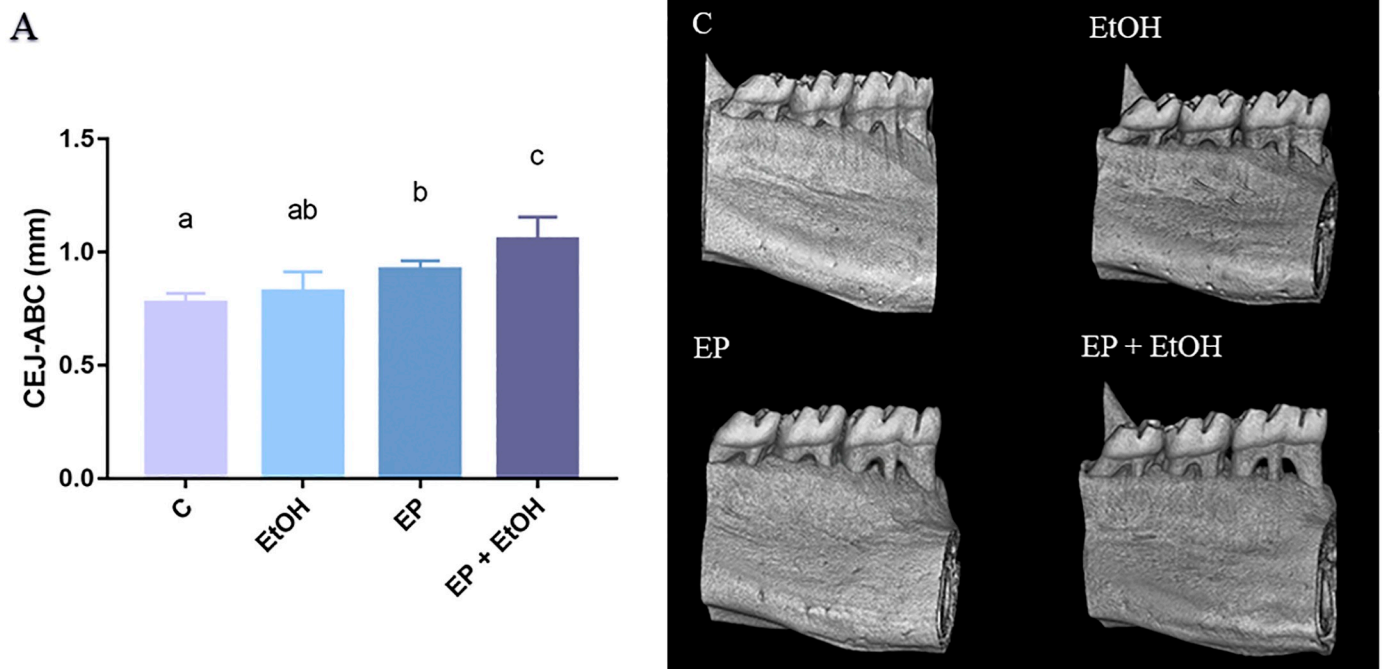
**Alveolar bone quality and bone density.** Control group (C) presented the higher trabecular thickness parameter (Tb.Th) values ( $0.15 \pm 0.02\text{mm}$ ). Interestingly, four binge drinking exposure in ethanol group showed reduction in Tb.Th even in the absence of experimental-induced periodontitis ( $p = 0.0468$ ). In experimental periodontitis group (EP) as well as in experimental periodontitis + ethanol (EP + EtOH) a decrease in Tb.Th parameter was observed compared to control and ethanol groups ( $p < 0.0001$ ). However, they were similar indicating that ethanol exposure *per se* promoted Tb.Th reduction and it was not intensified by experimental periodontitis induction.

In addition to Tb.Th, trabecular number parameter (Tb.N) was also evaluated. Similarly to Tb.Th data, Tb.N was reduced in Ethanol group compared to control ( $p = 0.0041$ ) and when experimental periodontitis was induced a decrease in bone quality was also detected (i.e.,



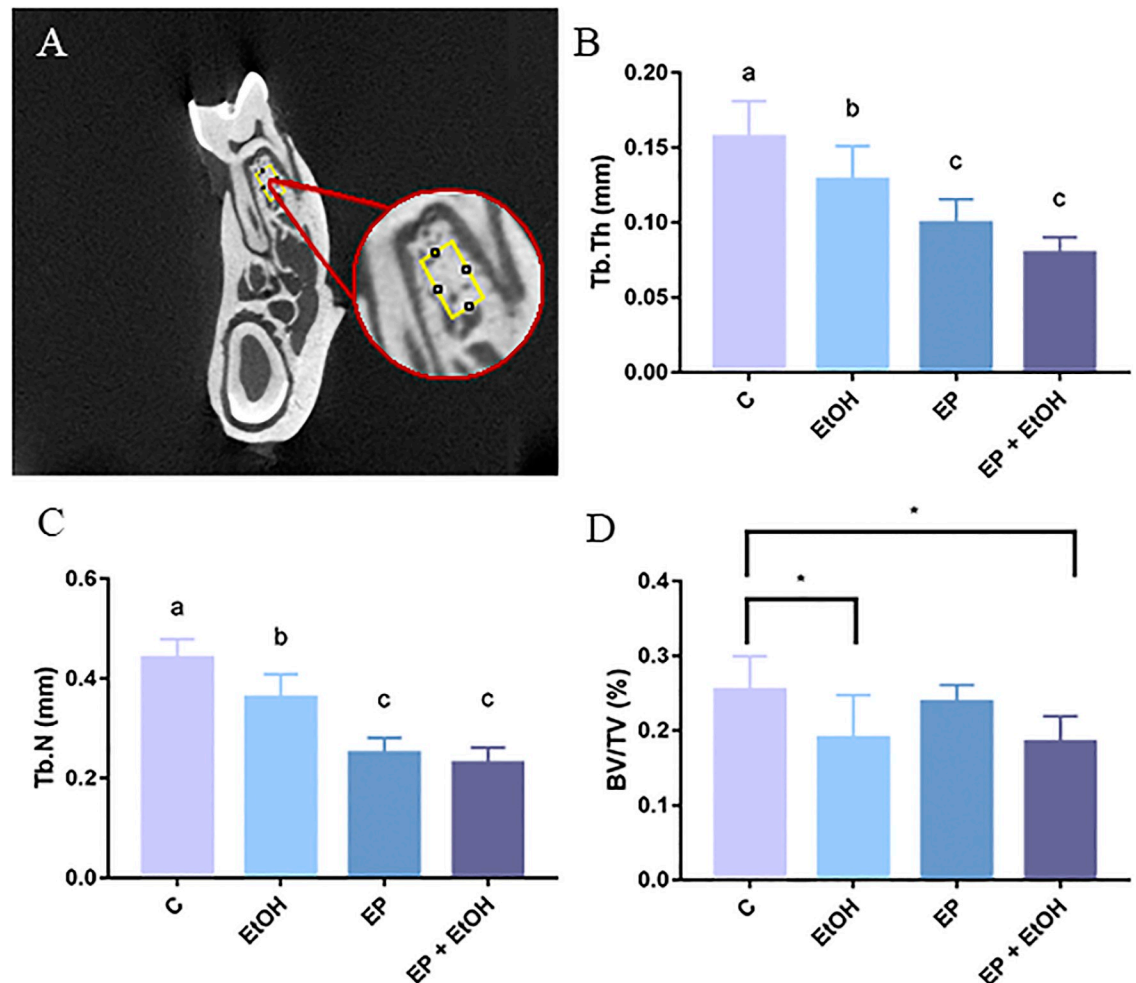
**Fig 2. Exposed root area in mm<sup>2</sup> in all experimental groups.** (A) Results are expressed as mean ± standard error of the number of exposed root area. On the right, representative photomicrographs of hemi-mandibles of the (C) Control group; (EtOH) Ethanol binge drinking group; (EP) Experimental periodontitis group and (EP + EtOH) Experimental periodontitis and Ethanol group. EP+EtOH group presented the highest ERA identified among the groups. Same letters indicate no significant differences between groups ( $P < 0.05$ , ANOVA followed by Tukey *post hoc* test). Scale bar: 0.5mm.

<https://doi.org/10.1371/journal.pone.0236161.g002>



**Fig 3. Cementum-enamel junction to alveolar bone crest (CEJ-ABC) distance (mm) in all experimental groups.** (A) Results are expressed as mean ± standard error of the distance of cementum-enamel junction to alveolar bone crest in mm. On the right panel, there is the 3D reconstruction of hemi-mandibles of the (C) Control group; (EtOH) Ethanol binge drinking group; (EP) Experimental periodontitis group and (EP + EtOH) Experimental periodontitis and Ethanol group. EP + EtOH group presented the highest alveolar bone loss identified by the greatest measure of the ACJ-ABC distance. Same letters indicate no significant differences between groups ( $P < 0.05$ , ANOVA followed by Tukey *post hoc* test).

<https://doi.org/10.1371/journal.pone.0236161.g003>



**Fig 4. Results from the Micro-CT quality analysis.** (A) Region of interest (ROI) used for evaluation. (B) Trabecular thickness parameter (Tb.Th) in all experimental groups. (C) Trabecular number parameter (Tb.N). For these results, same letters indicate no significant differences between groups ( $P < 0.05$ , ANOVA followed by Tukey post hoc test). (D) Bone density (%) parameter (BV/TV) obtained by micro-computed tomography (micro-CT). (\*) indicates significant difference between the groups ( $p < 0.05$ ).

<https://doi.org/10.1371/journal.pone.0236161.g004>

ligature-induced periodontitis and ligature-induced periodontitis plus ethanol binge drinking groups;  $p < 0.0001$ ). In fact, no differences were observed between experimental periodontitis *versus* experimental periodontitis plus ethanol exposure groups ( $p = 0.8188$ ), which is in accordance with Tb.Th evaluation, that reflects no synergistic pathological effects in this parameter.

Percent bone density (%BV/TV) was reduced solely in the ethanol binge drinking animals when compared to control group ( $p = 0.0411$ ). Experimental periodontitis *per se* did not affect bone density. The graphic representation of all quality and density parameters are shown on Fig 4.

## Discussion

The present study aimed to investigate the effects of intermittent and episodic ethanol exposure in mandibular alveolar bone accompanied or not by experimental-induced periodontitis in rats. Our findings showed, for the first time, that intermittent and episodic ethanol exposure *per se* did not increase alveolar bone loss, however, the bone quality was altered in all

parameters evaluated. In addition, experimentally induced periodontitis aggravated the alveolar bone loss and trabecular thickness when ethanol intake was associated.

Different protocols have tested the effect of ethanol exposure on periodontal diseases in animal models with distinct results [6, 7, 10, 13, 22, 23]. The idea behind such studies comes from the demonstrated association between alcohol consumption, especially in high doses, with periodontal diseases in populational studies even in a longitudinal approach [6]. The studies performed in animals help in the understanding of the biological plausibility of the encountered associations in populations. Our group has investigated the effects of ethanol exposure on the stomatognathic system, both in chronic as well as in a binge drinking protocol [9–11]. In alveolar bone, our previous data demonstrated that chronic heavy ethanol exposure (6.5g/kg/day) from adolescence till adulthood led to increased alveolar bone loss, even in the absence of experimentally-induced periodontitis [10]. Contradictorily, other study reported that different ethanol concentrations consumed for 8 weeks did not increase alveolar bone loss, however, in the presence of ligature-induced periodontitis, alveolar bone loss was higher than in the control group [23].

In the present investigation, we verified that intense and sporadic alcohol intake promoted changes in quality and density of alveolar bone alone and in association with ligature-induced periodontitis. The 3 days On- 4 days-Off ethanol (3g/kg/day) protocol has been tested in animal model, the results demonstrated that it is a valid way to simulate binge drinking [24–26]. Binge drinking protocol has been widely used for investigation related to bone tissue alterations provoked by alcohol intake in a rat model. It has been described that alcohol exposure displayed a disordered expression of genes that play a pivotal role in bone remodeling [27]. In another study, bone resorption under orthodontic treatment was intensified by binge pattern exposure [28]. In addition, reduced bone mineral density and changes in the number of bone tissue biomarkers, such as receptor activator of nuclear factor-kappa-B ligand (RANKL) and osteoprotegerin (OPG), has been attributed to ethanol intake [29]. However, it is not well established the effects of binge drinking on the vertical alveolar bone loss, as well as on the alveolar bone quality in adult rats. Besides, we investigated if ethanol exposure interferes on alveolar bone loss and quality displayed by ligature-induced periodontal disease.

In order to verify the effects of binge drinking on the vertical alveolar bone loss, as well as on the alveolar bone quality micro-CT was employed [30–33]. Micro-CT has become the gold standard for bone tissue morphology and microstructure analysis in small animal models, such as rats and mice, as it enables high-definition three-dimensional reconstruction of samples and evaluate both cortical and trabecular bone [34]. Firstly, our data revealed that 3 days On- 4 days Off ethanol exposure protocol did not increase vertical alveolar bone loss. The previous study of our group demonstrated that daily administered heavy ethanol exposure from adolescence till adulthood increased alveolar bone loss [10]. These findings suggest that the harmful effects of ethanol exposure on alveolar bone loss, as well as other body tissues, depends on the period of life, as well as the duration of exposure and amount of consumption. In addition to binge drinking exposure, on the 14<sup>th</sup> day of ethanol exposure, we submitted animals from two groups to ligature-induced periodontitis. Animals that received the associated protocol (ligature-induced periodontitis + binge drinking) presented higher alveolar bone loss compared to the others that were submitted to experimental periodontitis and ethanol exposure protocols. These data suggest that prolonged ethanol exposure may aggravate alveolar bone loss on the presence of periodontal disorder. These results could be explained by the fact that alcohol exposure promotes oxidative damage and pro-inflammatory effects affecting bone homeostasis, accelerating bone resorption process as well as inhibiting bone formation [35–37]. Additionally, recent studies have shown that bone density is reduced by heavy ethanol consumption, with osteocalcin decrease and RANK / OPG ratio increase [8, 22, 35].



Although increased alveolar bone loss was not observed in the group that was solely exposed to ethanol, the alveolar bone quality was negatively altered by binge drinking. In fact, trabecular thickness, trabecular number, and percent bone density was affected by ethanol-exposed animals. A recent study reported that trabecular structures (i.e., thickness and number) were reduced in sub-chronic ethanol consumption protocol [38], which supports our findings. Likewise, it is well established that ethanol consumption displays oxidative imbalance and pro-inflammatory processes [39].

Another very interesting finding of our study is the fact that ethanol exposure associated with experimental periodontitis aggravated alveolar bone loss and also disrupted bone quality indicators. Similar to ethanol consumption, periodontitis is also related to oxidative imbalance [40, 41]. We suggest that the pathological mechanisms shared by both isolated harmful stimuli, such as ethanol exposure and experimental periodontal disease, may provoke negative synergistic effects, intensifying alveolar bone tissue damage. Alcohol has been studied as a modifying factor of periodontal disease. In humans, a systematic review shows that several studies demonstrated an association between ethanol consumption and dependence with periodontitis. Although the heterogeneity between the articles is high, differing in the method of sample selection, alcohol consumption and alcohol use, periodontal indices and statistical analysis, the trend clearly demonstrates a detrimental effect [42]. Regarding the limits in translational researches, our results using pre-clinical animal model corroborate the idea that alcohol could negatively impact the pathogenesis of periodontitis. One possible explanation for that, is that the increase of C-reactive protein levels, as well as decrease of neutrophil chemotaxis and phagocytosis elicited by ethanol exposure may predispose to infection by periodontal bacteria [6]. In addition, TNF- $\alpha$  and IL-6 levels are higher in alcohol users [29], which might be equally in crevicular fluid, being related to the presence of periodontitis [6]. Furthermore, it is noteworthy that alcohol modulates bone cell activities in a dose-dependent manner. Thus, ethanol exposure causes an imbalance of the OPG / RANK / RANKL system, implicating in reduced osteoblast activity and osteoclastogenesis improvement [8, 10, 36], which consists of processes that also occurs during periodontitis development [43].

## Conclusion

It may be concluded that the intense and episodic ethanol intake (“binge pattern”) promoted decrease in quality of alveolar bone in all parameters analyzed. In addition, we demonstrated that experimentally-induced periodontitis was aggravated binge drinking-like alcohol exposure, qualitatively and quantitatively. Thus, alcohol exposure is possibly related to the modification of the progression periodontitis, intensifying bone tissue damage.

## Supporting information

**S1 File.**  
(DOCX)

## Acknowledgments

The authors are grateful to the Brazilian National Council for Scientific and Technological Development (CNPq) and Programa Nacional de Cooperação Acadêmica na Amazônia—PROCAD/Amazônia da Coordenação de Aperfeiçoamento de Pessoal de Nível Superior (CAPES).

## Author Contributions

**Conceptualization:** Deborah Ribeiro Frazão, Railson de Oliveira Ferreira, Rafael Rodrigues Lima.

**Formal analysis:** Deborah Ribeiro Frazão, Manoela Domingues Martins, Rafael Rodrigues Lima.

**Funding acquisition:** Rafael Rodrigues Lima.

**Investigation:** Deborah Ribeiro Frazão, Victória dos Santos Chemelo, Deiweson Monteiro, Railson de Oliveira Ferreira, Leonardo Oliveira Bittencourt, Gabriela de Souza Balbinot, Rafael Rodrigues Lima.

**Methodology:** Deborah Ribeiro Frazão, Deiweson Monteiro, Railson de Oliveira Ferreira, Leonardo Oliveira Bittencourt, Gabriela de Souza Balbinot, Rafael Rodrigues Lima.

**Project administration:** Deborah Ribeiro Frazão.

**Supervision:** Victória dos Santos Chemelo, Fabrício Mezzomo Collares, Cassiano Kuchenbecker Rösing, Rafael Rodrigues Lima.

**Validation:** Cristiane do Socorro Ferraz Maia, Fabrício Mezzomo Collares, Cassiano Kuchenbecker Rösing, Rafael Rodrigues Lima.

**Writing – original draft:** Deborah Ribeiro Frazão, Cristiane do Socorro Ferraz Maia, Manoela Domingues Martins, Rafael Rodrigues Lima.

**Writing – review & editing:** Cristiane do Socorro Ferraz Maia, Fabrício Mezzomo Collares, Cassiano Kuchenbecker Rösing, Manoela Domingues Martins, Rafael Rodrigues Lima.

## References

1. Lang NP, Bartold PM. Periodontal health. *J Periodontol.* 2018; 89: S9–S16. <https://doi.org/10.1002/JPER.16-0517> PMID: 29926938
2. Papapanou PN, Sanz M, Buduneli N, Dietrich T, Feres M, Fine DH, et al. Periodontitis: Consensus report of workgroup 2 of the 2017 World Workshop on the Classification of Periodontal and Peri-Implant Diseases and Conditions. *J Periodontol.* 2018; 89: S173–S182.
3. Albandar JM, Susin C, Hughes FJ. Manifestations of systemic diseases and conditions that affect the periodontal attachment apparatus: Case definitions and diagnostic considerations. *J Periodontol.* 2018; 89: S183–S203. <https://doi.org/10.1002/JPER.16-0480> PMID: 29926941
4. Dantas AM, Mohn CE, Burdet B, Zubilete MZ, Mandalunis PM, Elverdin JC, et al. Ethanol consumption enhances periodontal inflammatory markers in rats. *Arch Oral Biol.* 2012; 57: 1211–1217. <https://doi.org/10.1016/j.archoralbio.2012.02.008> PMID: 22424886
5. Wang J, Lv J, Wang W, Jiang X. Alcohol consumption and risk of periodontitis: A meta-analysis. *J Clin Periodontol.* 2016; 43: 572–583. <https://doi.org/10.1111/jcpe.12556> PMID: 27029013
6. Wagner MC, Haas AN, Oppermann R V., Rosing CK, Albandar JM, Susin C. Effect of Alcohol Consumption on Clinical Attachment Loss Progression in an Urban Population From South Brazil: A 5-Year Longitudinal Study. *J Periodontol.* 2017; 88: 1271–1280. <https://doi.org/10.1902/jop.2017.170231> PMID: 28753103
7. Liberman DN, Pilau RM, Gaio EJ, Orlandini LF, Rösing CK. Low concentration alcohol intake may inhibit spontaneous alveolar bone loss in Wistar rats. *Arch Oral Biol.* 2011; 56: 109–113. <https://doi.org/10.1016/j.archoralbio.2010.09.012> PMID: 20943212
8. Corrêa MG, Gomes Campos ML, Marques MR, Ambrosano GMB, Casati MZ, Nociti FH, et al. Alcohol intake may impair bone density and new cementum formation after enamel matrix derivative treatment: Histometric study in rats. *J Periodontol Res.* 2016; 51: 60–69. <https://doi.org/10.1111/jre.12279> PMID: 25959998
9. Fernandes LMP, Teixeira FB, Junior SMA, Pinheiro J de JV, Maia C do SF, Lima RR. Immunohistochemical changes and atrophy after chronic ethanol intoxication in rat salivary glands. *Histol Histo-pathol.* 2015; 30: 1069–1078. <https://doi.org/10.14670/HH-11-604> PMID: 25761695

10. Bannach SV, Teixeira FB, Fernandes LMP, Ferreira RO, da Silva Santana LN, Fontes-Júnior EA, et al. Alveolar bone loss induced by chronic ethanol consumption from adolescence to adulthood in wistar rats. *Indian J Exp Biol*. 2015; 53: 93–97. PMID: [25757239](#)
11. Fagundes NCF, Fernandes LMP, Paraense RSDO, De Farias-Junior PMA, Teixeira FB, Alves SM, et al. Binge Drinking of Ethanol during Adolescence Induces Oxidative Damage and Morphological Changes in Salivary Glands of Female Rats. *Oxid Med Cell Longev*. 2016; 2016. <https://doi.org/10.1155/2016/7323627> PMID: [27579155](#)
12. Dal-Fabbro R, Marques-de-Almeida M, Cosme-Silva L, Capalbo LC, Ervolino E, Cintra LTA, et al. Effects of different alcohol concentrations on the development of apical periodontitis in rats. *Arch Oral Biol*. 2019; 108. <https://doi.org/10.1016/j.archoralbio.2019.104538> PMID: [31476521](#)
13. Wagner MC, da Rocha JM, Gaio EJ, Cavagni J, Carrard VC, Rösing CK. Effect of 15% alcohol dependence on alveolar bone loss and TNF- $\alpha$  secretion in wistar rats. *Braz Dent J*. 2016; 27: 135–140. <https://doi.org/10.1590/0103-6440201600545>
14. (CISA) C de ISS e Á. Relatório Global sobre Álcool e Saúde—2018. In: Brazil [Internet]. 2018. <http://www.cisa.org.br/artigo/10049/relatorio-global-sobre-alcool-saude-2018.php>
15. NIAAA—National Institute on Alcohol Abuse and Alcoholism. Alcohol's Effects on Health. 2019. <https://www.niaaa.nih.gov/>
16. Rocco A, Compare D, Angrisani D, Sanduzzi Zamparelli M, Nardone G. Alcoholic disease: Liver and beyond. *World J Gastroenterol*. 2014; 20: 14652–14659. <https://doi.org/10.3748/wjg.v20.i40.14652> PMID: [25356028](#)
17. Hernández-Ríos P, Pussinen PJ, Vernal R, Hernández M. Oxidative stress in the local and systemic events of apical periodontitis. *Front Physiol*. 2017; 8: 1–8.
18. Bertola A, Mathews S, Ki SH, Wang H, Gao B. Mouse model of chronic and binge ethanol feeding (the NIAAA model). *Nat Protoc*. 2013; 8: 627–637. <https://doi.org/10.1038/nprot.2013.032> PMID: [23449255](#)
19. Vargas-Sanchez PK, Moro MG, dos Santos FA, Anbinder AL, Kreich E, Moraes RM, et al. Agreement, correlation, and kinetics of the alveolar bone-loss measurement methodologies in a ligature-induced periodontitis animal model. *J Appl Oral Sci*. 2017; 25: 490–497. <https://doi.org/10.1590/1678-7757-2016-0517> PMID: [29069146](#)
20. Cavagni J, Seibel L, Gaio EJ, Rosing CK. Methodological aspects in the study of periodontal breakdown in rats: influence of the presence and time of ligature. *Acta Odontol Latinoam*. 2017; 30: 39–45. PMID: [28688185](#)
21. Virto L, Haugen HJ, Fernández-Mateos P, Cano P, González J, Jiménez-Ortega V, et al. Melatonin expression in periodontitis and obesity: An experimental in-vivo investigation. *J Periodontol Res*. 2018; 53: 825–831. <https://doi.org/10.1111/jre.12571> PMID: [29900537](#)
22. Bastos MF, Gaag GLD, Romero JR, Gabrieli JJM, Marques MR, Duarte PM. Effects of Cachaça, a typical Brazilian alcoholic beverage, on alveolar bone loss and density: A study in peripubertal rats. *Arch Oral Biol*. 2014; 59: 82–91. <https://doi.org/10.1016/j.archoralbio.2013.10.002>
23. de Souza DM, Ricardo LH, Kantoski KZ, da Rocha RF. Influence of alcohol consumption on alveolar bone level associated with ligature-induced periodontitis in rats. *Braz Oral Res*. 2009; 23: 326–332. <https://doi.org/10.1590/s1806-83242009000300017> PMID: [19893970](#)
24. de Oliveira Ferreira R, de Brito Silva R, Magno MB, Carvalho Almeida APCPS, Fagundes NCF, Maia LC, et al. Does periodontitis represent a risk factor for rheumatoid arthritis? A systematic review and meta-analysis. *Ther Adv Musculoskelet Dis*. 2019; 11: 1759720X1985851. <https://doi.org/10.1177/1759720x19858514> PMID: [31316593](#)
25. Lamarão-Vieira K, Pamplona-Santos D, Nascimento PC, Corrêa MG, Bittencourt LO, Dos Santos SM, et al. Physical Exercise Attenuates Oxidative Stress and Morphofunctional Cerebellar Damages Induced by the Ethanol Binge Drinking Paradigm from Adolescence to Adulthood in Rats. *Oxid Med Cell Longev*. 2019; 2019. <https://doi.org/10.1155/2019/6802424> PMID: [30911348](#)
26. Callaci John J., Hime Ryan, Lauing Kristen, Wezeman Frederick H. and Brownson K. Binge Alcohol-Induced Bone Damage is Accompanied by Differential Expression of Bone Remodeling-Related Genes in Rat Vertebral Bone. *Calcif Tissue Int*. 2009; 84: 474–484. <https://doi.org/10.1007/s00223-009-9240-z> PMID: [19330277](#)
27. Callaci JJ, Himes R, Lauing K, Wezeman FH, Brownson K. Binge alcohol-induced bone damage is accompanied by differential expression of bone remodeling-related genes in rat vertebral bone. *Calcif Tissue Int*. 2009; 84: 474–484. <https://doi.org/10.1007/s00223-009-9240-z> PMID: [19330277](#)
28. De Araujo CM, Johann ACBR, Camargo ES, Tanaka OM. The effects of binge-pattern alcohol consumption on orthodontic tooth movement. *Dental Press J Orthod*. 2014; 19: 93–98. <https://doi.org/10.1590/2176-9451.19.6.093-098.oar> PMID: [25628085](#)

29. Mikosch P. Alcohol and bone. *Wiener Medizinische Wochenschrift*. 2014; 164: 15–24. <https://doi.org/10.1007/s10354-013-0258-5> PMID: 24477631
30. Dai J, Ma Y, Shi M, Cao Z, Zhang Y, Miron RJ. Initial changes in alveolar bone volume for sham-operated and ovariectomized rats in ligature-induced experimental periodontitis. *Clin Oral Investig*. 2016; 20: 581–588. <https://doi.org/10.1007/s00784-015-1531-3> PMID: 26179986
31. Hassumi JS, Mulinari-Santos G, Fabris AL da S, Jacob RGM, Gonçalves A, Rossi AC, et al. Alveolar bone healing in rats: micro-CT, immunohistochemical and molecular analysis. *J Appl Oral Sci*. 2018; 26: e20170326. <https://doi.org/10.1590/1678-7757-2017-0326> PMID: 29898174
32. Lisboa MRP, Gondim D V., Ervolino E, Vale ML, Frota NPR, Nunes NLT, et al. Effects of Electroacupuncture on Experimental Periodontitis in Rats. *J Periodontol*. 2015; 86: 801–811. <https://doi.org/10.1902/jop.2015.140630> PMID: 25741581
33. Schmidt APG. DIMORFISMO SEXUAL DA CABEÇA DA MANDÍBULA EM MACACOS CAPUCHINOS: CEBUS APELLA—AVALIAÇÃO POR MICROTOMOGRAFIA COMPUTADORIZADA SEXUAL DIMORPHISM OF THE MANDIBULAR CONDYLE ON CAPUCHINS: CEBUS APELLA—EVALUATION BY COMPUTERIZED MICROTOMOGRAPHY Piracicaba D. 2019.
34. Bouxsein ML, Boyd SK, Christiansen BA, Guldberg RE, Jepsen KJ, Müller R. Guidelines for assessment of bone microstructure in rodents using micro-computed tomography. *J Bone Miner Res*. 2010; 25: 1468–1486. <https://doi.org/10.1002/jbmr.141> PMID: 20533309
35. Callaci JJ, Juknelis D, Patwardhan A, Sartori M, Frost N, Wezeman FH. The Effects of Binge Alcohol Exposure on Bone Resorption and Biomechanical and Structural Properties are Offset by Concurrent Bisphosphonate Treatment. *Alcohol Clin Exp Res*. 2004; 28: 182–191. <https://doi.org/10.1097/01.ALC.0000108661.41560.BF> PMID: 14745317
36. Chakkalakal DA. Alcohol-induced bone loss and deficient bone repair. *Alcohol Clin Exp Res*. 2005; 29: 2077–2090. <https://doi.org/10.1097/01.alc.0000192039.21305.55> PMID: 16385177
37. Fernández-Solà J, Porta AP. New treatment strategies for alcohol-induced heart damage. *Int J Mol Sci*. 2016; 17. <https://doi.org/10.3390/ijms17101651> PMID: 27690014
38. Martiniakova M, Sarocka A, Babosova R, Grosskopf B, Kapusta E, Goc Z, et al. Changes in the microstructure of compact and trabecular bone tissues of mice subchronically exposed to alcohol. *J Biol Res*. 2018; 25: 1–7. <https://doi.org/10.1186/s40709-018-0079-1> PMID: 29876325
39. Das SK, Vasudevan DM. Alcohol-induced oxidative stress. *Life Sci*. 2007; 81: 177–187. <https://doi.org/10.1016/j.lfs.2007.05.005> PMID: 17570440
40. Castro MML, Duarte NN, Nascimento PC, Magno MB, Fagundes NCF, Flores-Mir C, et al. Antioxidants as Adjuvants in Periodontitis Treatment: A Systematic Review and Meta-Analysis. *Oxid Med Cell Longev*. 2019; 2019: 1–24. <https://doi.org/10.1155/2019/9187978> PMID: 31428231
41. Chen M, Cai W, Zhao S, Shi L, Chen Y, Li X, et al. Oxidative stress-related biomarkers in saliva and gingival crevicular fluid associated with chronic periodontitis: A systematic review and meta-analysis. *Journal of clinical periodontology*. 2019. <https://doi.org/10.1111/jcpe.13112> PMID: 30989678
42. Amaral C da SF, Vettore MV, Leão A. The relationship of alcohol dependence and alcohol consumption with periodontitis: A systematic review. *J Dent*. 2009; 37: 643–651. <https://doi.org/10.1016/j.jdent.2009.04.011> PMID: 19576673
43. Dahiya P, Kamal R, Gupta R, Bhardwaj R, Chaudhary K, Kaur S. Reactive oxygen species in periodontitis. *J Indian Soc Periodontol*. 2013; 17: 411–416. <https://doi.org/10.4103/0972-124X.118306> PMID: 24174716