



## Bilateral ureterolithiasis in a 7-month-old cat

Juliane Elisabeth Gress Paz<sup>1\*</sup> <sup>1</sup> Fernanda Vieira Amorim da Costa<sup>2</sup> <sup>2</sup>  
Gabriela da Cruz Schaefer<sup>1</sup> <sup>1</sup> Jaqueline Wisnieski Heck<sup>3</sup> <sup>3</sup>

<sup>1</sup>Programa de Pós-graduação em Ciências Veterinárias, Universidade Federal do Rio Grande do Sul (UFRGS), 91540-000, Porto Alegre, RS, Brasil. E-mail: ju\_paz@msn.com. \*Corresponding author.

<sup>2</sup>Departamento de Medicina Animal, Universidade Federal do Rio Grande do Sul (UFRGS), Porto Alegre, RS, Brasil.

<sup>3</sup>Médica veterinária autônoma, Porto Alegre, RS, Brasil.

**ABSTRACT:** *Feline ureteral obstruction can have several causes; however, ureterolithiasis has been increasing in occurrence. The restriction of urinary flow induced by the obstruction has harmful consequences to the body and can lead to acute renal failure. Calcium oxalate ureterolithiasis is reported in older cats, aged mean 12 years old. A case of bilateral ureteral obstruction in a 7-month-old mixed breed cat is described in this report. Imaging tests such as abdominal ultrasonography, radiography and excretory urography were performed to determine the diagnosis. The surgical procedure of bilateral ureterotomy was then performed, which allowed the improvement of the urinary flow of both kidneys and the resolution of clinical signs caused by uremia. The quantitative analysis of both uroliths revealed the composition of 100% monohydrate calcium oxalate. Calcium oxalate stones can also cause ureteral obstruction in young cats; although, are less common in this age. When conservative treatment fails, surgical intervention becomes necessary for the rapid return of renal function. To author's knowledge this is the first report of a ureterolithiasis caused by calcium oxalate in a young cat.*

**Key words:** *feline, calcium oxalate, ureterolith, ureterotomy, ureteral obstruction.*

## Ureterolitíase bilateral em um gato de sete meses de idade

**RESUMO:** *A obstrução ureteral em gatos pode ter diversas causas, entretanto, a ureterolitíase vem apresentando um aumento na sua ocorrência. A restrição do fluxo urinário induzida pela obstrução traz consequências graves ao organismo, podendo levar a insuficiência renal aguda. A ureterolitíase por cálculos de oxalato de cálcio é relatada em gatos mais velhos, com média de idade de 12 anos. Um caso de obstrução ureteral bilateral em um gato, SRD, com sete meses de idade é descrito nesse relato. Exames de imagem, como ultrassonografia e radiografia abdominais e urografia excretora, foram realizados para confirmar o diagnóstico. O procedimento cirúrgico de ureterotomia bilateral foi então realizado, permitindo a melhora do fluxo urinário de ambos os rins e dos sinais clínicos de uremia. A análise quantitativa de ambos os urolitos revelou a composição de 100% oxalato de cálcio monohidratado. Cálculos de oxalato de cálcio são um diagnóstico diferencial para obstrução ureteral também em gatos jovens, apesar de serem menos comuns. Quando há falha no tratamento conservador, a intervenção cirúrgica torna-se necessária para o rápido restabelecimento e preservação da função renal. No conhecimento dos autores, esse é o primeiro relato de ureterolitíase causada por oxalato de cálcio em um gato jovem.*

**Palavras-chave:** *felino, oxalato de cálcio, ureterólito, ureterotomia, obstrução ureteral.*

Ureteral obstruction induces urinary flow restriction, which can result in an uremic crisis, changes in the structure of the kidneys and ureters, and loss of renal function in an acute way (HARDIE & KYLES, 2004). The return of renal function can occur if the obstruction lasts less than a week, but the kidneys are permanently impaired after four weeks of obstruction (WEN et al., 1999). Causes of ureteral obstruction in cats include uroliths, neoplasms, trauma, inflammation, fibrosis, congenital stenosis and blood clots. There is an increase in the diagnosis of ureterolithiasis in cats in recent years (CLARKE, 2018a). Although, more than 98% of feline ureteral

stones are composed of calcium oxalate (BERENT, 2011), this type of urolith tends to develop more frequently in mature and elderly cats (KIRK et al., 1995). The most frequent reported causes of ureteral obstruction in young cats are congenital or iatrogenic, being ureterolithiasis a very rare condition at this age (MESTRINHO et al., 2013; LEE et al., 2014; JOHNSON et al., 2015; IOANNIDI et al., 2019).

Medical treatment for ureteral obstruction is effective only for a minority of cats with urolithiasis (KYLES et al., 2005). The surgical techniques described include single or multiple ureterotomy, ureteral resection and anastomosis,

ureteral reimplantation, subcutaneous bypass, and ureteronephrectomy (JOHNSON et al., 2015; CLARKE, 2018b).

This reported the occurrence and surgical treatment of bilateral ureteral obstruction due to calcium oxalate stones in a 7-month-old mixed breed cat (Figure 1A), treated at the Feline Medicine Service of the Veterinary Clinic Hospital of the Federal University of Rio Grande do Sul. The owner reported that the animal presented signs of abdominal pain, halitosis, anorexia, and prostration for five days. The cat was feeding dry food. Abdominal palpation revealed a bilateral renal enlargement, in addition to abdominal pain. Blood tests revealed severe azotemia with a creatinine value of 8.91 mg/dL (reference 0.8-1.6 mg/dL). Abdominal ultrasound examination showed bilateral hydronephrosis, hydroureter and pyelectasia. The left kidney presented regular contour, while the right kidney was irregular and had anechoic fluid between the kidney and the renal capsule. The fluid was collected and the analysis was compatible with urinary leakage, determined by comparing the fluid creatinine of 37.09 mg/dL with the serum creatinine of 8.91 mg/dL. The cat showed polyuria, and urinary density was low (1.008 reference 1.025 – 1.060) denoting isosthenuria. Excretory urography was performed and showed bilateral renomegaly, but the nephrogram and pyelogram were not clearly observed, indicating bilateral deficiency in renal filtration. During hospitalization, the patient received fluid therapy with lactated Ringer's solution at a rate of 60 mL/kg/day, methadone (0.2 mg/kg TID SC) amitriptyline (2 mg/kg SID PO) and dipyrone (25 mg/kg BID IV).

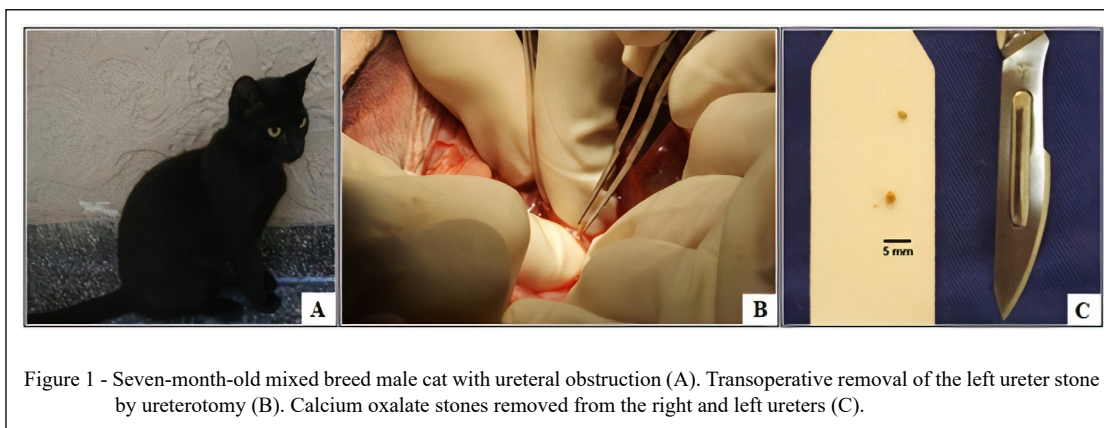
However, as there was no clinical improvement after two days of conservative

treatment (creatinine value increased to 10.14 mg/dL), the patient was referred to an exploratory laparotomy, followed by bilateral ureterotomy to remove small stones located in both ureters (Figure 1B). After the surgical procedure, the patient showed clinical improvement. Bilateral pyelectasis decreased and;consequently, bilateral hydronephrosis on imaging studies. Creatinine values normalized four days after the surgical procedure (1.3 mg/dL), and the patient was discharged home after six days of hospitalization.

The uroliths (Figure 1C) were sent to the Minnesota Urolith Center (University of Minnesota, USA) where they underwent quantitative analysis by polarized light microscopy and infrared spectroscopy techniques, which revealed the composition of both stones of 100% monohydrate calcium oxalate.

After 60 days of the hospital admission, the patient returned to the hospital for reassessment and remained without clinical signs. Abdominal ultrasonography revealed a small accumulation of subcapsular fluid in the right kidney, but there were no alterations in both renal pelvises and medullary region.

Ureterolithiasis is the main cause of ureteral obstruction in felines, and calcium oxalate is the most often stone found (ZAID et al., 2011). Conservative management include treatment with fluid therapy, continuous infusion of mannitol, amitriptyline, alpha-adrenergic blockers (prazosin) and glucagon (CLARKE, 2018a). In humans, more than 98% of small diameter ureteral stones ( $\leq 5$  mm) pass spontaneously up to the bladder, and the treatment consists mainly in treatment of pain relief (SEGURA et al., 1997). In cats, due to the small size of the ureter, which measures 0.4 mm in internal diameter, the spontaneously passage of stones is



not so frequent as in humans. A study reported that 30% of cats had a significant reduction in azotemia after conservative treatment (KYLES et al., 2005). The decision for surgical removal must be made with caution, as complications of this type of intervention are common (KOCHIN et al., 1993). The postoperative mortality rate varies between 16 and 21% (KYLES et al., 1998; KYLES et al., 2005; ROBERTS et al., 2011). In the case described, the surgical indication was given after an attempt of conservative treatment with amitriptyline, analgesics and fluid therapy. However, as the young cat had a bilateral obstruction, the time for surgical decision had to be shortened to when it was noticed that there was no clinical improvement with conservative management. In order to avoid the urolith's recurrence, the owner was advised to increase the cat's water intake, offering wet food and enhancing water resources. There is a risk of re-obstruction in about 22% of the reported cases, so the owner should be advised about the need for additional procedures and periodical monitoring (CLARKE, 2018b).

Ureteral obstruction by stones are more common in older animals. A study reported a median age of 12 years old in affected animals, with the youngest animal being 5 years old. Most obstructions in young cats are due to congenital malformation (ZAID et al., 2011). The case described is uncommon since the affected cat was only seven months old.

Although, reports of calcium oxalate urolithiasis are more frequent in adult cats, young cats can also present the disease. This type of urolith occurs when urine is oversaturated with calcium and oxalate. Aciduria is also a risk factor and genetic anomalies may be involved (BARTGES & CALLENS, 2015). When medical treatment for ureteral obstruction does not resolve the obstruction, surgical intervention is imperative for the restoration of renal function (CLARKE, 2018a).

Calcium oxalate urolithiasis must be a differential diagnosis for ureteral obstruction, even in young cats. Clinical signs such as acute abdominal pain associated with azotemia should be considered during clinical investigation. Conservative management can be tried, but if there is lack of improvement in clinical signs, ureterotomy should be performed. Veterinarians should pay attention to the incidence of this disease and occurrence in younger cats.

## ACKNOWLEDGMENTS

This study was financed in part by the Conselho Nacional de Desenvolvimento Científico e Tecnológico (CNPq)

(Grant number 131701/2018-5). And was financed in part by the Coordenação de Aperfeiçoamento de Pessoal de Nível Superior (CAPES), Brasil - Finance code 001.

## DECLARATION OF CONFLICT OF INTEREST

The authors declare no conflict of interest. The founding sponsors had no role in the design of the study; in the collection, analyses, or interpretation of data; in the writing of the manuscript, and in the decision to publish the results.

## AUTHORS' CONTRIBUTIONS

All authors contributed equally to the design, writing, and review of the manuscript.

## REFERENCES

- BARTGES, J. W.; CALLENS, A. J. Urolithiasis. *Veterinary Clinics of North America - Small Animal Practice*, 2015. v.45, n.4, p.747-768. Available from: <<https://www.sciencedirect.com/science/article/abs/pii/S0195561615000467?via%3Dihub>>. Accessed: Mar. 30, 2020. doi: 10.1016/j.cvsm.2015.03.001.
- BERENT, Allyson C. Ureteral obstructions in dogs and cats: A review of traditional and new interventional diagnostic and therapeutic options. *Journal of Veterinary Emergency and Critical Care*. 2011. Available from: <<http://doi.wiley.com/10.1111/j.1476-4431.2011.00628.x>>. Accessed: Mar. 30, 2020. doi: 10.1111/j.1476-4431.2011.00628.x.
- CLARKE, D. L. Feline ureteral obstructions Part 1: medical management. *Journal of Small Animal Practice*, 2018a. v.59, n.6, p.324-333. Available from: <<https://onlinelibrary.wiley.com/resolve/doi?DOI=10.1111/jsap.12844>>. Accessed: Mar. 31, 2020. doi: 10.1111/jsap.12844.
- CLARKE, D. L. Feline ureteral obstructions Part 2: surgical management. *The Journal of small animal practice*, jul. 2018b. v.59, n.7, p.385-397. Available from: <<http://www.ncbi.nlm.nih.gov/pubmed/29781101>>. Accessed: Sep. 24, 2019. doi: 10.1111/jsap.12861.
- HARDIE, E. M.; KYLES, Andrew E. Management of ureteral obstruction. *Veterinary Clinics of North America - Small Animal Practice*, 2004. v.34, n.4, p.989-1010. Available from: <<https://www.sciencedirect.com/science/article/abs/pii/S0195561604000361?via%3Dihub>>. Accessed: Mar. 27, 2020. doi: 10.1016/j.cvsm.2004.03.008.
- IOANNIDI, O. M. et al. Congenital unilateral ureteral stenosis with hydronephrosis in a kitten. *Topics in Companion Animal Medicine*, 1 set. 2019. v.36, p.22-24. Available from: <<http://www.ncbi.nlm.nih.gov/pubmed/31472725>>. Accessed: Mar. 31, 2020. doi: 10.1053/j.tcam.2019.06.003.
- JOHNSON, C. M. et al. Subcutaneous ureteral bypass device for treatment of iatrogenic ureteral ligation in a kitten. *Journal of the American Veterinary Medical Association*, 15 out. 2015. v.247, n.8, p.924-31. Available from: <<http://www.ncbi.nlm.nih.gov/pubmed/26421405>>. Accessed: Mar. 31, 2020. doi: 10.2460/javma.247.8.924.

- KIRK, C. A. et al. Evaluation of factors associated with development of calcium oxalate urolithiasis in cats. **Journal of the American Veterinary Medical Association**, 1 dez. 1995. v.207, n.11, p.1429–34. Available from: <<http://www.ncbi.nlm.nih.gov/pubmed/7493870>>. Accessed: Mar. 27, 2020. PMID: 7493870.
- KOCHIN, E. J. et al. Evaluation of a method of ureteroneocystostomy in cats. **Journal of the American Veterinary Medical Association**, 15 jan. 1993. v.202, n.2, p.257–60. Available from: <<http://www.ncbi.nlm.nih.gov/pubmed/8428831>>. Accessed: Sep. 20, 2019. PMID: 8428831.
- KYLES, A. E. et al. Diagnosis and surgical management of obstructive ureteral calculi in cats: 11 cases (1993–1996). **Journal of the American Veterinary Medical Association**, 15 out. 1998. v.213, n.8, p.1150–6. Available from: <<http://www.ncbi.nlm.nih.gov/pubmed/9787383>>. Accessed: Sep. 20, 2019. PMID: 9787383.
- KYLES, A. E. et al. Management and outcome of cats with ureteral calculi: 153 Cases (1984–2002). **Journal of the American Veterinary Medical Association**, 15 mar. 2005. v.226, n.6, p.937–944. Available from: <<https://avmajournals.avma.org/doi/abs/10.2460/javma.2005.226.937>>. Accessed: Mar. 30, 2020. doi: 10.2460/javma.2005.226.937.
- LEE, N. et al. Bilateral congenital ureteral strictures in a young cat. **Canadian Veterinary Journal**, 1 set. 2014. v.55, n.9, p.841–844. Available from: <<https://www.ncbi.nlm.nih.gov/pmc/articles/PMC4137923/>>. Accessed: Mar. 15, 2020. PMID: 25183890.
- MESTRINHO, L. A. et al. Xanthine urolithiasis causing bilateral ureteral obstruction in a 10-month-old cat. **Journal of Feline Medicine and Surgery**, out. 2013. v.15, n.10, p.911–916. Available from: <<https://journals.sagepub.com/doi/10.1177/1098612X13477413>>. Accessed: Mar. 31, 2020. doi: 10.1177/1098612X13477413.
- ROBERTS, S. F.; et al. Postoperative Mortality in Cats After Ureterolithotomy. **Veterinary Surgery**, 2011. v.40, n.4, p.438–443. Available from: <<https://onlinelibrary.wiley.com/doi/abs/10.1111/j.1532-950X.2011.00836.x>>. Accessed: Mar. 15, 2020. doi: 10.1111/j.1532-950X.2011.00836.x.
- SEGURA, J. W. et al. Ureteral Stones Clinical Guidelines Panel summary report on the management of ureteral calculi. The American Urological Association. **J Urol**, 1997. v.158, n.5, p.1915–1921. Available from: <<http://www.ncbi.nlm.nih.gov/pubmed/9334635>>. Accessed: Oct. 10, 2019. doi: 10.1016/S0022-5347(01)64173-9.
- WEN, J. G. et al. Obstructive nephropathy: An update of the experimental research. **Urological Research**, 1999. v.27, n.1, p.29–39. Available from: <<https://link.springer.com/article/10.1007/s002400050086>>. Accessed: Oct. 10, 2019. doi: 10.1007/s002400050086.
- ZOID, M. S. et al. Feline ureteral strictures: 10 cases (2007–2009). **Journal of Veterinary Internal Medicine**, [s.d.]. 2011, v.25, n.2, p.222–9. Available from: <<http://www.ncbi.nlm.nih.gov/pubmed/21314722>>. Accessed: Sept. 24, 2019. doi: 10.1111/j.1939-1676.2011.0679.x.