

Urinary incontinence secondary to a suspected congenital urethral deformity in a kitten

Perrine Henry , Luca Schiavo, Laura Owen and Katie E McCallum

Journal of Feline Medicine and Surgery Open Reports
1–6

© The Author(s) 2021

Article reuse guidelines:

sagepub.com/journals-permissions

DOI: 10.1177/20551169211045642

journals.sagepub.com/home/jfmsopenreports

This paper was handled and processed by the European Editorial Office (ISFM) for publication in *JFMS Open Reports*



Abstract

Case summary A 5-month-old entire male domestic shorthair kitten was referred for investigation of a month-long history of urinary incontinence. Clinical examination, baseline blood work and imaging (plain radiography and ultrasonography) were unremarkable. Urinalysis documented a urinary tract infection and a retrograde urethrocystogram revealed an outpouching of the pelvic urethra. Surgical exploration revealed the absence of the dorsal portion of the urethral wall in this section of pelvic urethra, replaced by an epithelial lined expanded ‘pouch’. The ventral aspect of the urethra appeared grossly normal. A modified perineal urethrostomy was performed to create an anastomosis of the urethral pouch to the skin of the perineum alongside conventional castration. The kitten made a full recovery and the incontinence resolved within 48 h. A congenital urethral diverticulum and secondary urinary tract infection were deemed the most likely aetiology in this case.

Relevance and novel information Urethral diverticuli are a rare condition in veterinary medicine. To our knowledge, it has only been reported in two dogs and presumptively in one cat, all of which made a complete recovery after surgical intervention. The present case reports an unusual urethral deformity as a potential differential diagnosis for lower urinary tract signs in a young cat.

Keywords: Urinary incontinence; FLUTD; urethral deformity; diverticulum

Accepted: 24 August 2021

Introduction

Congenital deformities of the urethra are uncommon in dogs and cats. They include agenesis,¹ hypoplasia,² duplication,^{3–7} hypospadias,⁸ urethrorectal⁷ or urethrovaginal⁹ fistulas and urethral diverticula.^{10–12} Diverticula are particularly rare in veterinary literature and have, to our knowledge, only been reported in two dogs and in one cat.^{10–12} All presented with non-specific lower urinary tract signs such as urinary incontinence, recurrent urinary tract infection (UTI), dysuria, stranguria and occasional urethral obstruction. The present case documents urinary incontinence secondary to a suspected congenital urethral diverticulum and its successful surgical management.

Case description

A 5-month-old entire male domestic shorthair kitten was referred for investigation of a month-long history of

stranguria, pollakiuria and urinary incontinence. The patient had been presented to the referring veterinarian a month earlier to investigate stranguria and pollakiuria. At the time, the kitten had been in its owner’s possession for 2 months. Clinical examination was unremarkable apart from a large, firm bladder that proved impossible to express, consistent with urethral obstruction. Blood work and abdominal radiographs performed at the time were unremarkable. Urethral catheterisation was easily

Department of Veterinary Medicine, Queen’s Veterinary School Hospital, Cambridge, UK

Corresponding author:

Perrine Henry DVM, MRCVS, Department of Veterinary Medicine, Queen’s Veterinary School Hospital, Madingley Road, Cambridge CB3 0ES, UK

Email: dr.vet.perrine.henry@gmail.com



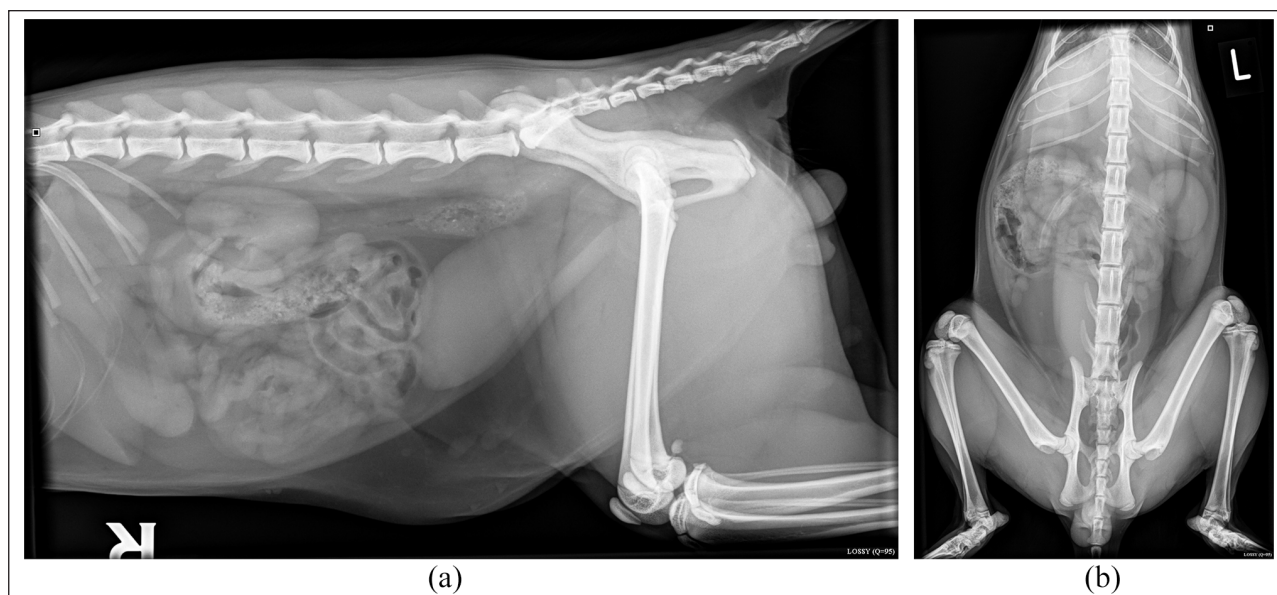


Figure 1 (a) Right lateral abdomen; and (b) ventrodorsal abdomen. Overall, the abdominal radiographs were unremarkable. Note the normal position of the bladder in the abdomen: full, with a smooth, rounded border

achieved, without evidence of a plug, sediment or urolith. Penile conformation and the urethral opening were reported to be normal. In-house examination of the urine sediment revealed bacteriuria. The kitten was discharged with a 7-day course of non-steroidal anti-inflammatory drugs (meloxicam [Loxicom; Norbrook] 0.05 mg/kg PO q24h), urethral smooth muscle relaxant (prazosin [Hypovase; Pfizer] 0.5 mg PO q12h) and antibiotics (potentiated amoxicillin/clavulanate [Synulox; Pfizer] 20 mg/kg PO q12h) pending urine culture, which was subsequently negative. Treatment was successful at preventing further obstructive episodes, but the patient had persistent stranguria, pollakiuria and urinary incontinence, as well as observed excessive grooming of the perineal area. The kitten had no significant previous medical history.

On referral, and since the initial obstructive episode, the kitten was reported to be well but constantly leaking drops of urine when roaming or leaving larger puddles while sleeping. Pollakiuria and stranguria were still reported. Clinical examination was unremarkable; in particular, abdominal palpation was comfortable, with a small soft bladder. Haematology was unremarkable and biochemistry only revealed a moderate increase in creatine kinase (794 IU/l [reference interval {RI} 33–168]); borderline high urea (10.9 mmol/l [RI 5.4–10.7]), possibly reflecting mild dehydration; and concurrent elevations in phosphate (2.56 mmol/l [RI 0.9–2.1]) and alkaline phosphatase (135 IU/l [RI 10–93]), which were deemed to be age related. The kitten was sedated for imaging with medetomidine (0.005 mg/kg IV [Sedator; Dechra]) and butorphanol (0.2 mg/kg IV [Torbugesic; Zoetis]). Abdominal

radiographs revealed a normally positioned, full bladder, with a smooth, rounded border (Figure 1). On abdominal ultrasound, although under-filled, the bladder wall appeared thickened, measuring 0.37 cm, with a hyperechoic mucosal layer and slightly irregular luminal border. No other abnormalities were noted. Cystocentesis was performed and urinalysis revealed inadequately concentrated (specific gravity 1.010) urine, bacteriuria and proteinuria, suggestive of a UTI. Culture and sensitivity revealed sparse pure growth of *Escherichia coli*, which was resistant to cephalexin. The kitten's inadequately concentrated urine was considered to reflect transient renal dysfunction. Secondary nephrogenic diabetes insipidus due to *E coli* pyelonephritis was also considered plausible, although there were no ultrasonographic features to support this. UTI was deemed unlikely to be the sole cause of the clinical signs and further imaging was performed.

The kitten was anaesthetised for a retrograde urethrocytogram. Methadone (0.2 mg/kg IV [Comfortan; Dechra]) and medetomidine (0.005 mg/kg IV) were administered as premedication; alfaxalone (3 mg/kg IV [Alfaxan; Dechra]) was given to effect for induction. Intubation was achieved using a size 4 mm cuffed endotracheal tube and the kitten was maintained on 2% isoflurane in oxygen (21/min). The images acquired revealed an outpouching of the intrapelvic urethra (Figure 2). A diagnosis of UTI secondary to a suspected urethral diverticulum was made. The kitten was discharged on potentiated amoxicillin–clavulanate (20 mg/kg PO q12h [Synulox; Pfizer]) pending surgical planning. A month later, surgical exploration of the perineal area was performed. In order to excise the redundant 'pouch',

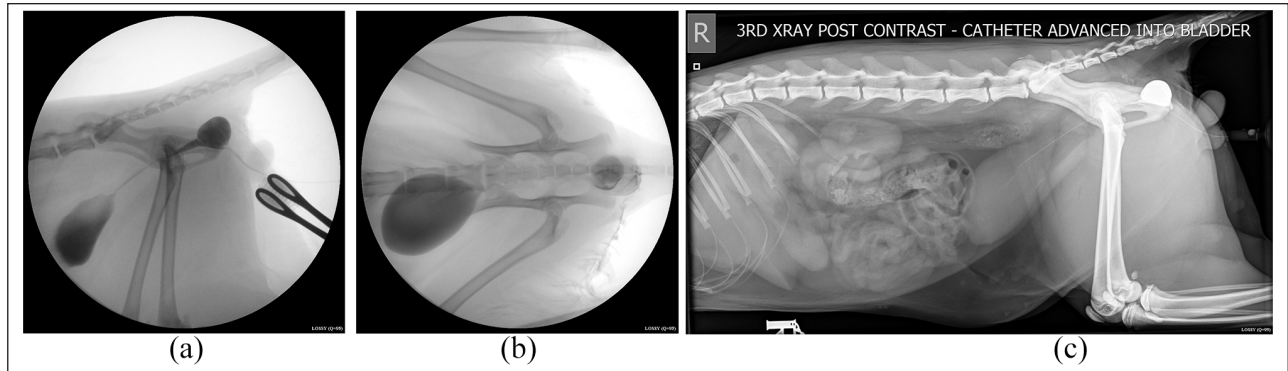


Figure 2 Positive contrast retrograde urethrocytogram. Right lateral and ventrodorsal views. (a,b) The bladder and urethra are filled with contrast material. (c) Only the distal urethra is filled. On all views, the contrast material highlights a rounded, well-defined structure branching dorsally to the urethra. This structure fills with contrast homogenously, and is connected to the intra-pelvic urethra, which is dilated cranially and then narrows to a normal diameter caudally

dissection around the abnormal area of the urethra was attempted; however, associations with the bulbourethral glands and other tissues rendered this approach challenging. The ‘pouch’ was incised to further investigate its anatomy. Inside the ‘pouch’ the true urethra could be seen along the ventral floor with normal mucosal lining, but the dorsal section of the urethra was absent, replaced instead with an epithelial lined diverticulum. Based on these findings, a modified perineal urethrostomy was performed alongside castration to anastomose the diverticulum to the perineal skin. The patient was hospitalised for 48 h for analgesia (buprenorphine [Buprecare; Animalcare] 0.02 mg/kg IV q6h and meloxicam 0.05 mg/kg PO q24h) and monitoring of urination, where appropriate use of the litter tray and absence of incontinence was observed. The kitten was discharged with a 5-day course of meloxicam (0.05 mg/kg PO q24h).

On re-examination 14 days postoperatively, the stoma site had healed well, sutures were removed and repeat cystocentesis was performed, returning a negative culture. Repeat urinalysis documented a specific gravity of 1.025, which can be indicative of normal urine concentrating ability in a cat fed a wet diet.¹³ Unfortunately, owing to financial constraints, follow-up biochemistry was not performed to document whether the azotaemia resolved – a limitation of this case report. The owners reported no further urinary incontinence or other lower urinary tract signs.

Telephone follow-up was performed 3 months postoperatively. Owing to financial constraints, repeat imaging and urinalysis were declined, but the owner reported the cat to be clinically well at this time, with no abnormal urinary tract signs observed and no stoma complications.

Discussion

Diverticula are epithelium-lined saccular dilations emerging from the lumen of a hollow organ, either presenting as a distended segment, or as a structure attached by a narrow

neck. There are sporadic single case reports of diverticula arising from various locations of the urinary tract, including the bladder body,¹⁴ sometimes associated with the incomplete closure of the urachus,¹⁵ the bladder fundus^{16,17} and neck,¹⁷ or even with the renal pelvis.¹⁸ To our knowledge, only three cases of urethral diverticula have been reported in the veterinary literature. The first two were dogs, both adult neutered males (2 and 7 years old, respectively), which presented with perineal swelling and lower urinary tract signs.^{11,12} The first had a lifelong history of dribbling urine and recurrent UTI; the second had a month-long history of stranguria and previous cystotomy for removal of uroliths. In both cases, surgical resection of most of the diverticula led to resolution of the dysuria. The third case was a 3-month-old male kitten with dysuria, stranguria and episodic urethral obstruction with urinary incontinence.¹⁰ Contrast radiographs revealed a dilated intrapelvic urethra branching into a normal penile urethra and a narrowed neck tract associated with a diverticulum in the scrotum and concurrent testicular fistula. The kitten underwent perineal urethrostomy and recovered uneventfully. No histopathology was performed, and the diagnosis of congenital urethral diverticulum was made on the assumption that the fistula was acquired secondary to the pooling of urine and subsequent backpressure.

Possible differential diagnoses in our kitten included persistent uterus masculinus or vestigial vagina.^{9,19} Both were deemed unlikely owing to the otherwise completely normal external genitalia. In the absence of histopathology, and considering all of the presenting and diagnostic findings, a congenital urethral diverticulum was thought to be the most likely diagnosis. Urethral diverticula are either congenital or acquired. They are uncommon in male humans and can be asymptomatic unless obstructive or associated with a UTI.²⁰ Congenital diverticula are classified into two types: saccular or diffuse. The saccular type presents as a pocket-like structure connected to the urethra by a narrow or wide

orifice. Diffuse diverticula, also called megalourethra or urethral ectasia, are characterised by a gradual increase in the width of the urethra. Megalourethra are generally not associated with obstruction of the urinary flow, whereas saccular diverticula are.²¹ Acquired causes include long-term indwelling catheterisation, trauma, strictures, surgical repair (hypospadias, stricture), urolithiasis and periurethral abscesses.¹⁰

In the present case, the spherical shape of the anomaly, associated with signs of urinary flow obstruction and large communicating neck were evocative of a congenital, wide mouth, saccular diverticulum. Unfortunately, the nature of the lesion was not confirmed histologically because the diverticulum was used to construct the perineal urethrostomy. Histology may have helped to differentiate a congenital from an acquired lesion. Congenital histopathology is consistent with an epithelial urethral mucosal layer and striated muscle layer (full-thickness urethral wall), whereas acquired diverticula are lined by epithelium and granulation tissue with absent muscle fibres.^{10,11} An acquired iatrogenic origin was debated, secondary to potential trauma during urethral catheterisation.

Although common as a procedure, urethral catheterisation is not without risks and can result in severe complications (UTI, hyperaemia and swelling of the penis/scrotum, urethral stricture, rupture).²² Formation of a diverticulum as a consequence of catheterisation has never been reported; however, urethral intussusception has been reported as a consequence in one cat, resulting in focal ampullar enlargement of the urethra on contrast radiographs.²³ In the present case, the role of the catheterisation in the disease process will remain unknown. Nevertheless, if contributing, it was believed to be an aggravating factor rather than an initiating one owing to both the smooth and homogenous lining of the diverticulum on gross examination supportive of a congenital origin and the disease process timeline.^{10,24}

Indeed, on initial presentation, the kitten displayed signs of feline lower urinary tract disease (FLUTD). FLUTD is a common disease that can present as haematuria, stranguria, pollakiuria, periuria or even urethral obstruction. It can result from numerous disorders of the urinary tract, including feline idiopathic cystitis (FIC), uroliths, UTI or neoplasia.²⁵ FIC has been diagnosed as the most common cause of FLUTD in cats aged <10 years.²⁶ The most common age to develop signs is between 1 and 6 years, with as little as 6.3% of affected cats having their first episode before 1 year of age.²⁷ Radiographs and urinalysis performed at the referring veterinarian failed to reveal any signs of uroliths or crystalluria but revealed bacteriuria, despite a negative culture. While UTI has been shown as an important cause of FLUTD in cats older than 10 years, it is uncommon in younger individuals. Studies have shown that the

prevalence of cats suffering from FLUTD presenting with a UTI ranges from 2% to 19%.²⁸ Finally, the epidemiology of FLUTD has been described in various studies and identified low activity, indoor lifestyle, diet, excessive body weight, male sex and being neutered as possible risk factors.^{29–32} In the present case, the cat was a strictly indoor male but very playful, single animal of the household, with an appropriate body condition score and was only 4 months old on initial presentation. Therefore, the stranguria and pollakiuria observed were unlikely to be attributed to FLUTD and it was hypothesised that the pseudo-obstructive episode was a result of ongoing UTI, secondary to stagnation of urine in the diverticulum.

An alternative explanation would be for the diverticulum to fill with urine during voiding of the bladder causing the distal wall, common to both the urethra and the outpouching, to collapse and act as a flap valve. This would result in a temporary occlusion of the urethral lumen and pollakiuria or stranguria. Subsequent dribbling would occur as a result of slow emptying of the diverticulum by movement or gravity.²¹ Acknowledging the epidemiology of FLUTD and prevalence of UTI in feline patients, in a young cat presenting with lower urinary tract disease with normal ancillary imaging, a thorough screening for potential predisposing causes should be performed, including contrast-enhanced urography.

Congenital urethral abnormalities are rare but possibly under-reported.¹⁰ Visualisation and assessment of the urethra in male cats requires the use of contrast-enhanced imaging. Although relatively simple as a procedure, positive contrast retrograde urethrography is not routinely performed unless prompted by a history of pelvic trauma, suspected urethral anomaly (stricture, tear), an unusual clinical history or once all other causes of abnormal urination have been ruled out.³³ In the present case contrast radiography was indicated owing to the clinical sign of urinary incontinence. In previous veterinary cases, both retrograde positive contrast cystourethrogram and excretory urogram were successful in identifying urethral diverticula.^{10,11} However, these techniques lack sensitivity and do not outline the relationship between the deformity and adjacent structures. Further investigation using positive contrast tomography and urethral endoscopy (in dogs and female cats only) can provide valuable insights into the anatomy of complex urinary tract lesions and may help with both surgical planning and prognosis.^{12,14}

In human medicine, when asymptomatic, urethral diverticula are treated conservatively with prophylactic antibiotics. However, serious complications can arise, including rupture, urinary stasis or partial urinary obstruction, promoting UTIs, stone formation, fistulation and even malignant transformation of the diverticulum.^{34–36} Some of these have equally been referenced in veterinary literature, in particular fistulation¹⁰ and UTI.¹¹ In those cases, surgery

is warranted. The goal of the surgery is to remove the diverticulum while preserving patency of the urethra and limiting postoperative complications. Numerous surgical techniques have been described, including minimally invasive techniques, urethroplasties or urinary diversion depending on the anatomy of the lesion.^{34,35}

In the three veterinary cases reported in the literature and in the present one, clinical signs resolved following surgical management. The methods described in dogs were either partial resection of the diverticulum with use of the remaining tissue for urethral reconstruction or suture ligation of the narrow neck of the diverticulum under endoscopic guidance without excision of the excessive tissues.^{11,12} In cats, only perineal urethrostomy has been reported.¹⁰ In our case, an initial attempt at resection of the diverticulum was aborted in favour of a modified perineal urethrostomy considering the challenging anatomy of the region, avoiding disruption of the dorsal nerve supply and anticipating a reduced likelihood of postoperative complications. In all cases, the surgical method elected was successful in resolving the clinical signs and no recurrence or complications were observed.

Short- and long-term complications of perineal urethrostomy are common, reported, respectively, in 13–25% and 20–42% of patients.³⁷ They include – among others – sterile cystitis, UTI, urinary incontinence and stricture.³⁸ The latter is one of the most severe and may require revision surgery. It is reported in up to 11% of patients undergoing perineal urethrostomy within the first 4 weeks,³⁹ with revision surgery being performed at a median of 71 days post-initial intervention.⁴⁰ In the present case, follow-up was obtained after 3 months. Despite no further investigations being conducted, the clinical signs associated with these complications (stranguria, dribbling urine, obstruction, licking at the stoma) are easily appreciated by owners, and none were reported.

Conclusions

This case represents an unusual differential for lower urinary tract signs and urinary incontinence in young cats. Retrograde urethrocytography allowed the diagnosis of a urethral deformity manifesting as an outpouching of the intrapelvic urethra and suspected to be a congenital diverticulum. Perineal urethrostomy was performed and resulted in a complete resolution of the clinical signs.

Conflict of interest The authors declared no potential conflicts of interest with respect to the research, authorship, and/or publication of this article.

Funding The authors received no financial support for the research, authorship, and/or publication of this article.

Ethical approval This work involved the use of non-experimental animals only (including owned or unowned animals and data from prospective or retrospective studies).

Established internationally recognized high standards ('best practice') of individual veterinary clinical patient care were followed. Ethical approval from a committee was therefore not specifically required for publication in *JFMS Open Reports*.

Informed consent Informed consent (either verbal or written) was obtained from the owner or legal custodian of all animal(s) described in this work (either experimental or non-experimental animals) for the procedure(s) undertaken (either prospective or retrospective studies). No animals or humans are identifiable within this publication, and therefore additional informed consent for publication was not required.

ORCID iD Perrine Henry  <https://orcid.org/0000-0003-1630-9080>

References

- Kruger JM, Osborne CA, Lulich JP, et al. **Inherited and congenital diseases of the feline lower urinary tract.** *Vet Clin North Am Small Anim Pract* 1996; 26: 265–279.
- Baines SJ, Speakman AJ, Williams JM, et al. **Genitourinary dysplasia in a cat.** *J Small Anim Pract* 1999; 40: 286–290.
- Sprocatti M, Reese D and Charlesworth T. **Surgical treatment and outcome of complete unilateral urinary tract duplication in a dog.** *Vet Surg* 2020; 49: 1641–1647.
- Palm CA, Glaiberman CB and Culp WT. **Treatment of a urethral duplication in a dog using cyanoacrylate and coil embolization.** *J Vet Intern Med* 2015; 29: 727–731.
- Duffey MH, Barnhart MD, Barthez PY, et al. **Incomplete urethral duplication with cyst formation in a dog.** *J Am Vet Med Assoc* 1998; 213: 1279.
- Thierry F, Drew S, Del-Pozo J, et al. **Incomplete urethral duplication associated with a dermoid cyst in a dog with urinary obstruction.** *J Comp Pathol* 2017; 156: 29–32.
- Tobias KS and Barbee D. **Abnormal micturition and recurrent cystitis associated with multiple congenital anomalies of the urinary tract in a dog.** *J Am Vet Med Assoc* 1995; 207: 191–193.
- Switonski M, Dzimira S, Aleksiewicz R, et al. **Hypospadias is not rare in dogs: five new cases, a retrospective study, and a review of the literature.** *Sex Dev* 2018; 12: 244–250.
- Yoon H, Han SH, Kim J, et al. **Urogenital anomalies and urinary incontinence in an English Cocker Spaniel dog with XX sex reversal.** *J Vet Intern Med* 2018; 32: 1166–1171.
- Foster SF, Hunt GB and Malik R. **Congenital urethral anomaly in a kitten.** *J Feline Med Surg* 1999; 1: 61–64.
- Atilla A. **Suspected congenital urethral diverticulum in a dog.** *Can Vet J* 2018; 59: 243–248.
- Watanabe T, Mochizuki S and Mishina M. **Urethral diverticulum in a dog.** *J Jpn Vet Med Assoc* 2015; 68: 124–127.
- Chew DJ, DiBartola SP and Schenck PA. *Canine and feline nephrology and urology.* 2nd ed. St Louis, MO: Elsevier/Saunders, 2011.
- Anson A, Strohmayer C, Larrinaga JM, et al. **Computed tomographic retrograde positive contrast cystography and computed tomographic excretory urography characterization of a urinary bladder diverticulum in a dog.** *Vet Radiol Ultrasound* 2019; 60: E66–E70.

- 15 Perondi F, Puccinelli C, Lippi I, et al. **Ultrasonographic diagnosis of urachal anomalies in cats and dogs: retrospective study of 98 cases (2009–2019).** *Vet Sci* 2020; 7: 84. DOI: 10.3390/vetsci7030084.
- 16 Kirk RW, McEntee K and Bentinck-Smith J. **Diseases of the urogenital system.** In: Catcott F (ed). *Canine medicine*. Santa Barbara, CA: American Veterinary Publications, 1968, p 400.
- 17 Goulden BE, Jolley RD and Wyburn RS. **Urinary incontinence associated with a diverticulum of the bladder neck in a dog.** *N Z Vet J* 1969; 17: 33–36.
- 18 Tsujimoto S, Okuda K, Okuda H, et al. **Perirenal pyelocaliceal diverticulum in an infant cat.** *J Vet Med Sci* 2005; 67: 329–331.
- 19 Sfiligoi G, Drobatz KJ and Saunders MH. **Uterus masculinus: an unusual complication in a case of feline urethral obstruction.** *J Vet Emerg Crit Care* 2006; 16: 50–53.
- 20 Goyal M, Sharma R, Gupta DK, et al. **Congenital anterior urethral diverticulum: sonographic diagnosis.** *J Clin Ultrasound* 1996; 24: 543–544.
- 21 Dorairajan T. **Defects of spongy tissue and congenital diverticula of the penile urethra.** *ANZ J Surg* 1963; 32: 209–214.
- 22 Corgozinho KB, de Souza HJ, Pereira AN, et al. **Catheter-induced urethral trauma in cats with urethral obstruction.** *J Feline Med Surg* 2007; 9: 481–486.
- 23 Broux O, Etienne AL and Hamaide A. **Urethral intussusception following traumatic catheterization in a male cat.** *Can Vet J* 2018; 59: 385–387.
- 24 Cinman NM, McAninch JW, Glass AS, et al. **Acquired male urethral diverticula: presentation, diagnosis and management.** *J Urol* 2012; 188: 1204–1208.
- 25 Kaul E, Hartmann K, Reese S, et al. **Recurrence rate and long-term course of cats with feline lower urinary tract disease.** *J Feline Med Surg* 2020; 22: 544–556.
- 26 Bartges JW and Kirk CA. **Nutrition and lower urinary tract disease in cats.** *Vet Clin North Am Small Anim Pract* 2006; 36: 1361–1376.
- 27 Defauw PA, Van de Maele I, Duchateau L, et al. **Risk factors and clinical presentation of cats with feline idiopathic cystitis.** *J Feline Med Surg* 2011; 13: 967–975.
- 28 Dorsch R, Teichmann-Knorrn S and Sjetne Lund H. **Urinary tract infection and subclinical bacteriuria in cats: a clinical update.** *J Feline Med Surg* 2019; 21: 1023–1038.
- 29 Piyaungsri K, Tangtrongsup S, Thitaram N, et al. **Prevalence and risk factors of feline lower urinary tract disease in Chiang Mai, Thailand.** *Sci Rep* 2020; 10: 196. DOI: 10.1038/s41598-019-56968-w.
- 30 Lekcharoensuk C, Osborne CA and Lulich JP. **Epidemiologic study of risk factors for lower urinary tract diseases in cats.** *J Am Vet Med Assoc* 2001; 218: 1429–1435.
- 31 Sævik BK, Trangerud C, Ottesen N, et al. **Causes of lower urinary tract disease in Norwegian cats.** *J Feline Med Surg* 2011; 13: 410–417.
- 32 Defauw PAM, Van de Maele I, Duchateau L, et al. **Risk factors and clinical presentation of cats with feline idiopathic cystitis.** *J Feline Med Surg* 2011; 13: 967–975.
- 33 Ticer JW, Spencer CP and Ackerman N. **Positive contrast retrograde urethrography: a useful procedure for evaluating urethral disorders in dogs.** *Vet Radiol* 1980; 21: 2–11.
- 34 Greiman AK, Rolef J and Rovner ES. **Urethral diverticulum: a systematic review.** *Arab J Urol* 2019; 17: 49–57.
- 35 Thakur N, Sabale VP, Mane D, et al. **Male urethral diverticulum uncommon entity: our experience.** *Urol Ann* 2016; 8: 478–482.
- 36 O'Connor E, Iatropoulou D, Hashimoto S, et al. **Urethral diverticulum carcinoma in females – a case series and review of the English and Japanese literature.** *Transl Androl Urol* 2018; 7: 703–729.
- 37 Ruda L and Heiene R. **Short- and long-term outcome after perineal urethrostomy in 86 cats with feline lower urinary tract disease.** *J Small Anim Pract* 2012; 53: 693–698.
- 38 Seneviratne M, Stamenova P and Lee K. **Comparison of surgical indications and short- and long-term complications in 56 cats undergoing perineal, transpelvic or prepubic urethrostomy.** *J Feline Med Surg* 2021; 23: 477–486.
- 39 Bass M, Howard J, Gerber B, et al. **Retrospective study of indications for and outcome of perineal urethrostomy in cats.** *J Small Anim Pract* 2005; 46: 227–231.
- 40 Phillips H and Holt DE. **Surgical revision of the urethral stoma following perineal urethrostomy in 11 cats: (1998–2004).** *J Am Anim Hosp Assoc* 2006; 42: 218–222.