

Clinician's guide to genes associated with Rett-like phenotypes – Investigation of a Danish cohort and review of the literature

Bitten Schönewolf-Greulich^{1,2}, Anne-Marie Bisgaard¹, Rikke S Møller^{3,4}, Morten Dunø⁵, Karen Brøndum-Nielsen⁵, Simran Kaur⁶, Nicole J Van Bergen⁶, Sebastian Lunke⁷, Stefanie Eggers⁷, Cathrine Jespersgaard², John Christodoulou^{6*}, Zeynep Tümer^{2*}

1. Center for Rett Syndrome, Kennedy Center, Department of Paediatrics, Copenhagen University Hospital, Rigshospitalet, Glostrup, Denmark
2. Applied Human Molecular Genetics, Kennedy Center, Department of Clinical Genetics, Copenhagen University Hospital, Rigshospitalet, Glostrup, Denmark
3. Danish Epilepsy Centre, Dianalund, Denmark
4. Institute for Regional Health Services, University of Southern Denmark, Odense, Denmark
5. Department of Clinical Genetics, Copenhagen University Hospital, Rigshospitalet, Copenhagen, Denmark
6. Neurodevelopmental Genomics Research Group, Murdoch Children's Research Institute, Melbourne and Department of Paediatrics, Melbourne Medical School, University of Melbourne, Melbourne, Australia.
7. Translational Genomics Unit, Murdoch Childrens Research Institute, Parkville, VIC, Australia

* Co-last authors

The authors declare no conflict of interests.

Correspondence to:

Bitten Schönewolf-Greulich
Center for Rett Syndrome
Kennedy Center
Rigshospitalet
Gl. Landevej 7
2600 Glostrup
Copenhagen, Denmark
Tel.: (+45) 43260150
E-mail: bitten.schoenewolf-greulich.01@regionh.dk

Keywords:

This is the author manuscript accepted for publication and has undergone full peer review but has not been through the copyediting, typesetting, pagination and proofreading process, which may lead to differences between this version and the Version of Record. Please cite this article as doi: [10.1111/cge.13153](https://doi.org/10.1111/cge.13153)

Rett-like, atypical Rett, RTT, *MECP2*, *CDKL5*, *FOXP1*, *KCNB1*, *SMC1A*

Author Manuscript

Abstract

The differential diagnostics in Rett syndrome has evolved with the development of next generation sequencing based techniques and many patients have been diagnosed with other syndromes or variants in newly described genes where the associated phenotype(s) is yet to be fully explored. The term Rett-like refers to phenotypes with distinct overlapping features of Rett syndrome where the clinical criteria are not completely fulfilled. In this paper we have combined a review of Rett-like disorders with data from a Danish cohort of 35 patients with Rett-like phenotypes emphasizing the diagnostic overlap with Pitt-Hopkins syndrome, Cornelia de Lange syndrome with *SMC1A* variants, and epileptic encephalopathies for example due to *STXBP1* variants. We also found a patient with a pathogenic variant in *KCNB1*, which has not previously been linked to a Rett-like phenotype. This study underlines the clinical and genetic heterogeneity of a Rett syndrome spectrum, and provides an overview of the Rett syndrome-related genes described to date, and hence serves as a guide for diagnosing patients with Rett-like phenotypes.

The neurodevelopmental disorder Rett syndrome (RTT) was first described in 1966 by Dr. Andreas Rett, who reported 22 girls with loss of speech and hand use, and who developed hand stereotypies¹. Apart from the classical/typical form (RTT) there are atypical forms of RTT (atypical RTT) with different clinical subgroups such as “preserved speech variant”², the “early seizure variant”^{3,4} and the “congenital variant”⁵. Today, the term Rett-like is used when there is an overlapping phenotype with typical or atypical RTT, but in whom the clinical criteria are not fulfilled. There are to date no formal published consensus criteria for a Rett-like diagnosis, and thus this description can be given to any patient with different combinations of the distinct features of RTT.

The genetic causes of typical RTT, atypical RTT and Rett-like disorders have been intensely studied. Typical RTT patients almost exclusively have pathogenic *MECP2* variants⁶, while atypical RTT and Rett-like patients show genetic heterogeneity. The most common genes involved apart from *MECP2* are: *CDKL5*, in which variants cause the early onset seizure disorder⁷ and *FOXP1*, which is responsible for the congenital RTT variant⁸. Several additional new genes have been suggested to be associated with atypical RTT and a Rett-like disorder⁹⁻¹². These studies have also revealed previously unrecognized clinical similarities of Rett spectrum phenotypes with other neurodevelopmental disorders. One of the unexpected findings has been the identification of *SMC1A* variants, which are traditionally linked to Cornelia de Lange syndrome, in Rett-like patients¹³. Furthermore, several Rett-like patients have pathogenic variants in epileptic encephalopathy genes¹⁴. From a clinical perspective these findings enable an improved comprehension of the genetic landscape of atypical RTT and Rett-like disorders, potentially transforming the primary clinical diagnosis to a genetic one. From a research perspective, the genetic landscape is yet to completely unfold, and some of the genes associated with these phenotypes may be linked through similar functional pathways.

In this study, we present a genetic review of a Rett-like spectrum (typical RTT, atypical RTT, Rett-like disorder) and our findings in a Danish Rett-like cohort, including association of the

epilepsy gene, *KCNB1*, as a new Rett-like gene. The purpose of this review is to provide a guide for molecular diagnosis of patients with Rett-like phenotypes.

RETT SYNDROME

RTT is mainly seen in females and presents with only a few neurodevelopmental symptoms before the age of 6-18 months¹⁵. A period of regression will then occur, and abilities especially related to hand function and speech can deteriorate or be lost altogether¹⁶. Hand stereotypies are a main feature and the patients often have severely impaired functional use of their hands¹⁷. Another distinct clinical feature often present which can help point to the diagnosis is the breathing abnormalities (including hyperventilation and/or breath holding episodes)¹⁸. Patients all have intellectual disability (ID). Other features that often develop over time include progressive microcephaly¹⁹, and epilepsy (occurring in approximately 68% at a mean age of 4.7 years)^{20, 21}. Scoliosis is also very common¹⁶. Facial dysmorphism is not distinct, but few have subtle dysmorphic facial features which do not enable a clinical diagnosis²².

Today the international diagnostic criteria published in 2010²³ are used to assist in establishing the clinical diagnosis of RTT (listed in Table 1). RTT patients should have four main criteria (partial or complete loss of purposeful hand movements, partial or complete loss of spoken language, a gait abnormality, and stereotypic hand movements); while a diagnosis of atypical RTT is suggested if the patient has two or more of the main in addition to five or more of the supportive criteria²³. Both forms are characterized by a period of developmental regression followed by recovery or stabilization. In addition, the presence of any of the following features exclude a diagnosis of typical or classic RTT: a brain injury, a neurometabolic disease or neurological infection, and abnormal psychomotor development with an onset before the age of 6 months²³.

“Insert table 1 about here”

THE RETT SYNDROME GENES

MECP2, encoding methyl CpG binding protein 2, is the major gene related to RTT and there are over 4600 *MECP2* variants (pathogenic, benign, or with unknown significance) described in the

literature²⁴. *MECP2* variants mainly cause RTT (including classical/typical and variant/atypical RTT), but may rarely also be associated with non-syndromic neurodevelopmental disorders including autism²⁵.

Variants in *CDKL5* (Cyclin-dependent kinase-like 5) have been reported in about 500 patients²⁴ and the most notable clinical feature of patients with pathogenic mutations of this gene is early onset epilepsy. These patients have ID and progressive microcephaly²⁶. Stereotypic hand movements, respiratory impairment with breath holding and hyperventilation, and severely impaired speech, hand function and gait may also be observed^{27 28}. These features are suggestive of RTT, but normal development during the first 6 months is rare in these patients and they often have facial dysmorphic features^{29 30}. Traditionally, the term Hanefeld or early onset epilepsy variant of RTT^{4, 26} has been used for this diagnosis, but recently the term *CDKL5* disorder has been introduced and is considered a separate clinical disorder from RTT³¹.

FOXP1 variants are less common (approximately 80 cases in total²⁹) and neurodevelopmental impairment is already observable in early infancy. As *FOXP1* is located on chromosome 14, variants affect males as well as females.

This condition has therefore been called the congenital variant of RTT⁸, and recently the term *FOXP1* syndrome has been introduced²⁹. These patients exhibit profound motor dysfunction, and stereotypic hand movements and abnormal breathing can be present³². There is rarely any speech development and eye contact is poor^{32, 33}. Epilepsy is common although the age of onset can vary substantially³⁴. They have progressive microcephaly^{33, 35} and MRI of the brain reveals poor myelination and/or corpus callosum hypoplasia or agenesis³².

MANY GENES, MANY DISORDERS

Apart from these three genes, there are at least 28 OMIM morbid genes (<https://www.omim.org/>) described in literature in which variants may cause gene disorders/syndromes with overlapping Rett-like phenotypes (Table 2)^{9, 10, 14, 36-38}. Some of these genes are associated with well-known syndromes such as Pitt-Hopkins syndrome (*TCF4*, *CNTNAP2*, *NRXN1*), Cornelia de Lange syndrome (*SMC1A*), Phelan-McDermid syndrome (*SHANK3*), Kleefstra syndrome (*EHMT1*), Christianson type X-linked mental retardation syndrome (*SLC9A6*), Angelman syndrome (*UBE3A*),

and Glass syndrome (*SATB2*). In addition, a substantial number of genes are epileptic encephalopathy genes (*STXBPI*, *SCN1A*, *SCN2A*, *SCN8A*, *GRIN2A*, *GRIN2B*, *HCN1*, *SLC6A1*, *KCNA2*, *EEF1A2* and *KCNB1*).

“Insert table 2 about here”

DANISH COHORT OF RTT, ATYPICAL RTT AND RETT-LIKE PHENOTYPES

In Denmark, patients with clinical features suggestive of RTT are referred to the National Danish Centre for Rett syndrome and currently, we have registered 146 living patients. All these patients were initially investigated for the three known RTT genes and the sequence variant distribution is: *MECP2* – 99 cases, *CDKL5* – 10 cases, and *FOXG1* – 2 cases.

Among the patients, without deficiencies in one of these three genes (n=35), pathogenic sequence variants were identified in *SCN2A* (n=1), *STXBPI* (n=2) and *TCF4* (n=1); all genes previously linked to Rett-like phenotype (Table 2), using different technologies including single gene or whole exome sequencing, and a previously described epilepsy gene panel³⁹. Notably, in one patient we identified a *de novo* variant in *KCNB1*, which was not previously linked to Rett syndrome spectrum. Patient 2 (*STXBPI*) and patient 3 (*SCN2A*) have previously been published^{40, 41} (Table 1).

Remaining patients were investigated using an in-house gene panel which included the genes described in Table 2. Through this approach we identified two patients with variants within *SMCIA* (n=1) and *SHANK3* (n=1) (Table 1). With these results pathogenic variants of a total of 23 different have been found in RTT/atypical RTT/Rett-like patients (Fig. 1).

The project was approved by the Danish regional ethics committee, the regional dataprotection agency and informed consent was obtained from all participating patients.

“Insert Fig. 1 about here”

CLINICAL OR GENETIC DIAGNOSIS?

The description of variants within several different genes in patients with overlapping phenotypes creates practical challenges with diagnosis in clinical practice. Next generation sequencing based methodologies (gene panels or whole exome/genome sequencing) have overcome some difficulties and diagnosis tends to move from a sole clinical to a genetic confirmation. However, understanding the clinical picture of different disorders is crucial for selection of the most relevant genes to be investigated and for assessing the clinical significance of genomic variants identified in these genes. In the following section we will compare different disorders and causative genes in comparison with RTT features (Table 2).

Pitt-Hopkins and Pitt-Hopkins like syndromes

Pitt-Hopkins syndrome was first described in 1978 in patients with distinct facial dysmorphism and overbreathing⁴². Neurodevelopment and speech are severely impaired, and several patients have progressive microcephaly and seizures^{28, 43}. Gait is often ataxic. Fetal pads on fingers and toes, and stereotypic hand movements such as hand clapping are important features. *TCF4* is the main causative gene for the classical Pitt-Hopkins phenotype⁴⁴; variants in this gene have also been reported in two patients with a Rett-like phenotype^{10, 12}. In the Danish cohort a single patient suspected of having RTT due to hyperventilation and hand stereotypies has a pathogenic *TCF4* variant (Table 1).

Bi-allelic loss-of-function variants in *CNTNAP2* or *NRXN1* can also result in a Pitt-Hopkins like phenotype⁴⁵. These patients also have severe ID and in some regression or stagnation in development^{45, 46}. Other prominent symptoms include epileptic seizures, a speech deficit with loss of verbal skills, and hyperventilation; and some of the patients are described as being non-dysmorphic.⁴⁶ Even though variants of these genes are not yet found in Rett-like patients, they should be included in the genomic analyses of this patient group due the phenotypic overlap.

Cornelia de Lange syndrome (CdLS)

CdLS is characterized by ID, a recognizable pattern of dysmorphic facial features (synophrys, thick arched eyebrows, long eye lashes and downslanting palpebral fissures), hirsutism, short neck, and

possible presence of major malformations, such as limb defects⁴⁷. There are five known genes associated with CdLS. Mutations in *SMC1A* are the second most common cause of CdLS, and commonly associated with seizures, but limb defects are rare⁴⁷. The phenotype associated with *SMC1A* variants may in some include Rett-like features^{47, 48} (Fig. 2). They may have hand stereotypies, apnea, microcephaly, and some have a period of regression. *SMC1A* variants have been described in several patients with a Rett-like disorder^{11, 49}, and we identified a single patient with atypical RTT in the Danish cohort (Fig. 1). The phenotypic spectrum of *SMC1A* spans from CdLS to Rett-like phenotypes, and *SMC1A* can now be considered as the fourth most common gene mutated in patients with a clinical Rett syndrome spectrum (Fig. 1).

“Insert Fig. 2 about here”

Phelan-McDermid syndrome and *SHANK3*

Phelan-McDermid syndrome patients have various degrees of ID and speech deficits, epilepsy, hypotonia, structural brain and/or renal abnormalities and prevalent dysmorphic features, including a pointed chin and dysplastic toenails^{50, 51}. The syndrome is caused by microdeletions encompassing *SHANK3* at 22q13 or a pathogenic variant in this gene, which is also associated with autism⁵². *SHANK3* variants have been reported in two patients with RTT⁵³ and a Rett-like phenotype¹², respectively. In the Danish cohort a *SHANK3* variant was identified in a single patient, who fulfills some of the main criteria of RTT, but due to her normal gait, not categorized as typical RTT. On the other hand she has classical autistic behavior compatible with a *SHANK3* variant⁵².

Christianson type X-linked mental retardation

Christianson type X-linked mental retardation syndrome was first described in 1999 in a large family with males affected with profound ID, absence of speech and epilepsy⁵⁴. Since then, several patients with common features (such as ataxic gait, hyperkinetic movements, a happy demeanor and poor fine motor skills) have been reported^{55, 56}. Epilepsy is reported in approximately 80% of cases,

and some have had a period of regression^{55, 56}. Because of this combination of clinical features, the syndrome has been considered a differential diagnosis of Angelman syndrome⁵⁷. Christianson type X-linked mental retardation is caused by pathogenic variants in *SLC9A6* and has also been identified in two Rett-like patients^{11, 12}.

***SATB2* Associated syndrome (Glass syndrome)**

Pathogenic variants in *SATB2* have been identified in patients with neurodevelopmental disability, speech deficits and nonspecific dysmorphic features, which together have been named as Glass syndrome or “*SATB2* associated syndrome”. Many patients have cleft palate or dental anomalies, but seizures were not prominent and they do not exhibit neurodevelopmental regression^{58, 59}. *SATB2* variants have also been described in two patients with a Rett-like phenotype, both of whom had hand stereotypies, impaired hand function and ID, but had no period of regression or seizures³⁷. *SATB2* associated syndrome should be considered when evaluating Rett-like patients, especially if they have oral anomalies.

Kleefstra syndrome

The key features of Kleefstra syndrome are ID, hypotonia, dysmorphic features and cardiac defects^{36, 60}. However, some characteristic symptoms overlapping with RTT, such as speech loss and impaired walking, may be present⁶¹. Additional nonspecific RTT features, including microcephaly, a sleep disorder and teeth grinding, have been described numerously⁶⁰. Some patients have stereotypic movements and respiratory abnormalities, but are different to those observed in RTT patients^{36, 61}. Kleefstra syndrome is caused by 9q34.3 microdeletions including *EHMT1* or sequence variants of this gene⁶⁰. *EHMT1* variants have not yet been reported in patients with a Rett-like phenotype, but have great phenotypic overlap and has been linked to the Rett-like spectrum³⁶.

Angelman syndrome (AS)

AS and RTT have often been described as potential differential diagnoses of each other, because they both present with severe ID, microcephaly, speech deficits and abnormal hand movements³⁶. However, there are clinically identifiable differences between AS and RTT: AS patients have facial

dysmorphism and they do not have hand wringing, but hand flapping. The EEG is almost always abnormal and often with a classical AS pattern³⁵. AS can be caused by several genetic/epigenetic mechanisms, including variations in *UBE3A*⁶², variants of which have not yet been reported in Rett syndrome patients.

Epilepsy

More than 500 genes have been associated with epilepsy, including genes causing encephalopathy, and pathogenic variants of several of the latter have also been described in patients with Rett-like features (Table 2, Fig. 1). In Fig. 3 we have compiled the age of onset of seizures for all the genes that have been associated with RTT or Rett-like clinical spectrum, as the type and age of onset of epilepsy can be an important indicator of which group of genes is likely to be causative. The epileptic encephalopathies may overlap with Rett-like phenotypes, especially where there is a period of regression with the onset of epilepsy, together with progressive microcephaly, and intellectual, speech and motor deficits¹⁴. Epileptic encephalopathies are defined as conditions where the progressive disturbance in cerebral function is thought to be the result of the epileptiform abnormalities⁶³. However, in some of the so-called epileptic encephalopathies it is likely that the neurodevelopmental co-morbidities are primary, since neurodevelopmental abnormalities can occur before the onset of seizures, and in fact some patients never experience any seizures. This has been the case with *STXBPI* variants, for instance, where patients have moderate to severe ID, speech deficits, ataxia and tremor⁶⁴⁻⁶⁶; epilepsy is described in 95% of cases with a median age of 6 weeks but ranging from 1 day to 12 years⁶⁵. Six patients with a Rett-like phenotype, including two Danish patients, have been found to have *STXBPI* variants^{10, 11, 14, 67} (Fig. 1).

Variants in *SCN1A*, *SCN2A* and *SCN8A* lead to early onset of seizures and variants in these genes have been described in single cases with Rett-like features. The development of epilepsy is variable in these cases, but in all of them a period of regression has followed the epileptic seizures^{12, 14, 68}. In addition, patients may have ataxia, encephalopathy, various degrees of ID and hand stereotypies, and so these genes should be considered in Rett-like patients with early onset epilepsy. The severity of epilepsy is variable in patients with *SCN1A*, and an *SCN1A* variant was found in one patient with a Rett-like phenotype¹². In the Danish cohort we identified a single patient with an

SCN2A variant. She was referred with the suspicion of RTT, but her clinical history was more suggestive of a primary epileptic encephalopathy disorder, since the regression was related to the onset of intractable epilepsy.

GRIN2A and *GRIN2B* are two genes which cause ID and childhood onset epilepsy⁶⁹. Variants in *GRIN2A* cause a clinical heterogeneous disorder, and have been reported in 20% of patients with Landau-Kleffner syndrome, continuous spike and waves during slow-wave sleep syndrome and electroclinically atypical rolandic epilepsy⁷⁰. *GRIN2B* is currently considered an epileptic encephalopathy gene^{71, 72}, but variants have been reported in patients both with and without epilepsy. Evaluation of larger cohorts is needed to better define the phenotype associated with variants in this gene. Notably, variations in *GRIN2A* and *GRIN2B* have been reported in three Rett-like patients, all of whom had hand stereotypies, whereas the patient with a *GRIN2B* variant also had a breathing disturbance^{11, 12}.

Variants of *HCN1* and *SLC6A1* have been reported only in few patients in epileptic encephalopathy cohorts^{73, 74}; and *EEF1A2* variants were detected in a few patients with ID, dysmorphic facial features epilepsy with a variable age of onset⁷⁵. Variants in these genes are described in single patients with a Rett-like phenotype, including stereotypic hand movements and breathing abnormalities as distinct features of RTT^{11, 12}.

KCNA2 variants are phenotypically linked to infantile epilepsy and episodic ataxia,⁹ but also to hereditary spastic paraplegia⁷⁶. The only Rett-like phenotype patient with a *KCNA2* variant had an onset of regression a few months before the onset of intractable epilepsy. She also had loss of hand skills, hand stereotypies, microcephaly and a speech deficit⁹.

KCNB1 has previously been described as a gene related to epileptic encephalopathy and ID, and sequence variants have only been described in a few patients, one of whom had handwringing^{77, 78}. *KCNB1* variants have not previously been described in Rett-like patients, even though they may be associated with clinical features overlapping with those of RTT. In the Danish cohort we identified a single case with pathogenic *KCNB1* variant. The patient displayed many RTT features, including neurodevelopmental regression, loss of hand function, hand stereotypies and a speech deficit, and the onset of cognitive and motor decline was prior to her seizures. We suggest that this finding warrants the inclusion of *KCNB1* in the expanding group of Rett-like genes.

“Insert Fig. 3 about here”

WDR45 and other genes

WDR45 variants were first linked to a neurodegenerative disorder with iron deposits, and have been reported in four patients with an initial diagnosis of RTT or a Rett-like disorder, mainly because of cognitive and motor decline and hand stereotypies. Patients with *WDR45* variants can be interpreted as Rett-like in the early stages of development before the brain MRI scans displaying the iron deposits typical of *WDR45* disorder become obvious^{11, 79}.

Variants of all the other genes listed in Fig. 1^{10, 37, 80-82}, except for *WDR45*^{38, 79, 83}, have been observed in only one or two patients, and these genes are described in more detail in the supplementary material.

“Insert link to supplementary material about here”

CLINICAL SIGNATURES OF RETT-LIKE PHENOTYPES

In a cohort of 35 Danish patients with Rett-like features but without *MECP2*, *CDKL5* or *FOXP1* variants, six patients revealed pathogenic changes in five other genes (*SMC1A*, *TCF4*, *SHANK3*, *STXBP1* and *SCN2A*), previously linked to a Rett-like phenotype. Furthermore, we identified a *KCNB1* variant, expanding the range of “Rett spectrum genes.”

These findings, together with the published reports, underscore that RTT and Rett-like phenotypes represent a clinically heterogeneous group of disorders, which may be designated as being part of a Rett syndrome spectrum (Fig. 1). The underlying genetic defects are also quite heterogeneous, with pathogenic variants reported in a number of genes, but where variants of each gene are detected in only a few patients, as outlined above. However, a number of recurrences have been reported in a number of genes such as *SMC1A*, *TCF4*, *SHANK3* and *WDR45*, as well as a group of epileptic encephalopathy genes, all of which should be considered in the molecular diagnosis of patients with Rett-like phenotypes.

Since the reports of Andreas Rett and Bengt Hagberg and international colleagues, who undertook thorough initial evaluations of patients with RTT, unique co-morbidities have been identified¹⁶. These co-morbidities distinguish patients with RTT from those who have other neurodevelopmental disorders. Some of the recent genes associated with Rett-like phenotypes were detected through a genotype first approach as a consequence of large scale genetic screening technologies, but not based on the clinical phenotype of the patients. However, it is possible to describe co-morbidities when patients are extensively phenotyped and compared to an adequate cohort of cases with mutations in the same gene. Descriptions of genes in a specific group of patients with a single major clinical feature like epilepsy may not emphasize other features or co-morbidities. Therefore, the full spectrum of the clinical picture will only be revealed when larger cohorts of patients with pathogenic variants of the same gene are described. This can lead to the “lumper” and “splitter” conundrum, where, for instance, newly identified genes associated with a Rett-like phenotype and severe epilepsy may be perceived as primary epileptic encephalopathies, or may be perhaps cast as separate syndromes based on their spectrum of co-morbidities. This has been discussed especially with regards to *STXBPI* variants^{65, 84} that have been recurrently reported in Rett-like patients (Fig. 1). We also suggest a new “Rett-like gene”, namely *KCNBI*, where several patients harbouring mutations in this gene have handwringing and regression.

In the Danish cohort we found that using the clinical criteria described by Neul et al (2010), the diagnosis of RTT is often very clear and pinpoints to a phenotype associated with *MECP2* variants with great accuracy²³. However, it can be argued if the atypical RTT criteria really apply to patients with variants in *CDKL5* and *FOXP1*, since these patients often have early neurodevelopmental symptoms and/or early onset epilepsy. We find that when diagnosing Rett-like patients it is helpful to establish the age of onset of epilepsy as a pointer to the correct molecular diagnosis (Fig. 3). In the Danish cohort, a female patient was molecularly diagnosed, at the age 52 years old, with a *CDKL5* variant by direct sequencing, which was performed because clinical examination and a thorough medical history revealed a period of severe epilepsy in early infancy. Thus, it should always be remembered that the phenotype may evolve with time. However, one must be cautious about applying hard and definite rules. For instance for *FOXP1* the mean age of onset of seizures has been reported as 6.8 years, but seizures can occur as early as 6 months of age, and not all of the

patients have seizures (87%)³⁴. Thus, a variant in this gene may be considered if there are other features suggestive of a *FOXG1* defect, regardless age of onset of seizures (Fig. 3).

When evaluating a patient who does not fulfill the clinical RTT criteria but has overlapping features, some key features should be taken into consideration in order to establish the diagnosis: psychomotor development should be carefully assessed for the first year of life to evaluate the age of onset of regression, and the age of onset of epilepsy. Furthermore, careful characterization of hand movements and breathing pattern are invaluable. Because of the clinical and genetic heterogeneity, the diagnostic approach for patients with a Rett-like phenotype is shifting to a genotype first approach using gene panels, whole exome or genome sequencing. Nevertheless the clinical evaluation with identification of distinct clinical features is still highly crucial to assess the validity of causation of the putative sequence variants. Furthermore, as more patients with variants in the same genes are identified, clinical subgroups can be outlined.

PERSPECTIVES

From a clinical perspective an overview of the genes involved in typical RTT, atypical RTT and Rett-like phenotypes enables a better understanding of the genetic landscape of the RTT spectrum. From a research perspective the genes associated with Rett-like phenotypes need to be elucidated further in order to gain a more complete understanding of the genetic and functional networks involved. Apart from the known genes, variants in a number of other genes with yet unknown functions have been found through screening of large Rett-like phenotype cohorts^{10, 12}. Some of these may represent new candidate genes and further investigations of future cohorts and functional studies are necessary to establish their potential role in this disease pathogenesis. Furthermore, elucidation of the functional pathways involved could pave the way for the development of future targeted therapies.

Acknowledgements

We thank the patients and their families for participating in the project. The research has been funded by “Dr. Louises Børnehospitals Fond” and “Fonden til Lægevidenskabens Fremme”.

Legends for figures:**Figure 1:**

23 OMIM genes found in Rett-like phenotypes in literature (dark grey) and in the Danish database (light grey).

Figure 2:

Clinical spectrum of *SMC1A* spanning from Rett syndrome to Cornelia de Lange Syndrome.

Figure 3:

Average time for first epileptic seizure.* indicates that >5% of patients with variations in this gene have been reported without epilepsy.

Reference List

- (1) Rett A. On a remarkable syndrome of cerebral atrophy associated with hyperammonaemia in childhood. *Wien Med Wochenschr* 2016;166(11-12):322-324.
- (2) Zappella M. The Rett girls with preserved speech. *Brain Dev* 1992;14(2):98-101.
- (3) Hagberg BA, Skjeldal OH. Rett variants: a suggested model for inclusion criteria. *Pediatr Neurol* 1994;11(1):5-11.
- (4) Hanefeld F. The clinical pattern of the Rett syndrome. *Brain Dev* 1985;7(3):320-325.
- (5) Rolando S. Rett syndrome: report of eight cases. *Brain Dev* 1985;7(3):290-296.

- (6) Amir RE, Van den Veyver IB, Wan M, Tran CQ, Francke U, Zoghbi HY. Rett syndrome is caused by mutations in X-linked MECP2, encoding methyl-CpG-binding protein 2. *Nat Genet* 1999;23(2):185-188.
- (7) Weaving LS, Christodoulou J, Williamson SL et al. Mutations of CDKL5 cause a severe neurodevelopmental disorder with infantile spasms and mental retardation. *Am J Hum Genet* 2004;75(6):1079-1093.
- (8) Ariani F, Hayek G, Rondinella D et al. FOXP1 is responsible for the congenital variant of Rett syndrome. *Am J Hum Genet* 2008;83(1):89-93.
- (9) Allou L, Julia S, Amsallem D et al. Rett-like phenotypes: expanding the genetic heterogeneity to the KCNA2 gene and first familial case of CDKL5-related disease. *Clin Genet* 2016.
- (10) Lopes F, Barbosa M, Ameur A et al. Identification of novel genetic causes of Rett syndrome-like phenotypes. *J Med Genet* 2016;53(3):190-199.
- (11) Sajan SA, Jhangiani SN, Muzny DM et al. Enrichment of mutations in chromatin regulators in people with Rett syndrome lacking mutations in MECP2. *Genet Med* 2016.
- (12) Lucariello M, Vidal E, Vidal S et al. Whole exome sequencing of Rett syndrome-like patients reveals the mutational diversity of the clinical phenotype. *Hum Genet* 2016;135(12):1343-1354.
- (13) Lebrun N, Lebon S, Jeannet PY, Jacquemont S, Billuart P, Bienvenu T. Early-onset encephalopathy with epilepsy associated with a novel splice site mutation in SMC1A. *Am J Med Genet A* 2015;167A(12):3076-3081.
- (14) Olson HE, Tambunan D, LaCoursiere C et al. Mutations in epilepsy and intellectual disability genes in patients with features of Rett syndrome. *Am J Med Genet A* 2015;167A(9):2017-2025.
- (15) Bisgaard AM, Schonewolf-Greulich B, Ravn K, Ronde G. Is it possible to diagnose Rett syndrome before classical symptoms become obvious? Review of 24 Danish cases born between 2003 and 2012. *Eur J Paediatr Neurol* 2015;19(6):679-687.
- (16) Hagberg B. Clinical manifestations and stages of Rett syndrome. *Ment Retard Dev Disabil Res Rev* 2002;8(2):61-65.
- (17) Downs J, Bebbington A, Jacoby P et al. Level of purposeful hand function as a marker of clinical severity in Rett syndrome. *Dev Med Child Neurol* 2010;52(9):817-823.
- (18) Pini G, Bigoni S, Congiu L et al. Rett syndrome: a wide clinical and autonomic picture. *Orphanet J Rare Dis* 2016;11(1):132.
- (19) Schultz RJ, Glaze DG, Motil KJ et al. The pattern of growth failure in Rett syndrome. *Am J Dis Child* 1993;147(6):633-637.

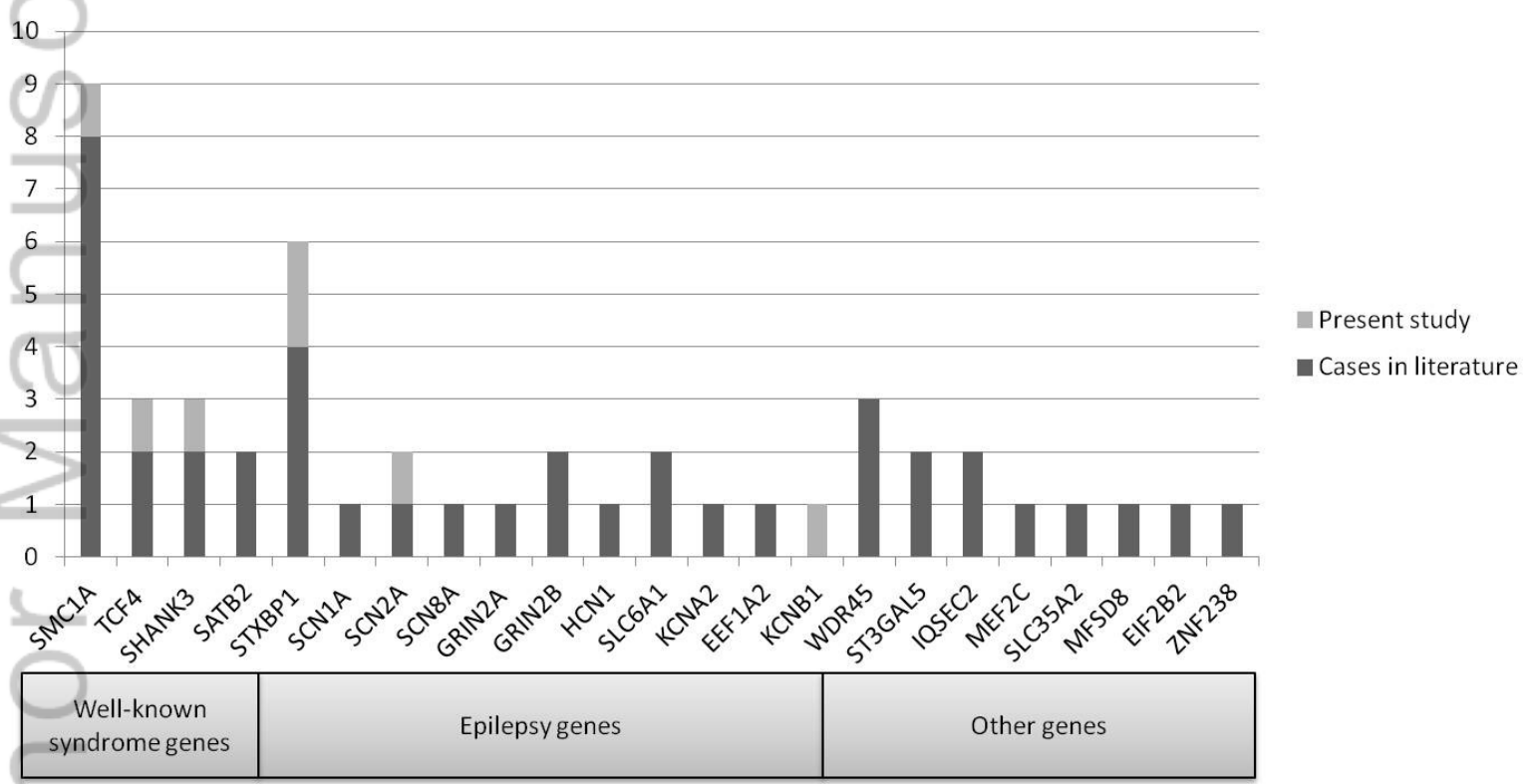
- (20) Lim Z, Downs J, Wong K, Ellaway C, Leonard H. Expanding the clinical picture of the MECP2 Duplication syndrome. *Clin Genet* 2016.
- (21) Nissenkorn A, Levy-Drummer RS, Bondi O et al. Epilepsy in Rett syndrome--lessons from the Rett networked database. *Epilepsia* 2015;56(4):569-576.
- (22) Allanson JE, Hennekam RC, Moog U, Smeets EE. Rett syndrome: a study of the face. *Am J Med Genet A* 2011;155A(7):1563-1567.
- (23) Neul JL, Kaufmann WE, Glaze DG et al. Rett syndrome: revised diagnostic criteria and nomenclature. *Ann Neurol* 2010;68(6):944-950.
- (24) Krishnaraj R, Ho G, Christodoulou J. RettBASE: Rett syndrome database update. *Hum Mutat* 2017.
- (25) Schonewolf-Greulich B, Tejada MI, Stephens K et al. The MECP2 variant c.925C>T (p.Arg309Trp) causes intellectual disability in both males and females without classic features of Rett syndrome. *Clin Genet* 2016;89(6):733-738.
- (26) Evans JC, Archer HL, Colley JP et al. Early onset seizures and Rett-like features associated with mutations in CDKL5. *Eur J Hum Genet* 2005;13(10):1113-1120.
- (27) Fehr S, Downs J, Ho G et al. Functional abilities in children and adults with the CDKL5 disorder. *Am J Med Genet A* 2016;170(11):2860-2869.
- (28) Marangi G, Zollino M. Pitt-Hopkins Syndrome and Differential Diagnosis: A Molecular and Clinical Challenge. *J Pediatr Genet* 2015;4(3):168-176.
- (29) Mitter D, Pringsheim M, Kaulisch M et al. FOXC1 syndrome: genotype-phenotype association in 83 patients with FOXC1 variants. *Genet Med* 2017.
- (30) Archer HL, Evans J, Edwards S et al. CDKL5 mutations cause infantile spasms, early onset seizures, and severe mental retardation in female patients. *J Med Genet* 2006;43(9):729-734.
- (31) Fehr S, Wilson M, Downs J et al. The CDKL5 disorder is an independent clinical entity associated with early-onset encephalopathy. *Eur J Hum Genet* 2013;21(3):266-273.
- (32) Kortum F, Das S, Flindt M et al. The core FOXC1 syndrome phenotype consists of postnatal microcephaly, severe mental retardation, absent language, dyskinesia, and corpus callosum hypogenesis. *J Med Genet* 2011;48(6):396-406.
- (33) Mencarelli MA, Spanhol-Rosseto A, Artuso R et al. Novel FOXC1 mutations associated with the congenital variant of Rett syndrome. *J Med Genet* 2010;47(1):49-53.
- (34) Seltzer LE, Ma M, Ahmed S et al. Epilepsy and outcome in FOXC1-related disorders. *Epilepsia* 2014;55(8):1292-1300.

- (35) Thibert RL, Larson AM, Hsieh DT, Raby AR, Thiele EA. Neurologic manifestations of Angelman syndrome. *Pediatr Neurol* 2013;48(4):271-279.
- (36) Willemsen MH, Rensen JH, van Schrojenstein-Lantman de Valk HM, Hamel BC, Kleefstra T. Adult Phenotypes in Angelman- and Rett-Like Syndromes. *Mol Syndromol* 2012;2(3-5):217-234.
- (37) Lee JS, Yoo Y, Lim BC, Kim KJ, Choi M, Chae JH. SATB2-associated syndrome presenting with Rett-like phenotypes. *Clin Genet* 2016;89(6):728-732.
- (38) Okamoto N, Ikeda T, Hasegawa T et al. Early manifestations of BPAN in a pediatric patient. *Am J Med Genet A* 2014;164A(12):3095-3099.
- (39) Moller RS, Larsen LH, Johannesen KM et al. Gene Panel Testing in Epileptic Encephalopathies and Familial Epilepsies. *Mol Syndromol* 2016;7(4):210-219.
- (40) Weckhuysen S, Holmgren P, Hendrickx R et al. Reduction of seizure frequency after epilepsy surgery in a patient with STXBP1 encephalopathy and clinical description of six novel mutation carriers. *Epilepsia* 2013;54(5):e74-e80.
- (41) Wolff M, Johannesen KM, Hedrich UB et al. Genetic and phenotypic heterogeneity suggest therapeutic implications in SCN2A-related disorders. *Brain* 2017.
- (42) de Winter CF, Baas M, Bijlsma EK, van HJ, Routledge S, Hennekam RC. Phenotype and natural history in 101 individuals with Pitt-Hopkins syndrome through an internet questionnaire system. *Orphanet J Rare Dis* 2016;11:37.
- (43) Peippo M, Ignatius J. Pitt-Hopkins Syndrome. *Mol Syndromol* 2012;2(3-5):171-180.
- (44) Amiel J, Rio M, de PL et al. Mutations in TCF4, encoding a class I basic helix-loop-helix transcription factor, are responsible for Pitt-Hopkins syndrome, a severe epileptic encephalopathy associated with autonomic dysfunction. *Am J Hum Genet* 2007;80(5):988-993.
- (45) Zweier C, de Jong EK, Zweier M et al. CNTNAP2 and NRXN1 are mutated in autosomal-recessive Pitt-Hopkins-like mental retardation and determine the level of a common synaptic protein in Drosophila. *Am J Hum Genet* 2009;85(5):655-666.
- (46) Smogavec M, Cleall A, Hoyer J et al. Eight further individuals with intellectual disability and epilepsy carrying bi-allelic CNTNAP2 aberrations allow delineation of the mutational and phenotypic spectrum. *J Med Genet* 2016;53(12):820-827.
- (47) Boyle MI, Jespersgaard C, Brondum-Nielsen K, Bisgaard AM, Tumer Z. Cornelia de Lange syndrome. *Clin Genet* 2015;88(1):1-12.
- (48) Huisman S, Mulder PA, Redeker E et al. Phenotypes and genotypes in individuals with SMC1A variants. *Am J Med Genet A* 2017.

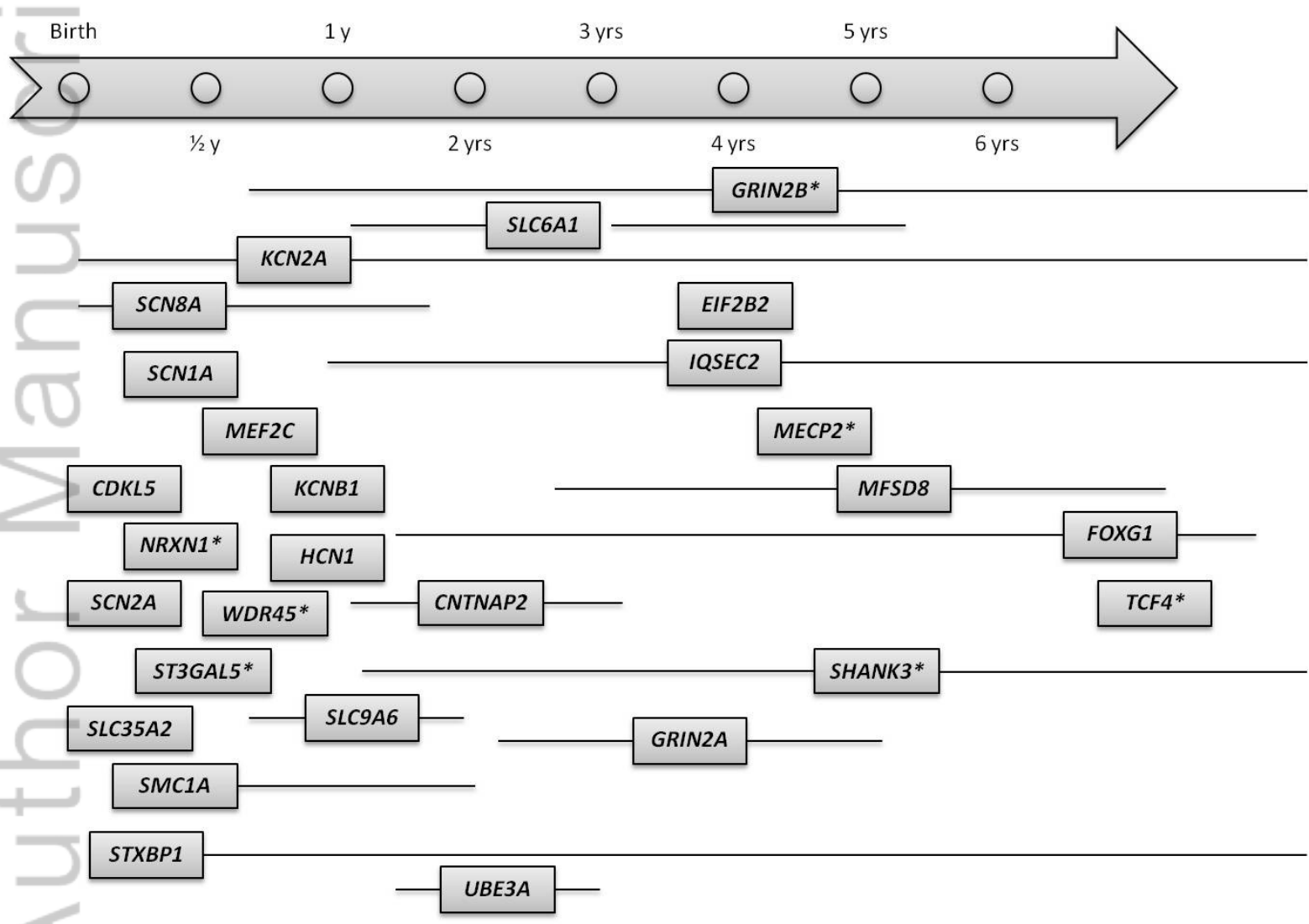
- (49) Gilissen C, Hehir-Kwa JY, Thung DT et al. Genome sequencing identifies major causes of severe intellectual disability. *Nature* 2014;511(7509):344-347.
- (50) Sarasua SM, Dwivedi A, Boccutto L et al. Association between deletion size and important phenotypes expands the genomic region of interest in Phelan-McDermid syndrome (22q13 deletion syndrome). *J Med Genet* 2011;48(11):761-766.
- (51) Kolevzon A, Angarita B, Bush L et al. Phelan-McDermid syndrome: a review of the literature and practice parameters for medical assessment and monitoring. *J Neurodev Disord* 2014;6(1):39.
- (52) Boccutto L, Lauri M, Sarasua SM et al. Prevalence of SHANK3 variants in patients with different subtypes of autism spectrum disorders. *Eur J Hum Genet* 2013;21(3):310-316.
- (53) Hara M, Ohba C, Yamashita Y, Saitsu H, Matsumoto N, Matsuishi T. De novo SHANK3 mutation causes Rett syndrome-like phenotype in a female patient. *Am J Med Genet A* 2015;167(7):1593-1596.
- (54) Christianson AL, Stevenson RE, van der Meyden CH et al. X linked severe mental retardation, craniofacial dysmorphism, epilepsy, ophthalmoplegia, and cerebellar atrophy in a large South African kindred is localised to Xq24-q27. *J Med Genet* 1999;36(10):759-766.
- (55) Gilfillan GD, Selmer KK, Roxrud I et al. SLC9A6 mutations cause X-linked mental retardation, microcephaly, epilepsy, and ataxia, a phenotype mimicking Angelman syndrome. *Am J Hum Genet* 2008;82(4):1003-1010.
- (56) Schroer RJ, Holden KR, Tarpey PS et al. Natural history of Christianson syndrome. *Am J Med Genet A* 2010;152A(11):2775-2783.
- (57) Tan WH, Bird LM, Thibert RL, Williams CA. If not Angelman, what is it? A review of Angelman-like syndromes. *Am J Med Genet A* 2014;164A(4):975-992.
- (58) Bengani H, Handley M, Alvi M et al. Clinical and molecular consequences of disease-associated de novo mutations in SATB2. *Genet Med* 2017.
- (59) Zarate YA, Kalsner L, Basinger A et al. Genotype and phenotype in 12 additional individuals with SATB2-associated syndrome. *Clin Genet* 2017.
- (60) Kleefstra T, Brunner HG, Amiel J et al. Loss-of-function mutations in euchromatin histone methyl transferase 1 (EHMT1) cause the 9q34 subtelomeric deletion syndrome. *Am J Hum Genet* 2006;79(2):370-377.
- (61) Verhoeven WM, Egger JI, Vermeulen K, van de Warrenburg BP, Kleefstra T. Kleefstra syndrome in three adult patients: further delineation of the behavioral and neurological phenotype shows aspects of a neurodegenerative course. *Am J Med Genet A* 2011;155A(10):2409-2415.

- (62) Kishino T, Lalande M, Wagstaff J. UBE3A/E6-AP mutations cause Angelman syndrome. *Nat Genet* 1997;15(1):70-73.
- (63) Engel J, Jr. A proposed diagnostic scheme for people with epileptic seizures and with epilepsy: report of the ILAE Task Force on Classification and Terminology. *Epilepsia* 2001;42(6):796-803.
- (64) Gburek-Augustat J, Beck-Woedl S, Tzschach A, Bauer P, Schoening M, Riess A. Epilepsy is not a mandatory feature of STXBP1 associated ataxia-tremor-retardation syndrome. *Eur J Paediatr Neurol* 2016;20(4):661-665.
- (65) Stamberger H, Nikanorova M, Willemsen MH et al. STXBP1 encephalopathy: A neurodevelopmental disorder including epilepsy. *Neurology* 2016;86(10):954-962.
- (66) Helbig I, Tayoun AA. Understanding Genotypes and Phenotypes in Epileptic Encephalopathies. *Mol Syndromol* 2016;7(4):172-181.
- (67) Romaniello R, Saettini F, Panzeri E, Arrigoni F, Bassi MT, Borgatti R. A de-novo STXBP1 gene mutation in a patient showing the Rett syndrome phenotype. *Neuroreport* 2015;26(5):254-257.
- (68) Baasch AL, Huning I, Gilissen C et al. Exome sequencing identifies a de novo SCN2A mutation in a patient with intractable seizures, severe intellectual disability, optic atrophy, muscular hypotonia, and brain abnormalities. *Epilepsia* 2014;55(4):e25-e29.
- (69) von SC, Ensslen M, Moller RS et al. Epilepsy in patients with GRIN2A alterations: Genetics, neurodevelopment, epileptic phenotype and response to anticonvulsive drugs. *Eur J Paediatr Neurol* 2017.
- (70) Lesca G, Rudolf G, Bruneau N et al. GRIN2A mutations in acquired epileptic aphasia and related childhood focal epilepsies and encephalopathies with speech and language dysfunction. *Nat Genet* 2013;45(9):1061-1066.
- (71) Endele S, Rosenberger G, Geider K et al. Mutations in GRIN2A and GRIN2B encoding regulatory subunits of NMDA receptors cause variable neurodevelopmental phenotypes. *Nat Genet* 2010;42(11):1021-1026.
- (72) Lemke JR, Lal D, Reinthaler EM et al. Mutations in GRIN2A cause idiopathic focal epilepsy with rolandic spikes. *Nat Genet* 2013;45(9):1067-1072.
- (73) Carvill GL, McMahon JM, Schneider A et al. Mutations in the GABA Transporter SLC6A1 Cause Epilepsy with Myoclonic-Atonic Seizures. *Am J Hum Genet* 2015;96(5):808-815.
- (74) Nava C, Dalle C, Rastetter A et al. De novo mutations in HCN1 cause early infantile epileptic encephalopathy. *Nat Genet* 2014;46(6):640-645.

- (75) Nakajima J, Okamoto N, Tohyama J et al. De novo *EEF1A2* mutations in patients with characteristic facial features, intellectual disability, autistic behaviors and epilepsy. *Clin Genet* 2015;87(4):356-361.
- (76) Manole A, Mannikko R, Hanna MG, Kullmann DM, Houlden H. De novo *KCNA2* mutations cause hereditary spastic paraplegia. *Ann Neurol* 2017;81(2):326-328.
- (77) Saitsu H, Akita T, Tohyama J et al. De novo *KCNB1* mutations in infantile epilepsy inhibit repetitive neuronal firing. *Sci Rep* 2015;5:15199.
- (78) Torkamani A, Bersell K, Jorge BS et al. De novo *KCNB1* mutations in epileptic encephalopathy. *Ann Neurol* 2014;76(4):529-540.
- (79) Hoffjan S, Ibsler A, Tschentscher A, Dekomien G, Bidinost C, Rosa AL. *WDR45* mutations in Rett (-like) syndrome and developmental delay: Case report and an appraisal of the literature. *Mol Cell Probes* 2016;30(1):44-49.
- (80) Lee JS, Yoo Y, Lim BC et al. *GM3* synthase deficiency due to *ST3GAL5* variants in two Korean female siblings: Masquerading as Rett syndrome-like phenotype. *Am J Med Genet A* 2016;170(8):2200-2205.
- (81) Lambert L, Bienvenu T, Allou L et al. *MEF2C* mutations are a rare cause of Rett or severe Rett-like encephalopathies. *Clin Genet* 2012;82(5):499-501.
- (82) Craiu D, Dragostin O, Dica A et al. Rett-like onset in late-infantile neuronal ceroid lipofuscinosis (*CLN7*) caused by compound heterozygous mutation in the *MFSD8* gene and review of the literature data on clinical onset signs. *Eur J Paediatr Neurol* 2015;19(1):78-86.
- (83) Ohba C, Nabatame S, Iijima Y et al. De novo *WDR45* mutation in a patient showing clinically Rett syndrome with childhood iron deposition in brain. *J Hum Genet* 2014;59(5):292-295.
- (84) Gupta A. *STXBP1*-Related E. *Epilepsy Curr* 2016;16(5):302-304.



Billede1.jpg



Billede3.jpg

Auth Manuscript


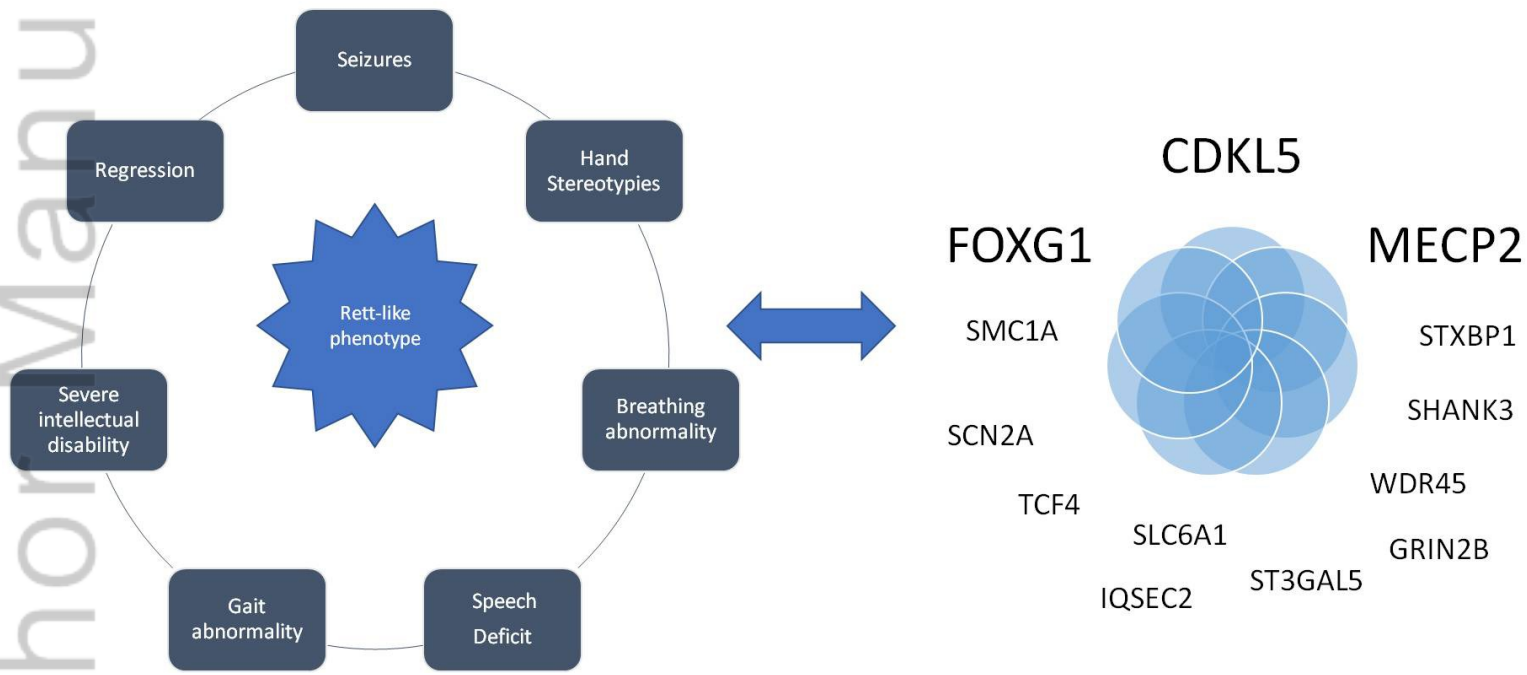


figure2.jpg

Exploring the genes in Rett-like phenotypes



Graphical abstract.jpg

Table 1: Summary of the clinical RTT features of the Danish Rett-like cases.

Gene	<i>STXBP1</i>	<i>STXBP1</i>	<i>SCN2A</i>	<i>KCNB1</i>	<i>TCF4</i>	<i>SHANK3</i>	<i>SMC1A</i>
Gender	female	female	female	female	female	female	female
Variation	c.1061G>A	c.230T>A	c.3955C>T	c.946G>A	c.1669dupC	c.2265+1G>A	c.3576delA
Inheritance	<i>de novo</i>	<i>de novo</i>	<i>de novo</i>	<i>de novo</i>	<i>de novo</i>	<i>de novo</i>	<i>de novo</i>
Head size	microcephaly	normal	progressive microcephaly	normal	progressive microcephaly	normal	progressive microcephaly
Epilepsy	from birth to 6 months	from 2 weeks to 3 months	from 17 months	From 2 years	from 2 1/2 years	no	from 2 1/2 years
Other features					dysmorphic features	infections	
Diagnostic criteria for Rett syndrome:							
Required diagnostic Criteria							
Age for a period of regression followed by recovery or stabilization	1 1/2 years	none	17 months	6 months	none	5 1/2 years old	2 1/2 years
Exclusion Criteria for typical RTT	0/3	1/3	0/3	0/3	1/3	0/3	0/3
Brain injury	no	no	no	no	no	no	no
Neurometabolic disease, or severe infection	no	no	no	no	no	no	no
Grossly abnormal development first 6 months	no	yes	no	no	yes	no	no
Main Criteria	3/4	3/4	3/4	4/4	4/4	3/4	4/4
Hand skills	partial loss	impaired	poor	lost	poor	partial loss	partial loss
Language	lost	never acquired	never acquired	never acquired	never acquired	partial loss	lost
Gait	partial loss	impaired	impaired	no gait	impaired	normal	no gait
Stereotypic hand movements	no	no	Stereotypies or automatisms	hand wringing	hand wringing	hands to mouth	hand wringing
Supportive Criteria for atypical RTT	8/11	5/11	7/11	3/11	4/11	4/11	5/11
Breathing abnormality	yes	no	yes	yes	yes	no	yes
Bruxism	yes	yes	yes	no	no	yes	no
Impaired sleep pattern	yes	no	yes	yes	yes	yes	no
Abnormal muscle tone	yes	yes	yes	yes	yes	no	yes
Peripheral vasomotor disturbances	no	no	no	no	no	no	no
Scoliosis/kyphosis	yes	yes	no	no	no	no	yes
Growth retardation	yes	no	yes	no	no	no	yes
Small cold hands and feet	yes	no	yes	no	no	no	yes
Inappropriate laughing/screaming spells	no	no	yes	no	yes	yes	no
Diminished response to pain	yes	yes	yes	no	no	yes	no
Intense eye communication	no	yes	no	no	no	no	no
RTT Diagnosis (based on the Neul criteria)	Atypical	Atypical	Atypical	Typical	RTT-like	RTT-like	Typical

The HPO terms corresponding to the symptoms, which are part of the Rett-syndrome diagnostic criteria are listed in Supplementary table.

This article is protected by copyright. All rights reserved.

Table 2. List of causative genes in Rett-like diagnoses or differential diagnoses and the phenotypical overlap with Rett syndrome.

	Present in RTT											Not present in RTT		Disorders	OMIM#	Inheritance
	Required	4 main criteria				Other common symptoms			Exclusion criteria	Other symptoms						
	Developmental regression	Purposeful hand movements lost/absent	Speech severe deficit/loss	Gait abnormality	Stereotypic hand movements	Breathing abnormality	ID	Epilepsy	Microcephaly	CNS abnormality	Dysmorphic facial features	Other prominent symptoms				
RTT genes	<i>MECP2</i>	+	+	+	+	+	+	+	-	-			Rett Syndrome	312750	XLD	
	<i>CDKL5</i>	+	+	+	+	+	+	+	-	+			Epileptic encephalopathy 2	300672	XLD	
	<i>FOXG1</i>	+	+	+	+	+	-	+	+	-			Rett syndrome, congenital variant	613454	AD	
Well-known syndrome genes	<i>SMC1A</i>	+	+	+	+	+	+	+	+	+			Cornelia de Lange syndrome 2	300590	XLD	
	<i>TCF4</i>	-	+	+	+	+	+	+	+	+			Pitt-Hopkins syndrome	610954	AD	
	<i>CNTNAP2</i>	+	+	+	+	+	+	+	+	+			Pitt-Hopkins like, syndrome 1	610042	AR	
	<i>NRXN1</i>	-	+	+	+	+	+	+	+	+			Pitt-Hopkins like syndrome 2	614325	AR	
	<i>SHANK3</i>	+	-	+	+	+	-	+	-	+			Phelan-McDermid syndrome	606232	AD	
	<i>SATB2</i>	-	+	+	+	+	+	+	-	+		CP	Glass syndrome	612313	AD	
	<i>SLC9A6</i>	+	-	+	+	-	+	+	+	+			Mental retardation, X-linked syndromic, Christianson type	300243	XLD	
	<i>EHMT1</i>	+	-	+	+	-	+	+	+	+		CHD	Kleefstra syndrome	610253	AD	
	<i>UBE3A</i>	-	-	+	+	+	-	+	+	+	+		Angelman syndrome	105830	AD	
	<i>STXBP1</i>	+	+	+	+	+	-	+	+	-	-		Epileptic encephalopathy 4	612164	AD	
Genes of epilepsy	<i>SCN1A</i>	+	+	+	+	+	-	+	+	+			Epileptic encephalopathy, early infantile, 6 (Dravet syndrome)	607208	AD	
	<i>SCN2A</i>	+	+	+	+	+	-	+	+	-			Epileptic encephalopathy, 11	613721	AD	
	<i>SCN8A</i>	+	-	+	+	+	-	+	+	-			Epileptic encephalopathy, 13	600702	AD	
	<i>GRIN2A</i>	+	-	+	+	+	-	+	-	-			FESD (incl. Landau-Kleffner syndrome)	245570	AD	
	<i>GRIN2B</i>	-	-	+	+	+	+	+	+	-	+		Epileptic encephalopathy, early infantile, 27	616139	AD	
	<i>HCN1</i>	-	+	+	+	+	+	+	+	-	-		Epileptic encephalopathy, early infantile, 24	602780	AD	
	<i>SLC6A1</i>	+	?	+	+	+	-	+	?	?	+		Myoclonic-atonic epilepsy	616421	AD	
	<i>KCNA2</i>	+	+	+	+	-	+	+	+	+	+		Epileptic encephalopathy, early infantile, 32	616366	AD	
	<i>EEF1A2</i>	-	-	+	+	+	+	+	+	-	+		Epileptic encephalopathy, early infantile 33	616409	AD	
	<i>KCNB1</i>	+	+	+	+	+	-	+	+	-	-		Epileptic encephalopathy, early infantile, 26	616056	AD	
Other genes	<i>WDR45</i>	+	+	+	+	+	-	+	+	+	+		Neurodegeneration with brain iron accumulation 5	300894	XLD	
	<i>ST3GAL5</i>	+	+	+	+	+	-	+	+	-	+	SPD	Salt and pepper developmental regression syndrome	609056	AR	
	<i>IQSEC2</i>	+	+	+	+	+	+	+	+	-	-		X-linked mental retardation, MRX1	309530	XLD	
	<i>MEF2C</i>	-	+	+	+	+	-	+	+	+	+		<i>MEF2C</i> haploinsufficiency syndrome	613443	AD	
	<i>SLC35A2</i>	-	+	+	+	+	-	+	+	+	+	RP	Congenital disorder of glycosylation type IIm	300896	XLD	
	<i>MFSD8</i>	+	+	+	+	+	+	+	+	+	-	VL	Ceroid lipofuscinosis neuronal 7	610951	AR	
	<i>EIF2B2</i>	+	+	+	+	+	-	+	+	+	-		Leukoencephalopathy with vanishing white matter	603895	AR	
	<i>ZNF238</i>	+	-	+	+	+	+	+	-	+	+		Mental Retardation, autosomal dominant 22 (AD)	612337	AD	

(+ is noted if the symptom has been described in one or more patients with pathogenic variant in the gene).
 The symptoms emphasized are the main clinical features according to the 2010 classification of clinical Rett and other very specific features of RTT.
 Abbreviations: SPD, skin pigmentation disorder, CHD, coronary heart disease, RP, retinitis pigmentosa, CP, cleft palate, VL, visual loss, FESD, Epilepsy, focal, with speech disorder and with or without mental retardation.
 Grey colour are clinical symptoms in common with RTT.

list of causative genes.eps



Minerva Access is the Institutional Repository of The University of Melbourne

Author/s:

Schonewolf-Greulich, B; Bisgaard, A-M; Moller, RS; Duno, M; Brondum-Nielsen, K; Kaur, S; Van Bergen, NJ; Lunke, S; Eggers, S; Jespersgaard, C; Christodoulou, J; Tumer, Z

Title:

Clinician's guide to genes associated with Rett-like phenotypes-Investigation of a Danish cohort and review of the literature

Date:

2019-02-01

Citation:

Schonewolf-Greulich, B., Bisgaard, A. -M., Moller, R. S., Duno, M., Brondum-Nielsen, K., Kaur, S., Van Bergen, N. J., Lunke, S., Eggers, S., Jespersgaard, C., Christodoulou, J. & Tumer, Z. (2019). Clinician's guide to genes associated with Rett-like phenotypes- Investigation of a Danish cohort and review of the literature. CLINICAL GENETICS, 95 (2), pp.221-230. <https://doi.org/10.1111/cge.13153>.

Persistent Link:

<http://hdl.handle.net/11343/283431>

File Description:

Accepted version