



Since January 2020 Elsevier has created a COVID-19 resource centre with free information in English and Mandarin on the novel coronavirus COVID-19. The COVID-19 resource centre is hosted on Elsevier Connect, the company's public news and information website.

Elsevier hereby grants permission to make all its COVID-19-related research that is available on the COVID-19 resource centre - including this research content - immediately available in PubMed Central and other publicly funded repositories, such as the WHO COVID database with rights for unrestricted research re-use and analyses in any form or by any means with acknowledgement of the original source. These permissions are granted for free by Elsevier for as long as the COVID-19 resource centre remains active.

about IL-23 efficacy in the axial domain. Imaging can be used for patient inclusion and as an outcome measure in prospective trials. A recent study specifically addressing the efficacy of secukinumab, an IL-17A inhibitor, in axial psoriatic arthritis included MRI scans and clinical outcome measures to provide objective evidence of efficacy.<sup>10</sup> Although relying on MRI imaging can also have limitations, this approach is currently the only way to provide objective evidence of spinal efficacy.

Studies addressing the efficacy of different therapies in axial psoriatic arthritis are of high importance for treatment guidelines and for daily clinical practice. Current treatment guidelines in psoriatic arthritis rely largely on the results of studies in primary axial spondyloarthritis. Evidence of efficacy in axial psoriatic arthritis would certainly affect not only the guidelines but also the choice of appropriate treatment options in individual patients.

I report grants or research support from AbbVie, Amgen, Celgene, Eli Lilly, Novartis and Pfizer; consultancy fees AbbVie, Amgen, Boehringer Ingelheim, Bristol Myers Squibb, Celgene, Eli Lilly, Gilead, Galapagos, Janssen, Novartis, Pfizer and UCB; and speaker fees from AbbVie, Amgen, Biogen, Celgene, Eli Lilly, Galapagos, Gilead, Janssen, Medac, Novartis, Pfizer, and UCB.

Laura C Coates  
laura.coates@ndorms.ox.ac.uk

Nuffield Department of Orthopaedics, Rheumatology and Musculoskeletal Sciences, University of Oxford, Oxford OX3 7LD, UK

- 1 Mease PJ, Helliwell PS, Gladman DD, et al. Efficacy of guselkumab on axial involvement in patients with active psoriatic arthritis and sacroiliitis: a post-hoc analysis of the phase 3 DISCOVER-1 and DISCOVER-2 studies. *Lancet Rheumatol* 2021; published online June 29. [https://doi.org/10.1016/S2665-9913\(21\)00105-3](https://doi.org/10.1016/S2665-9913(21)00105-3).
- 2 Deodhar A, Gensler LS, Sieper J, et al. Three multicenter, randomized, double-blind, placebo-controlled studies evaluating the efficacy and safety of ustekinumab in axial spondyloarthritis. *Arthritis Rheumatol* 2019; **71**: 258–70.
- 3 Sieper J, Poddubnyy D, Miossec P. The IL-23-IL-17 pathway as a therapeutic target in axial spondyloarthritis. *Nat Rev Rheumatol* 2019; **15**: 747–57.
- 4 Ez-Zaitouni Z, van Lunteren M, Bakker PAC, et al. The influence of discrepant imaging judgements on the classification of axial spondyloarthritis is limited: a replication in the SpondyloArthritis Caught Early (SPACE) cohort. *Ann Rheum Dis* 2018; **77**: e1.
- 5 de Hooge M, Pialat JB, Reijnen M, et al. Assessment of typical SpA lesions on MRI of the spine: do local readers and central readers agree in the DESIR-cohort at baseline? *Clin Rheumatol* 2017; **36**: 1551–59.
- 6 Gladman DD, Helliwell PS, Poddubnyy D, Mease PJ. Updates on axial psoriatic arthritis from the 2020 GRAPPA annual meeting. *J Rheumatol* 2021; published online March 1. <https://doi.org/10.3899/jrheum.201672>.
- 7 Taylor WJ, Harrison AA. Could the Bath ankylosing spondylitis disease activity index (BASDAI) be a valid measure of disease activity in patients with psoriatic arthritis? *Arthritis Rheum* 2004; **51**: 311–15.
- 8 Fernandez-Sueiro JL, Willisch A, Pertega-Diaz S, et al. Validity of the bath ankylosing spondylitis disease activity index for the evaluation of disease activity in axial psoriatic arthritis. *Arthritis Care Res (Hoboken)* 2010; **62**: 78–85.
- 9 Reddy S, Husni ME, Scher JU, Craig E, Ogdie A, Walsh J. Use of the BASDAI in psoriatic arthritis patients with and without axial disease. *ACR Convergence* 2020; online; Nov 5–9, 2020 (abstr 344).
- 10 Baraliakos X, Gossec L, Pournara E, et al. Secukinumab in patients with psoriatic arthritis and axial manifestations: results from the double-blind, randomised, phase 3 MAXIMISE trial. *Ann Rheum Dis* 2021; **80**: 582–90.



## Adult-onset Still's disease following COVID-19 vaccination

Published Online  
July 22, 2021  
[https://doi.org/10.1016/S2665-9913\(21\)00218-6](https://doi.org/10.1016/S2665-9913(21)00218-6)

The spread of the COVID-19 pandemic has led to unprecedented acceleration of vaccine development. Although tested on thousands of people before regulatory approval, very rare adverse events can manifest during roll-out of vaccines to the general population.

During follow-up of the COVID-19 vaccine roll-out, side-effects related to a hypothetical immune system overstimulation or over-reaction have been described, such as adenoviral vector vaccine-induced immune thrombotic thrombocytopenia<sup>1</sup> and systemic immune-mediated diseases after mRNA-vaccine.<sup>2,3</sup> However, to our knowledge, there have been no reports of Adult-onset Still's disease (AOSD) after vaccination with a COVID-19 adenoviral vector vaccine (ie, ChAdOx1 nCoV-19 vaccine).

AOSD is considered a rare inflammatory disorder affecting young adults and IL-1 has a central role in the pathogenesis. Inhibition of IL-1 $\beta$  by monoclonal antibodies and of the IL-1 receptor by antagonists,

substantially ameliorates clinical symptoms.<sup>4</sup> Increasing evidence points towards a similar role for IL-1 in COVID-19 hyperinflammation, and several reports suggest that inhibition of IL-1 substantially reduces hyperinflammation, respiratory insufficiency, and mortality in patients in hospital with severe COVID-19.<sup>5</sup>

Here, we report the case of a 36-year-old male, without any comorbidities or family history of autoimmune diseases, who developed AOSD after the first dose of the ChAdOx1 nCoV-19 vaccine. The day after the vaccination, he developed high-grade fever (>39°C) that lasted for 48 h. The fever then returned 4 days later, preceded by sore throat and accompanied by evanescent and not pruritic rash and chest pain. He was treated at home with antibiotics and non-steroidal anti-inflammatory drugs without improvement. He presented to the emergency room of a local hospital (Santo Spirito Hospital, Rome, Italy) due to the increasing severity of his symptoms and was admitted

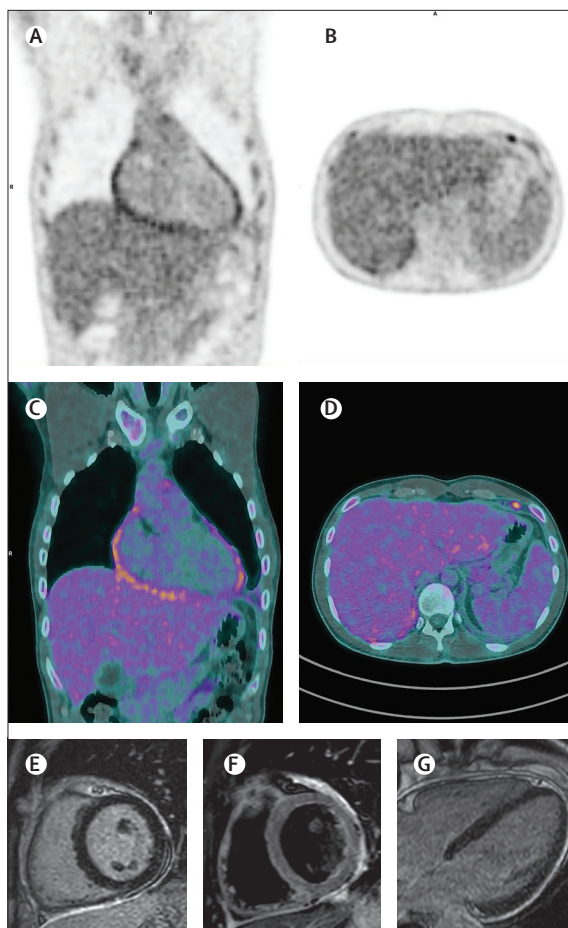
to the internal medicine unit for further exploration. On admission, the patient was febrile with tachycardia, with chest pain exacerbated by inspiration. His pulse was 120 beats per min, temperature was 38.9°C, blood pressure was 120/60 mm Hg, and oxygen saturation was 96%. Nothing relevant was found on physical examination.

After being tested for viral and bacterial agents, which were all negative, given the presence of leukocytosis ( $30.83 \times 10^9$  cells per L with 86.6% neutrophil) and fever, broad-spectrum antibiotic treatment was started, without any clinical or laboratory response during 10 days. The treating physicians suspected that the patient might have an autoimmune condition and so started him on methylprednisolone 0.75 mg/kg, and the fever disappeared after 3 days of treatment. To further investigate the case, the patient was transferred to our rheumatology unit at the Fondazione Policlinico Universitario Agostino Gemelli IRCCS (Rome, Italy).

21 days after the first episode of fever, physical examination and vital parameters were normal, with chest pain exacerbated by inspiration being an isolated finding. Despite the increase of corticosteroid treatment at 1mg/kg, laboratory tests confirmed persistent leukocytosis, abnormal liver function, high acute-phase reactants (C-reactive protein 188 mg/L, erythrocyte sedimentation rate 85 mm/h, IL-6 11.8 ng/L, soluble IL-2R 9.74 UI/L), high serum ferritin (1482 ng/mL, normal range 12–240 ng/mL), and transitory increased troponin (1695 pg/dL).

RT-PCR SARS-CoV-2 tests were done several times with negative results. Microbiological routine tests (including common viral serology and bacterial blood cultures) were negative for anything clinically relevant. An autoimmune panel was normal, except for the presence of beta-2-glycoprotein IgG (29.7 U/mL) and lupus anticoagulant.

Ecocardiography showed pericardial effusion, without modification of ejection fraction. Lung and abdominal ultrasound assessments and CT scan revealed bilateral pleural effusion, posterior wall pericardial effusion, subcentimetric lymphadenopathy, and mild splenomegaly. A PET-CT scan was done and excluded neoplasms or vasculitis, but confirmed cardiophrenic lymphadenopathies and pleuropericardial effusion. cardiac MRI was compatible with recent myopericarditis (figure).



**Figure:** PET (A, B), PET-CT (C, D), and cardiac MRI (E–G) scans of a patient with recent myopericarditis

The figure shows the involvement of pericardium with three different imaging techniques: PET, PET-CT, and MRI, 14 and 21 days after initial symptoms onset. Images A (coronal PET) and C (fused PET-CT images) show increased radiopharmaceutical uptake in the pericardium, and images B (axial PET) and D (PET-CT slices) in lymph node located in left cardiophrenic angle. MRI delayed-enhancement images acquired on the mid-ventricular short-axis (E) and horizontal long axis (F) planes show very high signal in the pericardium correspondence, almost circumferentially affected. A suspected thin underlying epicardial and myocardial involvement can be seen. On T2-weighted imaging with fat suppression on the same plane as in image E (F) presence of hypo intense components can be seen along the epicardial surface suggesting fibrin deposits.

In accordance with Yamaguchi criteria,<sup>4</sup> a diagnosis of AOSD was made and corticosteroid treatment was continued. Because of myocardial involvement, persistent leukocytosis and high ferritin (946 ng/mL), treatment with the IL-1 receptor antagonist anakinra was started (100 mg daily). After 4 days, we observed a complete normalisation of symptoms and blood tests and the patient was discharged.

At 1 month of follow-up, he reported feeling well and ferritin levels and inflammatory markers were within normal limits.

The first case of AOSD after COVID-19 has recently been reported.<sup>6</sup> Systemic inflammation, unremitting fever, high serum ferritin, and a hyperinflammatory syndrome that induces major organ involvement characterise both AOSD<sup>7</sup> and severe COVID-19,<sup>8</sup> suggesting they might be triggered by the same mechanisms.

In the present case, the strong temporal association between the symptoms and COVID-19 vaccination prompted us to suspect a causal connection, since similar AOSD cases have been observed after vaccinations for influenza, hepatitis A, and hepatitis B.<sup>9</sup> However, we cannot exclude the possibility that the timing with regards to vaccination was coincidental. Possible pathogenic mechanisms might include high levels of spike protein production after vaccination, that also cause the immune system activation in COVID-19, suggesting that the inflammatory storm of AOSD can be triggered either by the infection or by the vaccination. Intrinsic adjuvant activity of adenoviral particles targeting innate immune cells and ultimately resulting in the production of type I interferon and multiple pro-inflammatory cytokines, might be another potential cause.<sup>10</sup> Finally, the role of vaccines-adjuvants such as polysorbate 80, which is present also in the influenza and hepatitis vaccines, might also be considered.<sup>3</sup> The response of COVID-19 to IL-1 blockade, known to produce substantial benefit in AOSD, further supports the hypothesis of a strict pathogenic connection between hyperinflammatory syndromes and severe COVID-19.<sup>5</sup>

We declare no competing interests. The patient provided informed consent to publish this case.

*Flavia Leone, Pier Giacomo Cerasuolo, Silvia Laura Bosello, Lucrezia Verardi, Enrica Fiori, Fabrizio Coccioillo, Biagio Merlino, Angelo Zoli, \*Maria Antonietta D'Agostino mariaantonietta.dagostino@unicatt.it*

UOC di Reumatologia, Fondazione Policlinico Universitario A Gemelli IRCCS, Università Cattolica del Sacro Cuore, 00168 Roma, Italy (FL, PGC, SLB, LV, AZ, MAD); UOC di Pronto Soccorso e Medicina d'Urgenza, Presidio Ospedaliero Santo Spirito, Rome, Italy (EF); Nuclear Medicine Unit, Fondazione Policlinico Universitario A Gemelli, IRCCS, Rome, Italy (FC); Department of Radiological and Hematological Sciences, Section of Radiology, Fondazione Policlinico Universitario A Gemelli, IRCCS, Università Cattolica del Sacro Cuore, Rome, Italy (BM)

- 1 Greinacher A, Thiele T, Warkentin TE, Weisser K, Kyrle PA, Eichinger S. Thrombotic thrombocytopenia after ChAdOx1 nCov-19 vaccination. *N Engl J Med* 2021; **384**: 2092–101.
- 2 Steinberg J, Thomas A, Iravani A. <sup>18</sup>F-fluorodeoxyglucose PET/CT findings in a systemic inflammatory response syndrome after COVID-19 vaccine. *Lancet* 2021; **397**: e9.
- 3 Watad A, De Marco G, Mahajna H, et al. Immune-mediated disease flares or new-onset disease in 27 subjects following mRNA/DNA SARS-CoV-2 vaccination. *Vaccines (Basel)* 2021; **9**: 435.
- 4 Feist E, Mitrovic S, Fautrel B. Mechanisms, biomarkers and targets for adult-onset Still's disease. *Nat Rev Rheumatol* 2018; **14**: 603–18.
- 5 Cavalli G, De Luca G, Campochiaro C, et al. Interleukin-1 blockade with high-dose anakinra in patients with COVID-19, acute respiratory distress syndrome, and hyperinflammation: a retrospective cohort study. *Lancet Rheumatol* 2020; **2**: e325–31.
- 6 Bamidis AD, Koehler P, di Cristanziano V, et al. First manifestation of adult-onset Still's disease after COVID-19. *Lancet Rheumatol* 2021; **3**: e319–21.
- 7 Fauter M, Gerfaud-Valentin M, Delplanque M, Georjin-Lavielle S, Sève P, Jamilloux Y. Adult-onset Still's disease complications. *Rev Med Interne* 2020; **41**: 168–79 (in French).
- 8 Siripanthong B, Nazarian S, Muser D, et al. Recognizing COVID-19-related myocarditis: the possible pathophysiology and proposed guideline for diagnosis and management. *Heart Rhythm* 2020; **17**: 1463–71.
- 9 Yoshioka K, Fujimoto S, Oba H, Minami M, Aoki T. Onset of adult-onset Still's disease following influenza vaccination. *Mod Rheumatol* 2011; **21**: 432–35.
- 10 Teijaro JR, Farber DL. COVID-19 vaccines: modes of immune activation and future challenges. *Nat Rev Immunol* 2021; **21**: 195–97.



## Adult-onset Still's disease after mRNA COVID-19 vaccine

Published Online  
July 22, 2021  
[https://doi.org/10.1016/S2665-9913\(21\)00219-8](https://doi.org/10.1016/S2665-9913(21)00219-8)

We report a case of severe adult-onset Still's disease (AOSD) presenting in a patient after receiving the mRNA-1273 COVID-19 vaccine (Moderna). A 45-year-old healthy woman developed a sore throat, intermittent headache, and fever of 38.3°C at 5 days after the second dose of the vaccine, approximately one month after the first dose. Over the next few days, she continued to have persistent daily fevers of up to 40°C despite consistent use of acetaminophen and nonsteroidal anti-inflammatory drugs. She subsequently developed severely debilitating myalgias, arthralgias, and pleurisy that ultimately prompted her to seek medical attention.

On admission to hospital, she had daily fevers of  $\geq 39^{\circ}\text{C}$  and developed acute hypoxic respiratory failure requiring a 100% non-rebreather mask. Initial laboratory testing was notable for a leukocytosis, elevated erythrocyte sedimentation rate (85 mm/h; reference range 0–20 mm/h), C-reactive protein, and ferritin concentration (table). Cardiac biomarkers were increased, including troponin I to 0.35 ng/mL (reference range 0.00–0.04 ng/mL) and NT-proBNP to 1815 pg/mL (reference range 0–125 pg/mL). Imaging studies were notable for diffuse bilateral infiltrates on chest x-ray, no pulmonary embolus on chest CT scan, and left supraclavicular lymphadenopathy on neck CT and MRI.