

Multiple brain abscesses and ventriculitis secondary to chronic periodontitis

Torbjørn Østvik Pedersen¹  | Jostein Kråkenes² | Sigbjørn Løes^{1,3}

¹Department of Maxillofacial Surgery, Haukeland University Hospital, Bergen, Norway

²Department of Radiology, Haukeland University Hospital, Bergen, Norway

³Faculty of Medicine, University of Bergen, Bergen, Norway

Correspondence

Torbjørn Østvik Pedersen, Department of Maxillofacial Surgery, Haukeland University Hospital, Jonas Lies vei 65, 5021 Bergen, Norway.
Email: Torbjorn.Pedersen@uib.no

Abstract

Chronic marginal periodontitis is a common oral disease, but can in rare cases cause severe intracranial infection. This case illustrates that poor dental status can be life threatening, in particular for immunocompromised patients.

KEYWORDS

Intracranial infection, oral infection, periodontitis

A 60-year-old man was admitted with suspected bacterial meningitis. His medical history included alcohol abuse and chronic hepatitis C, but no immunosuppressive agents. MRI revealed multiple small intracerebral abscesses and ventriculitis (Figure 1). Growth of *Candida albicans*, *actinomyces*

or, *streptococcus mitis/oralis*, and *actinomyces odontolyticus* was found in CSF culture. Further, 16s rDNA PCR from CSF was positive for bacterial gene material from the primary pathogens of chronic marginal periodontitis *parvimonas micra*, *porphyromonas gingivalis*, and *fusobacterium*

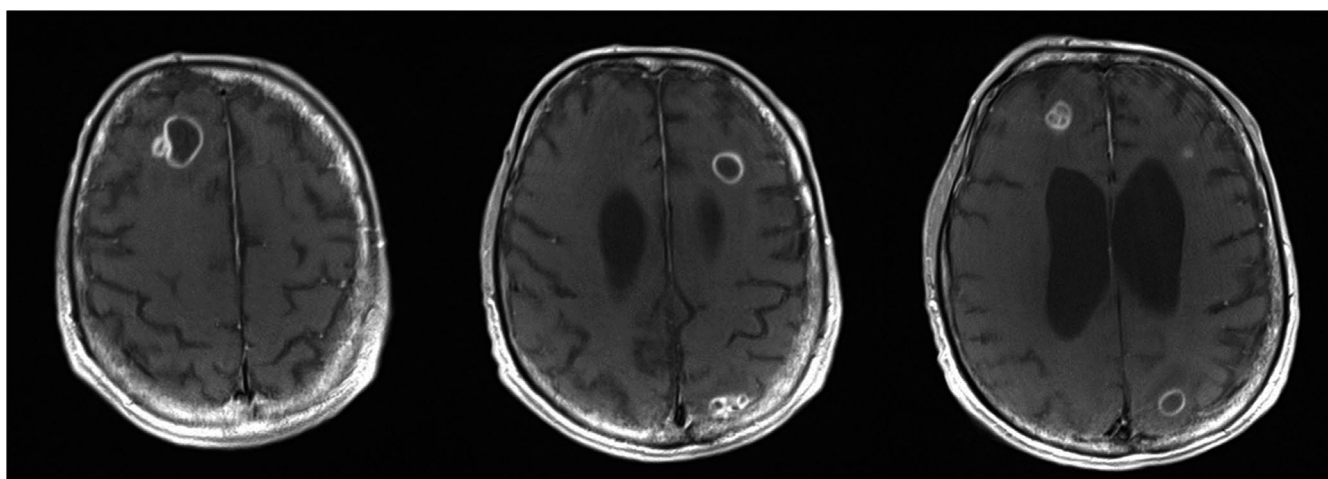


FIGURE 1 Contrast enhanced T1-weighted MRI showing multiple brain abscesses of different size

This is an open access article under the terms of the Creative Commons Attribution-NonCommercial-NoDerivs License, which permits use and distribution in any medium, provided the original work is properly cited, the use is non-commercial and no modifications or adaptations are made.

© 2020 The Authors. *Clinical Case Reports* published by John Wiley & Sons Ltd.

nucleatum.¹ Targeted antimicrobial treatment was initiated with ceftriaxone, metronidazole, and fluconazole. The patient had poor dental status, and teeth with clinical and radiological signs of chronic infection were removed. Surgical intervention intracranially was carefully considered, but not performed due to the localization of abscesses and risk of complications. Some reduction in the size of the abscesses was noted the following weeks, but with persistent ventriculitis. There was a rapid deterioration in mental status, and targeted treatment was discontinued after 2 months. The patient died shortly after.

ACKNOWLEDGMENTS

None.

CONFLICT OF INTEREST

None declared.

AUTHOR CONTRIBUTIONS

TØP: involved in clinical assessment and treatment of the patient, and drafting the manuscript. JK: involved in radiological assessment and diagnosis, critical revision of the

manuscript, and approval of the final version. SL: involved in clinical assessment of the patient, critical revision of the manuscript, and approval of the final version.

ETHICAL APPROVAL

Consent from the next of kin was considered sufficient, and additional ethical approval was not required.

ORCID

Torbjørn Østvik Pedersen  <https://orcid.org/0000-0001-9463-3076>

REFERENCE

1. Ezzo PJ, Cutler CW. Microorganisms as risk indicators for periodontal disease. *Periodontol.* 2000;2003(32):24-35.

How to cite this article: Pedersen TØ, Kråkenes J, Løes S. Multiple brain abscesses and ventriculitis secondary to chronic periodontitis. *Clin Case Rep.* 2020;8:3611–3612. <https://doi.org/10.1002/ccr3.3349>