



# Cerebral Venous Thrombosis and Hyperthyroidism

Knudsen-Baas KM<sup>1\*</sup>, Kråkenes J<sup>2</sup>, Thordarson HB<sup>3</sup>, Sjo M<sup>4</sup> and Waje-Andreassen U<sup>1</sup><sup>1</sup>Department of Neurology, Haukeland University Hospital, Bergen, Norway<sup>2</sup>Department of Radiology, Section of Neuroradiology, Haukeland University Hospital, Norway<sup>3</sup>Department of Medicine, Section of Endocrinology, Haukeland University Hospital, Norway<sup>4</sup>Department of Medicine, Section of Hematology, Haukeland University Hospital, Norway

## Abstract

Cerebral venous thrombosis (CVT) is mostly caused by pro-thrombotic factors. Hyperthyroidism is not a well-known risk factor. We present a case report on a 17 year old girl who developed life-threatening CVT after Graves' disease. A review of the literature reveals further 34 cases of CVT and hyperthyroidism. Abnormalities in the coagulation system leading to hypercoagulability such as increased coagulation factors are detected in patients with hyperthyroidism, and these abnormalities seem to be thyroxin-dependent. The cause of CVT may be multi-factorial. Our patient used oral hormonal contraception without complications until the development of severe Graves' disease. Hyperthyroidism is suspected as the main precipitating cause of CVT in this case. We recommend performing MRI with venous angiography when a hyperthyroid patient presents with unusual headache alone or in combination with other neurological symptoms. If CVT is proven, blood screening for coagulation abnormalities should be performed. On the other hand, diagnostics for finding the cause of CVT should include blood tests of thyroid function. Early treatment of CVT and hyperthyroidism is mandatory.

## Introduction

Cerebral venous thrombosis (CVT) represents only about 0.5-1 % of all strokes [1]. The incidence is estimated to be 2-4 per million per year, but the number is probably higher due to undiagnosed cases [1,2]. CVT occurs most often in the 3<sup>rd</sup> decade of life and then affects mostly women, but among children and elderly patients there is no difference concerning sexes [1].

CVT has the best prognosis at a young age without severe neurological deficits, such as hemiparesis, epileptic seizures and coma, or other co-morbidity such as cancer and serious infection [3]. A prospective multi-center study showed that 75% of patients with CVT were women with a mean age of 34 years and the best prognosis was found for women with risk factors like hormonal contraception, pregnancy and maternity [4].

Pro-thrombotic causes are found in about 85% of patients with CVT and include hormonal, genetic and acquired hematologic, inflammatory or immunologic causes, infections, cancer and other specific causes while about 15% are considered to be idiopathic [5].

Symptoms of CVT are usually increasing headache, blurred vision and acute focal neurological disturbances of function, such as paresis and focal seizures. Magnetic resonance imaging (MRI) with venous angiography is the gold standard for the diagnosis of CVT and is superior to computer tomography (CT), which is found negative in 10-30% [6].

Symptoms of Graves' disease are goiter, exophthalmos and ophthalmopathy (staring eyes) and skin changes, such as pre-tibial myxedema with thickened, orange-skin similar areas which are itching or hyper pigmented. Muscle weakness, weight changes, tremor, perspiration, nervousness, irritability, intolerance to heat, tachycardia and atrial fibrillation are symptoms that may occur due to Graves' disease or other hyperthyroidism [7].

Hyperthyroidism is not a well-known risk factor for CVT. Our case report is a young woman who developed life-threatening CVT after Graves' disease. We have further reviewed the literature concerning CVT and hyperthyroidism.

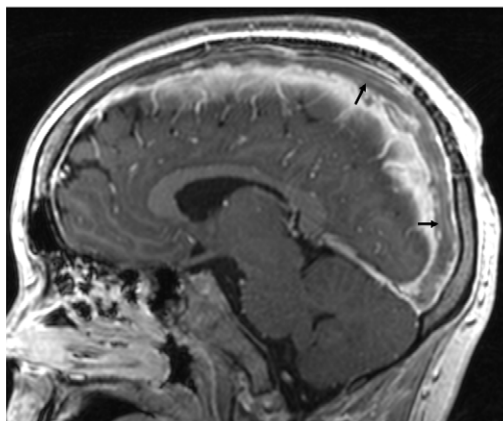
A 17 year old girl, non-smoker, had used the hormonal contraception Mercilon (150 µg desogestrel and 20 µg etinylestradiol) for two years without any medical problems. After several weeks of irritability, tiredness, weight-gain, intolerance to heat, slight diarrhea, development of goiter and itching pre-tibial myxedema, Graves' disease was diagnosed with free thyroxin (fT4)83.9 pmol/l (reference 12.6-21.0), TSH <0.01 mU/l (reference 0.51-4.3) and thyroid-receptor antibodies >40 IU/l (reference <1.5). After start of treatment with carbimazole she was discharged from the hospital, but on the same day she developed right occipital headache, pain in the neck and nausea. Four days later, she had a transient hemiparesis and focal seizures in her left hand. On the fifth day she was admitted to our department after recurrent and persisting left hemiparesis and lost consciousness due to generalized seizures. Her pupils were dilated, not reacting to light and Glasgow Coma Scale score at admittance was 3 points. She was intubated and propofol-narcosis was started due to no response to diazepam. MRI showed extensive thrombosis in the sagittal sinus, the right transversus sinus, the sigmoid sinus and the proximal right jugular vein (Figures 1 and 2) with venous infarction (Figure 3) in the right parietal region. Two minor bleedings were present in the right temporal lobe because of stasis (Figure 4). The left sinus transversus was atretic. She was treated with dalteparin, adjusted after anti-factor-X a measurements in plasma, four hours after the last injection with the level-aim between 0.6-1.0 IU/ml (reference 0.00-0.01). She slightly recovered over weeks, but developed significant bilateral exophthalmos. Anti-thrombin,

\*Corresponding author: Kristin Marie Knudsen-Baas, Department of Neurology, Haukeland University Hospital, Jonas Lies Vei 65, N-5053 Bergen, Norway, Tel: +47 97564429; Fax: +47 55975164; E-mail: [kristin.marie.knudsen-baas@helse-bergen.no](mailto:kristin.marie.knudsen-baas@helse-bergen.no)

Received November 25, 2013; Accepted January 07, 2014; Published January 16, 2014

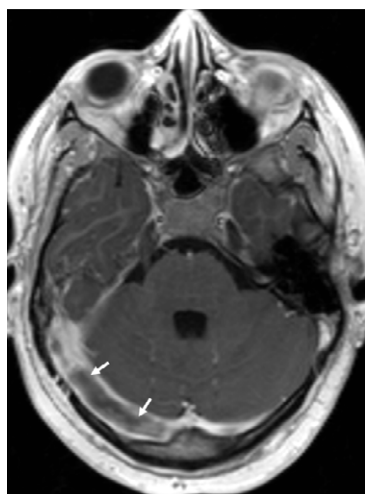
Citation: Knudsen-Baas KM, Kråkenes J, Thordarson HB, Sjo M, Waje-Andreassen U (2014) Cerebral Venous Thrombosis and Hyperthyroidism. Intern Med 4: 136. doi:10.4172/2165-8048.1000136

Copyright: © 2014 Knudsen-Baas KM, et al. This is an open-access article distributed under the terms of the Creative Commons Attribution License, which permits unrestricted use, distribution, and reproduction in any medium, provided the original author and source are credited.



Time of repetition (TR), Time of echo (TE), measured in milliseconds (ms)

**Figure 1:** T1-weighted 3D-volume imaging with contrast (slide thickness 1.1 mm, TR 2020 ms, TE 3.93 ms) shows filling defects consistent with thrombosis in the superior sagittal sinus and in the right transverse sinus (arrows).



**Figure 2:** T1-weighted 3D-volume imaging with contrast (slide thickness 1.1 mm, TR 2020 ms, TE 3.93 ms) shows filling defects consistent with thrombosis in the superior sagittal sinus and in the right transverse sinus (arrows).

protein-C, protein-S, Factor V Leiden mutation and pro-thrombin G20210A polymorphism were normal. The methylenetetrahydrofolat reductase (MTHFR) gene was heterozygote.

After two months, the NIHSS score was 0 and the patient continued her education as planned. After six months, anti-epileptic treatment was already discontinued and control MRI-angiography showed recanalization. Anticoagulation was discontinued. After eight months, thyroidectomy was performed due to non-optimal controlled Graves' disease by medical treatment alone. She was also operated for bilateral exophthalmos. The patient has given written consent for publishing her case and the images.

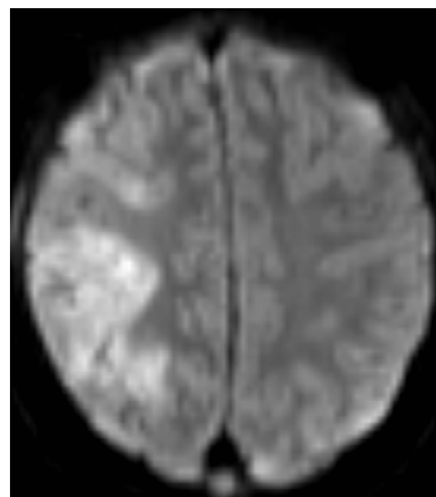
### Review of the Literature

In addition to our patient, we found 34 other cases of CVT and hyperthyroidism (Table 1). The mean age is 32 years. The youngest patient was an eight year old girl and the oldest patient a 60 year old man. Five of the 35 patients were older than 40 years and 22 patients

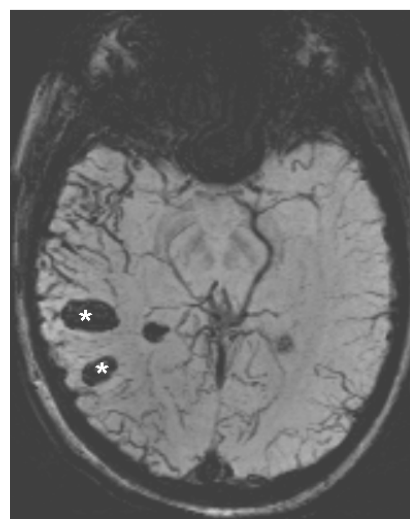
were women. Graves' disease was present among 21 of the 35 patients and 17 of these were women.

### Discussion

The predominance of women and young age are compatible with results of other studies of CVT [3] and earlier review articles about CVT and hyperthyroidism [30,36]. The prevalence of CVT is 1,7% for thyroid morbidity, 34,1% for pro-thrombotic conditions (anti-thrombin III deficiency, protein-S- or protein-C deficiency, anti-phospholipid syndrome, activated protein-C resistance, factor V Leiden mutation, pro-thrombin G20210A mutation) and 53,3% for use of oral hormonal contraception [37]. However, as the overview is only listing case studies, it is not possible to draw conclusions about frequency of coagulation deficiencies, infections or the use of oral contraception as blood samples were not standardized screened and cases were not standardized reported.



**Figure 3:** Diffusion Weighted Imaging (b1000) (slide thickness 5 mm, TR 3200 ms, TE 94 ms) shows venous infarction in the right parietal lobe.



**Figure 4:** Susceptibility Weighted Imaging (SWI) (slide thickness 2 mm, TR 50 ms, TE 40 ms) shows hemorrhagic lesions in the right temporal lobe (asterisks) and accented vein drawings due to stasis.

First author, published year (reference)	Age/ M=male F=female	Type of hyperthyroidism	Coagulation deficiency and other risk factors
Schutta, 1991 [8]	34/M	Thyrotoxicosis	Plasminogen deficiency, thrombocytosis, chronic inflammatory lung disease
Siegert, 1995 [9]	24/M 32/F	Graves` disease (GD) GD	None mentioned 4 months after giving birth
Silburn, 1996 [10]	18/F	GD	None mentioned
Dulli, 1996 [11]	32/F	Thyrotoxicosis	Active protein C--resistance (APC-R)
De Schryver, 1999 [12]	32/M	Thyrotoxicosis	Protein C deficiency, positive Lupus anticoagulant
Verberne, 2000 [13]	28 /F	GD	Increased factor VIII
Dai, 2000 [14]	39 /M	Hyperthyroidism	None mentioned
Longe, 2000 [15]	18 / M 38 /M	Hyperthyroidism GD	None mentioned
Ra, 2001 [16]	60 /M	GD	Protein C deficiency, increased fibrinogen
Maes, 2002 [17]	39 /F	GD	Increased factor VIII
Molloy, 2003 [18]	28 /F	GD	Heterozygous factor V Leiden mutation
Colleran, 2003 [19]	37/F	GD	None mentioned
Madronero-Vuelta, 2004 [20]	42 /F	De Quervains thyroiditis	Heterozygous pro-thrombin G20210A mutation
Karouache, 2004 [21]	38 / F	GD	None mentioned
	44 / F	GD	
Mouton, 2005 [22]	32 / F	Postpartum thyroiditis	Increased factor VIII
	49 / F	GD	Increased factor VIII,APC-R
	50 / F	GD	Increased factor VIII
	38 /F	GD	Increased factor VIII
Kasuga, 2006 [23]	39 /M	Hyperthyroidism	Increased factor VIII
Roch, 2006 [24]	25 / F	GD	Increased factor VIII
Nagumo, 2007 [25]	28 /F	GD	Protein C deficiency
Kim, 2008 [26]	23 /F	GD/ thyrotoxicosis	Increased factor VIII
Pekdemir, 2008 [27]	28 /M	Hyperthyroidism	None mentioned
Strada, 2008 [28]	29 /M	Thyrotoxicosis	Elevated homocysteine, homozygous MTHFR C677T gene
Usami, 2009 [29]	34 /F	Thyrotoxicosis	Gastroenteritis and dehydration, increased factor VIII, protein C deficiency, anti-phospholipid antibodies positive
Bensalah, 2011 [30]	23 /M	GD	None mentioned
Hermans, 2011 [31]	22 /F	GD	None mentioned
Van Eimeren, 2012 [32]	8 /F	Hyperthyroidism	Heterozygous factor V Leiden mutation
Knudsen-Baas, 2012	17 /F	GD	Heterozygous MTHFR gene
Hwang, 2012 [33]	31/M	Hyperthyroidism	Increased factor IX and XI
Merino, 2012 [34]	30/M	Hyperthyroidism	Increased factor VIII and von Willebrand factor Ag
Migeot, 2013 [35]	26/F	GD	Post-partum, increased factor VIII

Table 1: Overview of published cases from 1991 to 2013 of patients with cerebral venous thrombosis and hyperthyroidism.

## Hyperthyroidism and the coagulation system

Several studies of patients with hyperthyroidism have shown increased incidence of venous thromboembolic events [38], such as pulmonary embolism [39] and deep venous thrombosis [40]. Increased level of fT4 is associated with increased synthesis and secretion of factor VIII [40]. Abnormalities in the coagulation system, such as increased fibrinogen, von Willebrand factor (vWF), Plasminogen activator inhibitor 1 (PAI-1), coagulation factors VIII, IX and X and shorter activated partial thromboplastin time (APTT) have been found in hyperthyroid patients compared with euthyroid controls [41]. In a follow-up study, healthy volunteers were given levothyroxin and it was proved increased levels of fibrinogen, vWF, PAI-1 and coagulation factors VIII, IX and X [42]. These findings indicate that hypercoagulability and decreased fibrinolysis in hyperthyroidism is thyroxin-dependent.

A case study that supports the hypothesis of hypercoagulability reported death from CVT caused by thyroid crisis [25]. Another patient, also with life-threatening CVT and thyroid crisis, was treated with plasmapheresis which led to rapid reduction of fT3 and fT4 and

removal of anti-phospholipid antibodies, with significant clinical improvement and normalization of factor VIII and vWF [29].

## Other risk factors for CVT?

Our patient had heterozygous metylenetetrahydrofolat reductase (MTHFR) gene. MTHFR mutation gene defects may lead to hyperhomocysteinemia. The prevalence of MTHFR mutations is found to be 14% but is only of clinical relevance when the gene is homozygote and homocysteine is elevated [43]. The heterozygous MTHFR gene was not regarded as a risk factor in our patient. One of the 35 patients in our overview had homozygous MTHFR gene and hyperhomocysteinemia [28].

Mechanical compression of veins from goiter has been mentioned [44] and a case study reports compression of truncus brachiocephalicus from goiter [45]. However, this was not suspected in our patient. It is not suspected that carbimazole increases the risk of venous thromboembolism [46].

Our patient had no problems tolerating a combination of desogestrel and ethinylestradiol before the development of Graves' disease. Some

of the other cases in the literature with hyperthyroidism and CVT were certainly not caused by hormonal contraception as twelve patients were men and one of the females was eight years old. A Danish cohort study of more than 1.6 million women found low risks of thrombotic stroke and myocardial infarction with hormonal contraception, although there were slight differences concerning components and dosages [47]. It is possible that use of hormonal contraceptive contributed to the CVT in our patient, but we suspect Graves' disease as the main cause.

## Conclusions

The cause of CVT may be multi-factorial. A review of the literature shows several cases of CVT due to hyperthyroidism. Studies indicate that a high thyroxin level causes a hypercoagulable condition. We suspect severe Graves' disease as the main precipitating cause of life-threatening CVT in a 17 year old girl with previously uncomplicated use of hormonal contraception. CVT should be suspected and MRI with venous angiography be performed when unusual headache alone or in combination with neurological deficits occurs in patients with hyperthyroidism. In case of CVT, blood screening for coagulation abnormalities is indicated. On the other hand, hyperthyroidism should be suspected in young patients with CVT. CVT and hyperthyroidism must be treated as soon as possible.

## References

1. Einhäupl K, Stam J, Bousser MG, De Bruijn SF, Ferro JM, et al. (2010) EFNS guideline on the treatment of cerebral venous and sinus thrombosis in adult patients. *Eur J Neurol* 17: 1229-1235.
2. Coutinho JM, Stam J (2010) How to treat cerebral venous and sinus thrombosis. *J Thromb Haemost* 8: 877-883.
3. Ferro JM, Canhão P, Stam J, Bousser MG, Barinagarrementeria F, et al. (2004) Prognosis of cerebral vein and dural sinus thrombosis: results of the International Study on Cerebral Vein and Dural Sinus Thrombosis (ISCVT). *Stroke* 35: 664-670.
4. Coutinho JM, Ferro JM, Canhão P, Barinagarrementeria F, Cantú C, et al. (2009) Cerebral venous and sinus thrombosis in women. *Stroke* 40: 2356-2361.
5. Stam J (2005) Thrombosis of the cerebral veins and sinuses. *N Engl J Med* 352: 1791-1798.
6. Rizzo L, Crasto SG, Rudà R, Gallo G, Tola E, et al. (2010) Cerebral venous thrombosis: role of CT, MRI and MRA in the emergency setting. *Radiol Med* 115: 313-325.
7. Dan Longo, Anthony Fauci, Dennis Kasper, Stephen Hauser, Jameson J, et al. (2011) *Harrison's Principles of Internal Medicine*. (18<sup>th</sup> edn) McGraw Hill Professional, New York, USA.
8. Schutta HS, Williams EC, Baranski BG, Sutula TP (1991) Cerebral venous thrombosis with plasminogen deficiency. *Stroke* 22: 401-405.
9. Siegert CE, Smelt AH, de Bruin TW (1995) Superior sagittal sinus thrombosis and thyrotoxicosis. Possible association in two cases. *Stroke* 26: 496-497.
10. Silburn PA, Sandstrom PA, Staples C, Mowat P, Boyle RS (1996) Deep cerebral venous thrombosis presenting as an encephalitic illness. *Postgrad Med J* 72: 355-357.
11. Dulli DA, Luzzio CC, Williams EC, Schutta HS (1996) Cerebral venous thrombosis and activated protein C resistance. *Stroke* 27: 1731-1733.
12. De Schryver EL, Hoogenraad TU, Banga JD, Kappelle LJ (1999) Thyrotoxicosis, protein C deficiency and lupus anticoagulant in a case of cerebral sinus thrombosis. *Neth J Med* 55: 201-202.
13. Verberne HJ, Fliers E, Prummel MF, Stam J, Brandjes DP, et al. (2000) Thyrotoxicosis as a predisposing factor for cerebral venous thrombosis. *Thyroid* 10: 607-610.
14. Dai A, Wasay M, Dubey N, Giglio P, Bakshi R (2000) Superior sagittal sinus thrombosis secondary to hyperthyroidism. *J Stroke Cerebrovasc Dis* 9: 89-90.
15. Longe AC, Farooqui KM, Ayed A, Al-Gozi A, Al Humaidi MA (2000) Cerebral venous thrombosis associated with thyrotoxicosis: report of two cases. *Ann Saudi Med* 20: 29-31.
16. Ra CS, Lui CC, Liang CL, Chen HJ, Kuo YL, et al. (2001) Superior sagittal sinus thrombosis induced by thyrotoxicosis. Case report. *J Neurosurg* 94: 130-132.
17. Maes J, Michotte A, Velkeniers B, Stadnik T, Jochmans K (2002) Hyperthyroidism with increased factor VIII procoagulant protein as a predisposing factor for cerebral venous thrombosis. *J Neurol Neurosurg Psychiatry* 73: 458.
18. Molloy E, Cahill M, O'Hare JA (2003) Cerebral venous sinus thrombosis precipitated by Graves' disease and Factor V Leiden mutation. *Ir Med J* 96: 46-47.
19. Colleran KM, Ratliff DM, Burge MR (2003) Potential association of thyrotoxicosis with vitamin B and folate deficiencies, resulting in risk for hyperhomocysteinemia and subsequent thromboembolic events. *Endocr Pract* 9: 290-295.
20. Madroñero-Vuelta AB, Sanahuja-Montesinos J, Bergua-Llop M, Araguás-Arasanz C (2004) [Cerebral venous thrombosis associated to subacute De Quervain's thyroiditis in a carrier for the G20210A mutation of the prothrombin gene]. *Rev Neurol* 39: 533-535.
21. Karouache A, Mounach J, Bouraza A, Ouahabi H, Reda R, et al. (2004) [Cerebral thrombophlebitis revealing hyperthyroidism: two cases report and literature review]. *Rev Med Interne* 25: 920-923.
22. Mouton S, Nighoghossian N, Berruyer M, Derex L, Philippeau F, et al. (2005) Hyperthyroidism and cerebral venous thrombosis. *Eur Neurol* 54: 78-80.
23. Kasuga K, Naruse S, Umeda M, Tanaka M, Fujita N (2006) [Case of cerebral venous thrombosis due to graves' disease with increased factor VIII activity]. *Rinsho Shinkeigaku* 46: 270-273.
24. Roch N, Payet B, Duffour JF, Amaranto P, Chaumentin G (2006) Thrombophlébite cérébrale et hyperthyroïdie. *La Revue de Médecine Interne* 27: S370.
25. Nagumo K, Fukushima T, Takahashi H, Sakakibara Y, Kojima S, et al. (2007) [Thyroid crisis and protein C deficiency in a case of superior sagittal sinus thrombosis]. *Brain Nerve* 59: 271-276.
26. Kim DD, Young S, Chunilal S, Cutfield R (2008) Possible association of venous thromboembolism and hyperthyroidism: 4 case reports and literature review. *N Z Med J* 121: 53-57.
27. Pekdemir M, Yilmaz S, Ersel M, Sarisooy HT (2008) A rare cause of headache: cerebral venous sinus thrombosis due to hyperthyroidism. *Am J Emerg Med* 26: 383.
28. Strada L, Gandolfo C, Del Sette M (2008) Cerebral sinus venous thrombosis in a subject with thyrotoxicosis and MTHFR gene polymorphism. *Neurol Sci* 29: 343-345.
29. Usami K, Kinoshita T, Tokumoto K, Ino T, Ozawa K, et al. (2009) Successful treatment of plasma exchange for severe cerebral venous thrombosis with thyrotoxicosis. *J Stroke Cerebrovasc Dis* 18: 239-243.
30. Bensalah M, Squizzato A, Ould Kablia S, Menia H, Kemali Z (2011) Cerebral vein and sinus thrombosis and hyperthyroidism: a case report and a systematic review of the literature. *Thromb Res* 128: 98-100.
31. Hermans E, Mariën P, De Deyn PP (2011) Sinus sigmoideus thrombosis secondary to graves' disease: a case description. *Case Rep Neurol* 3: 203-209.
32. van Eimeren VF, Billingham L, Askalan R, Laughlin S, Brandão LR, et al. (2012) Cerebral sinus venous thrombosis in a child with hyperthyroidism. *Pediatr Blood Cancer* 58: 107-108.
33. Hwang JU, Kwon KY, Hur JW, Lee JW, Lee HK (2012) The role of hyperthyroidism as the predisposing factor for superior sagittal sinus thrombosis. *J Cerebrovasc Endovasc Neurosurg* 14: 251-254.
34. Merino M, Guizarro MG, Iglesias P, Aladro Y, Montero P (2012) [Thyrotoxicosis and cerebral venous sinus thrombosis, causality or chance alone?]. *Endocrinol Nutr* 59: 462-463.
35. Migeot M, Rutgers MP, Gille M (2013) Puerperal cerebral sinus venous thrombosis and acute hyperthyroidism in Graves' disease. *Acta Neurol Belg* 113: 331-333.
36. Franchini M, Lippi G, Targher G (2011) Hyperthyroidism and venous thrombosis: a casual or causal association? A systematic literature review. *Clin Appl Thromb Hemost* 17: 387-392.
37. Saposnik G, Barinagarrementeria F, Brown RD Jr, Bushnell CD, Cucchiara

- B, et al. (2011) Diagnosis and management of cerebral venous thrombosis: a statement for healthcare professionals from the American Heart Association/American Stroke Association. *Stroke* 42: 1158-1192.
38. Kootte RS, Stuijver DJ, Dekkers OM, van Zaane B, Fliers E, et al. (2012) The incidence of venous thromboembolism in patients with overt hyperthyroidism: a retrospective multicentre cohort study. *Thromb Haemost* 107: 417-422.
39. Lin HC, Yang LY, Kang JH (2010) Increased risk of pulmonary embolism among patients with hyperthyroidism: a 5-year follow-up study. *J Thromb Haemost* 8: 2176-2181.
40. van Zaane B, Squizzato A, Huijgen R, van Zanten AP, Fliers E, et al. (2010) Increasing levels of free thyroxine as a risk factor for a first venous thrombosis: a case-control study. *Blood* 115: 4344-4349.
41. Franchini M, Lippi G, Manzato F, Vescovi PP, Targher G (2010) Hemostatic abnormalities in endocrine and metabolic disorders. *Eur J Endocrinol* 162: 439-451.
42. Van Zaane B, Squizzato A, Debeij J, Dekkers OM, Meijers JC, et al. (2011) Alterations in coagulation and fibrinolysis after levothyroxine exposure in healthy volunteers: a controlled randomized crossover study. *J Thromb Haemost* 9: 1816-1824.
43. McBane RD 2nd, Tafur A, Wysokinski WE (2010) Acquired and congenital risk factors associated with cerebral venous sinus thrombosis. *Thromb Res* 126: 81-87.
44. Squizzato A, Gerdes VE, Brandjes DP, Büller HR, Stam J (2005) Thyroid diseases and cerebrovascular disease. *Stroke* 36: 2302-2310.
45. Silvestri R, De Domenico P, Raffaele M, Lombardo N, Casella C, et al. (1990) Vascular compression from goiter as an unusual cause of cerebrovascular accident. *Ital J Neurol Sci* 11: 307-308.
46. Statens legemiddelverk. Karbimazol 2011.
47. Lidegaard Ø, Løkkegaard E, Jensen A, Skovlund CW, Keiding N (2012) Thrombotic stroke and myocardial infarction with hormonal contraception. *N Engl J Med* 366: 2257-2266.

**Citation:** Knudsen-Baas KM, Kråkenes J, Thordarson HB, Sjo M, Waje-Andreassen U (2014) Cerebral Venous Thrombosis and Hyperthyroidism. Intern Med 4: 136. doi:[10.4172/2165-8048.1000136](https://doi.org/10.4172/2165-8048.1000136)

### Submit your next manuscript and get advantages of OMICS Group submissions

#### Unique features:

User friendly/feasible website-translation of your paper to 50 world's leading languages  
Audio Version of published paper  
Digital articles to share and explore

#### Special features:

300 Open Access Journals  
25,000 editorial team  
21 days rapid review process  
Quality and quick editorial, review and publication processing  
Indexing at PubMed (partial), Scopus, EBSCO, Index Copernicus and Google Scholar etc  
Sharing Option: Social Networking Enabled  
Authors, Reviewers and Editors rewarded with online Scientific Credits  
Better discount for your subsequent articles

Submit your manuscript at: <http://www.omicsonline.org/submission>

