

This is a provisional PDF only. Copyedited and fully formatted version will be made available soon.



P O L I S H G Y N E C O L O G Y

GINEKOLOGIA POLSKA

ORGAN POLSKIEGO TOWARZYSTWA GINEKOLOGICZNEGO
THE OFFICIAL JOURNAL OF THE POLISH GYNECOLOGICAL SOCIETY

ISSN: 0017-0011

e-ISSN: 2543-6767

Remission of HPV infection after LEEP-conization — a retrospective study

Authors: Marcin Przybylski, Dominik Pruski, Sonja Millert-Kalinska, Andrzej Zmaczynski, Rafal Baran, Anna Horbaczewska, Robert Jach, Lucja Zaborowska

DOI: 10.5603/GP.a2021.0164

Article type: Research paper

Submitted: 2021-06-14

Accepted: 2021-07-20

Published online: 2021-09-24

This article has been peer reviewed and published immediately upon acceptance. It is an open access article, which means that it can be downloaded, printed, and distributed freely, provided the work is properly cited.

Articles in "Ginekologia Polska" are listed in PubMed.

ORIGINAL PAPER / GYNECOLOGY

Remission of HPV infection after LEEP-conization — a retrospective study

Marcin Przybylski¹, Dominik Pruski¹, Sonja Millert-Kalinska¹, Andrzej Zmaczynski², Rafal Baran², Anna Horbaczewska², Robert Jach², Lucja Zaborowska²

¹*Department of Obstetrics and Gynecology, District Public Hospital in Poznan, Poland*

²*Department of Gynaecological Endocrinology, Jagiellonian University Medical College, Cracow, Poland*

Corresponding author:

Lucja Zaborowska

Department of Gynaecological Endocrinology, Jagiellonian University Medical College, Cracow, Poland

e-mail: zaborowska.lucja@gmail.com

ABSTRACT

Objectives: Human papillomavirus (HPV) infection is one of the most common sexually transmitted diseases. Long-term exposure to the HPV is a known cause of squamous intraepithelial lesions that consequently lead to cervical cancer development. The loop electrosurgical excision procedure (LEEP) conization is an established early cervical cancer treatment method. We aim to assess the remission of HPV infection after LEEP in non-vaccinated patients with pre-cancerous cervical lesions and establish the efficacy of cervical cancer prophylaxis.

Material and methods: We analyzed 31 LEEP conizations performed due to low and high-grade squamous intraepithelial lesions in 2019–2020. We obtained molecular test samples and detected DNA of 37 different HPV genotypes. After a six-month follow-up, each patient underwent subsequent high-risk HPV testing and genotyping.

Results: We observed that 54.8% of qualified patients were infected with HPV 16. We discovered complete viral remission in 64.5% of cases. After surgery, margins were negative in 71% of the patient's samples. During the follow-up, six patients got infected with new strains of HPV.

Conclusions: We found that a correctly performed LEEP conization may contribute to the remission of persistent HPV infection; a more extended follow-up period might be recommended due to a high rate of post-surgery HPV infections.

Key words: cervical cancer; loop electrosurgical excision procedure; LEEP; HPV

INTRODUCTION

Cervical cancer remains the fourth most frequent cancer in women worldwide [1] despite the fact that this disease is theoretically wholly preventable. Persistent infection with high-risk human papillomavirus is the direct cause of the majority of cervical intraepithelial neoplasia (CIN) and invasive cervical cancers. Vaccination against HPV prevents infections with specific HPV types and, consequently, the development of cervical cancer caused by the virus's specific strains [2–4]. We have been observing a decrease in cervical cancer incidence for several decades thanks to these preventive measures and screening.

Doctors and scientists have been searching years for diagnostic tools which show the highest sensitivity, specificity, and patients' acceptance and allow to detect the disease at its earliest stage possible. These tools might be particularly useful in countries where cervical cancer incidence is still much higher than the world's average. An example of such a method is the optoelectronic method using a Truscreen. The procedure was convenient and had great potential for future use, especially in countries with limited access to colposcopy. However, despite this method's acceptable specificity, its sensitivity was significantly worse when compared to standard colposcopy and the HPV DNA test [5].

Early treatment of squamous intraepithelial lesions (SIL), especially high-grade (HSIL) is considered the most crucial method of preventing cervical cancer. Cold knife conization, loop electrical excision procedure (LEEP), and large loop excision of the transformation zone (LLETZ) find themselves among other established treatment procedures

According to the Updated Consensus Guidelines for the *Management of Abnormal Cervical Cancer Screening Tests and Cancer Precursors*, both ablation and excision effectively treat CIN. Randomized trials comparing different modalities show similar efficacy, ranging from 90% to 95% [6]. High-grade post-treatment disease may occur even in 18% of patients [7]; most recurrences are observed within two years post-treatment [8].

Previous studies reported that the incomplete excision of the endocervical cone margin during LEEP was a significant predictor for either persistence or recurrence of cervical intraepithelial neoplasia during follow-up [9, 10]. That is why the prolonged, careful

observation of patients after surgical treatment may offer a significant chance to improve their future prognosis. However, no recommendation specifies both time and methods of subsequent follow-up. When considering other procedures, HPV testing may offer adequate sensitivity for predicting recurrence, while HPV genotyping seems helpful in increasing the post-treatment predictive value [11].

The study aimed to assess the molecular remission of HPV infection in patients after LEEP — conization who refused to be vaccinated against HPV. We carried out a retrospective study to assess the ability of Pap-smear, HR-HPV testing, and their combination to identify residual or recurrent disease during the patients' follow-up.

MATERIAL AND METHODS

This retrospective study included 31 patients with squamous intraepithelial neoplasia (SIL) treated with LEEP — conization between 2019 and 2020 at Provincial Hospital in Poznań. The LEEP — conization was performed in a total of 160 women; the only inclusion criterion for the study was the lack of consent for HPV vaccination. We obtained samples from all the patients for a Pap-smear and molecular test. The latter detected DNA of 37 different HPV genotypes. After six months of follow-up, each woman underwent subsequent high-risk human papillomavirus testing and genotyping. All patients gave informed consent to participate in the study. The research was approved by the Bioethics Committee of the Medical Chamber of Wielkopolska.

Pap-smear for molecular assessment was collected with the endocervical Cyto-Brush and preserved in PreservCyt® (Hologic Corp.) and SurePath® (BD Diagnostics-TriPath) reserved for the biological samples. The probe was handed over to the independent, standardized laboratory. HPV detection was performed using the PCR method, followed by DNA enzyme immunoassay and genotyping with a reverse hybridization line probe assay. Sequence analysis was performed to characterize HPV — positive samples with unknown HPV genotypes. The molecular test detected DNA of 37 different HPV genotypes.

Each colposcopy was performed by a specialist in gynecologic oncology with 10-year experience in SmartOPTIC colposcope. We performed a test with 5% aqueous solution of acetic acid and Schiller's test with Lugol's iodine in all included cases. The colposcopic images were evaluated according to Reid's Colposcopic Index which assesses the color, lesion boundaries and surface, blood vessels and result of the iodine test. All colposcopic images were archived. We used classification created by The International Federation of Cervical

Pathology and Colposcopy, recommended by the Polish Society of Colposcopy and Cervical Pathophysiology.

The excisions were performed via the colposcope after application of acetic acid 5% and Lugol's iodine. The sizes of the loops were selected according to the size of the lesion. When lesions reached high to the cervix, the lesion was excised deeper. We additionally sampled the lesions' margins. Finally, the curettage of the cervical canal was performed in order to obtain adequate endocervix samples. Between 12 to 16 paraffin blocks were prepared from each cervical specimen; each block was divided and examined in four to five sections.

Histopathological analysis was performed in an independent laboratory by experienced pathologists. The follow-up schedule for all women included cytology and high-risk HPV genotyping at six months.

Calculations were performed using the statistical package of Statistica (ver. 13.1), all graphs were created with Microsoft Excel. Statistical hypotheses were verified at the level of significance of $p < 0.05$. Fisher's exact test was used to analyze the relationship between persistent HPV infection after LEEP - conization and a positive margin. This specific test was chosen due to the expected small number of positive samples. A logistic regression model was used to assess the relationship between age, HPV infection status, parity, and final histological diagnosis.

RESULTS

LEEP-conization procedure

The mean age of women admitted for planned excision was 33 years. The vast majority of patients had less than three children, and more than a half lived in a town or a city with less than 100,000 inhabitants. Table 1 presents descriptive characteristics of the study group. According to the Pap-smear results, one-third of hospitalized women were diagnosed with HSIL, one-third with LSIL, and 20% with atypical squamous cells (unable to exclude HSIL). We compiled all Pap-smear results in Figure 1. In total, 29 of 31 patients (93.5%) were positive for the HPV test before the surgery. In a group of 29 women with positive HPV test results, 17 cases (58.6%) tested positive for genotype 16. All the performed HPV test results and the occurrence of different genotypes are shown in Table 2.

According to the primary Pap-smear, HPV infection status, and colposcopy results, 25 (80.6%) of women were pre-diagnosed with HSIL while five (16.1%) with LSIL. One patient had discrepancies in the results. According to the histopathological material acquired in the study, more than half of women had HSIL lesions, and about 32% of patients had no pathological changes in tested samples. Excised margins were fully clean in 22 women (71%) in both the ectocervix and cervical canal. A negative ectocervix margin was observed in 23 patients (74.2%), while a negative cervical canal margin was found in 30 cases (96.7%). One patient presented a positive margin in the cervical canal despite having a negative margin in the ectocervix samples. Final histopathological results after LEEP-conization are presented in Figure 2.

Follow-up

In the follow-up, we performed both Pap-smear and HPV genotyping tests. Pap-smear results were normal in 30 (96.7%) women. HPV genotyping tests showed viral remission in 20 patients (64.5%), whereas in three cases (9%), the HPV infection was classified as persistent. One-third of negative Pap-smear cases were re-classified to persistent or recurrent HPV infection, based on their positive genotyping results. The persistent HPV infection was observed in three out of eight women with positive margins; however, the majority of these patients showed viral remission. Six patients (19.4%) had recurrent or persistent infection despite having a negative cervical margin. The relationship between the positive margin and persistent infection did not turn out to be statistically significant ($p > 0.05$). Seven patients tested positive for new HPV strains that hadn't been detected before. The occurrence of positive margins and HPV infections after LEEP-conization is presented in Table 3.

There was one Pap-smear positive for cancer cells, although the LEEP-conization results did not confirm the presence of any pathological changes. We also described one case with the preliminary cytological diagnosis of NILM (negative for intraepithelial lesion or malignancy), that was re-classified to HSIL after the performed histopathological examination. We assessed the correlation between age, HPV infection status, parity, and the final histological diagnosis — we found no statistically significant relationships ($p > 0.05$).

DISCUSSION

This study assessed the molecular remission of HPV infection in patients after LEEP-conization who refused vaccination against HPV. Active and effective treatment of HSIL is

the primary approach to control the occurrence and development of cervical cancer. Cervical conization is one of the standardized treatments for HSIL. However, previous studies reported that residual lesions and disease recurrence might occur frequently following this surgical procedure [12]. The positive margins after cervical conization are generally considered to be a risk factor for the recurrence or persistence of SIL [13]. On the other hand, the viral clearance rate at the follow-up after conization is associated with negative excision margins, as confirmed by Cricca et al. [14]. In our study margins appeared to be clean in 22 (71%) women; the relationship between the positive margin and persistent infection did not turn out to be statistically significant. These divergent results might be caused by the insufficient size of the study group.

We also investigated the ability of Pap-smear and HR-HPV testing to identify residual or recurrent disease during the patients' follow-up. Despite the importance of early detection of treatment failure, follow-up after conservative treatment of high-grade CIN has not yet been standardized and varies in terms of timing, intervals, and methods. According to the ASCCP consensus guidelines, acceptable post-treatment management options for women with CIN 2/3 include HPV DNA testing at 6 to 12 months. Follow-up with the use of Pap-smear alone or in combination with colposcopy at six months is also acceptable [21]. Several investigators analyzed the sensitivity and specificity of HPV DNA testing compared with Pap-smear to detect residual or recurrent disease after undergone treatment [22–24]. HPV testing was found to be more sensitive than follow-up cytology, with comparable specificity of both mentioned methods [24, 25]. Women who are HPV-positive after surgery were statistically at higher risk for treatment failure [25, 27].

In research performed by Bruno et al., [26], 182 of 192 (94.7%) patients tested positive for HPV infection before the surgery. One hundred four women (57.1%) tested positive for genotype 16, 78 (42.8%) for other genotypes [26]. Our findings show a similar ratio — 93.5% positive patients to 58.6% — cases positive for HPV 16 genotype. Women with pre-treatment HPV infections had higher incidence of post-treatment HPV presence compared to women who were HPV negative at or before treatment. Women who had been previously treated for cervical disorders may be more prone to develop subsequent cervical intraepithelial lesions or even cervical cancer than women without a history of cervical disease and treatment [16]. Although a substantial proportion of post-treatment dysplasia and cancers may result from an incomplete excision of the lesion, or the persistence of the lesion-associated HPV type, the affected patients are also at risk of developing a second cervical precancerous condition due to the acquisition of newly acquired HPV strains. Data on type-specific HPV infections

associated with a higher probability of cervical disease development after treatment are limited [17–20]. Most studies did not distinguish between recurrent or residual cervical disease, and most of them did not differentiate the newly acquired HPV-related lesions.

A finding beyond this study's scope confirmed that 9 of 31 women (29%) were still infected with HPV after surgical treatment. Interestingly, in seven of these cases the detected genotypes were new and not present in any previous samples. According to a review prepared by Anne F. Rositch et al., [15] most HPV incidence estimates were recorded among women treated for cervical neoplasia using LEEP. Presented data showed that the HPV incidence ranged from 0% to 18% at 2 to 6 months post-treatment and 0% to 24% at 6 to 35 months post-treatment [15]. Our results indicate that the rate of HPV infection after LEEP-conization (29%) is above the mentioned average.

This study's limitations include its retrospective design and the fact that the entire research was conducted in a single medical facility. This fact may reduce the generalizability of our results to a broader geographic area. Further research with a prolonged follow-up period is highly recommended.

CONCLUSIONS

A negative margin from the target lesion and a positive margin from the cervical canal may indicate that the changes may be located deeper, outside of the transformation zone. Therefore, it is important to remember that a simple Pap-smear test may not show the disease's full advancement and should not be treated as the only source of clinical decisions. A more extended period of follow-up might be recommended due to a high rate of post-surgery HPV infections.

REFERENCES

1. WHO Cervical Cancer. <https://www.who.int/health-topics/cervical-cancer> (13.04.2021).
2. Bosch FX, de Sanjosé S. Chapter 1: Human papillomavirus and cervical cancer--burden and assessment of causality. *J Natl Cancer Inst Monogr.* 2003(31): 3–13, doi: [10.1093/oxfordjournals.jncimonographs.a003479](https://doi.org/10.1093/oxfordjournals.jncimonographs.a003479), indexed in Pubmed: [12807939](https://pubmed.ncbi.nlm.nih.gov/12807939/).

3. Bosch FX, Lorincz A, Muñoz N, et al. The causal relation between human papillomavirus and cervical cancer. *J Clin Pathol.* 2002; 55(4): 244–265, doi: [10.1136/jcp.55.4.244](https://doi.org/10.1136/jcp.55.4.244), indexed in Pubmed: [11919208](https://pubmed.ncbi.nlm.nih.gov/11919208/).
4. zur Hausen H. Papillomaviruses causing cancer: evasion from host-cell control in early events in carcinogenesis. *J Natl Cancer Inst.* 2000; 92(9): 690–698, doi: [10.1093/jnci/92.9.690](https://doi.org/10.1093/jnci/92.9.690), indexed in Pubmed: [10793105](https://pubmed.ncbi.nlm.nih.gov/10793105/).
5. Pruski D, Kędzia W, Przybylski M. The assesment of real optoelectronic method in the detection of cervical intraepithelial neoplasia. *Ginekol Pol.* 2008; 79(5): 342–346.
6. Massad LS, Einstein MH, Huh WK, et al. 2012 ASCCP Consensus Guidelines Conference. 2012 updated consensus guidelines for the management of abnormal cervical cancer screening tests and cancer precursors. *Obstet Gynecol.* 2013; 121(4): 829–846, doi: [10.1097/AOG.0b013e3182883a34](https://doi.org/10.1097/AOG.0b013e3182883a34), indexed in Pubmed: [23635684](https://pubmed.ncbi.nlm.nih.gov/23635684/).
7. Ghaem-Maghami S, Sagi S, Majeed G, et al. Incomplete excision of cervical intraepithelial neoplasia and risk of treatment failure: a meta-analysis. *The Lancet Oncology.* 2007; 8(11): 985–993, doi: [10.1016/s1470-2045\(07\)70283-8](https://doi.org/10.1016/s1470-2045(07)70283-8).
8. Paraskevaïdis E, Arbyn M, Sotiriadis A, et al. The role of HPV DNA testing in the follow-up period after treatment for CIN: a systematic review of the literature. *Cancer Treat Rev.* 2004; 30(2): 205–211, doi: [10.1016/j.ctrv.2003.07.008](https://doi.org/10.1016/j.ctrv.2003.07.008), indexed in Pubmed: [15023438](https://pubmed.ncbi.nlm.nih.gov/15023438/).
9. Felix JC, Muderspach LI, Duggan BD. The significance of positive margins in loop electrosurgical cone biopsies. *Obstet Gynecol.* 1994; 84: 996–1000, indexed in Pubmed: [7970484](https://pubmed.ncbi.nlm.nih.gov/7970484/).
10. Brockmeyer AD, Wright JD, Gao F, et al. Persistent and recurrent cervical dysplasia after loop electrosurgical excision procedure. *Am J Obstet Gynecol.* 2005; 192(5): 1379–1381, doi: [10.1016/j.ajog.2004.12.044](https://doi.org/10.1016/j.ajog.2004.12.044), indexed in Pubmed: [15902114](https://pubmed.ncbi.nlm.nih.gov/15902114/).
11. Söderlund-Strand A, Kjellberg L, Dillner J. Human papillomavirus type-specific persistence and recurrence after treatment for cervical dysplasia. *J Med Virol.* 2014; 86(4): 634–641, doi: [10.1002/jmv.23806](https://doi.org/10.1002/jmv.23806), indexed in Pubmed: [24123176](https://pubmed.ncbi.nlm.nih.gov/24123176/).

12. Park JY, Kim DY, Kim JH, et al. Human papillomavirus test after conization in predicting residual disease in subsequent hysterectomy specimens. *Obstet Gynecol.* 2009; 114(1): 87–92, doi: [10.1097/AOG.0b013e3181ab6dca](https://doi.org/10.1097/AOG.0b013e3181ab6dca), indexed in Pubmed: [19546763](https://pubmed.ncbi.nlm.nih.gov/19546763/).
13. Wright TC, Cox JT, Massad LS, et al. 2001 ASCCP-sponsored Consensus Workshop. 2001 Consensus guidelines for the management of women with cervical intraepithelial neoplasia. *J Low Genit Tract Dis.* 2003; 7(3): 154–167, doi: [10.1097/00128360-200307000-00002](https://doi.org/10.1097/00128360-200307000-00002), indexed in Pubmed: [17051063](https://pubmed.ncbi.nlm.nih.gov/17051063/).
14. Cricca M, Venturoli S, Morselli-Labate AM, et al. HPV DNA patterns and disease implications in the follow-up of patients treated for HPV16 high-grade carcinoma in situ. *J Med Virol.* 2006; 78(4): 494–500, doi: [10.1002/jmv.20567](https://doi.org/10.1002/jmv.20567), indexed in Pubmed: [16482538](https://pubmed.ncbi.nlm.nih.gov/16482538/).
15. Rositch AF, Soeters HM, Offutt-Powell TN, et al. The incidence of human papillomavirus infection following treatment for cervical neoplasia: a systematic review. *Gynecol Oncol.* 2014; 132(3): 767–779, doi: [10.1016/j.ygyno.2013.12.040](https://doi.org/10.1016/j.ygyno.2013.12.040), indexed in Pubmed: [24412508](https://pubmed.ncbi.nlm.nih.gov/24412508/).
16. Melnikow J, McGahan C, Sawaya GF, et al. Cervical intraepithelial neoplasia outcomes after treatment: long-term follow-up from the British Columbia Cohort Study. *J Natl Cancer Inst.* 2009; 101(10): 721–728, doi: [10.1093/jnci/djp089](https://doi.org/10.1093/jnci/djp089), indexed in Pubmed: [19436026](https://pubmed.ncbi.nlm.nih.gov/19436026/).
17. Kreimer AR, Schiffman M, Herrero R, et al. Long-term risk of recurrent cervical human papillomavirus infection and precancer and cancer following excisional treatment. *Int J Cancer.* 2012; 131(1): 211–218, doi: [10.1002/ijc.26349](https://doi.org/10.1002/ijc.26349), indexed in Pubmed: [21823117](https://pubmed.ncbi.nlm.nih.gov/21823117/).
18. Kang WD, Oh MJ, Kim SMO, et al. Significance of human papillomavirus genotyping with high-grade cervical intraepithelial neoplasia treated by a loop electrosurgical excision procedure. *Am J Obstet Gynecol.* 2010; 203(1): 72.e1–72.e6, doi: [10.1016/j.ajog.2010.01.063](https://doi.org/10.1016/j.ajog.2010.01.063), indexed in Pubmed: [20417477](https://pubmed.ncbi.nlm.nih.gov/20417477/).

19. Jones J, Saleem A, Rai N, et al. Human Papillomavirus genotype testing combined with cytology as a 'test of cure' post treatment: the importance of a persistent viral infection. *J Clin Virol.* 2011; 52(2): 88–92, doi: [10.1016/j.jcv.2011.06.021](https://doi.org/10.1016/j.jcv.2011.06.021), indexed in Pubmed: [21831706](https://pubmed.ncbi.nlm.nih.gov/21831706/).
20. Ribaldone R, Boldorini R, Capuano A, et al. Role of HPV testing in the follow-up of women treated for cervical dysplasia. *Arch Gynecol Obstet.* 2010; 282(2): 193–197, doi: [10.1007/s00404-009-1316-5](https://doi.org/10.1007/s00404-009-1316-5), indexed in Pubmed: [20012636](https://pubmed.ncbi.nlm.nih.gov/20012636/).
21. Wright TC, Massad LS, Dunton CJ, et al. 2006 American Society for Colposcopy and Cervical Pathology-sponsored Consensus Conference. 2006 consensus guidelines for the management of women with cervical intraepithelial neoplasia or adenocarcinoma in situ. *J Low Genit Tract Dis.* 2007; 11(4): 223–239, doi: [10.1097/LGT.0b013e318159408b](https://doi.org/10.1097/LGT.0b013e318159408b), indexed in Pubmed: [17917567](https://pubmed.ncbi.nlm.nih.gov/17917567/).
22. Costa S, Simone P, Venturoli S, et al. Factors predicting human papillomavirus clearance in cervical intraepithelial neoplasia lesions treated by conization. *Gynecologic Oncology.* 2003; 90(2): 358–365, doi: [10.1016/s0090-8258\(03\)00268-3](https://doi.org/10.1016/s0090-8258(03)00268-3).
23. Sarian LO, Derchain SF, Pitta Dd, et al. Factors associated with HPV persistence after treatment for high-grade cervical intra-epithelial neoplasia with large loop excision of the transformation zone (LLETZ). *J Clin Virol.* 2004; 31(4): 270–274, doi: [10.1016/j.jcv.2004.05.012](https://doi.org/10.1016/j.jcv.2004.05.012), indexed in Pubmed: [15494268](https://pubmed.ncbi.nlm.nih.gov/15494268/).
24. Debarge V, Collinet P, Vinatier D, et al. Value of human papillomavirus testing after conization by loop electrosurgical excision for high-grade squamous intraepithelial lesions. *Gynecologic Oncology.* 2003; 90(3): 587–592, doi: [10.1016/s0090-8258\(03\)00372-x](https://doi.org/10.1016/s0090-8258(03)00372-x).
25. Alonso I, Torné A, Puig-Tintoré LM, et al. Pre- and post-conization high-risk HPV testing predicts residual/recurrent disease in patients treated for CIN 2-3. *Gynecol Oncol.* 2006; 103(2): 631–636, doi: [10.1016/j.ygyno.2006.04.016](https://doi.org/10.1016/j.ygyno.2006.04.016), indexed in Pubmed: [16780934](https://pubmed.ncbi.nlm.nih.gov/16780934/).

26. Bruno MT, Cassaro N, Garofalo S, et al. HPV16 persistent infection and recurrent disease after LEEP. *Virology*. 2019; 16(1): 148, doi: [10.1186/s12985-019-1252-3](https://doi.org/10.1186/s12985-019-1252-3), indexed in Pubmed: [31775792](https://pubmed.ncbi.nlm.nih.gov/31775792/).
27. Kang WD, Oh MJ, Kim SM, et al. Significance of human papillomavirus genotyping with high-grade cervical intraepithelial neoplasia treated by a loop electrosurgical excision procedure. *Am J Obstet Gynecol*. 2010; 203(1): 72.e1–72.e6, doi: [10.1016/j.ajog.2010.01.063](https://doi.org/10.1016/j.ajog.2010.01.063), indexed in Pubmed: [20417477](https://pubmed.ncbi.nlm.nih.gov/20417477/).

Table 1. Descriptive characteristics of the study group

Characteristics	Category	Value
Evaluated patients, <i>n</i>		31
Mean age at evaluation, <i>years</i>		33
Area of residence, <i>n (%)</i>	> 100.000 inhabitants	13 (42)
	≤ 100.000 inhabitants	18 (58)
Thyroid disease, <i>n (%)</i>	Present	5 (16)
	Absent	26 (84)
Parity, <i>n (%)</i> of children	0	14 (45.2)
	1–2	13 (42)
	≥ 3	4 (12.9)

¹The percentage was calculated by subtracting the remaining % values from 100%

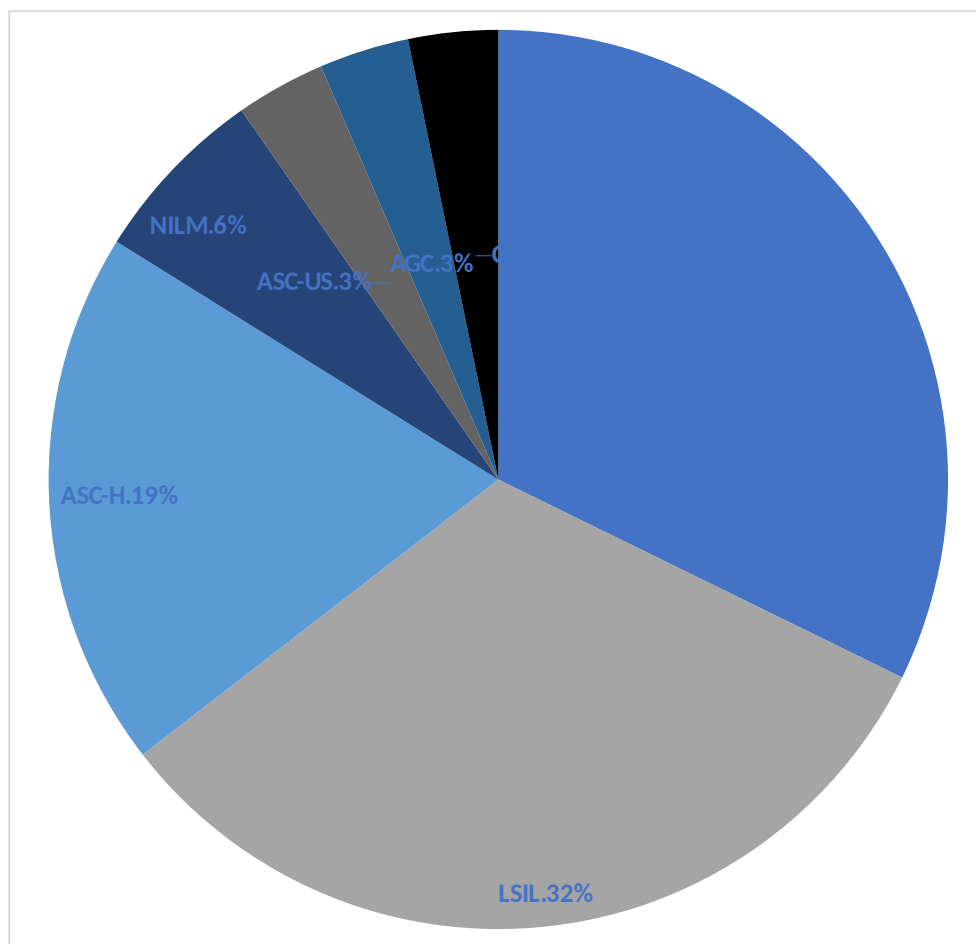


Figure 1. Pap-smear results

Table 2. Occurrence of HPV genotypes within positive genotyping results.

HPV type [†]	Before treatment ¹ ,	After treatment ² ,
	<i>n</i> (%)	<i>n</i> (%)
16	17 (29.8)	1 (5.9)
58	4 (7)	1 (5.9)
73	4 (7)	1 (5.9)
31	3 (5.29)	0 (0)
33	3 (5.29)	0 (0)
45	3 (5.29)	2 (11.7)
53	3 (5.29)	2 (11.7)
66	3 (5.29)	1 (5.9)
6	2 (3.5)	0 (0)
11	2 (3.5)	0 (0)
51	2 (3.5)	1 (5.9)
54	2 (3.5)	1 (5.9)
18	1 (1.75)	0 (0)
35	1 (1.75)	0 (0)
52	1 (1.75)	0 (0)

56	1 (1.75)	1 (5.9)
59	1 (1.75)	2 (11.7)
61	1 (1.75)	0 (0)
62	1 (1.75)	0 (0)
68	1 (1.75)	1 (5.9)
82	1 (1.75)	1 (5.9)
90	0 (0)	1 (5.9)
70	0 (0)	1 (5.9)

† The patients could test positive for 1 or more HPV genotypes

¹ A total number of HPV genotypes detected among 29 cases: 57

² A total number of HPV genotypes detected among 11 cases: 17

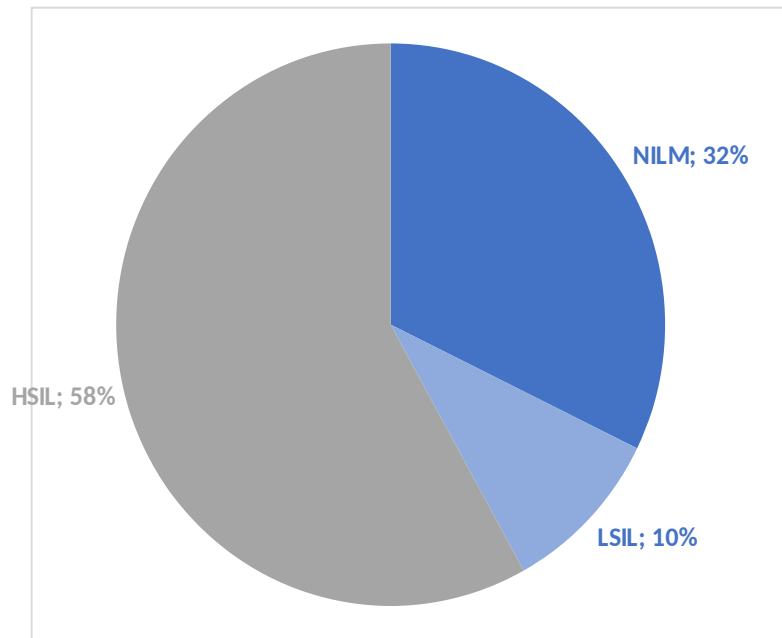


Figure 2. Histopathological results after LEEP-conization

Table 3. Occurrence of HPV infection after LEEP-conization

Characteristics	Category	HPV status		Total	p-value
		Positive	Negative		
All cases		11 (35.5)	20 (64.5)	31 (100)	
Ectocervix margin	Positive	3 (37.5)	5 (62.5)	8 (100)	0.643
	Negative	6 (26.1)	17 (73.9)	23 (100)	
Cervical canal margin	Positive	0 (0)	1 (100)	1 (100)	1.000
	Negative	9 (30)	21 (70)	30 (100)	

Data given as a number of cases (percent)