

ONLINE FIRST

This is a provisional PDF only. Copyedited and fully formatted version will be made available soon.



P O L I S H G Y N E C O L O G Y

GINEKOLOGIA POLSKA

ORGAN POLSKIEGO TOWARZYSTWA GINEKOLOGICZNEGO
THE OFFICIAL JOURNAL OF THE POLISH GYNECOLOGICAL SOCIETY

ISSN: 0017-0011

e-ISSN: 2543-6767

Endovascular embolization as a treatment for symptomatic adenomyosis – results of preliminary study

Authors: Krzysztof Pyra, Maciej Szmygin, Hanna Szmygin, Viktor Bèrczi, Rafał Kidziński, Tomasz Jargiełło, Tomasz Paszkowski, Sławomir Woźniak

DOI: 10.5603/GP.a2021.0136

Article type: Research paper

Submitted: 2021-06-09

Accepted: 2021-06-11

Published online: 2021-07-06

This article has been peer reviewed and published immediately upon acceptance. It is an open access article, which means that it can be downloaded, printed, and distributed freely, provided the work is properly cited.

Articles in "Ginekologia Polska" are listed in PubMed.

Endovascular embolization as a treatment for symptomatic adenomyosis — results of preliminary study

Krzysztof Pyra¹, Maciej Szmygin¹, Hanna Szmygin², Viktor Bèrczi³, Rafal Kidzinski⁴, Tomasz Jargiello¹, Tomasz Paszkowski⁵, Sławomir Wozniak⁵

¹*Department of Interventional Radiology and Neuroradiology, Medical University of Lublin, Poland*

²*Department of Endocrinology, Medical University in Lublin, Poland*

³*Semmelweis University, Department of Radiology, Hungary*

⁴*Department of Radiology, Medicover Hospital in Warsaw, Poland*

⁵*3rd Chair and Department of Gynecology, Medical University in Lublin, Poland*

Short title: Embolization for symptomatic adenomyosis

Corresponding author:

Maciej Szmygin

Department of Interventional Radiology and Neuroradiology, Medical University of Lublin, Poland

e-mail: mszmygin@gmail.com

ABSTRACT

Objectives: To present preliminary results of minimally invasive endovascular embolization as a treatment of symptomatic adenomyosis or adenomyosis with fibroids and to assess the long-term clinical outcome.

Material and methods: Between 2015 and 2020 twelve patients with symptomatic adenomyosis or adenomyosis with fibroids underwent uterine artery embolization (UAE). All patients were evaluated in terms of patient's overall satisfaction, relief of clinical symptoms, reintervention and hysterectomy as well as menopause rates.

Results: Mean age on admission was 48 years. Reported symptoms included: dysmenorrhea with the mean VAS score of 7.8, menorrhagia and problems with urination. Successful embolization was achieved in all patients (100%). A reduction in pelvic pain intensity assessed using VAS was observed in 11/12 (92%) of the patients — pain decreased by 6.2 points on average (from 7.8 to 1.6 pts). In one patient (8%) the recurrence of pain was

observed. All patients reported decrease of menstrual bleeding and consequently improvement of everyday life quality. Avoidance of hysterectomy was achieved in 83% of the women. Five patients experience absence of menstrual periods for at least 12 months after the embolization resulting in menopause rate of 42%. Ten patients (83%) reported to be very or fairly satisfied with the results and would recommend this treatment to a friend.

Conclusions: Uterine artery embolization might be safe and effective method of treatment for patients with symptomatic adenomyosis with or without fibroids with very high rate of satisfied patients.

Key words: uterine artery embolization; adenomyosis; long-term results; minimally invasive

INTRODUCTION

Adenomyosis describes a benign uterine disorder in which endometrial glandular tissue is located within the uterine myometrium [1]. The most common clinical presentations of adenomyosis include cyclical uterine pain, abnormal menstrual bleeding and infertility [2]. Additionally, adenomyosis often co-exists with other uterine disorders, most commonly leiomyoma, endometriosis and endometrial polyps which makes the diagnosis challenging and difficult [3]. Traditionally, adenomyosis was associated with multiparous middle-aged woman suffering from menorrhagia, however, with recent availability and accessibility of advanced imaging techniques especially magnetic resonance imaging (MRI) and transvaginal ultrasound (TVUS), it is now diagnosed in young patients with wide range of clinical symptoms or even asymptomatic patients [4, 5]. Nonetheless, adenomyosis remains under-reported and under-diagnosed with estimated prevalence of 35–40% according to some authors [6]. Treatment modalities include surgical, pharmacological and minimally invasive methods. Hysterectomy which is the definitive cure is not an option for women willing to preserve their fertility. Conservative treatment focuses on either inhibition of enzymes producing the prostaglandins responsible for painful cramping during menstruation (non-steroidal anti-inflammatory drugs) or endometrial proliferation inhibiting drugs (*e.g.*, oral contraceptive pills, levonorgestrel, danazol and aromatase inhibitors) [7, 8]. Minimally invasive interventional radiological procedures are promising therapies for patients who desire future fertility. They include thermal ablation (MRI or ultrasound-guided) and uterine artery embolization (UAE) [9–11]. Long-term follow-up showed that patients with symptomatic adenomyosis who underwent UAE reported high rate of clinical improvement and avoided hysterectomy in over 80% of cases [12].

Objectives

The aim of this study is to present our experience with UAE as a treatment of symptomatic adenomyosis or adenomyosis with fibroids and to assess the long-term clinical outcome.

MATERIAL AND METHODS

This retrospective preliminary study was conducted in a clinical hospital in Poland. It evaluated 12 patients with symptomatic adenomyosis or adenomyosis with fibroids who presented between 2015 and 2020 and underwent UAE. All procedures were performed in accordance with the institutional ethical standards and with the 1964 Helsinki Declaration. Informed consent was obtained from all individual participants included in the study.

All patients with adenomyosis with or without concomitant fibroids were assessed for treatment by an experienced gynecologist. After obtaining a medical history, baseline symptoms were categorized into following categories: menstrual bleeding characteristics, pelvic pain (assessed by VAS score from 0 to 10 — 0 representing lack of pain and 10 unbearable pain), urinary discomfort and health-related quality of life items (limitations in daily activities, energy/mood, self-consciousness and sexual function). Afterwards, each patient underwent physical examination and TVUS followed by an MRI study. All data was then evaluated by an interventional radiologist for possible endovascular treatment. Additional laboratory tests included platelet count, clotting time and renal functions markers (creatinine and glomerular filtration rate) were performed. The methods and procedures used in this study comply with the ethical standards. The study was conducted according to the Helsinki Declaration.

Endovascular embolization

All endovascular procedures were carried out in the angio suite with a digital subtraction angiography (DSA) system (Artis Zee, Siemens AG, Erlangen, Germany). In local anesthesia femoral artery was punctured and bilateral selective catheterization of uterine arteries was performed using a coaxial system microcatheter. Embolization was performed with microspheres (500–900 µm) until complete stasis of contrast media in the distal ascending segment of the uterine artery on both sides. During the procedure, additional analgesic treatment (ketoprofen, paracetamol and morphine) was administered if needed. Following the procedure all patients received additional analgesic treatment and were monitored at the Department of Gynecology.

Follow-up

Clinical outcome was assessed based on a direct contact with a patient or structured telephone survey during the long-term follow-up period (range from 4 to 58 months). The evaluation included: patient's overall satisfaction, relief of clinical symptoms, reintervention and hysterectomy as well as menopause rates. We also inquired whether the patient would recommend this treatment to a friend.

RESULTS

A total of 12 patients met the inclusion criteria. Mean age on admission was 48 years (from 39 to 56). Four patients (33%) were diagnosed with pure adenomyosis and eight (67%) with adenomyosis with fibroids. Six patients (50%) had history of pregnancy and labor. Reported symptoms included: dysmenorrhea (92%) with the mean VAS score of 7.8 (range from 6 to 10), menorrhagia with menstrual clots (58%), menorrhagia without menstrual clots (33%) and problems with urination (8%). As far as health-related quality of life items were concerned, 50% of women complained about limitation of daily activities and low energy due to heavy menstrual bleeding and 33% had problems with their sexual life. Successful embolization was achieved in all patients (100%). There were no major procedure-related complications. On average patients spent two days in the hospital.

A reduction in pelvic pain intensity assessed using VAS was observed in 11/12 (92%) of the patients - pain decreased by 6.2 points on average (from 7.8 to 1.6 pts) in the follow-up period (from 4 to 58 months, mean 39 months). In one patient (8%) the recurrence of pain was observed two months after the embolization. This patient required hysterectomy. All patients reported decrease of menstrual bleeding and consequently improvement of everyday life quality. In one patient the decrease was not satisfactory, and she underwent secondary hysterectomy. Thus, avoidance of hysterectomy was achieved in 83% of the women. Five patients experience absence of menstrual periods for at least 12 months after the embolization resulting in menopause rate of 42%. Most patients (10/12, 83%) reported to be very or fairly satisfied with the results and would recommend this treatment to a friend.

Demographic details and long-term results are presented in Table 1.

DISCUSSION

Adenomyosis remains a problematic diagnosis due to its variable presentation and common coexistence of other gynecologic disorders. Contrast-enhanced MRI and transvaginal ultrasound are currently the most accurate imaging techniques for the diagnosis

of adenomyosis [13]. Although hysterectomy is considered the only definite treatment both hormonal and minimally invasive embolization treatments are widely implemented. The former aims to reduce the junctional zone thickness whereas the latter results in the reduction of uterine volume [14, 15]. Both therapeutic approaches are reported to be successful, especially in view of the short-term results [16, 17]. However, according to Pelage et al., even if short-term results of endovascular treatment of patients with adenomyosis are promising, the long-term clinical outcome is disappointing and nearly 50% of treated patients do not show clinical improvement [18]. Similarly, authors of a study which included 54 patients with symptomatic adenomyosis treated with UAE observed a recurrence rate of 38% [19].

On the other hand, authors of a study who evaluated seven-year clinical results of UAE among patients with symptomatic adenomyosis using UFS-Qol questionnaire observed that 76% of the patients reported to be asymptomatic [12]. Similarly high rate of symptom improvement was achieved by Bae et al. [20], who followed up 50 patients with pure adenomyosis for four years after endovascular treatment. In our study, all patients reported decrease of menstrual pain although in one case the decrease was not satisfactory. Average VAS score after the treatment was 1.6 which corresponded to mild pain (decrease from average 6.2 points before the embolization which corresponded to moderate/severe pain) [21]. Overall effectiveness of UAE appears to be higher compared to conservative surgical methods which include endomyometrial ablation/resection and laparoscopic myometrial electrocoagulation [22].

In terms of patients who undergo hysterectomy despite the endovascular treatment, the results range from 10 to 28% according to above-mentioned studies [12,19,20]. Our results confirm these findings — avoidance of hysterectomy was achieved in 83% (2/12) of the patients. Thus, the mean failure rate is comparable with other minimally invasive surgical methods [23].

In our study, we observed the occurrence of menopause in 42% of patients within first year after embolization. Premature induction of menopause and subclinical diminution of ovarian functional reserve after UAE is a known complication of endovascular treatment [24]. However, one should keep in mind, that the mean age of followed-up patients was 48 (range from 39 to 56) with only one patient younger than 40 years, whereas the average age of women for reaching menopause is 51 years in countries like Poland [25].

We are aware that our study has limitations. First and foremost, the relatively small group of patients which limits the validity of data, and which makes strong conclusions hazardous. In addition to that, the small sample size precludes more detailed statistical

analysis. Finally, heterogeneity of analyzed patients. When adenomyosis occurs with uterine fibroids occur, it is very difficult to determine if the symptoms are caused by one disorder or another. Since pure adenomyosis is a relatively rare condition, we also included the patients with coexistent fibroids.

CONCLUSIONS

In conclusion, despite the limited number of patients, our preliminary study showed promising results confirming that uterine artery embolization might be a safe and effective method of treatment for patients with symptomatic adenomyosis with or without fibroids with very high rate of satisfied patients.

Conflict of interest

The authors declare that they have no conflict of interest.

Financial founding

The authors received no financial founding.

Ethical approval

All procedures performed in studies involving human participants were in accordance with the ethical standards of the institutional and/or national research committee and with the 1964 Helsinki declaration and its later amendments or comparable ethical standards.

Informed consent

Informed consent was obtained from all individual participants included in the study.

Contributions

All authors contributed significantly to the paper: MSZ, KP, HS and SW evaluated the data and prepared the manuscript. KP, MSZ, SW, TJ and TP participated in described procedures. All authors approved the final version of the manuscript.

REFERENCES

1. Struble J, Reid S, Bedaiwy MA. Adenomyosis: A Clinical Review of a Challenging Gynecologic Condition. *J Minim Invasive Gynecol.* 2016; 23(2): 164–185, doi: [10.1016/j.jmig.2015.09.018](https://doi.org/10.1016/j.jmig.2015.09.018), indexed in Pubmed: [26427702](https://pubmed.ncbi.nlm.nih.gov/26427702/).
2. Yu O, Schulze-Rath R, Grafton J, et al. Adenomyosis incidence, prevalence and treatment: United States population-based study 2006-2015. *Am J Obstet Gynecol.* 2020; 223(1): 94.e1–94.e10, doi: [10.1016/j.ajog.2020.01.016](https://doi.org/10.1016/j.ajog.2020.01.016), indexed in Pubmed: [31954156](https://pubmed.ncbi.nlm.nih.gov/31954156/).
3. McElin TW, Bird CC. Adenomyosis of the uterus. *Obstet Gynecol Annu.* 1974; 3: 425–441.
4. Chapron C, Vannuccini S, Santulli P, et al. Diagnosing adenomyosis: an integrated clinical and imaging approach. *Hum Reprod Update.* 2020; 26(3): 392–411, doi: [10.1093/humupd/dmz049](https://doi.org/10.1093/humupd/dmz049), indexed in Pubmed: [32097456](https://pubmed.ncbi.nlm.nih.gov/32097456/).
5. Pinzauti S, Lazzeri L, Tosti C, et al. Transvaginal sonographic features of diffuse adenomyosis in 18-30-year-old nulligravid women without endometriosis: association with symptoms. *Ultrasound Obstet Gynecol.* 2015; 46(6): 730–736, doi: [10.1002/uog.14834](https://doi.org/10.1002/uog.14834), indexed in Pubmed: [25728241](https://pubmed.ncbi.nlm.nih.gov/25728241/).
6. Abbott JA. Adenomyosis and Abnormal Uterine Bleeding (AUB-A)-Pathogenesis, diagnosis, and management. *Best Pract Res Clin Obstet Gynaecol.* 2017; 40: 68–81, doi: [10.1016/j.bpobgyn.2016.09.006](https://doi.org/10.1016/j.bpobgyn.2016.09.006), indexed in Pubmed: [27810281](https://pubmed.ncbi.nlm.nih.gov/27810281/).
7. Marjoribanks J, Proctor ML, Farquhar C. Nonsteroidal anti-inflammatory drugs for primary dysmenorrhoea. *Cochrane Database Syst Rev.* 2003(4): CD001751, doi: [10.1002/14651858.CD001751](https://doi.org/10.1002/14651858.CD001751), indexed in Pubmed: [14583938](https://pubmed.ncbi.nlm.nih.gov/14583938/).
8. Farquhar C, Brosens I. Medical and surgical management of adenomyosis. *Best Pract Res Clin Obstet Gynaecol.* 2006; 20(4): 603–616, doi: [10.1016/j.bpobgyn.2006.01.012](https://doi.org/10.1016/j.bpobgyn.2006.01.012), indexed in Pubmed: [16563872](https://pubmed.ncbi.nlm.nih.gov/16563872/).
9. Zhou M, Chen JY, Tang LD, et al. Ultrasound-guided high-intensity focused ultrasound ablation for adenomyosis: the clinical experience of a single center. *Fertil*

Steril. 2011; 95(3): 900–905, doi: [10.1016/j.fertnstert.2010.10.020](https://doi.org/10.1016/j.fertnstert.2010.10.020), indexed in Pubmed: [21067723](https://pubmed.ncbi.nlm.nih.gov/21067723/).

10. Kim KA, Yoon SW, Lee C, et al. Short-term results of magnetic resonance imaging-guided focused ultrasound surgery for patients with adenomyosis: symptomatic relief and pain reduction. *Fertil Steril*. 2011; 95(3): 1152–1155, doi: [10.1016/j.fertnstert.2010.09.024](https://doi.org/10.1016/j.fertnstert.2010.09.024), indexed in Pubmed: [20970127](https://pubmed.ncbi.nlm.nih.gov/20970127/).
11. Smeets AJ, Nijenhuis RJ, Boekkooi PF, et al. Long-term follow-up of uterine artery embolization for symptomatic adenomyosis. *Cardiovasc Intervent Radiol*. 2012; 35(4): 815–819, doi: [10.1007/s00270-011-0203-1](https://doi.org/10.1007/s00270-011-0203-1), indexed in Pubmed: [21717251](https://pubmed.ncbi.nlm.nih.gov/21717251/).
12. de Bruijn AM, Smink M, Hehenkamp WJK, et al. Uterine Artery Embolization for Symptomatic Adenomyosis: 7-Year Clinical Follow-up Using UFS-Qol Questionnaire. *Cardiovasc Intervent Radiol*. 2017; 40(9): 1344–1350, doi: [10.1007/s00270-017-1686-1](https://doi.org/10.1007/s00270-017-1686-1), indexed in Pubmed: [28516272](https://pubmed.ncbi.nlm.nih.gov/28516272/).
13. Ascher SM, Arnold LL, Patt RH, et al. Adenomyosis: prospective comparison of MR imaging and transvaginal sonography. *Radiology*. 1994; 190(3): 803–806, doi: [10.1148/radiology.190.3.8115630](https://doi.org/10.1148/radiology.190.3.8115630), indexed in Pubmed: [8115630](https://pubmed.ncbi.nlm.nih.gov/8115630/).
14. Wood C. Surgical and medical treatment of adenomyosis. *Hum Reprod Update*. 1998; 4(4): 323–336, doi: [10.1093/humupd/4.4.323](https://doi.org/10.1093/humupd/4.4.323), indexed in Pubmed: [9825848](https://pubmed.ncbi.nlm.nih.gov/9825848/).
15. Siskin GP, Tublin ME, Stainken BF, et al. Uterine artery embolization for the treatment of adenomyosis: clinical response and evaluation with MR imaging. *AJR Am J Roentgenol*. 2001; 177(2): 297–302, doi: [10.2214/ajr.177.2.1770297](https://doi.org/10.2214/ajr.177.2.1770297), indexed in Pubmed: [11461849](https://pubmed.ncbi.nlm.nih.gov/11461849/).
16. Kim MD, Won JW, Lee DY, et al. Uterine artery embolization for adenomyosis without fibroids. *Clin Radiol*. 2004; 59(6): 520–526, doi: [10.1016/j.crad.2003.11.018](https://doi.org/10.1016/j.crad.2003.11.018), indexed in Pubmed: [15145722](https://pubmed.ncbi.nlm.nih.gov/15145722/).
17. Jha RC, Takahama J, Imaoka I, et al. Adenomyosis: MRI of the uterus treated with uterine artery embolization. *AJR Am J Roentgenol*. 2003; 181(3): 851–856, doi: [10.2214/ajr.181.3.1810851](https://doi.org/10.2214/ajr.181.3.1810851), indexed in Pubmed: [12933493](https://pubmed.ncbi.nlm.nih.gov/12933493/).

18. Pelage JP, Jacob D, Fazel A, et al. Midterm results of uterine artery embolization for symptomatic adenomyosis: initial experience. *Radiology*. 2005; 234(3): 948–953, doi: [10.1148/radiol.2343031697](https://doi.org/10.1148/radiol.2343031697), indexed in Pubmed: [15681687](https://pubmed.ncbi.nlm.nih.gov/15681687/).
19. Kim MD, Kim S, Kim NK, et al. Long-term results of uterine artery embolization for symptomatic adenomyosis. *AJR Am J Roentgenol*. 2007; 188(1): 176–181, doi: [10.2214/AJR.05.1613](https://doi.org/10.2214/AJR.05.1613), indexed in Pubmed: [17179361](https://pubmed.ncbi.nlm.nih.gov/17179361/).
20. Bae SH, Kim MD, Kim GM, et al. Uterine Artery Embolization for Adenomyosis: Percentage of Necrosis Predicts Midterm Clinical Recurrence. *J Vasc Interv Radiol*. 2015; 26(9): 1290–6.e2, doi: [10.1016/j.jvir.2015.04.026](https://doi.org/10.1016/j.jvir.2015.04.026), indexed in Pubmed: [26074028](https://pubmed.ncbi.nlm.nih.gov/26074028/).
21. Haefeli M, Elfering A. Pain assessment. *Eur Spine J*. 2006; 15 Suppl 1: S17–S24, doi: [10.1007/s00586-005-1044-x](https://doi.org/10.1007/s00586-005-1044-x), indexed in Pubmed: [16320034](https://pubmed.ncbi.nlm.nih.gov/16320034/).
22. Wood C. Surgical and medical treatment of adenomyosis. *Hum Reprod Update*. 1998; 4(4): 323–336, doi: [10.1093/humupd/4.4.323](https://doi.org/10.1093/humupd/4.4.323), indexed in Pubmed: [9825848](https://pubmed.ncbi.nlm.nih.gov/9825848/).
23. Litta P, Nappi L, Florio P, et al. Proposal of a modified transcervical endometrial resection (TCER) technique for menorrhagia treatment. Feasibility, efficacy, and patients' acceptability. *Gynecol Surg*. 2014; 11(3): 165–171, doi: [10.1007/s10397-014-0844-6](https://doi.org/10.1007/s10397-014-0844-6).
24. Kaump GR, Spies JB. The impact of uterine artery embolization on ovarian function. *J Vasc Interv Radiol*. 2013; 24(4): 459–467, doi: [10.1016/j.jvir.2012.12.002](https://doi.org/10.1016/j.jvir.2012.12.002), indexed in Pubmed: [23384832](https://pubmed.ncbi.nlm.nih.gov/23384832/).
25. Treloar AE. Menstrual cyclicity and the pre-menopause. *Maturitas*. 1981; 3(3-4): 249–264, doi: [10.1016/0378-5122\(81\)90032-3](https://doi.org/10.1016/0378-5122(81)90032-3), indexed in Pubmed: [7334935](https://pubmed.ncbi.nlm.nih.gov/7334935/).

Table 1. Demographic details and long-term results.

Patients — 12 (n, %)	Adenomyosis — 4, 33%	Adenomyosis with fibroids — 8, 67%
Demographic data		
Mean age (years) (min – max)	48 (39 to 56)	
History of pregnancy (n, %)	6, 50%	

Baseline symptoms	
Dysmenorrhea (n, %)	11, 92%
Menorrhagia with menstrual clots (n, %)	7, 58%
Menorrhagia without menstrual clots (n, %)	4, 33%
Problems with urination (n, %)	1, 8%
Limitation of daily activities (n, %)	6, 50%
Low energy	4, 33%
Clinical outcome	
Pain reduction (n, %)	11, 92%
Hysterectomy (n, %)	2, 17%
Decrease of menstrual bleeding (n, %)	12, 100%
Menopause (n, %)	5, 42%
Overall satisfaction (n, %)	10, 83%

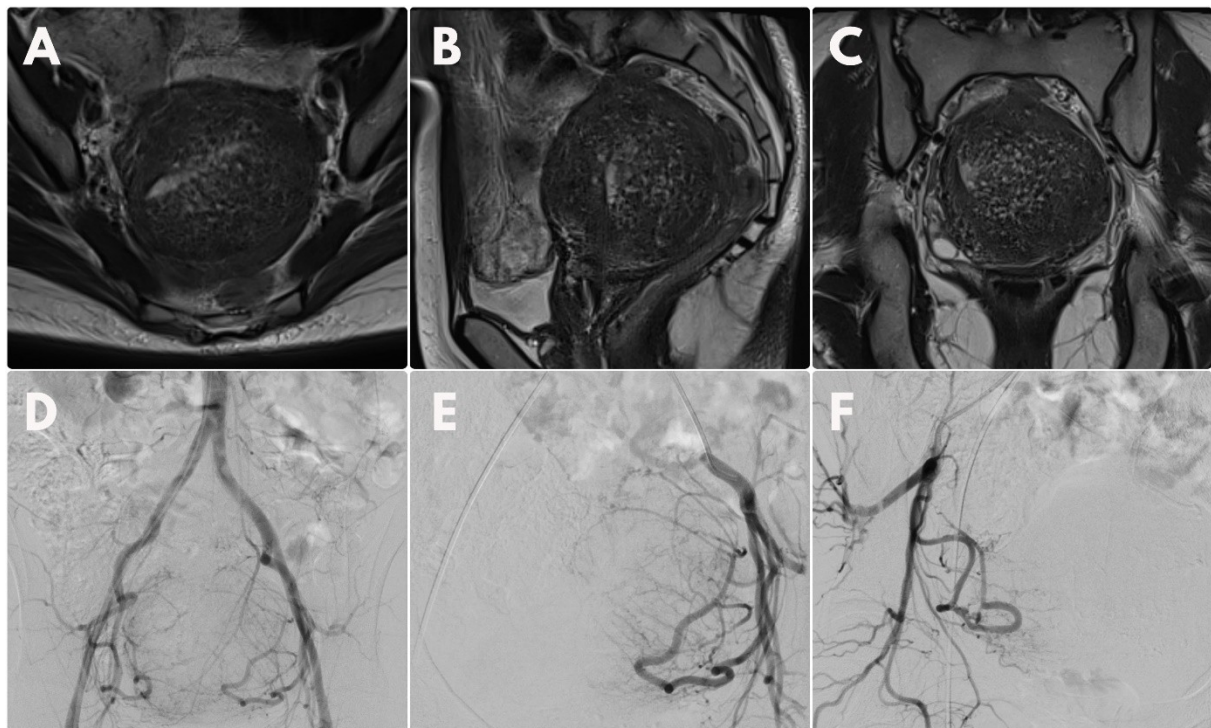


Figure 1. A–C. 45-year-old patient with adenomyosis confirmed by MRI; D. Initial angiography confirmed the presence of enlarged uterine arteries. Bilateral selective angiography of uterine arteries before embolization

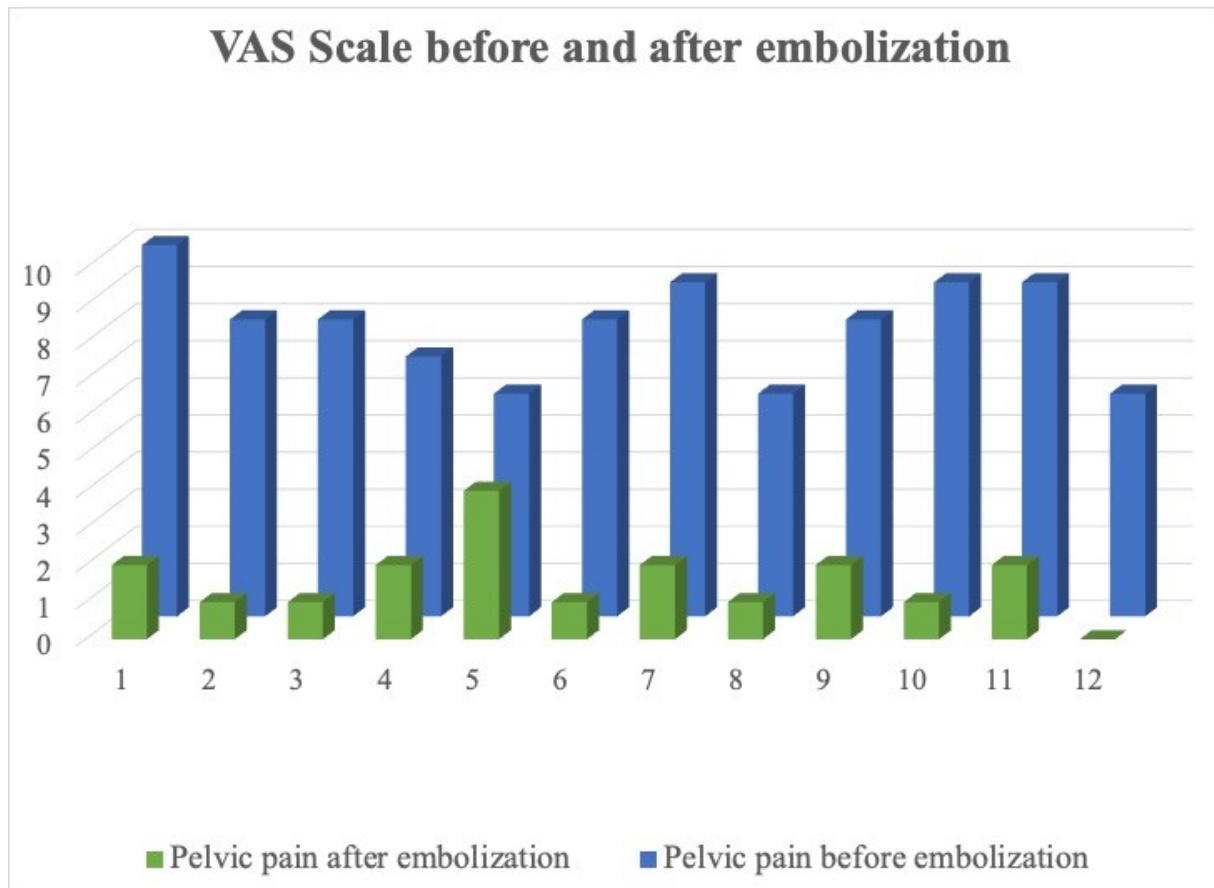


Figure 2. Rating VAS scale of the reported pelvic pain — before and after embolization